

An unusual case of lymphadenopathy: case study

Katelynn Kinley, PA-S; Jeffrey Vasiloff, MD, MPH

Background

Localized lymphadenopathy in and near the head and neck has a wide differential diagnosis including **common benign conditions and less common serious diseases**. Common causes include reactive lymphadenopathy from a nearby infection (**strep throat, mono, CMV, toxoplasmosis, acute HIV, cat scratch disease**). TB and atypical mycobacteria can also cause cervical lymphadenopathy, as well as systemic lupus erythematosus, as well as lymphoma and **cancers of the head and neck**. We present a case of patient with **localized lymphadenopathy and pain for 6 weeks**.

Case

A 52-year-old male presented to his primary care office with swelling in his right neck with associated pain x 6 weeks. Patient was **concerned for a pulled muscle** and had tried ibuprofen and ice without relief. His wife was concerned about a thyroid problem and suggested he see a doctor. With his PCP, he **denied sore throat, fever, cat scratches or bites, weight loss, and had no history of malignancy**. He had a 31-year history of smoking.

Physical Exam / Imaging

On exam he was a middle-aged man who **appeared well**. T 98.9, P75, R14, BP118/79. HEENT exam was unremarkable, but he had a 1.5 x 1 cm right supraclavicular mass that was extremely tender, soft, but not moveable. Thyroid exam was normal. He had no lymphadenopathy elsewhere nor any hepatosplenomegaly. **The rest of the exam was unremarkable**.

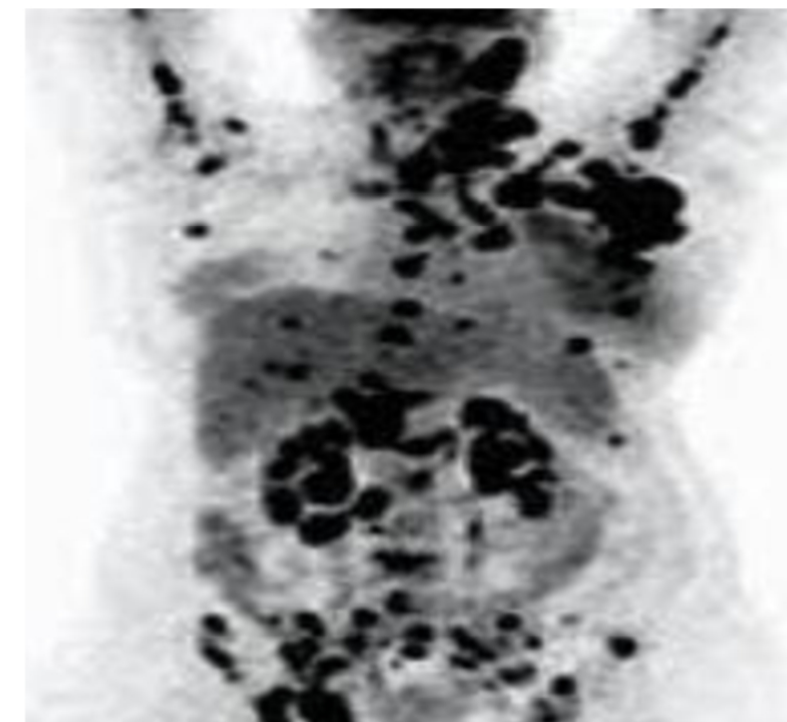
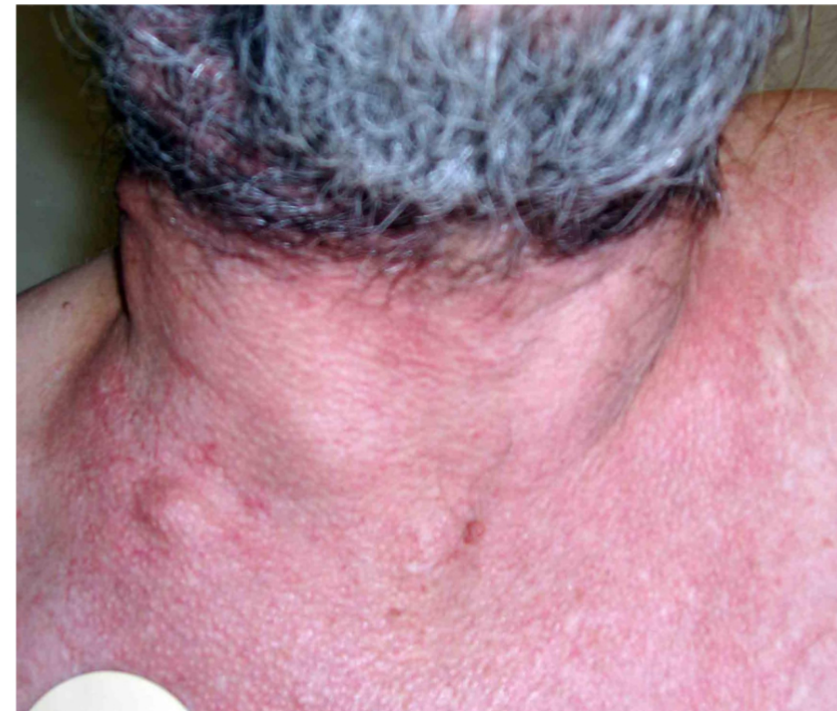Bloodwork was unremarkable. Chest X-ray was normal. **CT of the neck and chest revealed lymphadenopathy involving multiple thoracic compartments**.

He underwent fine-needle aspiration of the mass. Pathology revealed **adenocarcinoma**. The specimen was positive for TTF-1, cytokeratin AE 1-3, Ber-EP4, and MOC-31. PET scan revealed more extensive lymphadenopathy in the following areas: **cervical, internal mammary, right subpectoral, mediastinum, and hila, as well as some bone metastases**. No primary lung mass was seen.

Diagnosis and Treatment

He was diagnosed with adenocarcinoma of unknown primary; however, it was speculated that the origin was most likely the lung. He received cycles of carboplatin, Taxol, and Avastin.

Example of Supraclavicular Lymphadenopathy



Widespread disease on PET/CT scan typically found at diagnosis in patients with CUP.

Final Disposition

His clinical course was complicated by DVTs and PEs, and he ultimately succumbed from his disease 18 months after diagnosis.

Discussion

Carcinoma of unknown primary (CUP) is a catastrophic illness that is poorly understood. CUP is a heterogeneous disease of varying subtypes including **adenocarcinoma** (70% of cases); undifferentiated cancer (20-25%), squamous cell carcinoma (5%); and neuroendocrine cancers (1%). Treatment is directed toward the suspected primary. **The primary identification is made better by advances in immunohistochemistry as well as molecular cancer classifier assays**. Moving forward, earlier diagnosis is paramount to improve prognosis for patients with CUP. Fortunately, with screening for lung cancer in heavy smokers, and the recent development of liquid biopsies, there is hope for improved morbidity and mortality, and ultimately better outcomes in cases of CUP.