

**X-RAY REVIEW OF COMMON FRACTURES WORKSHOP**  
**AAPA ANNUAL CONFERENCE**  
**Indianapolis, Indiana**  
**May 24, 2022**

**Scott Frischknecht, PA-C**  
**Steve Kestlinger, PA-C**  
**Dennis Rivenburgh, PA-C**  
**Robert Thomas, PA-C**  
**Mary Vacala, PA-C**

**I. Types of Fractures**

A. Transverse

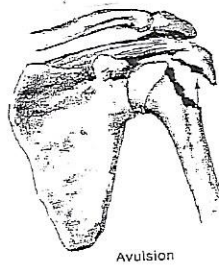
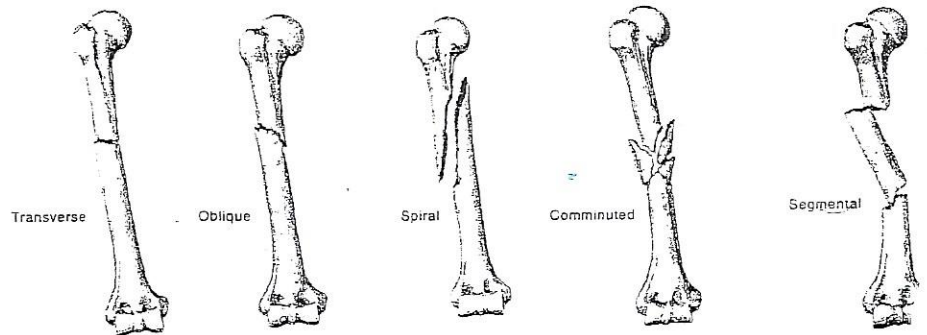
B. Oblique

C. Spiral

D. Comminuted

E. Segmental

F. Avulsion




**II. Fracture Descriptions**

A. Open versus Closed fracture



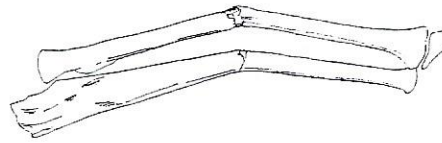
B. Extraarticular versus Intraarticular fracture



## V. Review of Pediatric Fractures

### A. Long bone fractures

#### 1. Greenstick fracture

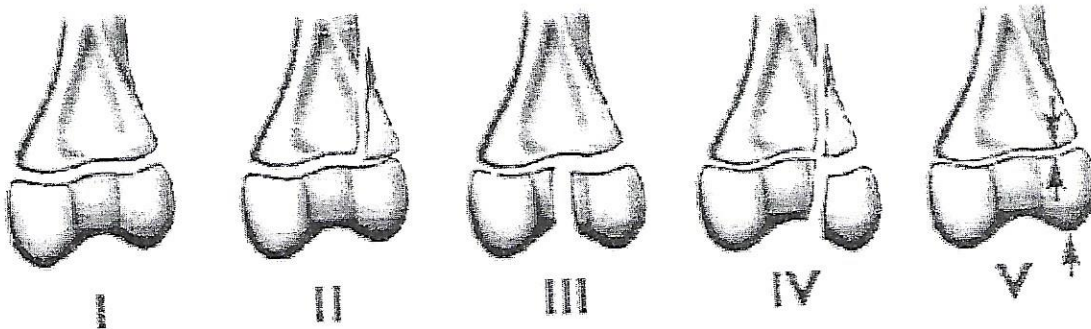


#### 2. Buckle (torus) fracture



B. Epiphyseal fractures are those which involve injury to the growth plate, which is the physis.

## VI. Salter-Harris Classification of growth plate fractures



Salter-Harris I - separation of the epiphysis from the metaphysis without any evidence of fracture fragment

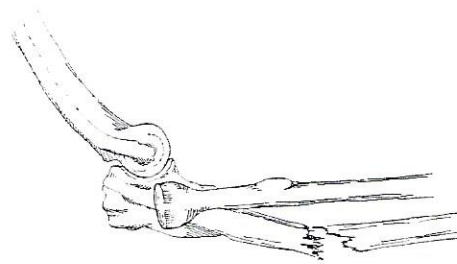
Salter-Harris II - fracture plane travels transversely through the physis and exits through the metaphysis: this is the most common type of epiphyseal fracture.

Salter-Harris III - - fracture extends along the growth plate and then exits directly through the epiphysis into the joint (this is an intraarticular fracture)

Salter-Harris IV - fracture extends longitudinally as a vertical split from the intraarticular surface across the epiphysis, through the physis, and then exits through the metaphysis

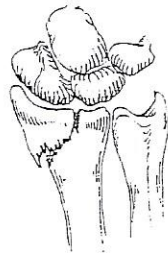Salter-Harris V - fracture occurs as a result of a severe crush injury to the growth plate (this is an impacted growth plate): this is the worst epiphyseal fracture

C. Fracture angulation: measured in degrees

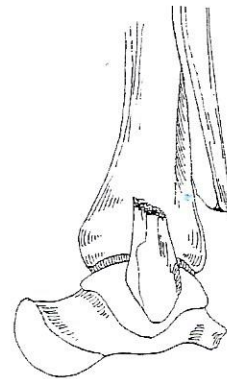


Example: 20 degrees

D. Fracture displacement: measured as a percent

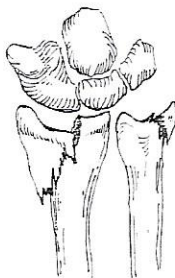


Example: 15%



Example: 100%

E. Fracture shortening: measured in mm or inches



Example: About 10mm

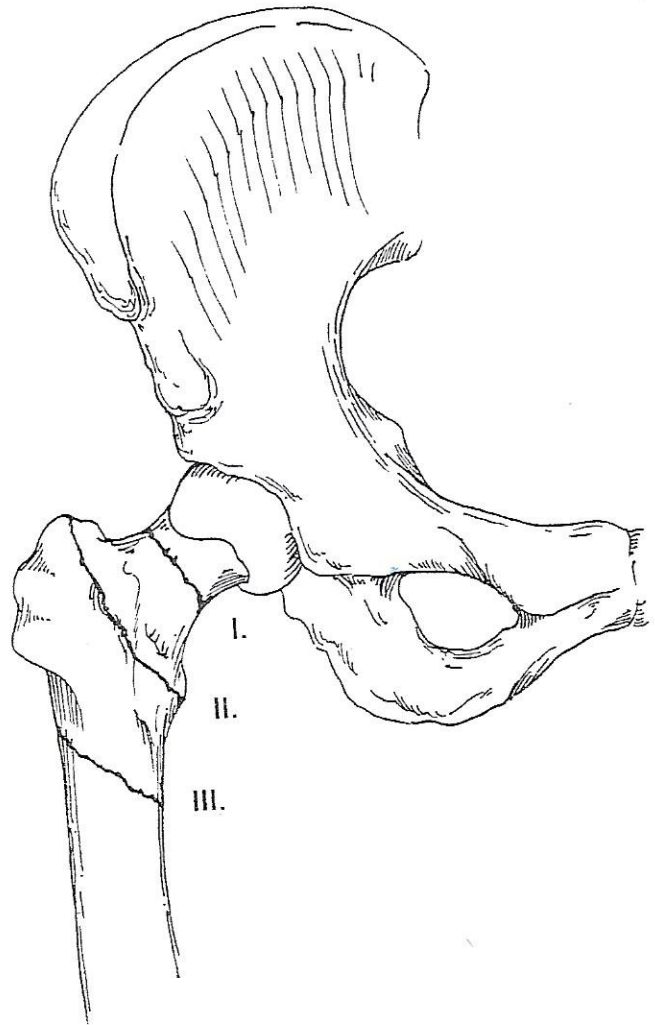
III. Always Obtain TWO X-ray views

IV. Review of Long Bone Anatomy

- A. Diaphysis – shaft of the bone
- B. Metaphysis – broad flare of the bone
- C. Physis – the growth plate
- D. Epiphysis – the end of the bone

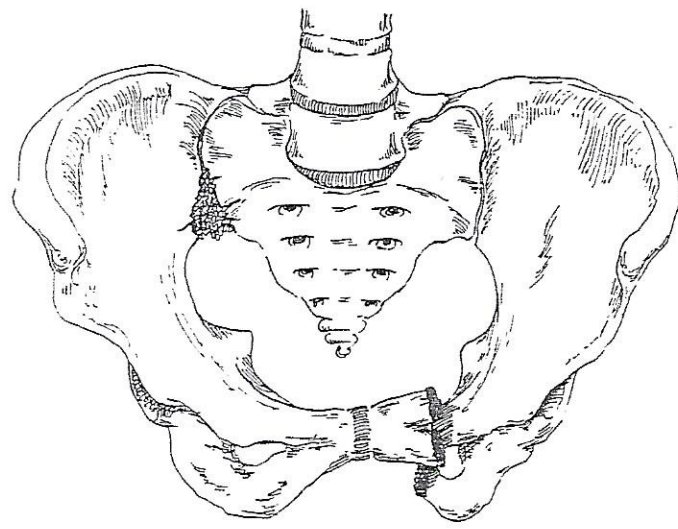
The Hip and Pelvis: Robert Thomas, PA-C

Femoral neck fracture (I.)



Intertrochanteric fracture (II.)

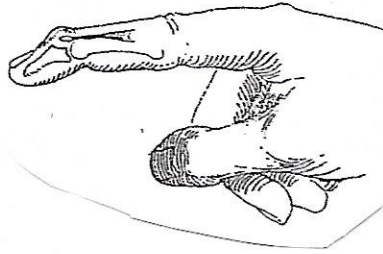
Subtrochanteric fracture (III.)



Pelvis fracture

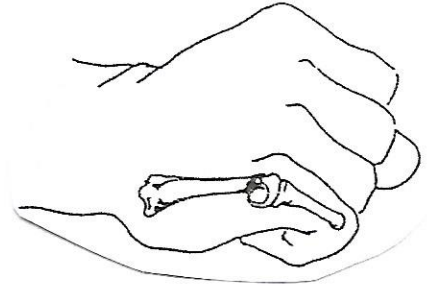
The Hand and Wrist: Dennis Rivenburgh, PA-C

Phalangeal fracture  
Mallet finger

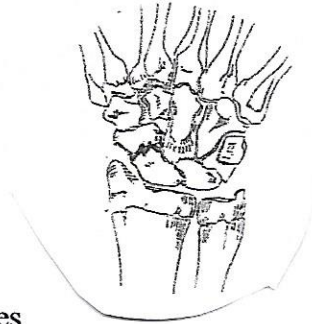


Metacarpal fracture

Boxer's fracture

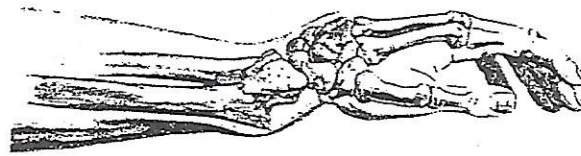


Scaphoid fracture

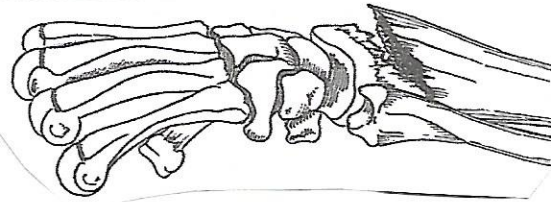


Distal Radius fractures

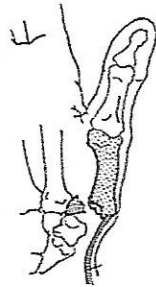
Colle's fracture



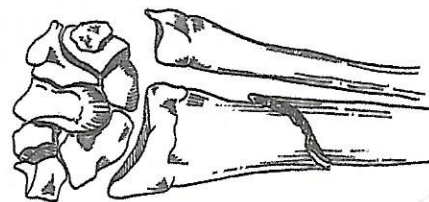
Smith's fracture



Bennett's fracture



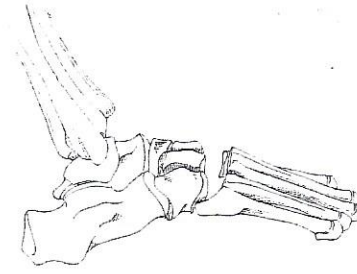
Galeazzi's fracture



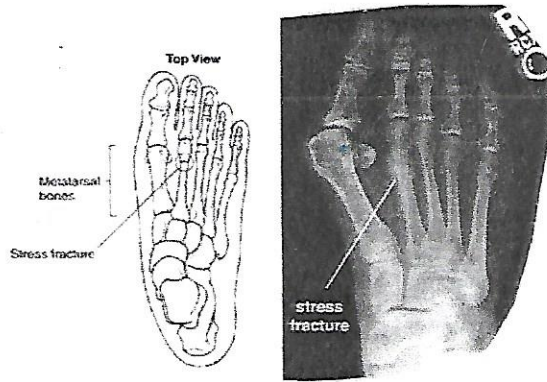


The Foot and Ankle: Mary Vacala, PA-C

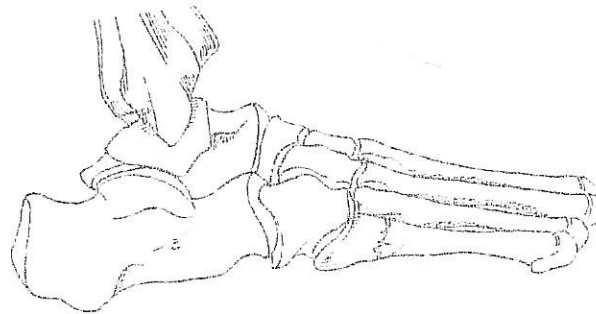
Lisfranc Fracture/Dislocation




Metatarsal Stress Fracture



Jones Fracture

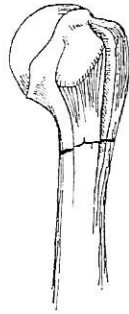


Distal Fibula Fracture

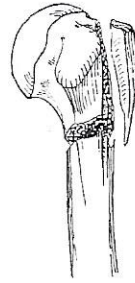


The Shoulder and Elbow, Steve Kestlinger, PA-C

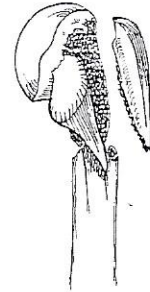Humerus fractures



Two Part

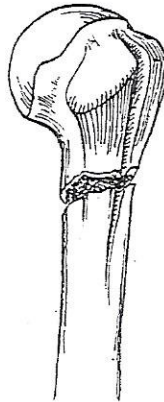


Three Part

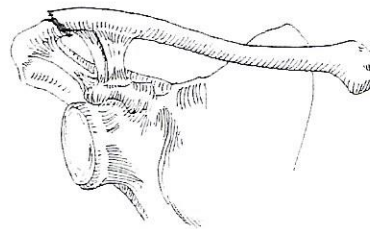
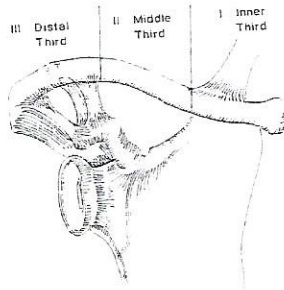


Four Part

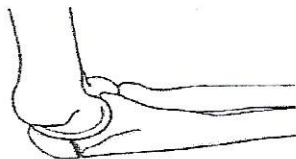Humerus shaft fracture



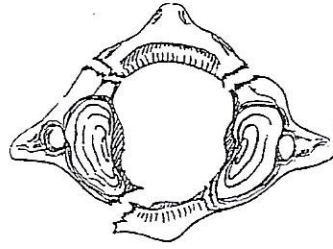
Clavicle fracture



Elbow fracture

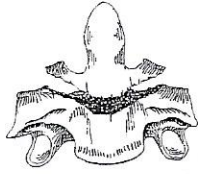


The Spine: Scott Frischknecht, PA-C  
Jefferson's Fracture (C1)

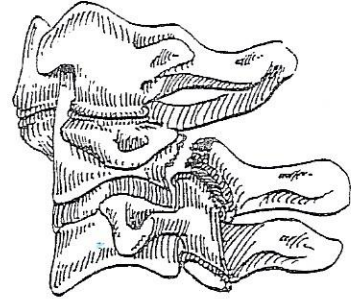


C2 Fractures:

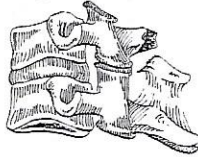
Odontoid (Dens) Fracture



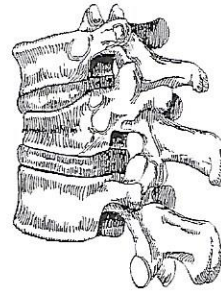
Hangman's Fracture



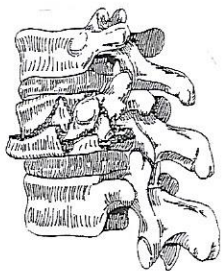
Clay Shoveler's Fracture (C6 or C7)



Compression Fracture



Burst fracture



Chance fracture

