



The Hoarse Whisperer

Kathryn Kugler, PA-C, MEd., DFAAPA
Penn State Health Milton Hershey Medical Center
Heart and Vascular Institute Cardiovascular and
Interventional Radiology



Disclosures

- I have no relevant relationships with ineligible companies to disclose within the past 24 months.
(Note: Ineligible companies are defined as those whose primary business is producing, marketing, selling, re-selling, or distributing healthcare products used by or on patients.)

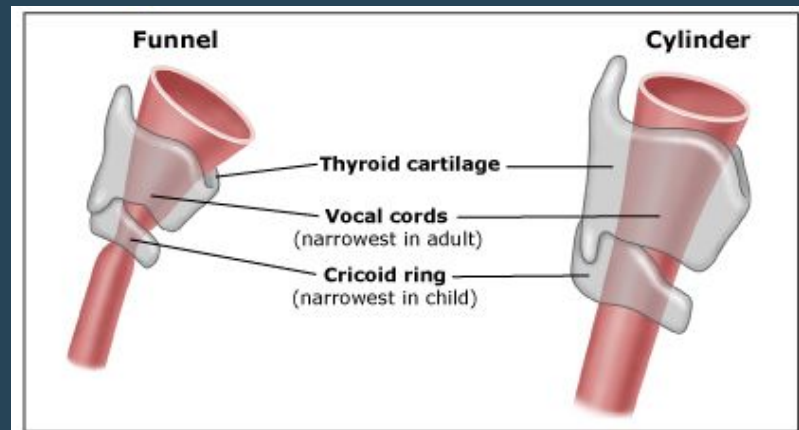


Educational Objectives

- At the conclusion of this session, participants should be able to:
 - Describe laryngeal anatomy and how pathologic alterations in the anatomy or physiology of the larynx affect phonation
 - Discuss the appropriate history and physical examination of the hoarse patient and formulate a comprehensive differential diagnosis
 - Summarize treatment options for hoarseness including medications, speech therapy and procedural and surgical modalities

Laryngeal Anatomy

- Located at the level of C3-C7
- Approximately 4-5cm long and wide with a slightly shorter anterior posterior diameter
- Funnel shaped as an infant, cylindrical as an adult

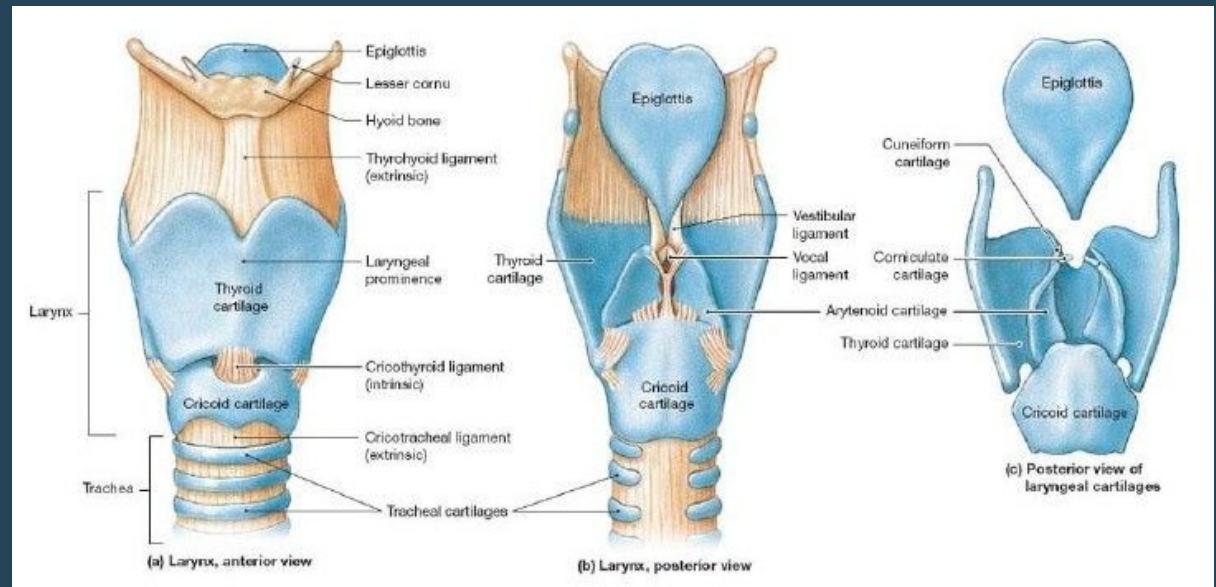


<https://somepomed.org/articulos/contents/images/f8/37/8795.myextj?title=Child+vs+adult+airway+1>

Laryngeal Anatomy

- Cartilage

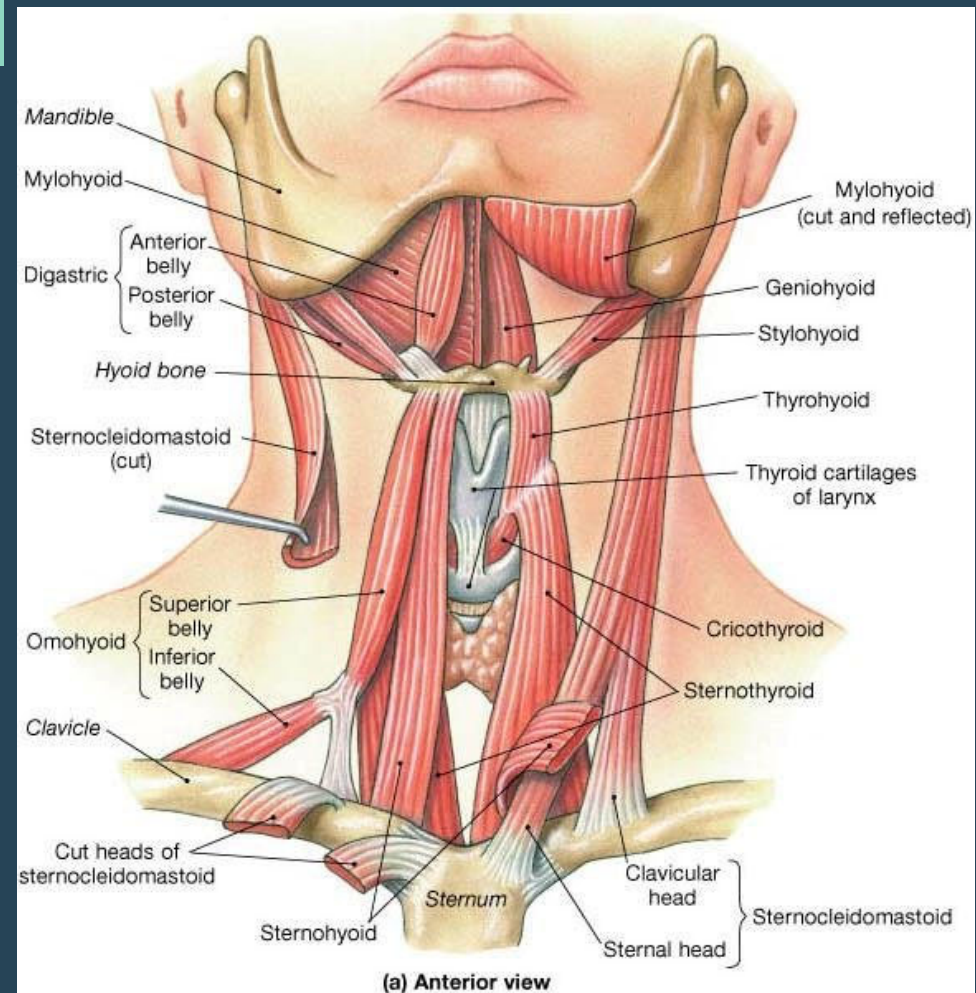
- Cricoid
- Thyroid
- Epiglottis
- Arytenoid
- Corniculate
- Cuneiform



<https://i.pinimg.com/736x/c3/0e/cb/c30ecb38add68b3a2e6f80deb8cb84ce.jpg>

Extrinsic Laryngeal Muscles

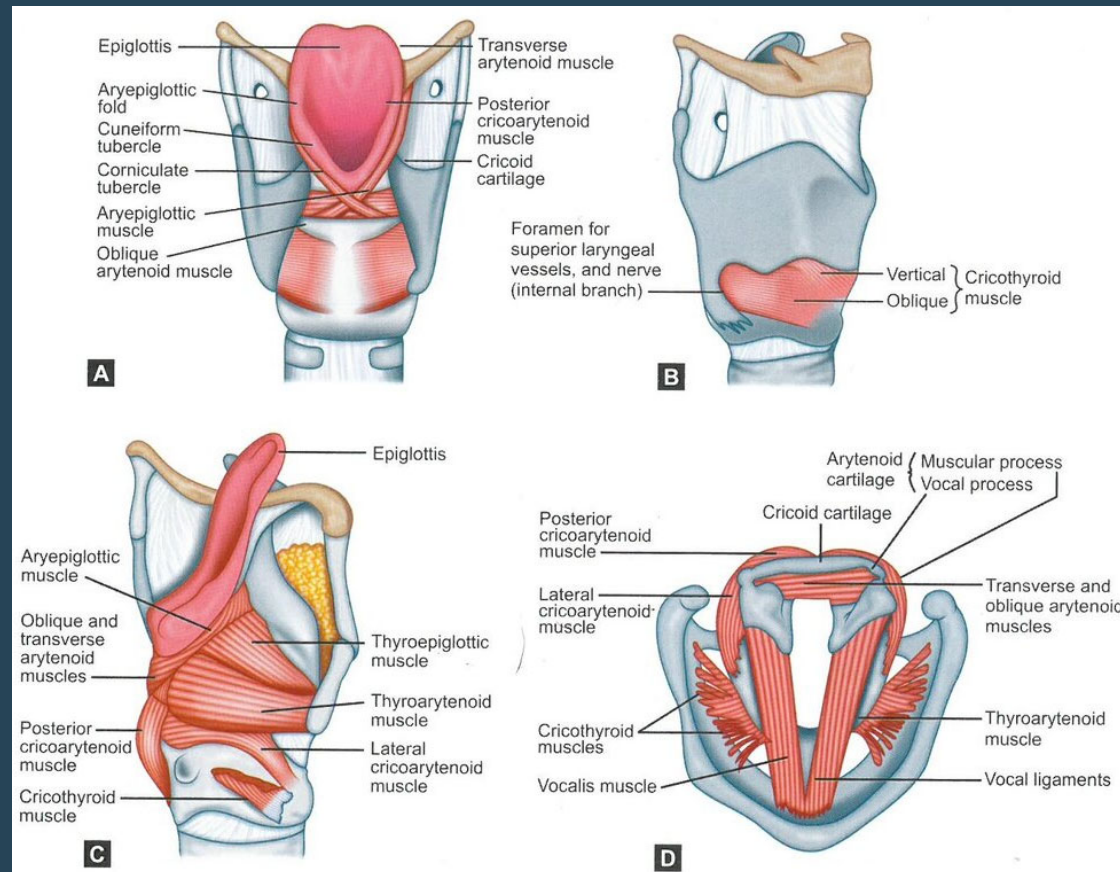
- **Elevation of larynx**
 - Superior aspect of the hyoid
 - Geniohyoid
 - Digastric
 - Mylohyoid
 - Thyrohyoid
 - Stylohyoid
 - Pharynx
 - Stylopharyngeus
 - Palatopharyngeus
 - Pharyngeal constrictor muscles
- **Depression of larynx**
 - Inferior surface of the hyoid
 - Sternohyoid
 - Omohyoid
 - Sternothyroid



<https://www.researchgate.net/profile/Tariq-Manzoor/publication/301549536/figure/fig6/AS:353286138941445@1461241387371/1-Extrinsic-muscles-of-larynx-muscles-of-face.png>

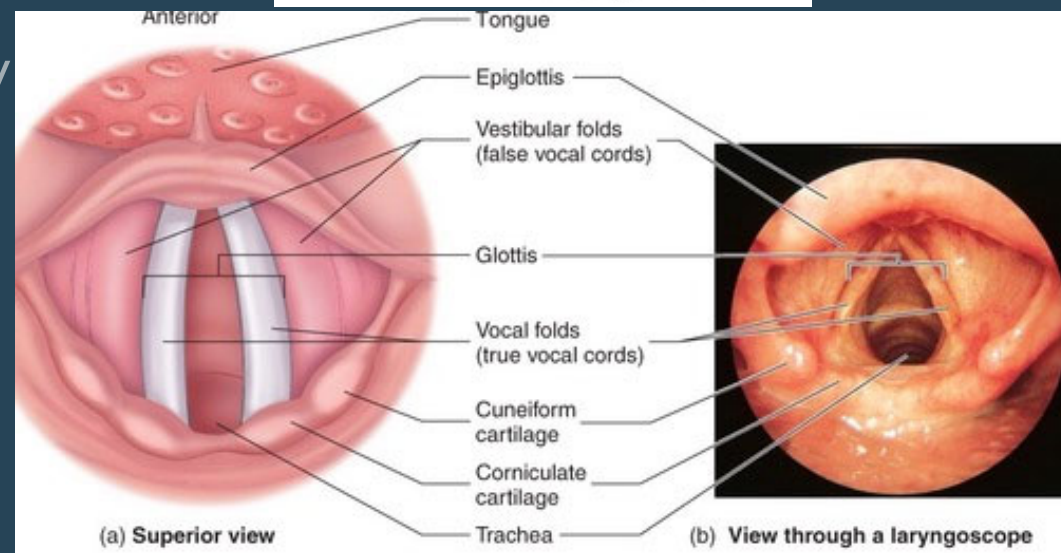
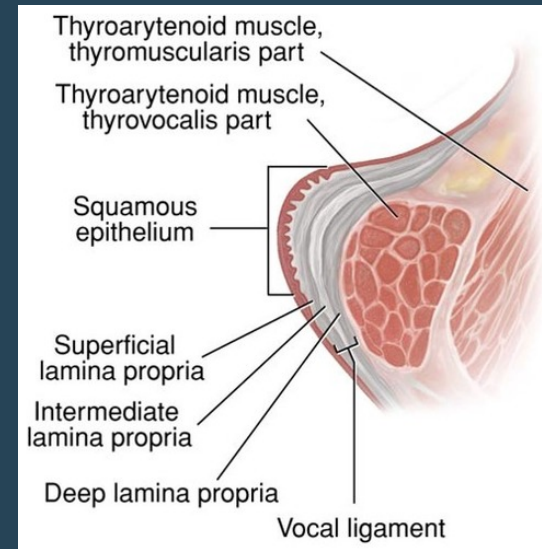
Intrinsic Laryngeal Muscles

- Muscles of the inlet
 - Aryepiglottic
 - Oblique arytenoid
 - Thyroepiglottic
- Muscles of the vocal folds
 - Adductors
 - Lateral cricoarytenoid
 - Transverse and oblique arytenoid
 - Abductors
 - Posterior cricoarytenoid
 - Tensors
 - Cricothyroid
 - Relaxers
 - Thyroarytenoid
 - Fine adjustments
 - Vocalis



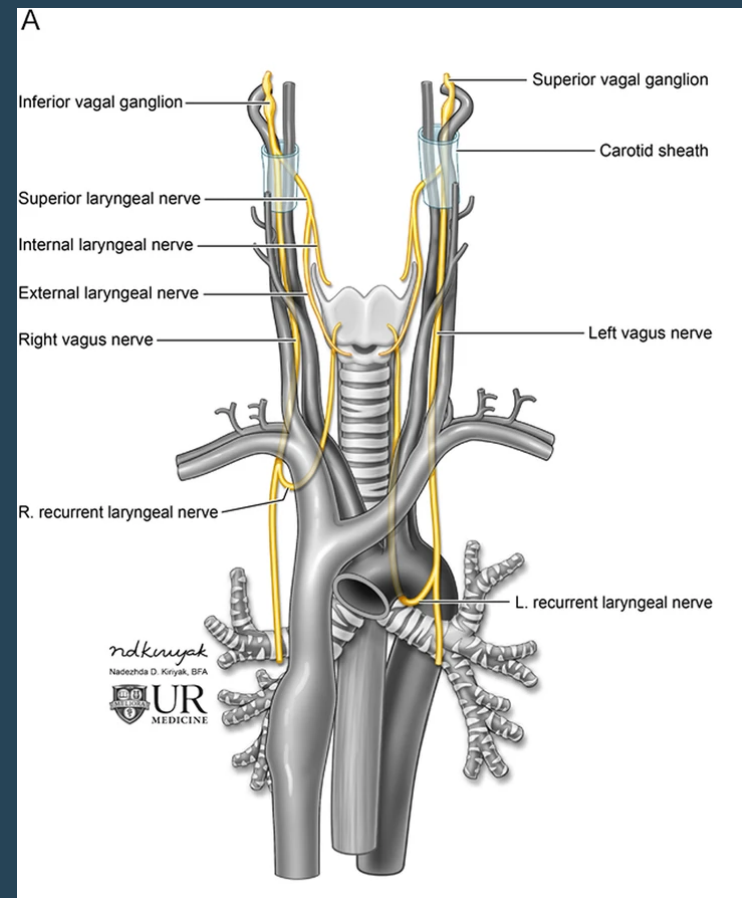
Laryngeal Anatomy

- Vocal Folds
 - True
 - False
- Mucosal Lining
 - True folds and mechanically exposed areas lined with non-keratinizing squamous epithelium
 - Lumen of larynx lined with respiratory epithelium



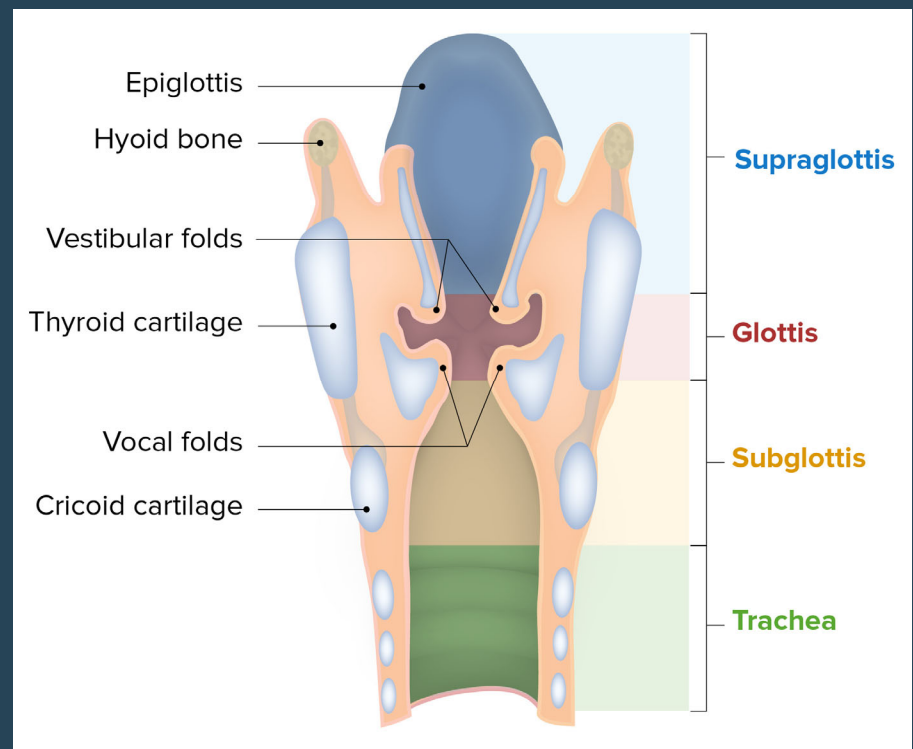
Laryngeal Anatomy- Innervation

- **Recurrent laryngeal**
 - All intrinsic muscles of the larynx except cricothyroid (external branch of superior laryngeal)
 - Some motor function of the pharynx
- **Superior laryngeal**
 - Sensory function of the vocal cords
- **Vagus Nerve**
 - Motor function of the pharynx
 - Sensory function of the external auditory canal and hypopharynx



Regions of the Larynx



- **Supraglottis**
 - All structures above the true folds
- **Glottis**
 - True folds and 1 cm below
- **Subglottis**
 - Area from the inferior boarder of the glottis to the boarder of the cricoid cartilage



<https://cdn.lecturio.com/assets/Components-and-regions-of-the-larynx.jpg>

Functions of the Larynx

- Phonation
- Airway patency
- Swallow
 - Larynx elevates
 - Epiglottis deflects posteriorly
 - Vocal cords close



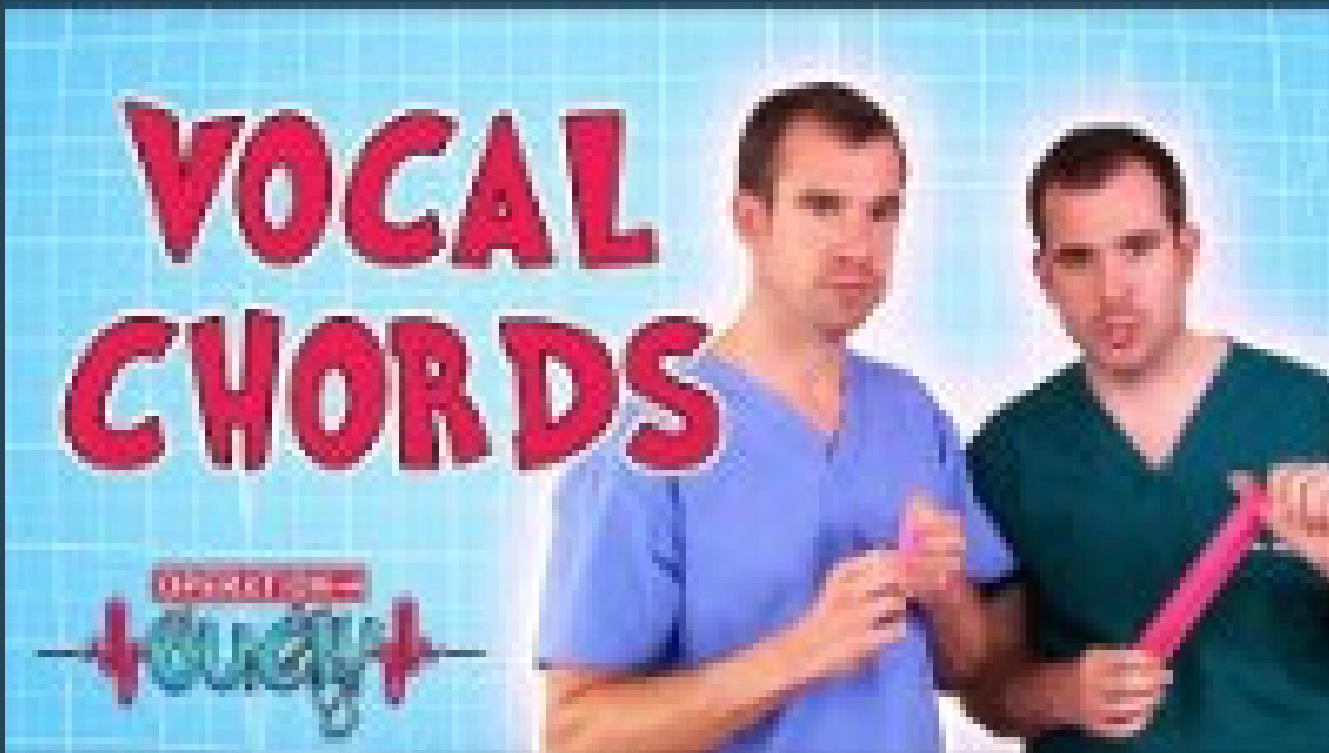https://www.google.com/url?sa=i&url=https%3A%2F%2Fcliparts.zone%2Fsing-cliparts&psig=AOvVaw3MBTFCIQkHcr8R2dWcwrbi&ust=1645896411592000&source=images&cd=vfe&ved=0CAsQjRxqFwoTCOCvyd2wm_YCFQAAAAAAdAAAAABAD
<https://image.shutterstock.com/image-vector/magician-swallowing-sword-illusionist-character-260nw-1767157352.jpg>
https://grid.gograph.com/deep-breathing-vector-clipart_gg66896024.jpg

A decorative vertical wavy line on the left side of the slide, composed of multiple overlapping light blue lines that create a shimmering, wave-like effect.

Phonation

- Voice is achieved when the vocal cords adduct and air passes through them causing a vibratory wave creating sound
- This sound resonates in the nose and pharynx
- Articulation of words is controlled by the tongue, palate and lips
- The pitch of voice is dependant on vocal fold length and tension

Phonation



<https://www.youtube.com/watch?v=GDzcLZDdxqs>



Evaluation of the Hoarse Patient



Hoarseness

- Often used to describe any change in vocal quality including:
 - Change in pitch
 - Breathiness
 - Strain
 - Fatigue
 - Tremor
 - Loss of voice
 - Voice breaks



History

- Duration of the change in voice
 - Recurrent?
- Gradual or sudden onset
- Speaking voice vs singing voice change
- Muscular neck pain with phonation
- Vocal fatigue
- Exacerbating or improving factors
- Triggers
 - Smoke exposure
 - Vocal abuse
 - Postnasal drip
 - Activities
 - Exercise
 - Scents
- Voice use
 - Hobbies
 - Coaching, singing
 - Work environment



History

- Reflux symptoms or history
- Globus sensation
- Cough
- Throat clearing
- Smoking and alcohol history
- HPV exposure history
- Surgical history
 - Neck or thoracic surgery
- Injury to the vocal cords or neck
 - Trauma
 - Intubation
- Other head and neck symptoms
 - Dysphagia
 - Odynophagia
 - Otalgia
 - SOB
 - Weight loss
 - Neck mass



Physical Exam

- Listen to the patient's voice
 - Scratchy or coarse
 - Breathy
 - Vocal fatigue
 - Tremulous
 - Wet or gurgling
 - Soft – unable to produce loud voice
 - Cracking
 - Stridorous
 - Halting
- Ear exam
 - Look for effusions
 - Unilateral
- Nasal exam
- Oral cavity exam
 - Palpation of base of tongue
- Neck exam
 - Lymphadenopathy
 - Thyroid

Normal Strobe





Differential Diagnosis

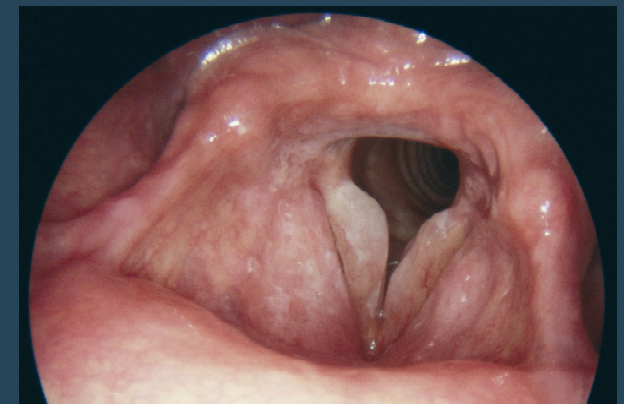
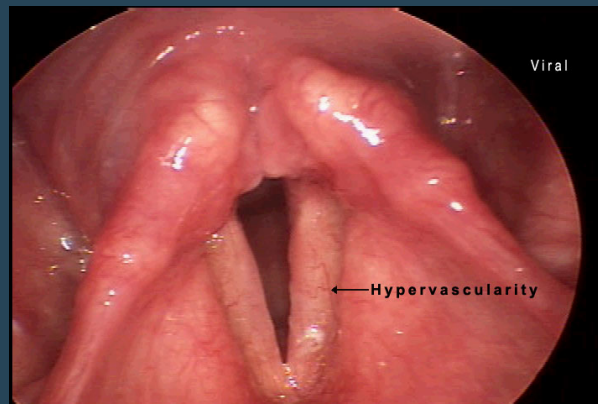
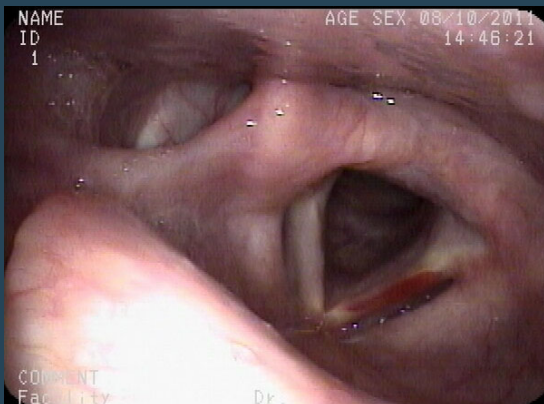
- Acute laryngitis
- Chronic laryngitis
- Benign lesions
- Malignant lesions
- Functional disorders
- Neurologic disorders
- Congenital abnormalities
- Systemic disorders



Acute Laryngitis

Causes

- Viral or bacterial infections that are short duration
- Cough related to illness can cause edema or injury to vocal folds resulting in hoarseness
- Vocal strain such as yelling can cause submucosal trauma with focal hemorrhage and edema



<https://app1.unmc.edu/medicine/heywood/laryngealdisease/Data/images/7/viralaryngitis.jpg>

https://www.merckmanuals.com/-/media/manual/professional/images/m/2/0/m2000166-laryngitis-science-photo-library-high.jpg?thn=0&sc_lang=en



Treatment

- Symptomatic Relief
 - Cough reduction
 - Hydration
 - Cessation of vocal strain
- Antibiotics are not indicated
- Steroids have very limited use (if any)



COVID-19

- One study found 5% of COVID-19 patients had hoarseness
- Another found hoarseness preceded hospitalization
- Causes
 - Vocal fold edema
 - Poor breath support due to lung involvement
 - Post viral vagal neuropathy
 - Psychogenic



Chronic Laryngitis

Irritants

- Potential irritants
 - Smoking
 - Postnasal drip
 - Chronic vocal strain (singers)
 - Chemicals
 - Inhaled steroids
- Treatment
 - Removal of offending agent
 - Treatment of postnasal drip



<https://www.healio.com/~media/slack-news/stock-images/pediatrics/s/smoking.jpg>

Treatment of Postnasal Drip

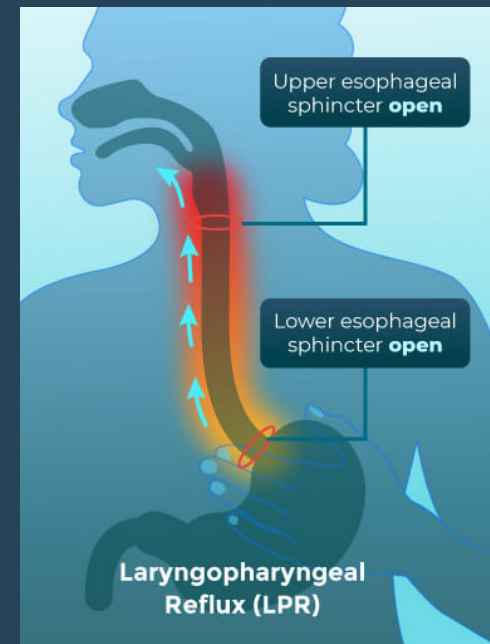
- **Topical Nasal Steroids**
 - Beclomethasone dipropionate (Beconase Aq, QNASL)
 - Budesonide (Rhinocort Aqua)
 - Ciclesonide (Omnaris)
 - Flunisolide (Nasarel)
 - Fluticasone (Flonase)
 - Fluticasone furoate (Veramyst)
 - Mometasone (Nasonex)
 - Triamcinolone acetonide (Nasacort AQ)
- **Other Nasal Sprays**
 - Azelastine (Astelin)
 - Ipratropium Bromide (Atrovent Nasal)
 - Azelastine and fluticasone (Dymista)
- **Nasal Rinses**
- **Treatment of any underlying allergic component**



<https://encrypted-tbn0.gstatic.com/images?q=tbn:ANd9GcTbi8JTF4BniHvVoy8sVhVieVWfbLjYkmFkPw&usqp=CAU>

Laryngeal Pharyngeal Reflux (LPR)

- Retrograde flow of stomach content to the larynx and pharynx whereby this material comes in contact with the upper aerodigestive tract
 - Globus
 - Throat clearing
 - Cough
 - Sore throat
 - Dysphagia
 - Laryngospasm
 - Choking



LPR Treatment

• Diet and lifestyle modification

- No eating or drinking 2 hours prior bedtime
- Elevate head of bed
- Avoidance diet
- Weight loss

Group	Recommend	Avoid/Limit
Milk or milk products	Skim, 1% or 2% low-fat milk, low-fat or fat-free yogurt	Whole milk (4%), chocolate milk
Vegetables	All other vegetables	Fried or creamy style vegetables, tomatoes
Fruits	Apples, berries, melons, bananas, peaches, pears	Citrus fruits, pineapple, kiwi
Breads and grains	All those made with low-fat content	Any prepared with whole milk or high-fat
Meat and meat substitutes	Low-fat meat, chicken, fish, turkey	Spicy cold cuts, sausage, bacon, fatty meat, chicken fat/skin
Fats and oils	None or small amounts	Keep amount limited on a given day
Sweets and desserts	All items with no or low-fat (<3g/serving)	Chocolate, desserts made with high amounts of oils and/or fats
Beverages	Water, juices (except citrus), herbal tea (not peppermint)	Alcohol, coffee, carbonated beverages, tea
Spices	All other spices that do not appear to have a negative effect	Hot mustard, vinegar, hot peppers, curry



Medication for LPR

- **PPI**

- Dexlansoprazole (Dexilant/
Kapidex)
- Esomeprazole (Nexium)
- Lansoprazole (Prevacid)
- Omeprazole (Prilosec)
- Omeprazole/sodium
bicarbonate (Zegrid)
- Pantoprazole (Protonix)
- Rabeprazole sodium (Aciphex)

- **Acid Reducers**

- Cimetadine (Tagamet)
- Famotidine (Pepcid)
- Nizatidine (Axid)
- Ranitidine (Zantac)

- **Antacids**

- Alka-Seltzer
- Gaviscon
- Mylanta
- Maalox
- Roloids
- Tums



Muscle Tension Dysphonia

- Imbalance of muscles used for phonation
- Broad spectrum of causes
 - Psychological/personality, vocal misuse, compensation for disease
- Treatment
 - Vocal therapy
 - Vocal hygiene
 - Relative vocal rest
 - Treatment of underlying disease



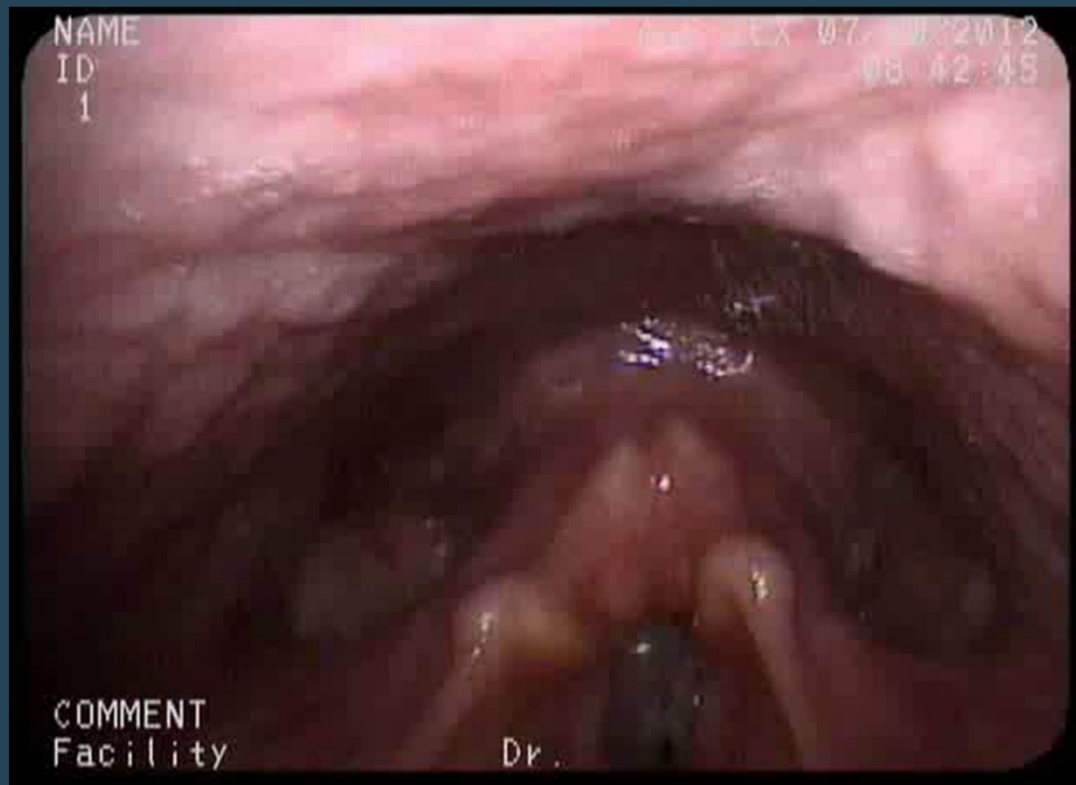Benign Lesions



Reinke's Edema (Polypoid Corditis)

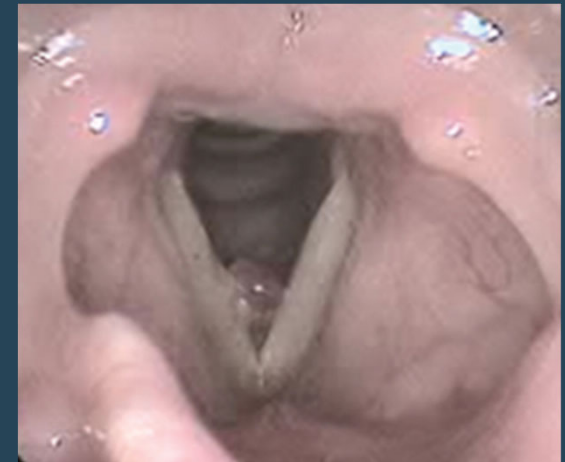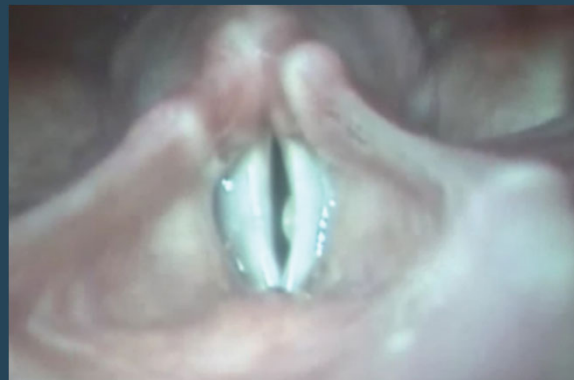- Viscous material collects in the lamina propria (Reinke's space) secondary to smoking
- Vocal folds appear floppy and swollen
- Occurs in smokers
- Treatment
 - Tobacco cessation
 - Surgery if does not resolve with tobacco cessation

Reinke's Edema/Polypoid Changes



Polyp

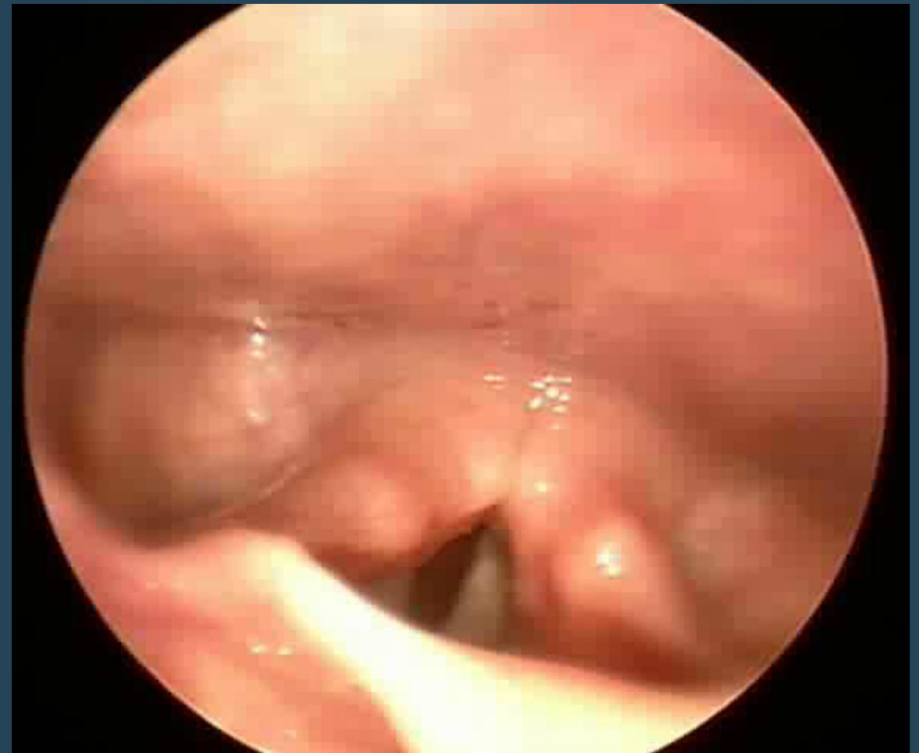- Caused by chronic laryngitis
- Often unilateral but may have a contact lesion
- Most often in the anterior third of the vocal fold more frequently seen in men
- Treatment
 - If smoking, quit
 - Vocal therapy
 - Surgical removal
 - Less studied treatments
 - Green laser
 - Steroid injection
 - Acupuncture



<https://www.researchgate.net/profile/Daniela-Vasconcelos-4/publication/330668815/figure/fig1/AS:722581145526287@1549288178720/Angiomatous-polyp-in-the-right-vocal-fold.png>
<https://voicesurgeon.net/wp-content/uploads/2018/11/Polyp-about-translucent-OR.jpg>

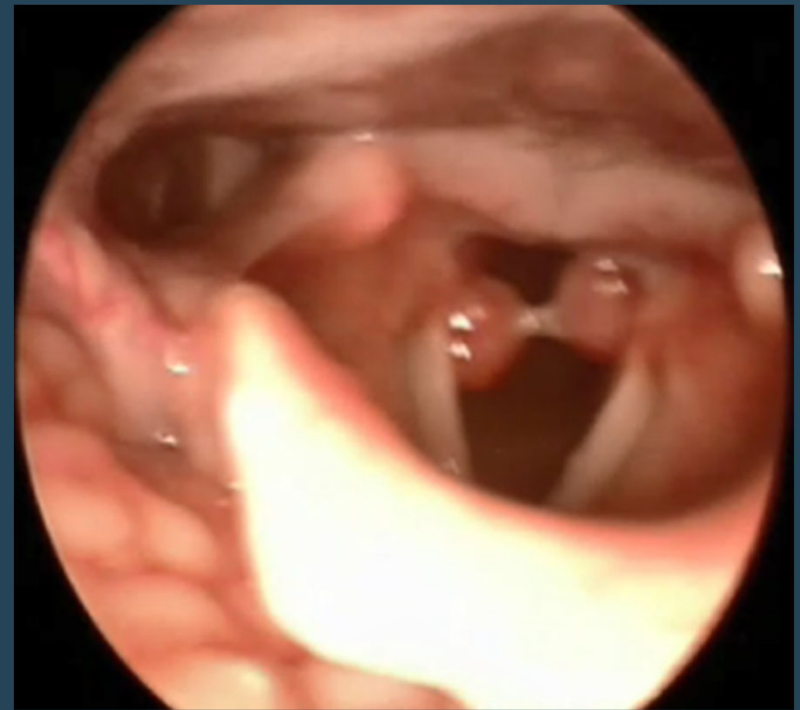Nodules

- Usually bilateral and relatively symmetric
- Occur in middle vocal fold most commonly
- More common in women and children
- Common in singers due to vocal abuse
- Most common cause of chronic hoarseness in children
- Treatment
 - Vocal therapy aimed at correcting vocal abuse
 - Surgical resection*



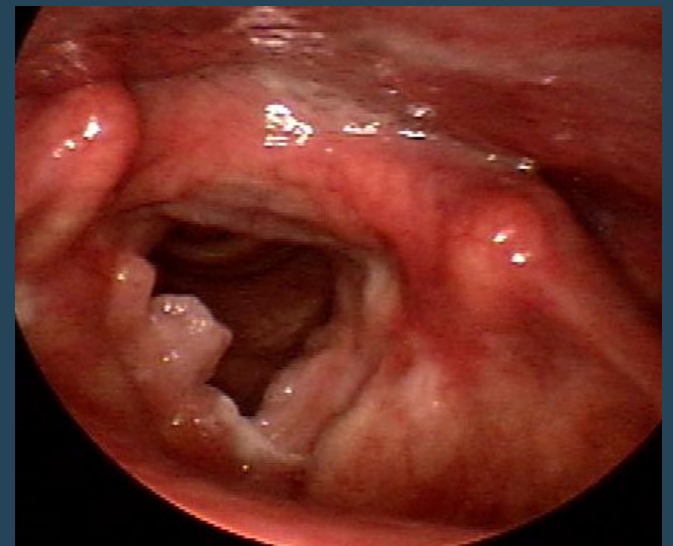
Granuloma

- Pseudotumor of the lateral wall of the posterior glottis
- Most commonly located in the posterior glottis
- Commonly associated with intubation trauma
- Can be associated with reflux, chronic throat clearing, vocal misuse
- Treatment
 - Treat underlying cause
 - Surgical resection reserved for airway compromise or persistent granuloma despite adequate treatment



Papillomatosis

- Warty growths caused by HPV 6 and 11
- Congenitally acquired at the time of birth from passing through the birth canal of a mother with HPV
- Can affect any portion of the larynx
- Rarely have malignant degeneration
- Treatment
 - Surgical resection
 - CO2 or KTP lasers
 - Prevention!





Treatment

- Most types of benign vocal fold lesions may benefit from treatment for LPR if they have symptoms or exam is consistent



Malignant Lesions



Malignant Vocal Fold Lesions

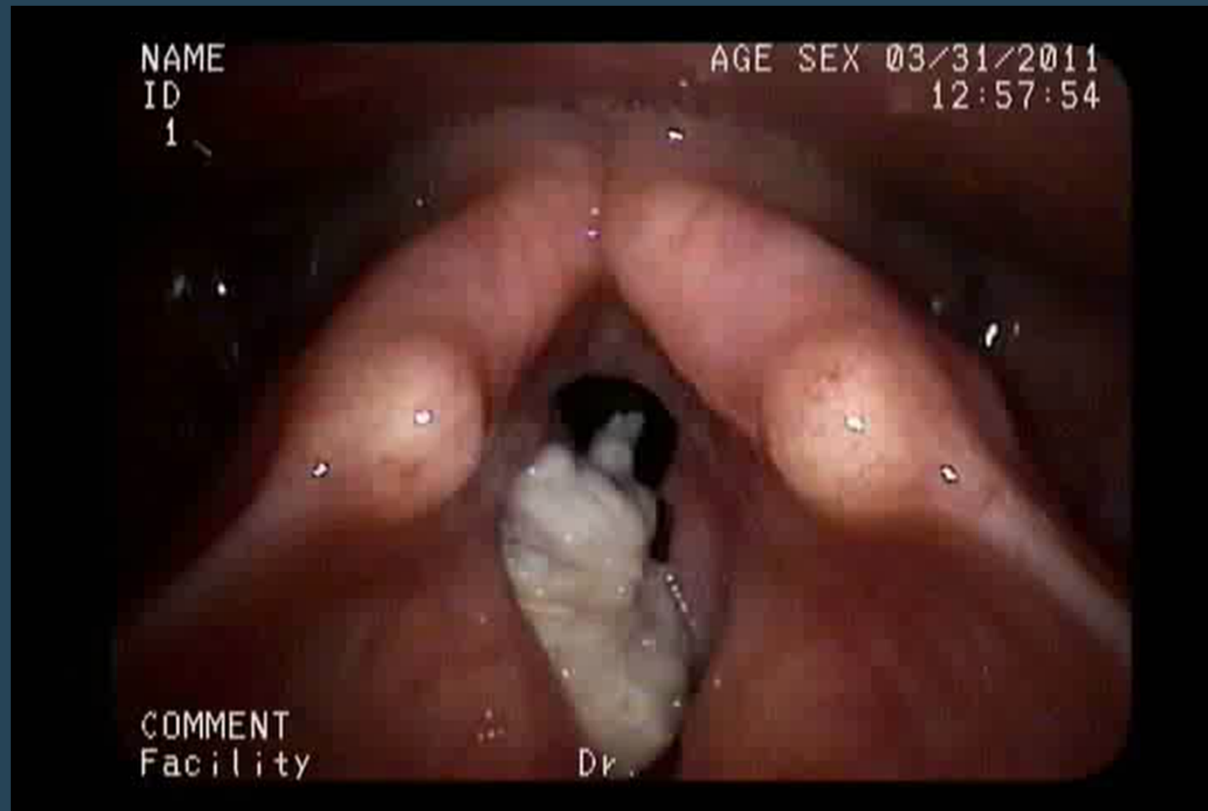
- Overwhelming majority of malignancies are Squamous Cell Cancer
- Risk factors
 - Smoking
 - Drinking alcohol
 - Strong family history of head and neck cancer
 - Increased risk in those who smoke and drink
 - HPV 16 and 18



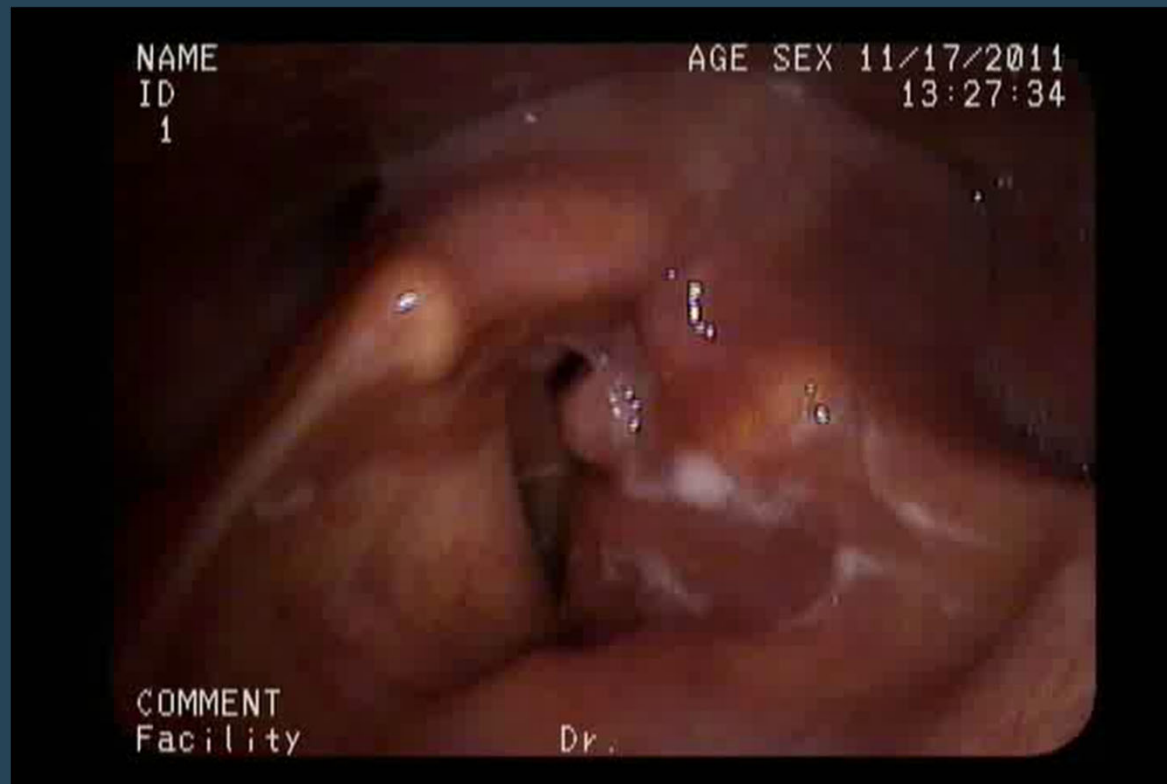Treatment

- Surgical
 - Local resection
 - Laser ablation
 - Partial laryngectomy
 - Total laryngectomy
 - May also need neck dissection for lymph node involvement or locally metastatic disease
- Chemotherapy
- Radiation Therapy
- Combination of the above

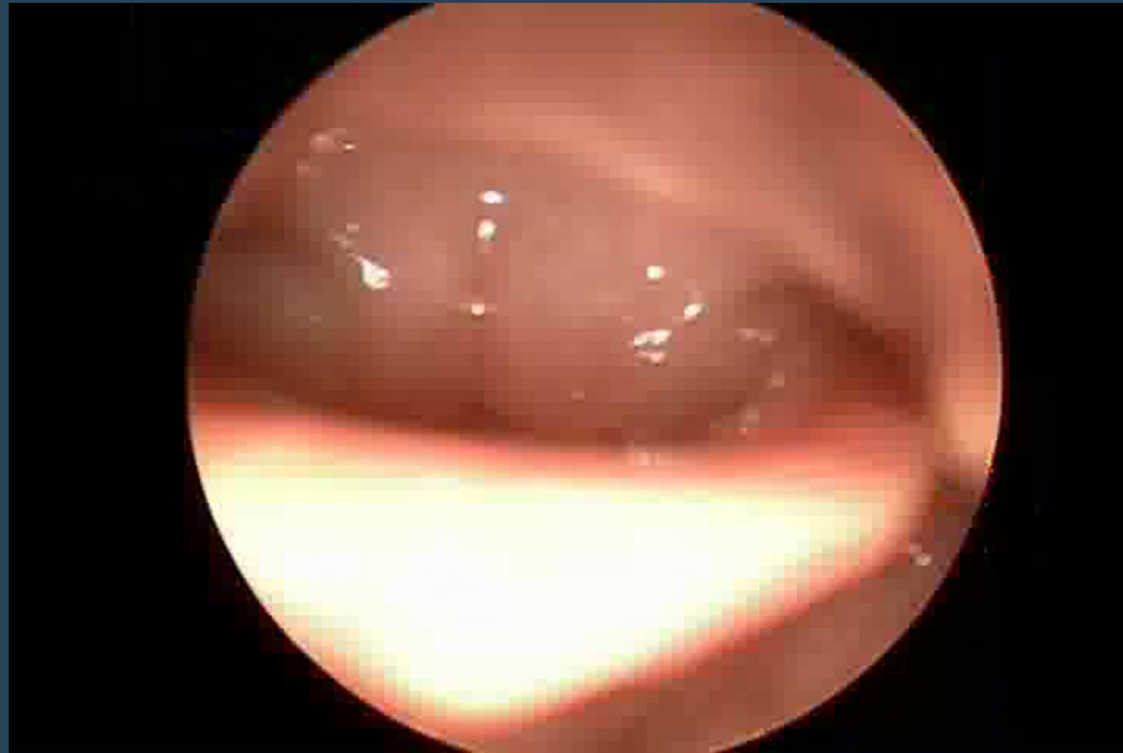Laryngeal Squamous Cell Cancer



Laryngeal Squamous Cell Cancer- Unilateral Fixed Vocal Fold



Laryngeal Squamous Cell Cancer- Fixed Vocal Folds





Functional Causes



Functional Vocal Fold Disorders

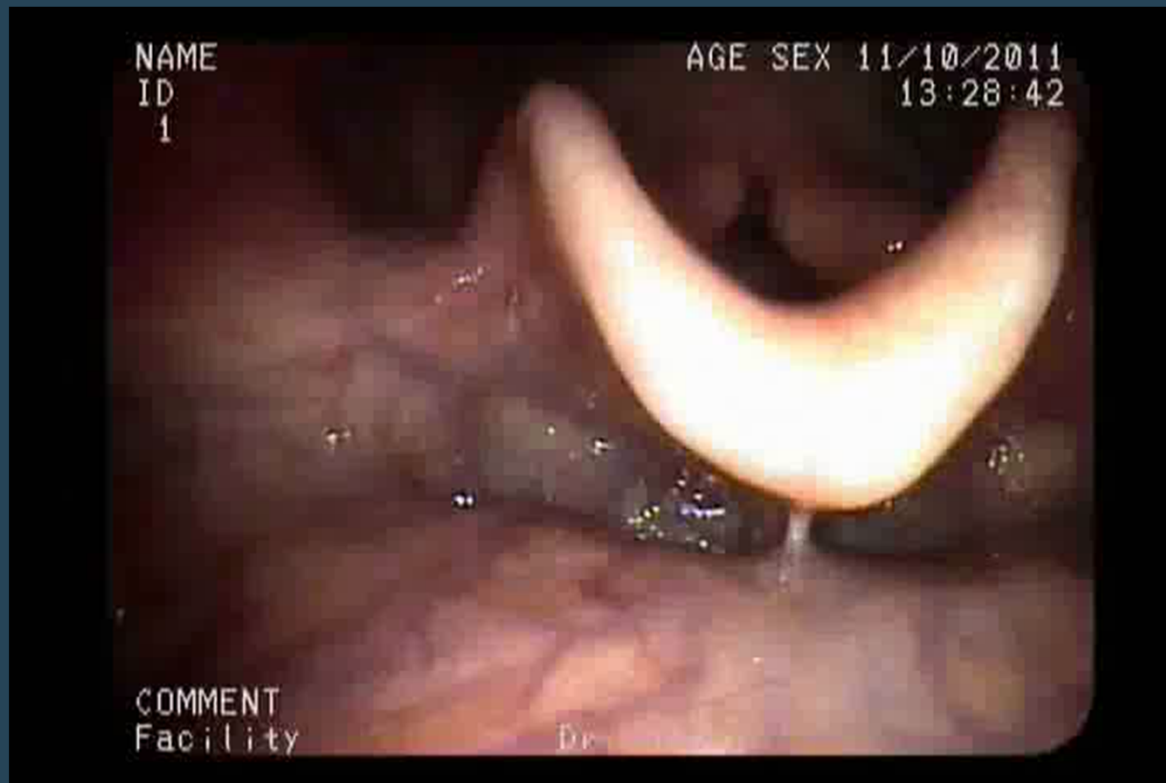- **Functional Dysphonia**
 - Change in voice without organic lesion
 - Stress and/or anxiety related in some patients
- **Paradoxical Vocal Fold Dysfunction**
 - Vocal fold adduction with inspiration and abduction with expiration
 - May cause inspirational stridor
 - Commonly exacerbated by exercise
- **Laryngeal Conversion Disorder**
 - Somatization of psychological issues



Treatment

- Vocal therapy and treatment of any underlying cause of irritation to the vocal folds is the primary treatment for all Functional Vocal Fold Disorders
- Reassurance that the patient is not “crazy”

Paradoxical Vocal Fold Motion



Glottal Fry

- Raspy, frog like, quality to the voice when used at the lowest register
- Caused by loose closure of the glottis allowing air to pop or rattle through the cords during phonation
- Often results in vocal fatigue and muscle discomfort
- Need to identify correct register for patient to speak in through speech therapy





Neurologic Causes



Unilateral Vocal Fold Paralysis

- Results from injury to recurrent laryngeal nerve (RLN)
- Often produces a breathy voice
- Can also cause aspiration
- Causes
 - Extra-laryngeal malignancy involving the RLN or vagal nerve in the head, neck or thorax
 - Injury during surgical procedures or intubation
 - Trauma
 - Degenerative neurological disorders
 - Idiopathic
- Treatment
 - Determine underlying cause and treat
 - Period of waiting to see if there is recovery of vocal fold paralysis unless severely symptomatic
 - 3-9 months on average
 - Speech therapy
 - Injection Laryngoplasty
 - Medialization thyroplasty

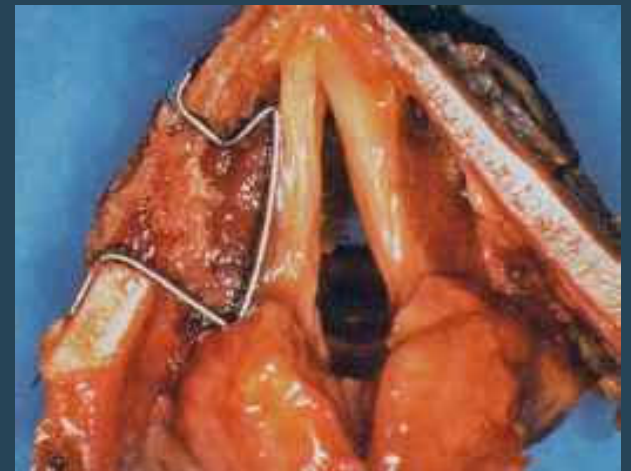
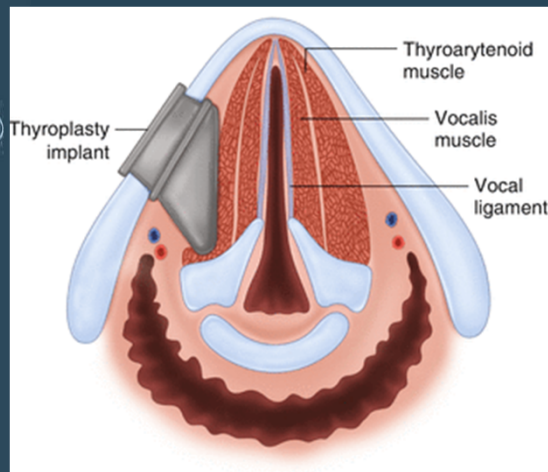


Injection Laryngoplasty

- Injection of an absorbable material to medialize the paralyzed vocal fold to restore more normal voice and swallow function
 - Improves function for 3+ months depending on the material used
- Approaches in the office with a flexible laryngoscope:
 - Percutaneous
 - Trans-cricothyroid membrane
 - Trans-thyroid cartilage
 - Trans-thyrohyoid membrane
 - Trans-nasal
 - Trans-oral
- Cymetra
- Juvederm
- Restylane/Perlane
- Radiesse
- RENÚ voice/ RENÚ gel
- Autologous fat/ fascia
- Gelfoam
- Teflon*
- Silicone*

Medialization Thyroplasty

- Surgical implantation of non-absorbable prosthesis to medialize the affected vocal fold to improve voice and swallow function



https://i2.wp.com/oncohemakey.com/wp-content/uploads/2017/11/A334875_1_En_19_Fig7_HTML.gif?w=960
https://encrypted-tbn0.gstatic.com/images?q=tbn:ANd9GcSYX7Wa-DfJTzDrJwcHPAM9PXn6Tpy7kV7CzpO5pXdoaGd5C6uepvBzlwF_LSHDUogN2!o&usqp=CAU
https://www.globehealth.net/vocal-fold/images/9595_86_64-thyroplasty-surgery.jpg



Bilateral Vocal Fold Paralysis

- Can cause respiratory compromise if in the paramedian position
 - Stridor
- Causes
 - Iatrogenic
 - Surgical injury to RLN or vagus nerve
 - Intubation
 - Organophosphate pesticides
 - Stroke or head injury
 - Neurologic disorders
 - Arnold-Chiari malformation
- Treatment is dependent on position of folds, voice and swallow function
 - Medialized vocal folds bilaterally can cause airway compromise
 - Tracheotomy
 - Cordotomy
 - Will decrease or eliminate voice
 - Lateralized vocal folds can cause lack of voice or aspiration
 - Tracheotomy
 - Unilateral vocal fold injection
 - Medialization thyroplasty
 - Speech therapy
 - Useful for patients without airway compromise or aspiration



Vocal Fold Paralysis in the Child

- **Iatrogenic**
 - Cardiothoracic surgery
 - Repair of tracheoesophageal fistula
 - Thyroidectomy
- **Neurologic**
 - Arnold Chiari malformation
 - Posterior fossa tumor
 - Hydrocephalus
- **Injury to recurrent laryngeal nerve from delivery or intrathoracic lesions**
- **Idiopathic**
- **Treatment**
 - Often spontaneously resolve
 - Speech therapy
 - Other interventions are the same as adults

Vocal Fold Paralysis





Spasmodic Dysphonia

- Intermittent focal laryngeal dystonia
- Halting strained and strangled voice quality
- Results from forceful adduction of vocal folds during phonation
- Most noticeable with vowels
- Treatment
 - Vocal therapy not usually effective
 - Injection of botulinum toxin into the laryngeal muscles reduces symptoms
 - Needed every 3-6 months

Spasmodic Dysphonia





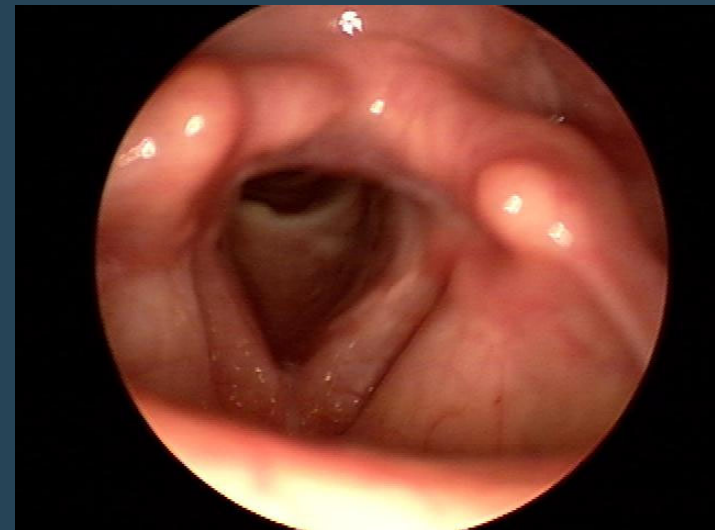
Congenital Abnormalities

Laryngeal Web

- Incomplete separation of the vocal folds
- Complete webbing is an emergency requiring immediate tracheotomy at birth
- Associated with cardiac and respiratory anomalies
- Present with weak or unusual cry
- If presents later in life may present with weak voice, breathiness, stridor

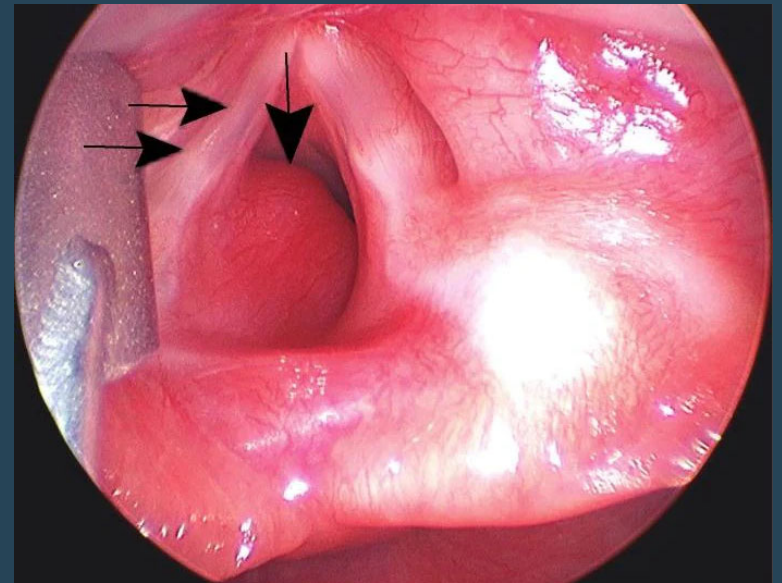
• Treatment

- Depends on severity of webbing
 - Surgical lysis
 - Stenting
 - Laryngeal reconstruction



Hemangioma

- Rare cause of hoarseness
- Associated with skin hemangiomas
- Treatment
 - Most do not require intervention
 - Ablation of hemangioma surgically



<https://img.medscapestatic.com/article/726/576/726576-fig2.jpg>



Systemic Disorders



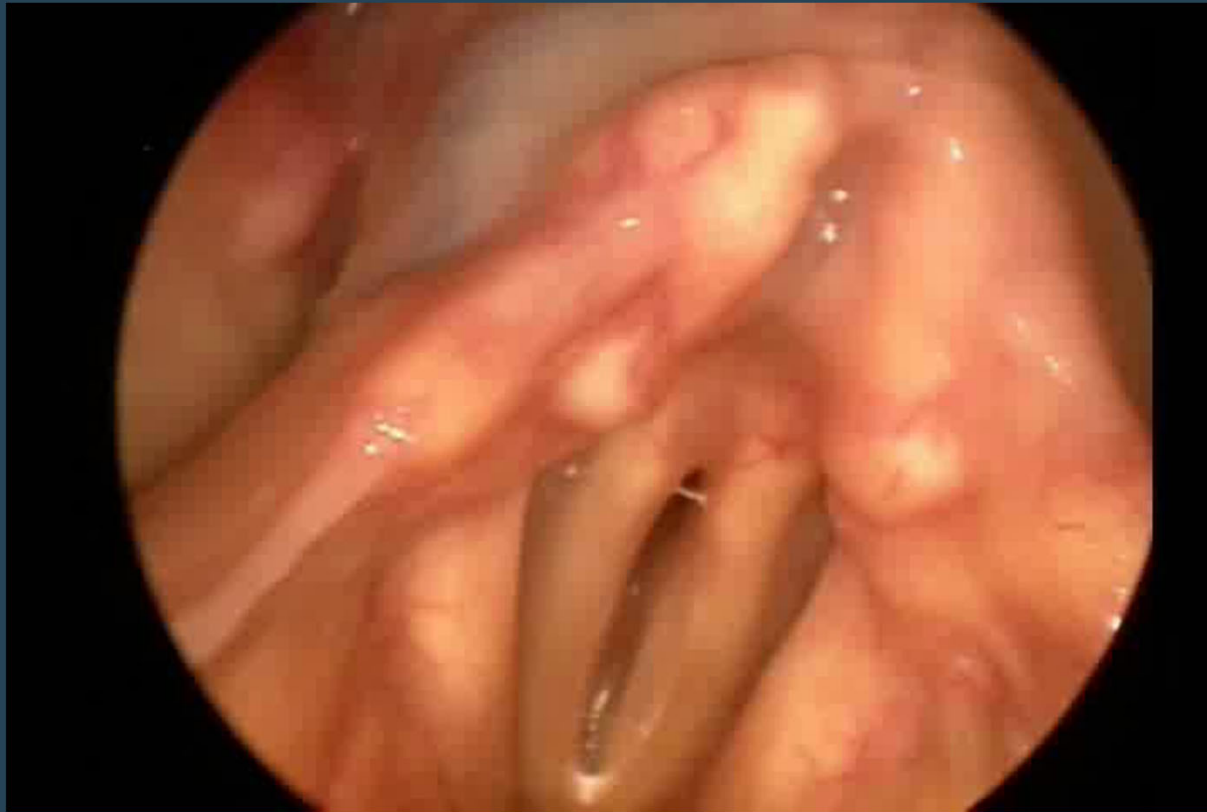Systemic Disorders

- Amyloidosis
- Wegner's Granulomatosis
- Post radiation changes
- Rheumatoid arthritis
- Parkinson's disease
- Motor Neuron Disorders
- Pregnancy
- Tremor
 - Stroke
 - Tumor
 - Multiple Sclerosis
- Motor Neuron Disorders
- Myasthenia Gravis
- Hypothyroid
- Hormonal therapy

Tremor

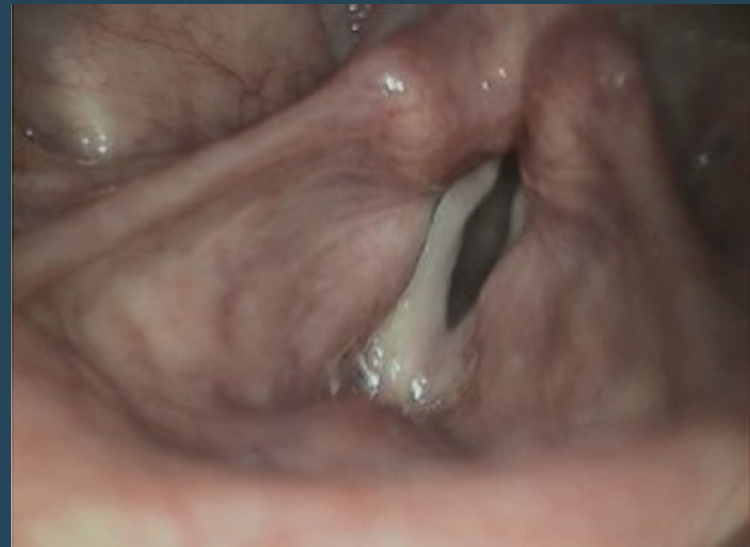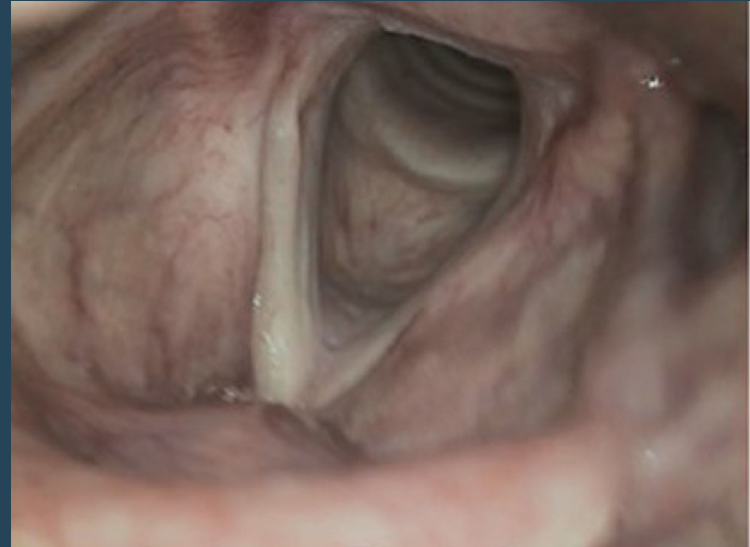


Amyloidosis



Presbylarynx

- Aging causes
 - Ossification of the laryngeal skeleton
 - Arthritis of the cricoarytenoid and cricothyroid joints
 - Degeneration of the vocal fold layers
 - Results in bowing defect of the vocal folds
- Treatment with speech therapy

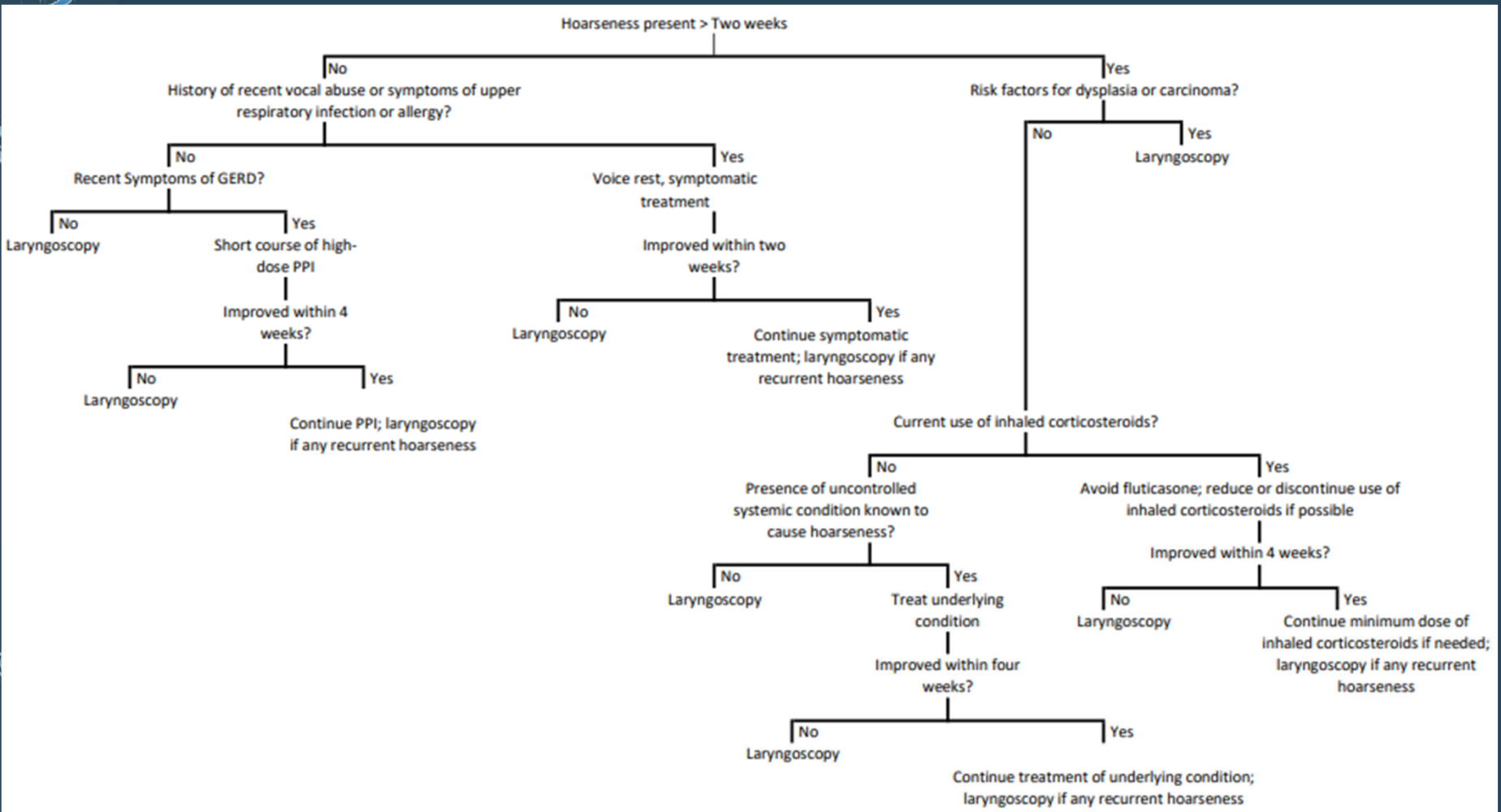




Take Home Points

- Investigate further or refer to an otolaryngologist
 - If a patient has “acute” laryngitis that **does not resolve** within expected time period
 - If you have a **strong level of suspicion** that the patient has a malignancy
 - For example a smoker and drinker with new onset hoarseness who has no other viral symptoms
 - If the patient has hoarseness **with neck mass and/or ear pain**
 - If you have treated possible irritant causes and the **hoarseness does not resolve**
 - If the patient also has **symptoms of aspiration or vocal fold paralysis**

Treatment and Referral Algorithm



Adapted from
<http://www.aafp.org/afp/2009/0815/p363.html>



References

- *Alloderm Select Alloderm Select Restore*. (2020, August). Allergan. Retrieved February 25, 2022 from https://media.allergan.com/actavis/actavis/media/allergan-pdf-documents/labeling/alloderm_ifu.pdf
- Bell, Daniel. (2021, August 2). *Intrinsic Muscles of the Larynx*. Radiopedia. Retrieved February 2022 from <https://radiopaedia.org/articles/intrinsic-muscles-of-the-larynx?lang=us>
- Campagnolo, A. M., Priston, J., Thoen, R. H., Medeiros, T., & Assunção, A. R. (2014). Laryngopharyngeal reflux: diagnosis, treatment, and latest research. *International archives of otorhinolaryngology*, 18(2), 184–191. <https://doi.org/10.1055/s-0033-1352504>
- Chhetri, D. K., & Jamal, N. (2014). Percutaneous injection laryngoplasty. *The Laryngoscope*, 124(3), 742–745. <https://doi.org/10.1002/lary.24417>
- Darweesh, M.E., El-Gazzar, A.F.Y., Sarag, S.M. (2021). Outcomes versus complications in patients undergoing different modalities of injection laryngoplasty. *Egypt J Otolaryngol* 37(10). <https://doi.org/10.1186/s43163-020-00064-8>
- Džukić, V., Krejović-Trivić, S., Vukašinović, M., Trivić, A., Pavlović, B., Milovanović, A., & Milovanović, J. (2015). Laryngeal Granuloma - Benefit in Treatment with Zinc Supplementation?. *Journal of medical biochemistry*, 34(2), 228–232. <https://doi.org/10.2478/jomb-2014-0028>
- Elilbol, E. (2021). Otolaryngological symptoms in COVID-19. *Eur Arch Otorhinolaryngol* 278, 1233–1236. <https://doi.org/10.1007/s00405-020-06319-7>
- Feierabend, R. H., & Shahram, M. N. (2009). Hoarseness in adults. *American family physician*, 80(4), 363–370.
- Hull, J. H., Backer, V., Gibson, P. G., & Fowler, S. J. (2016). Laryngeal Dysfunction: Assessment and Management for the Clinician. *American journal of respiratory and critical care medicine*, 194(9), 1062–1072. <https://doi.org/10.1164/rccm.201606-1249CI>
- Montoya, S., Portanova, A. & Bhatt, A.A. (2019) A radiologic review of hoarse voice from anatomic and neurologic perspectives. *Insights Imaging*, 10 (108). <https://doi.org/10.1186/s13244-019-0786-7>
- Pasha, R., Golub, J. (2018). *Otolaryngology Head and Neck Surgery Clinical Reference Guide, Sixth Addition*. Pleural Publishing.
- *Prolarynx*. Merz North America, Inc. Retrieved February 25, 2022 from <https://www.prolarynx.com/>
- Recurrent Respiratory Papillomatosis or Laryngeal Papillomatosis (2017, November 28). NIDCD. Retrieved February 2022 from <https://www.nidcd.nih.gov/health/recurrent-respiratory-papillomatosis>
- *RENU voice/ RENU gel*. InHealth Technologies. Retrieved February 2022 from <https://inhealth.com/renu-voice-renu-gel>
- Ryu IS, Nam SY, Han MW, Choi S, Kim SY, Roh J. (2012). Long-term Voice Outcomes After Thyroplasty for Unilateral Vocal Fold Paralysis. *Arch Otolaryngol Head Neck Surg*, 138(4):347–351. doi:10.1001/archoto.2012.42
- Saniasiyaya, J., Kulasegarah, J., & Narayanan, P. (2021). New-Onset Dysphonia: A Silent Manifestation of COVID-19. *Ear, nose, & throat journal*, 145561321995008. Advance online publication. <https://doi.org/10.1177/0145561321995008>
- Suárez-Quintanilla J, Fernández Cabrera A, Sharma S.(2021, September 8) *Anatomy, Head and Neck, Larynx*. In: *StatPearls* <https://www.ncbi.nlm.nih.gov/books/NBK538202/>
- Van Houtte, E., Van Lierde, K., & Claeys, S. (2011). Pathophysiology and treatment of muscle tension dysphonia: a review of the current knowledge. *Journal of voice : official journal of the Voice Foundation*, 25(2), 202–207. <https://doi.org/10.1016/j.jvoice.2009.10.009>
- Vasconcelos, D., Gomes, A., & Araújo, C. (2019). Vocal Fold Polyps: Literature Review. *International archives of otorhinolaryngology*, 23(1), 116–124. <https://doi.org/10.1055/s-0038-1675391>
- Vocal Cord Lesions (Nodules, Polyps and Cysts). (2019, February 3). Cleveland Clinic. Retrieved February 25, 2022 from <https://my.clevelandclinic.org/health/diseases/15424-vocal-cord-lesions-nodules-polyps-and-cysts>
- Vocal Cord Nodules and Polyps. ASHA. Retrieved February, 25 2022, from <https://www.asha.org/public/speech/disorders/vocal-cord-nodules-and-polyps/>
- Yang, D., Shi, Y., Tang, Y., Yin, H., Guo, Y., Wen, S., Wang, B., An, C., Wu, Y., & Gao, W. (2019). Effect of HPV Infection on the Occurrence and Development of Laryngeal Cancer: A Review. *Journal of Cancer*, 10(19), 4455–4462. <https://doi.org/10.7150/jca.34016>



Questions?

Feel free to email me with any further questions not answered today:

kkugler@pennstatehealth.psu.edu

The capacity to learn is
a *gift*; the ability to
learn is a *skill*; the
willingness to learn is a
choice.

Brian Herbert

<https://i.pinimg.com/originals/8e/ee/be/8eeeb447ccbea494dbc080ddd8ca16.png>