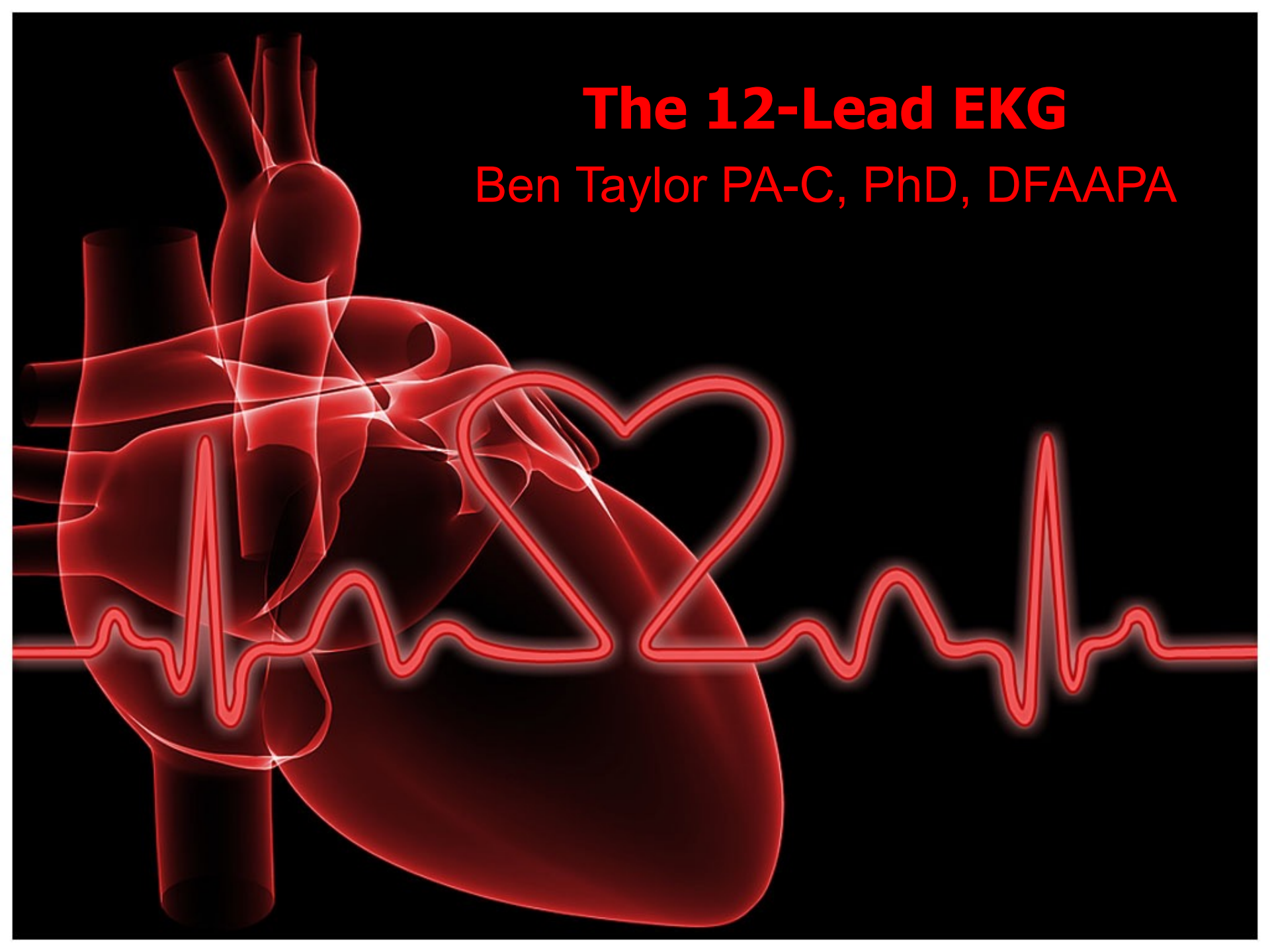


The 12-Lead EKG

Ben Taylor PA-C, PhD, DFAAPA





Disclosures

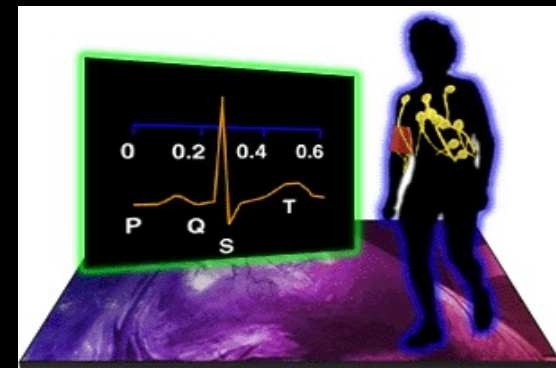
No relevant relationships with ineligible companies to disclose within the past 24 months



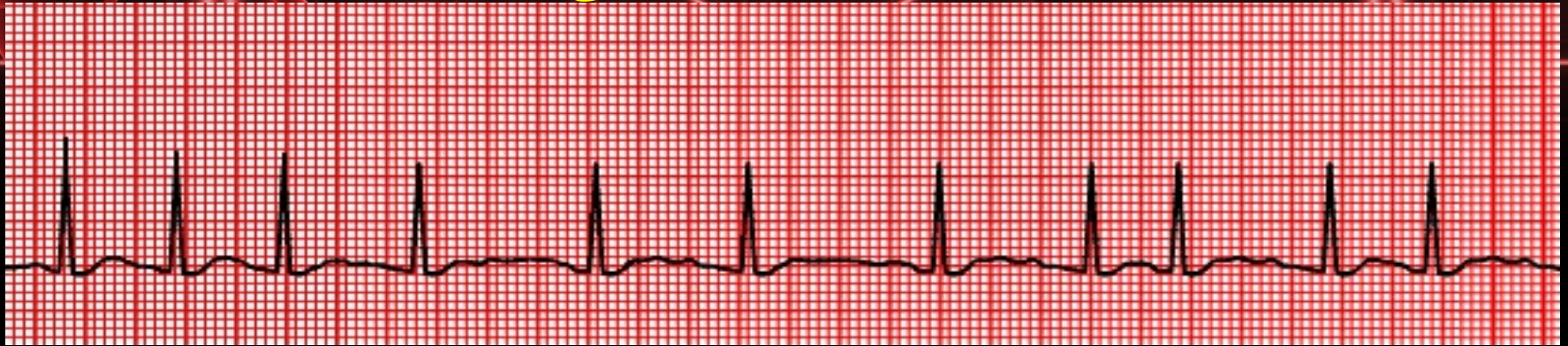Course Objectives

At the conclusion of this session, participants should be able to:

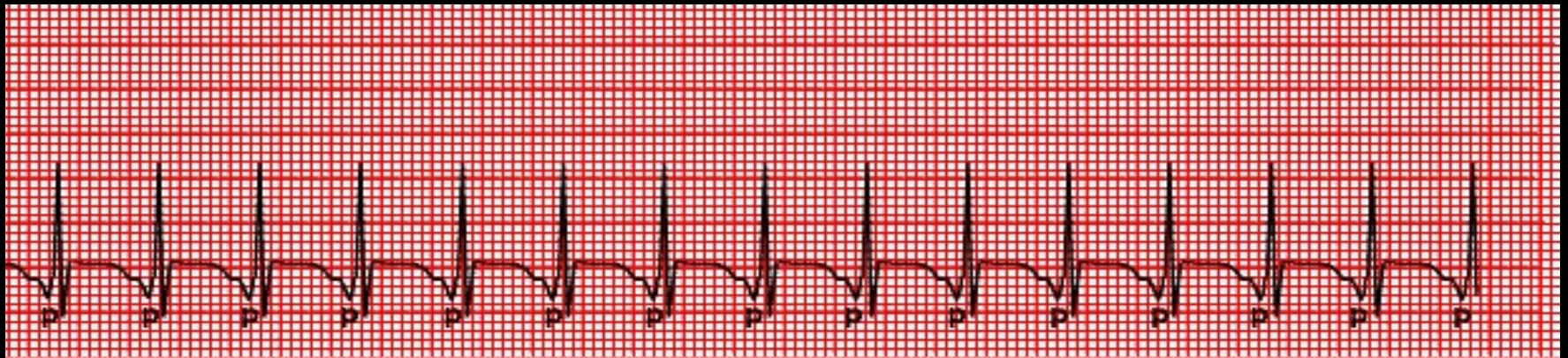- Apply a systematic approach to the interpretation of EKG's
- Identify dysrhythmias and their relevant implications
- Determine the mean QRS axis and state the common causes of axis deviation
- Describe the 12-Lead EKG features of ischemia, injury, and infarction
- Recognize ventricular hypertrophy, atrial enlargement, and bundle branch blocks



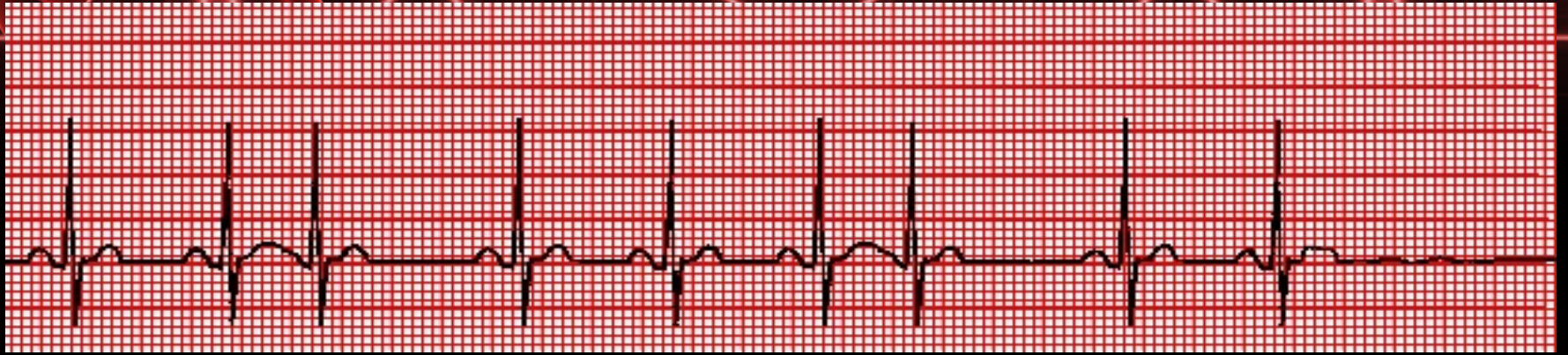
A Quick Review



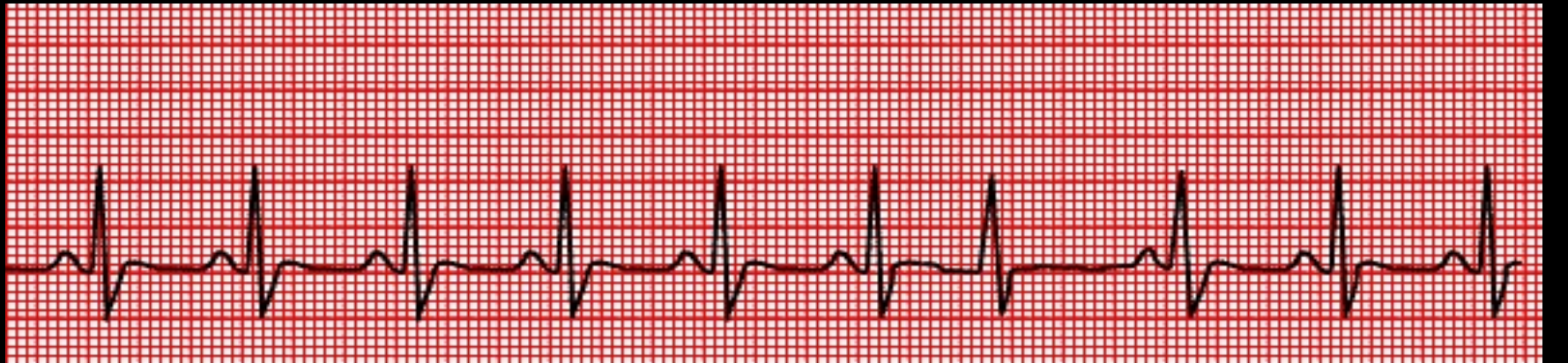A-fib



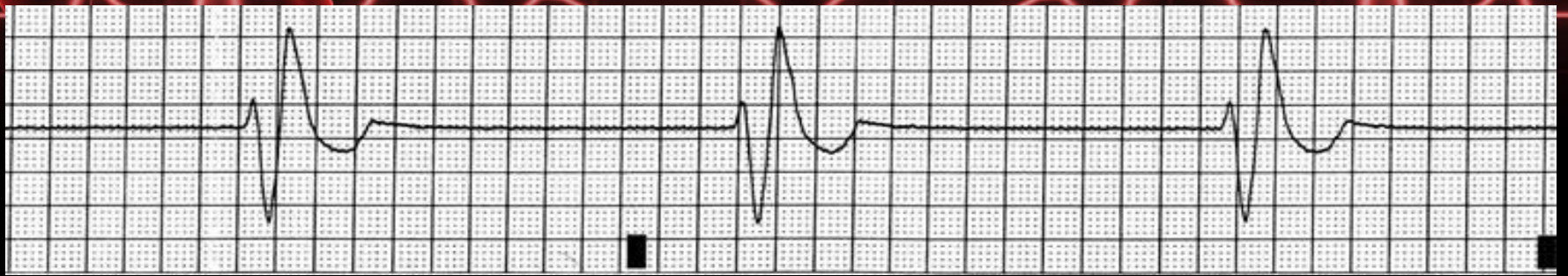
Junctional Tachycardia



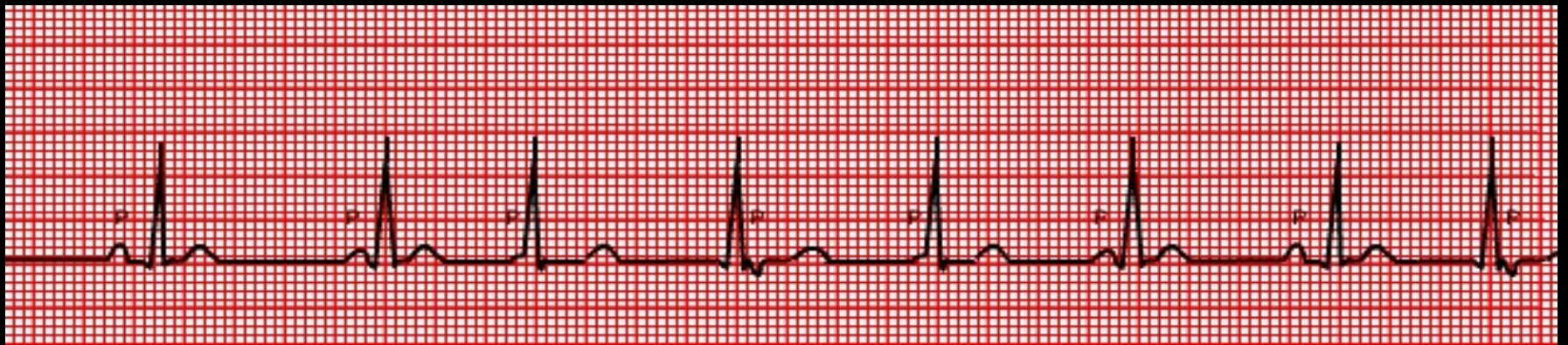PAC



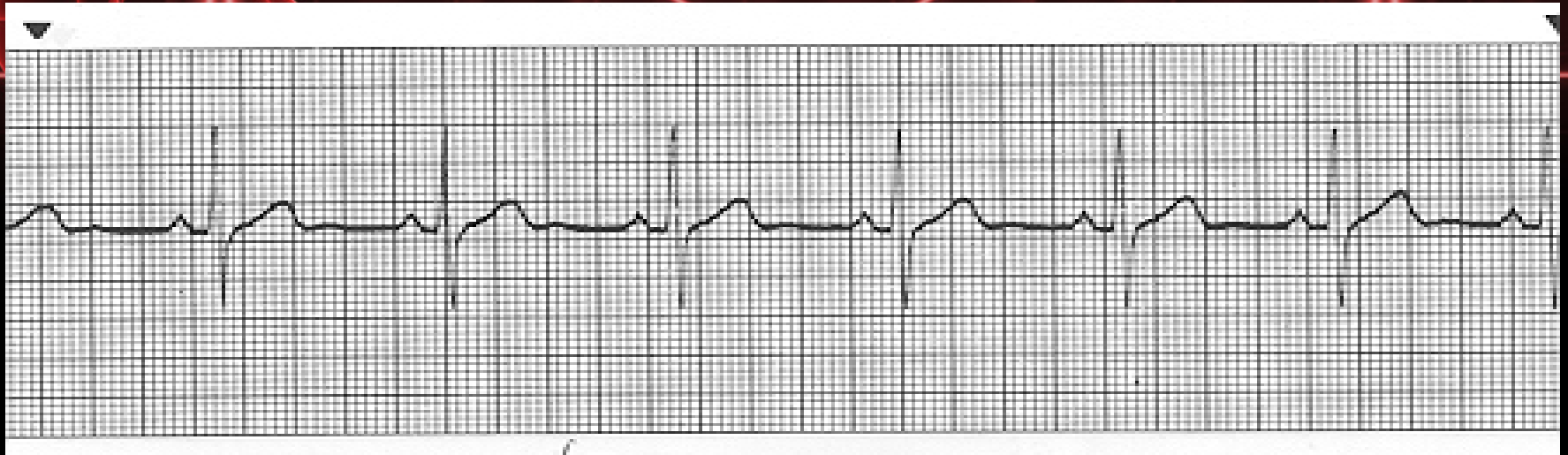
PJC



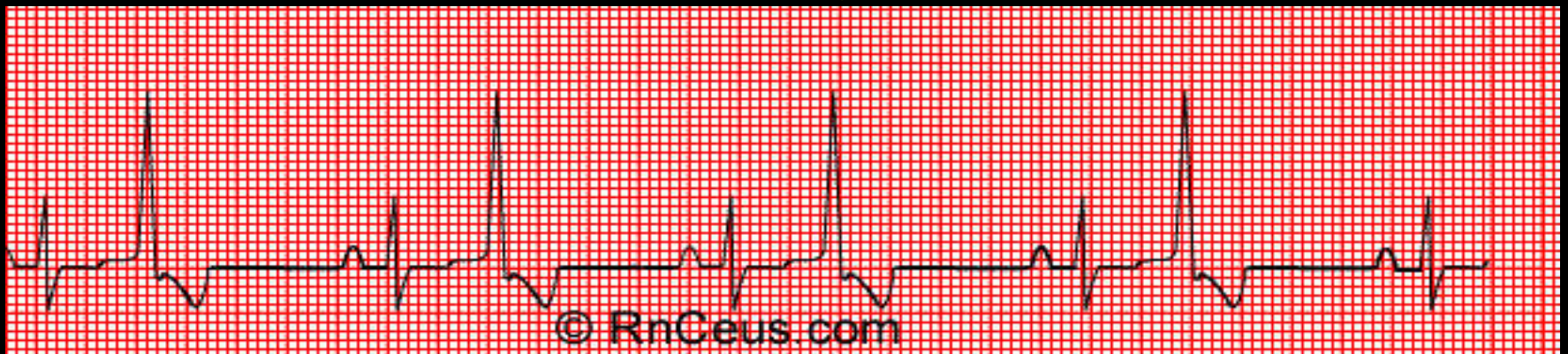
Idioventricular Rhythm



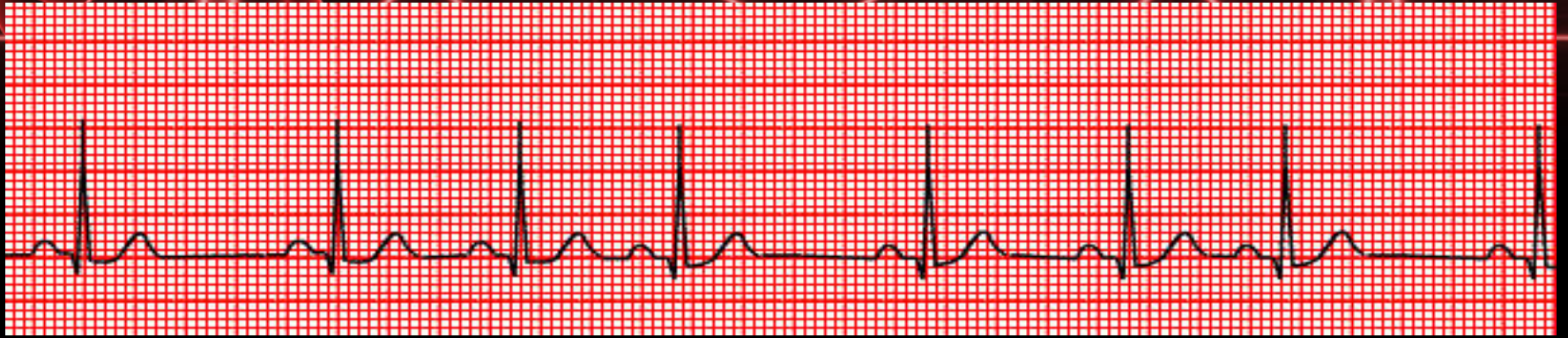
Wandering Pacemaker



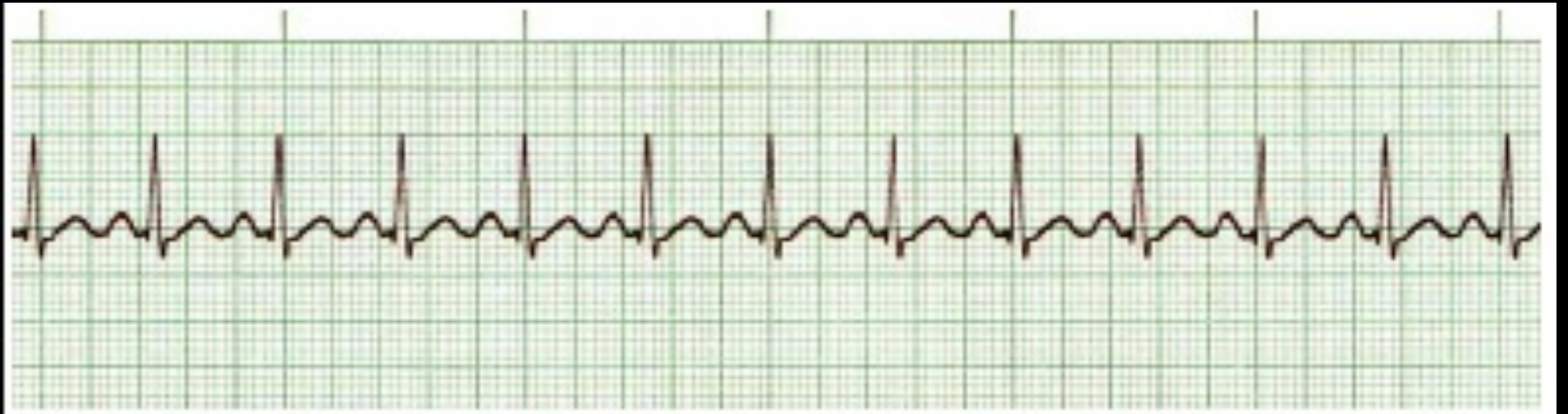Normal Sinus Rhythm



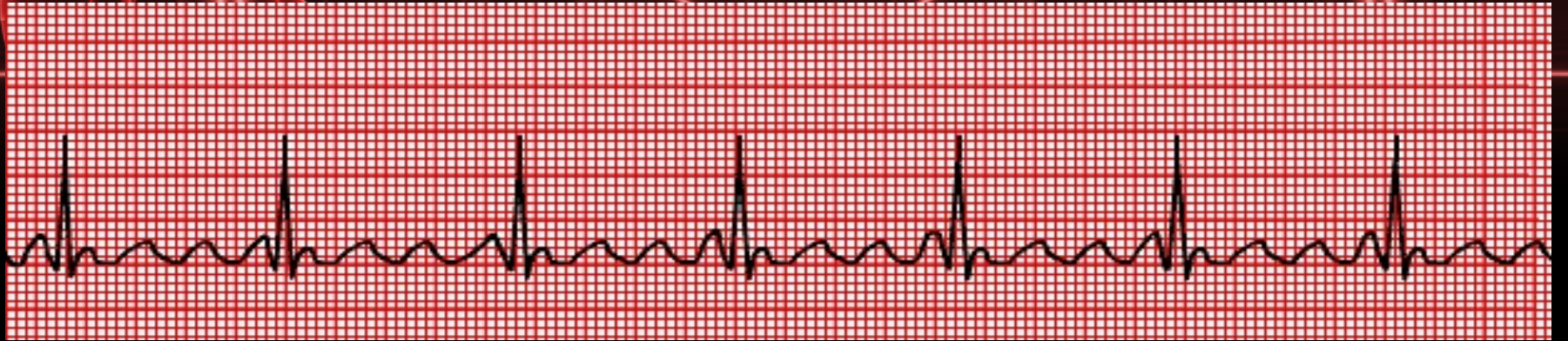
Sinus Rhythm with Bigeminy



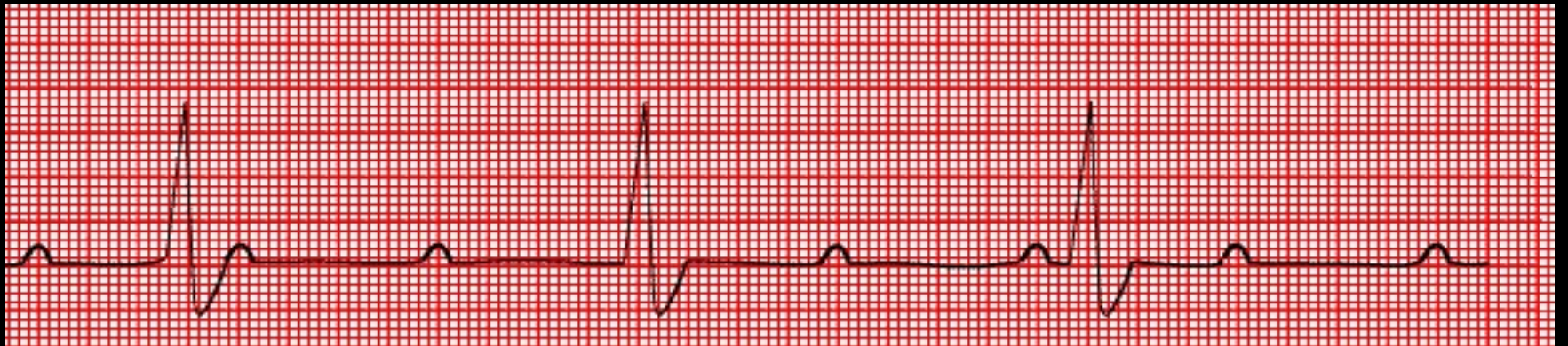Sinus Arrhythmia



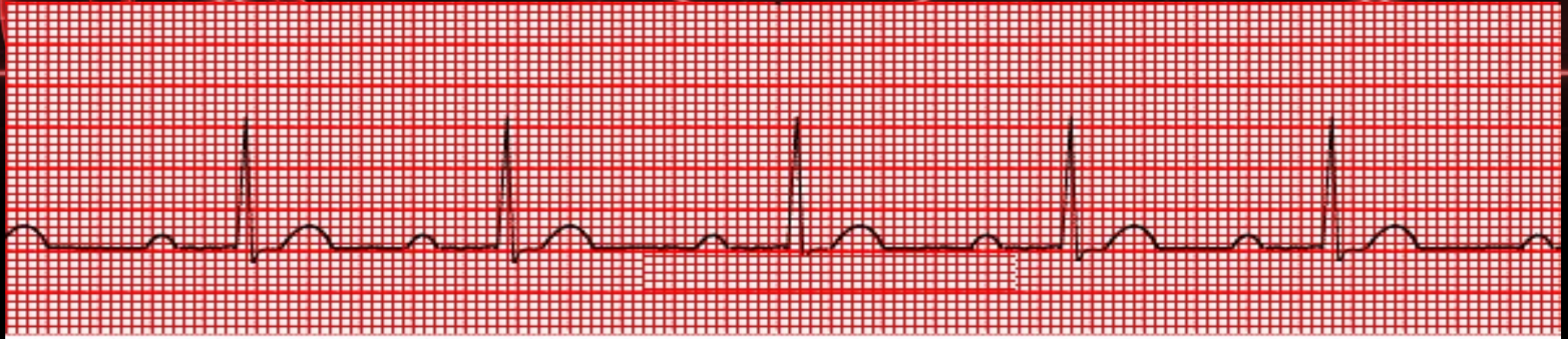
Sinus Tachycardia



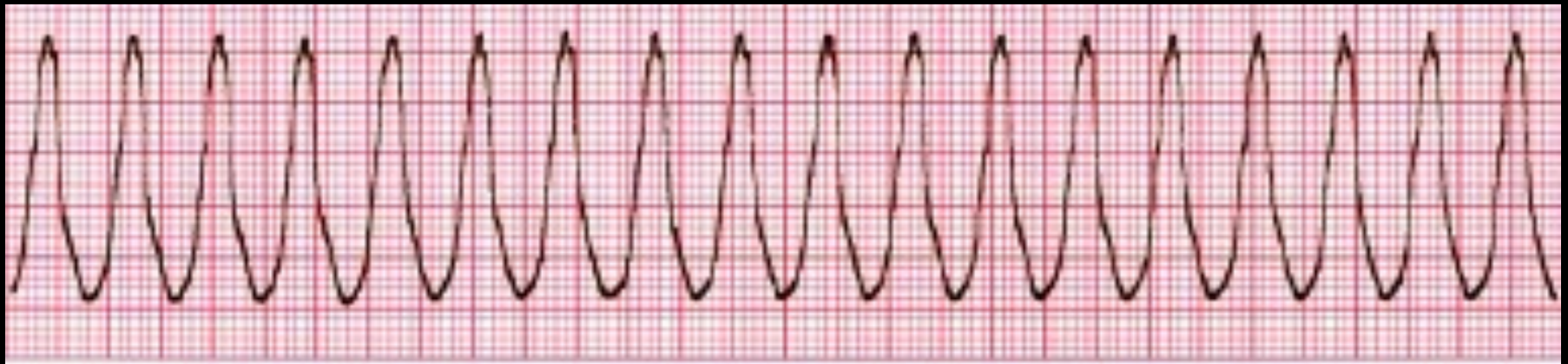Atrial Flutter



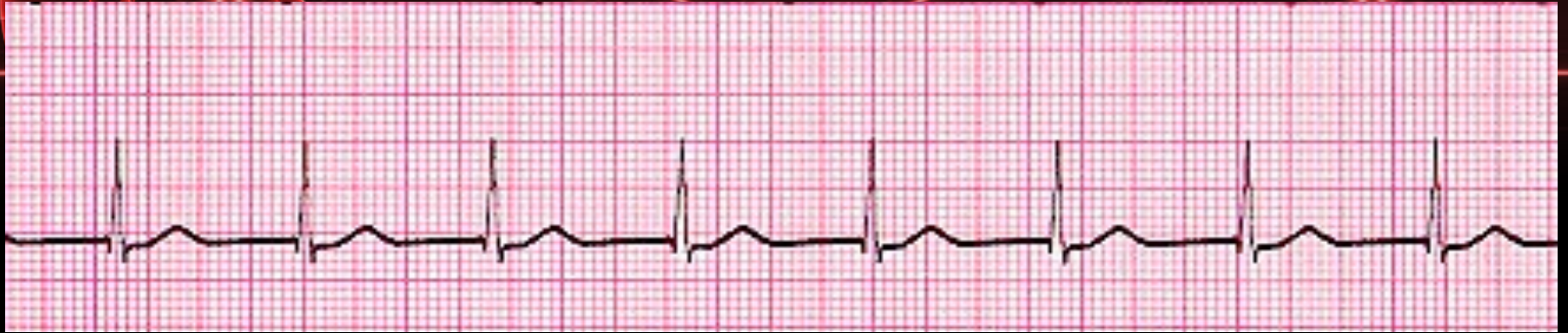3rd Degree AV Block



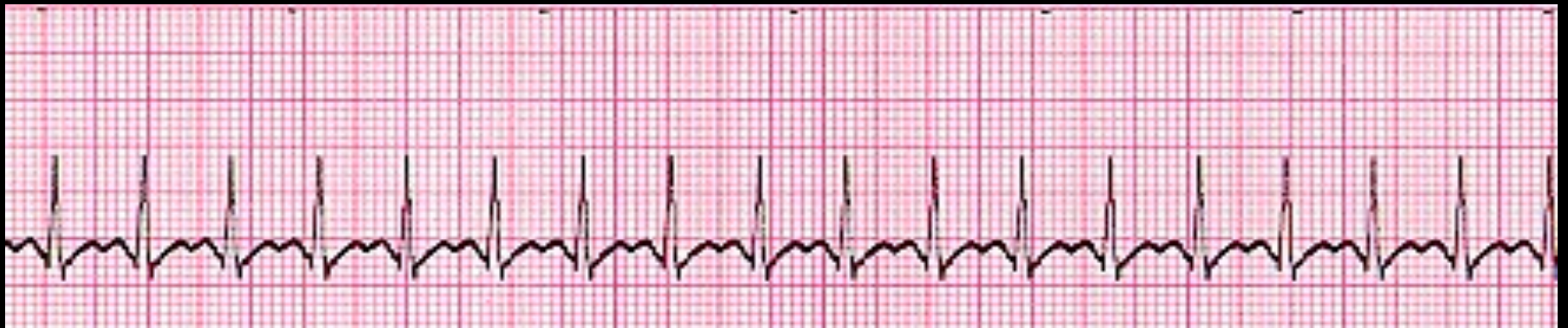1st Degree AV Block



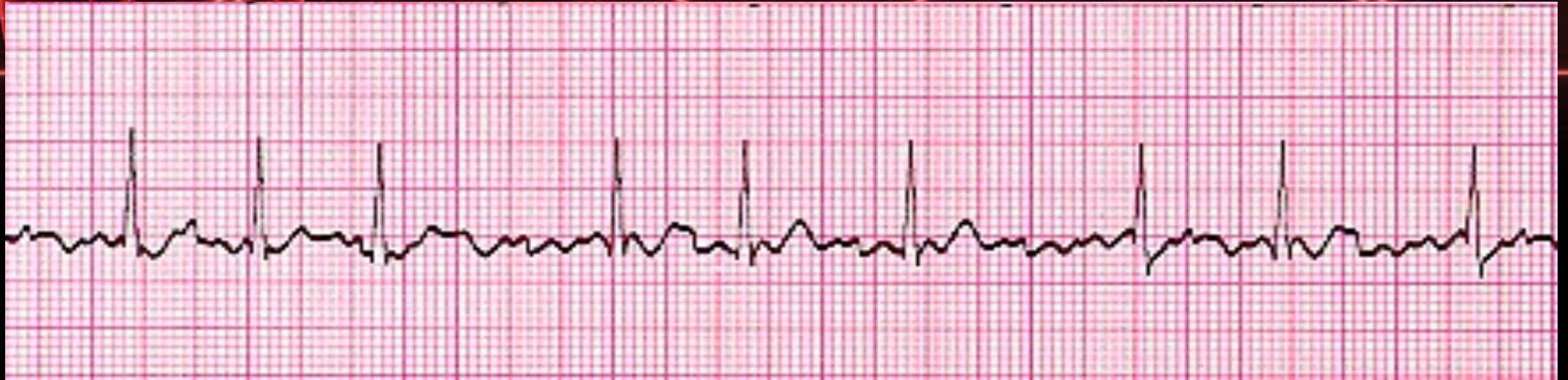Ventricular Tachycardia



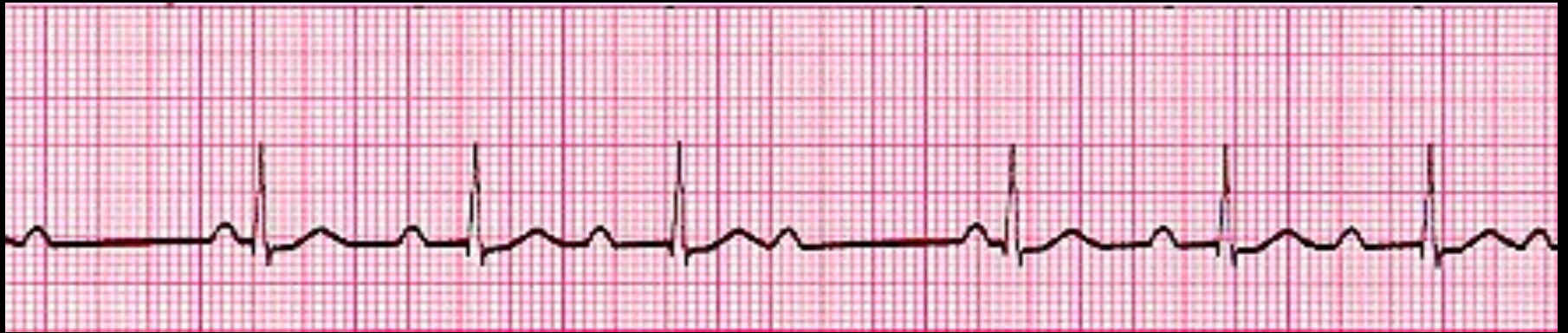Accelerated Junctional Rhythm



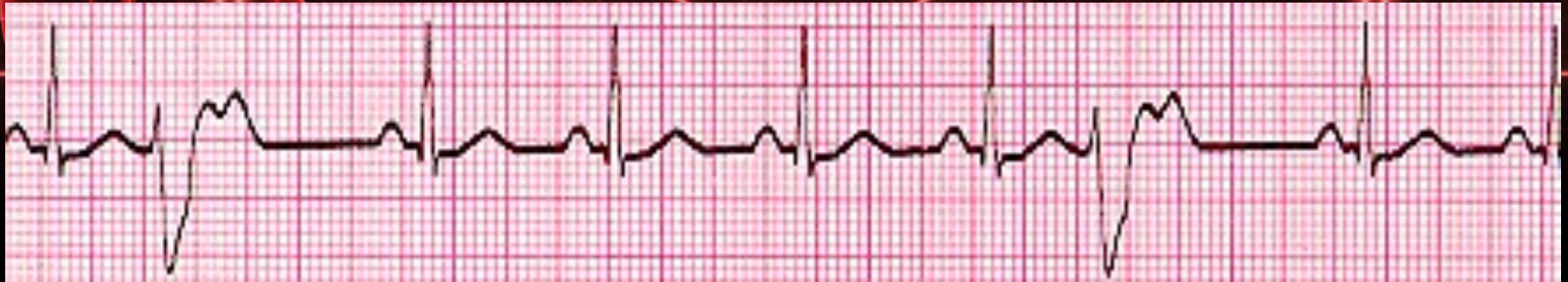Supraventricular Tachycardia



Atrial Fibrillation (again)



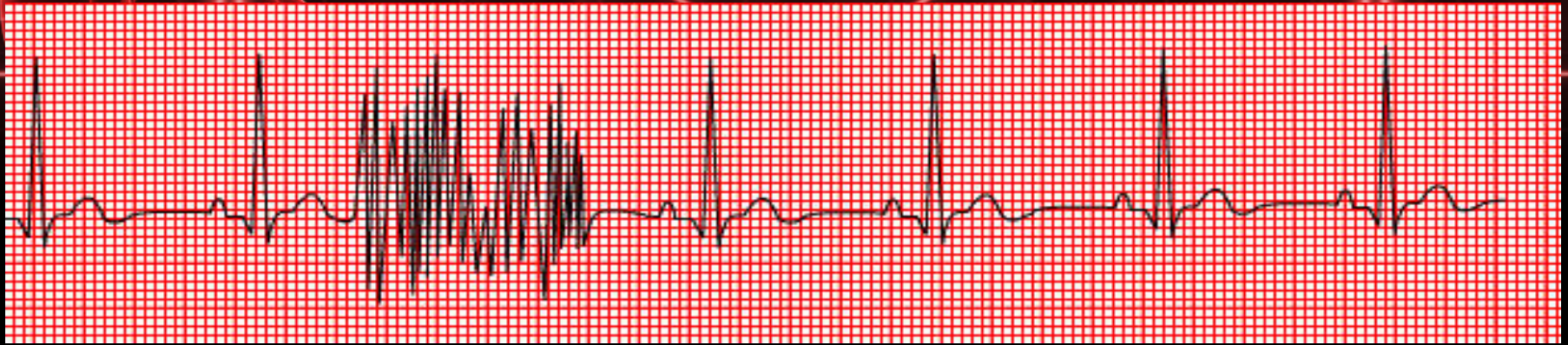2nd Degree AV Block type I (Wenchebach)



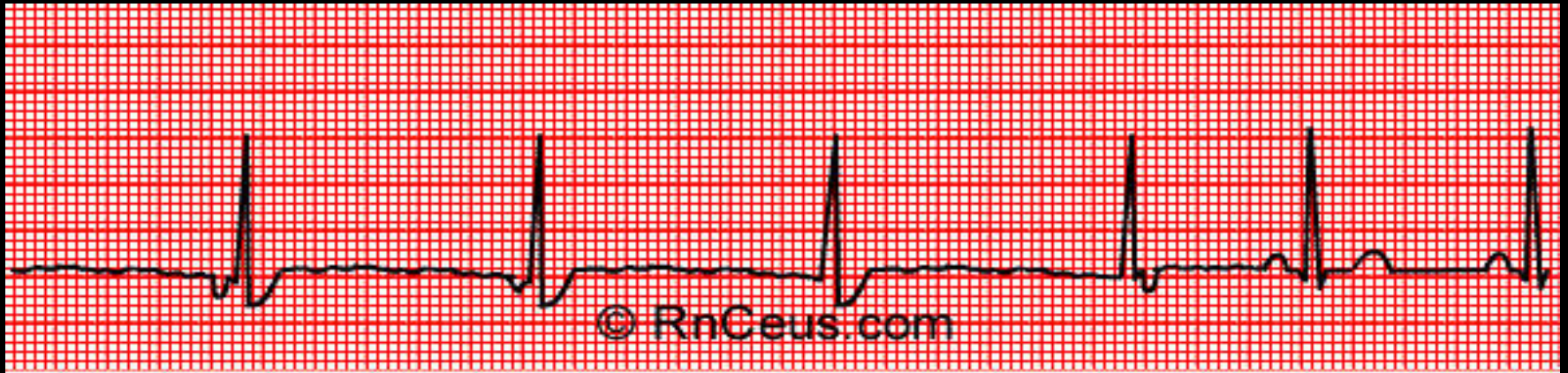
Sinus Rhythm with Unifocal PVC's



Torsade de Pointes



Sinus Rhythm with Artifact

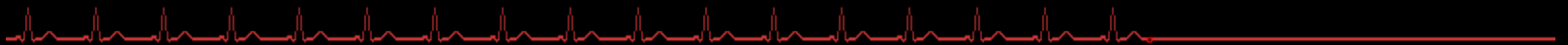

Junctional Escape Rhythm

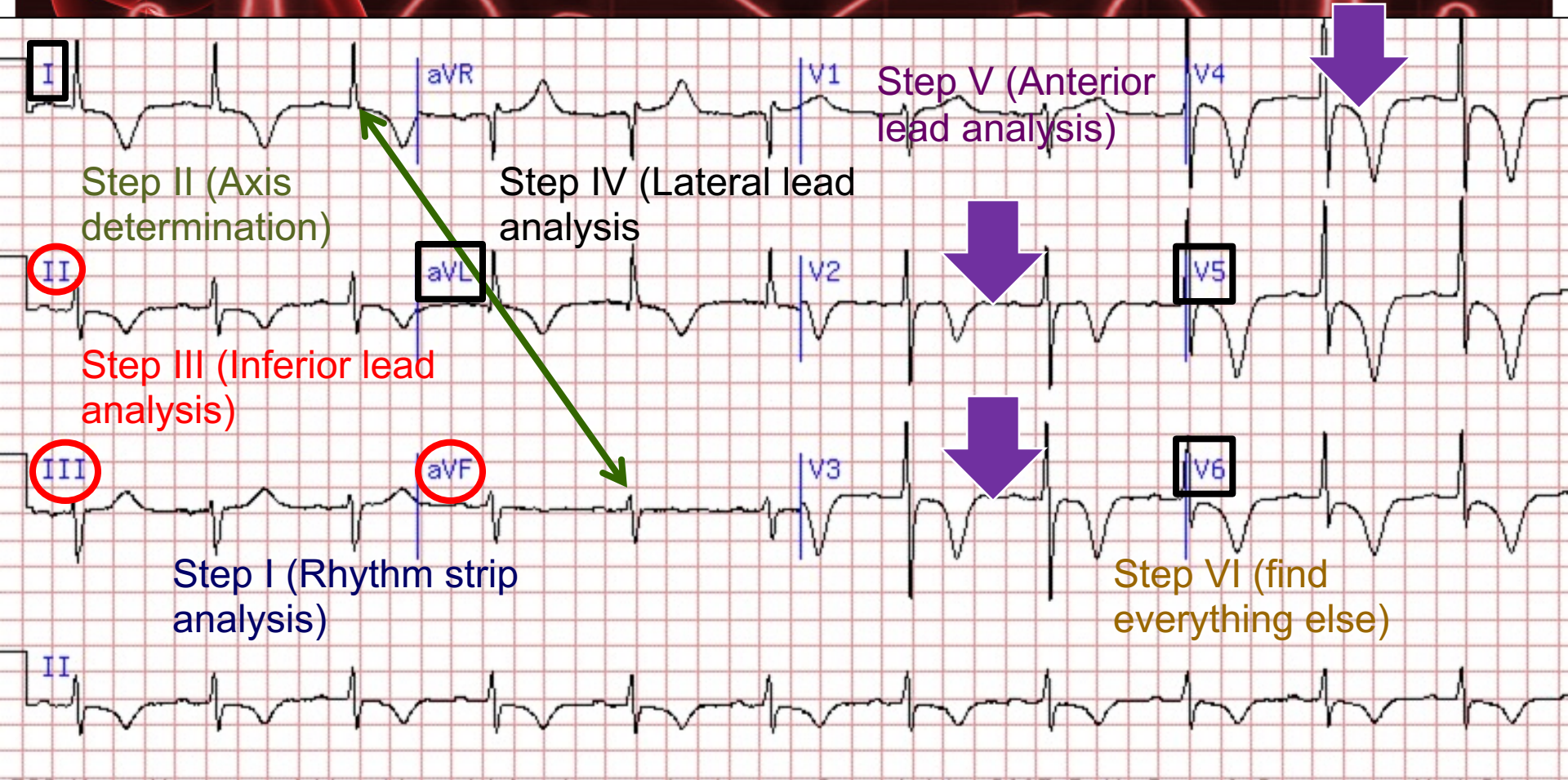


Steps in Interpreting the 12-Lead

1. Assess the rate (atrial and ventricular) and regularity of the underlying rhythm.
 - a) Assess the usual intervals and widths: PR interval, QRS width, QT interval.
 - b) Interpret the rhythm itself.
2. Determine the axis.
3. Grouped lead analysis
 - a) Look for signs of infarct vs. ischemia in all grouped leads
4. Look for any other abnormality



Assessing the EKG

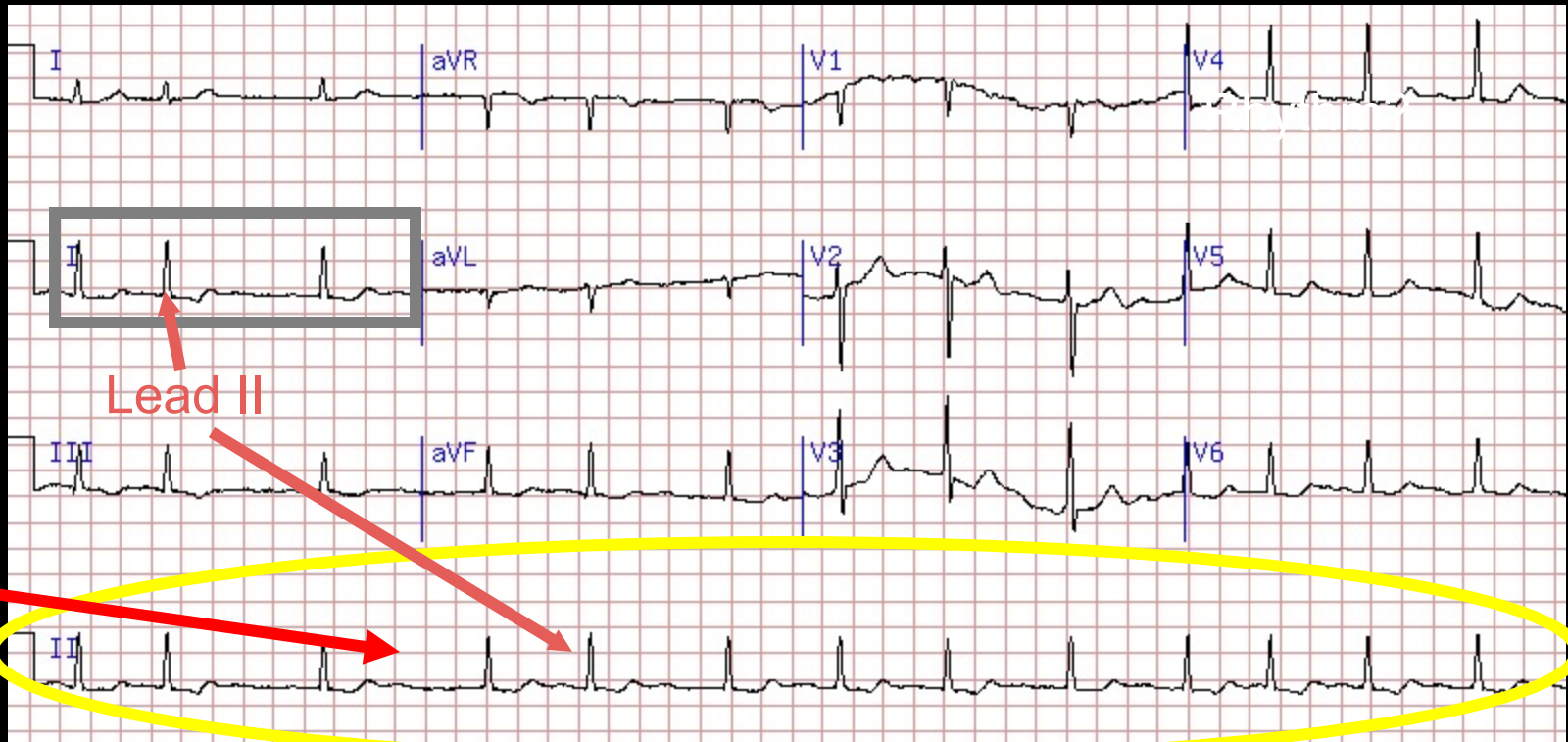


Assessing the EKG Rhythm

Tip: the rhythm strip portion of the 12-lead EKG is a good place to look at when trying to determine the rhythm because the 12 leads only capture a few beats.

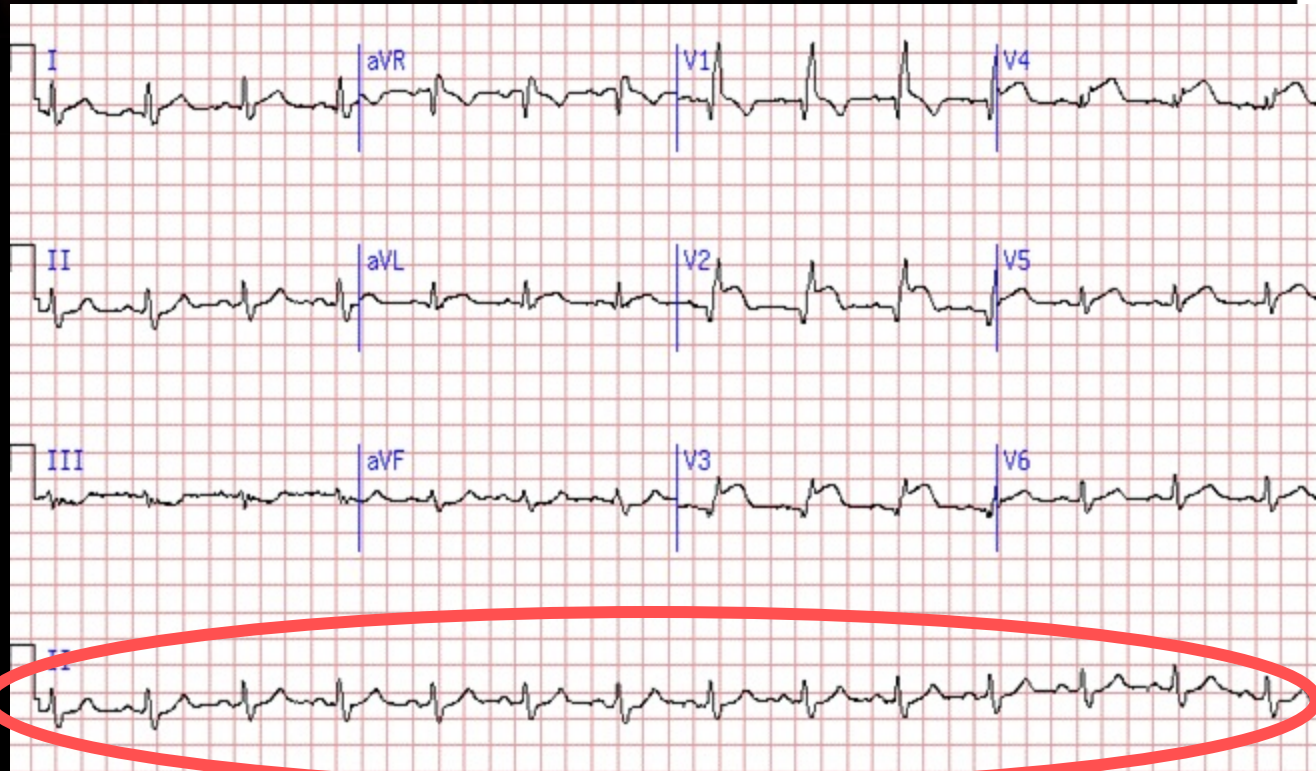
Atrial fibrillation

Rhythm strip



Assessing the EKG Rate

If you use the rhythm strip portion of the 12-lead EKG the total length of it is always 10 seconds long. So you can count the number of R waves in the rhythm strip and multiply by 6 to determine the beats per minute.



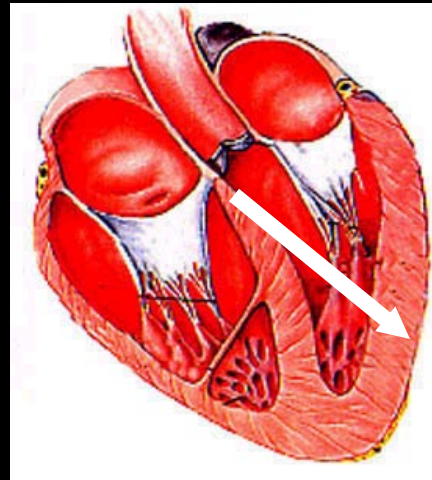
Rate?

$$14 (R \text{ waves}) \times 6 = 84 \text{ bpm}$$

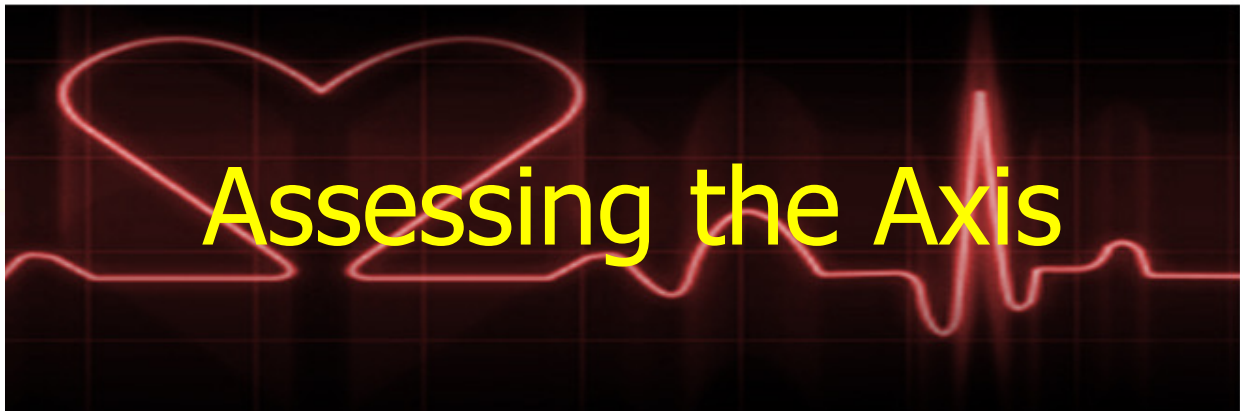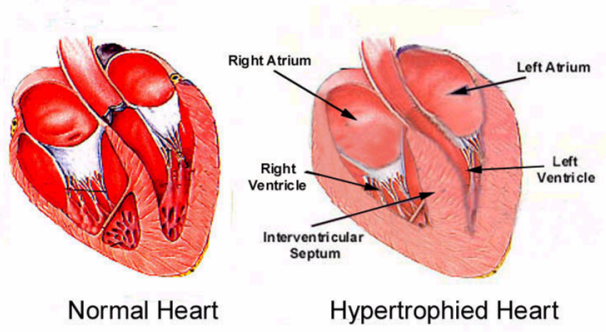


Assessing the Axis

Axis refers to the **mean QRS axis** (or vector) during ventricular depolarization. As you recall when the ventricles depolarize (in a normal heart) the direction of current flows leftward and downward because most of the ventricular mass is in the left ventricle. We like to know the QRS axis because an abnormal axis can suggest disease such as pulmonary hypertension from a pulmonary embolism.

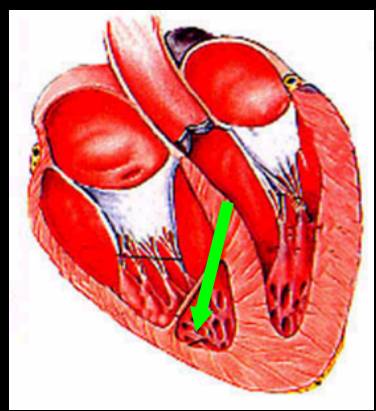
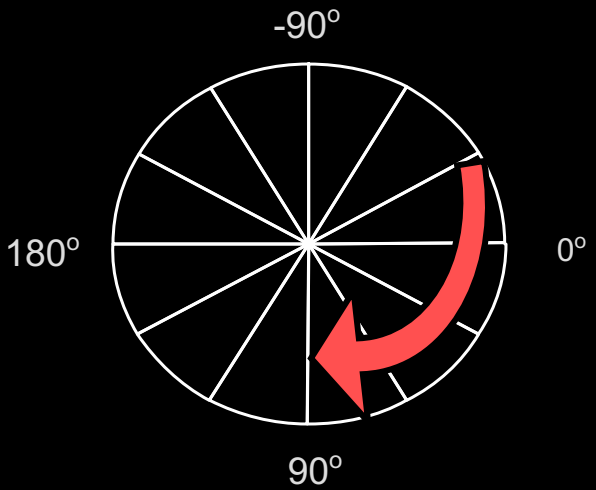
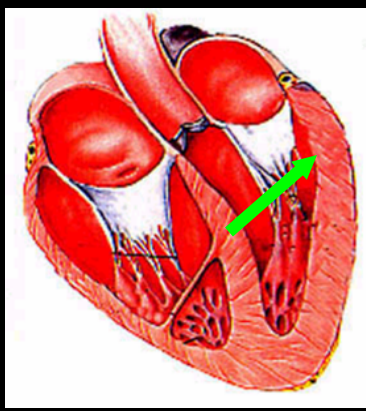


Hypertrophic Cardiomyopathy



- Causes of left axis deviation include:
 - Left ventricular hypertrophy
 - Inferior wall MI
 - Left bundle branch block
 - Left anterior fascicular block

- Causes of right axis deviation include:
 - Right ventricular hypertrophy
 - Lateral wall MI
 - Right bundle branch block
 - Pulmonary hypertension

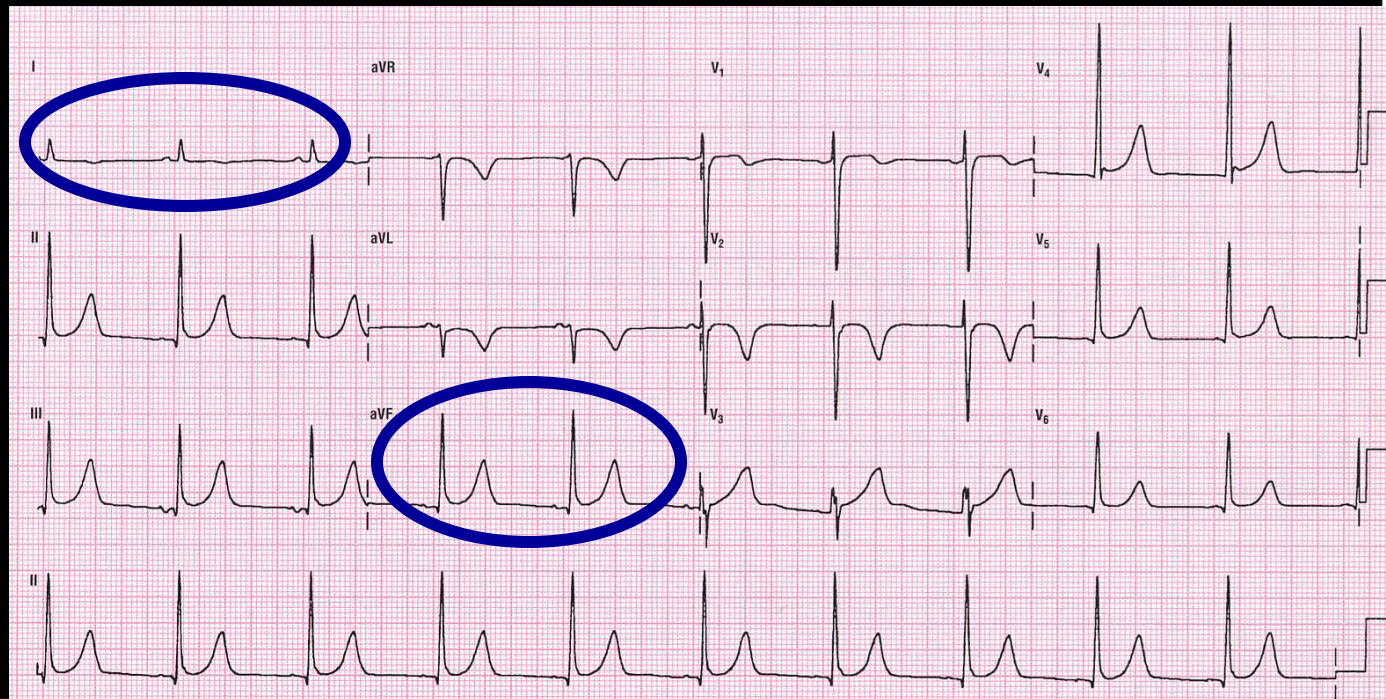


Assessing the Axis

We can quickly determine whether the QRS axis is normal by looking at leads I and aVF.

If the QRS complex is overall **positive** in **leads I** and **aVF**, the QRS axis is **normal**.

Both R-waves are more + than the S-waves



Assessing the Axis

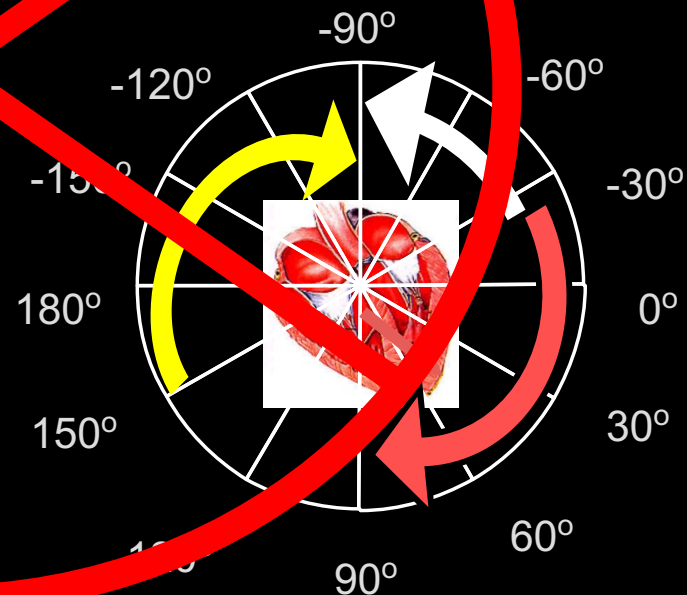
The QRS axis is determined by overlying a circle, in the frontal plane. By convention, the degrees of the circle are as shown

The **normal QRS axis** lies between -30° and $+90^{\circ}$.

A QRS axis that falls between -30° and -90° is abnormal and called **left axis deviation**.

A QRS axis that falls between $+90^{\circ}$ and $+150^{\circ}$ is abnormal and called **right axis deviation**.

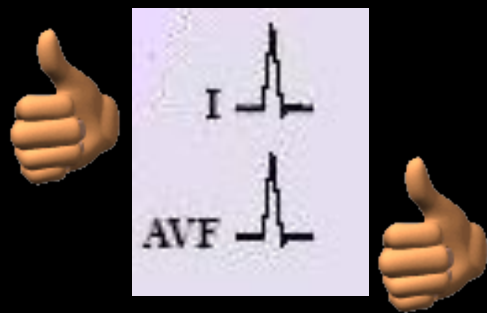
A QRS axis that falls between $+150^{\circ}$ and -90° is abnormal and called **extreme right axis deviation**.




Assessing the Axis

The thumb method

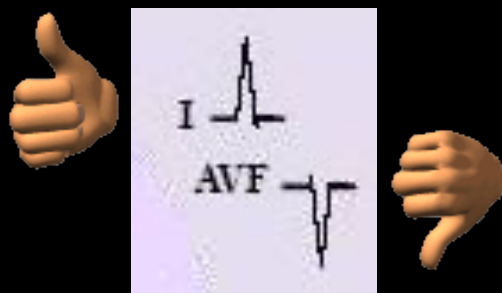
Always go with the positive thumb!!!!



Normal Axis



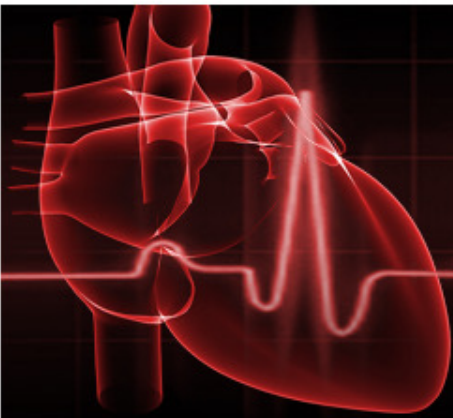
Right Axis



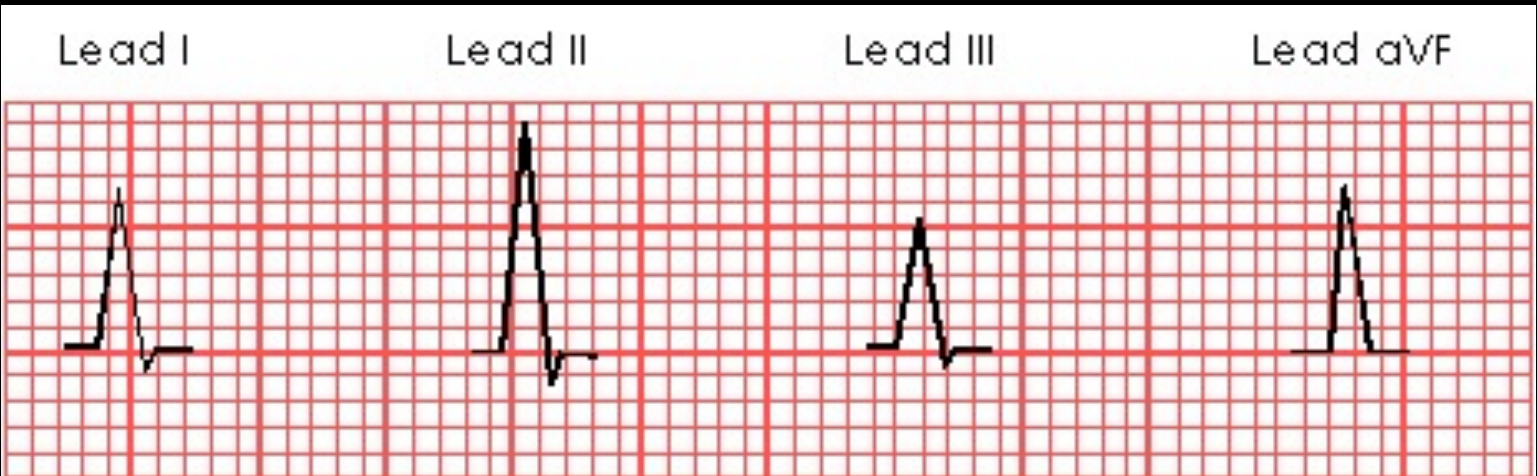
Left Axis



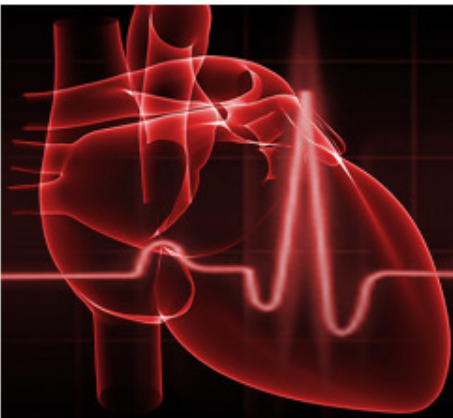
Extreme Right Axis



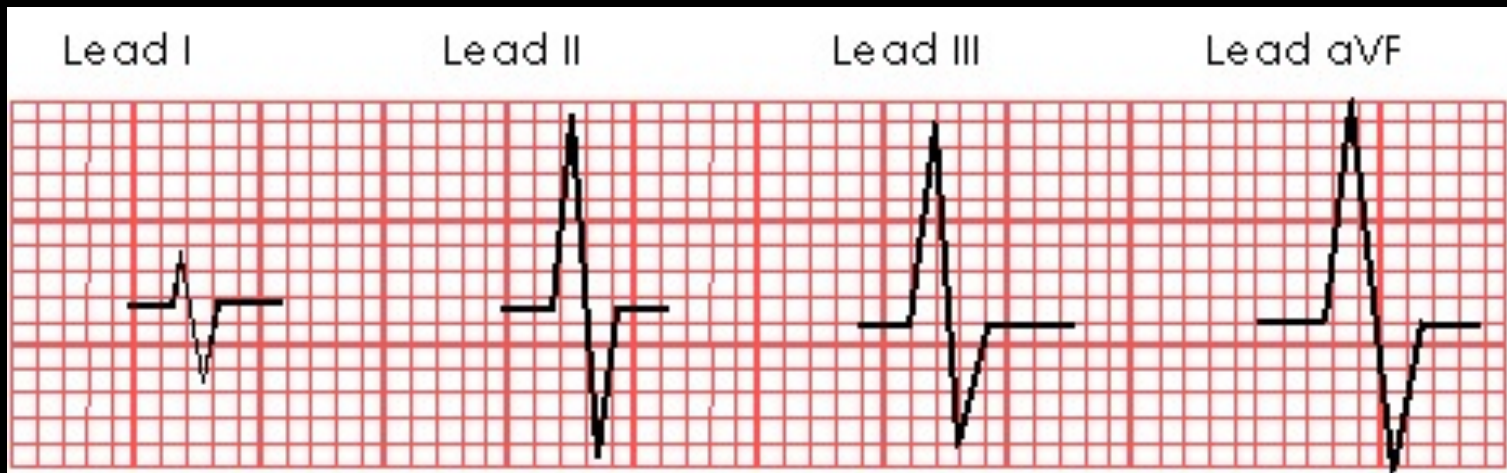
Normal, Right or Left Axis?



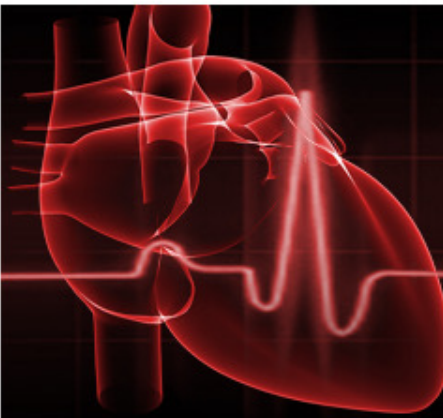
Normal



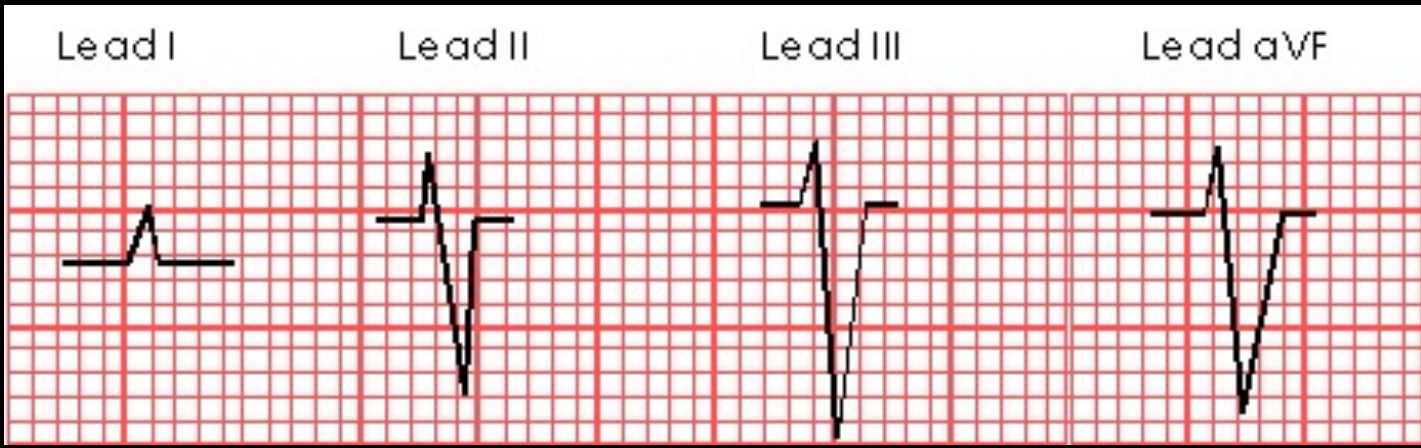
Normal, Right or Left Axis?



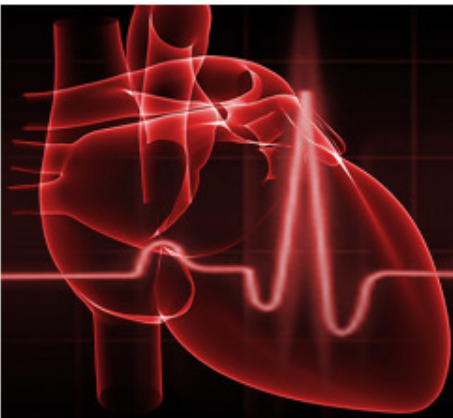
Right



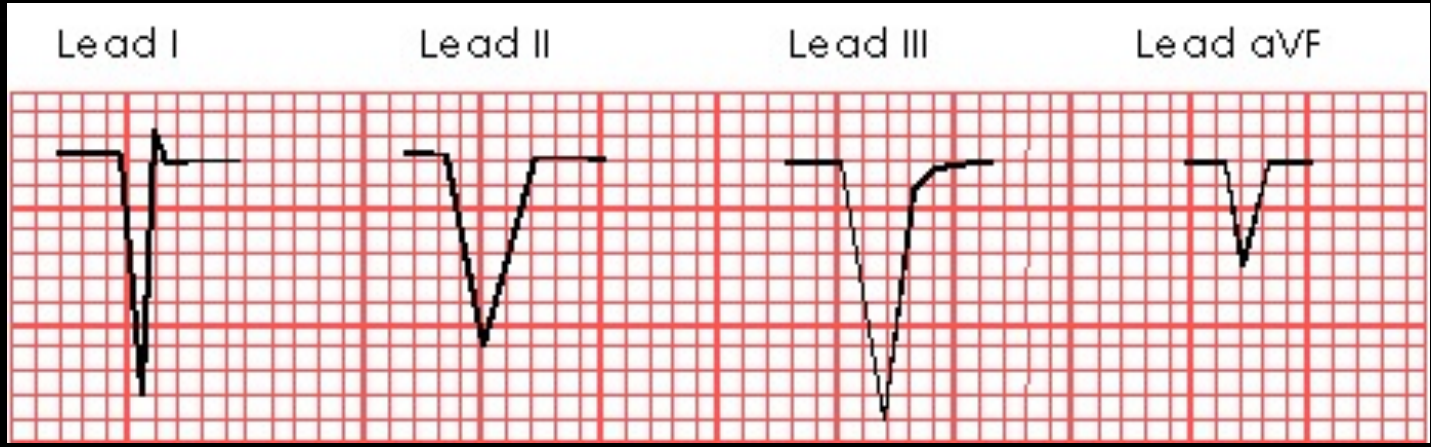
Normal, Right or Left Axis?



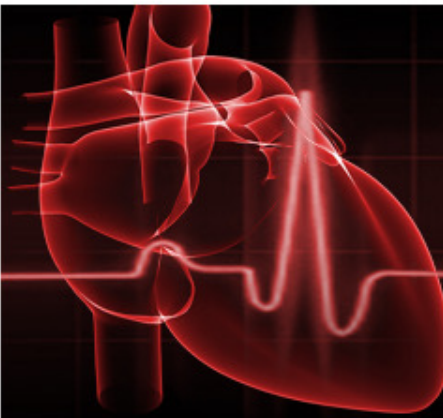
Left



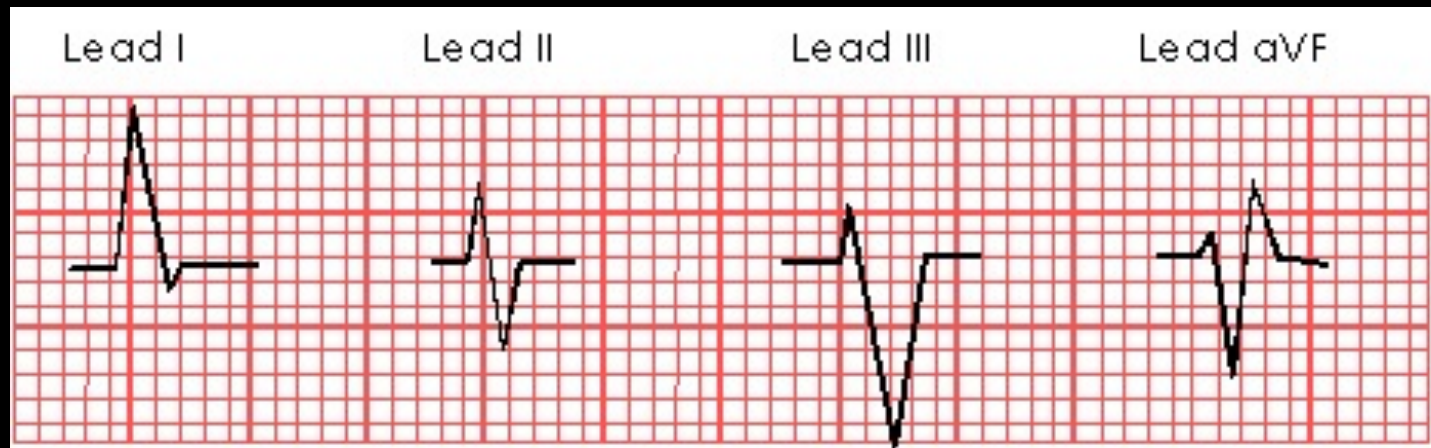
Normal, Right or Left Axis?



Extreme Right



Normal, Right or Left Axis?

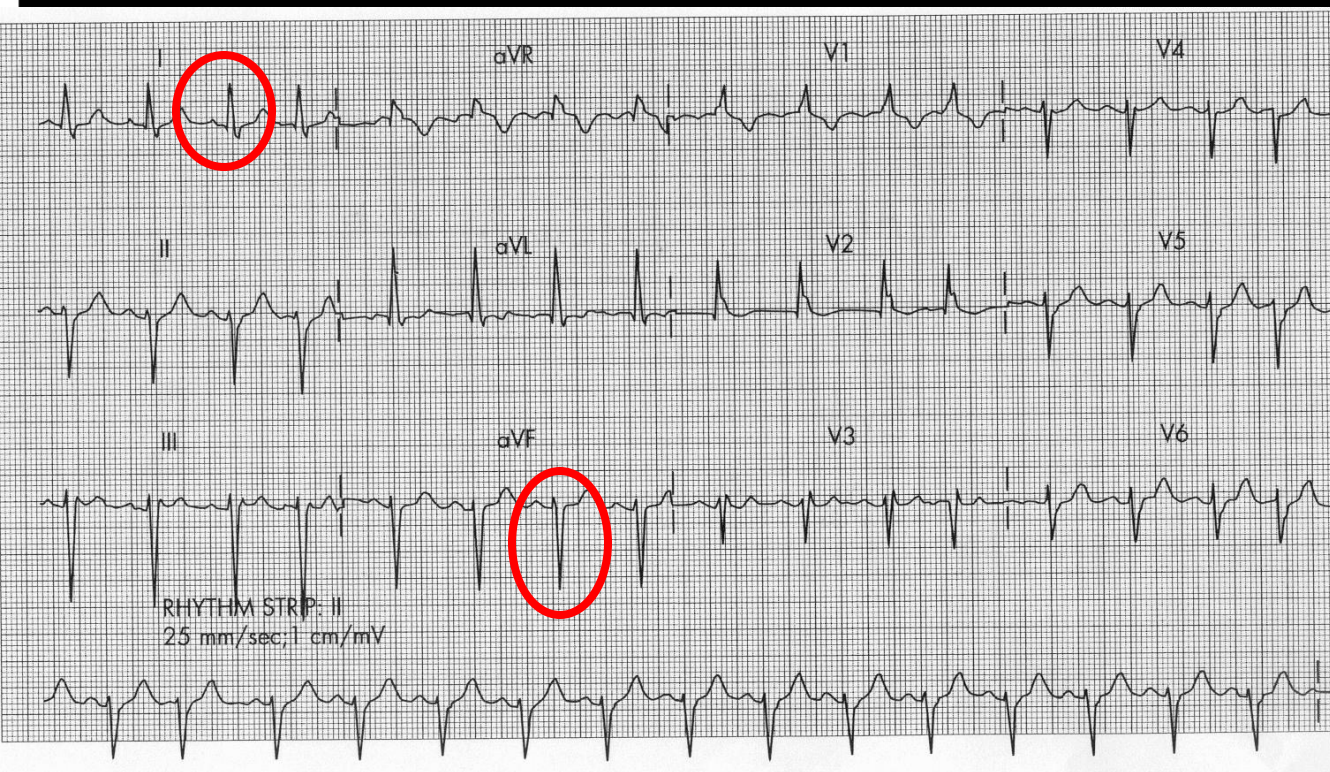


Left

Assessing the Axis

Is the QRS axis normal in this EKG?

No, there is left axis deviation.



The QRS is positive in I and negative in aVF.

Grouped lead analysis

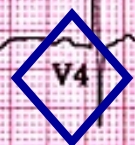

2. Lateral leads

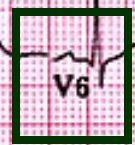
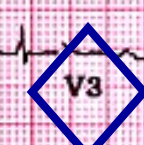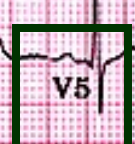
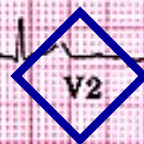
aVR



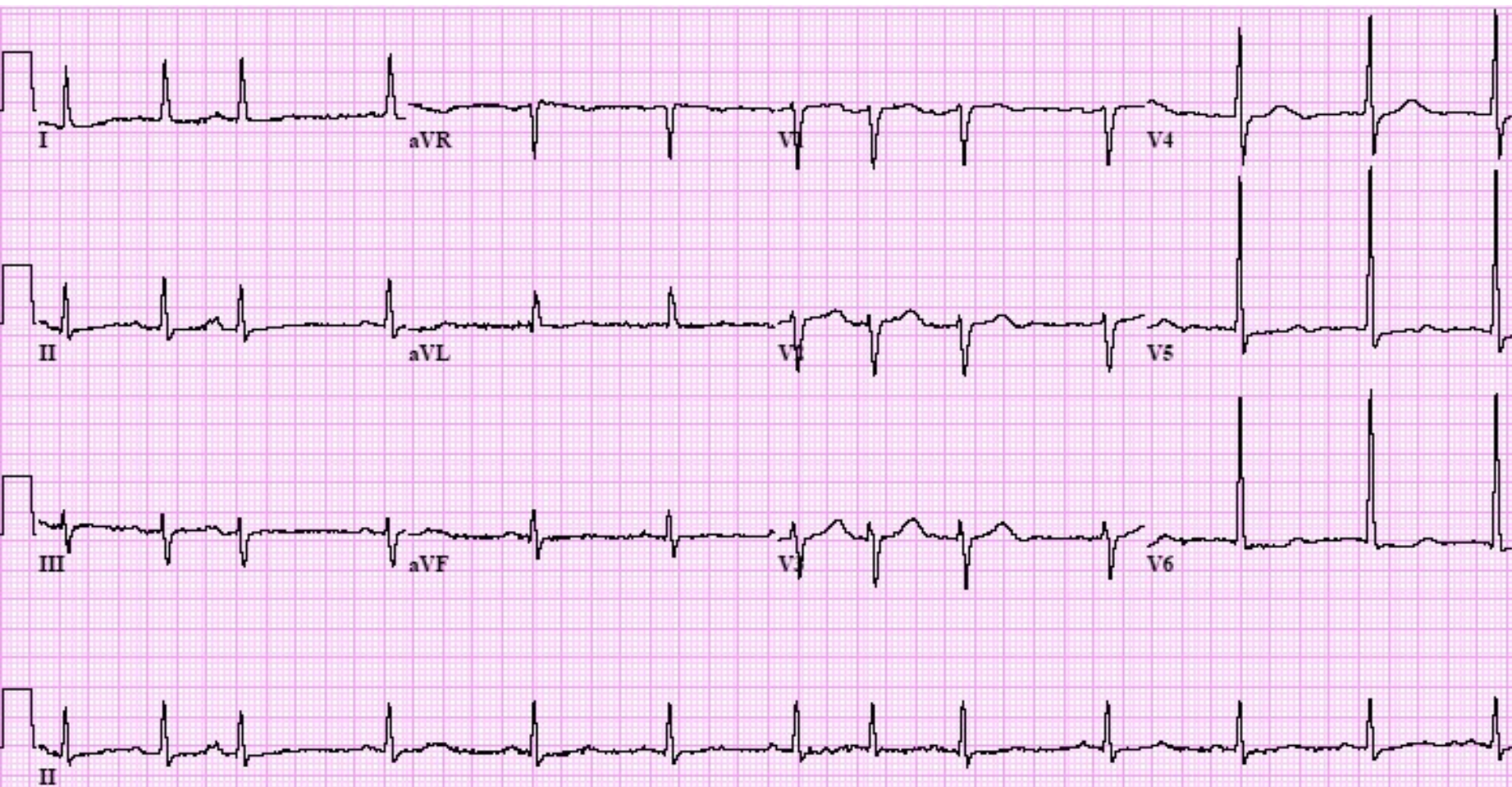
3. Anterior leads



1. Inferior leads



V1



Rate Variable Rhythm Regular? Irregular P-Waves Upright? Yes

Significant Q-Waves? No Any ectopic beats? Yes, but caused by the rhythm

Rhythm is Sinus Arrhythmia

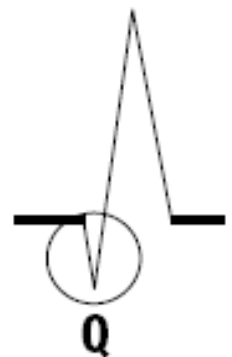


0

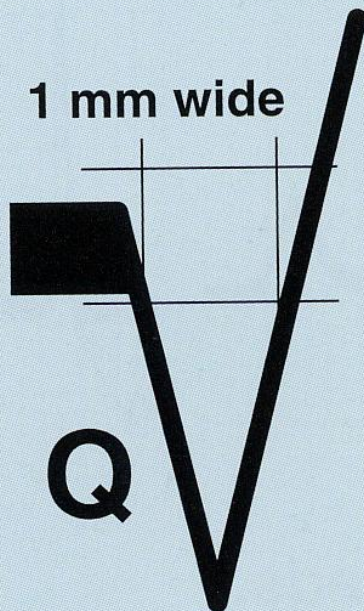
-Waves

Q wave = Necrosis (significant Q's only)

- Significant Q wave is one millimeter (one small square) wide, which is .04 sec. in duration...
- ... or is a Q wave 1/3 the amplitude (or more) of the QRS complex.
- Note those leads (omit AVR) where significant Q's are present
 - * A Q wave in lead III alone is not diagnostic of infarction, even if it is otherwise "significant" in size and width. Qs in III are ignored unless other abnormalities are seen b/c they usually represent.....
- Old infarcts: significant Q waves (like infarct damage) remain for a lifetime.

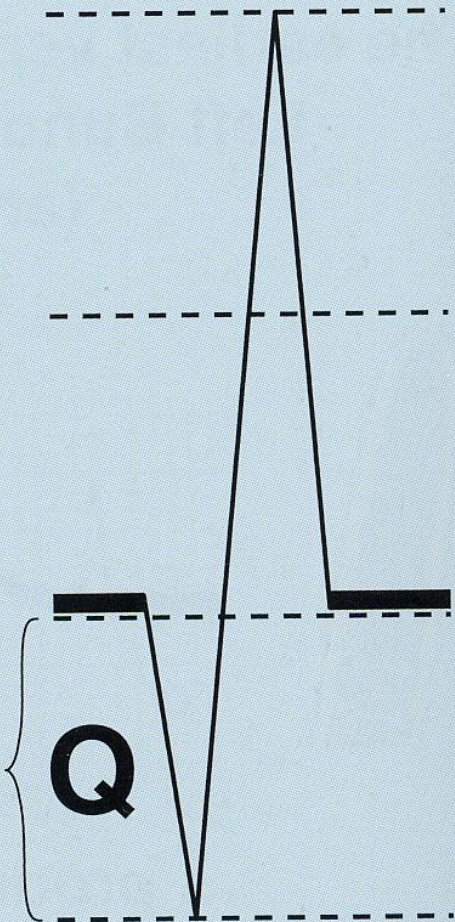


Significant Q waves

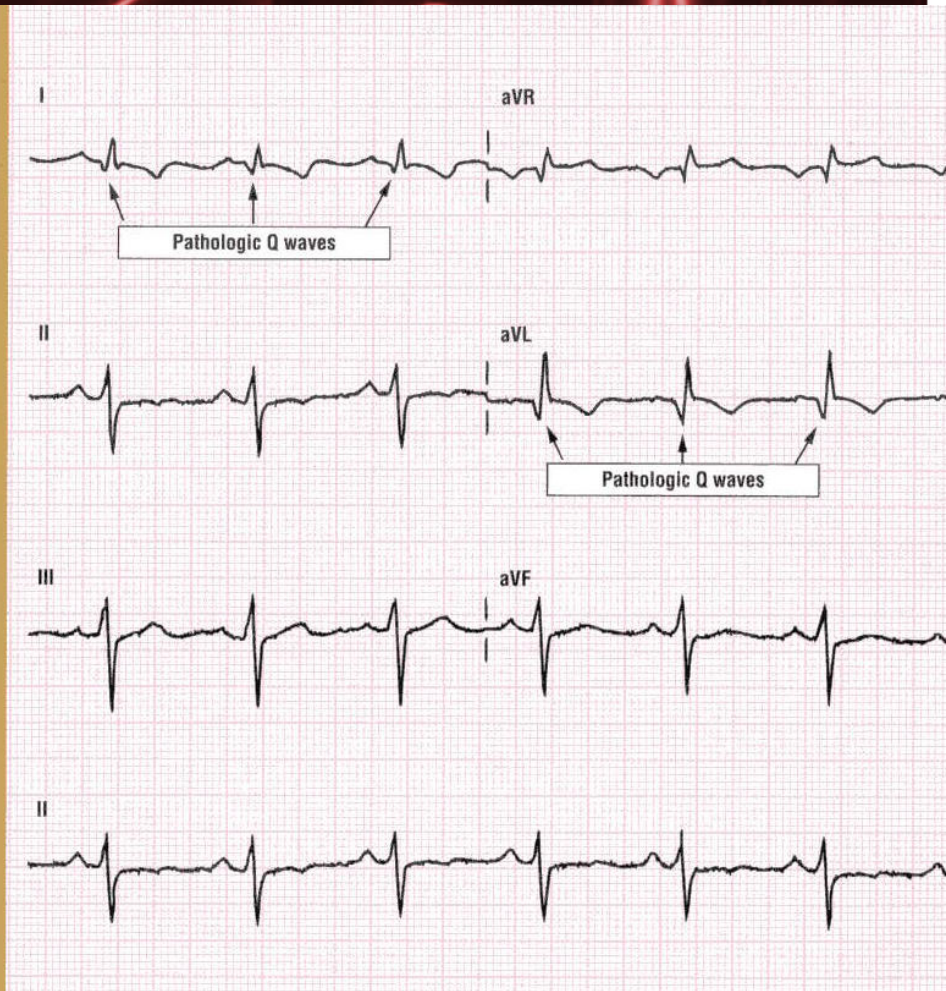
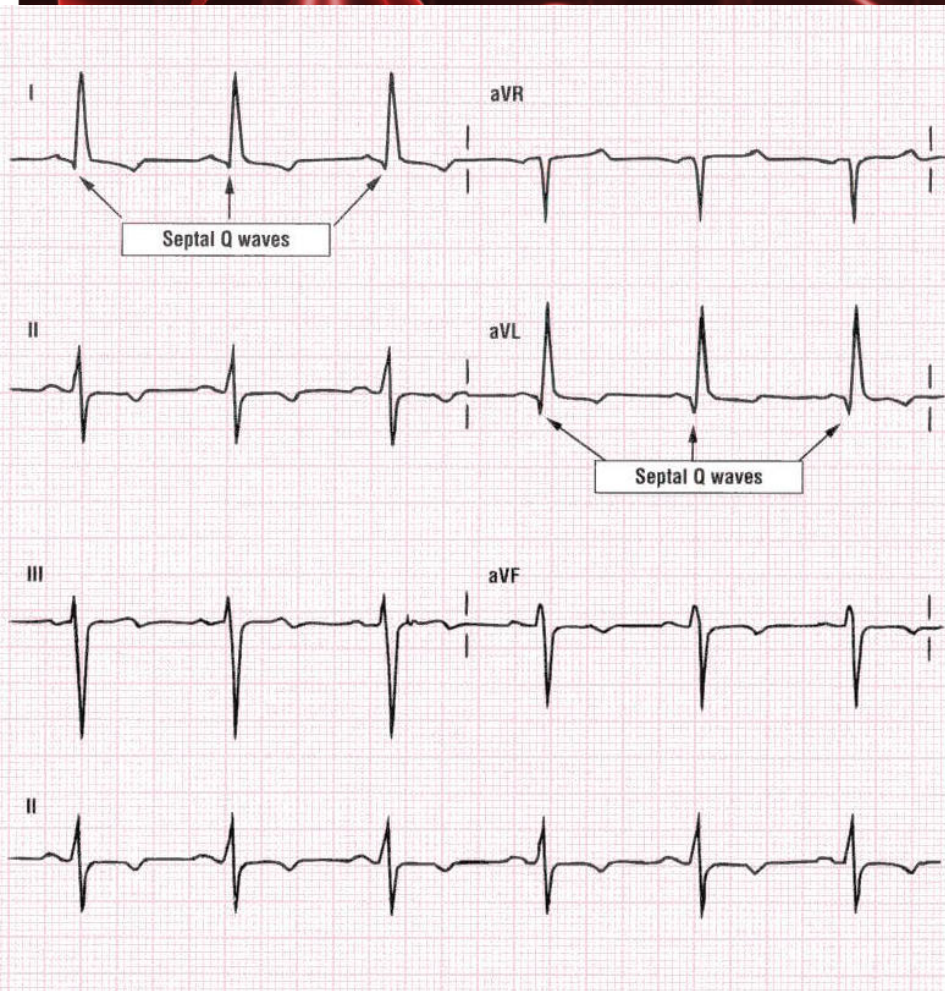


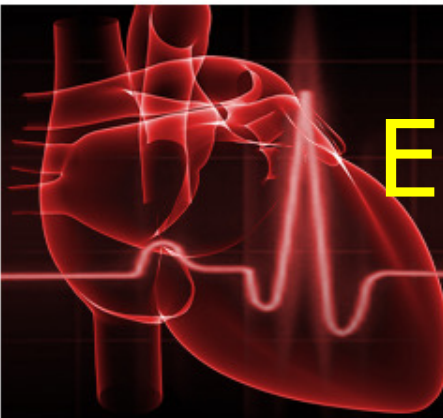
or

$\frac{1}{3}$ of QRS amplitude

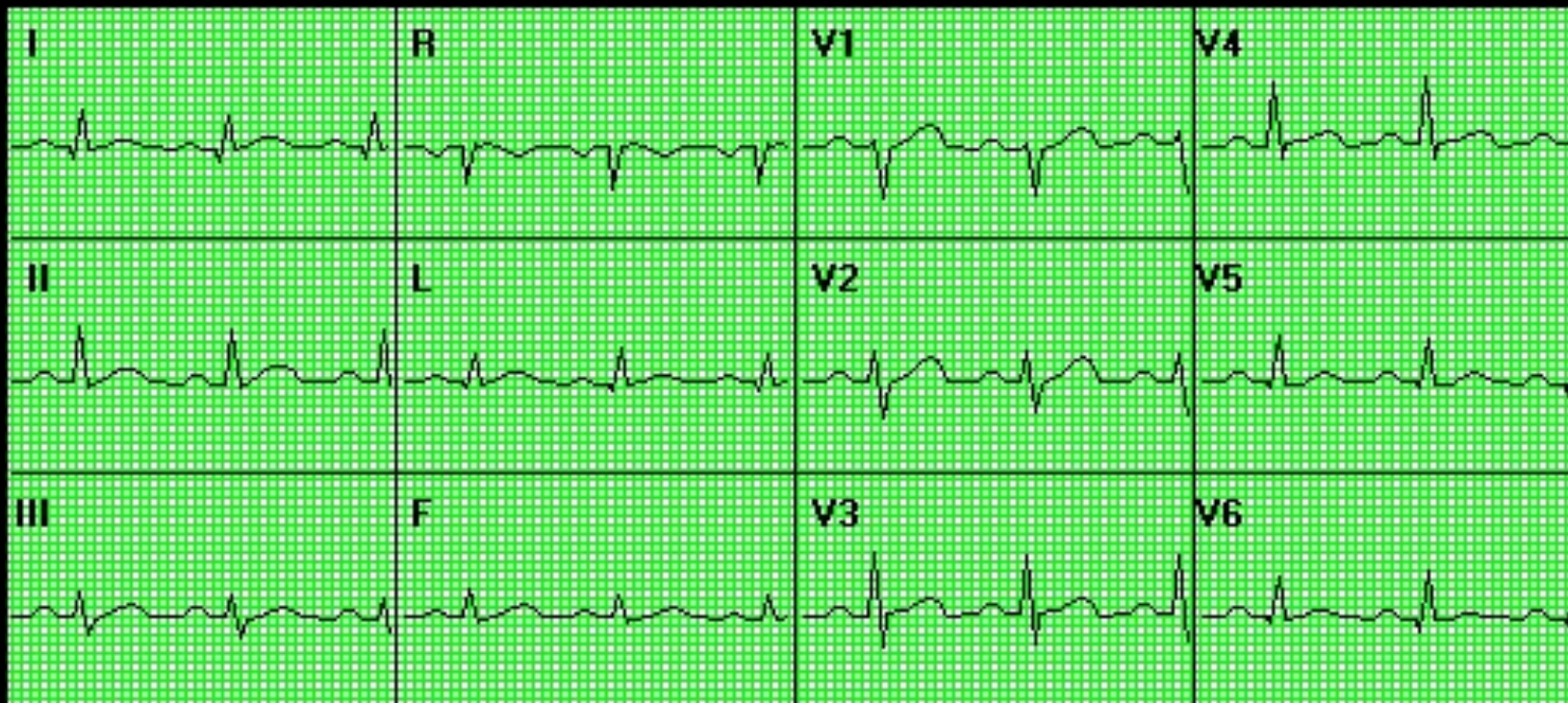


Normal vs. Abnormal Q-waves



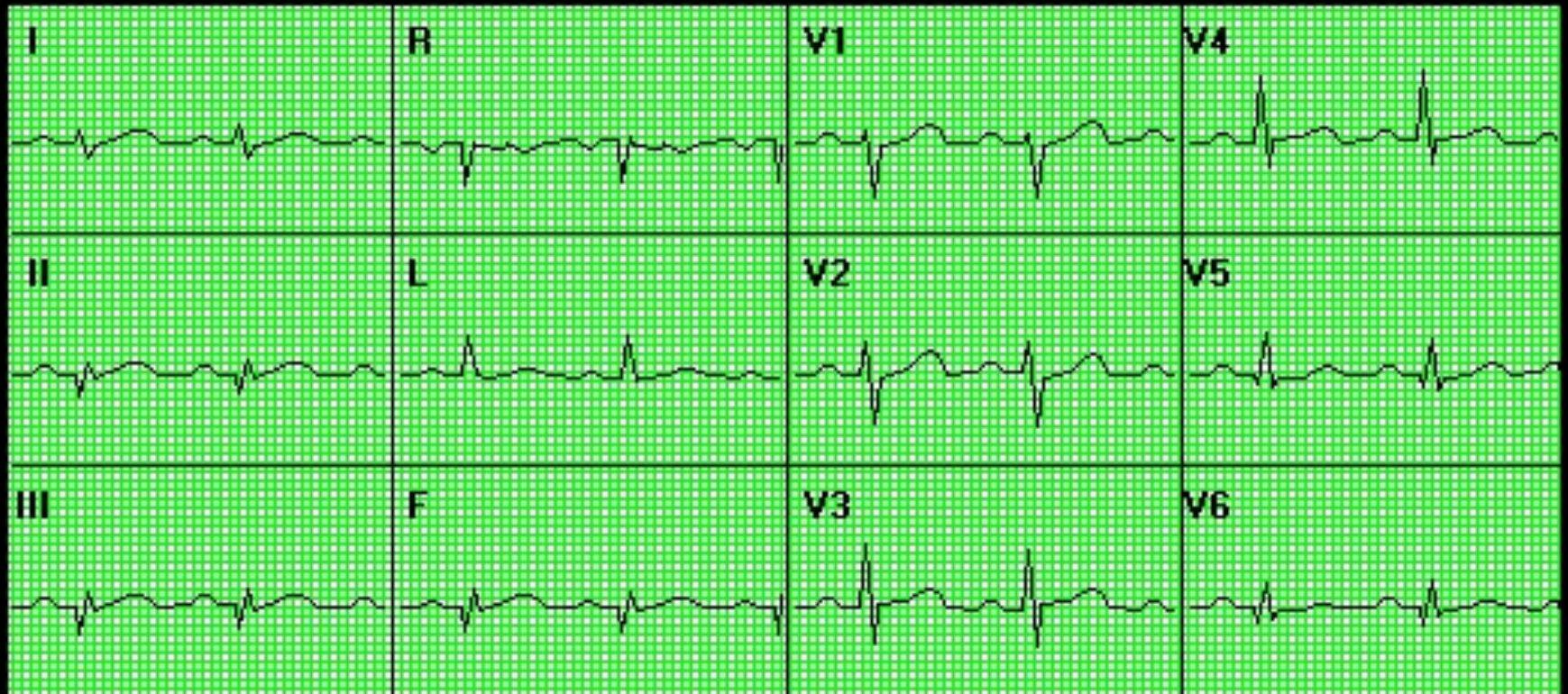


EKG showing normal Qs in I, AVL, V5 and V6

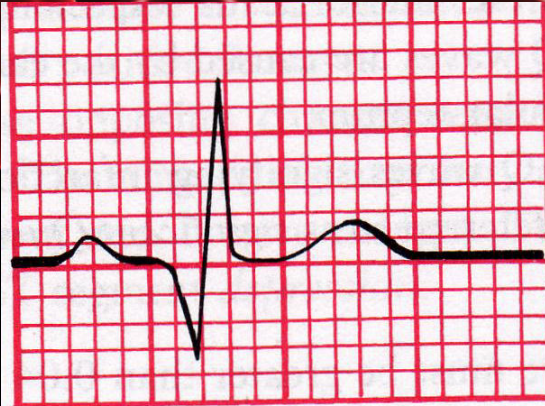




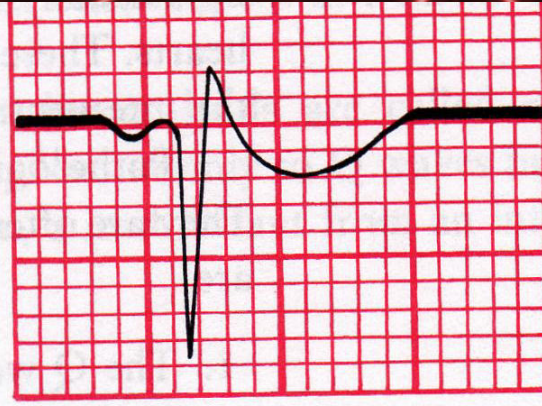
Q waves of old infarction in II, III, and AVF



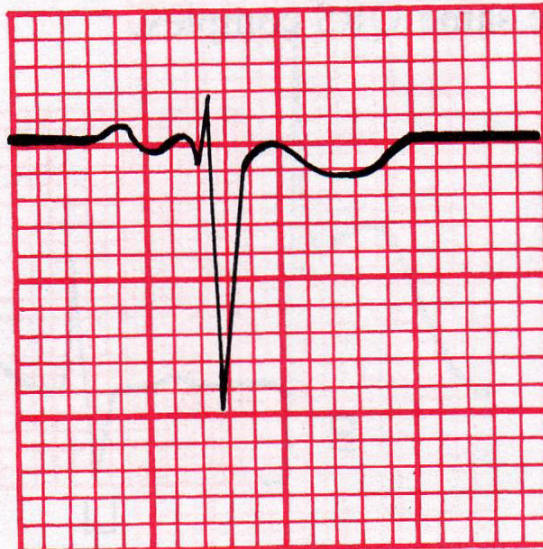
Significant or Not?



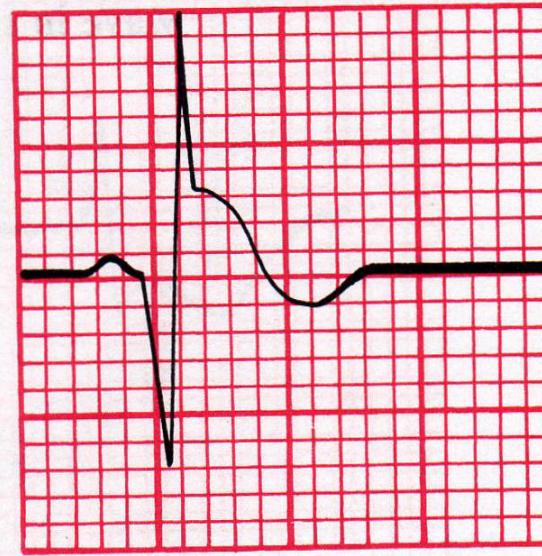
I



AVR

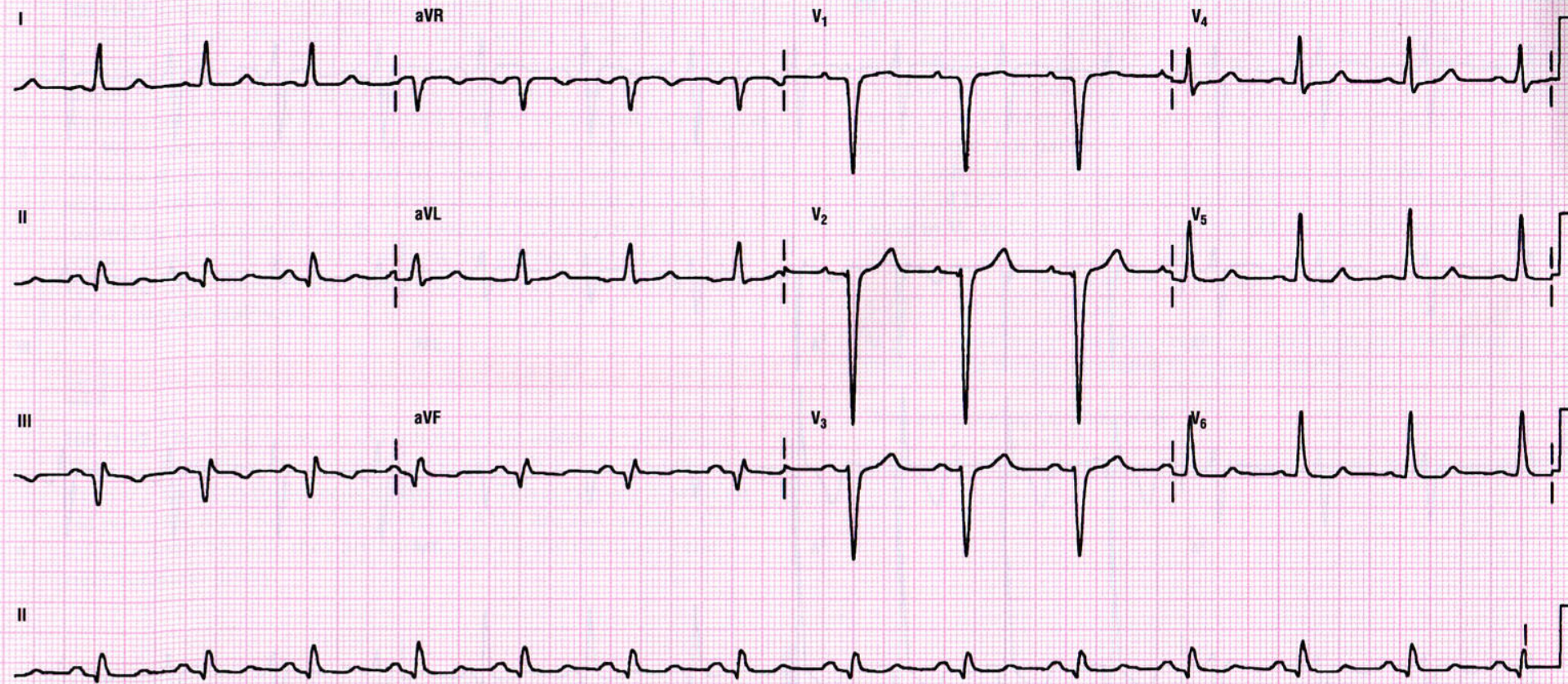


V₂

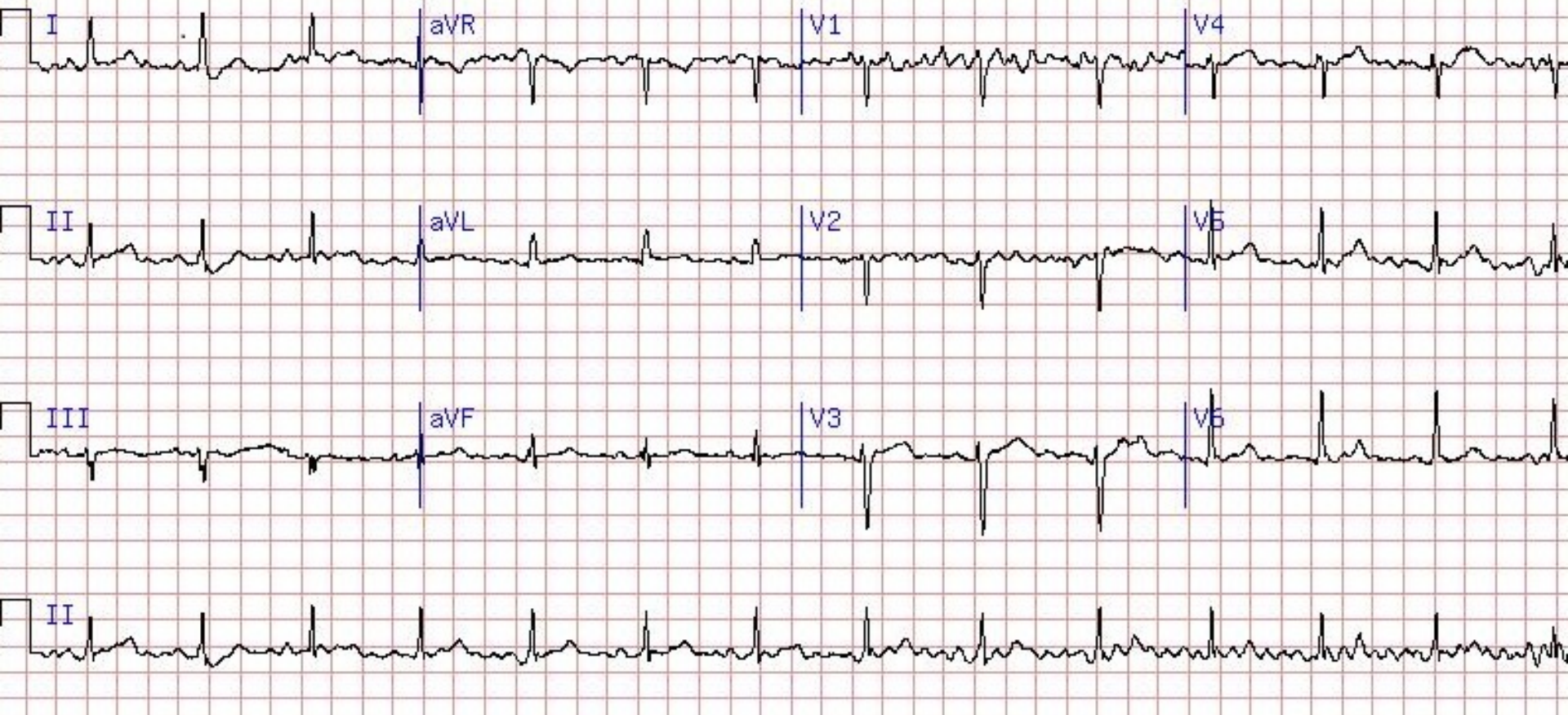


AVF

Any Significant Q's?



Yes in leads III & AVF only



Rate Variable Rhythm Regular? NO

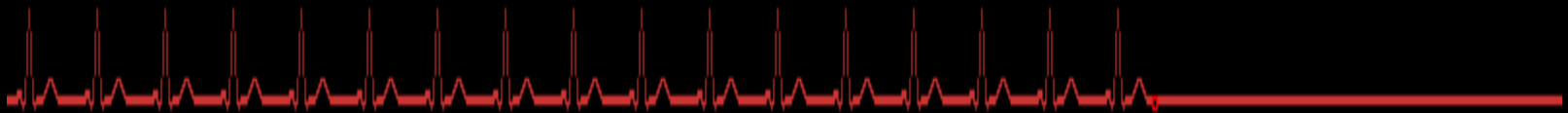P-Waves Upright? Indiscernible Significant Q-Waves? No

Any ectopic beats? No

Rhythm Diagnosis is A-Fib

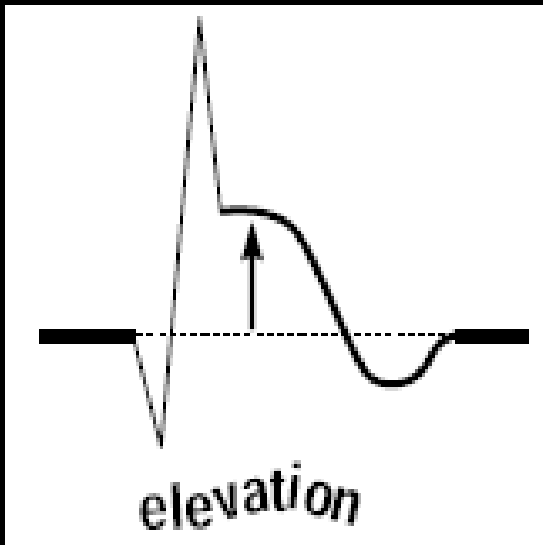


ST - Elevation

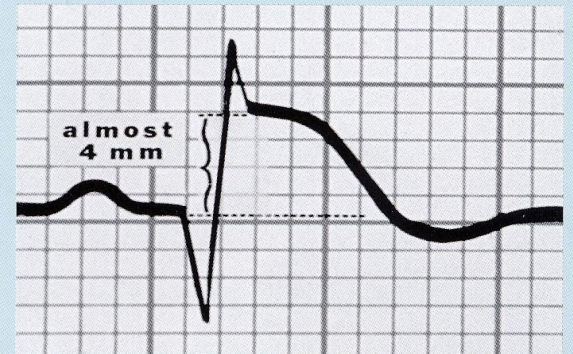


ST Elevation

- Signifies an acute process, ST segment returns to baseline with time.
- ST elevation associated with significant Q waves indicates an acute (or recent) infarct.

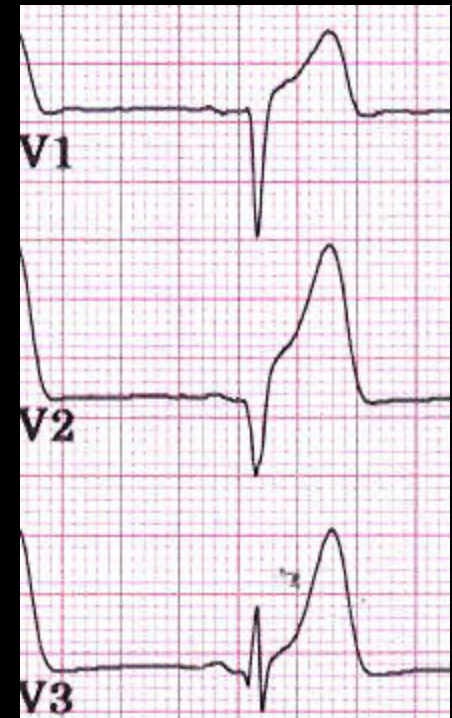
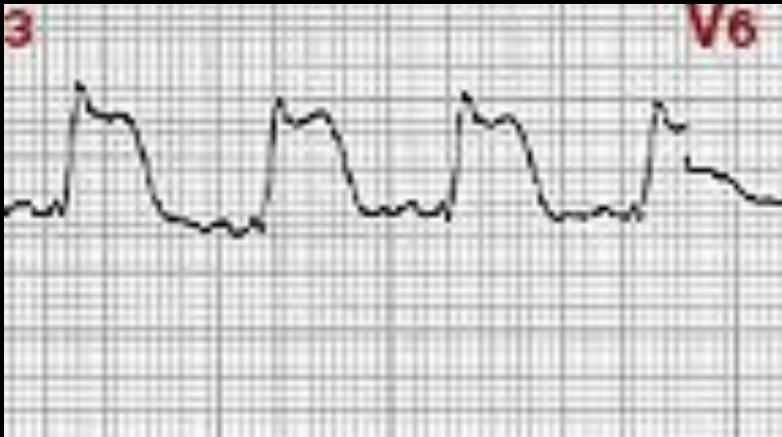
ST Elevation

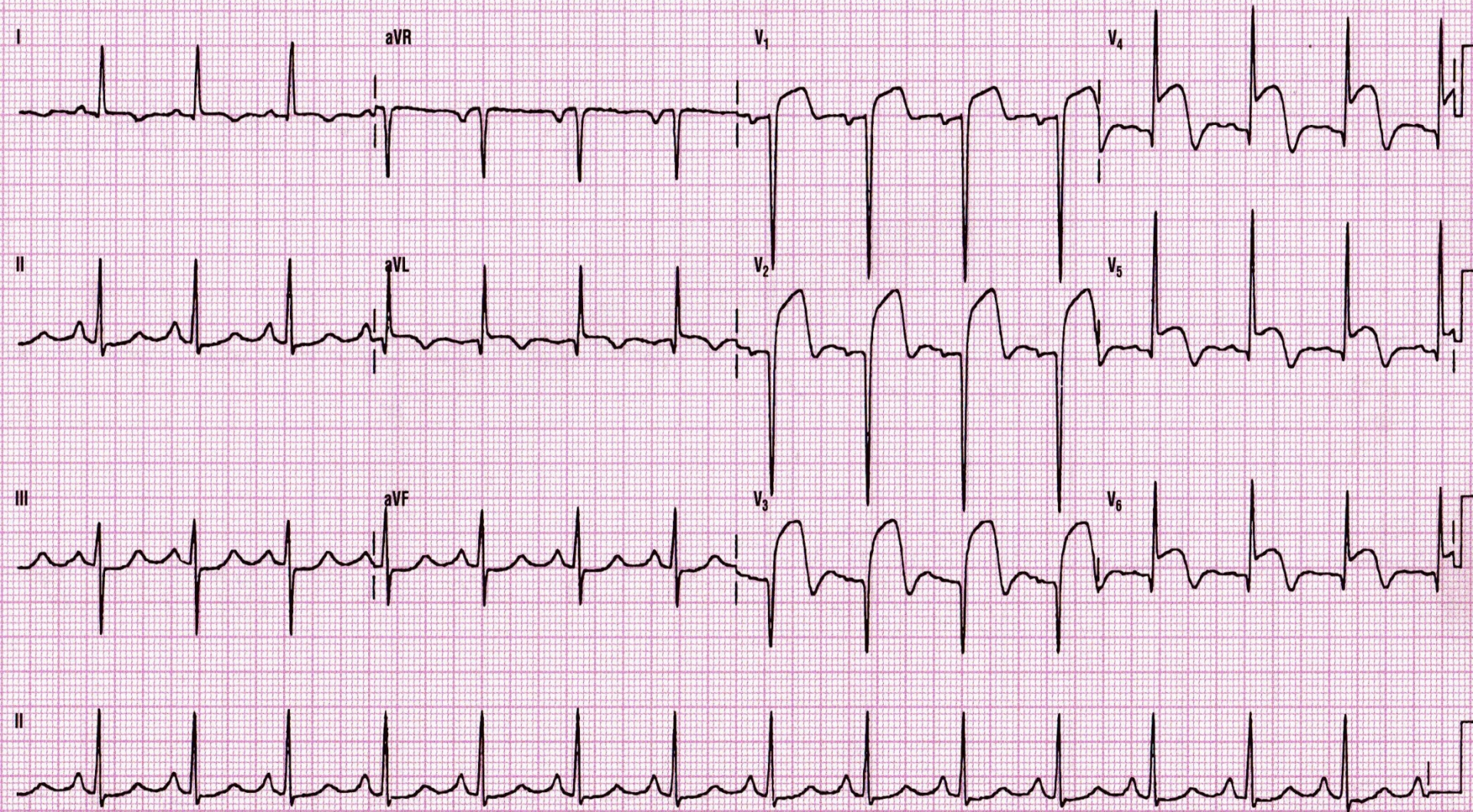


Causes of ST Elevation

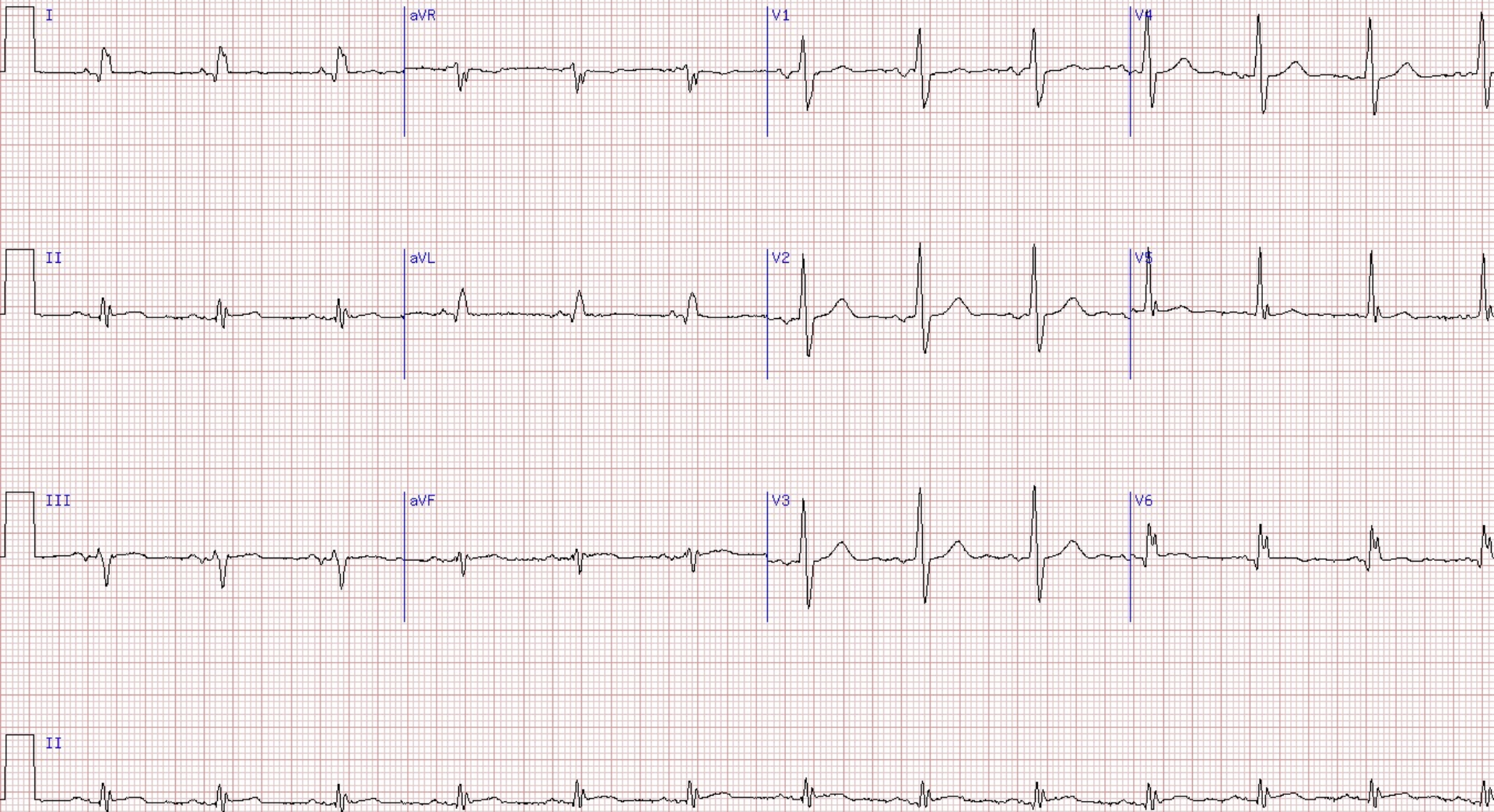
- Infarction
- Vasospastic angina
- Pericarditis
- Early repolarization



Is this ST Elevation?

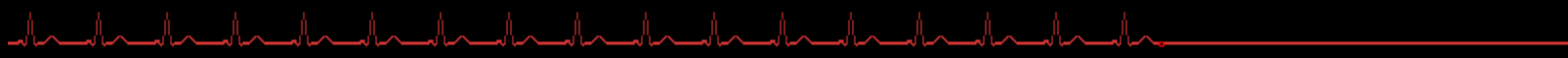

What about this?





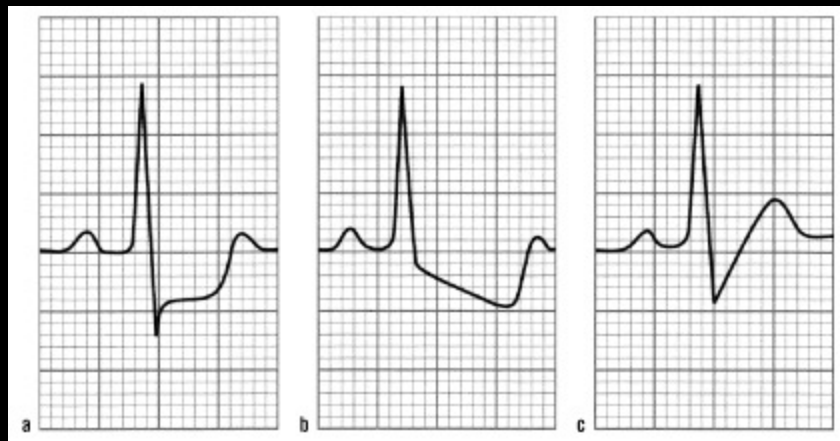
ST Depression





ST Depression Significance

- ST segment depression is considered significant if the ST segment is at least two boxes below baseline.
- With infarction, the location of the ischemia is reflected in the leads in which the ST depression occurs.

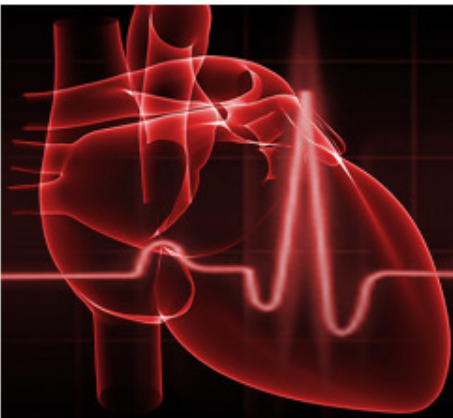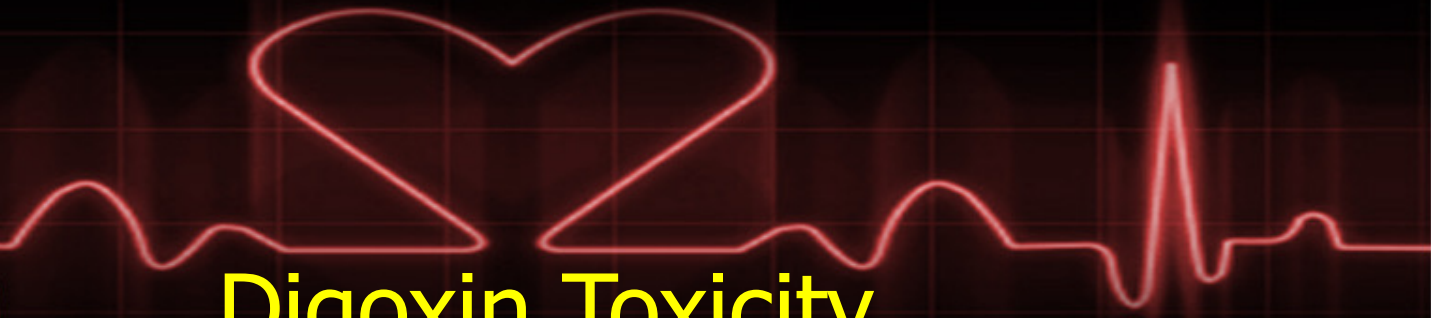




Common Causes of ST Segment Depression

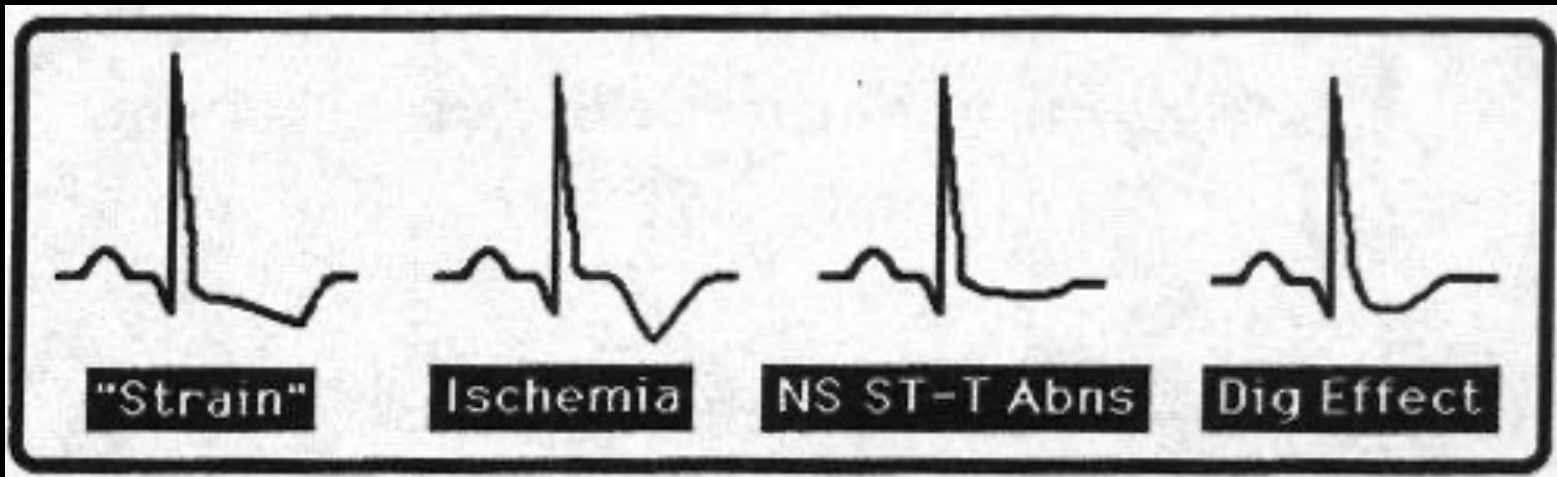
- Ischemia
- "Strain" in LVH
- Digitalis effect
- Bundle branch block
- Hypokalemia/Hypomagnesemia
- Reciprocal ST elevation
- Any combination of the above



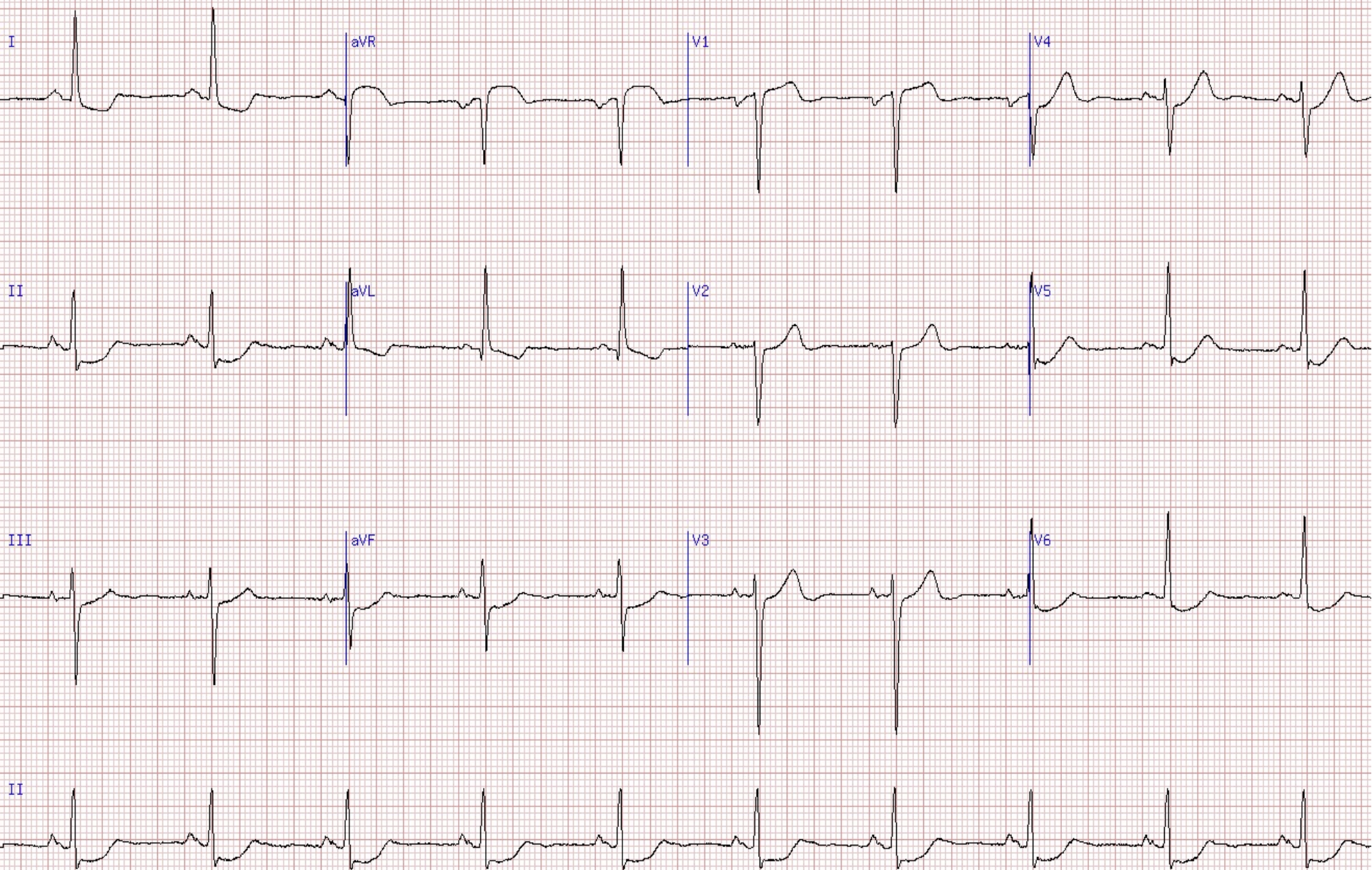


Digoxin Toxicity

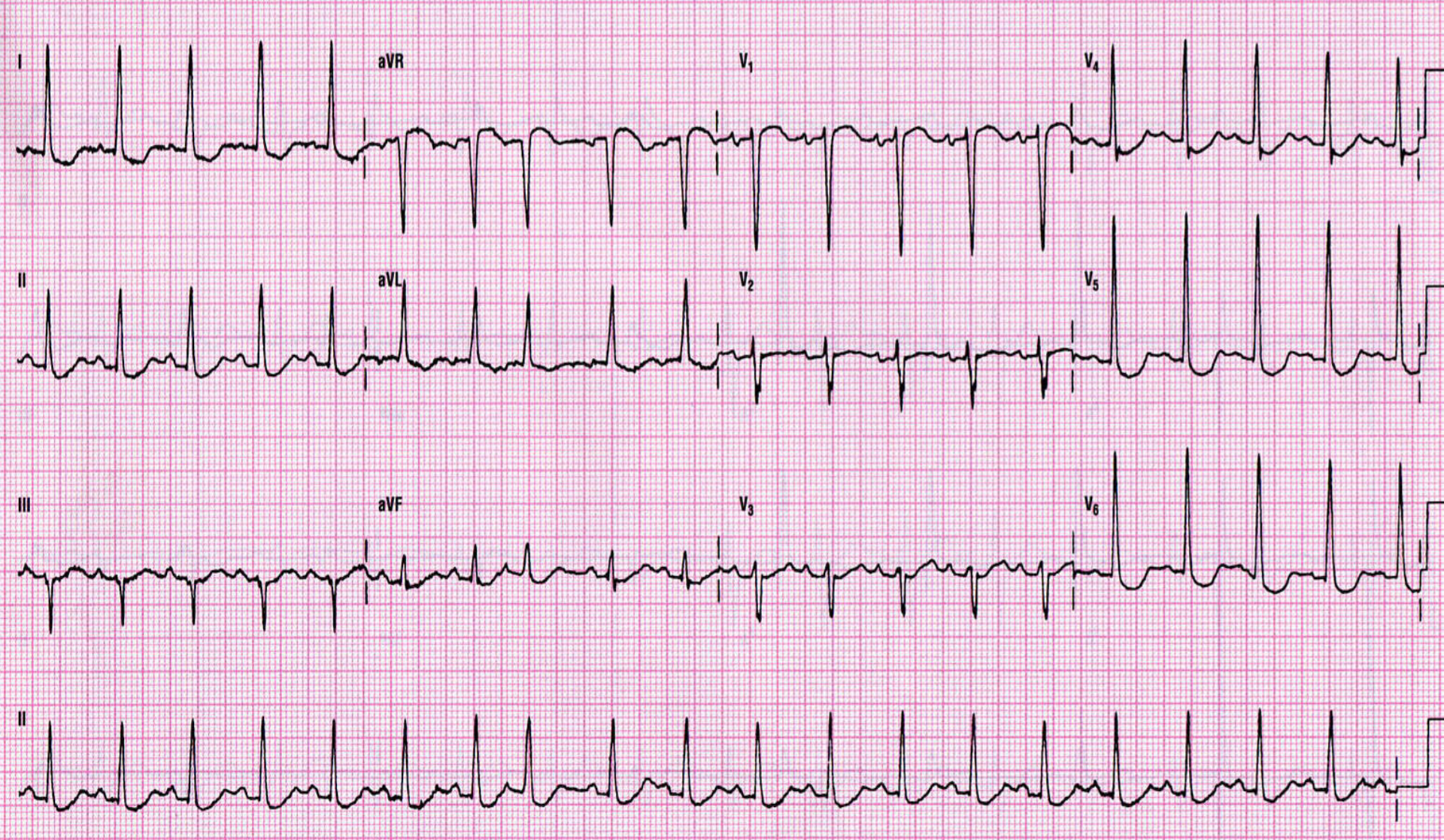
- Digoxin ("**Dig effect**") may produce either ST "scooping" or a "strain"-like pattern or no change at all.
- Can be seen in levels greater than 2.5mg/ml



Where's the Depression?



Dig Toxicity





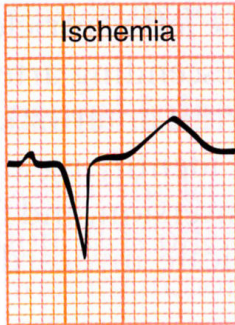What is “Electrical Reciprocity”?

- Electrical Reciprocity is like a mirror image. On the EKG, this means that ST elevations in one group will show up as ST depressions in another.
- When you see this, it is not considered ischemia.
- For example, a set of inferior ST elevations in II, III and AVF can produce lateral ST depressions in I, AVL, V5 and V6. You’d think that this would mean lateral ischemia, but no – it’s a reflection, bouncing electrically across the heart from the inferior injury, showing up in reverse.

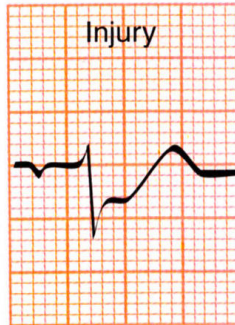
Reciprocal Changes

Reciprocal changes

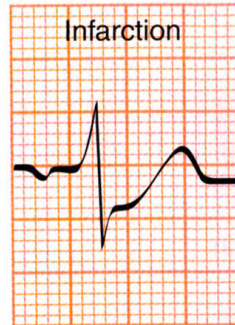
Ischemia



Injury

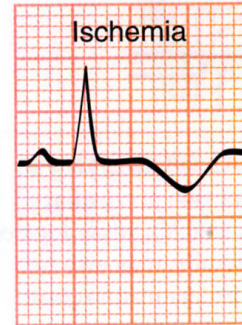

Infarction

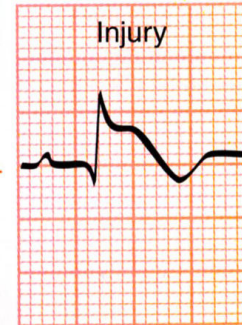

Changes on affected side of heart

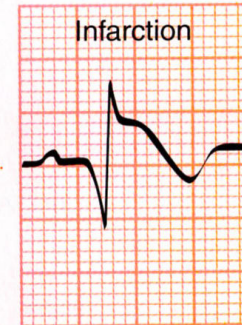Ischemia



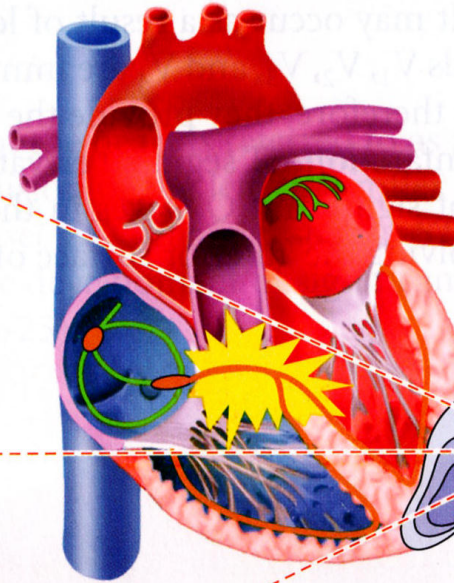
Injury



Infarction

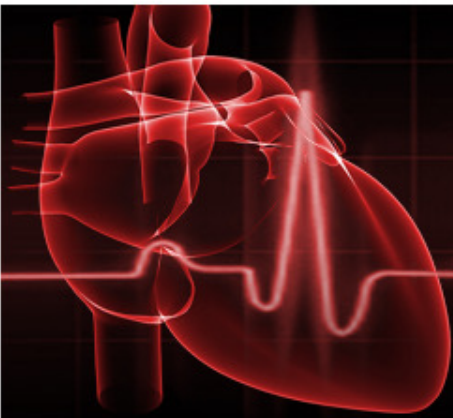


ECG lead



ECG lead

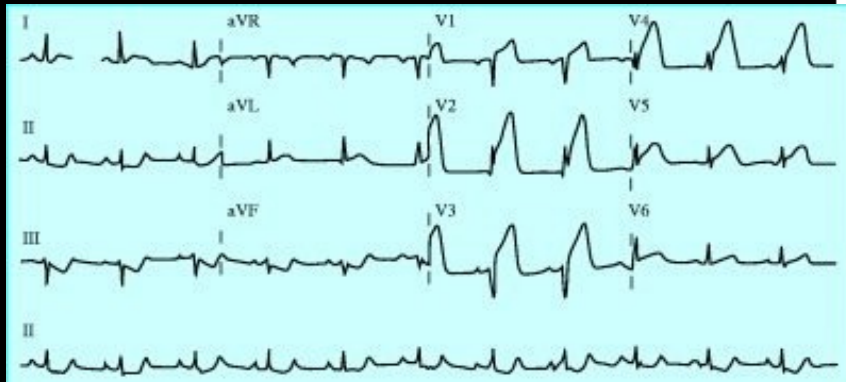




T Wave Categories

- Tall, peaked = hyperkalemia if generalized
infarction if localized
- Inverted = evolving infarction
chronic pericarditis
conduction block
ventricular hypertrophy
acute cerebral disease
other cardiac disease
- Flattened = nonspecific

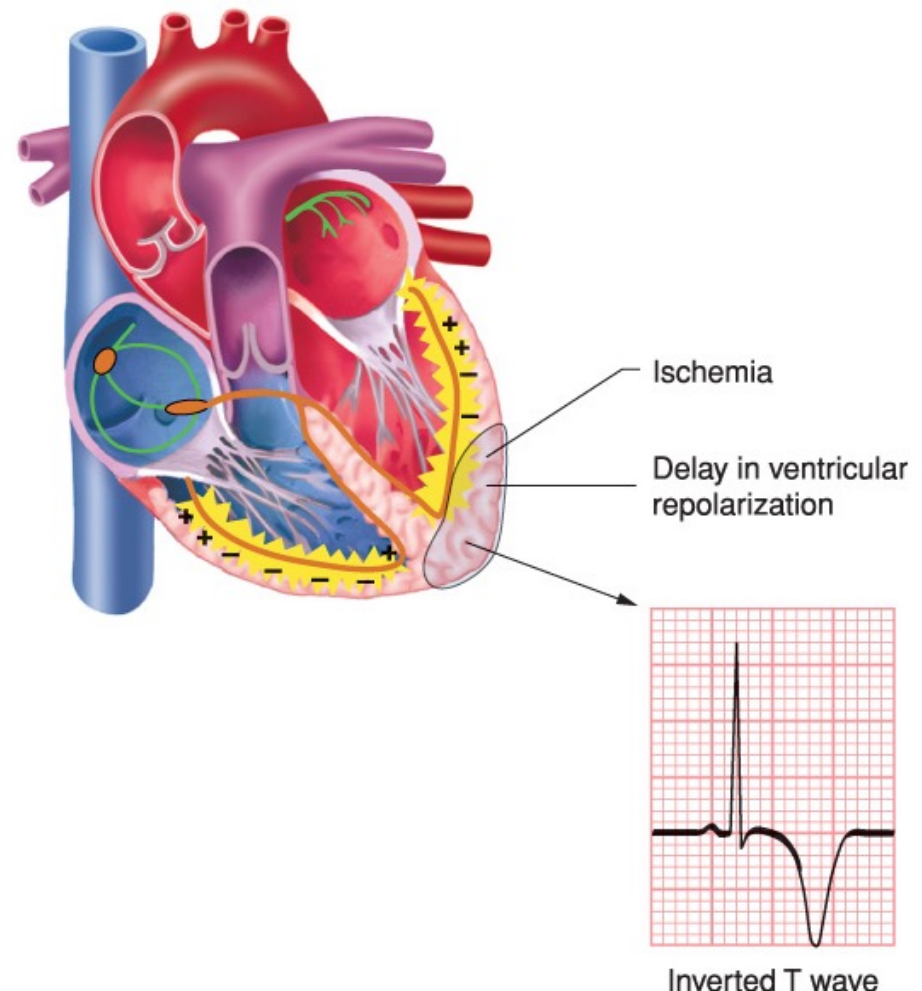
Hyperacute
T-wave



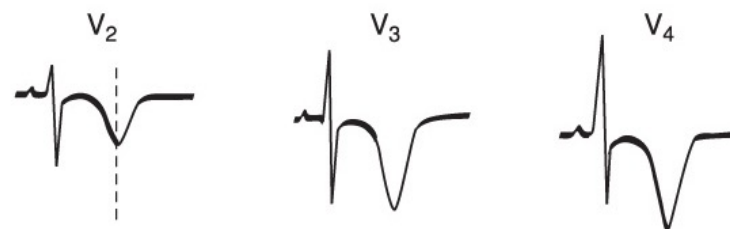
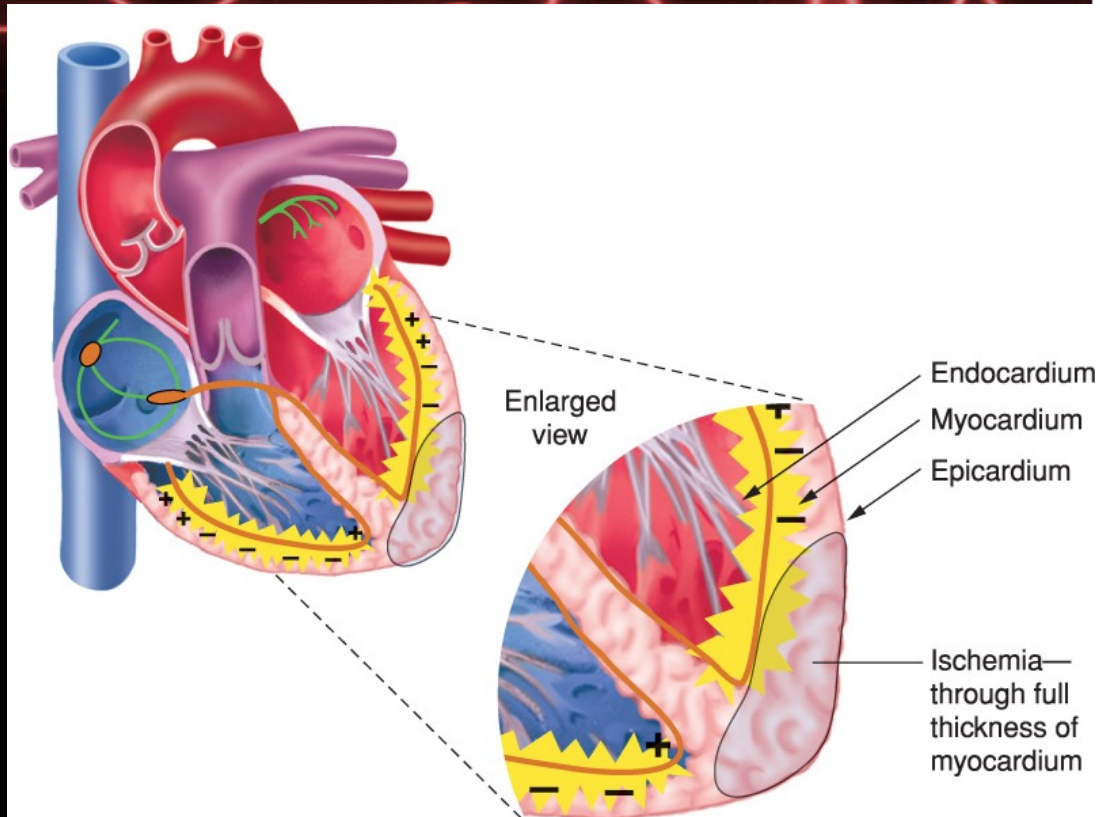


T Wave Inversion

- Occurs because ischemic tissue does not repolarize normally



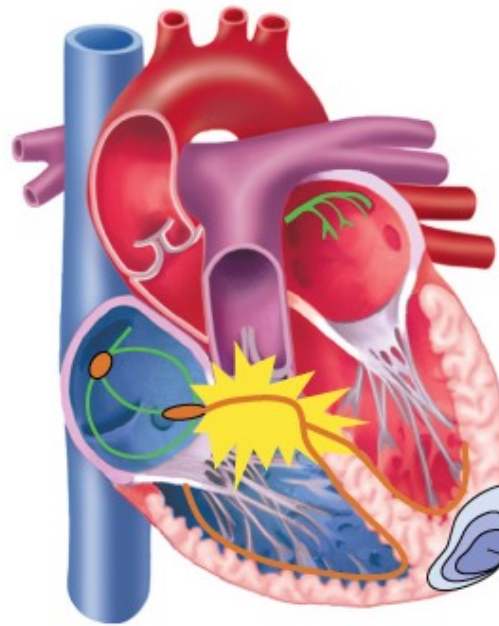
T Wave Inversion



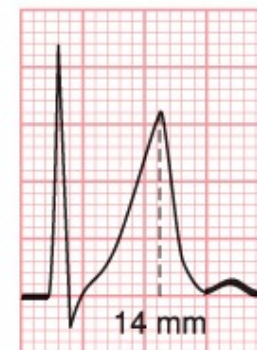T wave is symmetrical — meaning the right and left sides of the waveform are the same size

Peaked T Waves

- May be seen in early stages of acute myocardial infarction
- Within a short time (two hours) T waves invert



Infarction



T wave is more than 6 mm high in limb leads and 12 mm in precordial leads

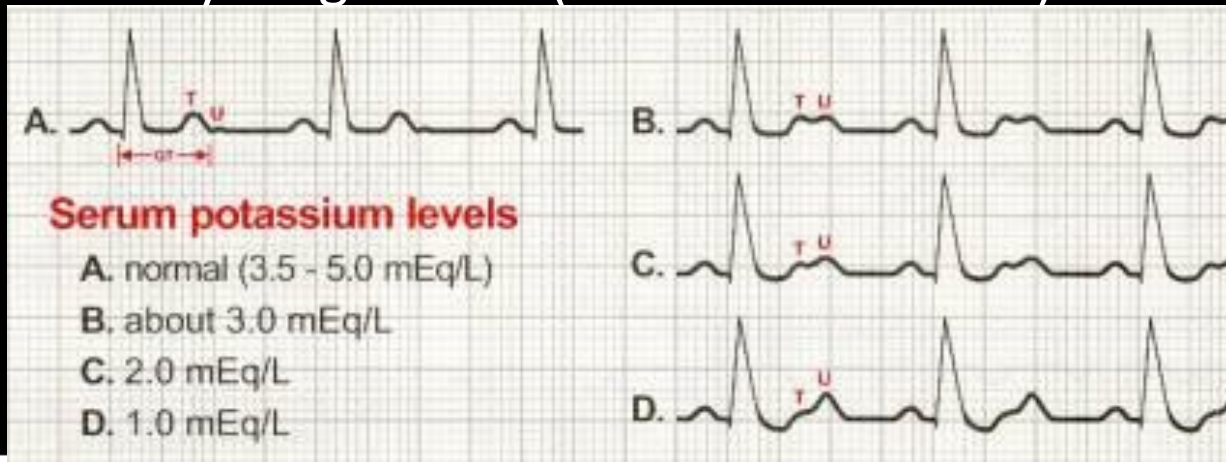or

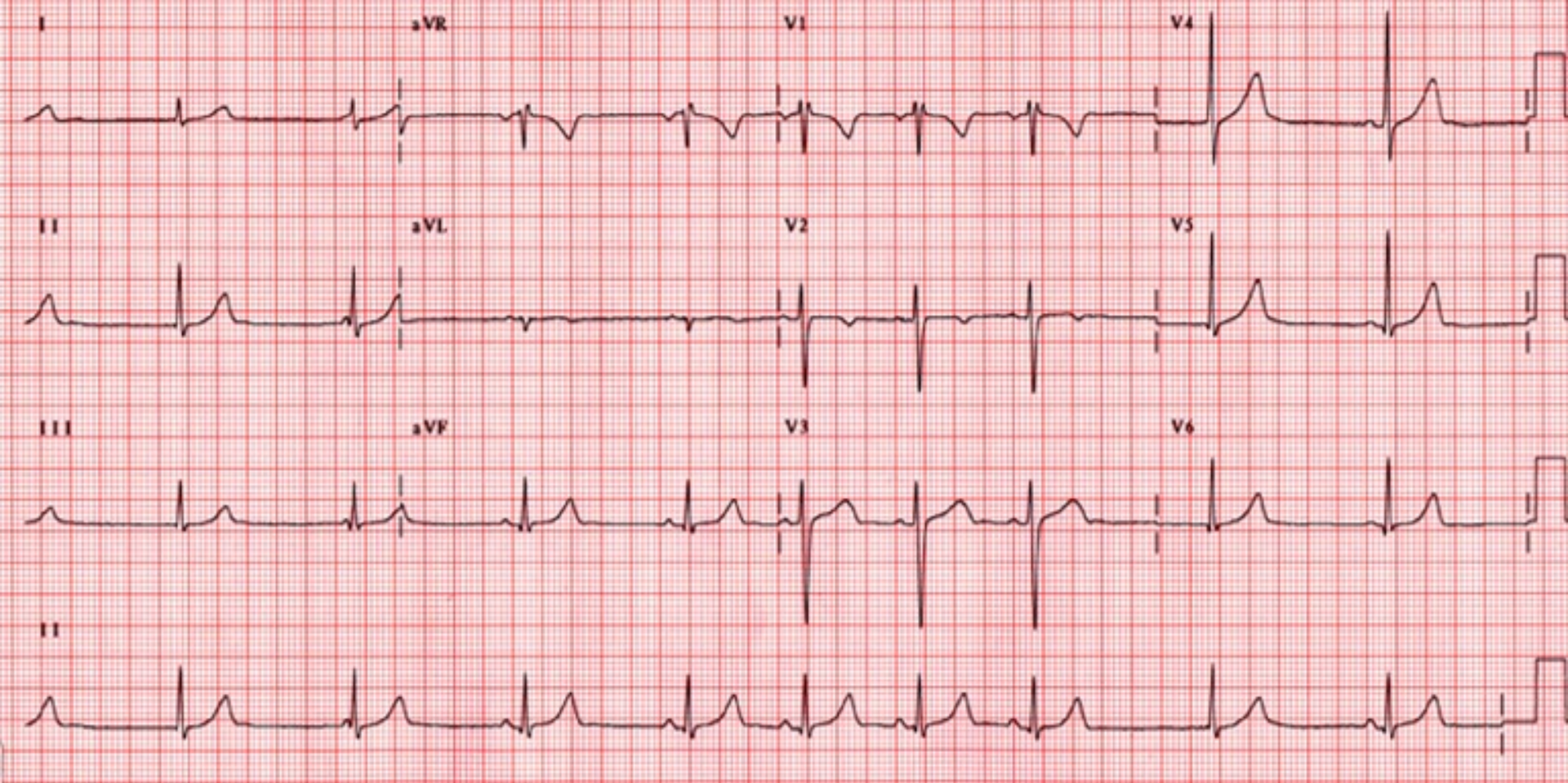
T wave is more than two-thirds the height of the R wave



Flattened T-Waves

- Flat T waves can be seen in many conditions, including ischemia, evolving infarction, and electrolyte abnormality (such as hypokalemia).
- In acute cerebral disease, such as intracranial hemorrhage, elongated or bizarre T waves may be seen. These Ts are often biphasic or deeply and sharply inverted. The QT interval is often dramatically lengthened (0.5 to 0.7 seconds).





Rate Variable Rhythm Regular? No P-Waves Upright? Intermittantly

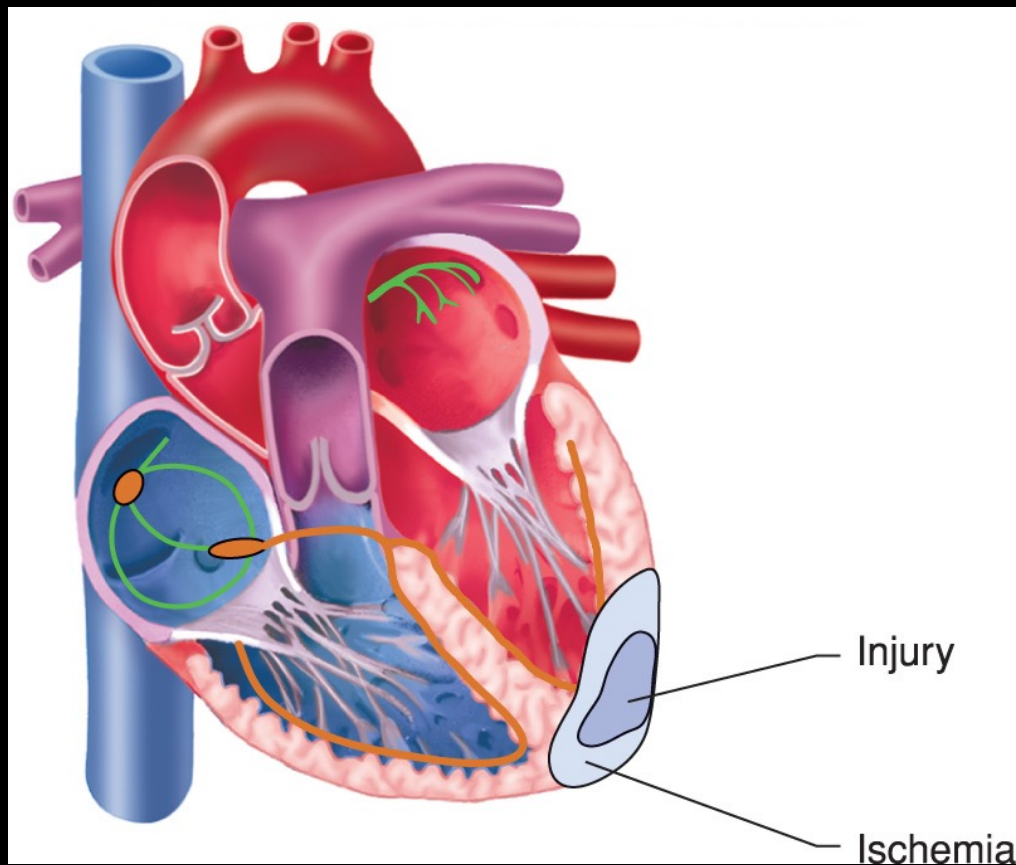
Significant Q-Waves? No Any ectopic beats? No

Rhythm Diagnosis is: Sinus Rhythm with Junctional Escape Rhythm Complexes



Myocardial Injury

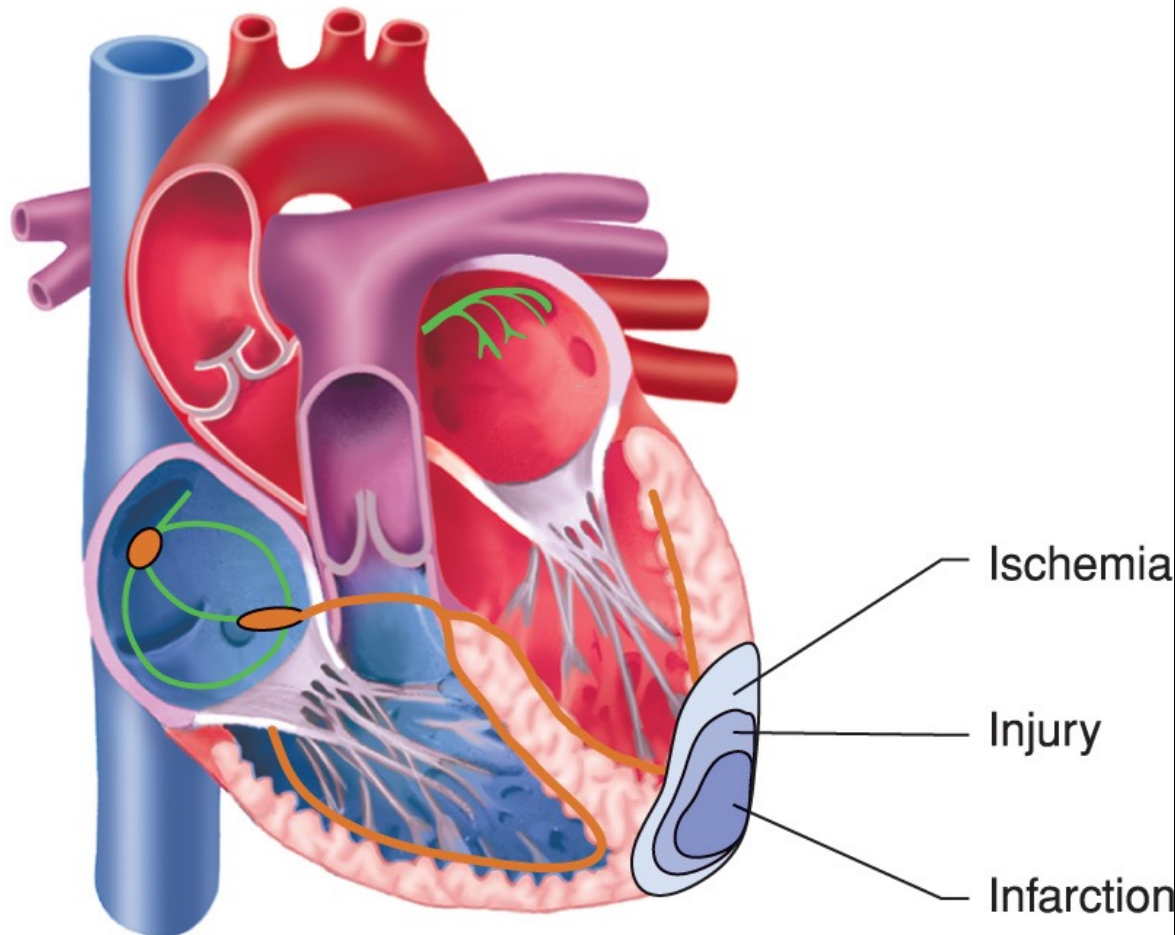
- Results if ischemia progresses unresolved or untreated





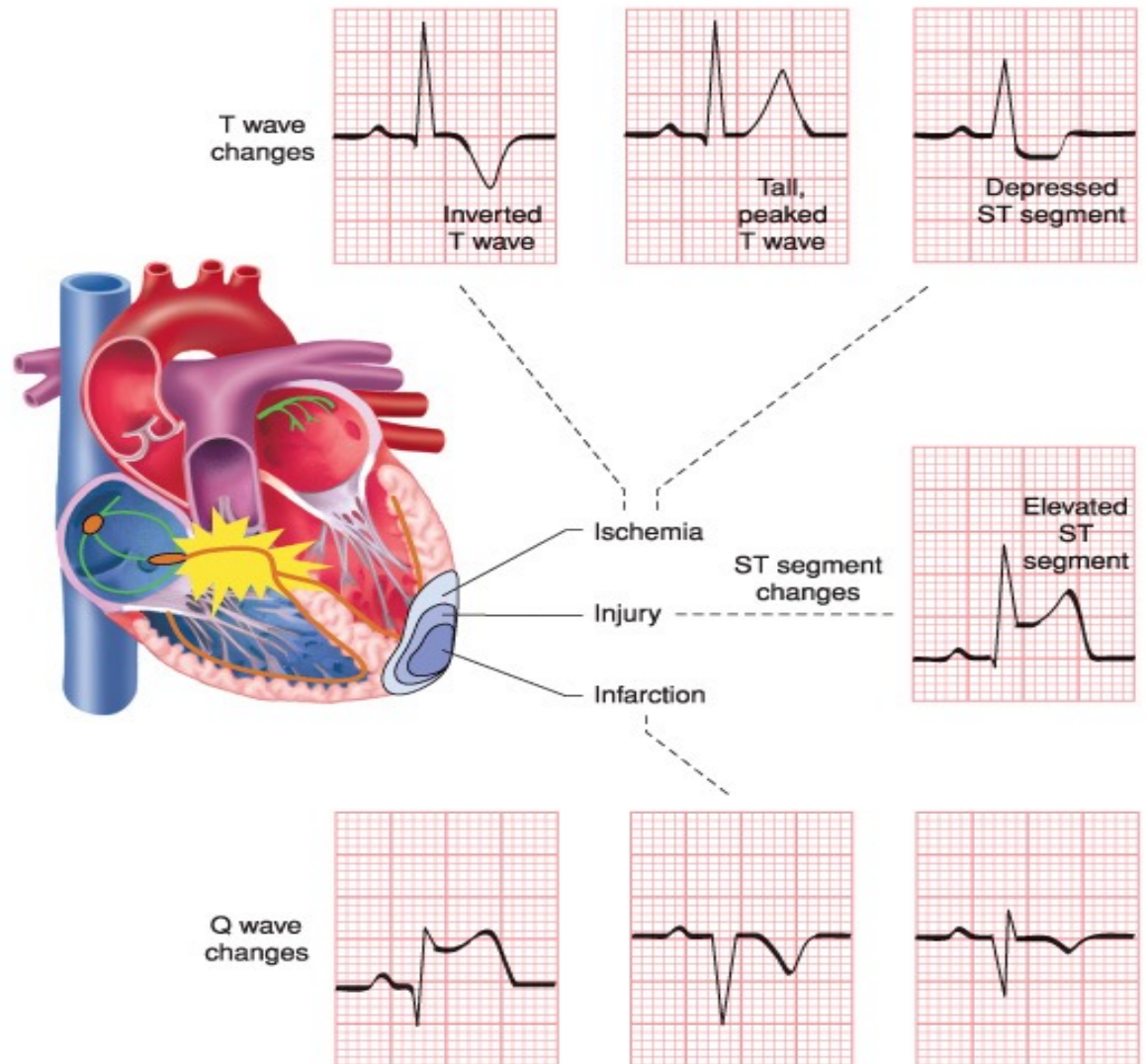
Myocardial Infarction

Death of
myocardial cells

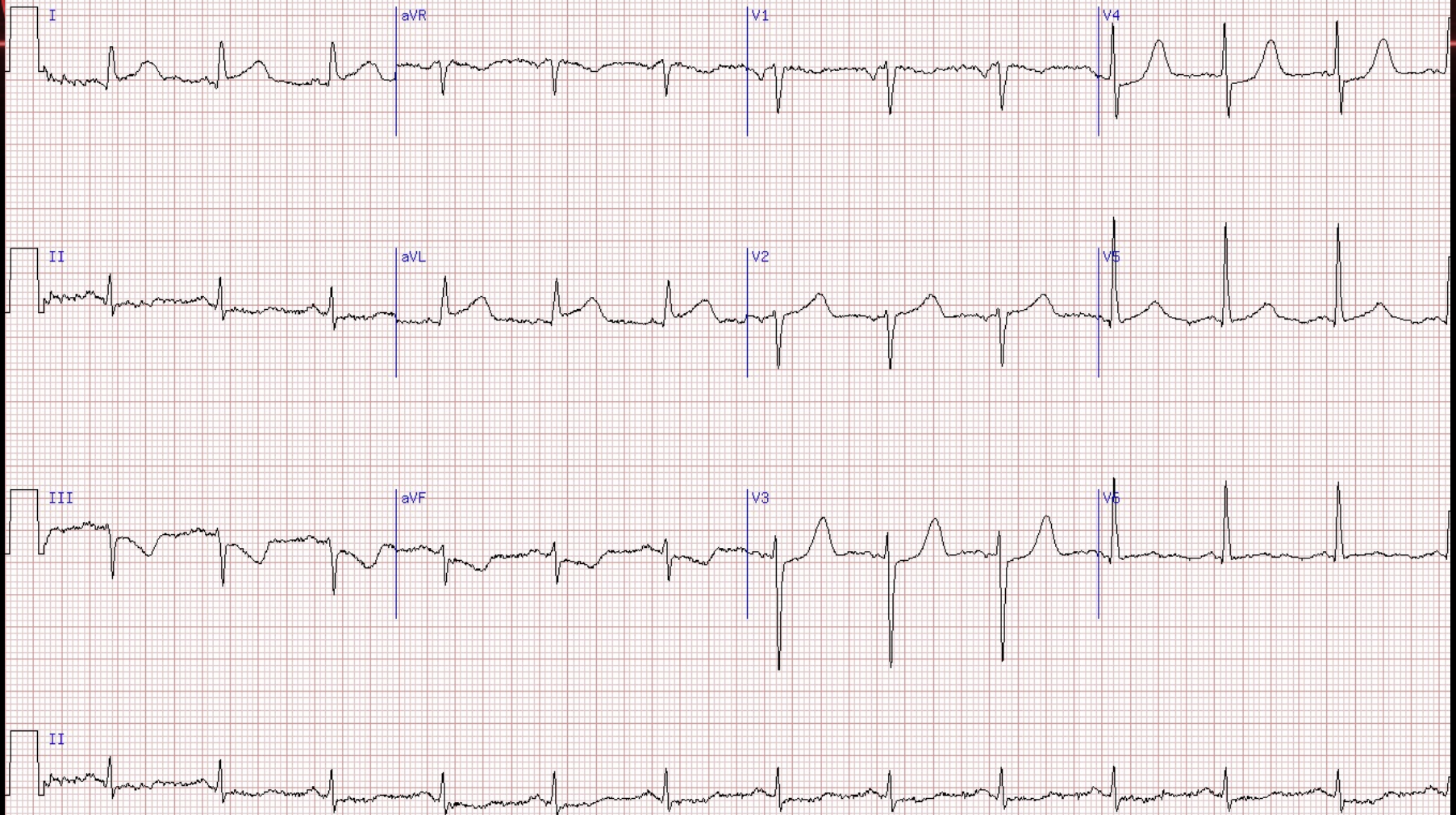




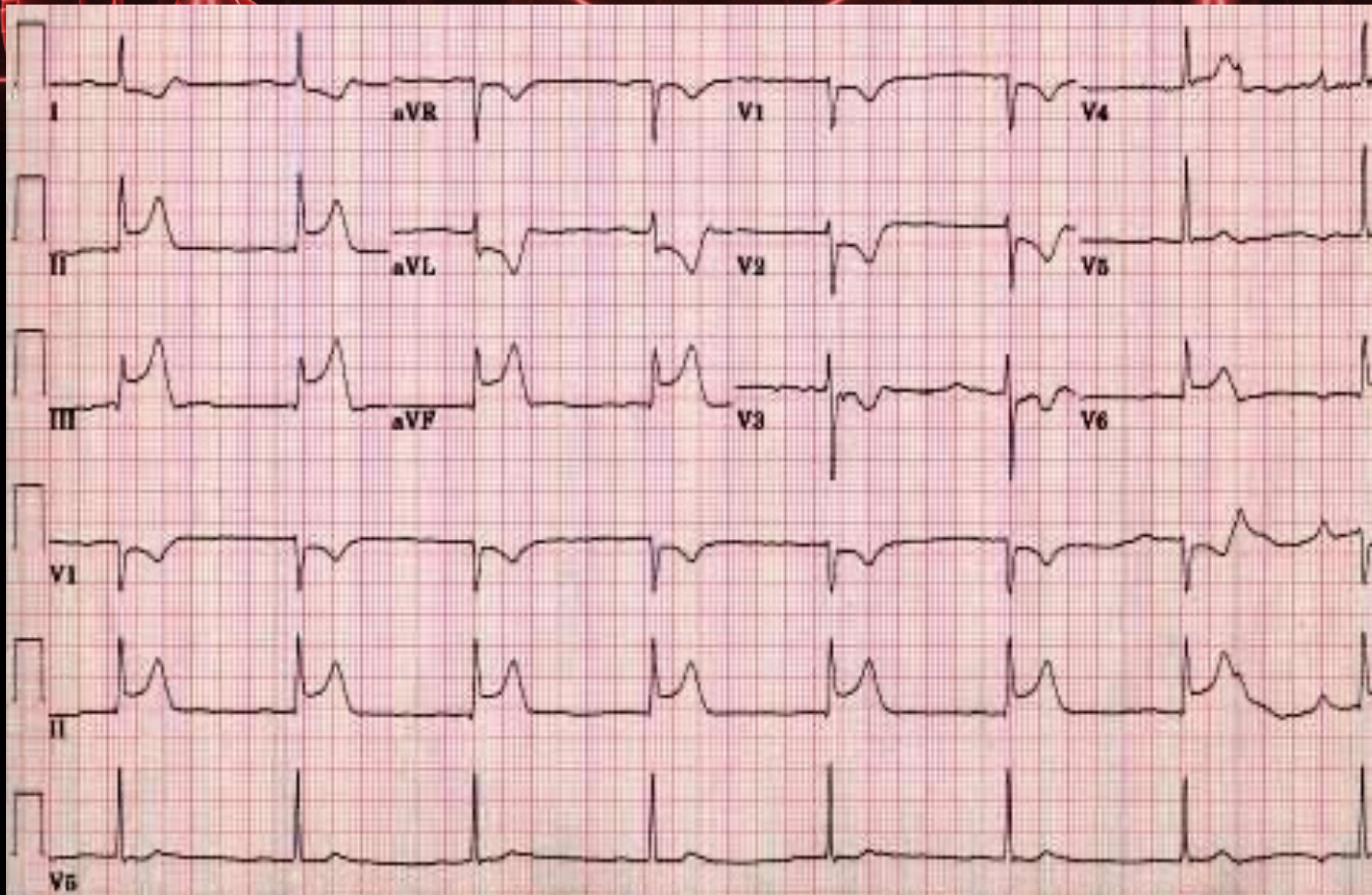
EKG Indicators



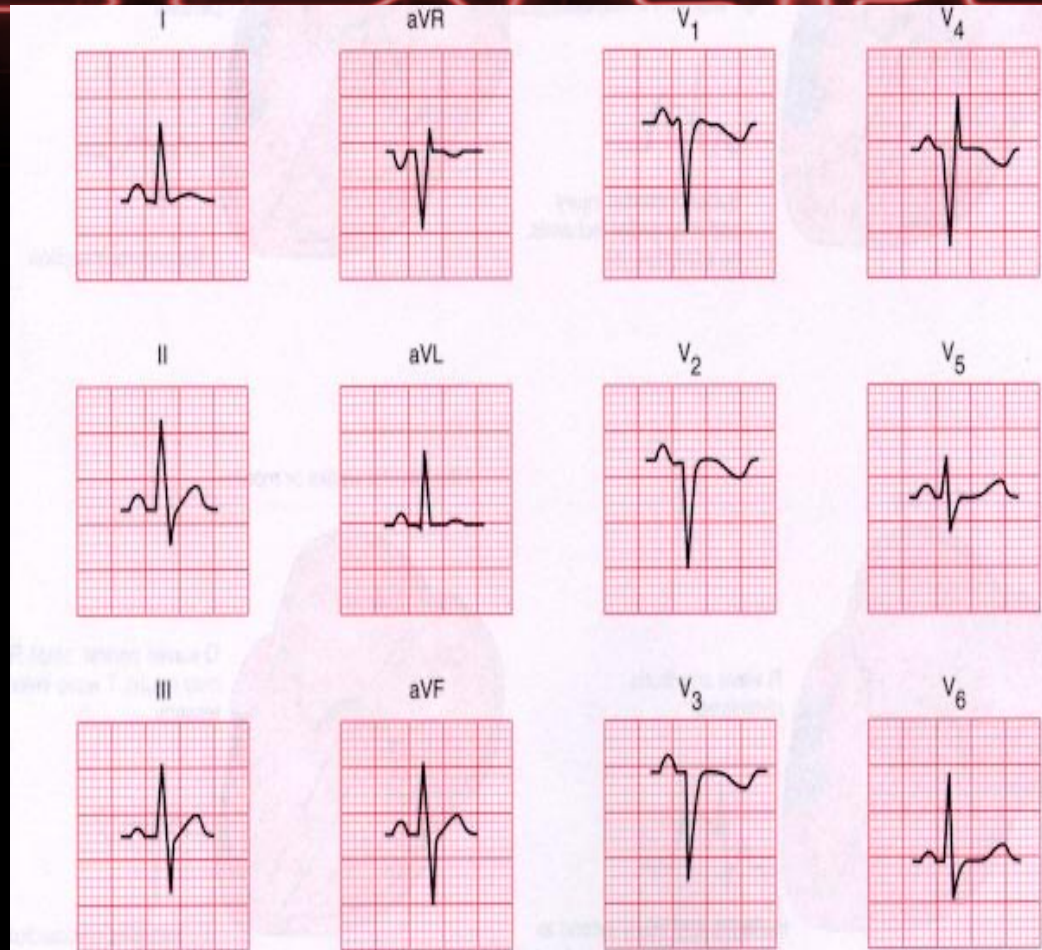
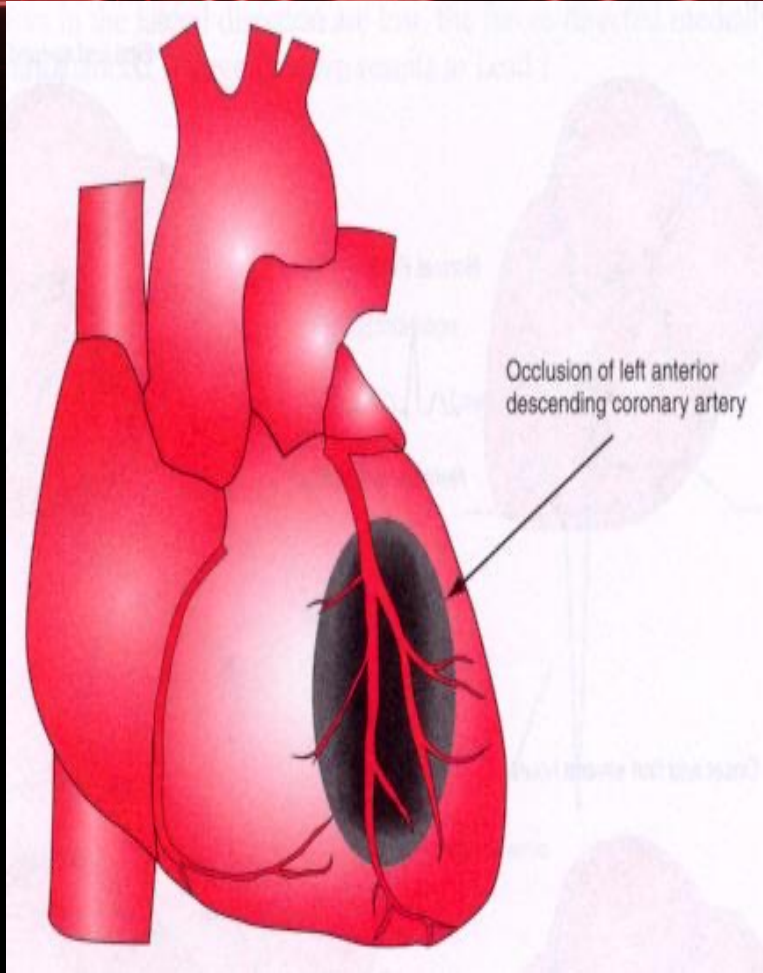
Lateral MI, Inferior Reciprocity



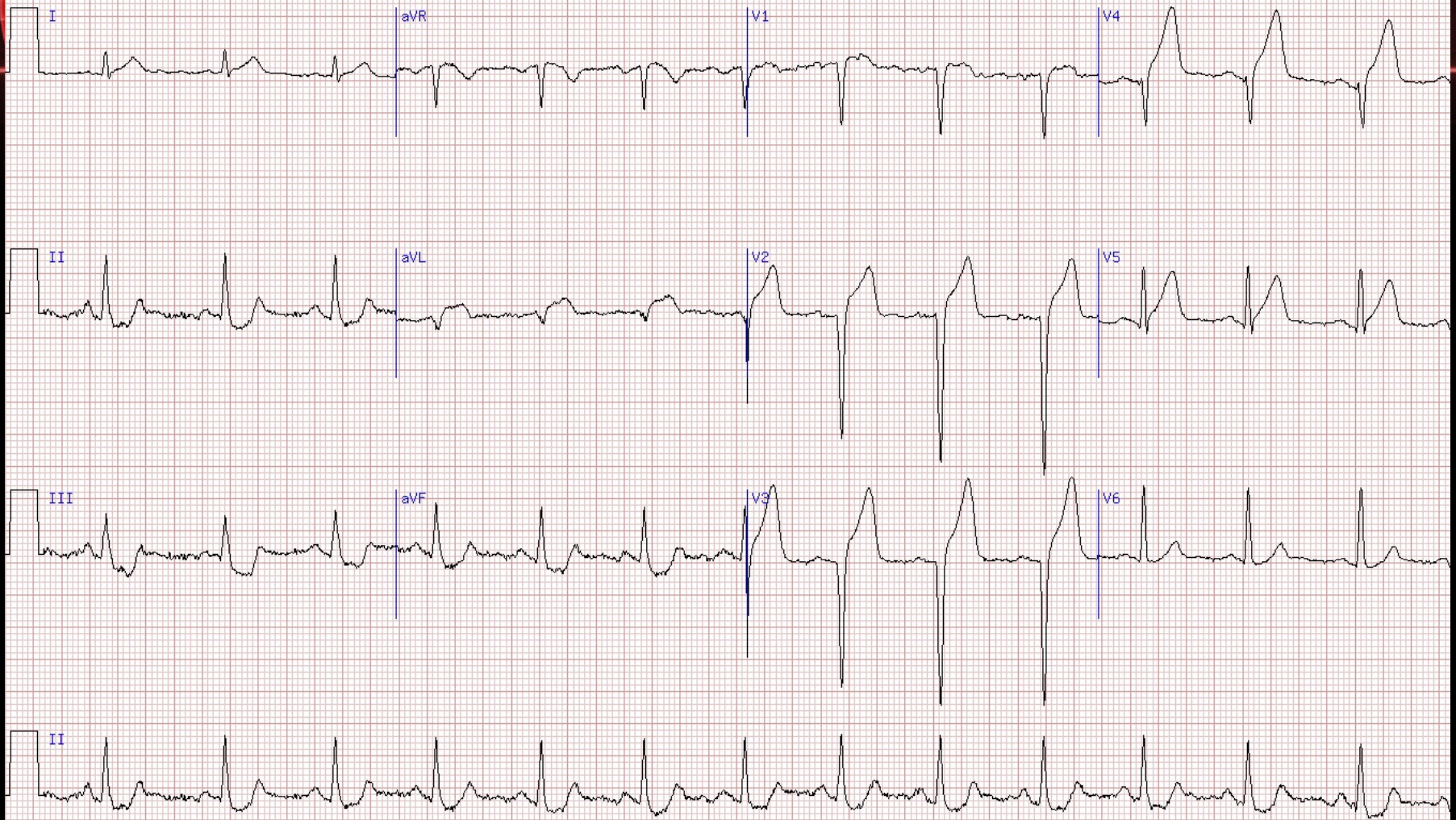
Inferior MI, Lateral Reciprocity



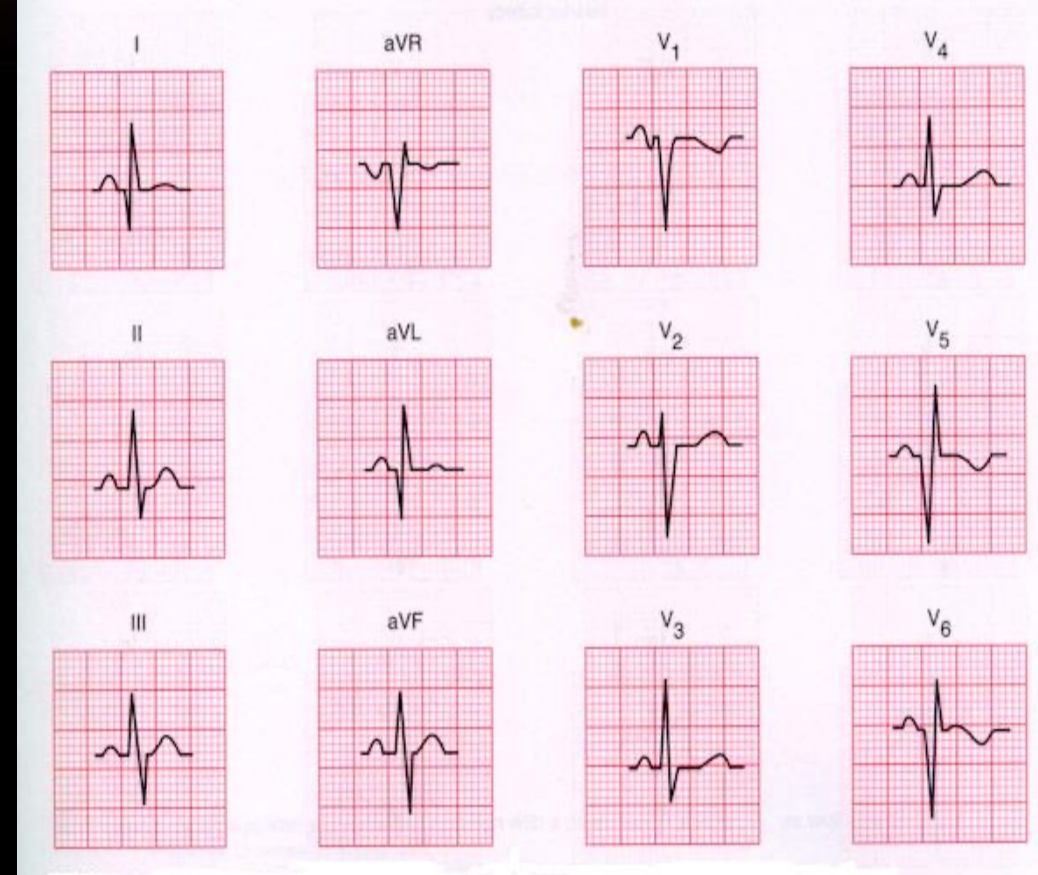
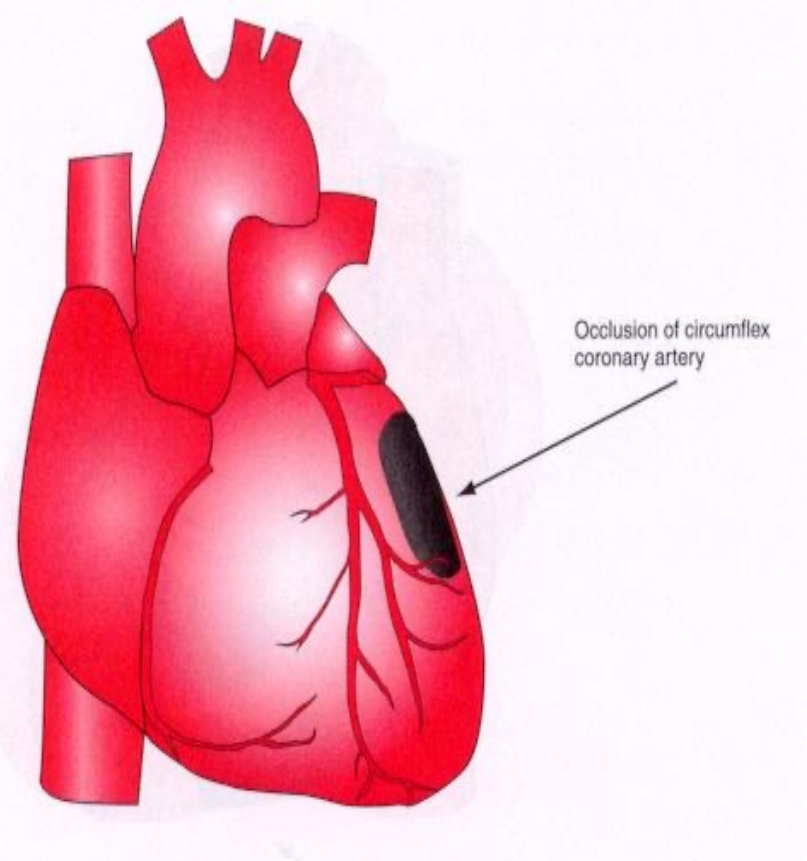
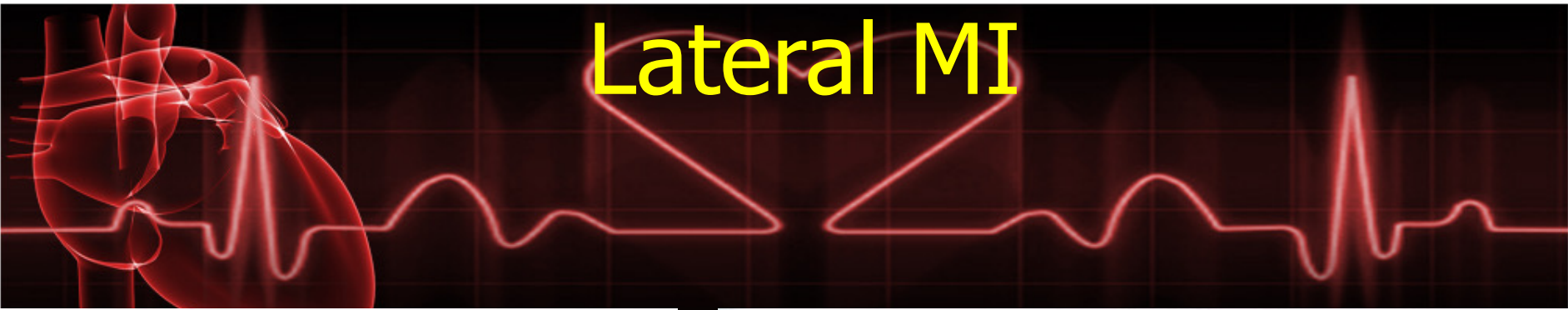
Anterior MI



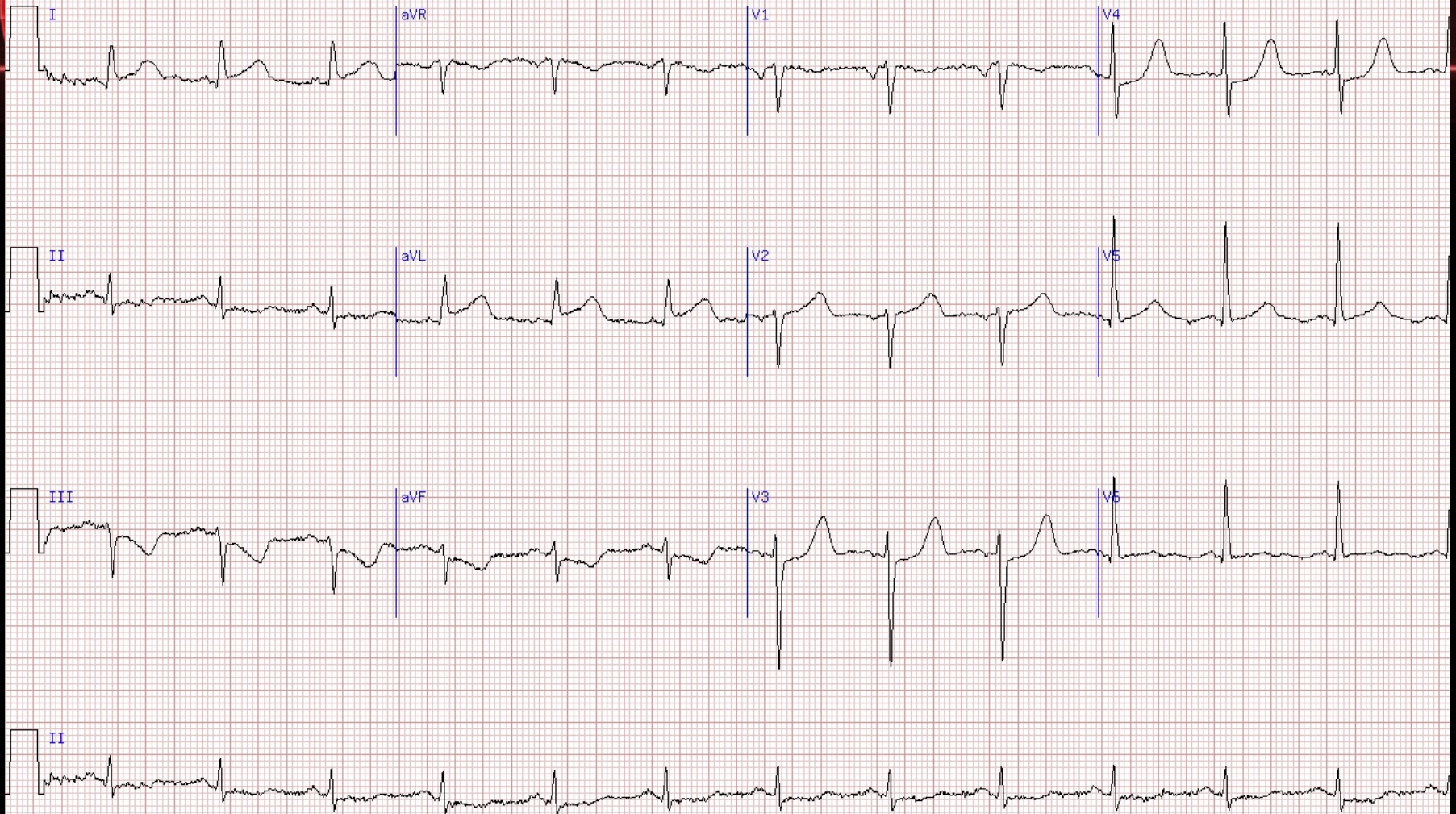
Anterior Wall MI



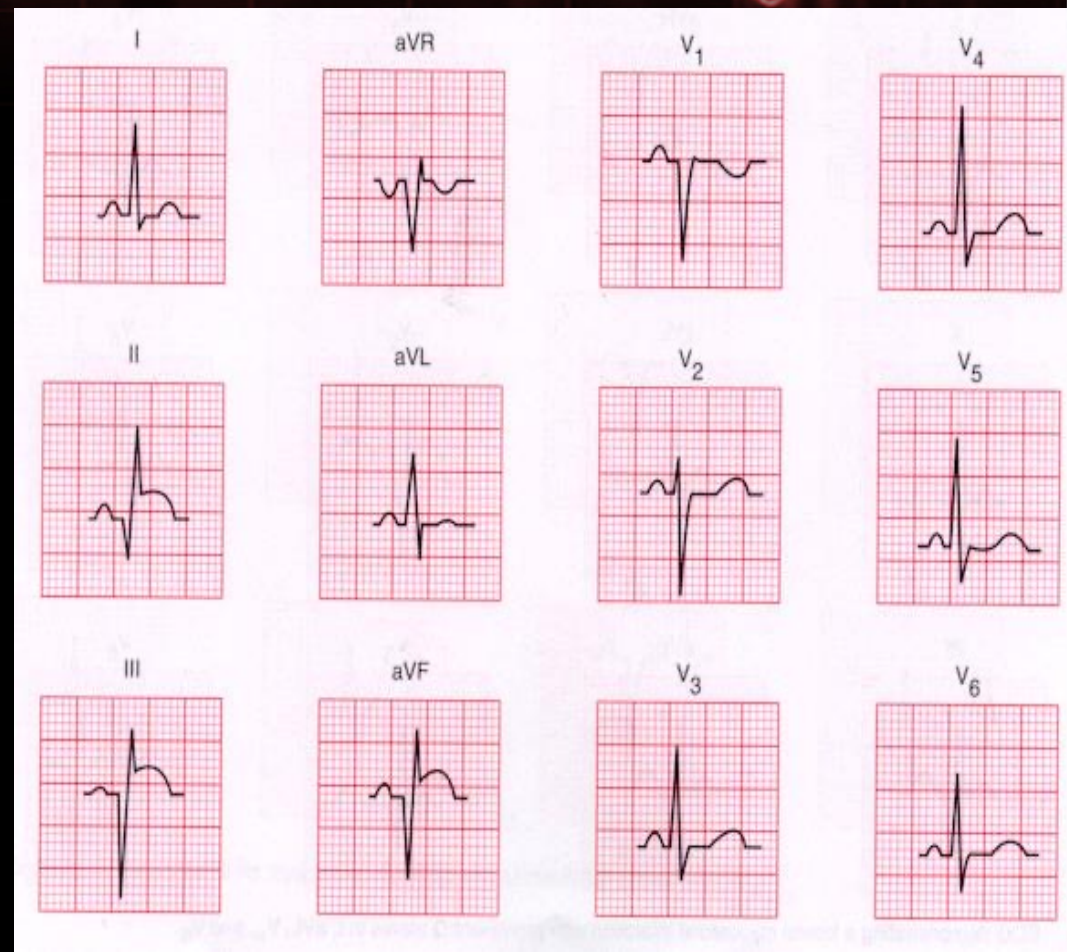
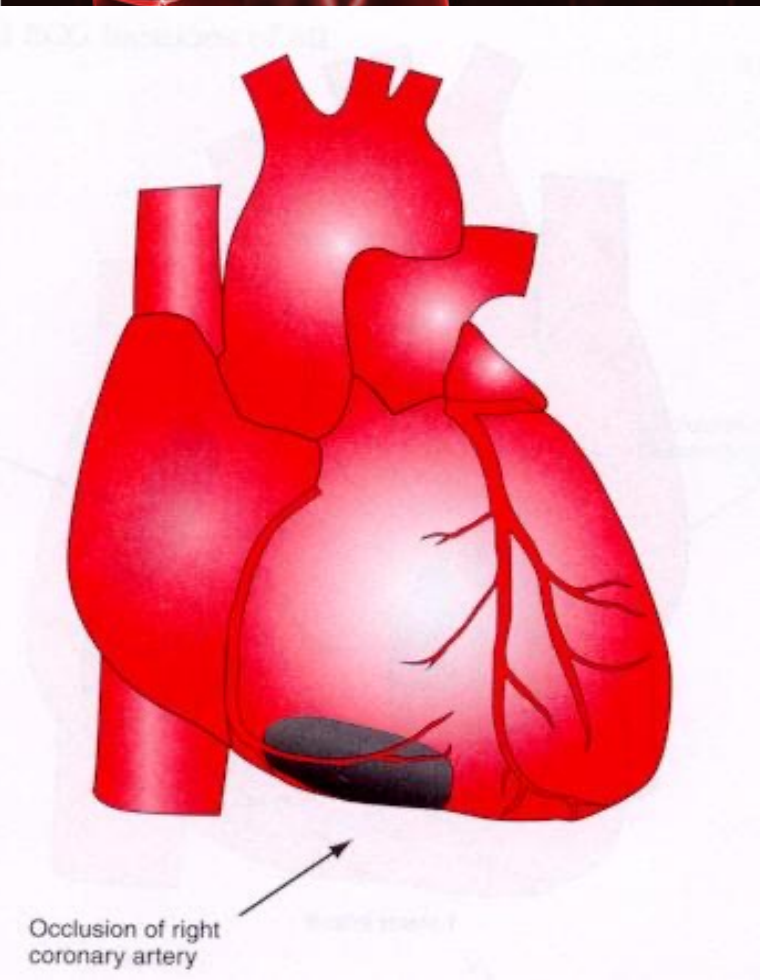
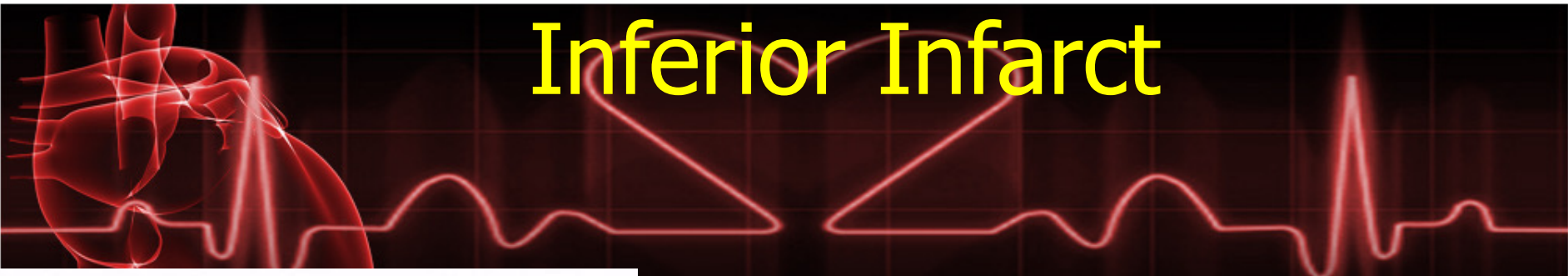Lateral MI



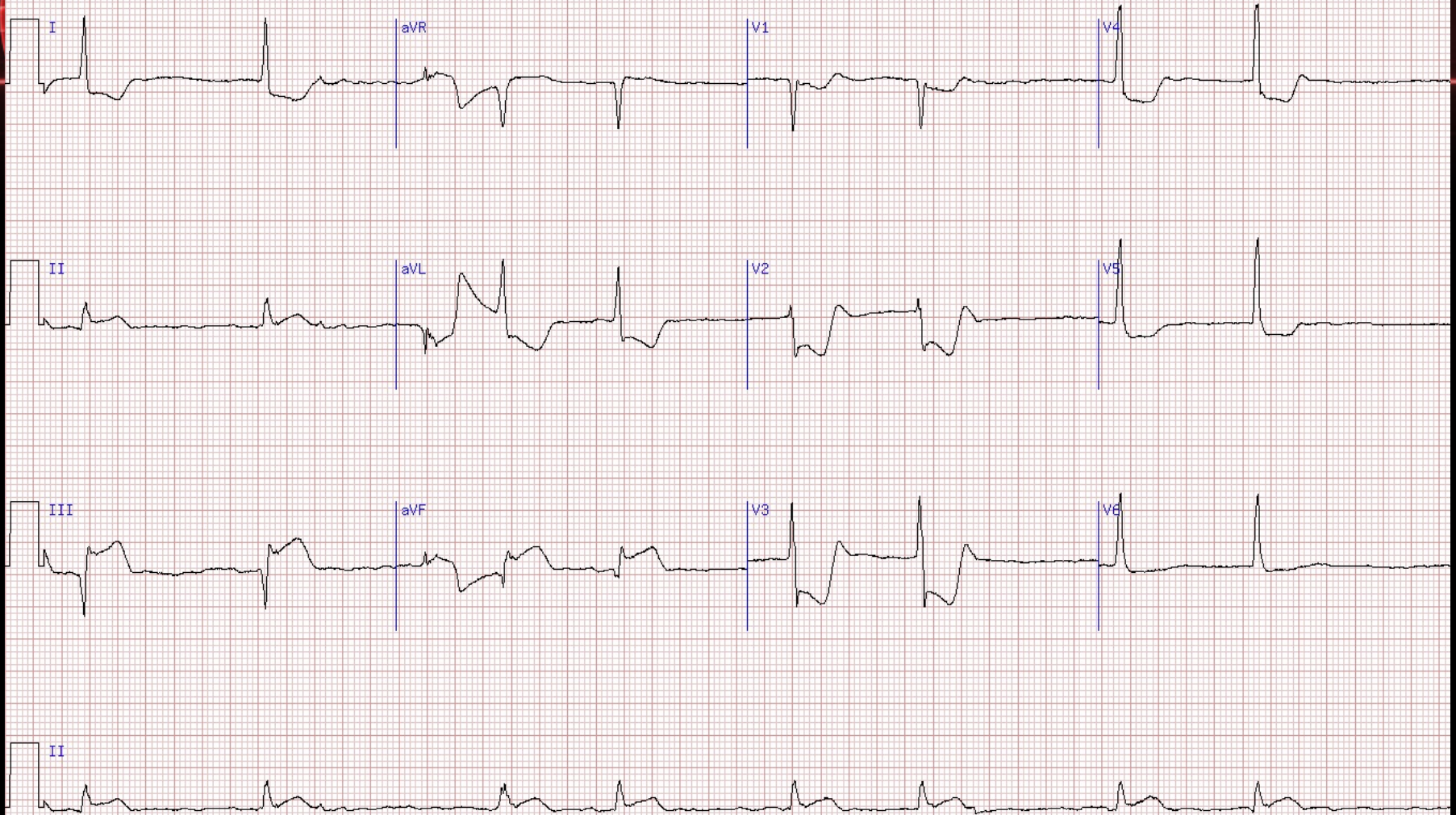
Lateral Wall MI



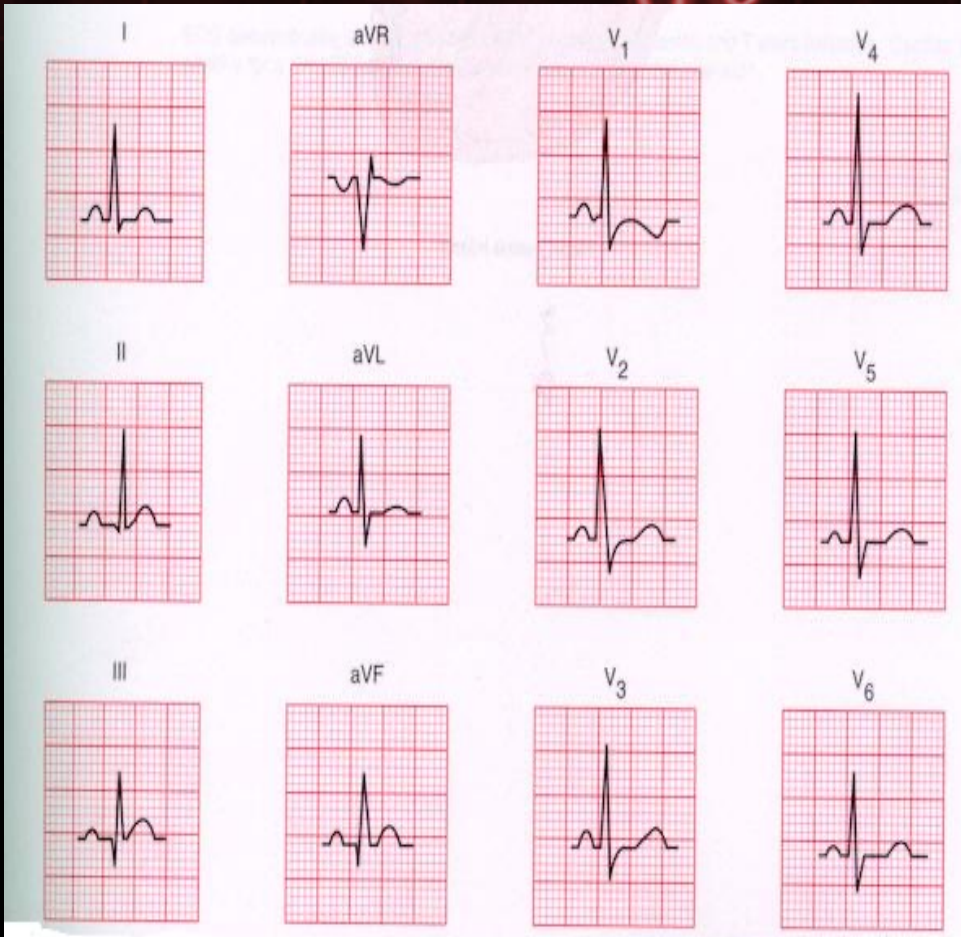
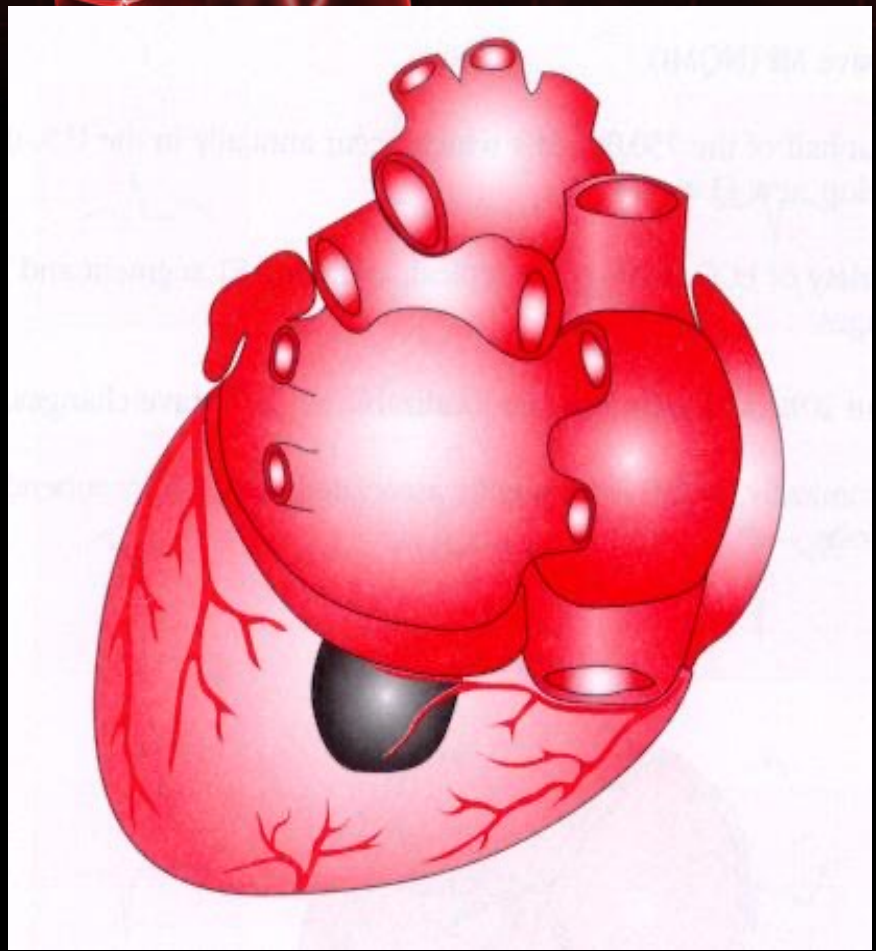
Inferior Infarct



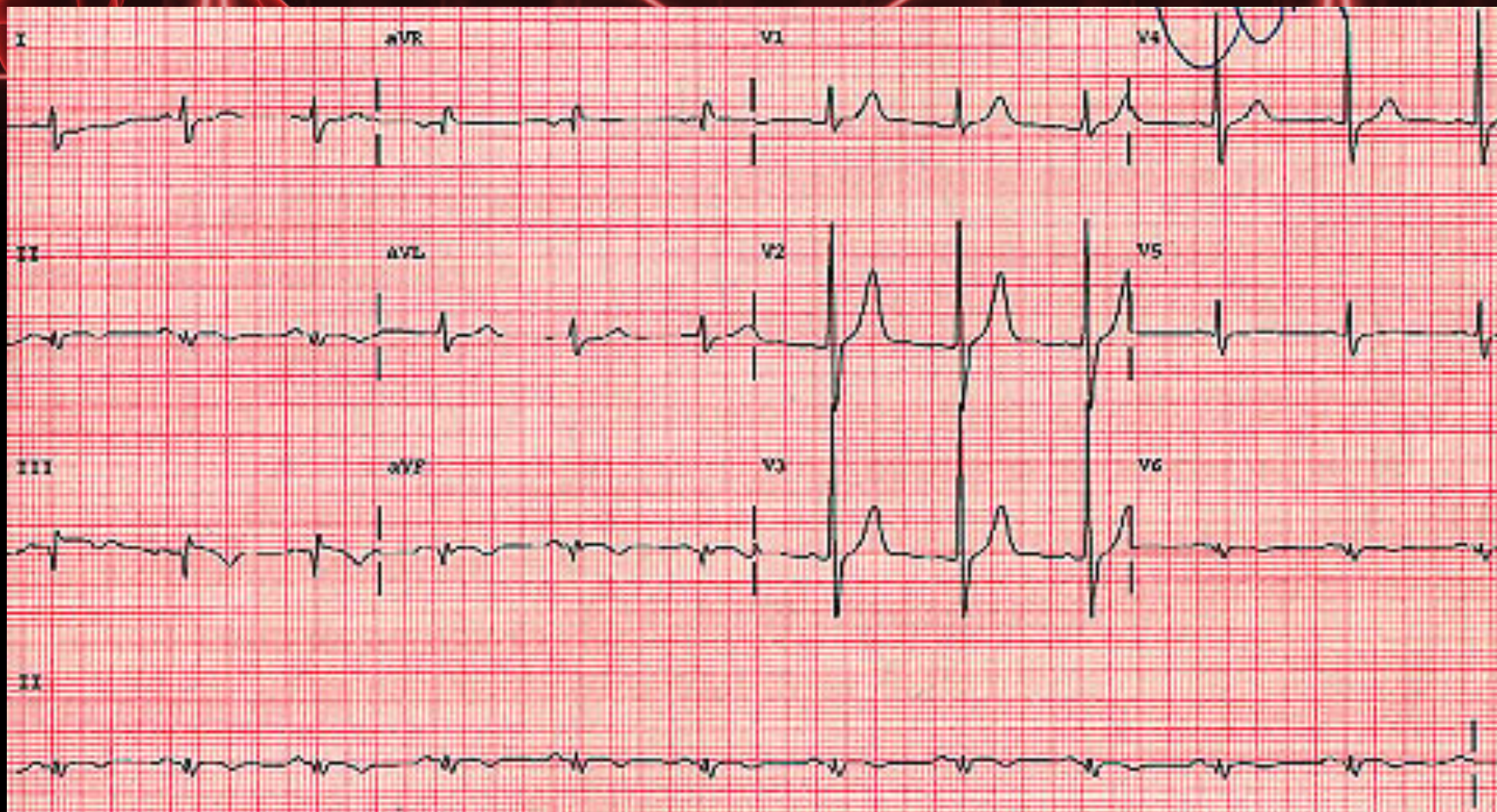
Inferior Wall MI



Posterior Infarct

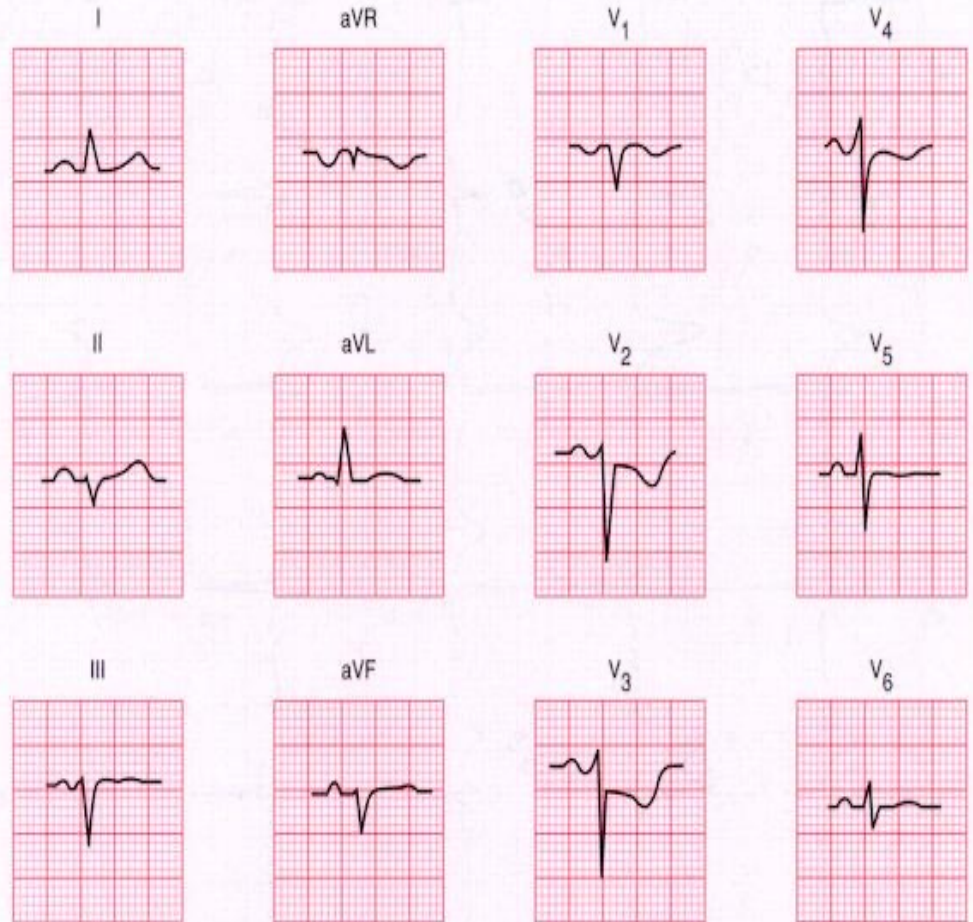
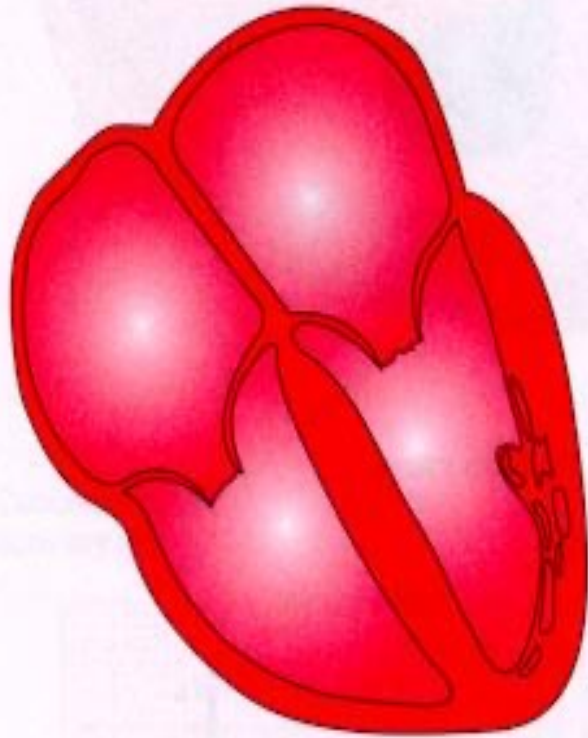


Posterior Wall MI



Notice tall R wave in V1. Posterior wall infarcts are often associated with inferior wall infarcts (Q waves in II, III and aVF).

Non Q-Wave Infarct



Your Next Patient.....

- **A 58 year old male calls EMS complaining of chest discomfort that awoke him out of his sleep. Upon EMS arrival, the patient is found sitting on the edge of the bed. He is anxious but alert and oriented to person, place, time, and event.**
- **Onset: 30 minutes ago while sleeping**
- **Provoke: Nothing makes the pain feel better or worse**
- **Quality: Severe pressure or “ache”**
- **Radiate: The pain does not radiate**
- **Severity: 10/10**
- **Time: He has had chest pain before but “not this bad”**

- **Past medical history: HTN, dyslipidemia**

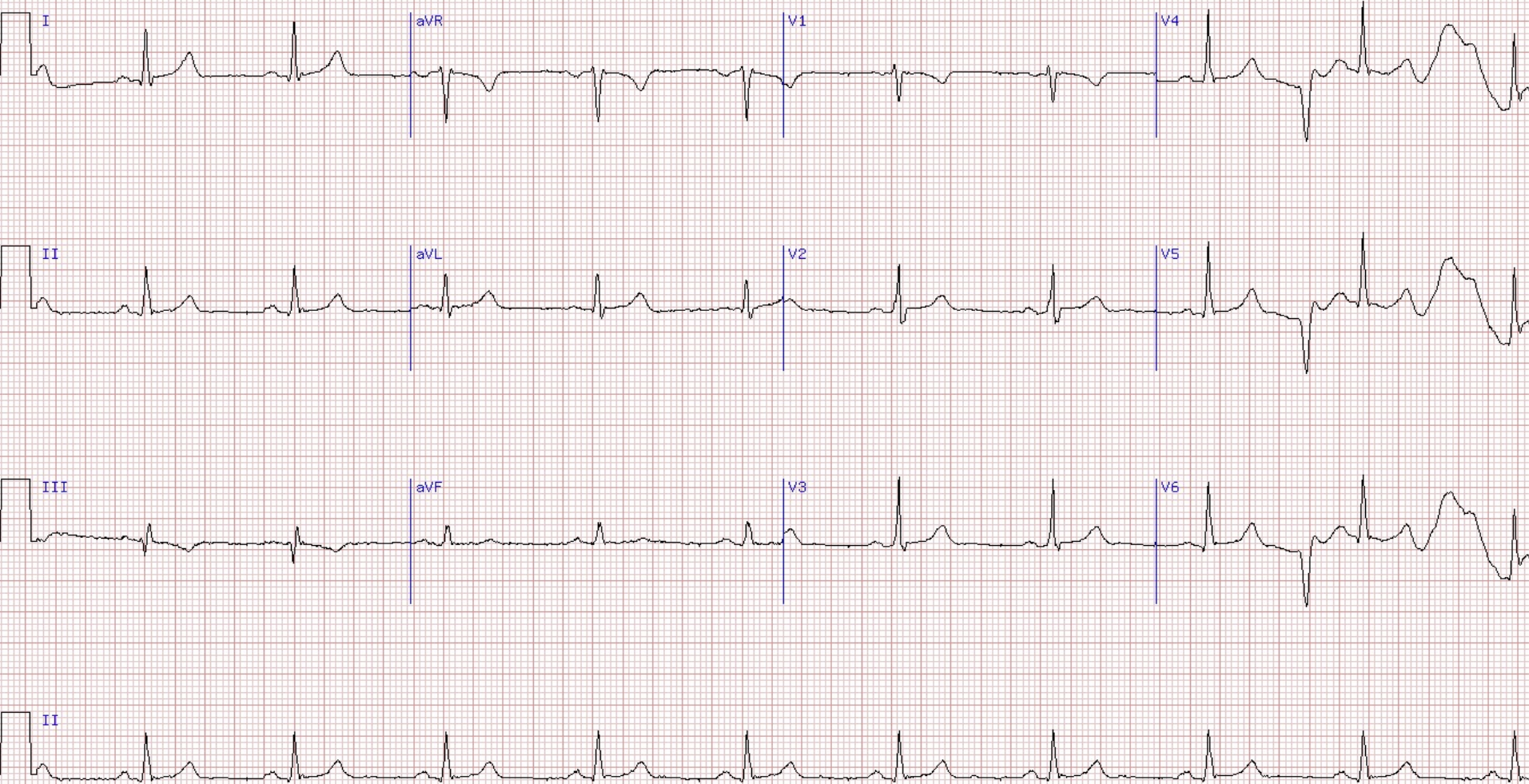
- **Medications: Lipitor, Norvasc, ASA**

- **Vital signs:**
 - **RR: 24**
 - **Pulse: 60**
 - **BP: 160/98**
 - **SpO2: 96 on RA**
 - **Temp: 99.1**
 - **BGL: 138**

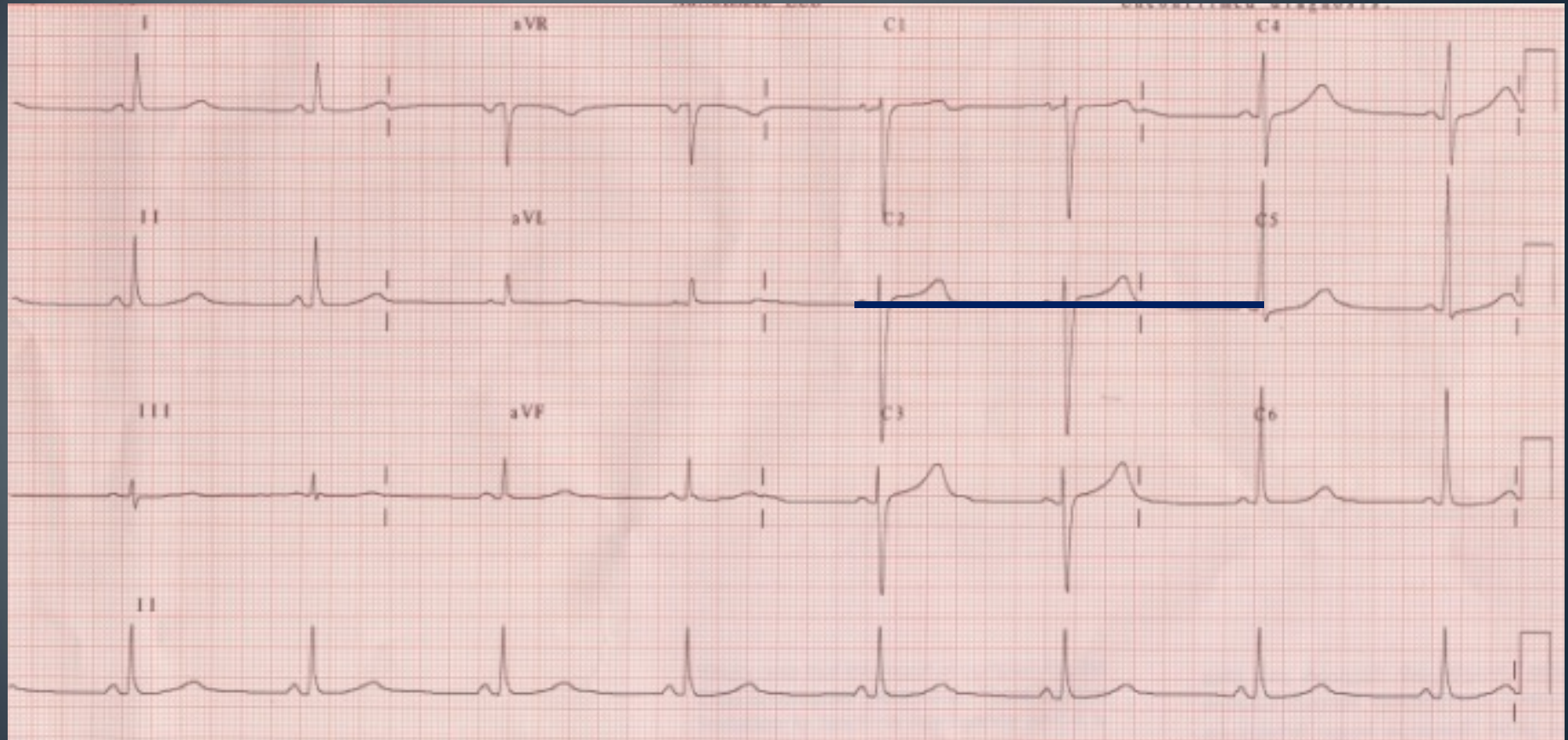
- **Breath sounds: basilar rales**

- **The patient admits to mild dyspnea. He states that he has “gained a little weight” recently and his doctor was getting ready to put him “on a water pill.”**

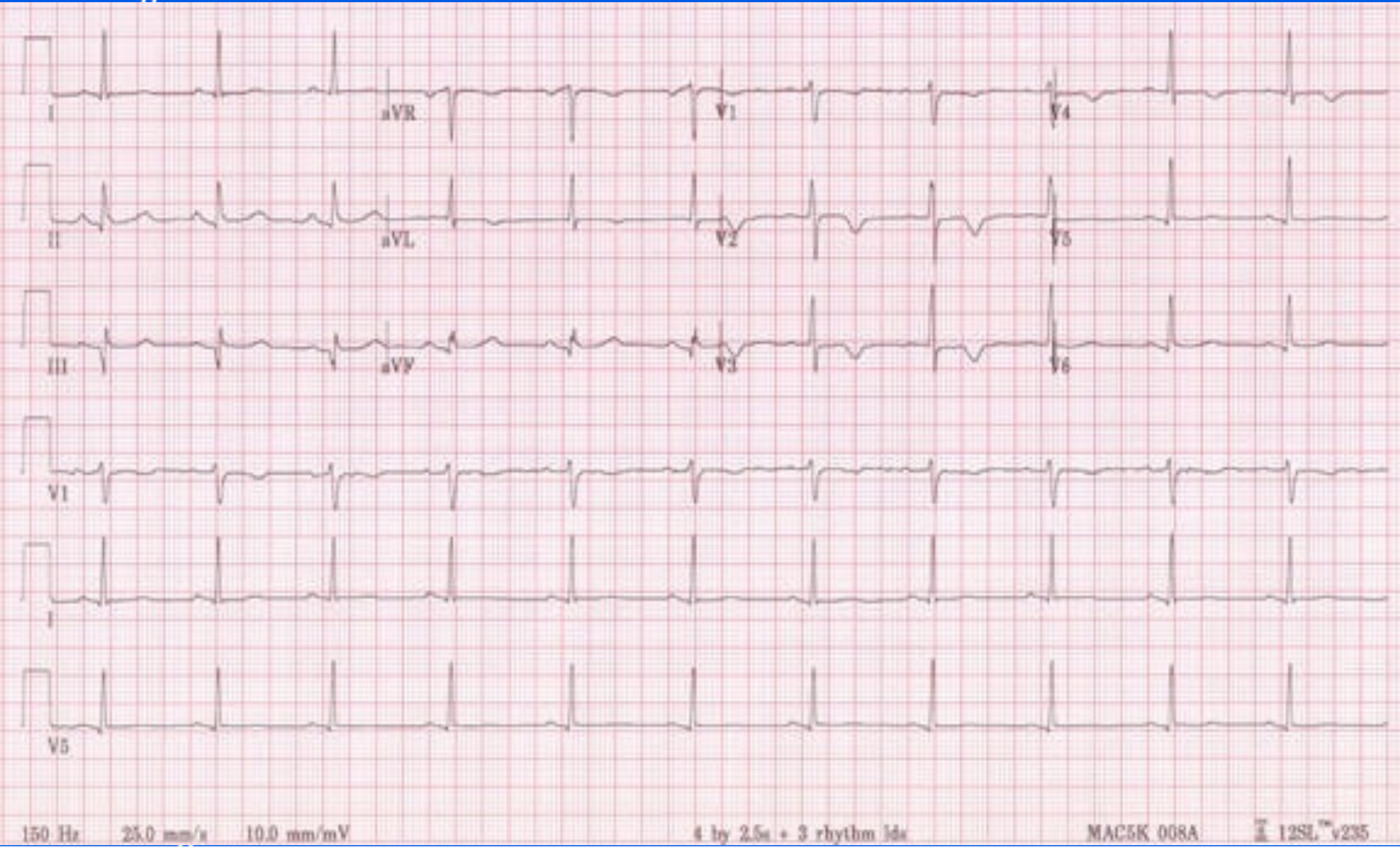
Can I Send Him Home?



One Hour Later

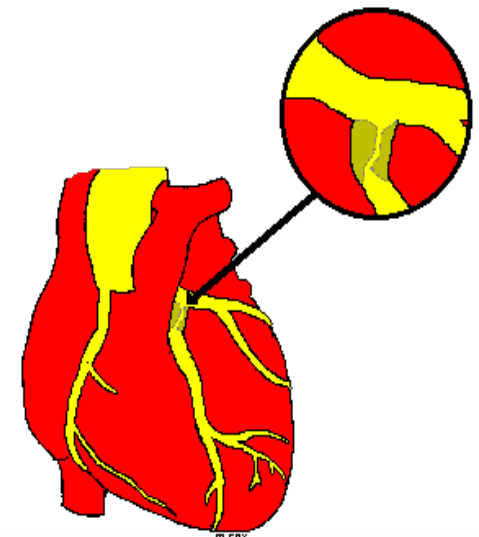


His EKG 4 days Later What Do You See?



Wellens Syndrome

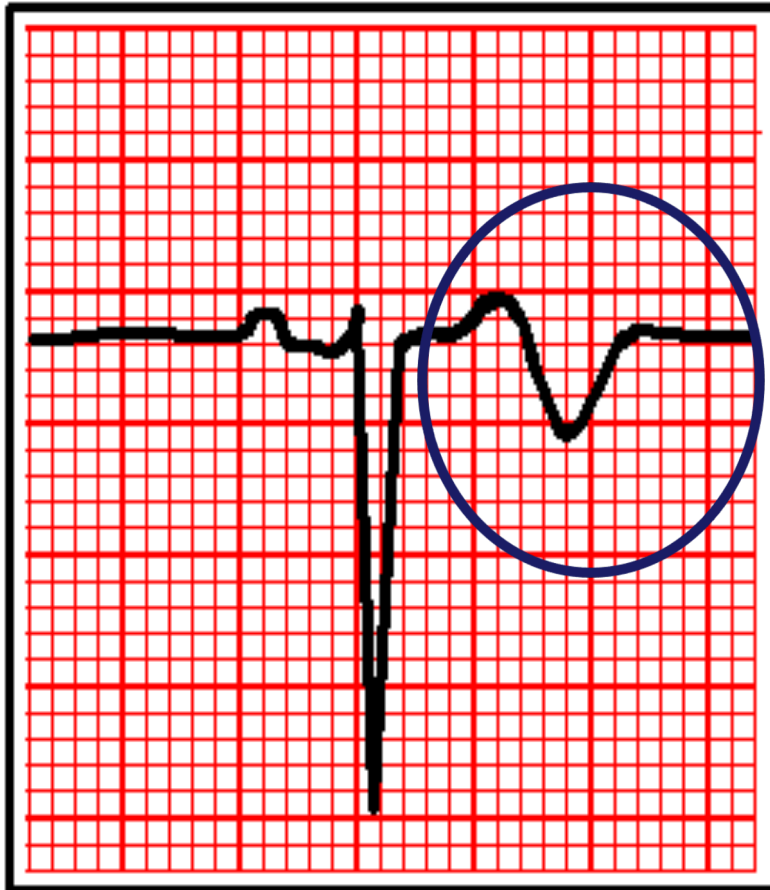
Wellens Syndrome is an easy to identify cardiac syndrome which indicates a critical high grade occlusion of the proximal LAD. If not identified and properly treated **the mean time from onset of symptoms to extensive anterior wall MI is 8.5 days**



Criteria of Wellens Syndrome

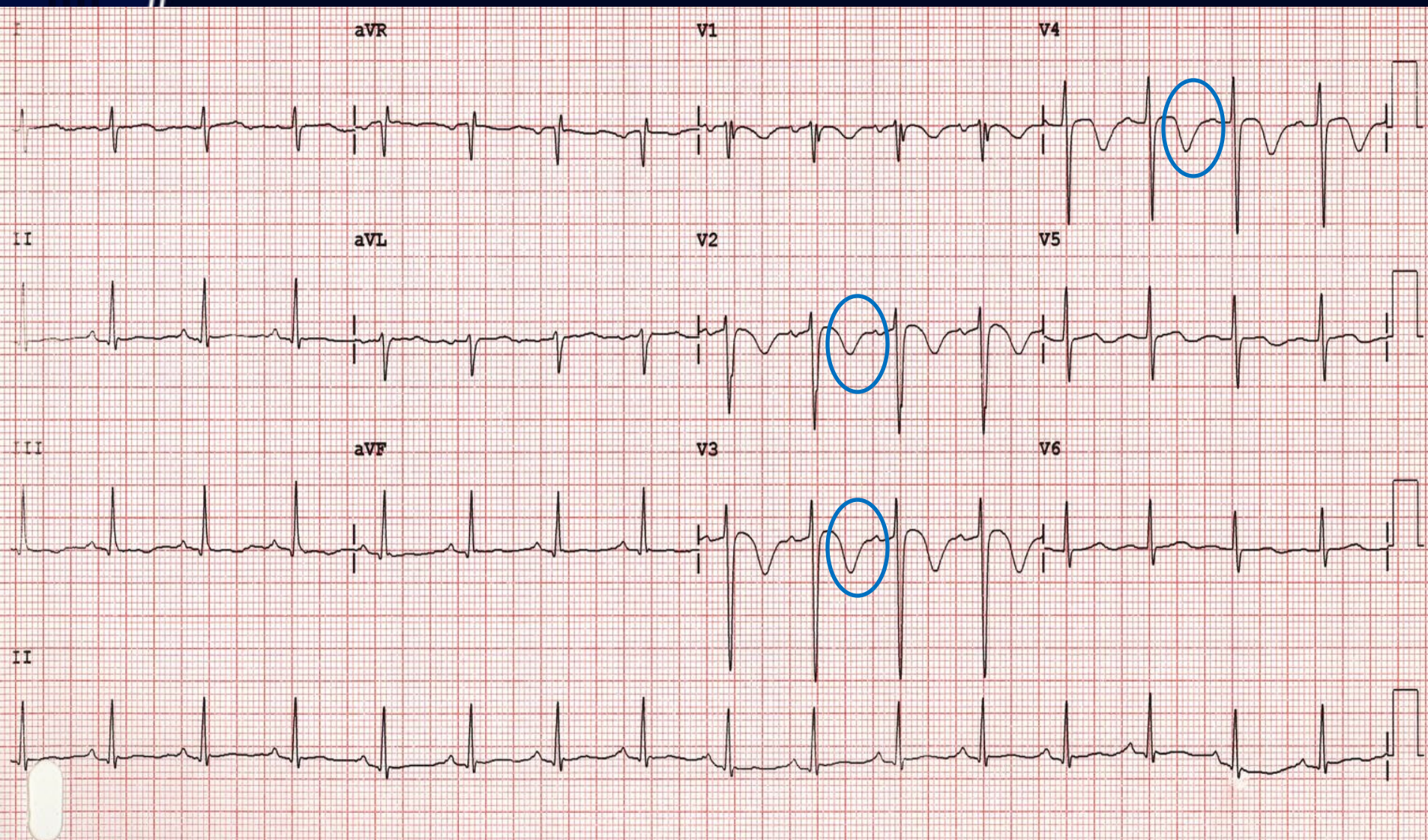
- Prior history of chest pain/angina
- Chest pain with normal EKG
- Normal or minimally elevated cardiac enzymes
- No pathologic precordial Q waves or loss of R waves
- ST segment in V2 and V3 that is isoelectric or minimally elevated (1mm), concave or straight
- Symmetric and deep T-wave inversion or biphasic T-waves in V2-V5 or V6 in pain free periods
- Proximal LAD stenosis

Wellens Syndrome

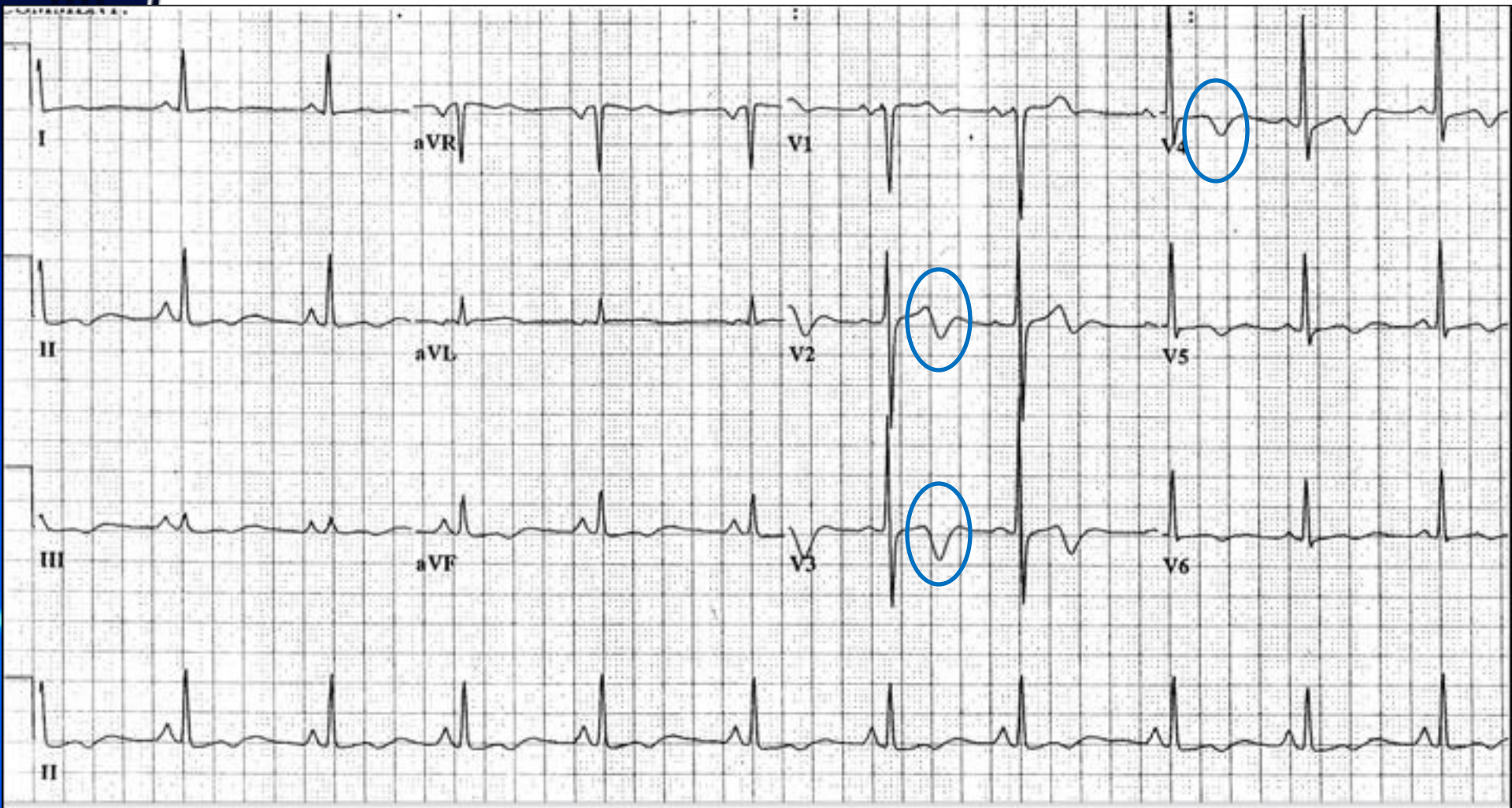

Biphasic T-wave

Wellens Syndrome Type I



Wellens Syndrome (Type II)



Wellens Syndrome Management

Transport to a facility capable of:

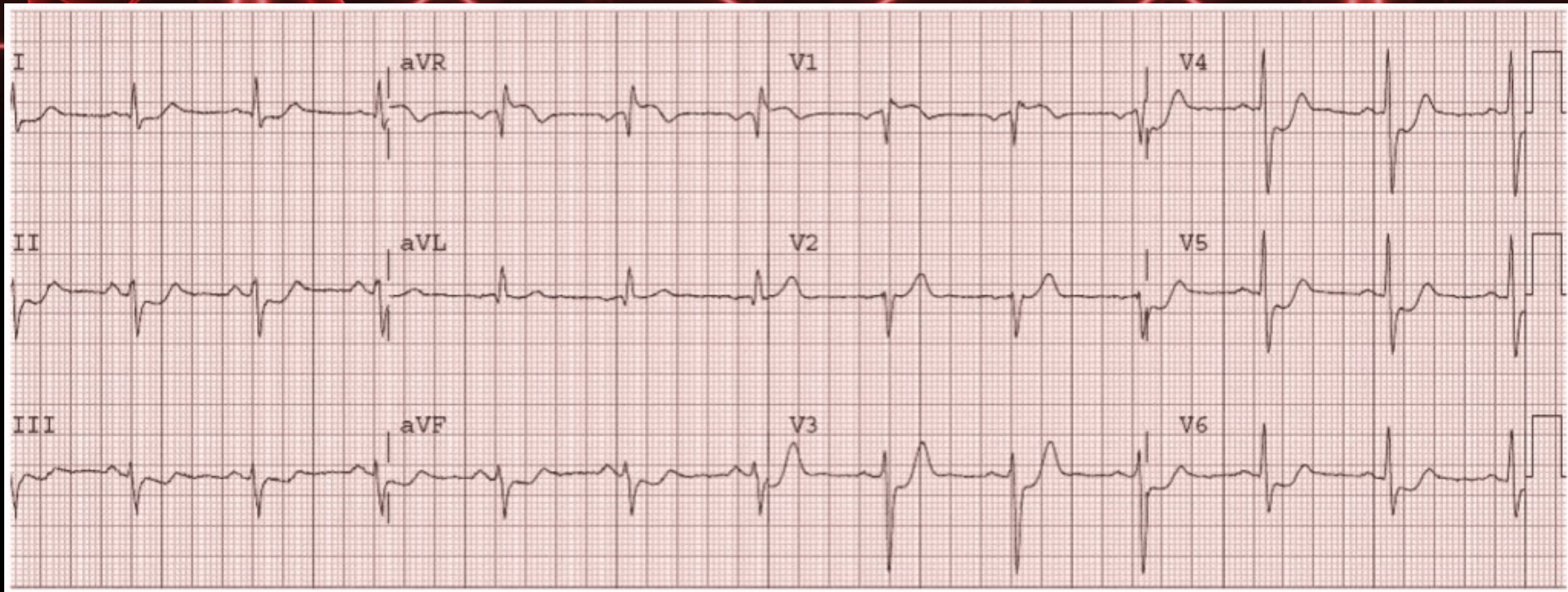
- ✓ Prompt percutaneous transluminal angioplasty
- ✓ Cardiac catheterization or
- ✓ CABG surgery



Would Have Never Guessed

- A 59-year-old man with a history of hypertension, smoking 1 ppd for 40 years, and body mass index (BMI) of 43 developed severe persistent central chest pain at rest that started this AM. His temperature is 100.0, blood pressure is 140/90 mm Hg, respirations are 22 per minute, heart rate is 70 beats per minute and O₂ Sat is 92% on room air. His EKG from EMS while in route is presented to you upon arrival. What do you do?


His EKG - What Do You See?





Left Main STEMI

- Lead aVR has often been called the “forgotten lead”, but it is worth paying attention to because ST-segment elevation in aVR portends a worse prognosis in ACS.
- ST elevation in aVR ≥ 1 mm is the strongest independent predictor of either severe LMCA or triple-vessel disease requiring CABG in patients with NSTEMI.
- Elevation in aVR of ≥ 0.5 mm is an independent predictor of mortality in patients with STEMI.



Left Main Coronary Artery Disease

- Early identification of LMCA disease is critical because acute occlusion can cause rapid hemodynamic and electrical deterioration.
- LMCA insufficiency due to critical stenosis of the left main artery is important to recognize because these patients can progress to complete occlusion and are likely to require surgical intervention (such as CABG).

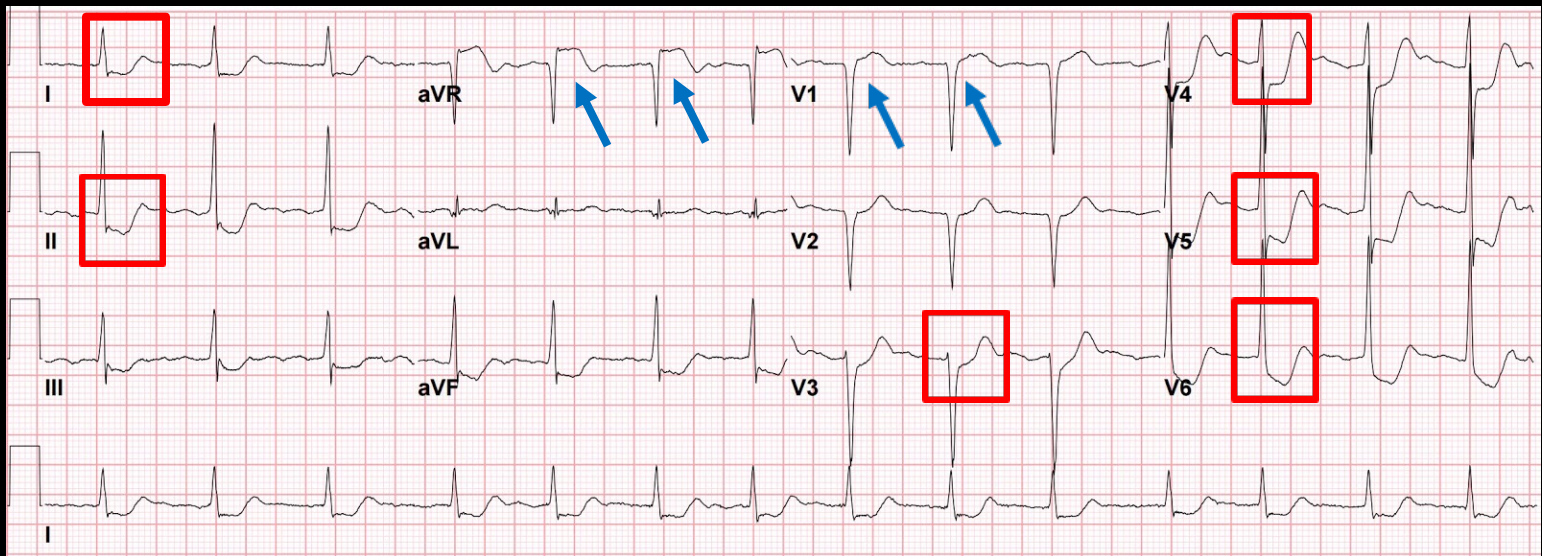


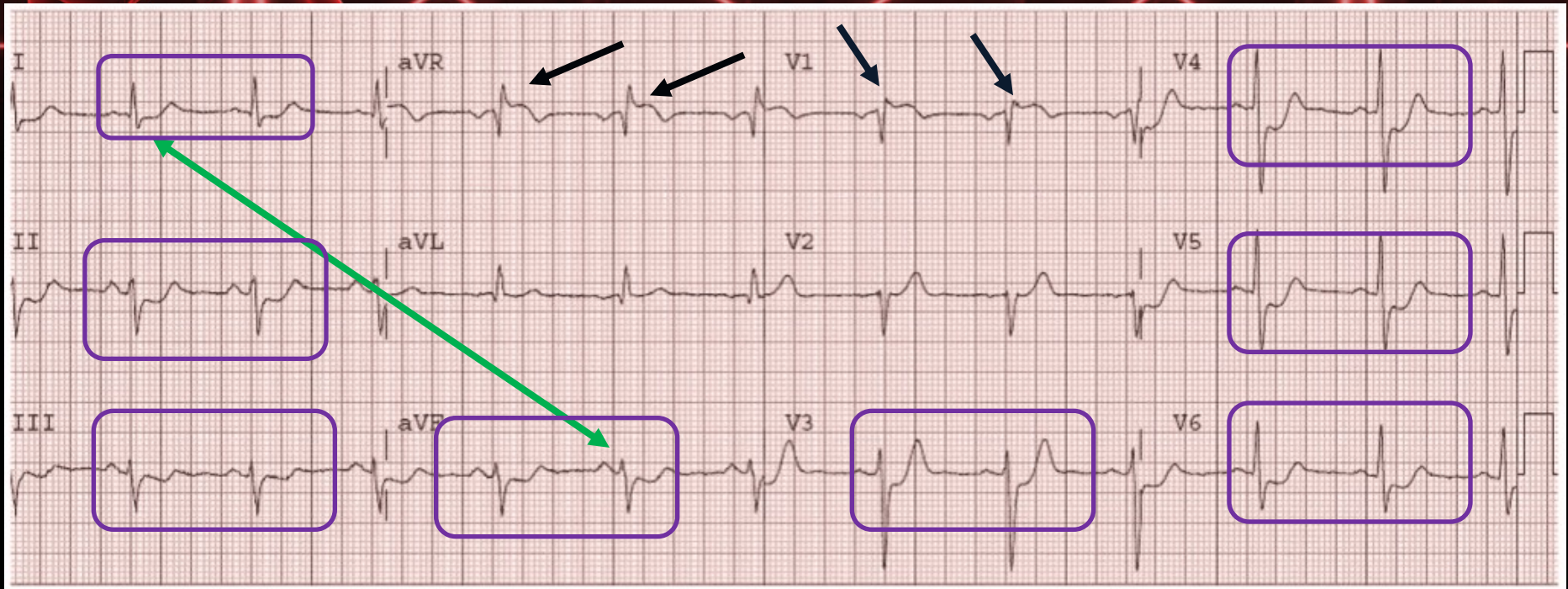
How it Occurs

- ST-elevation in aVR occurs by the following mechanisms:
 - Critical narrowing of the LMCA causing subendocardial ischemia due to insufficient blood flow.
 - Transmural infarction of the basal septum due to a very proximal LAD occlusion or complete LMCA occlusion.
 - Severe multi-vessel coronary artery disease. **
 - Diffuse subendocardial ischemia from oxygen supply/demand mismatch.

Classic Findings on EKG

- ST depression in leads I, II, aVL and V4-6
- ST elevation in aVR ≥ 1 mm
- ST elevation in aVR \geq V1

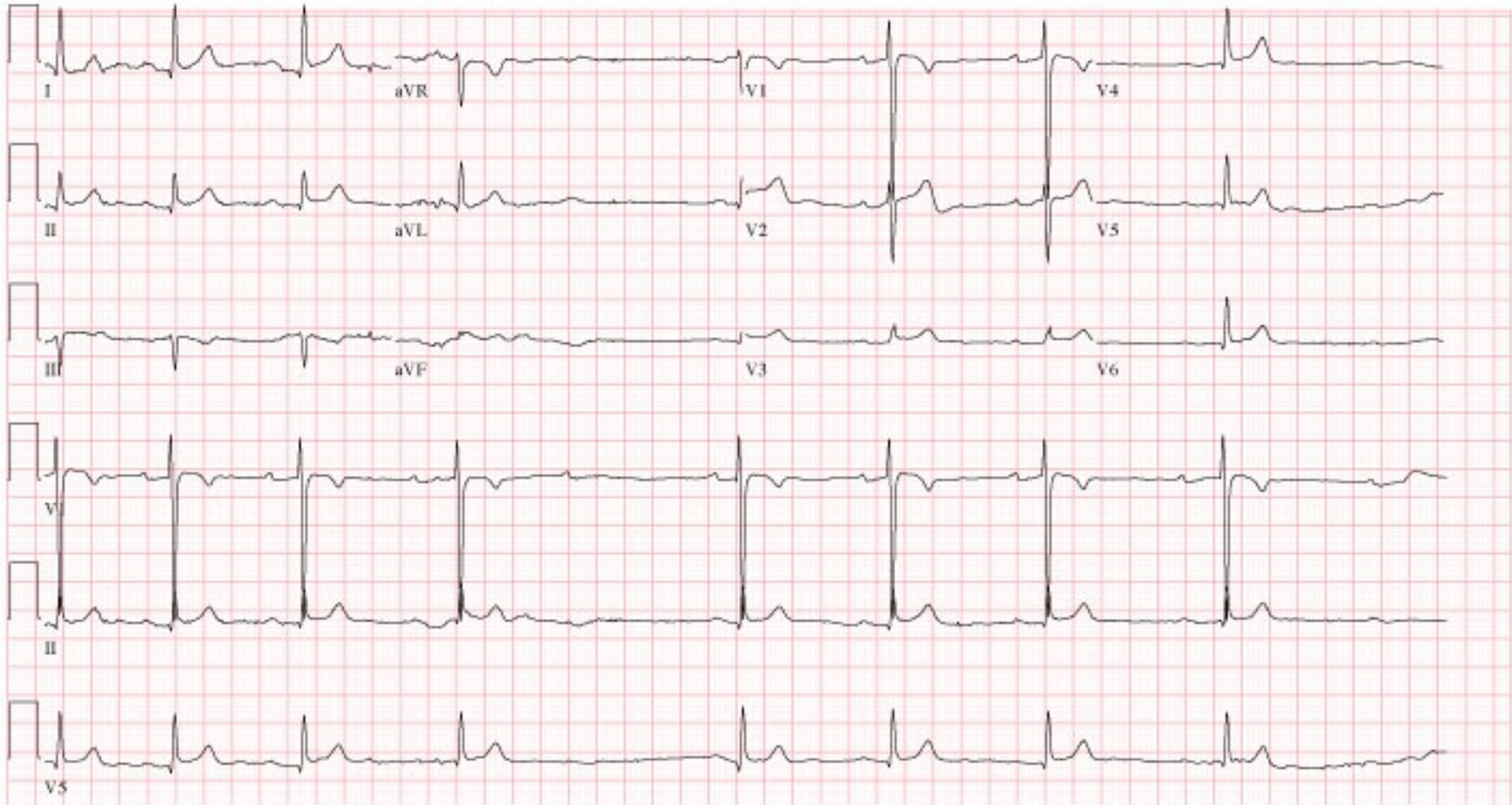






A Few Tips on Left Main Presentation

- STE ≥ 1 mm in aVR or V1 with STD ≥ 1 mm in ≥ 6 leads can suggest left main coronary artery insufficiency, proximal LAD insufficiency, or triple vessel disease, especially if accompanied by pathologic Q-waves, hemodynamic compromise, and/or refractory symptoms.
- STD are most prominent in the inferior and lateral leads and thought to represent subendocardial ischemia.
- This EKG pattern is not specific to LMCA/proximal LAD insufficiency and can be seen in other conditions (eg, pulmonary embolism, aortic dissection, LVH with strain pattern).



Rate 75 Rhythm Regular? No P-Waves Upright? Yes
Q-Waves No Any ectopic beats? Yes – lateral and anterior ST elevation
Rhythm Diagnosis is Sinus Rhythm with sinus pause and ST Elevation

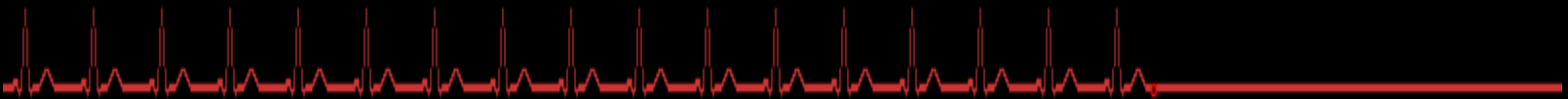

Now we search for everything else of importance.



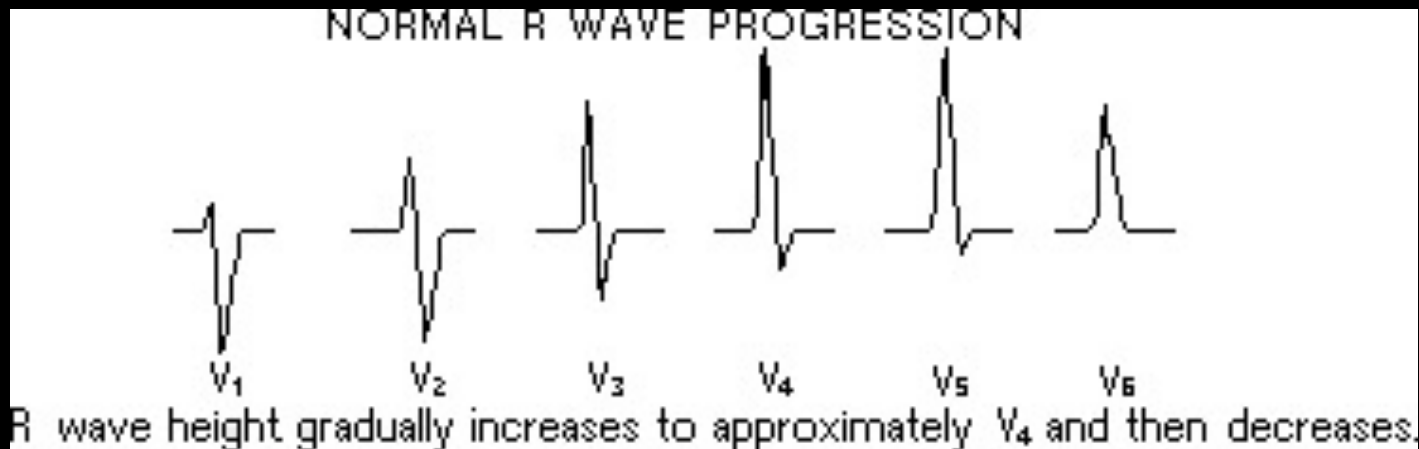


R-Wave Progression



R Wave Progression

- Normally the R wave becomes progressively taller as one moves across the precordial leads.
- A number of conditions may be associated with **"poor" R wave progression**, in which the R wave in leads V1 through V3-V4 either does not become bigger, or only increases very slowly in size.





Causes of Poor R Wave Progression

LVH

RVH

Pulmonary disease (i.e., COPD, chronic asthma)

Anterior or anteroseptal infarction

Conduction defects (i.e., LBBB, LAHB)

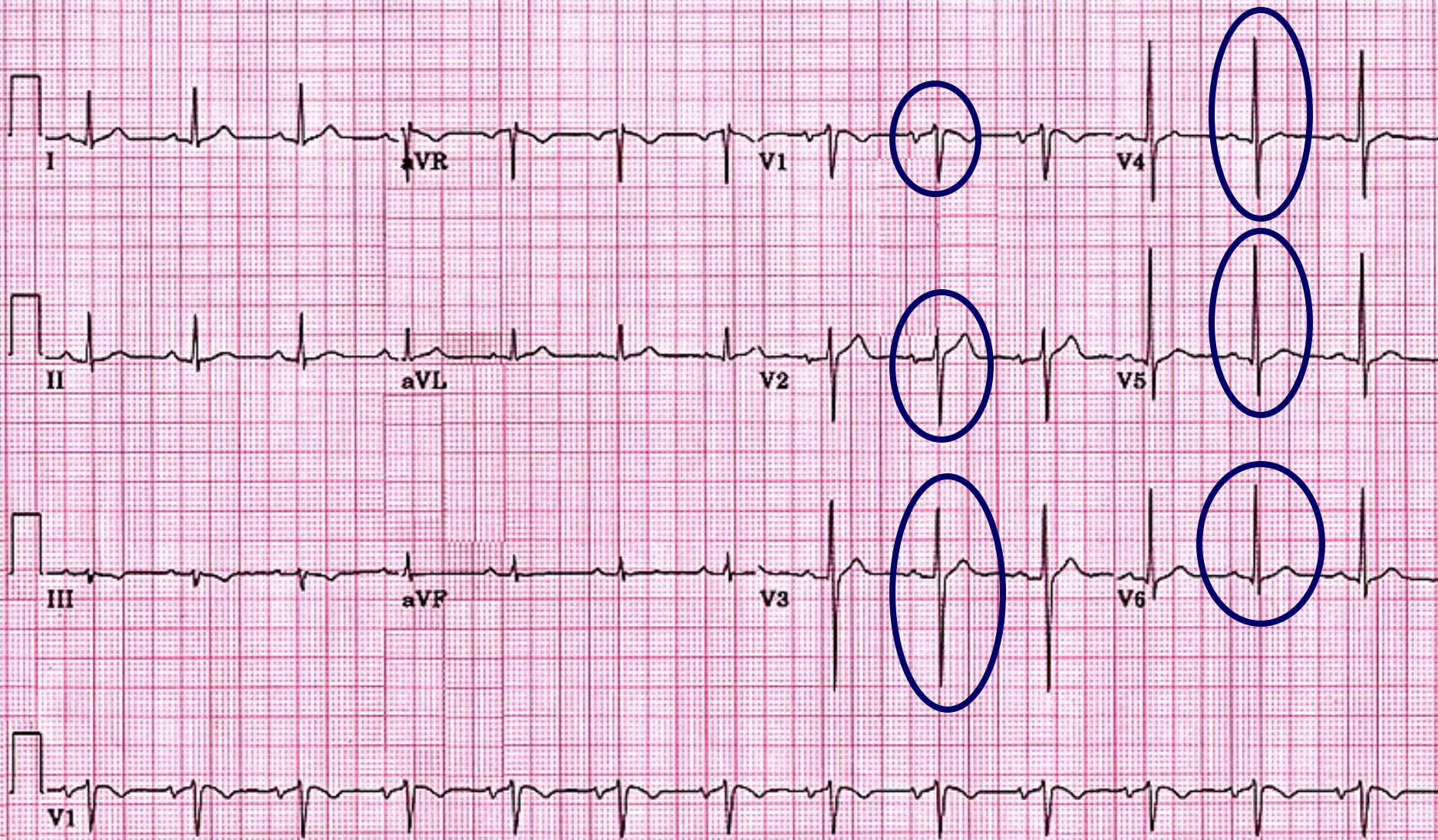
Cardiomyopathy

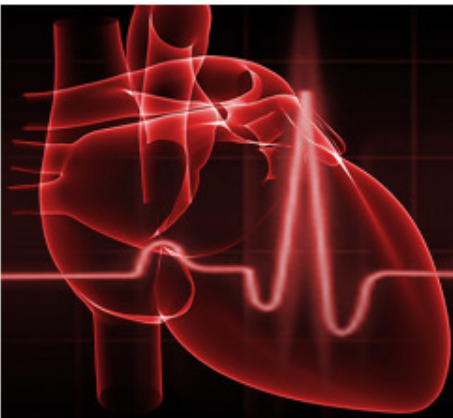
Chest wall deformity

Normal variant

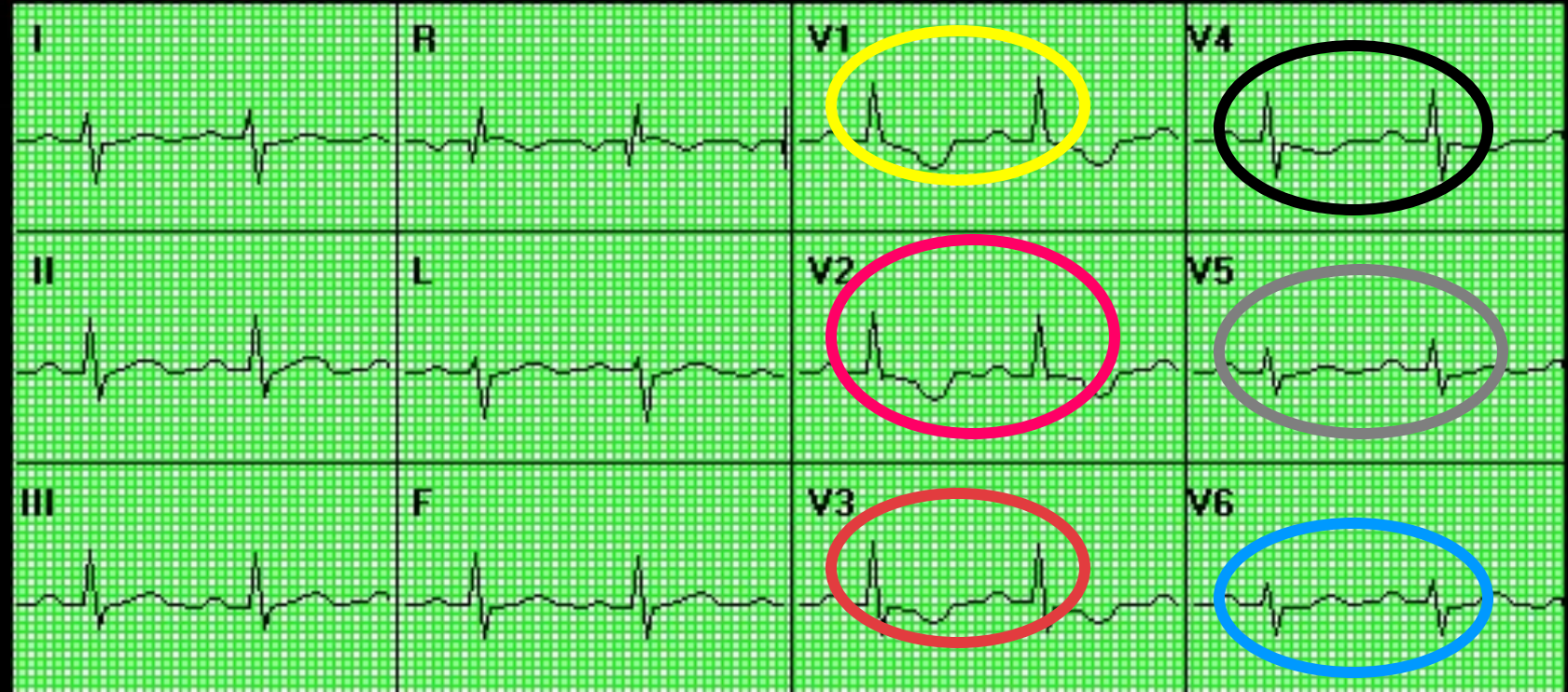
Lead misplacement

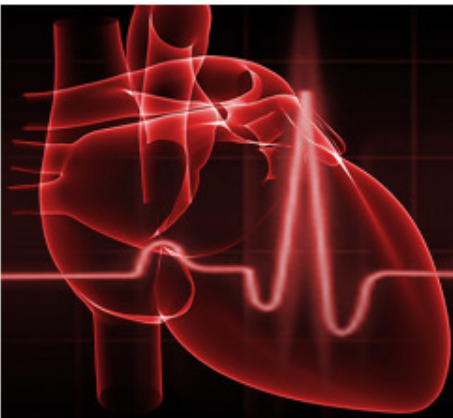
Good R-Wave Progression





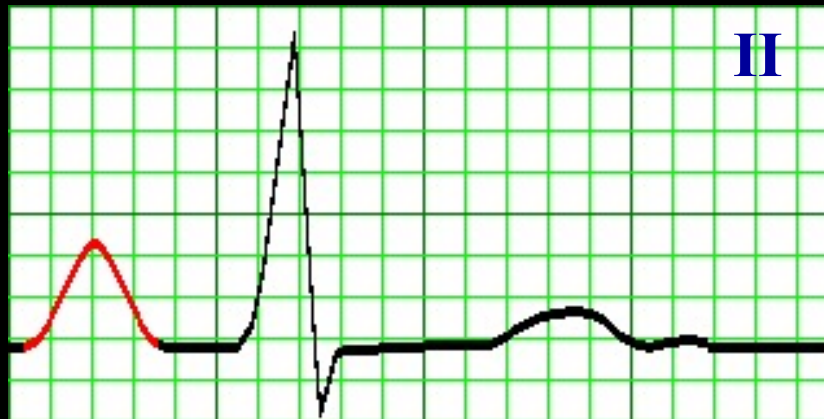
Poor R-wave Progression

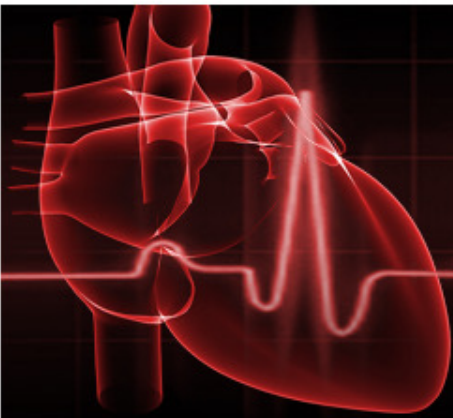




Right Atrial Enlargement

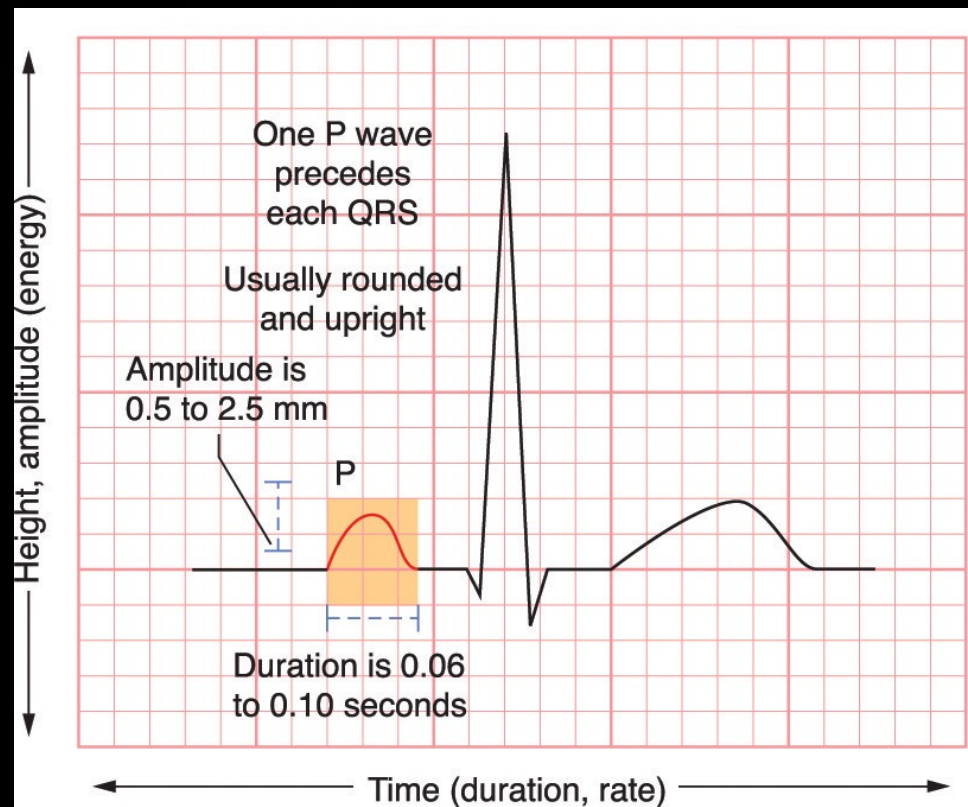
- Diagnosed by looking for a:
 - Biphasic P-wave in lead V1 &
 - P wave 2.5 millimeters or greater in height in lead II
- Causes of right atrial enlargement include COPD, mitral stenosis, mitral regurgitation, or pulmonary emboli.
- Because RAE is so frequently seen in chronic pulmonary disease, the peaked P wave is often called “P pulmonale.”





Normal P Wave

- Duration 0.06 – 0.10 seconds
- Amplitude 0.5 – 2.5 mm
- First portion represents right atrial depolarization
- Terminal portion represents left atrial depolarization



P-Pulmonale Pattern

P pulmonale in II, III, aVF

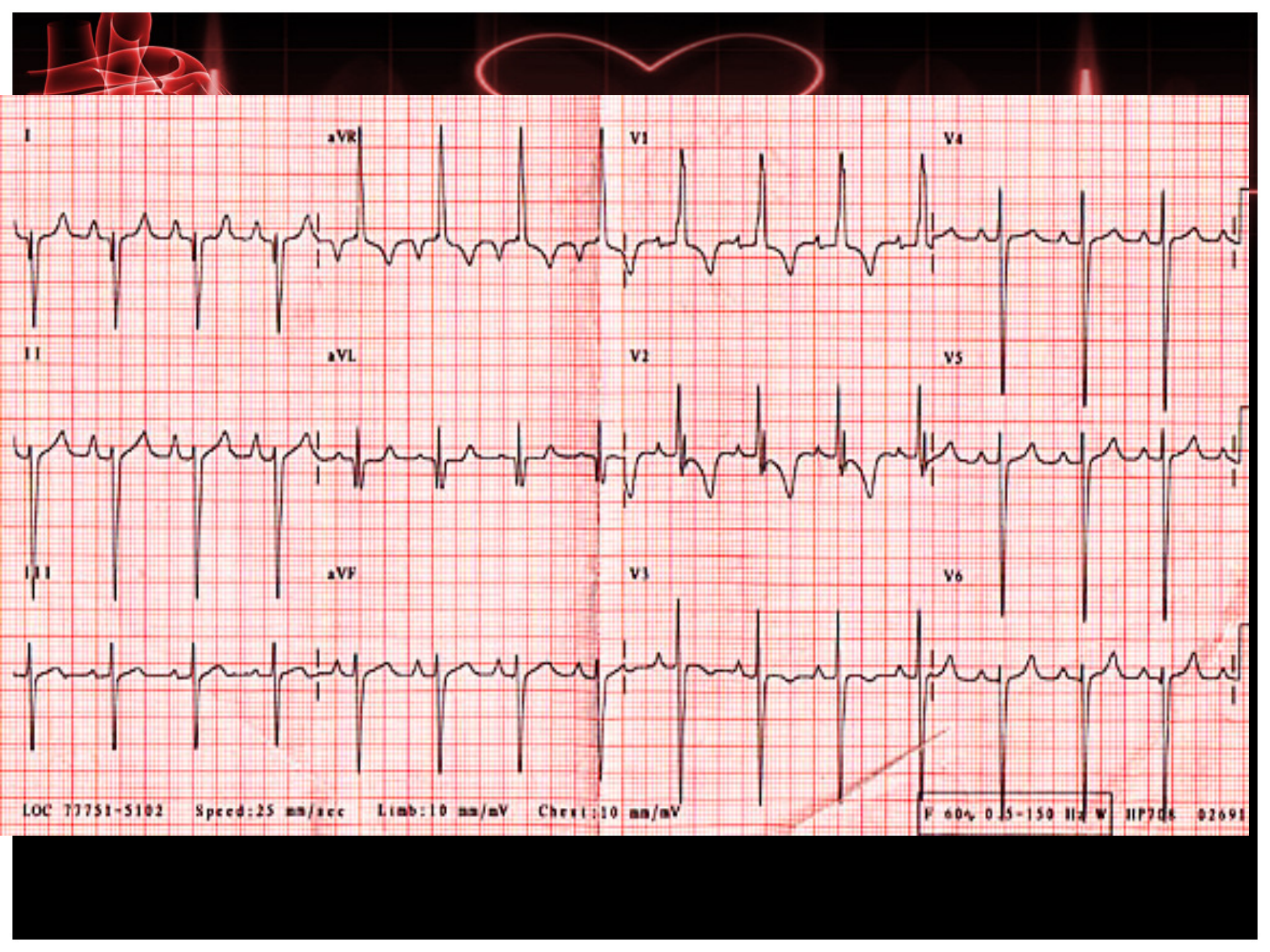


P pulmonale in V1



Classic finding in Severe Right Atrial Enlargement (RAE)

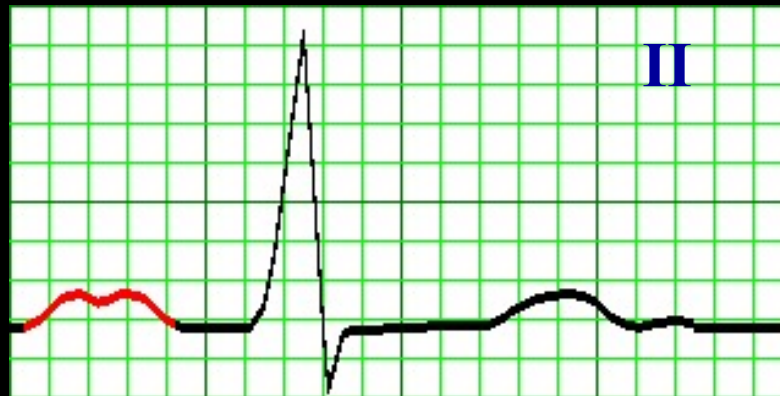Tall **P**eaked and **P**ointed **P** waves in the **P**ulmonary leads (II, III, aVF). If the **P** wave looks "uncomfortable to sit on", think **RAE!!!**



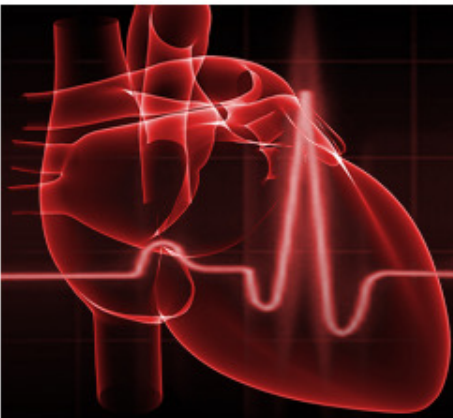




Left Atrial Enlargement

- Dilation or hypertrophy of the left atrium may increase the **DURATION** of the P wave (> 0.11 msec). (Recall that right atrial enlargement causes an increase in the **HEIGHT** or amplitude of the P wave.)

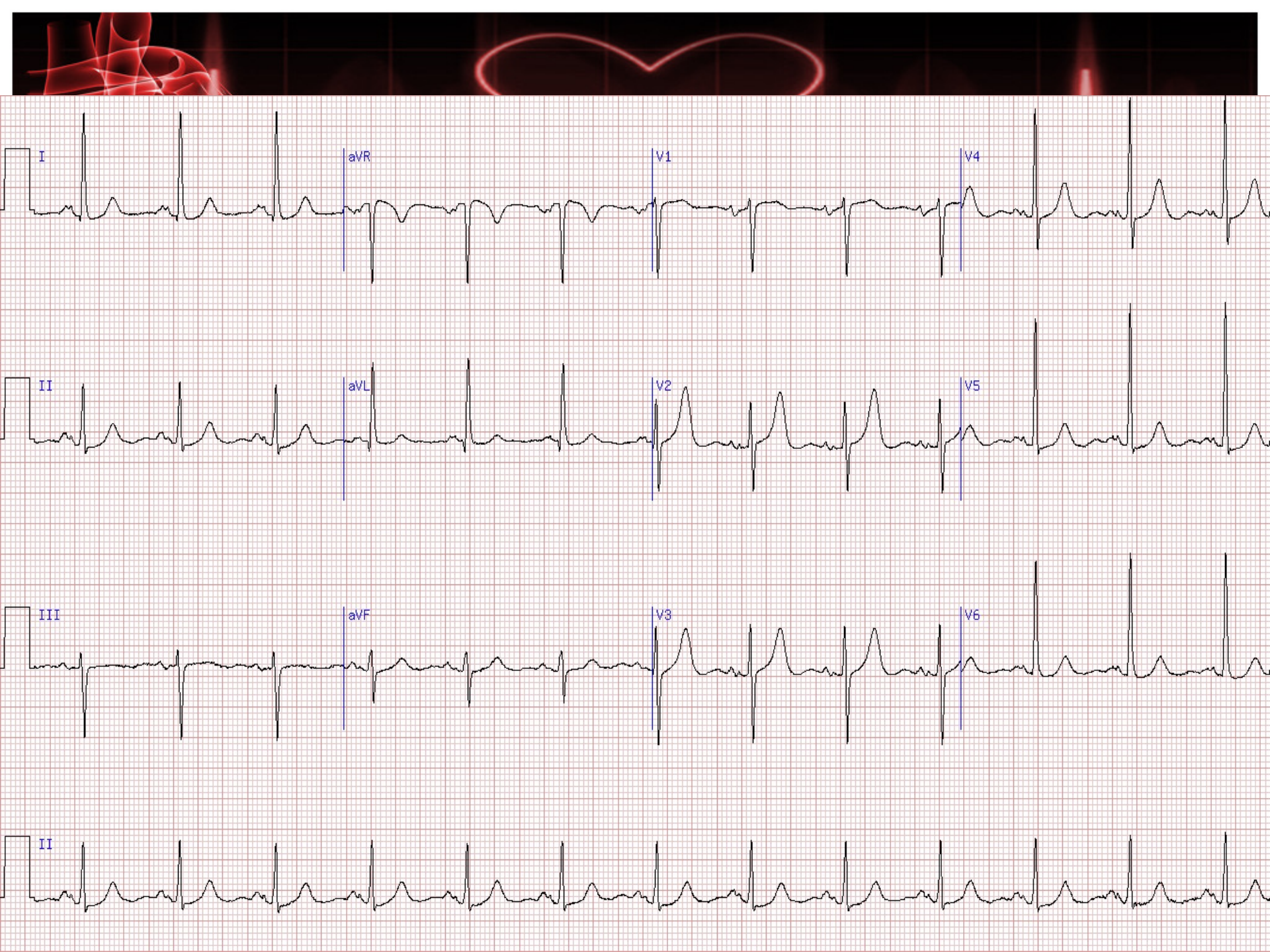


P-Mitrale Pattern



P mitrale in II, III, aVF	P mitrale in V1
	

- Diagnosed by finding an *m*-shaped (notched) and widened P wave (≥ 0.12 second) in a "*m*itral" leads (I, II, aVL) and/or a deep negative component to the P in lead V1.
- Caused by conditions that increase either pressure or volume loading on the atria leading to enlargement and/or hypertrophy.
 - Longstanding hypertension
 - Obstructive cardiomyopathy
 - Aortic stenosis
 - Aortic regurgitation

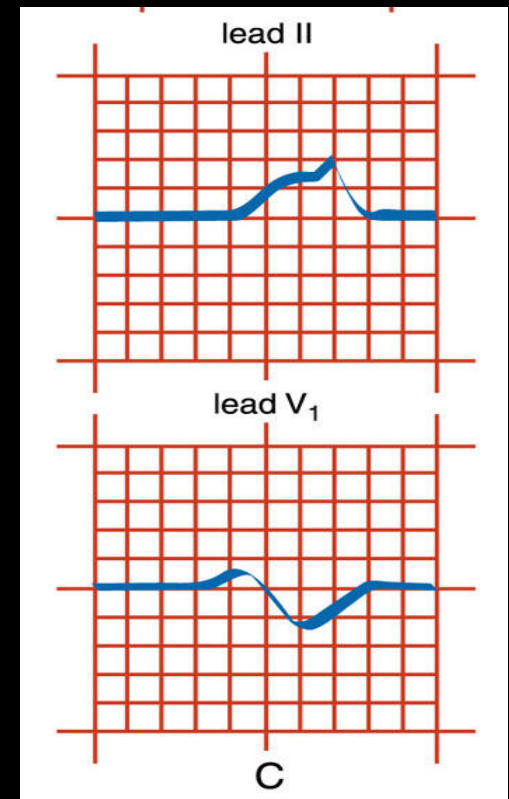
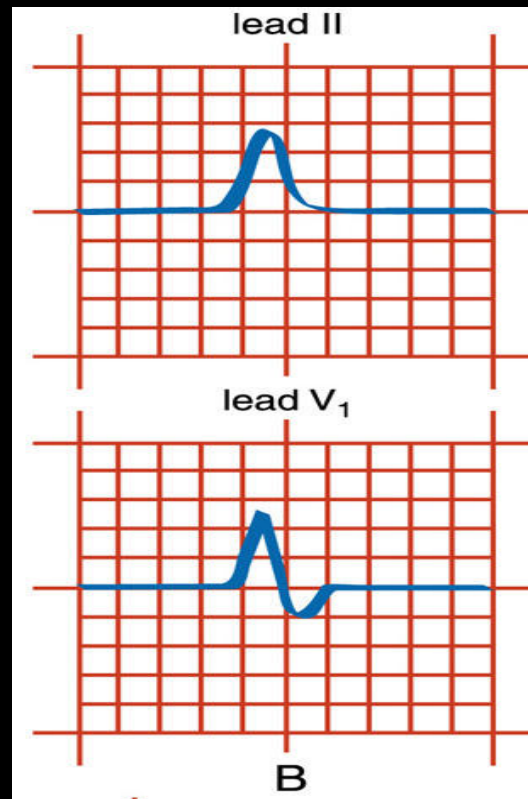
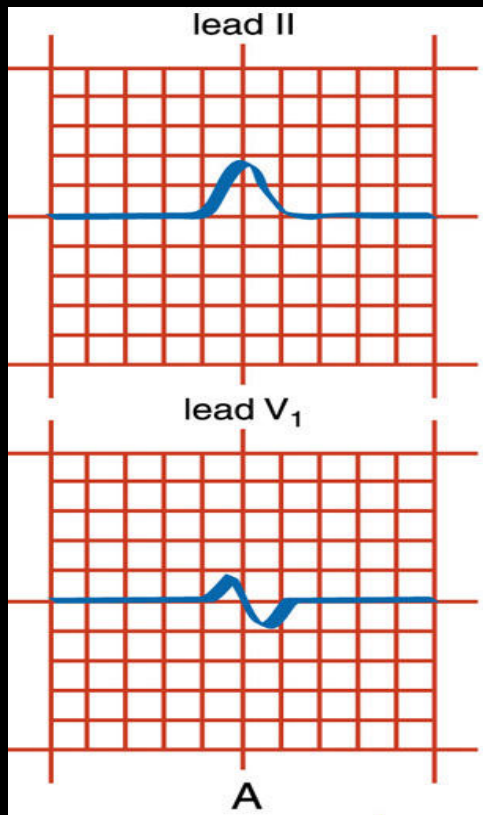


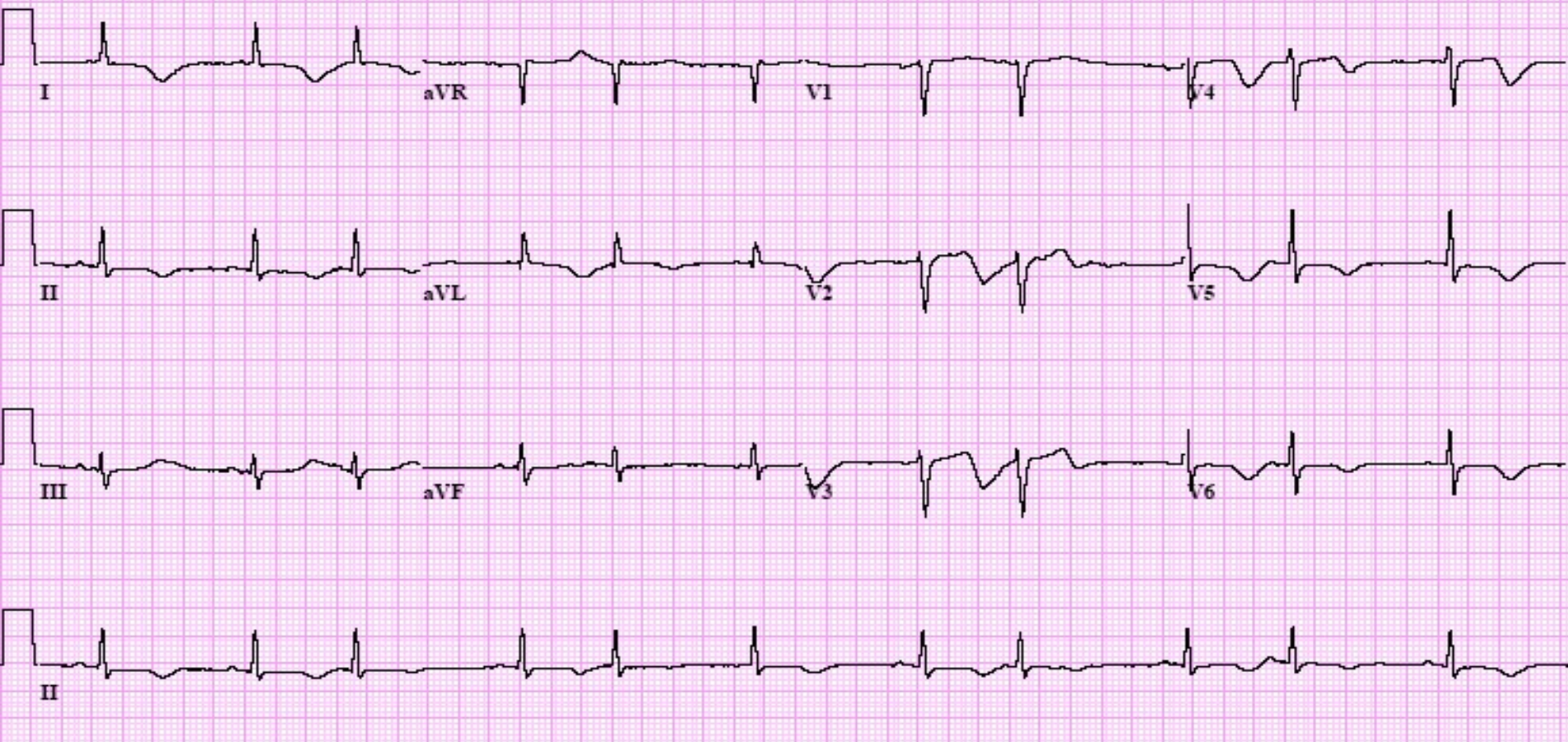
Summary

- **Atrial Enlargement Criteria**

P > 2.5mm height = RAE

P > 0.11 sec or P notch > 1 box width
or P biphasic > 1 box square = LAE





Rate Variable Rhythm Regular? No P-Waves Upright? Yes

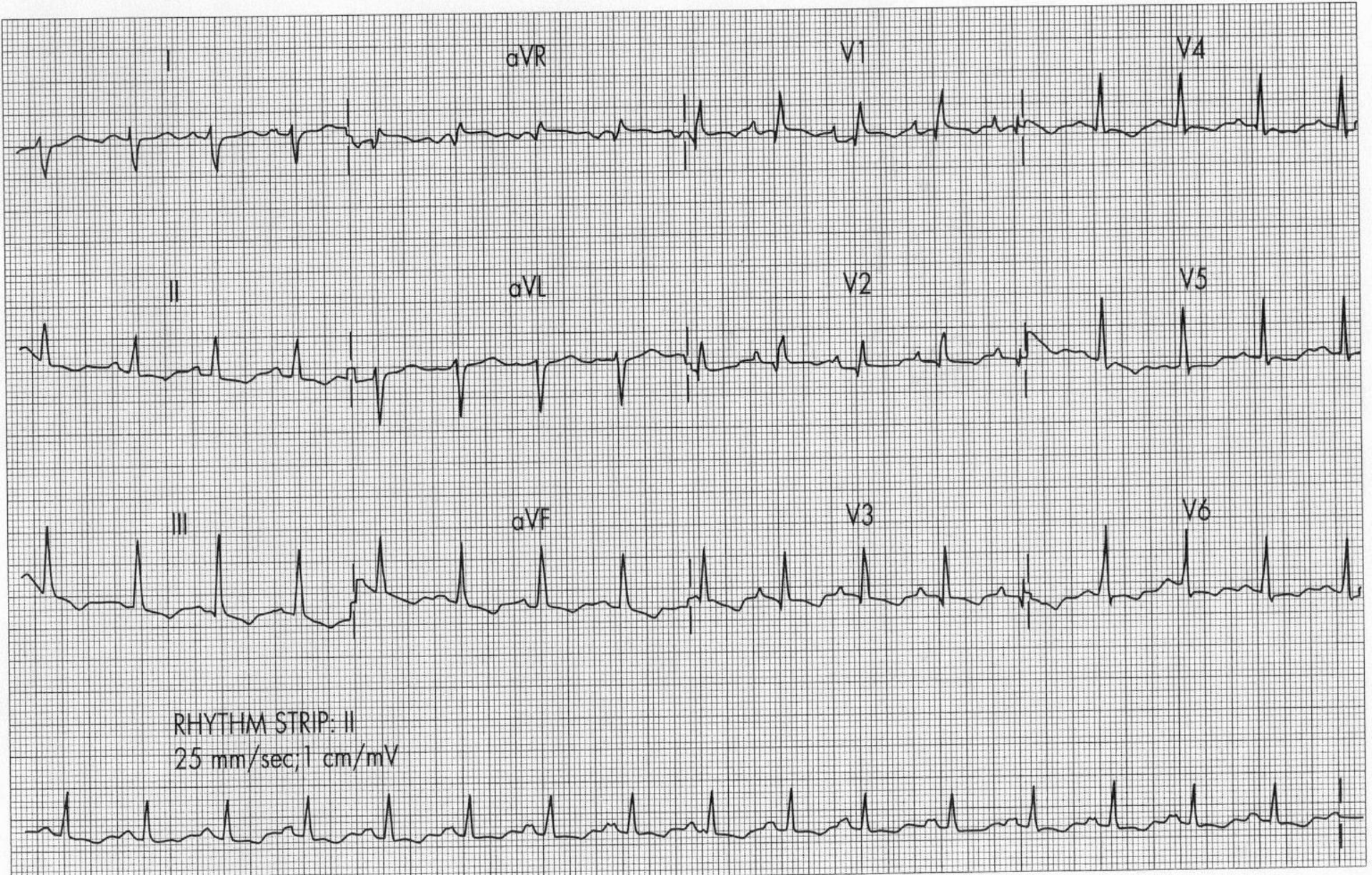
Q-Waves No Any ectopic beats? Yes

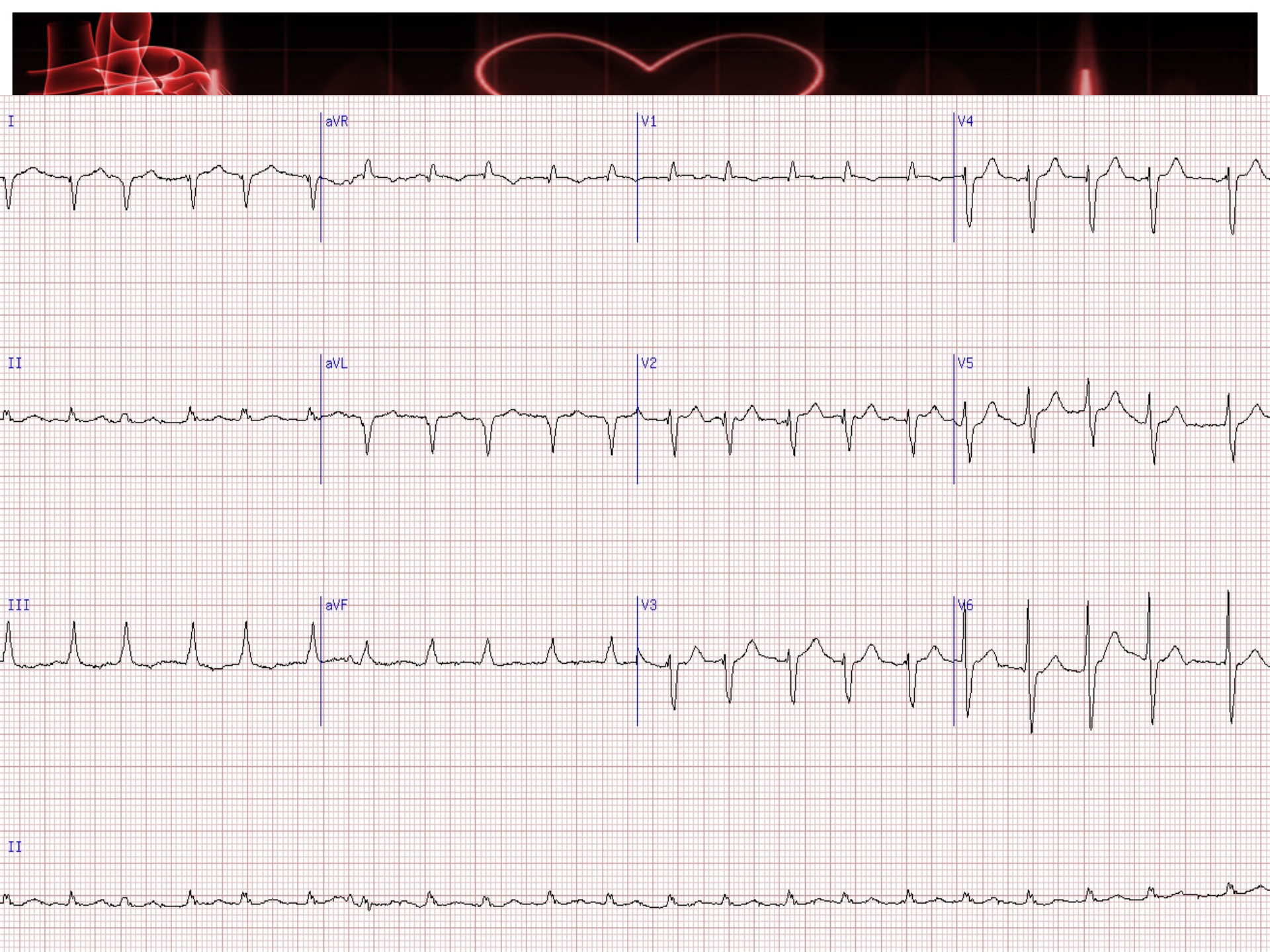
Rhythm Diagnosis is Sinus Rhythm with bigeminal pattern of PJC/PAC's



Right ventricular hypertrophy

- RVH increases the height of the R wave in V1. An R wave in V1 that is greater than 7 boxes in height, or larger than the S wave, is suspicious for RVH. Other findings are necessary to confirm the EKG diagnosis.
 - Other findings include right axis deviation, taller R waves in the right precordial leads (V1-V3), and deeper S waves in the left precordials (V4-V6). The T wave is inverted in V1 (and often in V2).
- True posterior infarction may also cause a tall R wave in V1, but the T wave is usually upright, and there is usually some evidence of inferior infarction (ST-T changes or Qs in II, III, and AvF).







Left Ventricular Hypertrophy

- Caused by increased loads on the left ventricle.
- Etiologies include:
 - hypertension, aortic stenosis or regurgitation, mitral regurgitation
- Left ventricular hypertrophy (LVH) may be difficult to diagnose with certainty from the EKG.
 - Different scoring criteria have been recommended.
- One of the simplest uses five criteria, with the certainty of diagnosis based on the number of criteria present. If one is present, diagnose “possible LVH”; if two, “probable LVH”; if three are found, “definite LVH.”



Multiple LVH Criteria

LVH Criteria #1:

Increased limb lead QRS voltage: R in lead I plus S in lead III greater than 25 mm.

LVH Criteria #2:

Increased precordial QRS voltage: S in lead V1 plus R in either V5 or V6 greater than 35 mm.

LVH Criteria #3:

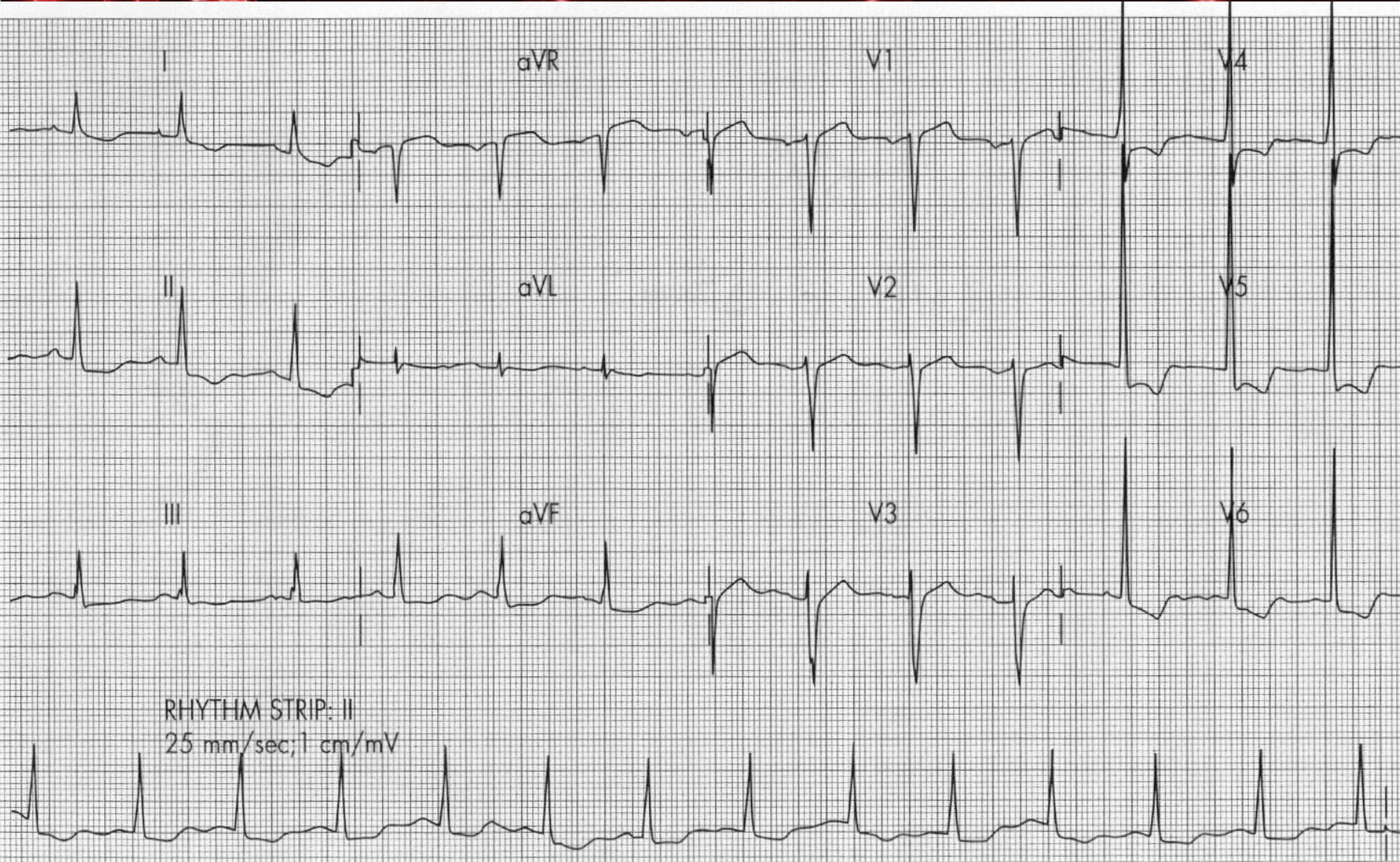
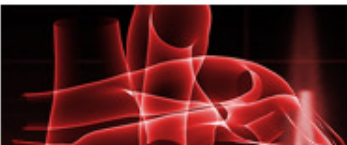
Typical ST and T abnormalities: ST depression or T wave inversion (or both) in the “lateral” leads (I, aVL, V4-V6)

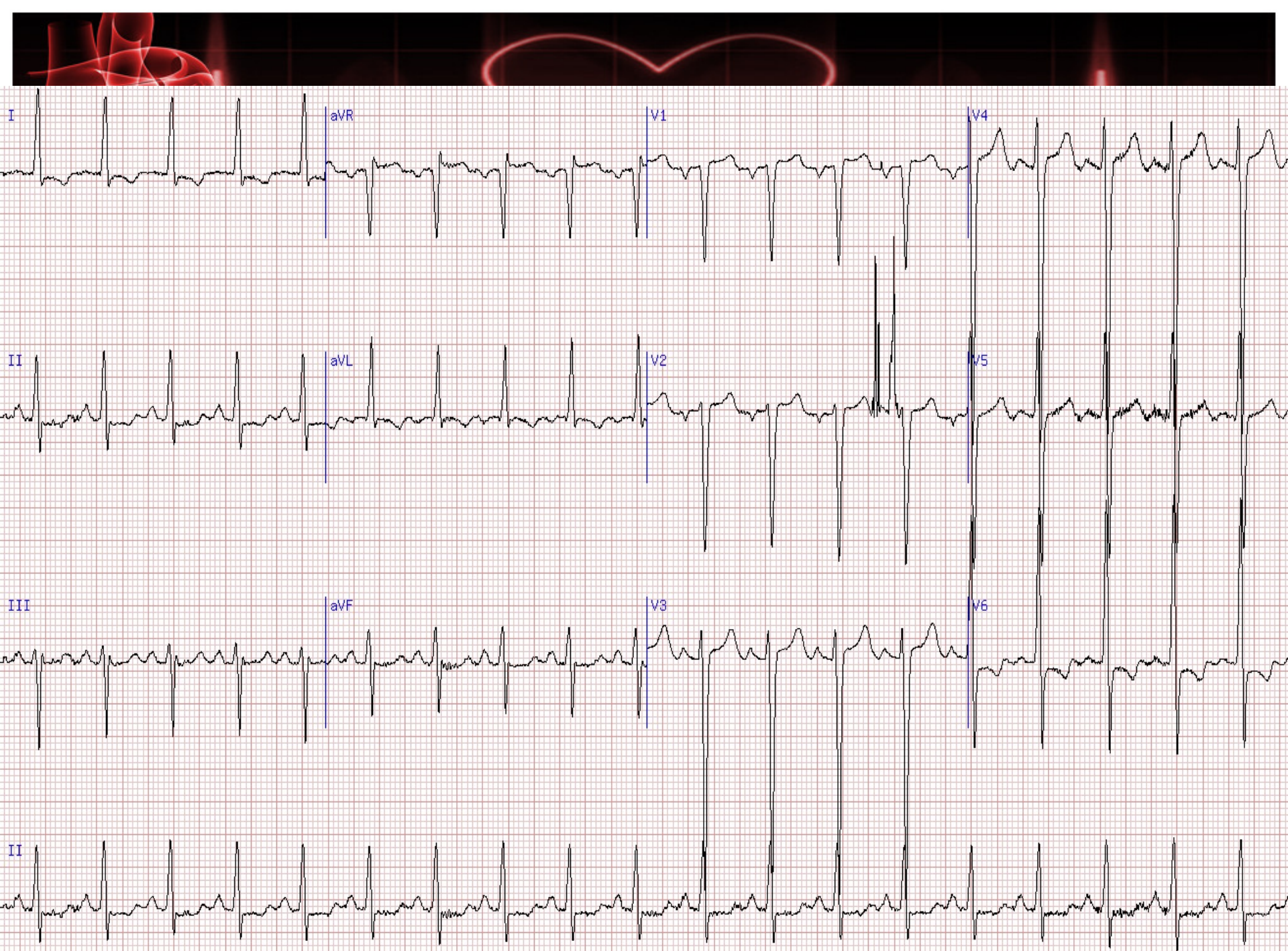
LVH Criteria #4:

Large leftward voltage: R wave in lead AVL greater than 11 mm.

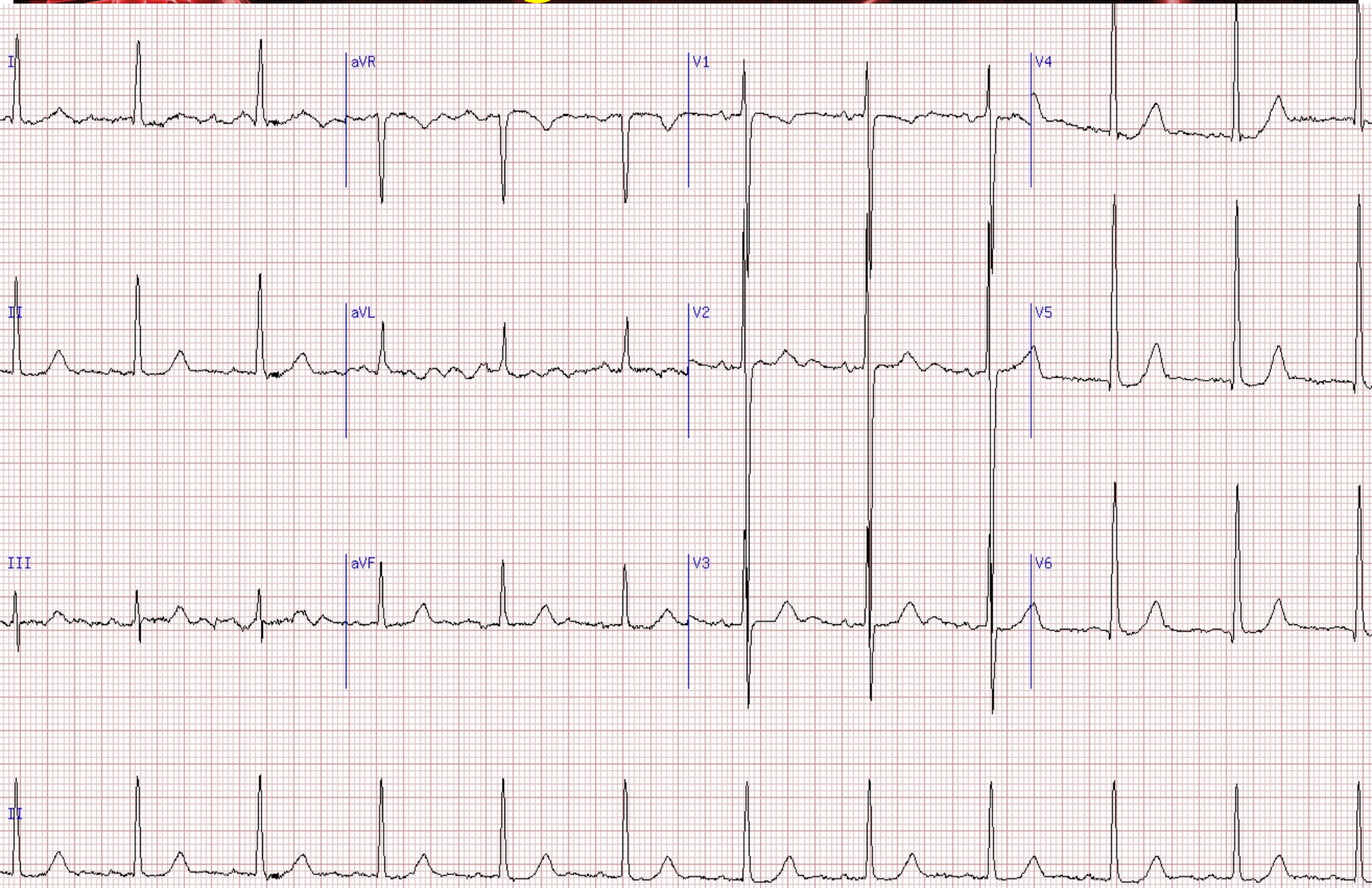
LVH Criteria #5:

Left atrial enlargement: Wide (greater than 0.11 msec) P wave. This criterion is used **IN SUPPORT** of the diagnosis, not alone.

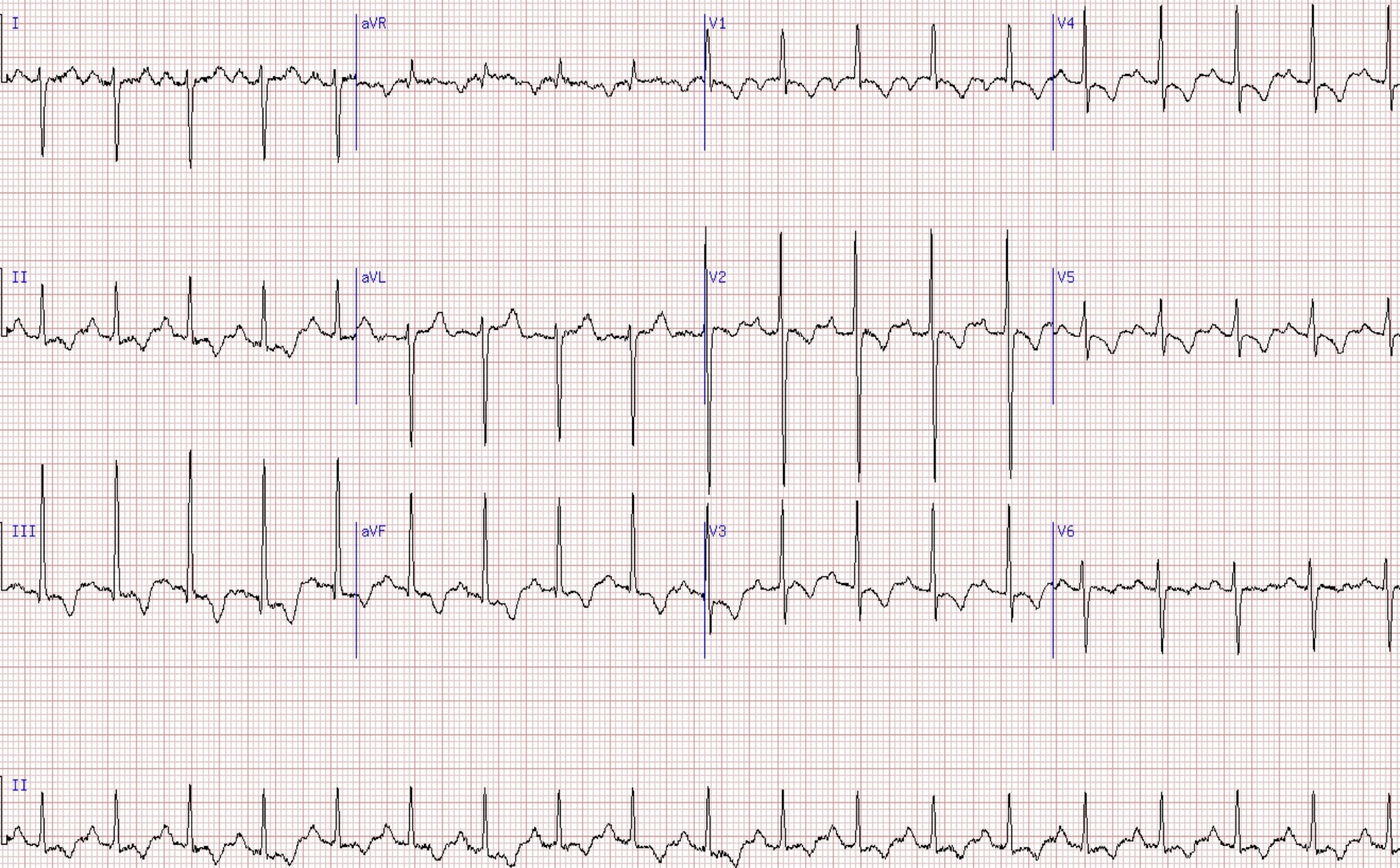




Right or Left?



Right or Left?





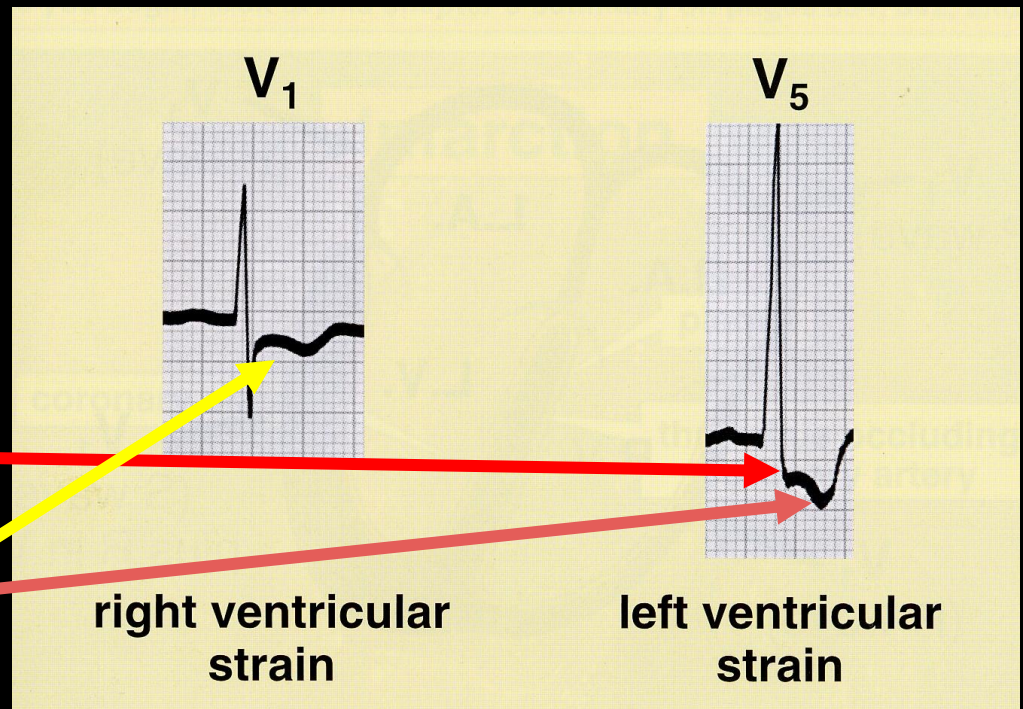
Strain in Hypertrophy

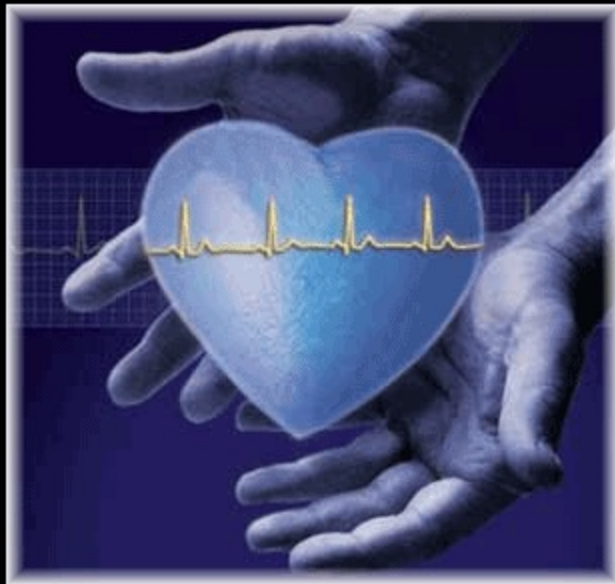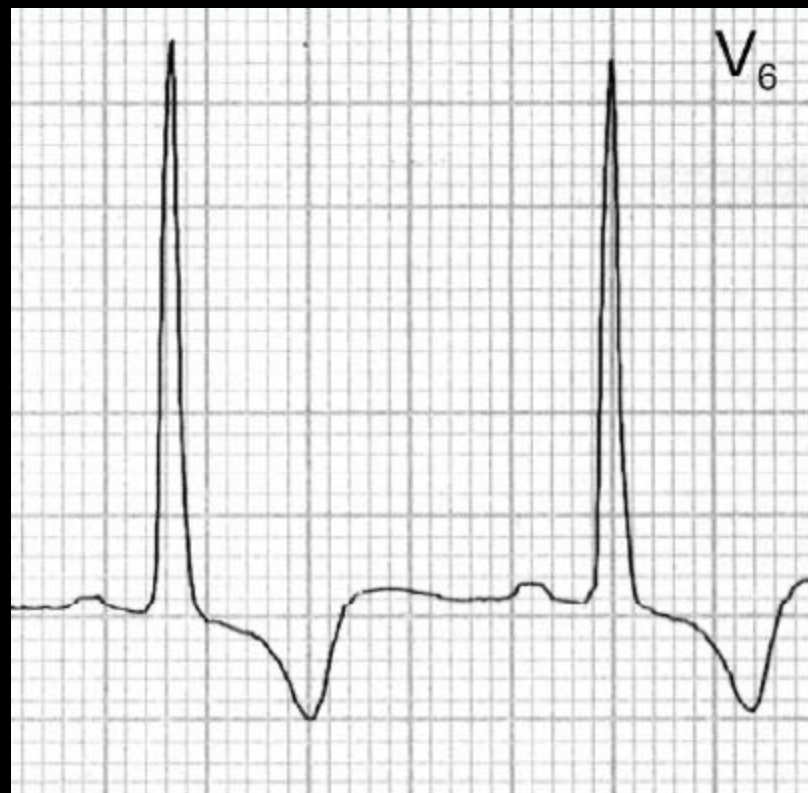
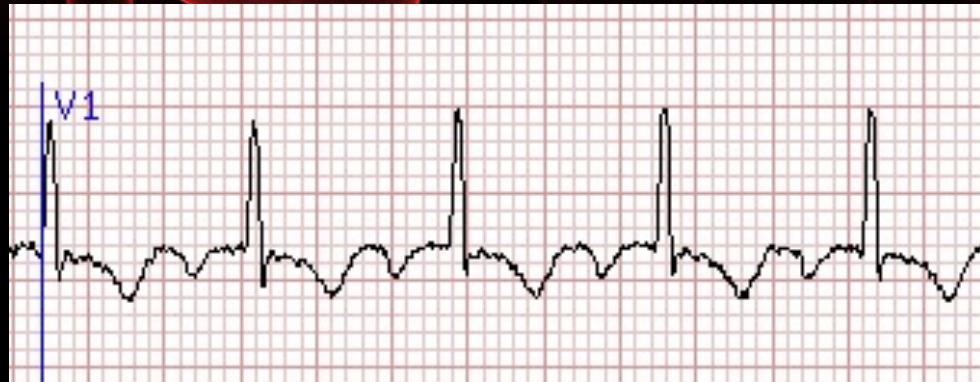- Strain is usually associated with ventricular hypertrophy since a ventricle that is straining against some kind of resistance will become hypertrophied in its attempt to compensate.
- Ventricular strain depresses the ST segment, which generally humps upward in the middle of the segment.

Strain

- Look for these changes when hypertrophy is present to determine if there is strain present:

- Downsloping ST segment & ST depression
- T-wave inversion

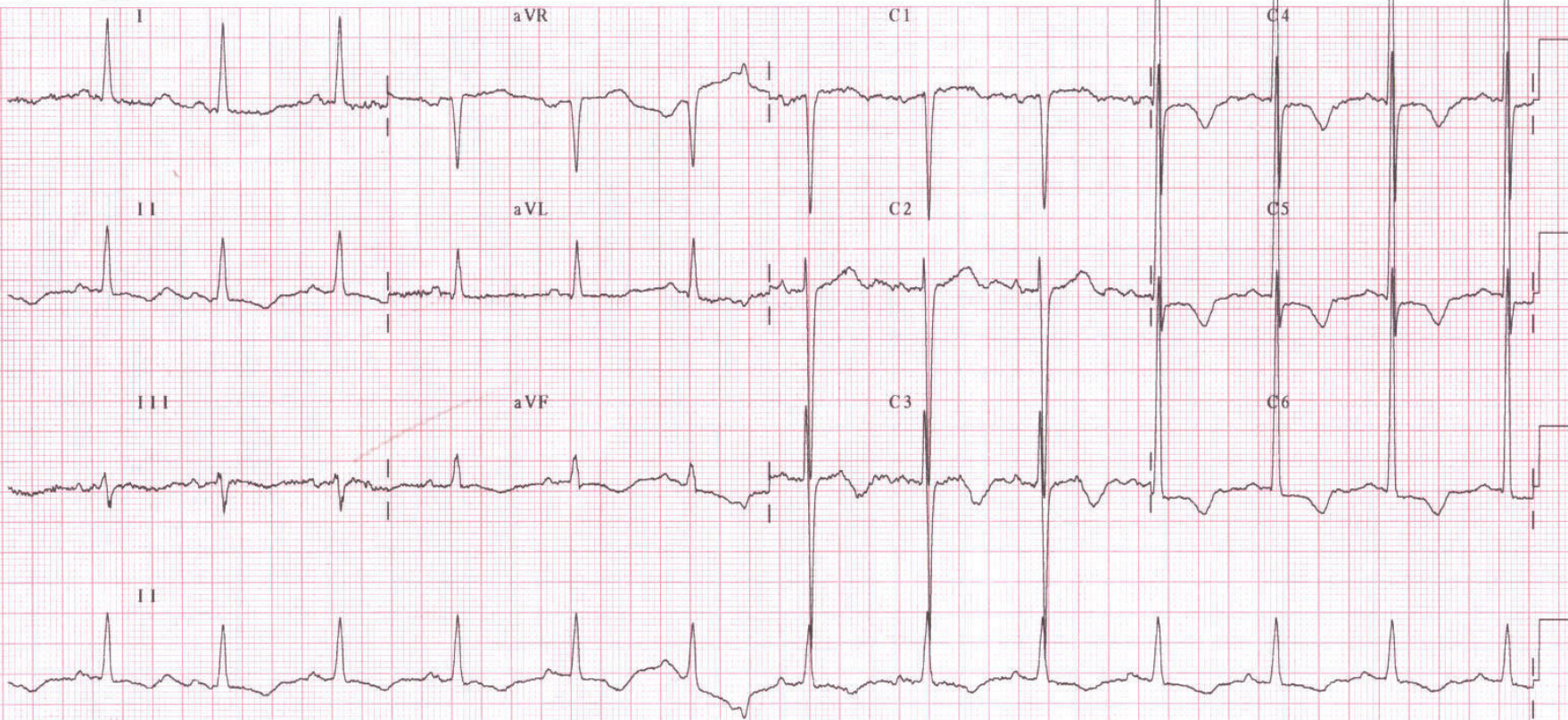




LVH with Strain

--Axis--

P 24
QRS 23
T 228





Summary

- **RVH Criteria**

R in V1 > 7 mm or > S wave

T in V1 inverted

Right axis deviation

S waves in V5-V6

- **LVH Criteria**

1) R-I + S-III > 25 mm

2) S-V1-2 + R-V5-6 > 35 mm

3) ST-Ts in left leads

4) R-L > 11 mm

5) LAE + other criteria

- Positive Criteria:

1=possible 2=probable

3=definite

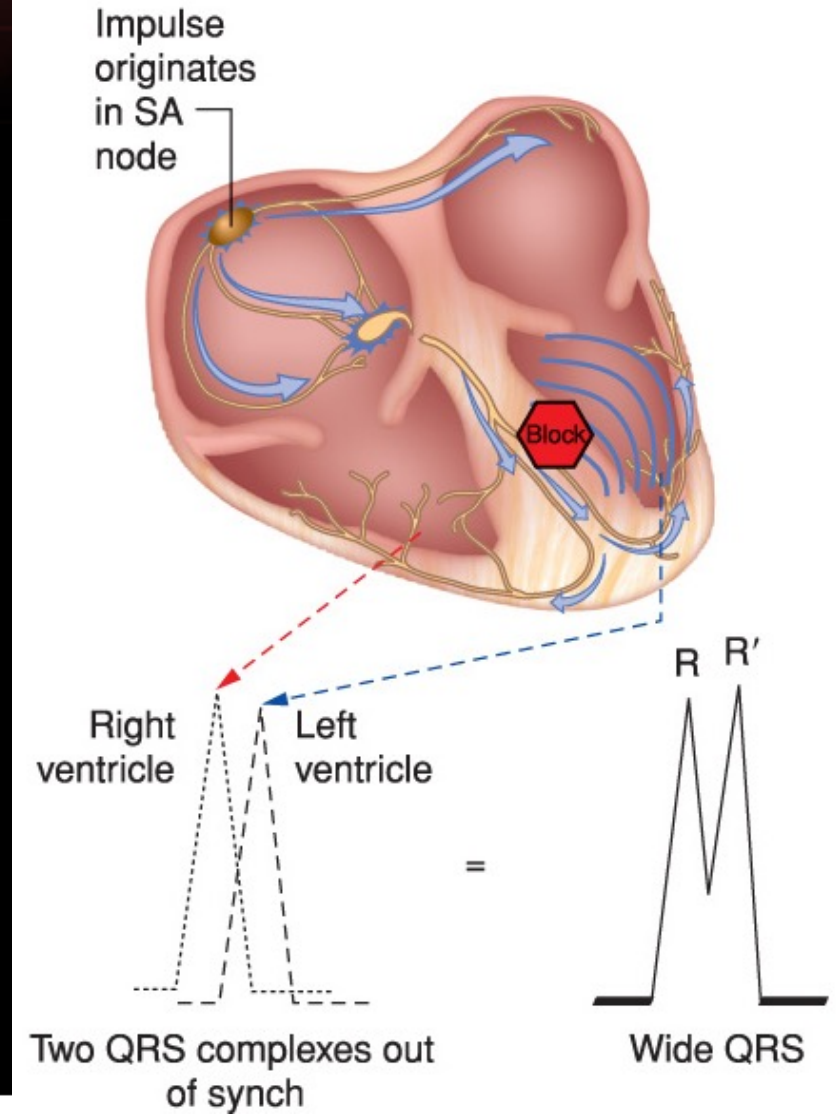


Bundle Branch Blocks

- All forms of bundle branch block involve delays or electrical blockages within the ventricles, they are all types of *intraventricular conduction deficits (IVCD)*. Bundle branch blocks may also be categorized as either partial (incomplete) or complete, depending on which patterns of electrical activity are detected on an EKG.
- When the criteria for BBB are partially met (e.g. < 0.12 sec), this is termed “incomplete bundle branch block”

Bundle Branch Block

- Widened QRS complex
- RR' configuration in chest leads





Risk factors and Etiologies of BBB

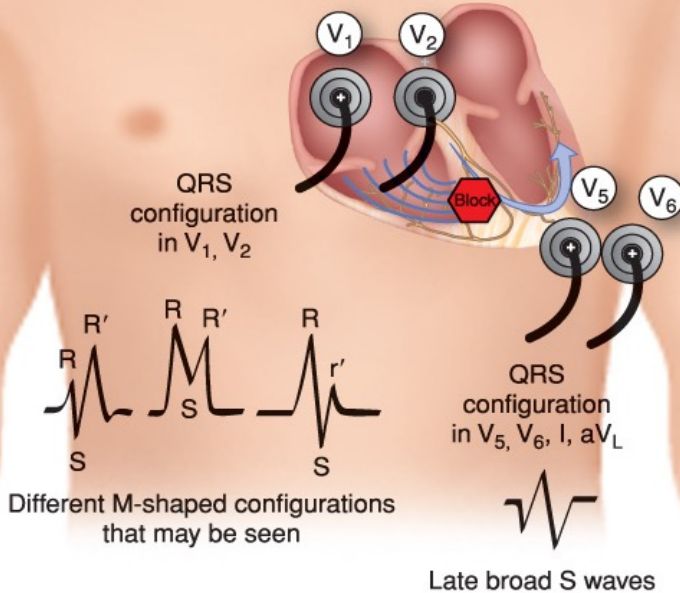
- Degenerative effects of aging
- Hypertension
- Past heart attack that damaged the heart muscle
- Past viral infection
- Valvular heart disease, particularly calcific aortic stenosis
- One of several heart or lung conditions that could have affected the ventricles (e.g., heart failure or COPD)
- Congenital condition
- Past injury to the chest



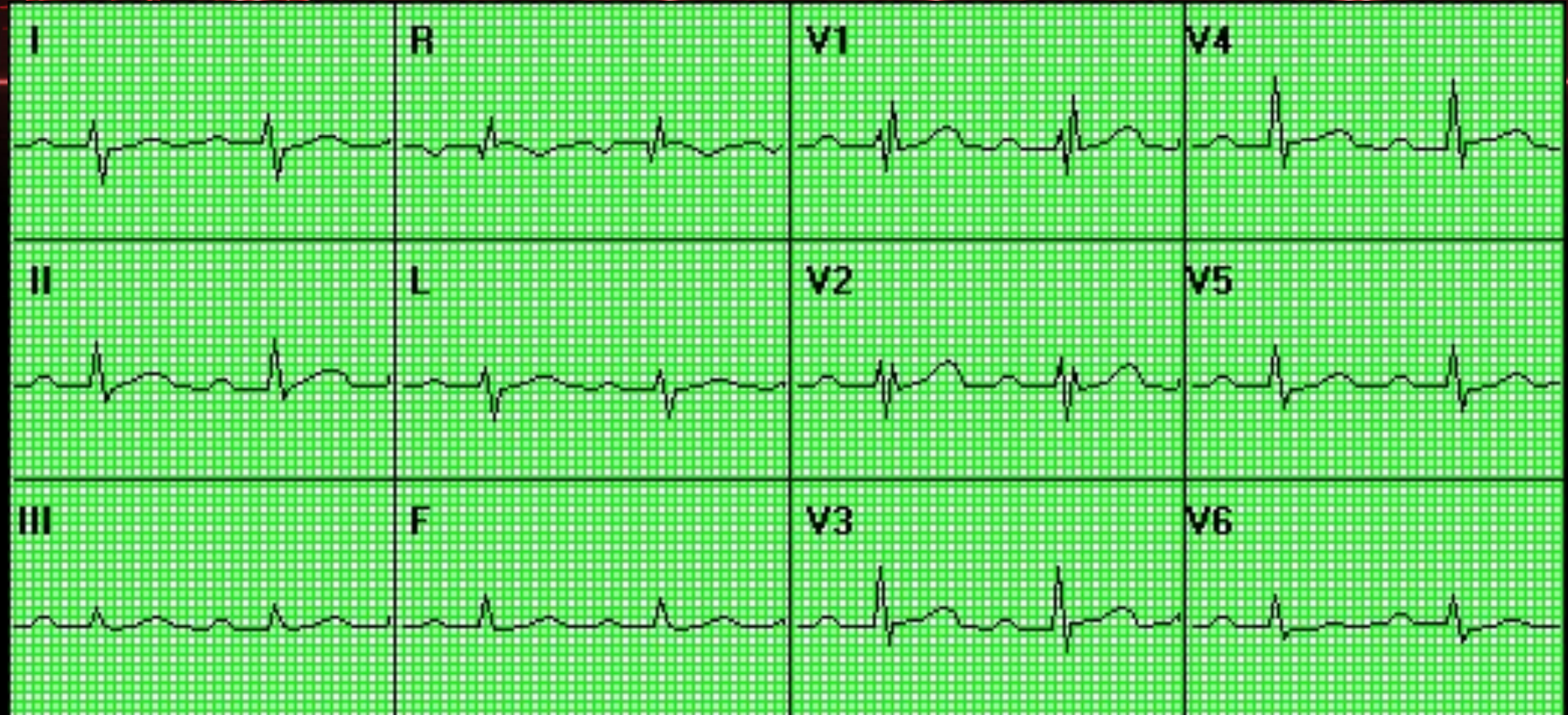
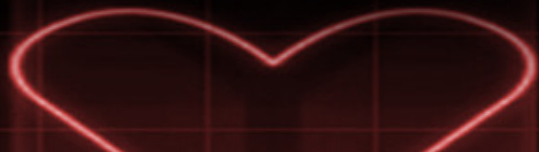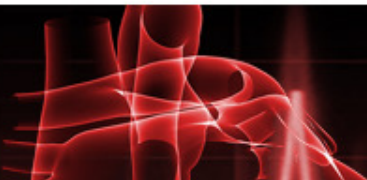
Right Bundle Branch Block

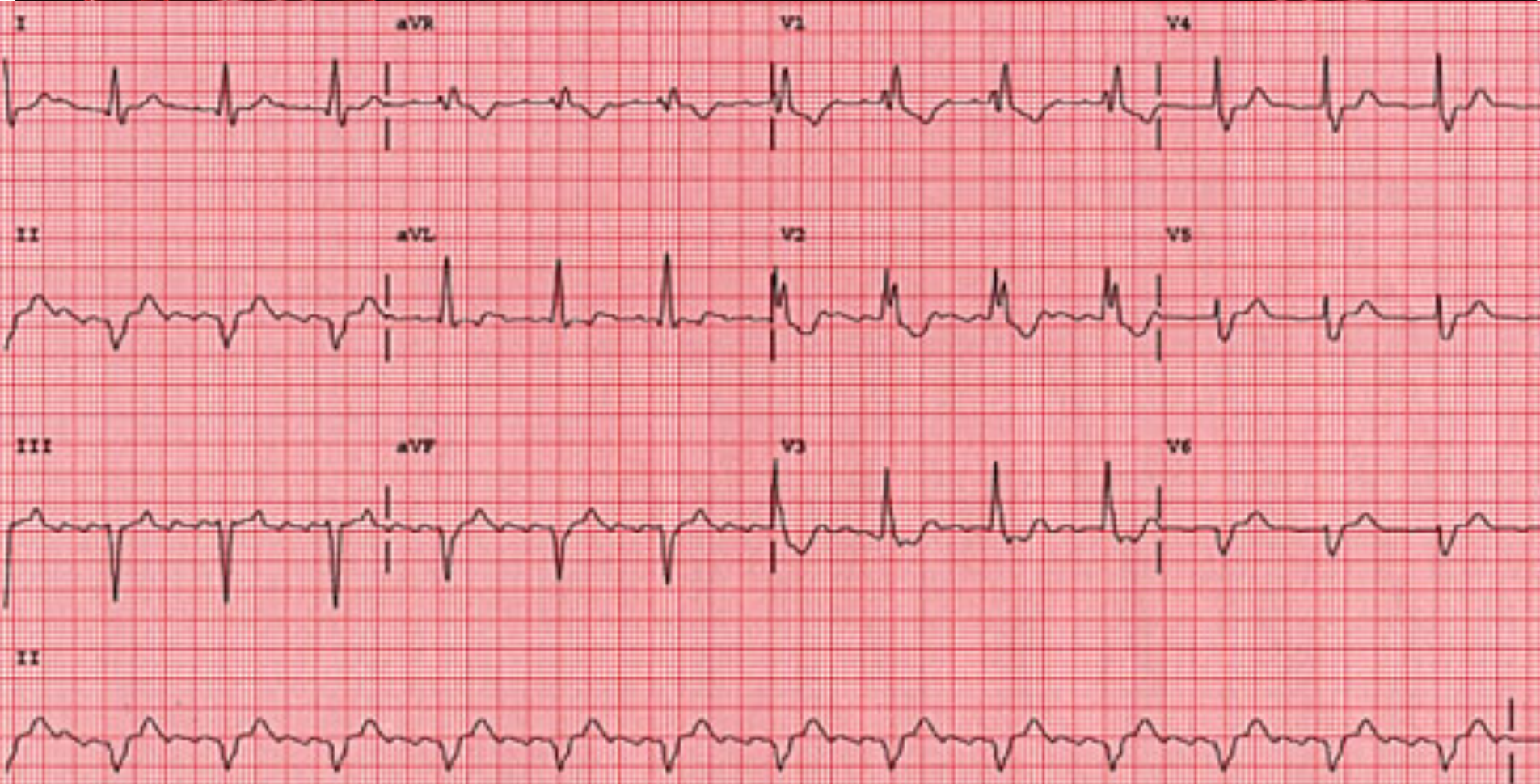

- When the right bundle branch is blocked, activation of the right ventricle begins when electrical activity “spills over” from the left ventricle. Depolarization of the right ventricle is delayed.
- The QRS is prolonged (over 0.10 sec) in right bundle branch block (RBBB). This extra length of the QRS is caused by late activation of the right ventricle, which is then seen after the left ventricle activity. Normally, right ventricle activity is not seen, as it is overshadowed by the larger left ventricle.
- In RBBB, a typical R_sR' wave occurs in lead V1. Also, a wide S wave is seen in leads I, V5, and V6, along with a broad R in lead R. When RBBB occurs in a patient with old or new septal infarction, the initial septal R wave may not be seen in lead V1. Instead, a wide QR complex is seen.

Right Bundle Branch Block



Look for RR' in leads V₁ or V₂





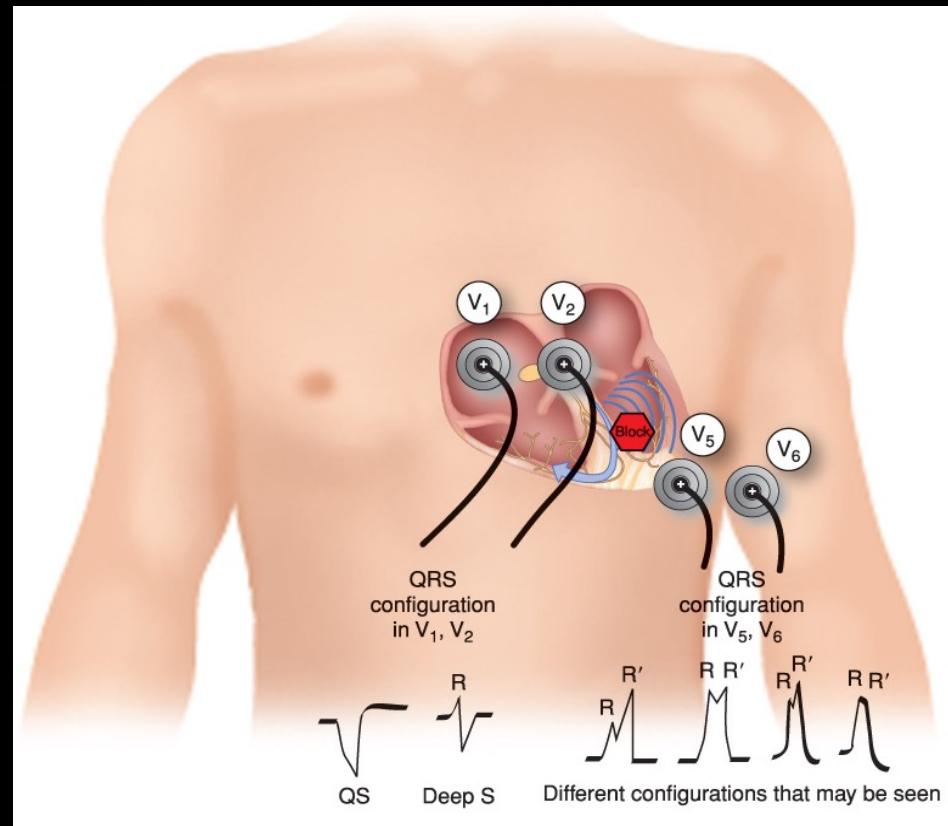


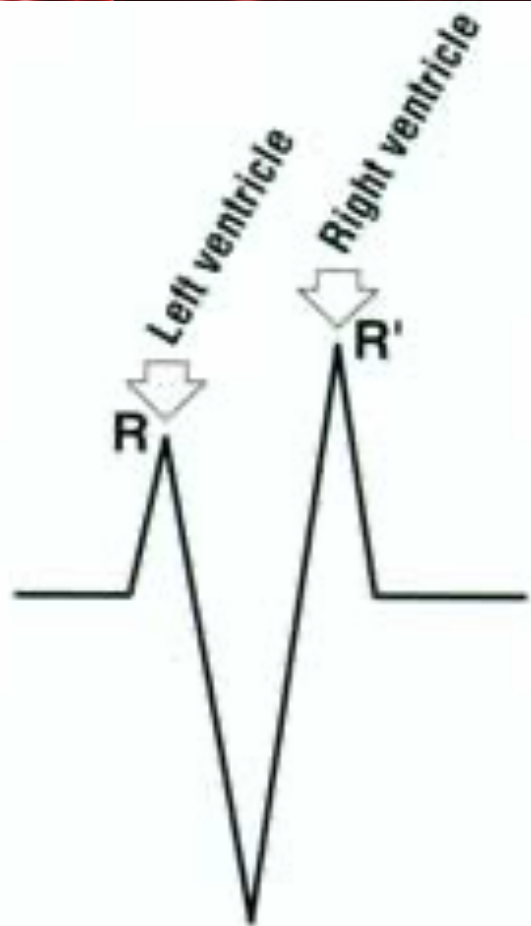
Left Bundle Branch Block

- LBBB usually indicates widespread cardiac disease. When the left bundle is blocked, activation of the left ventricle proceeds through the muscle tissue, resulting in a wide ($>.12$ msec) QRS complex.
- In left bundle branch blockage (LBBB), the QRS usually has the same general shape as the normal QRS, but is much wider and may be notched or deformed. Voltage (height of the QRS complex) may be higher.
- In LBBB, look for wide (possibly notched) R waves in I, L, or V5-V6, or deep broad S waves in V1-V3. There is left axis deviation. "Septal Q waves" sometimes seen in I, L, and V5-V6 disappear in LBBB.
- T waves in LBBB are usually oriented opposite the largest QRS deflection. That is, where large R waves are seen, T waves will be inverted. ST segment depression may occur.

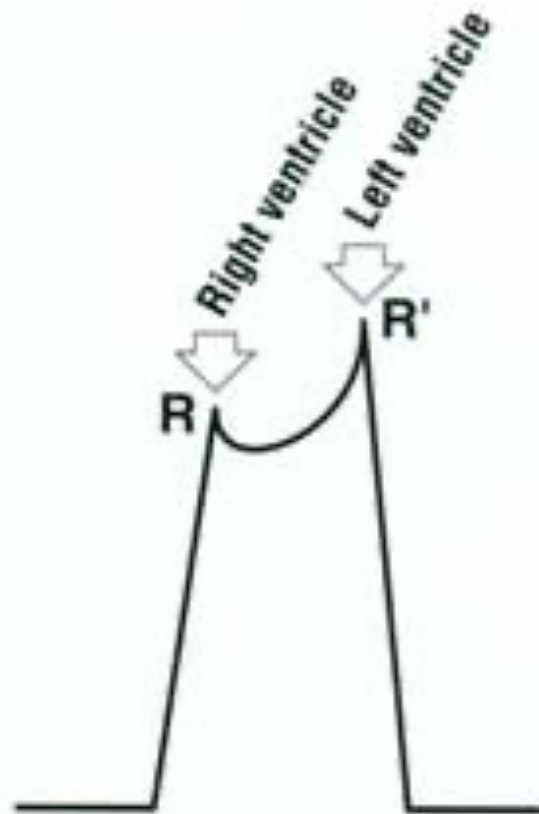
Left Bundle Branch Block

Look for RR' in leads
V₅ or V₆





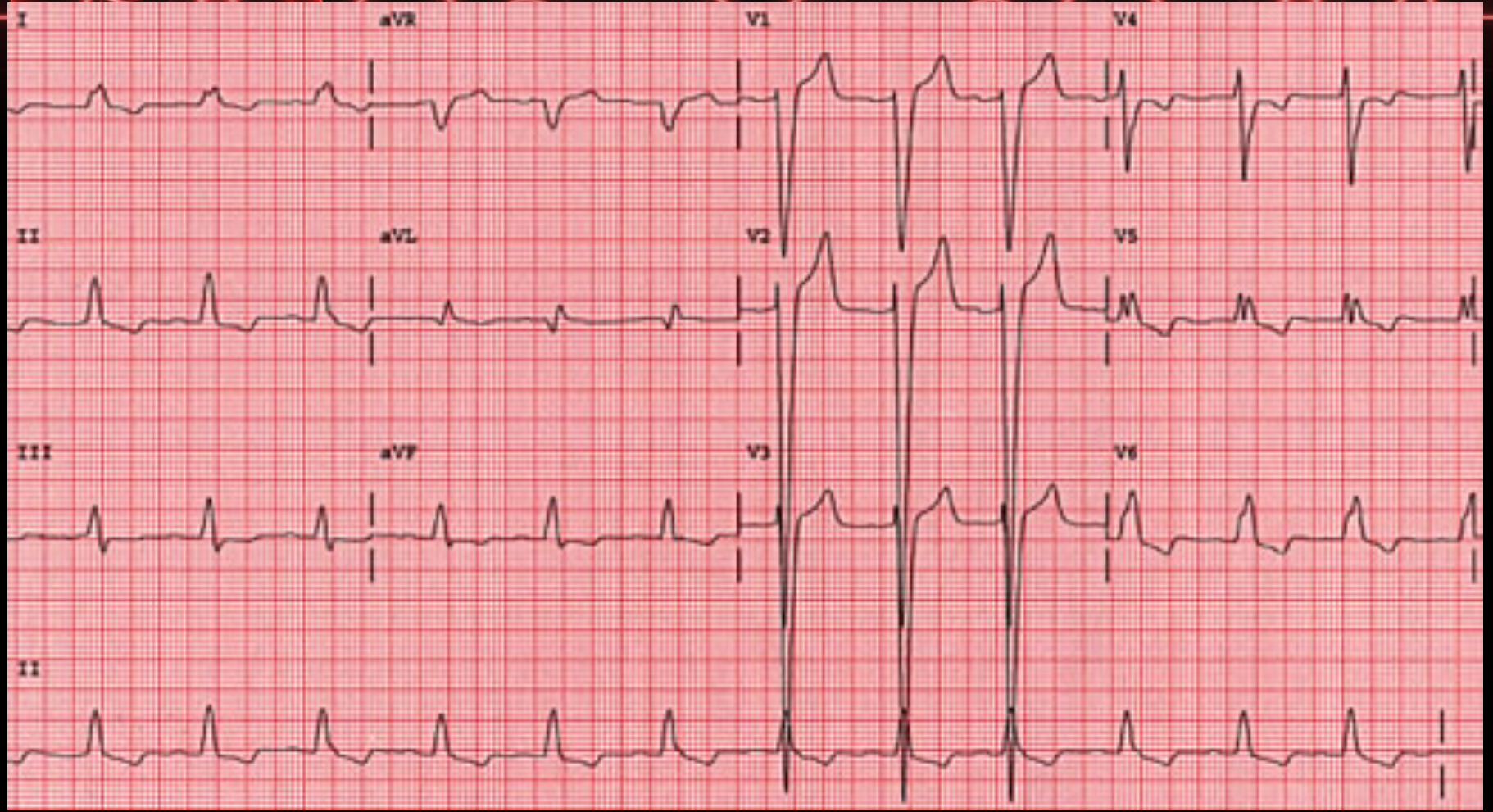
Right BBB

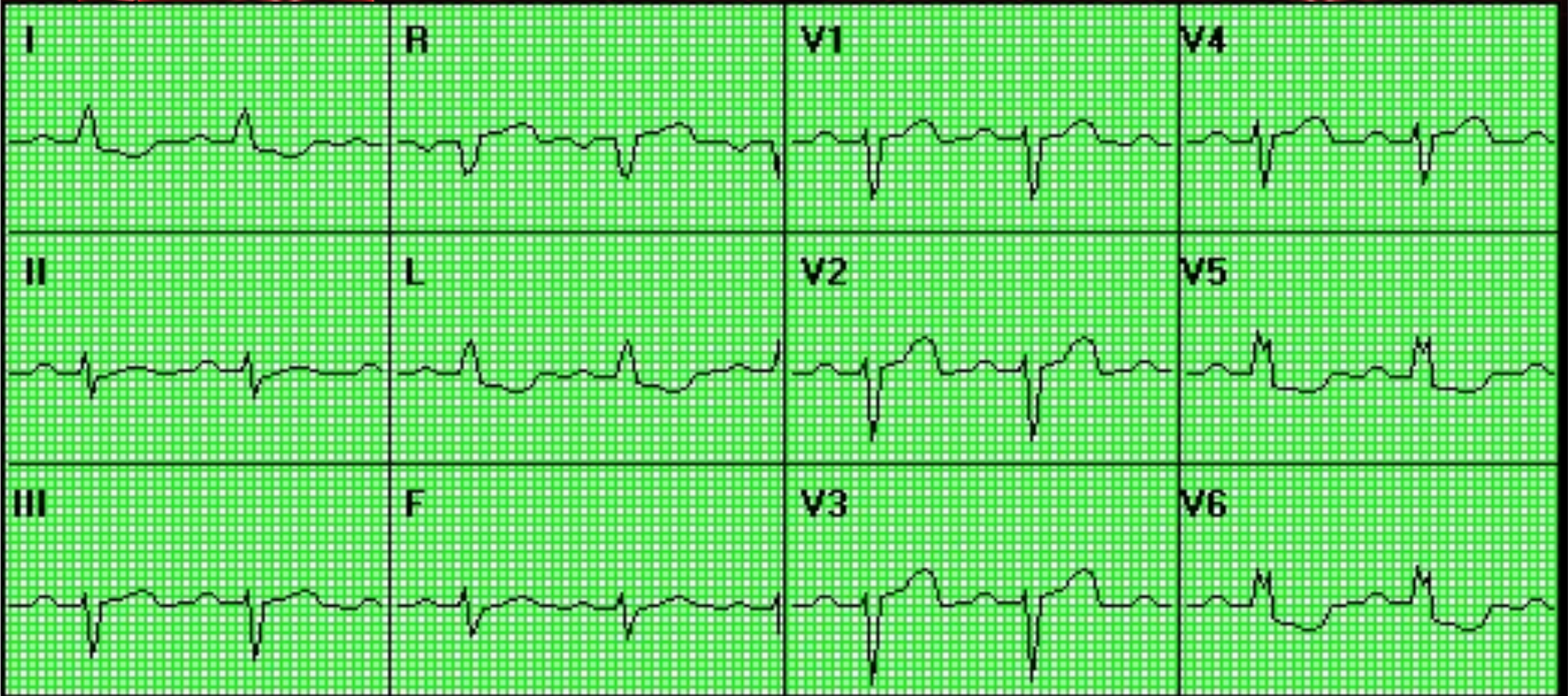


Left BBB

R and R' in Right and Left BBB often look like above

LBBB







Diagnosis of Infarction with BBB

- This is difficult, but not necessarily impossible. Look for ST-T wave changes or new Q waves in left-sided leads (I, aVL, V6) with LBBB.
- **New onset of LBBB is typically representative of an MI** which must be R/O.
- Evidence of infarction (Q waves, ST-T changes) is easier to see with RBBB.



EKG PEARLS

- **When you see a “normal” looking EKG on a test, start looking for:**
 - **Hyperkalemia :Peaked T waves**
 - **Hypokalemia : U waves**
 - **Hypomagnesimia : Prolonged QT**
 - **Hypercalcemia: Shortened QT**
 - **WPW : short PR, slurring of upstroke qrs**
 - **Hypothermia : Osborne J waves (notched downstroke QRS; reversed delta waves)**
 - **TCA overdose : S-tach, widening QRS, slurring of the terminal rS in aVR**
 - **Axis deviation & Hemiblocks : LAFB, LPFB**



EKG PEARLS

- **Usefulness of aVR & V1**
 - **Tall R wave in V1**
 - **Left main stem MI**
 - **RBBB**
 - **WPW**
 - **Posterior wall MI**
 - **Severe RV strain: PE, pneumothorax, severe COPD**
 - **aVR is normally flipped/negative polarity**
 - **Slurring terminal rS in TCA OD**
 - **PR elevation in pericarditis**
- **Diffuse ST elevation: think pericarditis**



More Practice Time



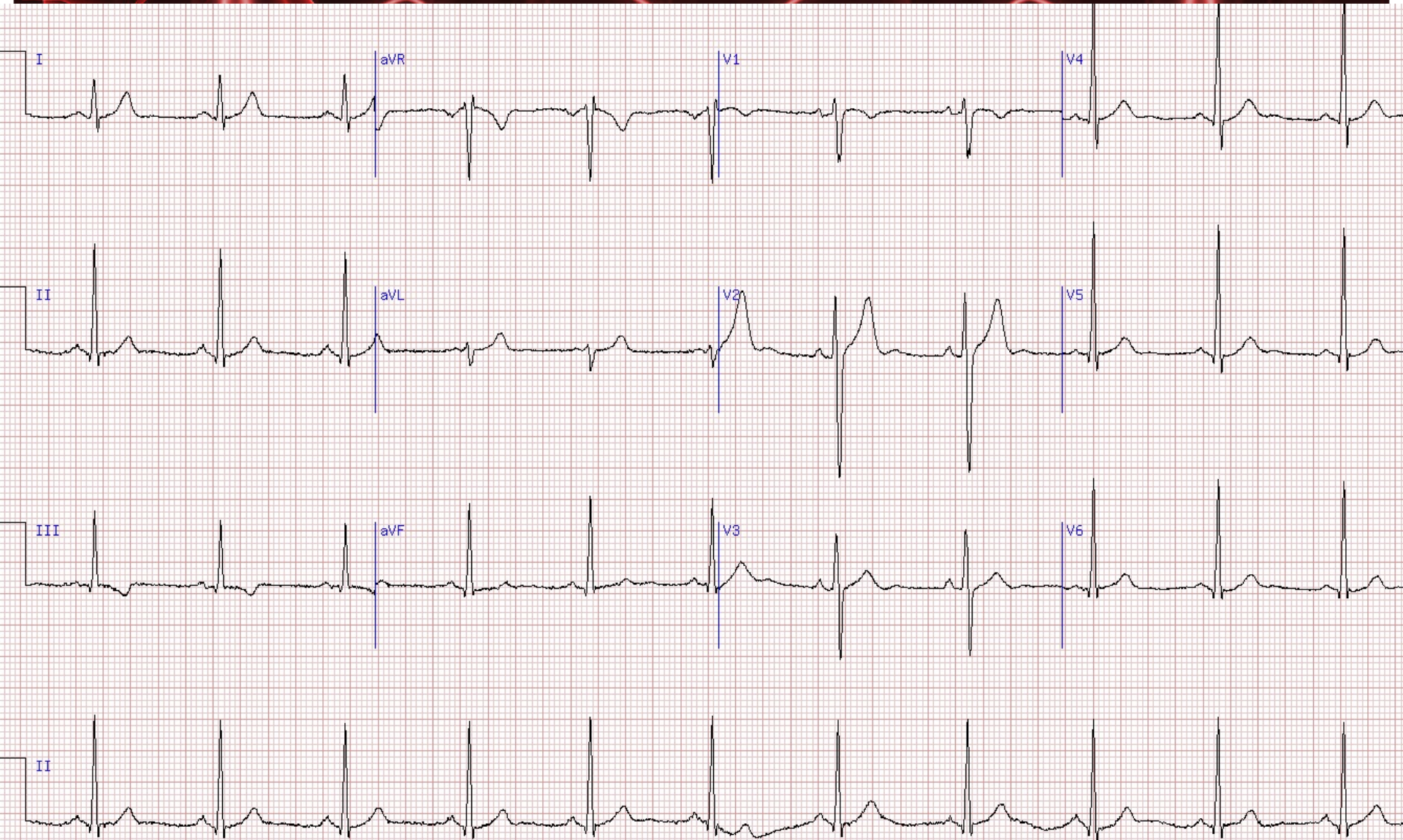


Take Home Pointers

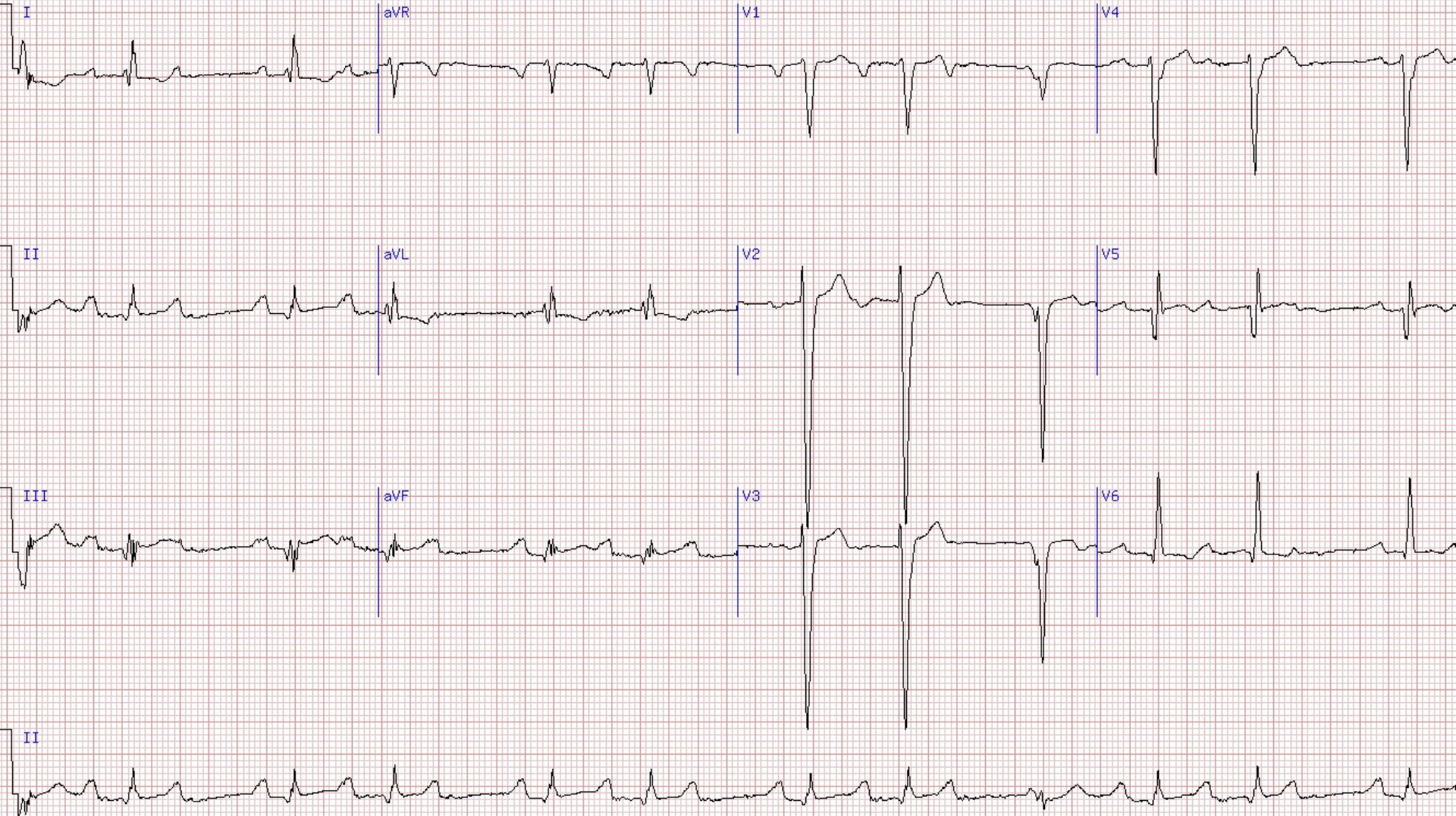
1. Use a Systematic Approach
 - a. Approach your analysis to the 12 lead EKG the same way every time.
2. Identify Lethal Rhythms first
3. Cover up the computer interpretation
4. Determine if the rhythm regular or irregular
5. Don't take forever trying to read the EKG
6. Look at every EKG you can to get more comfortable reading them

What Do you See?

Practice EKG 1

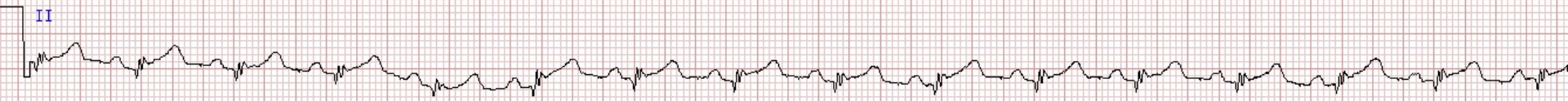
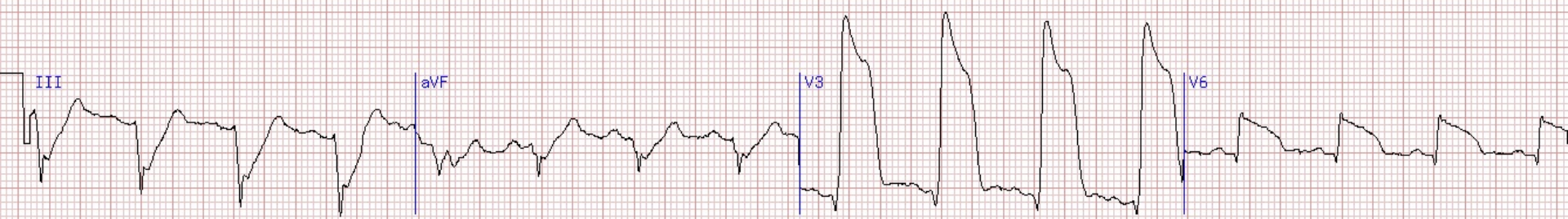
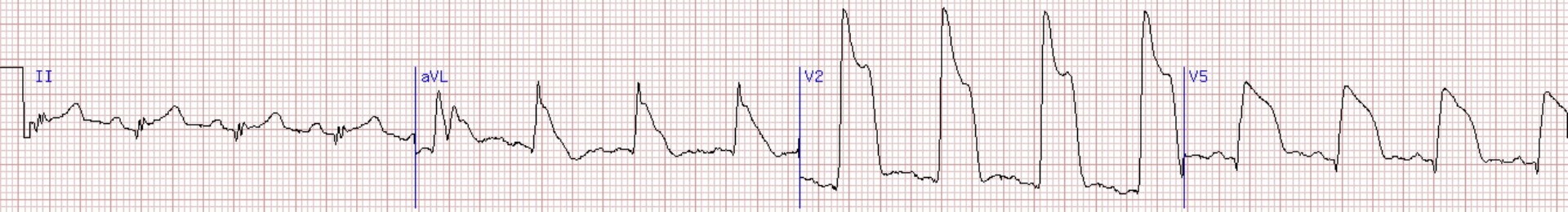
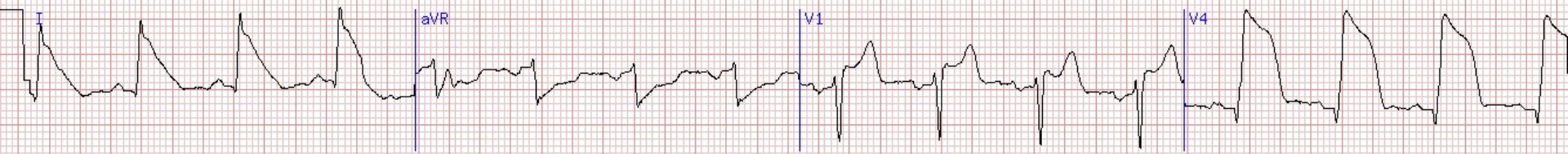

What Do you See?



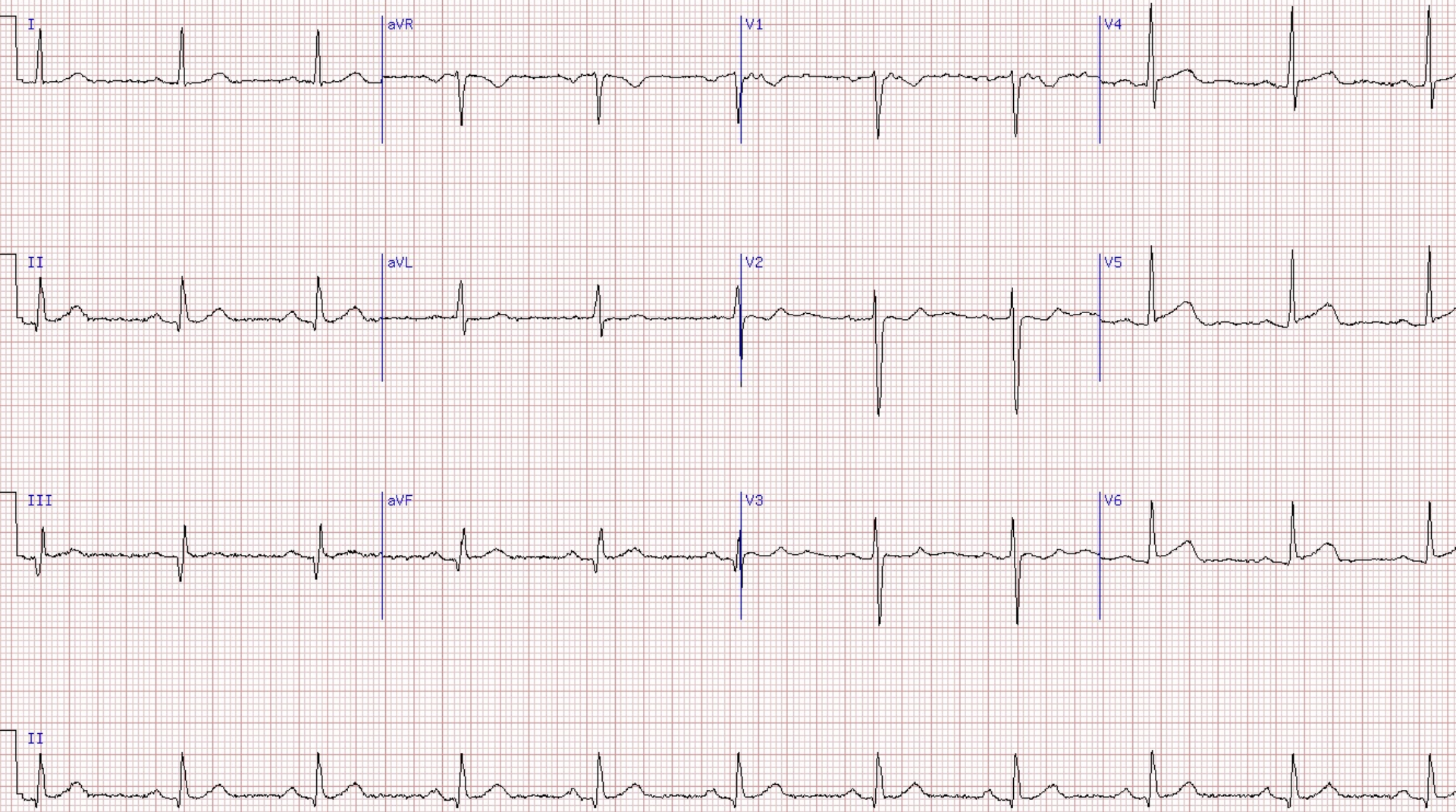


What Do you See?



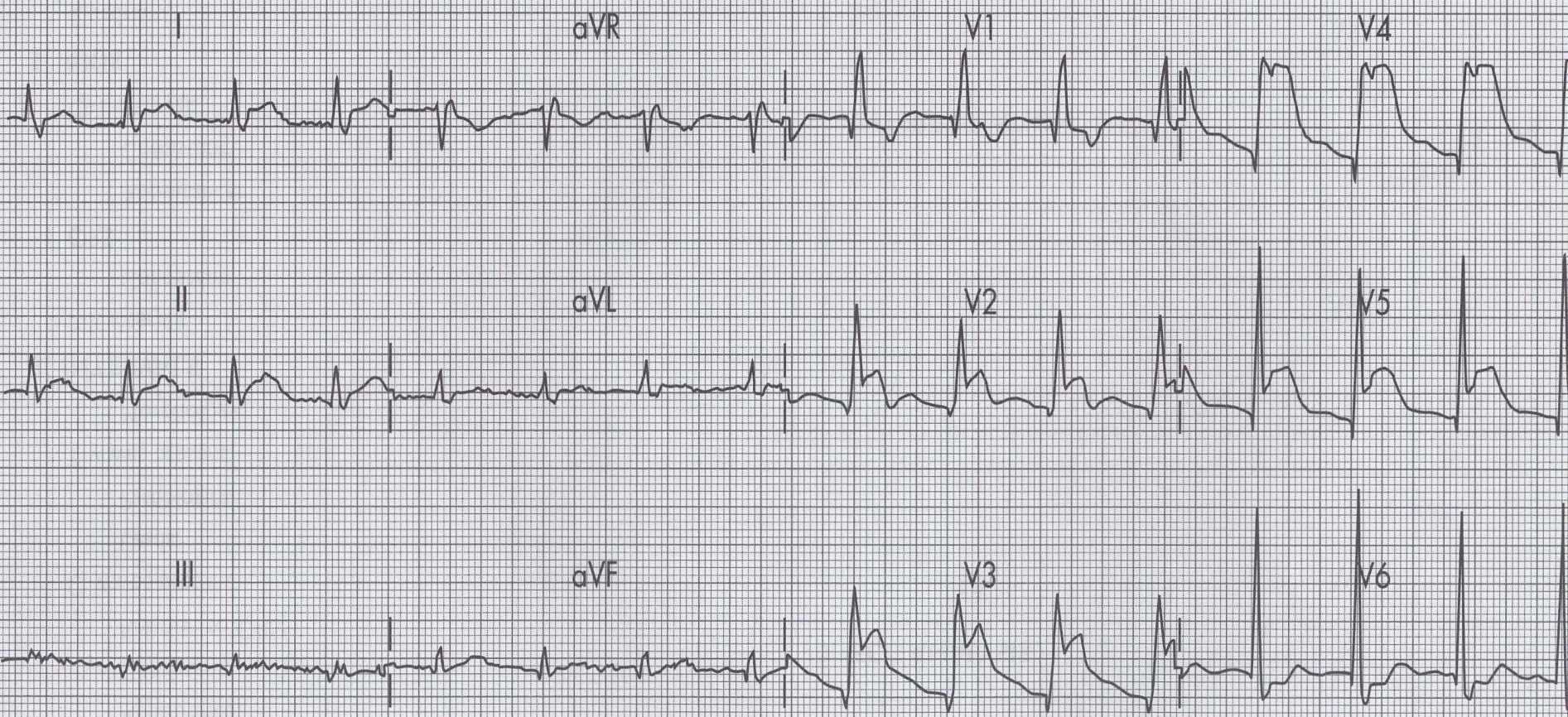
What Do you See?

Practice EKG 4

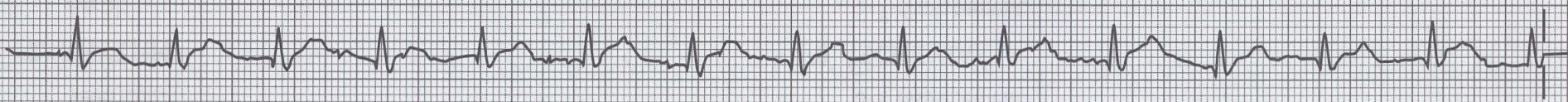

What Do you See?

Practice EKG 5

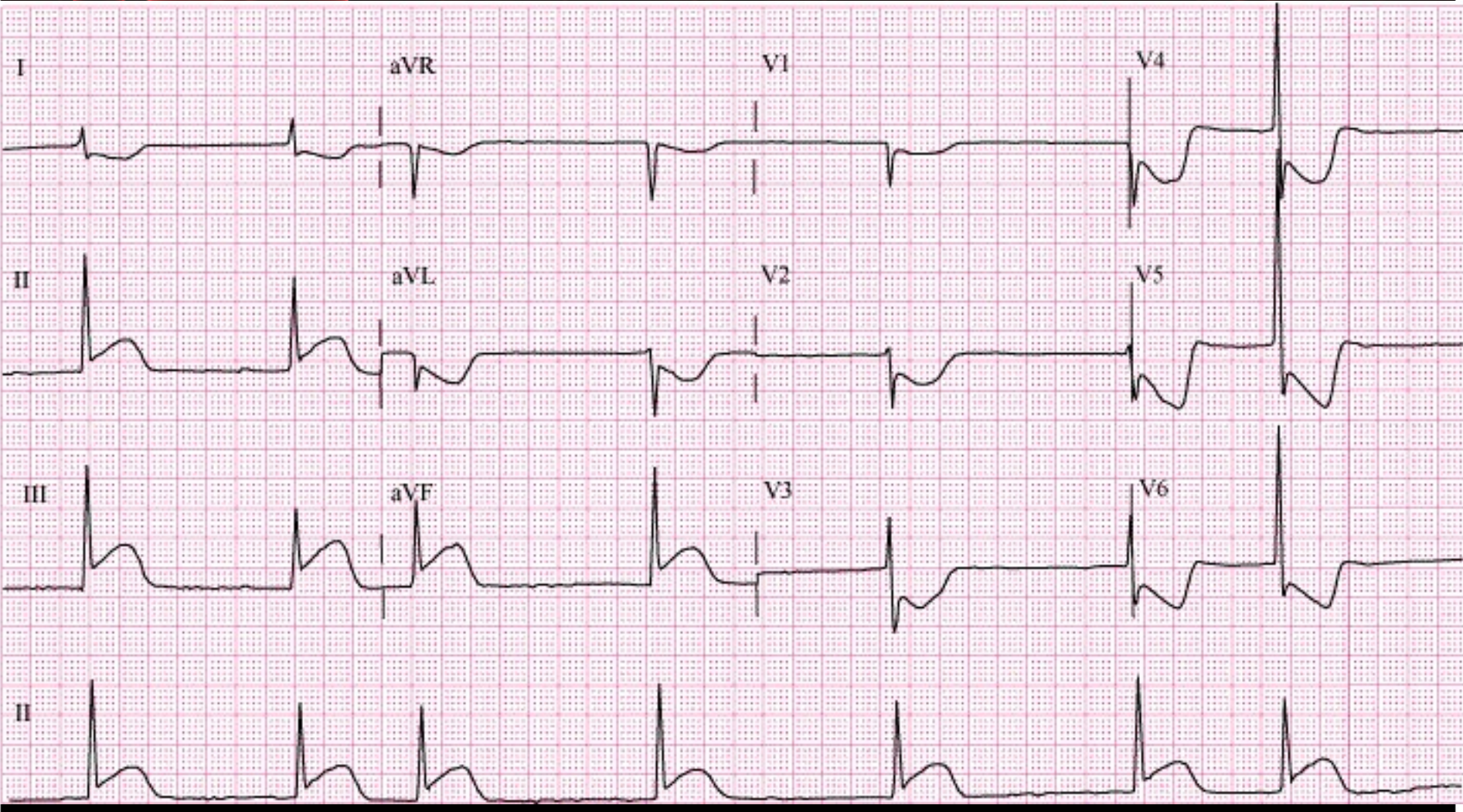


RHYTHM STRIP: II
25 mm/sec; 1 cm/mV



What Do you See?

Practice EKG 6





Questions????

SCHOOL IS OUT





References

- <https://litfl.com/ecg-library/ecg-references/>
- <https://www.uptodate.com/contents/ecg-tutorial-basic-principles-of-ecg-analysis>
- <https://www.healio.com/cardiology/learn-the-heart/ecg-review/ecg-interpretation-tutorial/stemi-mi-ecg-pattern>



If you would like further EKG information, send
me an email at:
benhwa@hotmail.com