

# Adhesive capsulitis: A review for clinicians

Monica Ricci, DMSc, PA-C

## ABSTRACT

Adhesive capsulitis, a common primary care and orthopedic diagnosis often referred to as frozen shoulder, is a painful inflammatory process that leads to a mechanical block in active and passive range of shoulder motion. Risk factors include diabetes and thyroid dysfunction. Diagnosis is made based on physical examination, but can be augmented by diagnostic imaging. Nonsurgical management is the mainstay of treatment because the disease is self-limiting. However, some patients may need surgical intervention.

**Keywords:** adhesive capsulitis, shoulder, orthopedic, frozen, range of motion, physical therapy

## Learning objectives

- Summarize the pathologic basis of adhesive capsulitis of the shoulder.
- Recognize when a patient is at increased risk for adhesive capsulitis of the shoulder.
- Understand the treatment options available for patients with adhesive capsulitis.

Adhesive capsulitis is a common primary care and orthopedic diagnosis and often is referred to as *frozen shoulder*. This painful inflammatory process leads to a mechanical block in active and passive range of motion (ROM) of the shoulder. This article reviews the pathology, risk factors, diagnosis, and management of adhesive capsulitis and when patients may need to be referred for surgical intervention.

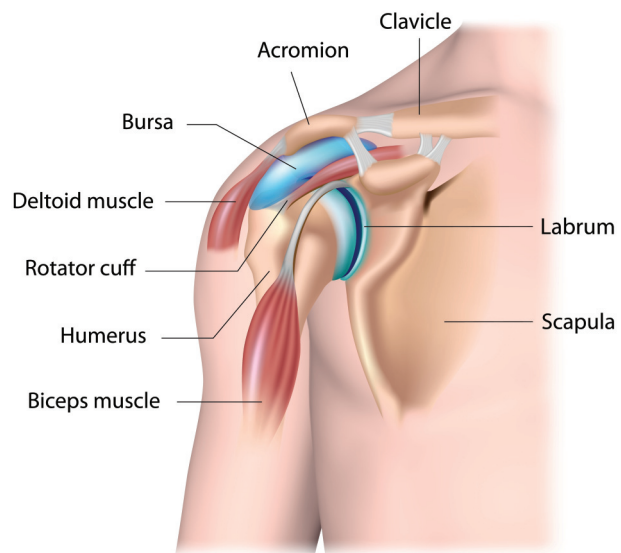
## PATHOLOGY

The main joint of the shoulder, the glenohumeral joint, is a ball-and-socket joint that exhibits more ROM than any other type of synovial joint (Figure 1). The glenohumeral joint is held together by static stabilizers (including the capsule, ligaments, and bony conformity) and dynamic stabilizers (muscles). To provide active movement to the

Monica Ricci practices in orthopedic surgery and sports medicine at Arthritis and Sports Orthopaedics in Sterling, Va. The author has disclosed no potential conflicts of interest, financial or otherwise.

DOI:10.1097/01.JAA.0000800236.81700.d4

Copyright © 2021 American Academy of PAs



© ALILA MEDICAL MEDIA/SHUTTERSTOCK.COM

FIGURE 1. Shoulder anatomy

upper limb, these muscles contract, placing force on the bones and allowing shoulder flexion, extension, abduction, adduction, and rotation. Passive ROM refers to the same movements, but instead of internal force of the muscles firing, the movement is created by an outside force such as another person moving the arm for the patient.

Adhesive capsulitis of the shoulder is characterized by functional loss of passive and active shoulder motion. This inflammatory process results in fibroblastic proliferation and extensive scar tissue formation. Fibroblastic proliferation, a late phase of the inflammatory process involved in tissue repair, leads to thickening, fibrosis, and adhesion of the capsule to itself and the humerus.

The disease course falls into three stages (Figure 2). The inflammatory response may be idiopathic, but often begins as a result of soft-tissue damage, such as a minor injury or surgery.

- *Freezing* refers to the progressive stiffening and mechanical loss of ROM exhibited by the patient. The freezing phase involves thickening and fibrosis of soft tissue and is associated with the most pain. Patients often will complain that their pain is the worst at night.

- The *frozen* stage includes peak shoulder stiffness. The hallmark of a frozen shoulder is loss of passive and active ROM.

**Key points**

- Adhesive capsulitis is an inflammatory process of the shoulder that results in painful decreased ROM.
- Risk factors for adhesive capsulitis include diabetes and hormone imbalances.
- Adhesive capsulitis is a self-limiting disease and most commonly resolves over time.
- Patients with adhesive capsulitis can experience severe discomfort that can be treated with physical therapy and intra-articular shoulder injections.

- *Thawing* is when the patient's ROM begins to return. On average, these three stages of adhesive capsulitis span 1 year of a patient's life.

**RISK FACTORS**

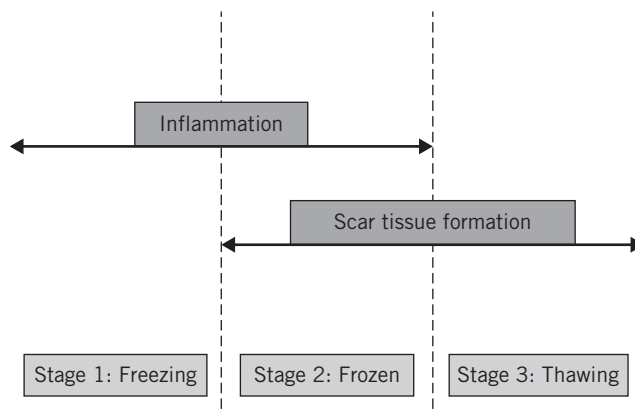
Adhesive capsulitis often is an idiopathic inflammatory condition, but risk factors have also been identified. The prevalence of adhesive capsulitis is 2% to 5%; it primarily affects patients ages 40 to 60 years.<sup>1</sup> For unknown reasons, most affected patients are postmenopausal women. Systemic risk factors include diabetes, hypothyroidism, hyperthyroidism, hypoadrenalism, or any other hormone imbalances.<sup>1</sup>

A recent study found that fasting glucose levels below 85 mg/dL were significantly negatively associated with adhesive capsulitis; levels over 90 mg/dL were significantly positively associated with the diagnosis.<sup>2</sup> Another study found that inflammatory markers such as an elevated C-reactive protein caused by dyslipidemia, insulin resistance, or hyperglycemia can be independent risk factors for adhesive capsulitis.<sup>3</sup> A case-controlled study summarized by the American Academy of Orthopaedic Surgeons (AAOS) found that patients with diabetes developed adhesive capsulitis at younger ages than patients without diabetes.<sup>1</sup>

Intrinsic risk factors include underlying damage to tendons from overuse such as rotator cuff tendon tears, biceps tendon tears, or tendonitis.<sup>1</sup> Extrinsic factors include previous shoulder surgery, cervical disk disease, or previous upper extremity fracture. These factors cause tissue damage that triggers an inflammatory process in the shoulder.<sup>1</sup> In the study summarized by the AAOS, 505 patients undergoing elective shoulder surgery (an example of an extrinsic risk factor) were followed postoperatively.<sup>1</sup> At 6-month follow-up, 11% of the patients were diagnosed with adhesive capsulitis.<sup>1</sup>

**PHYSICAL EXAMINATION**

The most common chief complaints of patients with adhesive capsulitis are shoulder stiffness and shoulder and upper arm pain that often radiates down the arm. Other complaints can range from muscle spasms to a generalized ache difficult to pinpoint. Significant findings on physical examination include painful decreased passive and painful decreased active ROM.



**FIGURE 2.** Stages of adhesive capsulitis

Most patients have significant reduction in at least two planes of passive and active ROM compared with the unaffected side. Specifically, the loss of passive ROM is what differentiates this disease from others such as rotator cuff pathologies. Internal and external rotation are often the first motions a patient loses and the last motions that return.

**DIAGNOSTICS**

If the patient is exhibiting moderate to severe pain and stiffness, completing a comprehensive and diagnostic physical examination may be difficult. For these patients, diagnostic testing may include radiographs and MRI. Radiographs can be used to rule out osteoarthritis, calcific tendonitis, or other causes of mechanical blocks in motion in patients with reduced shoulder ROM. An MRI may be used to assess the surrounding soft tissue for tendonitis or tears that can contribute to inflammation. MRI also can be used to contribute to the clinical picture of a patient with adhesive capsulitis. Findings on MRI include joint capsule thickening, synovial hypertrophy, abnormal hyperintensity and variable enhancement of the capsule and synovium, and/or low T2 signal due to scar tissue formation at the rotator interval.<sup>1</sup>

**TREATMENT**

Options for nonsurgical management include physical therapy, anti-inflammatory medications, and intra-articular injections. Although physical therapy is the mainstay of nonsurgical management, oral nonsteroidal anti-inflammatories (NSAIDs) or a tapered course of corticosteroids can be helpful in reducing patients' discomfort enough to make physical therapy tolerable.<sup>1</sup> Mobilization with physical therapy not only reduces pain, but improves function and ROM.<sup>1</sup>

Corticosteroid injections have been shown to be most effective during the early stage of the disease. In a double-blind controlled randomized study, patients who had corticosteroid injections had a notable decrease in shoulder pain at 6 weeks, compared with patients who received

placebo injections.<sup>4</sup> Likewise, in a study of 106 patients, four intra-articular corticosteroid injections were given over 8 weeks. The patients who received physical therapy and injections had more relief than those who received physical therapy alone.<sup>5</sup> When anti-inflammatories are combined with physical therapy, patients will most likely have the best outcome.

Platelet-rich plasma (PRP) therapy involves injecting a concentration of a patient's platelets into joints with the goal of accelerating the healing process of injured soft tissue. A recent triple-blind randomized controlled trial of 32 patients with adhesive capsulitis concluded that those given the PRP injections had greater improvement in pain and disability than those who received placebo.<sup>6</sup> Participants in this study were administered PRP 3 to 9 months after symptom onset. Further studies would aid in confirming when PRP is most effective. Overall, this technique has become recognized as a valid nonoperative management option.

Nearly 90% of patients with adhesive capsulitis have symptom resolution with nonsurgical management, but if nonsurgical management has failed to provide relief of symptoms after 9 months to 1 year, the condition is considered refractory and surgical intervention is indicated.<sup>1</sup> In a retrospective study, 98 patients with adhesive capsulitis were followed throughout their treatment.<sup>7</sup> Of these, 89.5% patients had a full recovery with nonoperative treatment. No significant risk factors for refractory adhesive capsulitis were identified.<sup>7</sup> Surgical intervention can include manipulation under anesthesia, a noninvasive procedure designed to relieve pain and break up excessive scar tissue, or arthroscopic capsular release, a minimally invasive surgery in which a probe is used to cut capsule tissue that surrounds the glenohumeral joint. Many studies show that manipulation under anesthesia is equivalent to capsular release in relief of clinical symptoms.<sup>8</sup> A systematic review of 22 studies assessed outcomes for patients treated with manipulation under anesthesia, capsular release, or a combination of both.<sup>8</sup> Researchers concluded that capsular release instead of manipulation under anesthesia, or in addition to it, had little benefit.<sup>8</sup> In a smaller, more recent study of 60 patients with refractory adhesive capsulitis, half underwent manipulation under anesthesia and the other half had capsular release.<sup>9</sup> Patients were evaluated preoperatively and at 3, 6, and 12 months postoperatively. Outcomes of these two groups were equivalent.<sup>9</sup>

In conclusion, no one treatment is superior in the management of the stiffness, pain, and loss of function that occurs with adhesive capsulitis.<sup>10</sup> When it comes to deciding on a treatment plan, consider the patient's stage of adhesive capsulitis, the duration and nature of the patient's symptoms, which treatments the patient has tried, how well the patient's pain is controlled, and the extent to which symptoms are affecting the patient's functional status.

## CONCLUSION

Adhesive capsulitis is a painful inflammatory process of the shoulder. Patients experience pain and stiffness as well as progressive loss of ROM. Adhesive capsulitis often is diagnosed in a primary care or orthopedic setting by a thorough physical examination augmented with imaging. Clinicians may find that patients with adhesive capsulitis have underlying comorbidities such as diabetes or hypothyroidism, a history of a minor injury or surgery, or elevated CRP on laboratory tests. Nonsurgical management such as physical therapy and corticosteroid injections are the mainstay of treatment, and the disease is most commonly self-limiting. Adhesive capsulitis arguably is the most painful shoulder condition and clinicians are encouraged to provide empathy and thorough patient education throughout treatment. **JAAPA**

**Earn Category I CME** Credit by reading both CME articles in this issue, reviewing the post-test, then taking the online test at <http://cme.aapa.org>. Successful completion is defined as a cumulative score of at least 70% correct. This material has been reviewed and is approved for 1 hour of clinical Category I (Preapproved) CME credit by the AAPA. The term of approval is for 1 year from the publication date of December 2021.

## REFERENCES

1. Redler LH, Dennis ER. Treatment of adhesive capsulitis of the shoulder. *J Am Acad Orthop Surg*. 2019;27(12):e544-e554.
2. Park HB, Gwark J-Y, Kam M, Jung J. Association between fasting glucose levels and adhesive capsulitis in a normoglycemic population: a case-control study. *J Shoulder Elbow Surg*. 2020;29(11):2240-2247.
3. Park HB, Gwark J-Y, Jung J, Jeong S-T. Association between high-sensitivity C-reactive protein and idiopathic adhesive capsulitis. *J Bone Joint Surg Am*. 2020;102(9):761-768.
4. Prestgaard T, Wormgoor MEA, Haugen S, et al. Ultrasound-guided intra-articular and rotator interval corticosteroid injections in adhesive capsulitis of the shoulder: a double-blind, sham-controlled randomized study. *Pain*. 2015;156(9):1683-1691.
5. Sharma SP, Bærheim A, Moe-Nilssen R, Kvåle A. Adhesive capsulitis of the shoulder, treatment with corticosteroid, corticosteroid with distension or treatment-as-usual; a randomized controlled trial in primary care. *BMC Musculoskelet Disord*. 2016;17:232.
6. Ünlü B, Çalış FA, Karapolat H, et al. Efficacy of platelet-rich plasma injections in patients with adhesive capsulitis of the shoulder. *Int Orthop*. 2021;45(1):181-190.
7. Levine WN, Kashyap CP, Bak SF, et al. Nonoperative management of idiopathic adhesive capsulitis. *J Shoulder Elbow Surg*. 2007;16(5):569-573.
8. Grant JA, Schroeder N, Miller BS, Carpenter JE. Comparison of manipulation and arthroscopic capsular release for adhesive capsulitis: a systematic review. *J Shoulder Elbow Surg*. 2013;22(8):1135-1145.
9. Kim D-H, Song K-S, Min B-W, et al. Early clinical outcomes of manipulation under anesthesia for refractory adhesive capsulitis: comparison with arthroscopic capsular release. *Clin Orthop Surg*. 2020;12(2):217-223.
10. Forsythe B, Lavoie-Gagne O, Patel BH, et al. Efficacy of arthroscopic surgery in the management of adhesive capsulitis: a systematic review and network meta-analysis of randomized controlled trials. *Arthroscopy*. 2021;37(7):2281-2297.