



Atrium Health
Musculoskeletal Institute

Proximal Humerus Fractures

Luke Harmer MD MPH

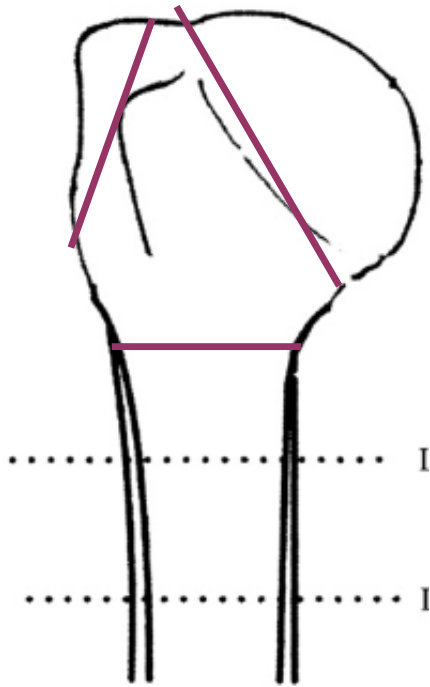
Extremities in the Carolinas – Trauma for General Orthopedics

May 17, 2021

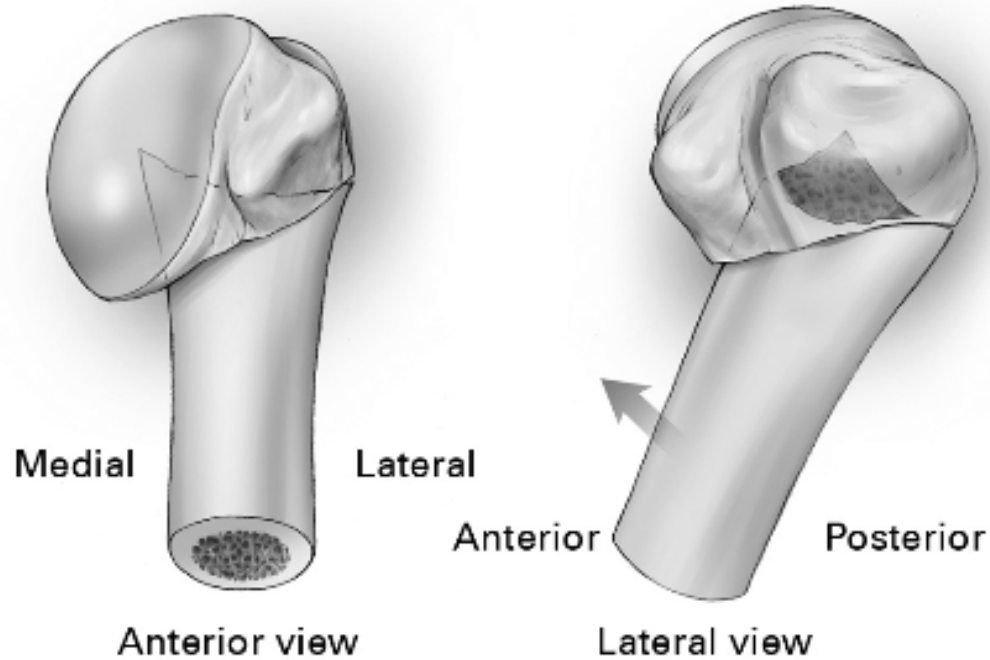
Objectives

1. Differentiate common fracture patterns
2. Guide nonsurgical management
3. Identify factors predicting poor nonsurgical outcome
4. List surgical principles for good surgical outcome
5. Describe which patients may benefit from arthroplasty

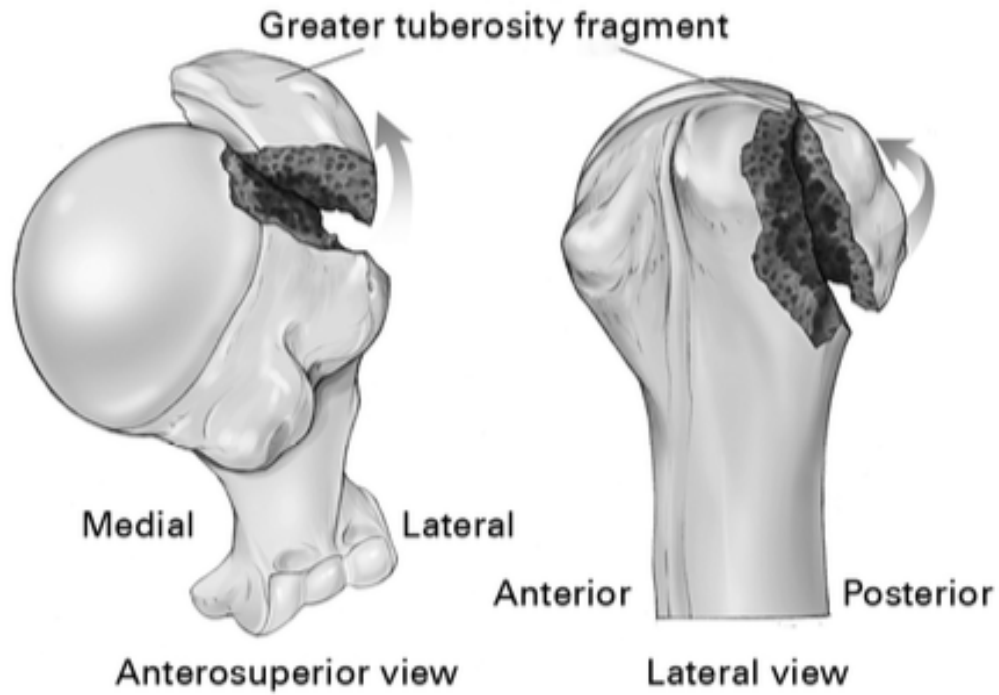
Classification - Neer



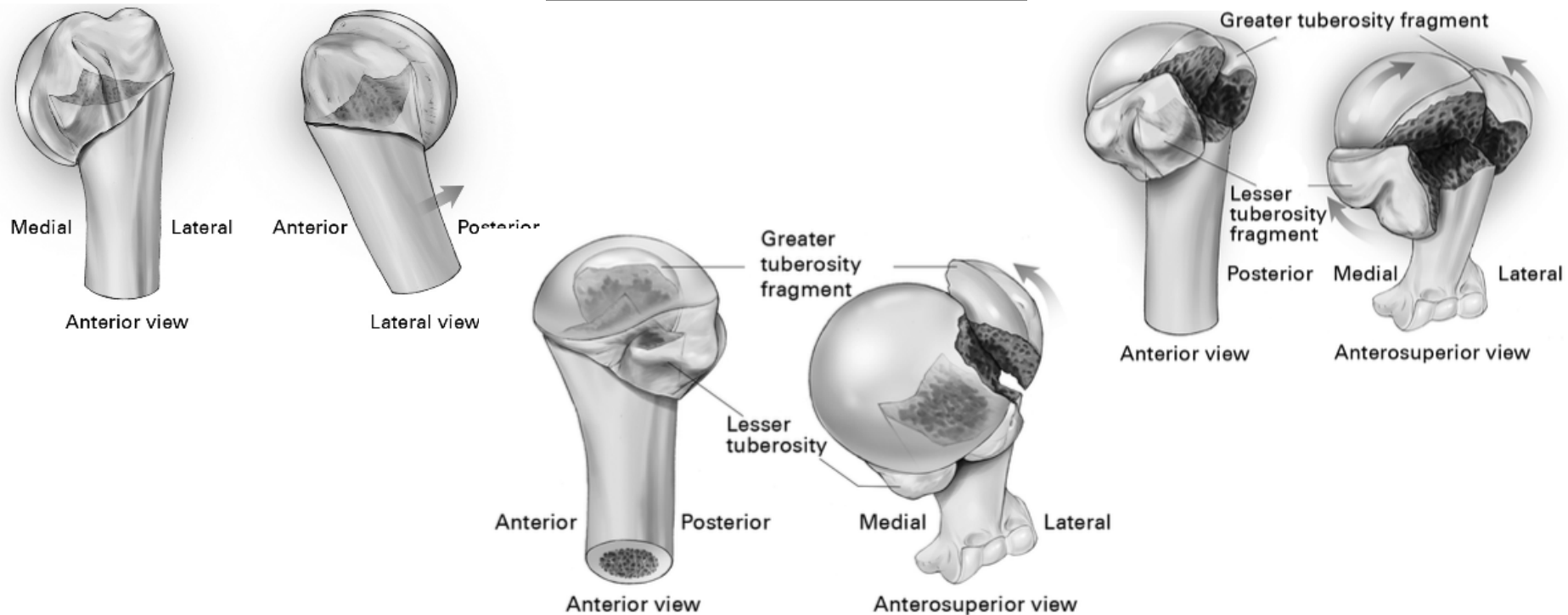
Anteromedial



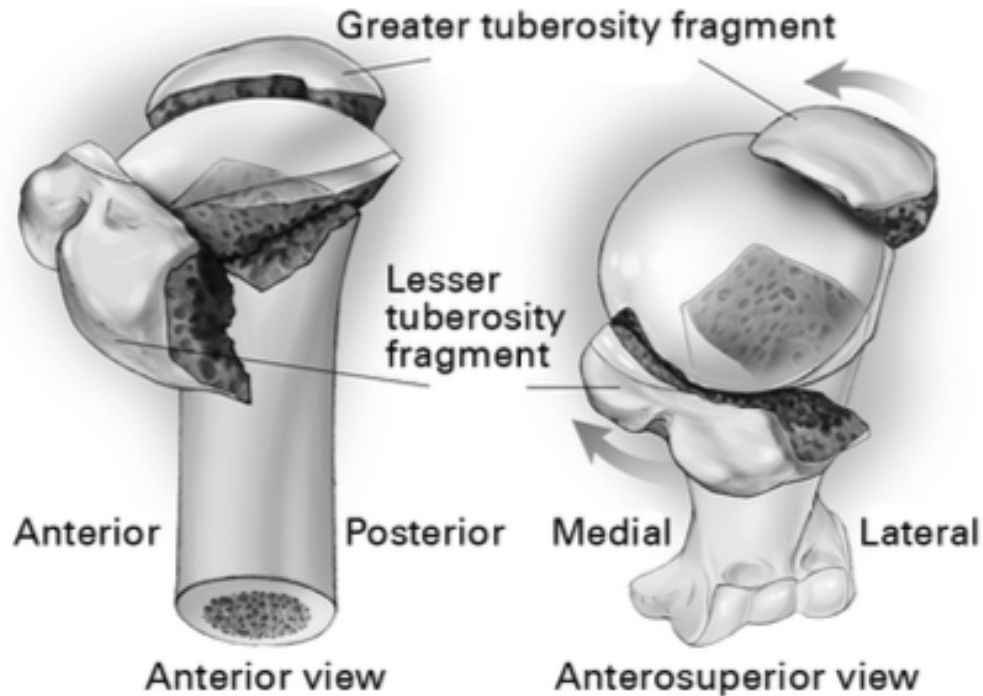
Greater Tuberosity



Posteromedial



Valgus impacted



Nonsurgical Management

Surgical vs Nonsurgical Treatment of Adults With Displaced Fractures of the Proximal Humerus The PROFHER Randomized Clinical Trial

- 250 patients
 - 87 excluded due to “clear indication for surgery”

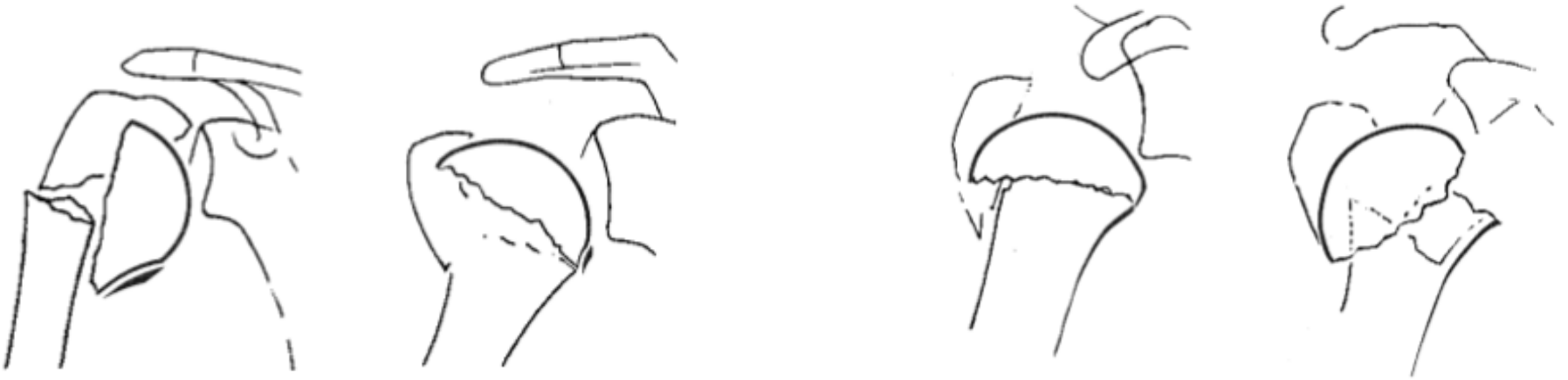
Arthroplasty

Factors Predicting Complication and Reoperation Rates Following Surgical Fixation of Proximal Humeral Fractures

- Predictors of poor outcome with fixation
 - Age greater than 55
 - High Charleston comorbidity index

Arthroplasty

- Avascular necrosis
 - Displaced medial hinge ($>2\text{mm}$)
 - Short medial calcar ($<8\text{mm}$)
 - Separate articular surface piece (anatomic neck fracture)



Arthroplasty

- Avascular necrosis
 - Displaced medial hinge ($>2\text{mm}$)
 - Short medial calcar ($<8\text{mm}$)
 - Separate articular surface piece (anatomic neck fracture)

