



Atrium Health
Musculoskeletal Institute



Claude “T.” Moorman, III, MD
Edward N. Hanley Jr Endowed Professor and Chair
Department of Orthopaedic Surgery
President, Atrium Health Musculoskeletal Institute

Orthobiologics in Sports Medicine

Claude T. Moorman III, MD

Edward N. Hanley, Jr Professor and Chair

Department of Orthopaedic Surgery



Disclosures

CTM III

- Consultant
 - Osteocentric
 - Lipogems
 - Enlyten
 - PrivIT
 - DJO





2015 National Champions!!!!



Sports Medicine Professionals in MSKI!!!!!!!



MSCs!!

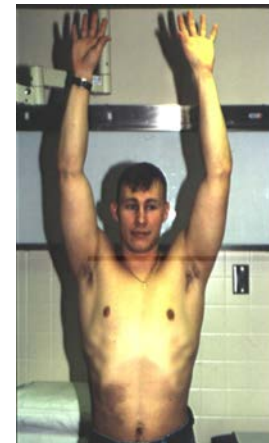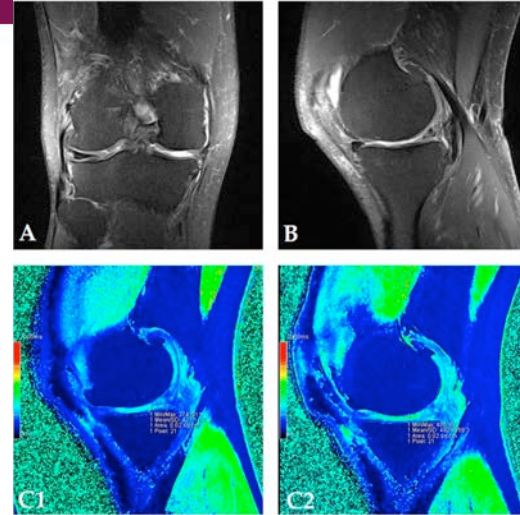
Level 5 Expert Opinion!

- Arnold Kaplan, PhD
- Mesenchymal Stem Cells (Mesoderm)
- Embryonic
 - Pluripotent
 - Directed
- Adult
 - Adipose/Marrow
 - More directed
- Exosomes



Cellular Therapies in Sports Medicine

- PRP
 - Leukocyte Poor
 - Leukocyte Rich
- Amniotic Membrane
- Amniotic Fluid
- MSC Therapies
 - Bone Marrow
 - Adipose
- GID Study



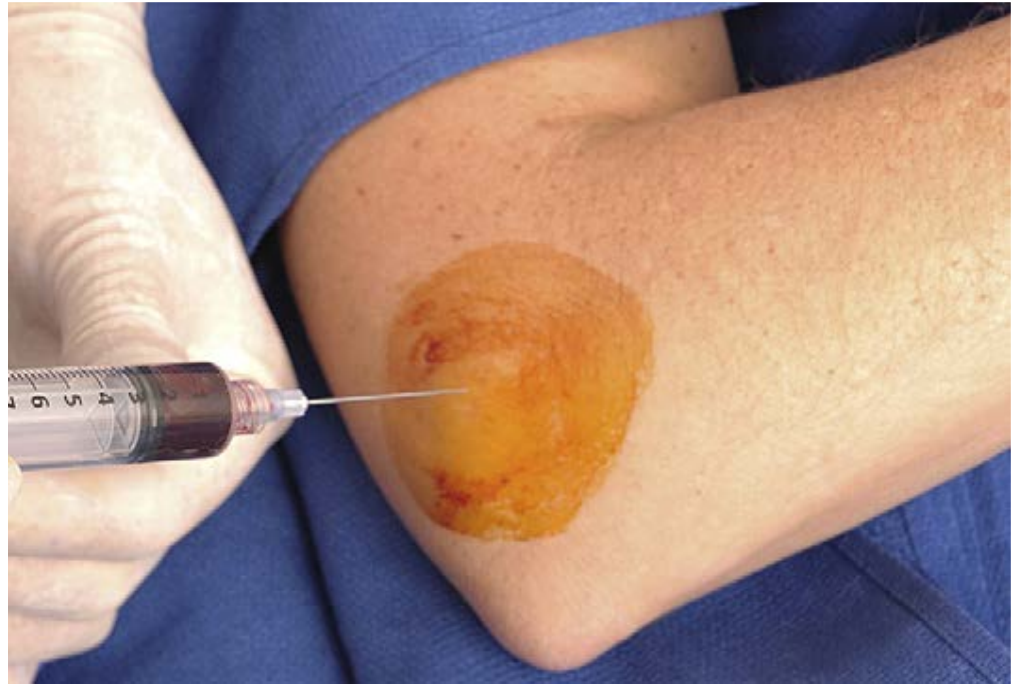

Glenn Gaston, MD

Chief, Hand Service OrthoCarolina
Musculoskeletal Institute Charlotte NC

Platelet Rich Plasma (PRP)

- 1st published medical literature 1954
- Marx et al 1990's bone grafting
- 2006 Mishra PRP for tennis elbow first pilot study
- Now 6000 references in Pubmed



Platelet Rich Plasma (PRP)

Table 1

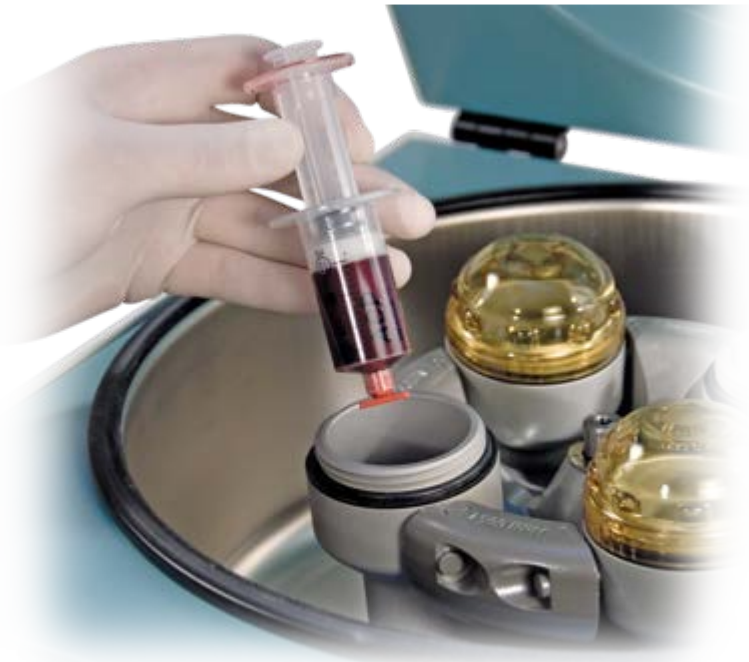Overview of the selected studies. (ABI – Autologous blood injection, PRP – Platelet Rich Plasma)

Author	Year	Study design	Comments
Mi et al	2017	Meta-analysis of randomized clinical trials	+ for PRP at 6 months (Steroid group had better initial results which declined subsequently)
Arirachakaran et al	2016	Network Meta-analysis and systematic review PRP vs steroid vs ABI	+ for PRP
Palacio et al	2016	PRP vs steroid	Equivocal
Gautam et al	2015	PRP vs steroid	+ for both PRP and steroid initially (Steroid group worsened after 6 months)
Khaliq A	2015	PRP vs steroid	+ for PRP
Lebiedziński et al	2015	PRP vs steroid	+ for PRP at one year
Yadav R	2015	PRP vs steroid	+ for PRP at 3 months
Behera P	2015	PRP vs steroid	+ for PRP at 3 months (Steroid group had better initial results which declined subsequently)
Krogh et al	2013	PRP vs steroids vs saline	Equivocal
Mishra et al	2012	PRP vs controls	+ for PRP at 6 months
Gosens et al	2011	PRP vs steroids	+ for PRP at 2 years (Steroid group had better initial results which declined subsequently)
Peerbooms	2010	PRP vs steroid injection	+ for PRP at one year (Steroid group had better initial results which declined subsequently)
Raeissadat et al	2014	PRP vs ABI	Equivocal
Thanasas	2011	PRP vs ABI	Equivocal (PRP gave faster relief)
Creaney	2011	PRP vs ABI	Equivocal (equal efficacy)

10 Favor PRP!!
5 Equivocal

Platelet Rich Plasma (PRP)

- What is it?
 - Platelets have over 300 cytokines, growth factors, and bioactive molecules
 - Modulate cell signalling
- Where is it?
 - Plasma portion of blood (because very light cellular element vs. red/white cells)



Platelet Rich Plasma (PRP)

- How do you make it?
 - Blood draw
 - Centrifuge
 - Draw off yellow plasma layer (3-5cc)
 - Inject



When do I use it?

- Failed minimal 6 months nonop
- Failed 8-12 weeks OT
- Failed bracing
- Failed one cortisone injection

- Wants to avoid surgery
- Understands cost issues
- *allowed by all pros sports even cycling

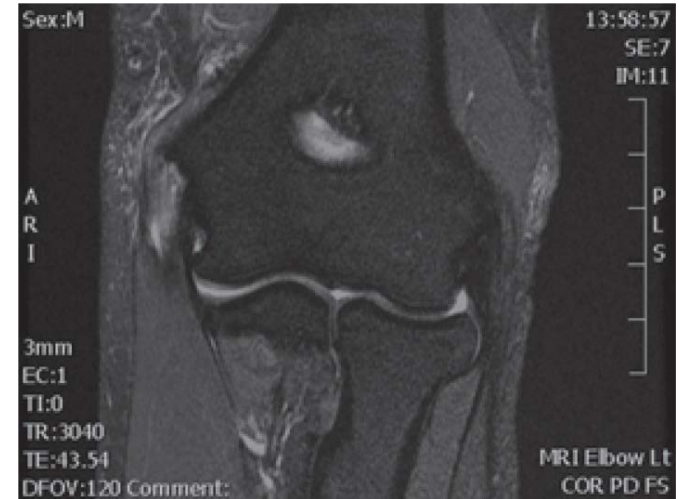My Personal Impression(Gaston)

- Many patients in whom I previously would have operated on avoided surgery after PRP
- I have converted 3 to surgery after PRP
- Patients hurt more than with CSI injections and for longer (week or so)



PRP Promising for Elbow Tendinopathies!

- **Great Second Line Therapy after Braces/OT**
- **Beats CS nearly every time!**
- **Often Beats Surgery!**
- **Doesn't Always work, but low risk and worth a try!!**



PRP Promising for Early Knee OA!

- Neutral Alignment
- Leukocyte Poor PRP!
- Less \$ than Adipose/
Marrow!!



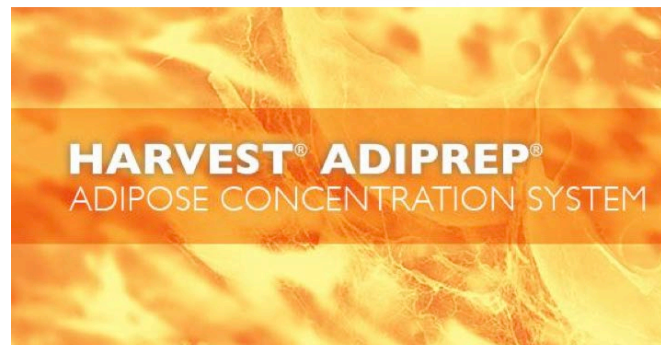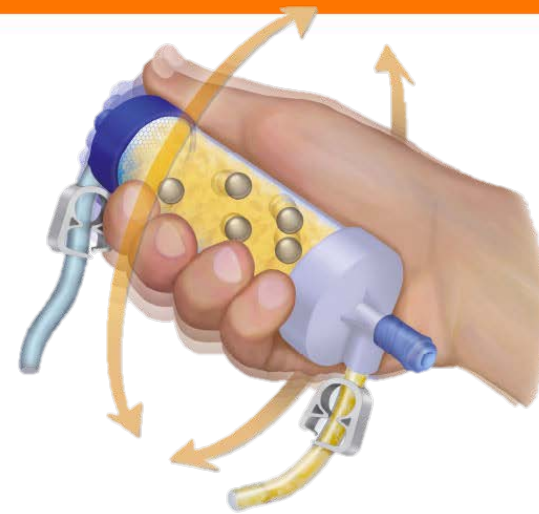
Cellular Therapy - Adipose Tissue

- Relatively easy to obtain with minimally invasive harvest
- High concentrations of regenerative cells found in adipose tissue (Kaplan, Guilak, Futrell)
 - **Order of Magnitude more activated cells —10X more than BMSC**
- From 1g of adipose tissue → 5000 stem cells can be isolated → 500x more cells than from an equivalent amount of bone marrow¹
- Cells are abundant
 - **Activated cells unlikely to decrease with age like as bone marrow-derived cells**
 - **NC Residents**
- Exosome - secretory product of fat graft (natural IL-1 inhibitor)
- Less risk associated with autologous therapies
 - Infection risk, graft vs host reactions

¹Hass, Ralf, Cornelia Kasper, Stefanie Böhm, and Roland Jacobs. "Different Populations and Sources of Human Mesenchymal Stem Cells (MSC): A Comparison of Adult and Neonatal Tissue-derived MSC." Cell Commun Signal Cell Communication and Signaling 9.1 (2011): 12.

Autologous Microfragmented Adipose Tissue (Adiprep) (LipoGems) (TULIP)

- FDA cleared
 - Dec 2014 - Class II medical device for processing autologous adipose tissue (510(k) first approval in US in December 2014)
 - Nov 2016 – cleared for **arthroscopic** applications
- Mechanical Agitation → minimal manipulation
 - Stainless steel ball bearings help to break up tissue by mechanical agitation, washing away mature adipocytes
 - Ball bearings emulsify the tissue to reduce quantity of impurities that cause inflammation (blood and oil products)

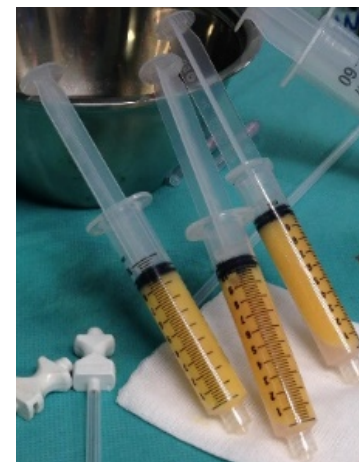

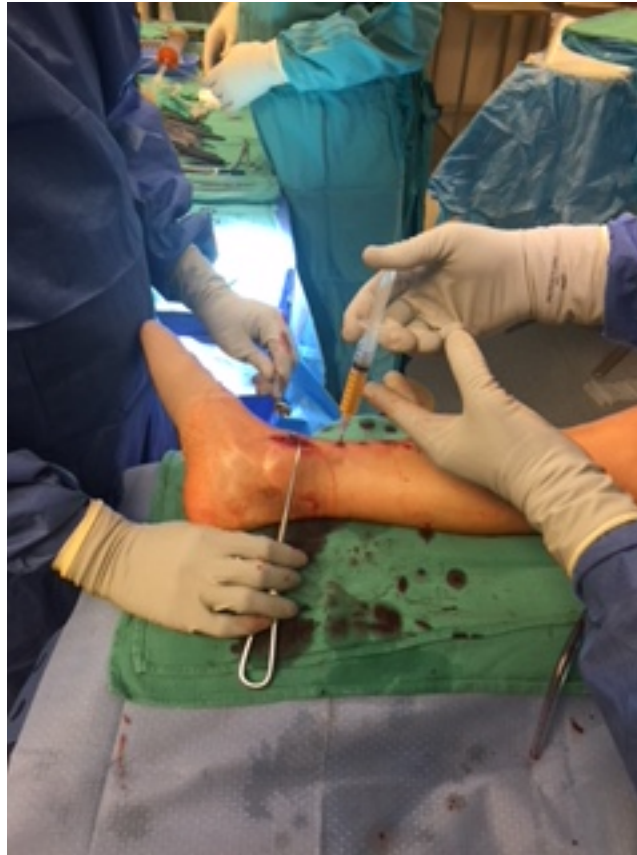
How Can This Help the Athlete????

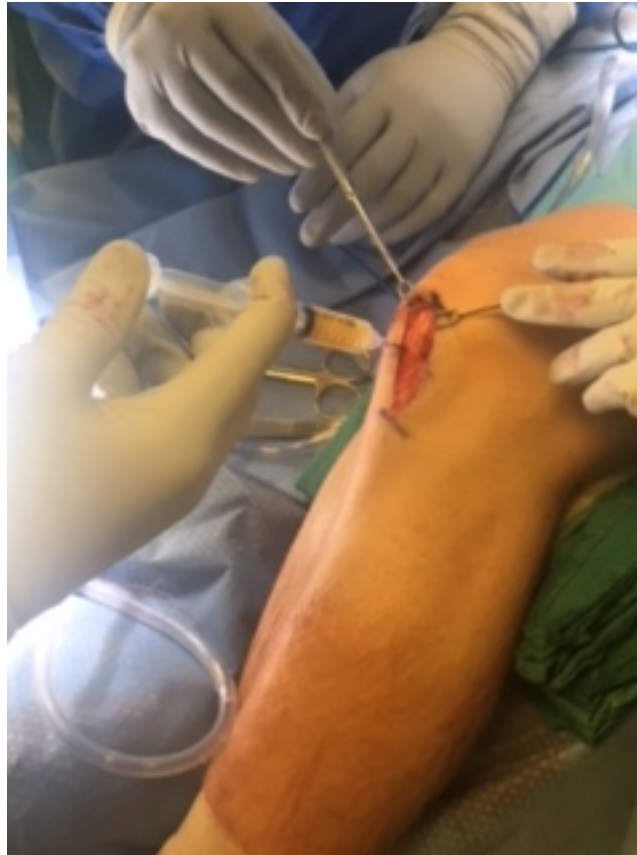- Adipose Derived Therapies
 - Promising early results
 - Possible utility in:
 - Shoulder OA
 - **Early Knee OA**
 - **Shoulder OA**
 - **Soft-tissue Healing**
 - **Chondral Injury Hip**
 - **Mfx Plus??**
 - Long term results pending
- 7 NIH registered clinical trials in orthopaedic surgery on Lipogems
 - 4 Knee OA
 - 2 shoulder
 - 1 diabetic foot



**200+ Cases
Level V**

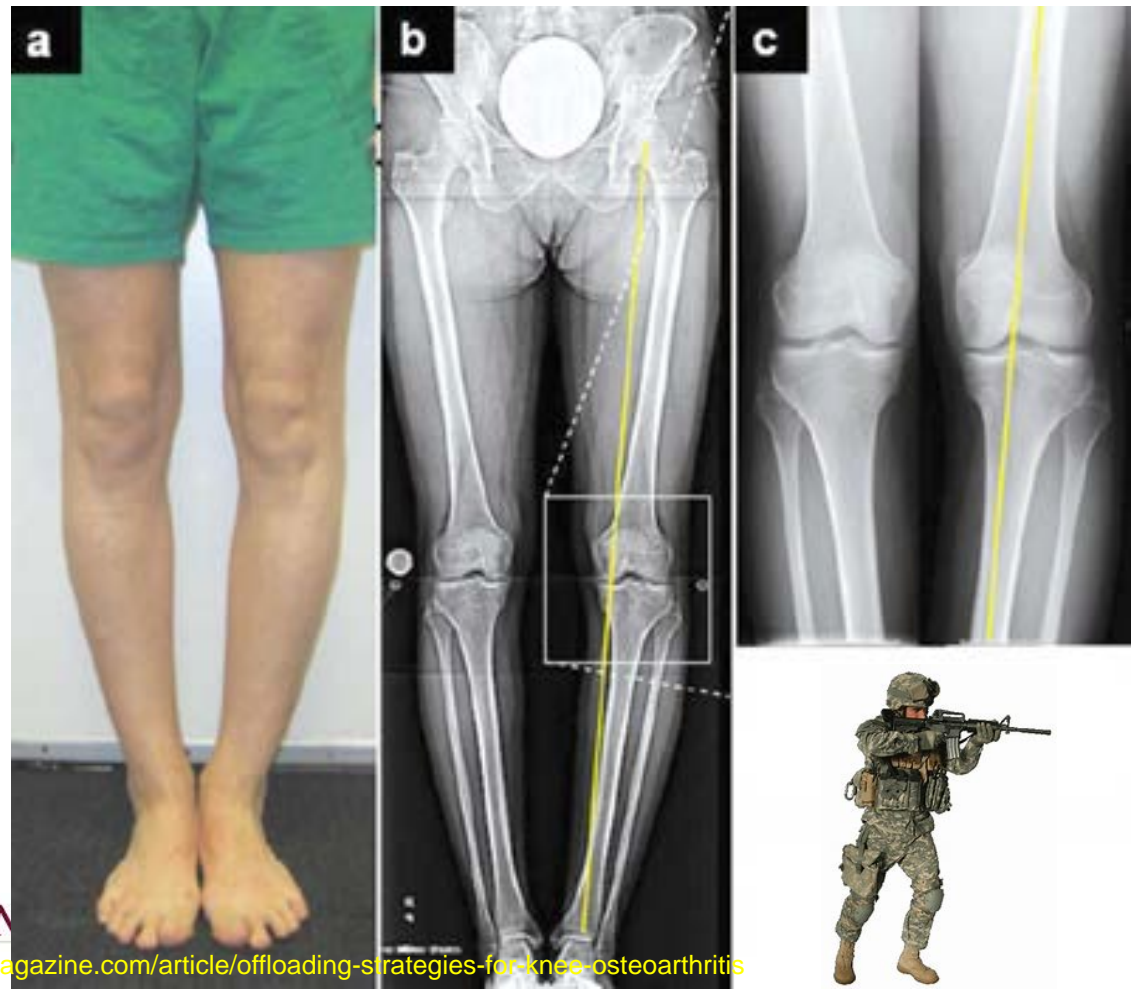






Role for aMAT

- Indications (early knee OA)
 - Neutral alignment
 - Early cartilage wear
 - Unipolar lesion (femoral or tibial side only) - no kissing lesions
 - REMEMBER - mechanics trump biology every time — not a good option for malaligned knee



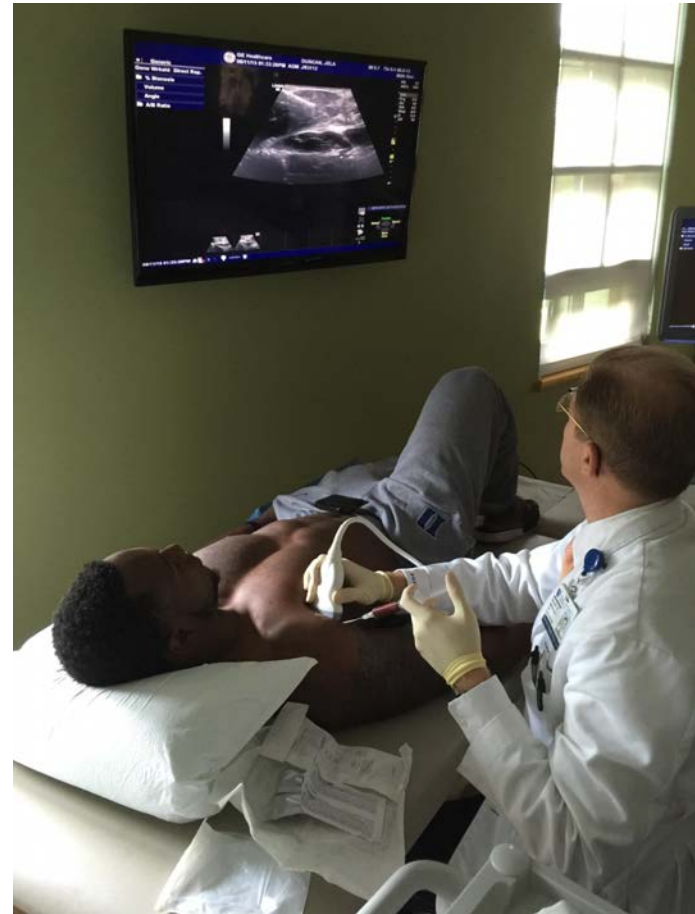Ground Rules for Cellular Therapies: FDA

- Autologous Tissue Only
- Minimal Manipulation of Cells
 - Centrifuge
 - Ball Bearing Separation
- No Enzymatic Alteration



Cellular Therapies

- Same Tissue as Source Cells
- Not covered by US insurance
- Italy-Medicare!

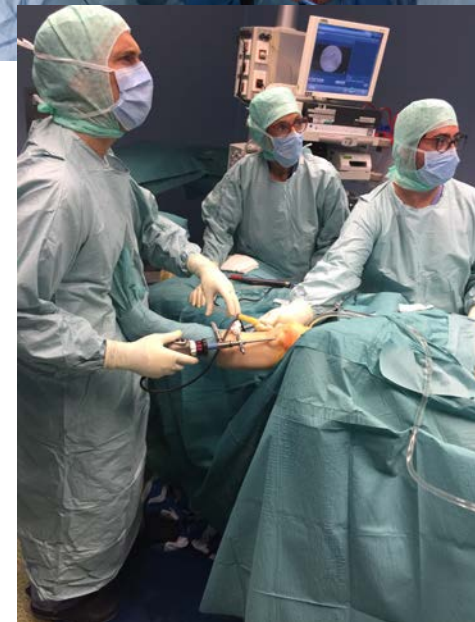
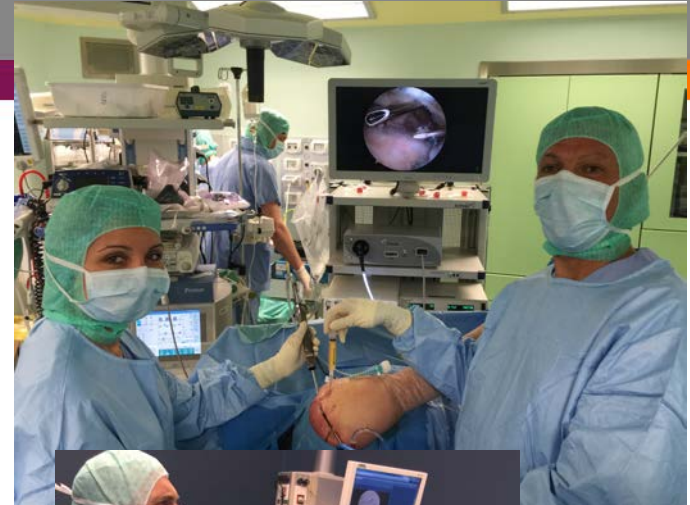


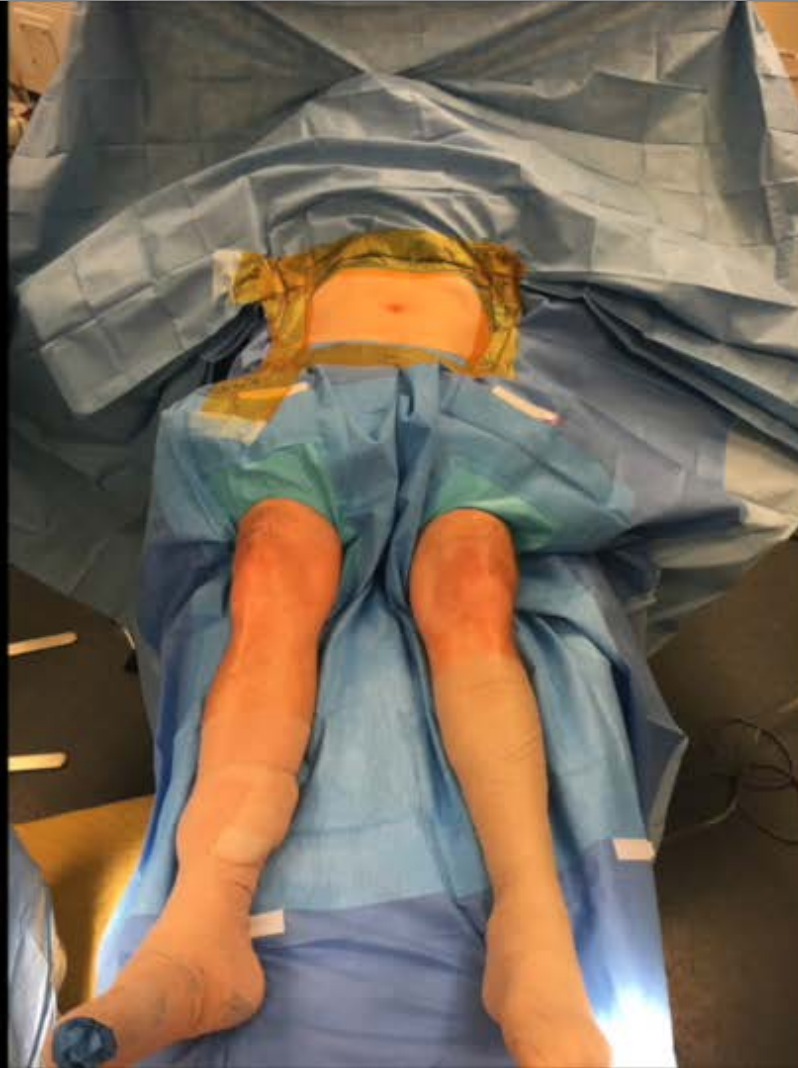Off to Italy to visit
Carlo Tremalodo in
Milan!!

Lessons from the Italians

- Compression on Liposuction site
- 10cc Injection
- Close Portal before injection
- Results good enough for Public Funding!!



Video





Atrium Health

Musculoskeletal Institute

Clinical Evidence

- ❑ 23 BASIC SCIENCE publications
- ❑ Over 15 ongoing ORTHO clinical trials (EU and USA)
- ❑ 17 publications in ORTHO
- ❑ 12 publications in other specialties (gyn, coloproctology, pain management, general surgery, wound healing)

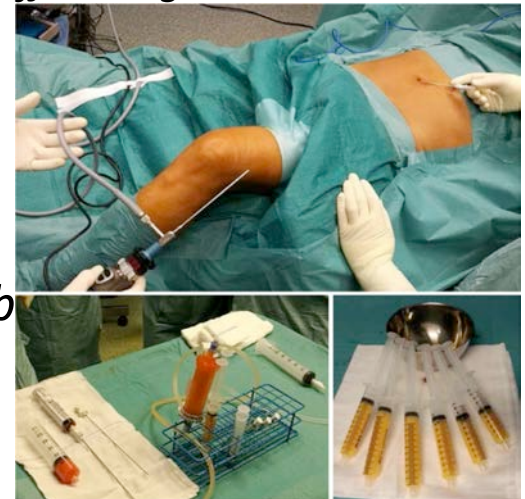Knee OA (Lipogems + Arthroscopy)- Retrospective study with 3 yr FU

Study Objective: *To evaluate the 1-year safety and outcome of a single intra-articular injection of autologous MFAT tissue as adjuvant therapy in patients affected by diffuse degenerative chondral lesions.*

Primary Investigator: Dr. Zorzi, Negrar Hospital, Verona, IT

Study Details:

- **Patient No: 30**
 - 24 recon procedures (ACL/LCL, meniscectomy, tib)
 - Single arthroscopic injection (10-15mls)
- **Outcome Measures:**
 - **Safety:** AEs within 36months
 - **Efficacy:** KOOS, IKDC, VAS, Tegner
- **Endpoints:**
 - Baseline, 12mo and 36mo



Russo et al. *Journal of Experimental Orthopaedics*
<https://doi.org/10.1186/s40634-018-0169-x>

(2018) 5:52

Journal of
Experimental Orthopaedics

SHORT REPORT

Open Access

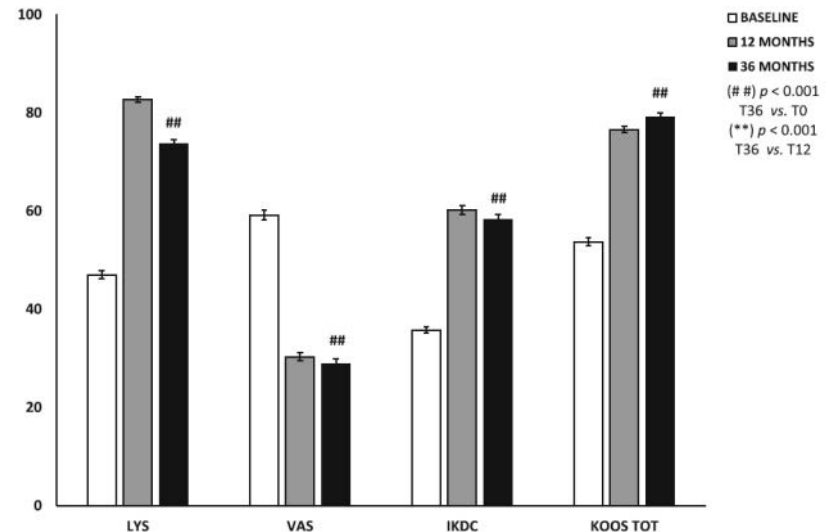


Autologous micro-fragmented adipose tissue for the treatment of diffuse degenerative knee osteoarthritis: an update at 3 year follow-up

A. Russo^{1,2*}, D. Screpis¹, S. L. Di Donato¹, S. Bonetti¹, G. Piovani¹ and C. Zorzi¹

Knee OA (Lipogems + arthroscopy)- Retrospective study with 3 yr FU

- No adverse events
- 22/29 patients had no other treatments at 3yr time point
- All measurements showed significant improvement from baseline at 3yrs
 - >50% of patients improved at least 20 points in all scores
 - 55% increased 30 points on VAS
- 77% of patients would repeat procedure



Russo et al. *Journal of Experimental Orthopaedics* (2018) 5:52

Same Study: 1 yr to 3 year Follow Up

Russo et al. *Journal of Experimental Orthopaedics* (2017) 4:33
DOI 10.1186/s40634-017-0108-2

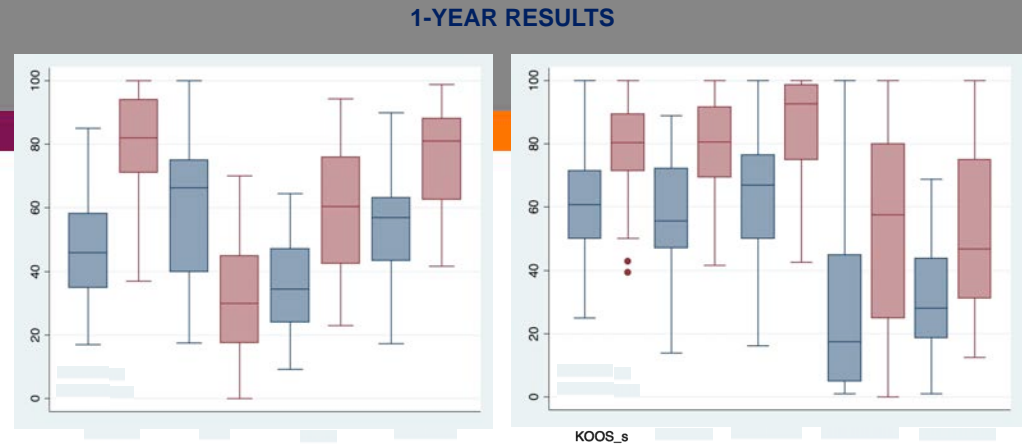
Journal of
Experimental Orthopaedics

RESEARCH

Open Access

Autologous and micro-fragmented adipose tissue for the treatment of diffuse degenerative knee osteoarthritis

A. Russo¹, V. Condello¹, V. Madonna¹, M. Guerriero² and C. Zorzi¹



Russo et al. *Journal of Experimental Orthopaedics* (2018) 5:52
<https://doi.org/10.1186/s40634-018-0169-x>

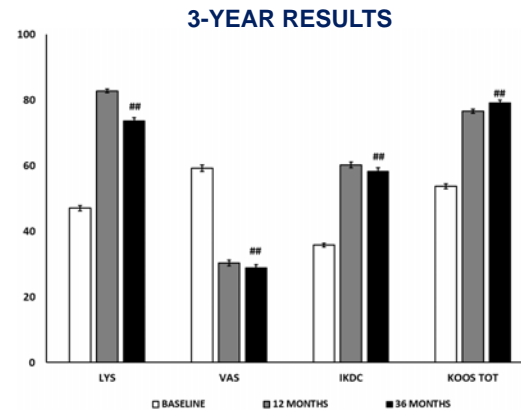
Journal of
Experimental Orthopaedics

SHORT REPORT

Open Access

Autologous micro-fragmented adipose tissue for the treatment of diffuse degenerative knee osteoarthritis: an update at 3 year follow-up

A. Russo^{1,2*}, D. Screpis¹, S. L. Di Donato¹, S. Bonetti¹, G. Piovani¹ and C. Zorzi¹



CONCLUSION:

- The results show the safety and feasibility of using MFAT in patients affected by diffuse degenerative chondral lesions.
- The technique is safe, minimally invasive, simple, one-step, with low percentage of complications, and compliant with the regulatory panorama.
- The results are maintained at 3 years.

Early Knee OA: Identification of Subpopulation with Greater Response

International Orthopaedics (2019) 43:7–13
<https://doi.org/10.1007/s00264-018-4182-6>

ORIGINAL PAPER



Preliminary results of autologous adipose-derived stem cells in early knee osteoarthritis: identification of a subpopulation with greater response

Alfredo Schiavone Panni¹ · Michele Vasso¹ · Adriano Braille¹ · Giuseppe Toro¹ · Annalisa De Cicco¹ · Davide Viggiano² · Federica Lepore¹

Received: 12 September 2018 / Accepted: 21 September 2018 / Published online: 3 October 2018
 © SICOT aisbl 2018

Abstract

Purpose The purpose of this study was to report the clinical and functional results of a series of patients with early knee osteoarthritis (KOA) treated with the intra-articular injection of autologous adipose-derived stem cells (aASCs) plus arthroscopic debridement. The hypothesis was that protocol would significantly improve the clinical and functional outcomes in patients with early KOA.

Methods Fifty-two patients with early KOA, who received arthroscopic debridement followed by percutaneous injection of aASCs, were enrolled into the study and retrospectively analyzed with an average follow-up of 15.3 (range, 6 to 24) months. Patients were assessed through the IKS knee and function scores and VAS pain scale.

Results The mean IKS knee score improved from 37.4 (range, 14 to 79) points pre-operatively to 62.6 (range, 27 to 95) points at the latest follow-up ($p < 0.01$). The mean IKS function score improved from 57.2 (range, 25 to 100) points pre-operatively to 83.0 (range, 35 to 100) points at the latest follow-up ($p < 0.01$). The mean VAS score decreased from 8.5 (range, 3 to 10) pre-operatively to 5.1 (range, 0 to 8) at the latest follow-up ($p < 0.01$). Additionally, patients with a pre-operative VAS score greater than 8 were found to show greater clinical and functional benefits compared with patients with VAS score lower than 8.

Conclusions The knee injection of aASCs associated to arthroscopic debridement increased significantly the clinical and functional scores in patients with early KOA at a mid-term follow-up, especially those with higher pre-operative VAS scores.

- n=52
- The injection of MFAT associated with arthroscopy (chondral shaving/abrasion and/or meniscal regularization) significantly increased the clinical and functional scores in patients with early knee OA at a mid-term follow-up (6-24 months).
- Significantly higher improvements in patients with pre-operative VAS score > 8.
- No treatment-related adverse events.
- At the latest follow-up, 96.2% of patients expressed satisfaction and reported good/excellent improvements in function and/or pain.

Mean IKS knee and function and VAS scores

	Preoperatively	Latest follow-up	p value
Mean IKS knee (points)	37.4 (14–79)	62.6 (27–95)	<< 0.01
Mean IKS function (points)	57.2 (25–100)	83.0 (35–100)	<< 0.01
VAS (points)	8.5 (3–10)	5.1 (0–8)	<< 0.01

Percent improvement of IKS knee and function and VAS scores in patients presenting with high or low pain

	VAS < 8	VAS > 8	p value
Improvement in IKS knee (% over basal)	26 ± 17%	115 ± 22%	0.005
Improvement in IKS function (% over basal)	22 ± 18%	64 ± 10%	0.05
Improvement in VAS (% over basal)	4 ± 15%	44 ± 4%	0.02

Knee OA: Prospective study in patients with refractory severe OA

Study Objective: *To evaluate the 1-year safety and functional outcome (pain, quality of life and function) following a single intra-articular injection of autologous MFAT tissue in patients with K/L grade 3 or 4 OA.*

Primary Investigator: Dr. Gerald Malanga, NJ Sports Medicine, Cedar Knolls, NJ

Study Details:

- **Patient Population:**
 - N=17 (26 joints)
 - Avg age: 72
 - K/L 3 or 4
 - Single ultrasound guided injection
- **Outcome Measures:**
 - Safety: AEs within 12months
 - Efficacy: KSS, NPS, LEAS
- **Endpoints:**
 - 6wks, 6 and 12 months

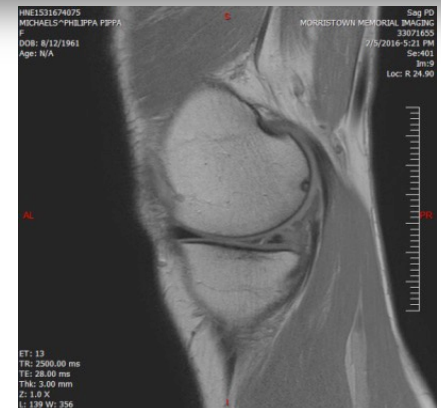
AJ The American Journal
of Orthopedics

Safety and Efficacy of Percutaneous Injection of Lipogems Micro-Fractured Adipose Tissue for Osteoarthritic Knees

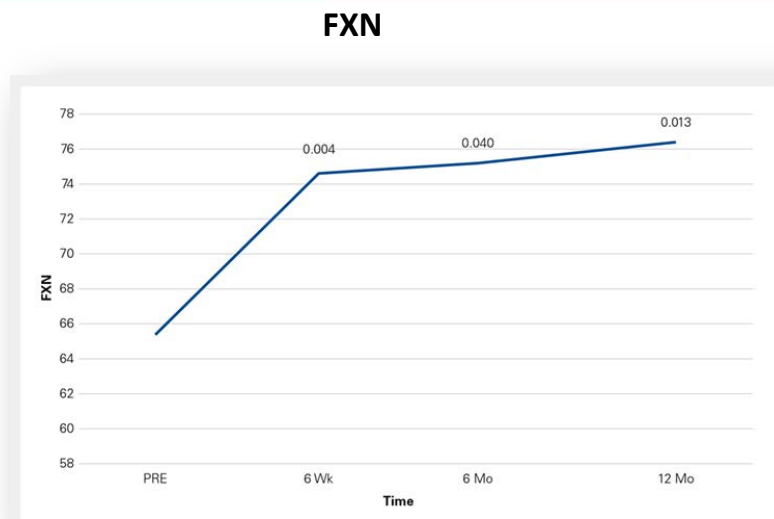
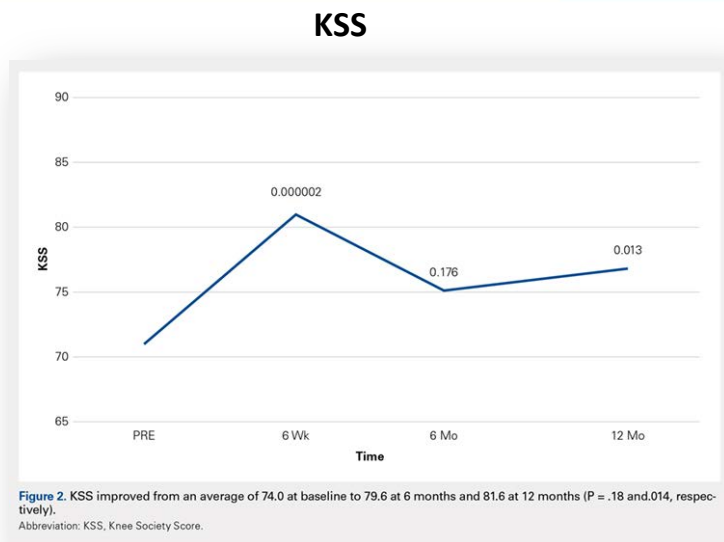
Publish date: November 19, 2018

Authors:

Jay Panchal, MD Gerard Malanga, MD Mitchell Sheinkop, MD



Significant improvements in pain, QoL, and Function



- No adverse events
- Significant improvement was observed on all scales at 6 weeks and maintained to 12mo
- All measurements showed significant improvement in pain, QoL and function for at least 12 months in this patient population (recommended for TKA)

Panchal et al., *Am J Orthop.* 2018;47(11)

Knee OA: Prospective study in patients with refractory severe OA with d(GEMRIC) MRI

Study Objective: To evaluate the effects intra-articular administration of autologous and microfragmented fat tissue therapy on cartilage extracellular matrix and content of proteoglycans in osteoarthritic cartilage (KL 3 and 4).

Primary Investigator: Dr. Damir Hudetz, St. Catherine Specialty Hospital, Zagreb, Croatia

Study Details:

• Patient Population

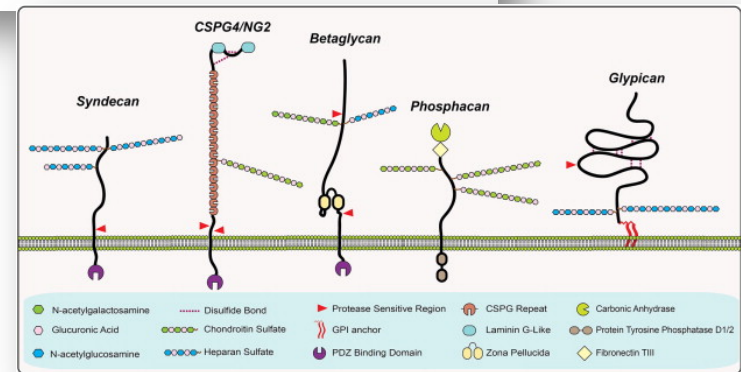
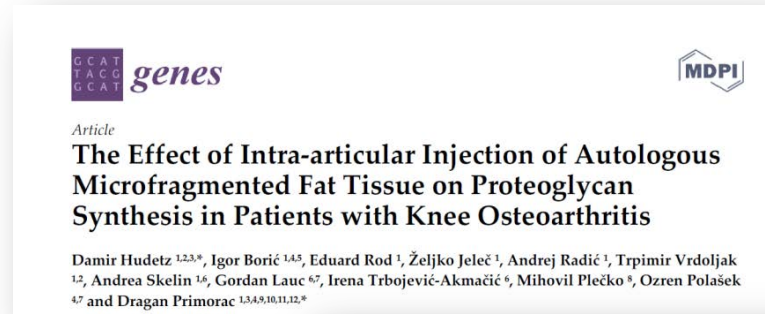
- 17 (32 knees)
- Single US guided injection

• Outcome Measures:

- Safety: AEs within 12months
- Efficacy: VAS, d(GEMRIC) MRI, IgG baseline

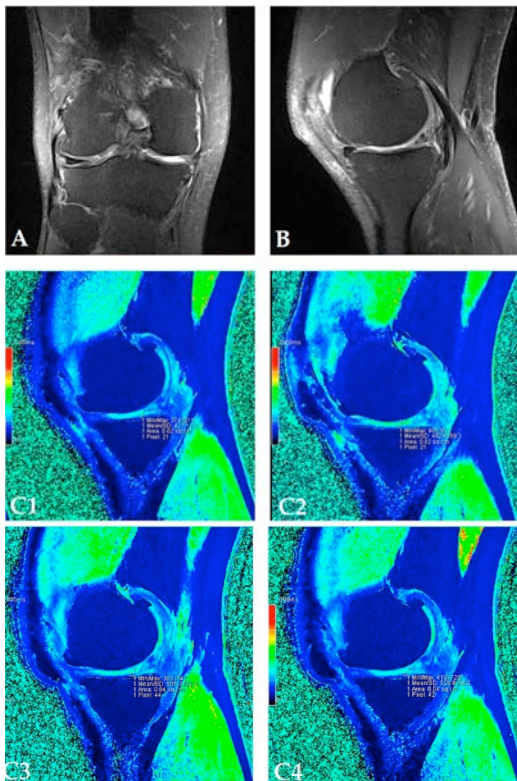
• Endpoints:

- Baseline, 3, 6 and 12 months

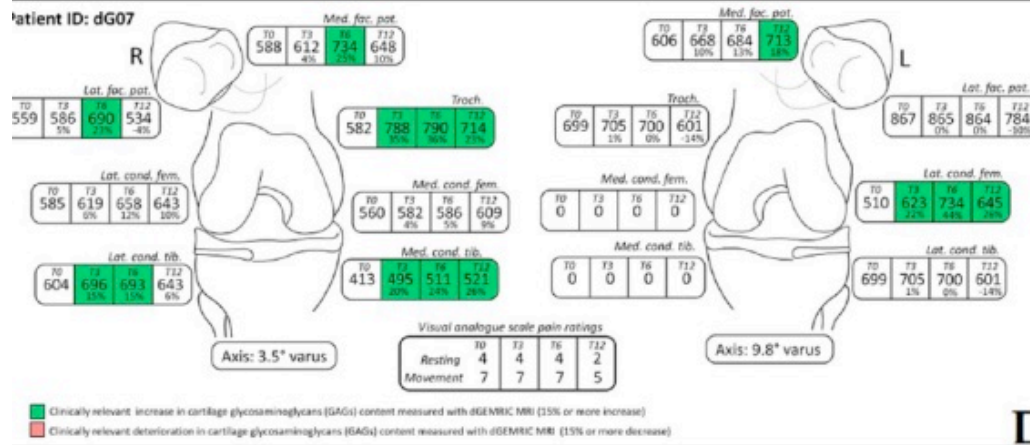


Articular Cartilage Proteoglycans

Knee OA: d(GEMRIC) Proteoglycan Evaluation



- Varus deformity 3.5° (R), 9.8° (L)
- 7 facets measured
- Clinically relevant increase in GAG = 15% from baseline



Knee OA: Pain scale (VAS)

Table 1. Basic clinical comparison across the follow-up.

	Initial (M0)	First Follow-up (M3)	Second Follow-up (M6)	Third Follow-up (M12)	<i>p</i> * (M0- M3)	<i>p</i> * (M0- M6)	<i>p</i> * (M0- M12)
C-reactive protein (CRP); mean ± SD (min-max)	6.54 ± 7.83 (1-20.3)	-	3.86 ± 3.71 (0.6-12)	5.17 ± 5.83 (0.6-23.1)	-	0.158	0.330
Visual analogue scale pain rating, resting; mean ± SD (min-max)	3.94 ± 2.56 (0-8)	1.24 ± 1.48 (0-4)	1.17 ± 1.62 (0-5)	0.56 ± 1.2 (0-4)	<0.001	<0.001	<0.001
Visual analogue scale pain rating, movement; mean ± SD (min-max)	7.33 ± 1.72 (4-10)	3.82 ± 2.07 (1-7)	3.67 ± 2.03 (0-7)	3.17 ± 1.98 (0-7)	<0.001	<0.001	<0.001

* Pair-wise testing with t-test for paired samples; SD: standard deviation; M: months

- 120/224 (**53%**) joint facets showed increase in PG levels at 12 mo
- Only 3.9% showed clinically relevant decrease (all KL 4)
- VAS change: 7.3 (baseline) to 3.1 (12mo)
- Increase in PG reflected VAS scoring and clinical results

Hudetz et al., *Genes*. 2017;8 (1-17)

Knee OA (Lipogems + Arthroscopy): Retrospective study in patients with mild to moderate refractory OA

Study Objective: To explore whether patients affected by symptomatic knee OA treated with micro-fragmented adipose tissue injection associated with a chondroplasty procedure experience an improvement in symptoms and function

Primary Investigator: Dr. Camera, Spotorno Foundation, Pietra Ligure - IT

Study Details:

• *Patient Population:*

- *N=35 mild to moderate OA (K/L 1-3, 1yr refract)*
- *Arthroscopic chondralplasty +/- meniscus repair +with **MFAT single injection adjunctive therapy***
- *SH (35), SM (14)*

• *Outcome Measures:*

- *Safety: AEs within 12months*
- *Efficacy: KOOS and WOMAC*

• *Endpoints:*

- *Baseline, 1, 3, 6 and 12 months*

Cattaneo et al. *BMC Musculoskeletal Disorders* (2018) 19:176
<https://doi.org/10.1186/s12891-018-2105-8>

BMC Musculoskeletal Disorders

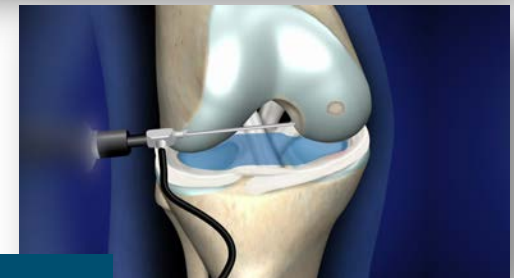RESEARCH ARTICLE

Open Access



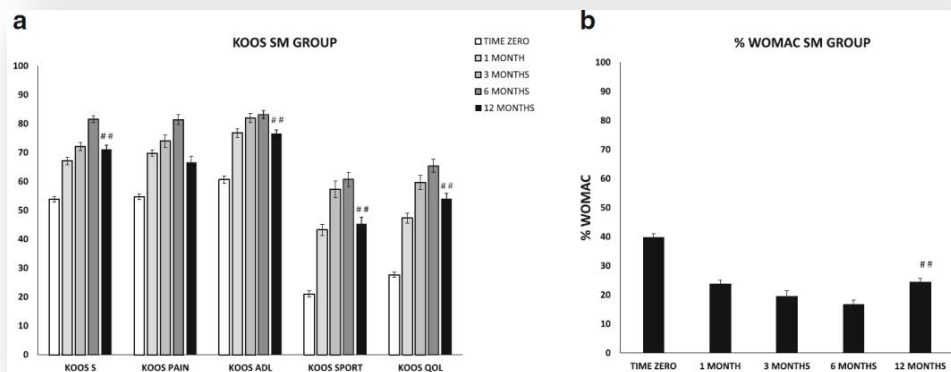
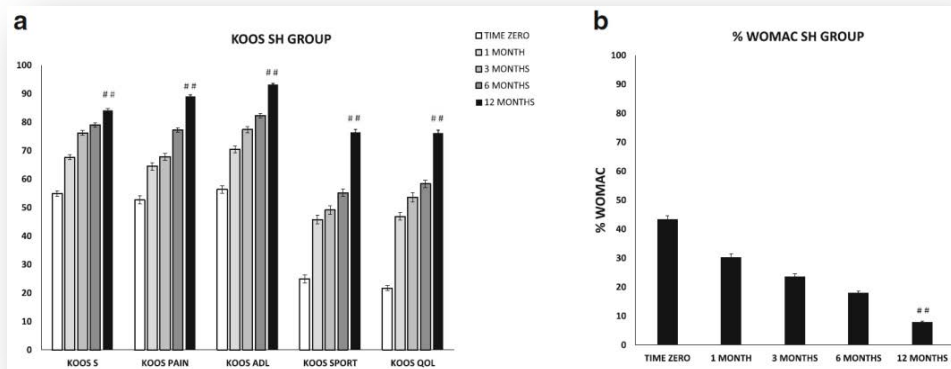
Micro-fragmented adipose tissue injection associated with arthroscopic procedures in patients with symptomatic knee osteoarthritis

G. Cattaneo^{1*}, A. De Caro¹, F. Napoli¹, D. Chiapale², P. Trada² and A. Camera¹



Cattaneo et al., *BMC Musculoskeletal Disorders* (2018) 19:175

Patient Functional Outcome Measurements



- No adverse events
- Chondroplasty (SH):
 - **KOOS:** Significant improvement was observed on all scales at all time points; **KOOS Sport (↓51)** and **QoL (↓54)** demonstrated highest improvements
 - **WOMAC:** stiffness and fxn limitation **43 to 8**
- Meniscus repair (SM)
 - **KOOS:** Significant improvement was observed at 12 mo
 - **WOMAC:** stiffness and fxn limitation **40 to 24**

Cattaneo et al., *BMC Musculoskeletal Disorders* (2018) 19:175

Patient Responder Percentage

Table 3 Summary of the results

	Δ KOOS_s	Δ KOOS_p	Δ KOOS_adl	Δ KOOS_spt	Δ KOOS_QoL	Δ WOMAC
SH						
Mean	29	36	37	51	54	-36
SE	1.11	1.45	1.31	1.73	1.32	1.31
% improved patients	90%	86%	95%	90%	95%	95%
SM						
Mean	17	12	16	24	26	-15
SE	2.2	2.4	1.7	2.7	1.7	1.8
% improved patients	64%	57%	86%	71%	86%	79%

- No adverse events
- No patient worsened, or underwent additional treatment over 12 mo timeframe
- 92% and 74% of patients clinically improved overall
- 100% of patient were satisfied with the treatment

Cattaneo et al., *BMC Musculoskeletal Disorders* (2018) 19:175

Shoulder OA: Prospective study in patients with refractory shoulder pain

Study Objective: To evaluate the safety, efficacy and long term benefits from ultrasound guided injection of an autologous, minimally manipulated, microfragmented adipose tissue.

Investigator: Dr. Gerard Malanga, New Jersey Sports Medicine, Morristown, NJ

Study Details:

• *Patient Population:*

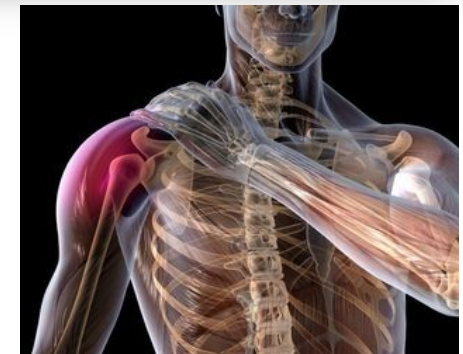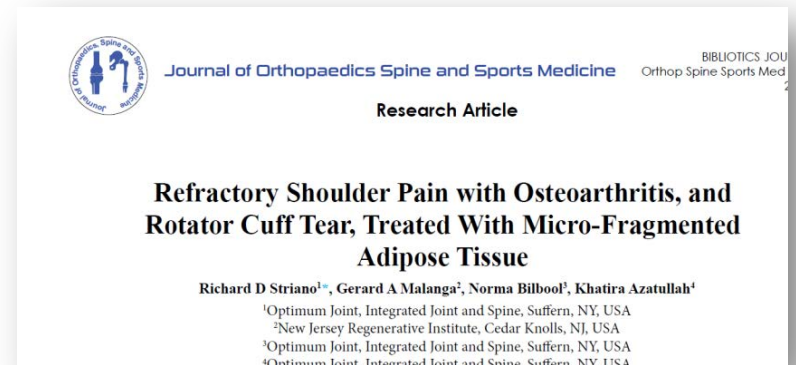- *N=18*
- *Refractory chronic (>1yr) shoulder pain with associated loss of function (multiple etiologies)*

• *Outcome Measures:*

- *Safety: AEs within 12months*
- *Efficacy: Numeric pain scale (VAS) and American Shoulder and Elbow Surgeon's (ASES) score*

• *Endpoints:*

- *Baseline, 1,5 wks; 3, 6 & 12mo*



Significant Improvements in Pain and Function

Subject Demographics and Pathology (18 subjects)	
Average age	65.9
Average BMI	32.2 kg/m ²
Laterality	
Right	13 (72.2%)
Left	7 (35%)
Glennohumeral osteoarthritis severity	
None	1 (5%)
Mild	2 (10%)
Moderate	5 (25%)
Severe	12 (60%)
Acromio-clavicular osteoarthritis	11 (55%)
Rotator cuff pathology	
Bicep Tendon	
Tendinosis	1 (5%)
Partial Tear	4 (20%)
Subscapularis Tendon	
Tendinosis	5 (25%)
Partial Tear	1 (5%)
Supraspinatus Tendon	
Tendinosis	9 (45%)
Partial Tear	9 (45%)
Full Thickness Tear	6 (30%)
Infraspinatus Tendon	
Tendinosis	7 (35%)
Partial Tear	1 (5%)
Full Thickness Tear	1 (6%)
Labral Tear	7 (35%)
Fatty Atrophy	6 (30%)

Table 1: Patient demographic summary.

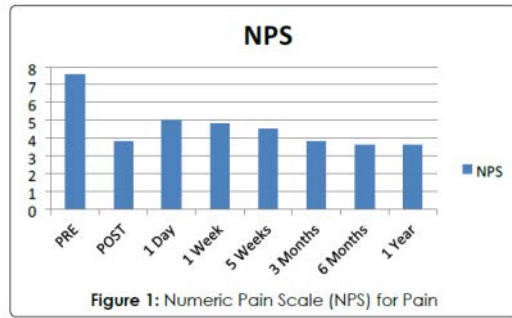


Figure 1: Numeric Pain Scale (NPS) for Pain

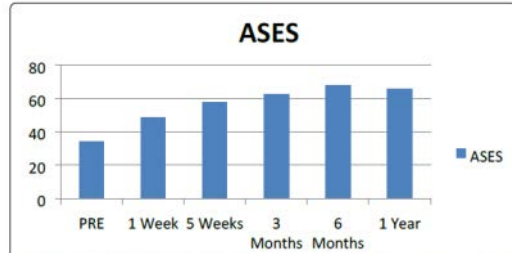

Figure 2: American Shoulder and Elbow Surgeon (ASES) Score

- No post-procedural complications or adverse events
- Sig improvements in all measured scores over all time points
- VAS AVG change: 7.3 to 3.5
- ASES AVG change: 37.7 to 89.2

Striano Roet, Malanga GA, Bilbool N, Azotullah, K. (2018) *J of Ortho Spine and Sports Med.* 2:1 014

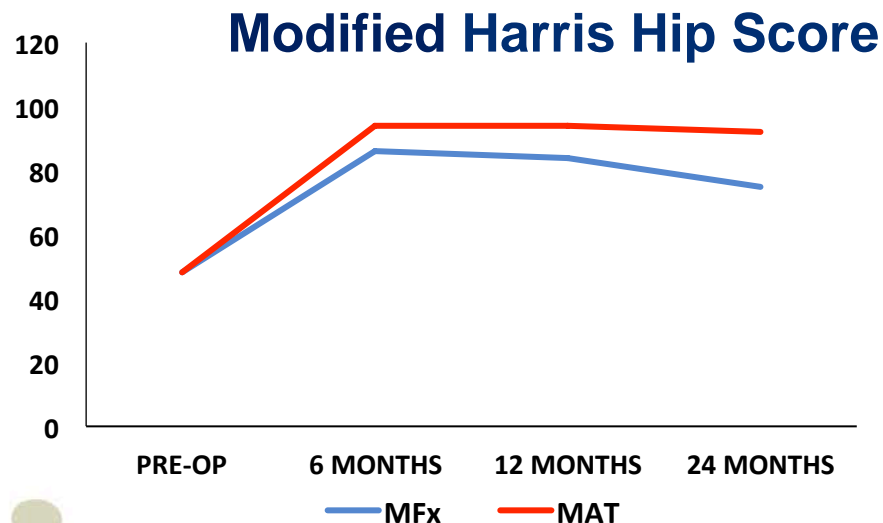
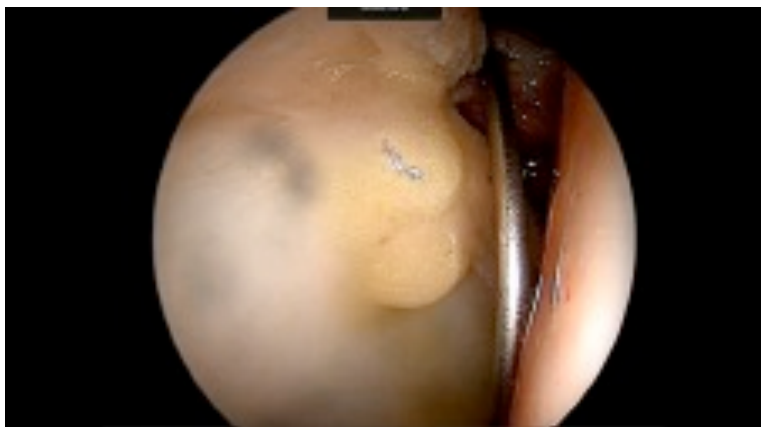Adipose Tissue Derived Mesenchymal Stem Cell for the Treatment of Chondral Lesions in The Hip.

A 2 year follow-up comparison study with microfractures –
Dr. A. Fontana – COF Lanzo Hospital – Como - Italy

AAOS/ ORS 2017 Award Winning Presentation

194 patients with acetabular chondral lesion grade III and IV:

- 77 treated with arthroscopic microfractures (MFx)
- 117 with arthroscopy+Lipogems (MAT)
- Mean patient age at surgery was 38 ± 10 (19-54 years) for MFx and 39 ± 9 (18-50 years) for MAT
- Mean lesion size was 3.6 ± 1.4 cm² (2-8 cm²) for MFx and 3.2 ± 1.5 cm² (2-8 cm²) for MAT



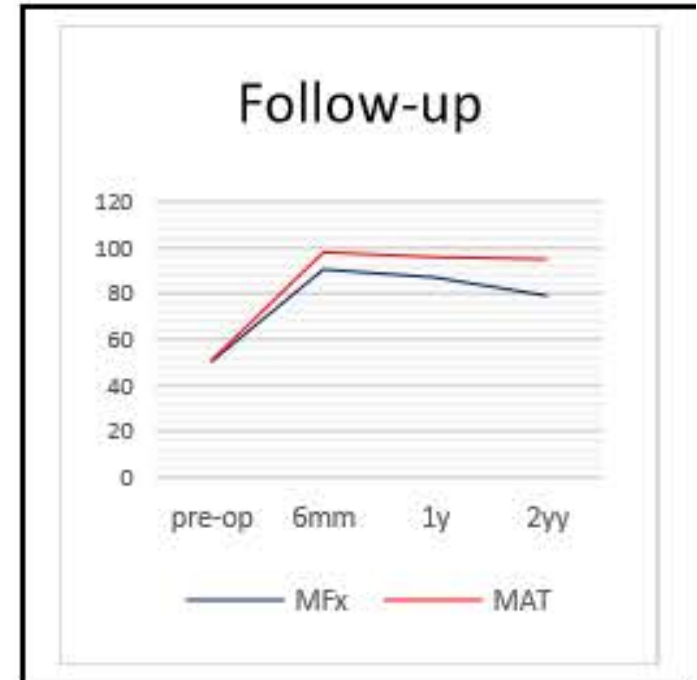
Results

Harris Hip Score

- Baseline Harris Hip Score was 48 ± 5 for Microfx and 48 ± 6 for Lipogems
- Both MFx and Lipogems significantly improved the clinical status at 6 months (mHHS 86 ± 9 /MFx - 94 ± 8 /MAT) and 1 year (mHHS 84 ± 6 /MFx - 94 ± 4 /MAT).
- Over the 2 years period, a progressive decrease in functionality was measured in the MFx group, while the positive outcomes of the MAT group remained stable (mHHS 75 ± 8 /MFx - 92 ± 6 /MAT).

Conversion to a THA

- No conversion to total hip arthroplasty (THA) was observed in the MAT
- THA was necessary in 10 (7.8%) of the patients of the Microfx group.

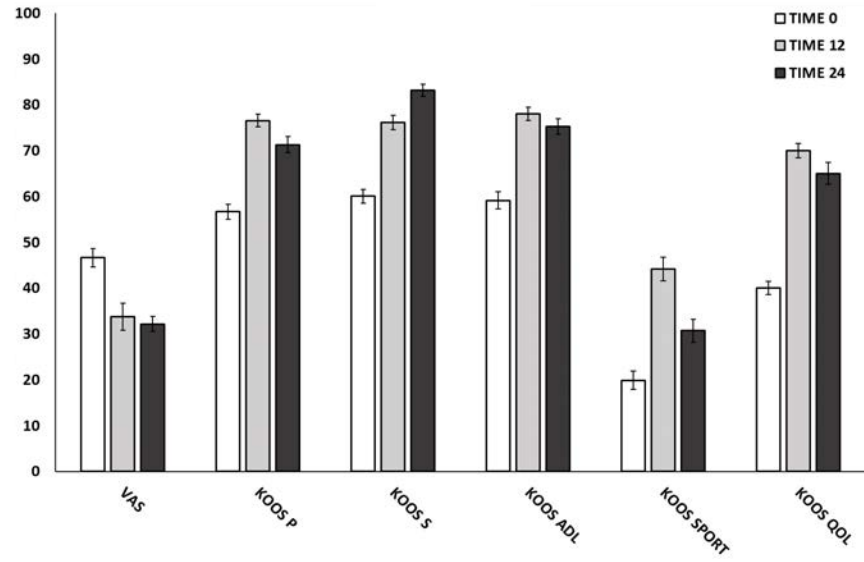


LIPOGEMS® injections for the treatment of knee chondropathy: 2 years follow up

Dr. Konrad Slynarski - Orthopedic Surgeon - Warsaw, Poland

Over **300** procedures with **LIPOGEMS** since **2014**

- Intra-articular injections in osteoarthritis treatment (even to 6 big joints during one procedure; various joints)
- During the surgical procedure:
 - around the injured ligaments and tendons
 - after ACL/PCL reconstruction
 - after meniscal suturing
 - around the surgical wound
 - into the osteotomy gap



Significant increase in KOOS scores - The improvement of the symptoms occurred few days after treatment and increased steadily throughout the whole period of the study.

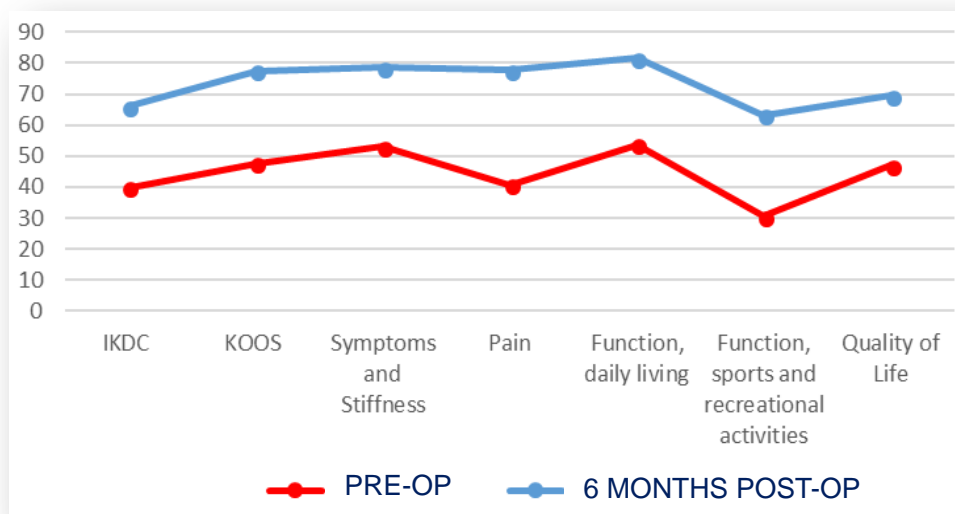
VAS (Visual Analog Scale) **PAIN SCALE** decreased from SEVERE to MILD

Rational on the Use of Processed Lipoaspirate Containing Mesenchymal Stromal Cells from the Adipose Tissue and Stromal Vascular Fraction and Short-term Clinical Assessment

Prof. Catani Fabio - University of Modena and Reggio Emilia, Polyclinic of Modena, ITALY

43 patients (2 KL grade III and 41 grade IV) treated with arthroscopy + Lipogems

- 16 patients had GOOD/EXCELLENT results (KOOS>80, IKDC>70)
- 23 patients had MODERATE results (KOOS 60-80, IKDC 50-70)
- 2 patients had SUFFICIENT results (KOOS<60, IKDC<50)
- 2 patients failed (TKA)

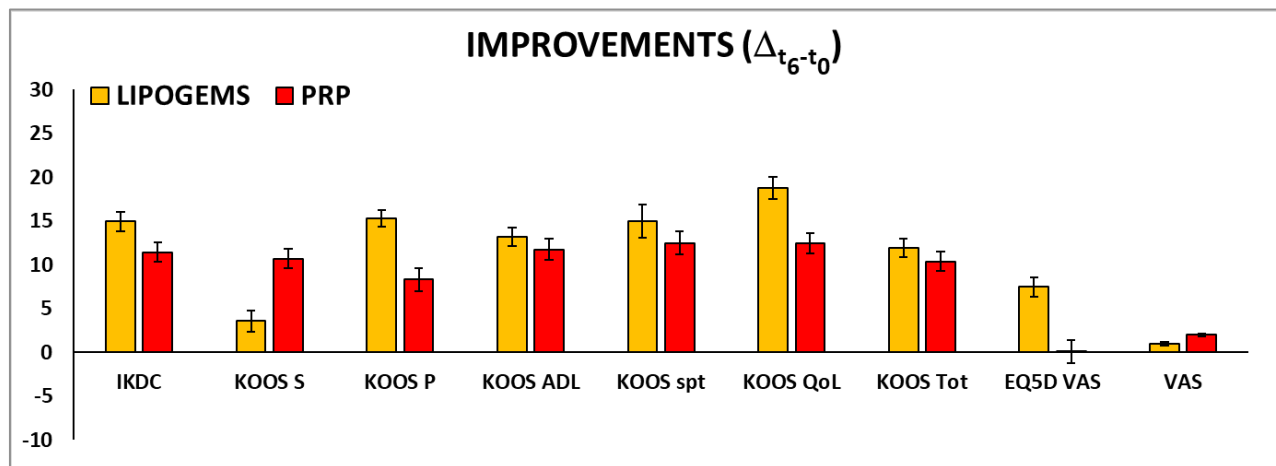


A SINGLE BLIND, RANDOMIZED, CONTROLLED STUDY OF A SINGLE, INTRA-ARTICULAR INJECTION OF AUTOLOGOUS MICRO-FRAGMENTED ADIPOSE TISSUE VS. PRP IN PATIENTS WITH OSTEOARTHRITIS OF THE KNEE

Prof. S. Zaffagnini – Rizzoli Institute – Bologna, ITALY

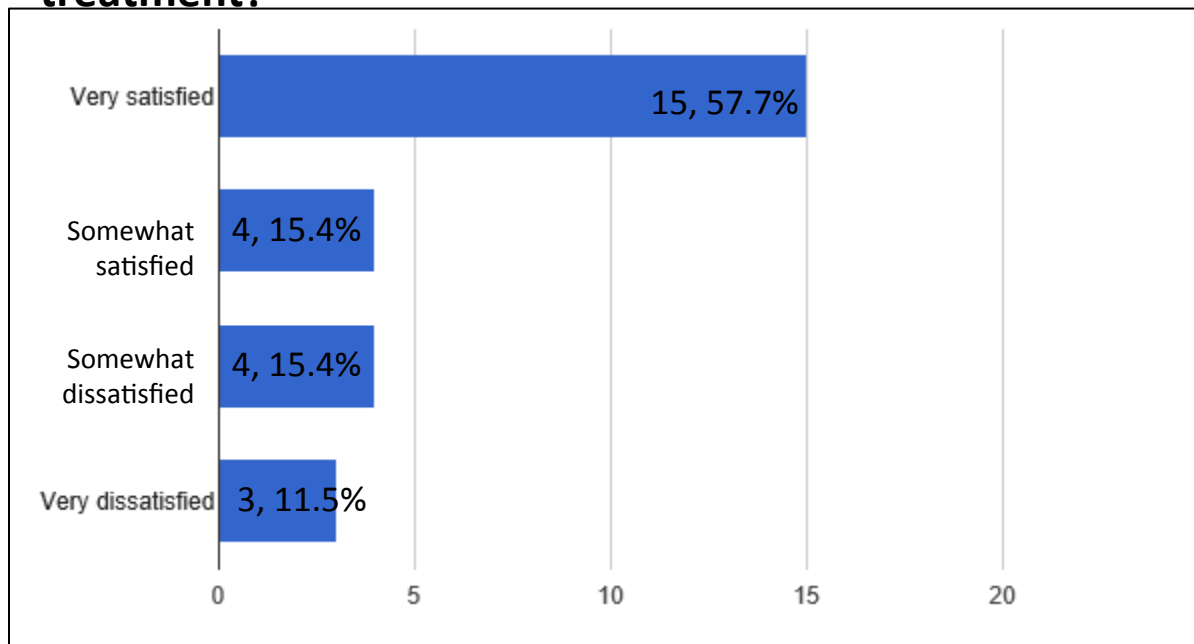
PRELIMINARY RESULTS AT 6 MONTHS

118 OA patients
LIPOGEMS VS PRP
KL I-IV
F-U 3, 6, 12, 24 M

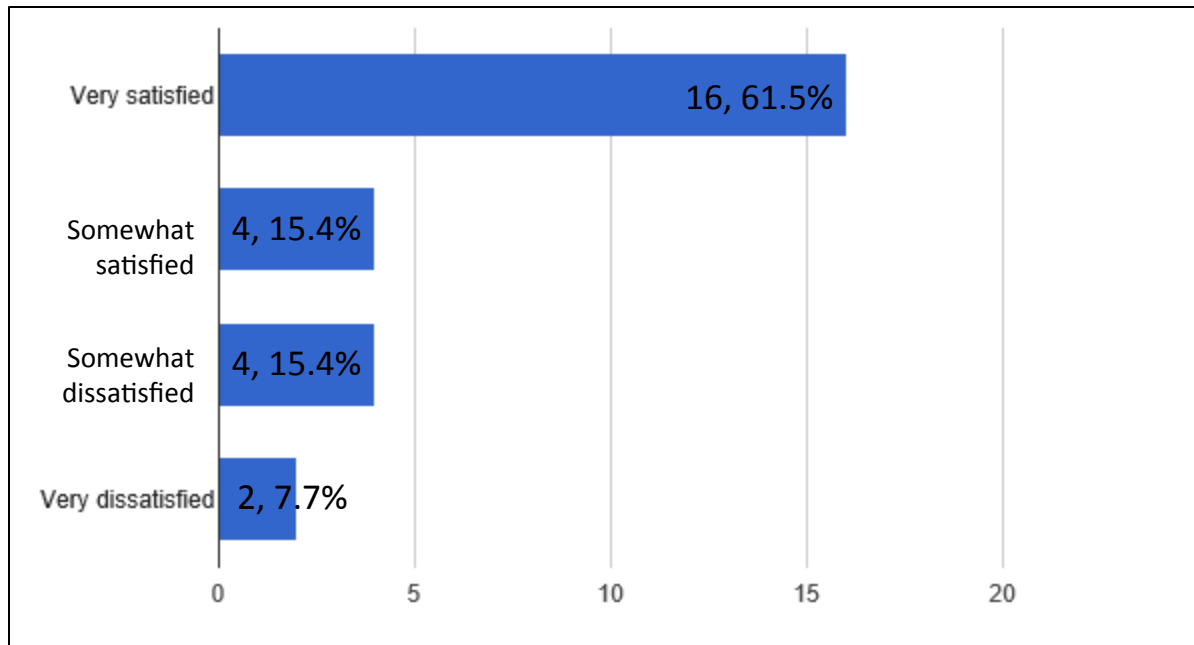


All patients have been treated ... WAITING FOR 1 and 2-YEAR DATA

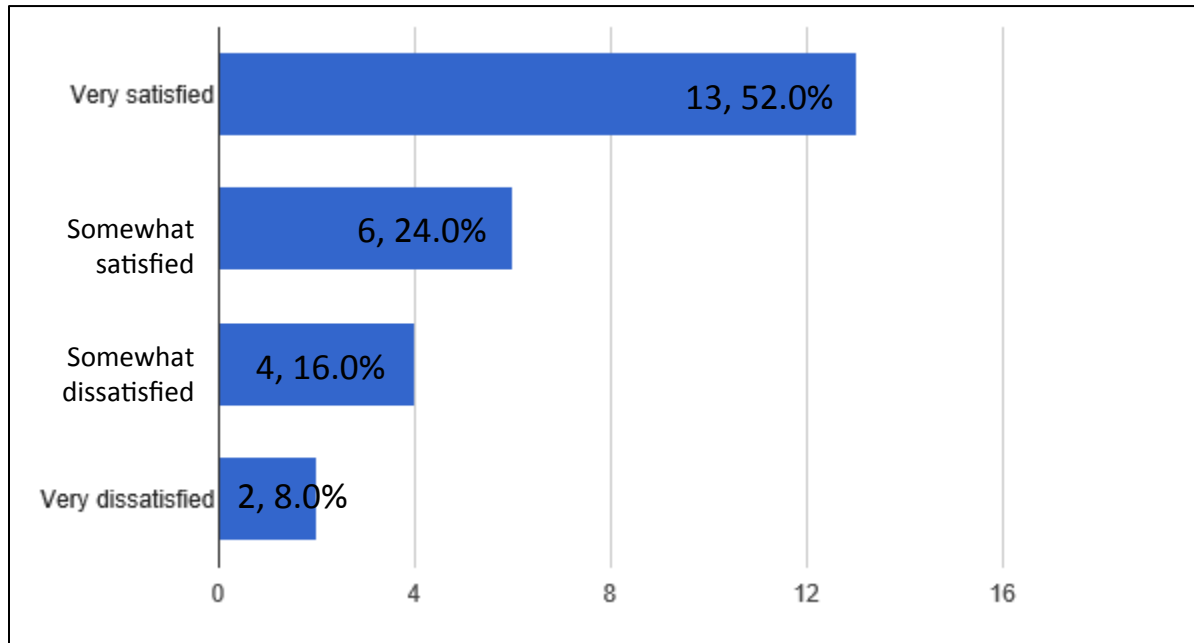
How satisfied are you with the results of your treatment?



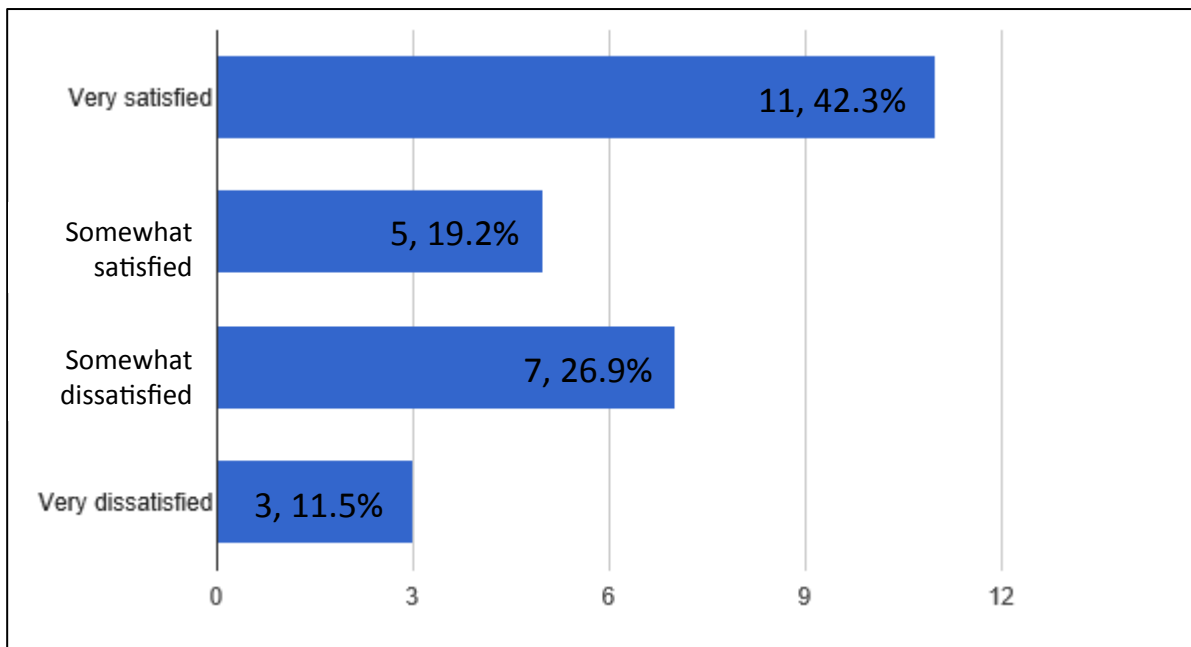
How satisfied are you with the results of your treatment for improving pain?



How satisfied are you with the results of your treatment for improving your ability to do home or yard work?



How satisfied are you with the results of your treatment for improving your ability to do recreational activities?



Owusu-Akyaw, K.et al. Adipose Derived Mesenchymal Stem Cells and Arthroscopy Surgery. Duke Orthopaedic Journal. Vol 7. 34-38. June-July 2017

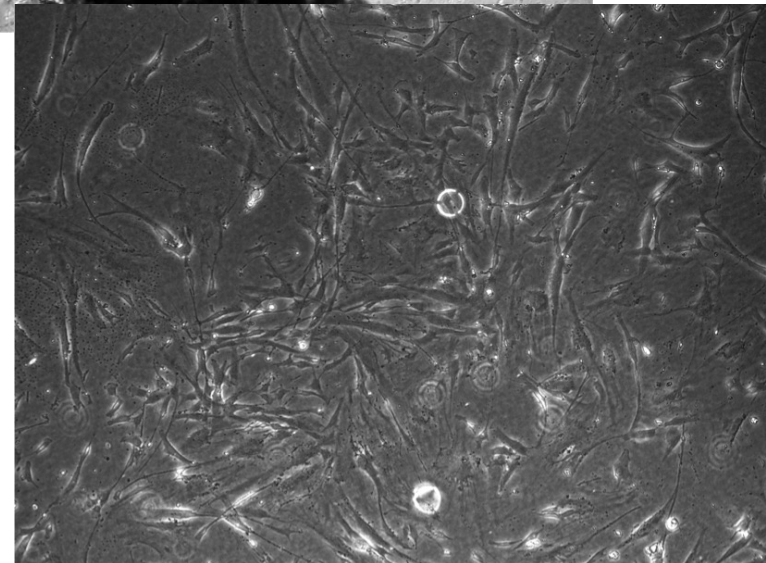


Safety Study:

- Abdominal Pain/Discomfort 30%
- Ecchymosis 20%
- 20% Contralateral injection soreness
- No infections
- No wound complications
- No recipient issues



Hilton Study

- 10 Samples
- Clusters of Adipocytes
- 5-15 million Cells
- 87-90% Viability
- Cells from Cultures resemble MSCs
- Sorting ongoing



New GID Trial!

- New Technology for MSC concentration—SVF
- 50-100M Cells!!
- Enzymatic separation/concentration
- NOT FDA approved
- Prospective Randomized Trial vs Placebo
- MSKI Team in Multi-center trial
- Promising!



What Have We Learned??????

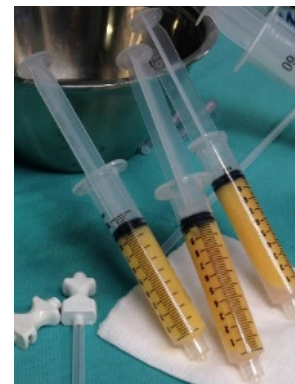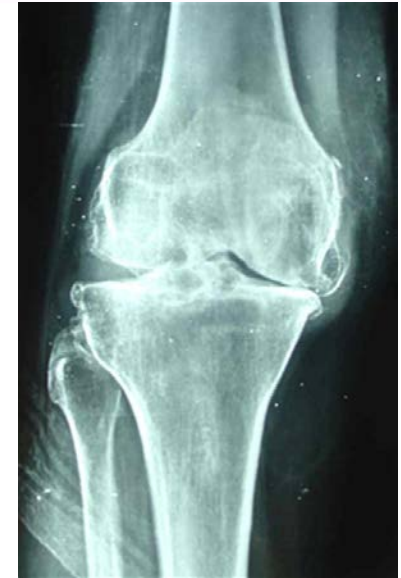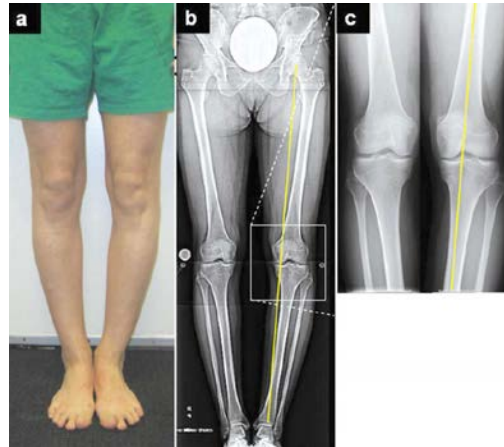
- Bimodal Response
 - Exosome 6 wks
 - Cellular 3-4 months
- Liposuction
 - Technique
 - Binder 48hrs
- Indications
 - Shoulder OA
 - Soft-Tissue Healing
 - Chondral Inj Hip
 - MFx Plus?



Bottom Line

Does This Work?????

- Promising!
- Safe Treatment
- Pain relief Solid
- Indications
 - Early Knee OA (KL 3)
 - Hip Chondral Inj
 - Soft-Tissue Healing
- Technique
 - Liposuction
 - Rehabilitation





THANK YOU!!