

# Managing patients with high-risk breast lesions, precursors on the breast neoplasia pathway

Katherine B. D'Antonio, PhD, PA-C; Meaghan McGuire, CRNP; Karlyn Rupert, PA-C

## ABSTRACT

Breast cancer remains the most commonly diagnosed cancer among women. Imaging abnormalities may be noted on routine breast cancer screenings and require biopsy for further evaluation. Atypia and carcinoma in situ are nonmalignant lesions identified via breast biopsy and are associated with an increased risk of invasive carcinoma. Because of the lack of specialized breast cancer prevention and risk reduction programs, patients may not be able to access optimal management of the various subtypes of atypia and carcinoma in situ. By understanding the pathology of high-risk breast lesions and the resulting elevated cancer risk, healthcare providers, specifically primary care providers, can better counsel, manage, and treat patients to provide comprehensive quality care.

**Keywords:** breast cancer, atypia, carcinoma in situ, high risk, invasive carcinoma, management

## Learning objectives

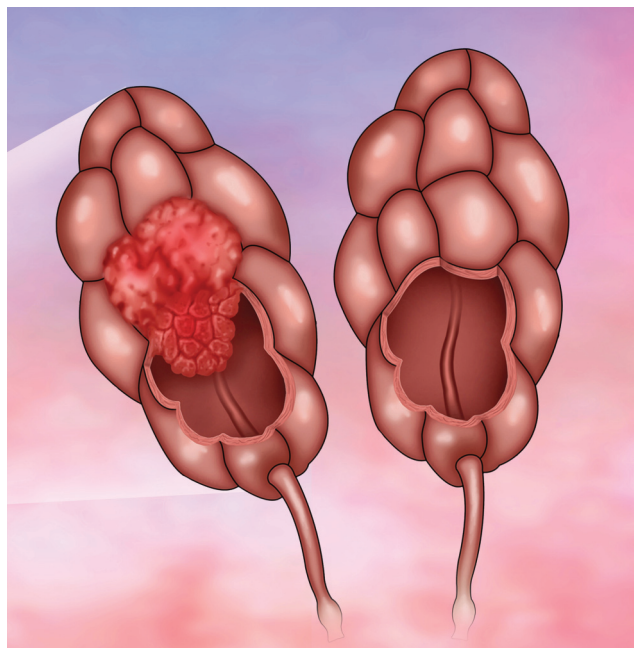
- Identify risk related to various breast pathologies and their corresponding primary management intervention and future cancer risk.
- Understand the role of risk prediction models to assess an individual's breast cancer risk.
- Review treatment options for risk-reducing medication for pre- and post-menopausal women, as well as the adverse reactions associated with each risk-reducing medication.

Breast cancer remains the most commonly diagnosed cancer among women in the United States, with an expected 281,550 new diagnoses of invasive cancer and 49,290 diagnoses of ductal carcinoma in situ in 2021.<sup>1</sup> Proactive breast cancer screening is a fundamental component of women's preventive health. During the evaluation of concerning mammographic findings, several nonmalig-

In the Womens Cancer Center at UPMC Magee Womens Hospital in Pittsburgh, Pa., **Katherine B. D'Antonio** is a senior PA, **Meaghan McGuire** is an NP, and **Karlyn Rupert** is a senior PA. The authors have disclosed no potential conflicts of interest, financial or otherwise.

DOI:10.1097/01.JAA.0000742948.34484.aa

Copyright © 2021 American Academy of PAs



© ILLUSMEDICAL/SHUTTERSTOCK.COM

nant breast lesions may be identified on needle biopsy. Patients with atypical ductal hyperplasia (ADH), atypical lobular hyperplasia (ALH), and lobular carcinoma in situ (LCIS) are known to have elevated future risk of invasive breast cancer.<sup>2</sup> For women with a history of atypia or lobular carcinoma in situ, referral to a specialized breast cancer risk assessment program for education and management is beneficial. Unfortunately, this type of specialized resource is not universally accessible and clinicians in other specialties, such as primary care, gynecology, or surgery, may be called upon to provide guidance. This article describes two categories of lesions in the breast cancer neoplasm pathway—atypias and lobular carcinoma in situ (LCIS)—and current recommendations on care, screening, and preventive strategies (Table 1).

The hallmark of atypias and carcinoma in situ (CIS) is disordered overgrowth; the distinction between the two categories lies in the location of origin (ducts or lobules) and the volume of affected tissue with CIS involving a larger area. Initial diagnosis of atypia or CIS most often is made by a pathologist evaluating tissue obtained by a needle biopsy ordered to evaluate concerning radiographic

### Key points

- Atypia and LCIS are important markers of elevated future breast cancer risk.
- Risk-reducing medication and lifestyle modification can effectively reduce future breast cancer risk for appropriate patients.
- Counseling by a healthcare provider trained in cancer risk assessment ensures that patients receive the most up-to-date recommendations about lifestyle, screening, and risk-reducing therapies.

or physical examination findings. The recommendation to biopsy is based on elevated concern for invasive cancer in the breast (Table 2). When atypia and LCIS (that is, not cancer) are found on core needle biopsy, clinicians have a few considerations:

- Did the needle biopsy miss a cancer? Will the lesion be upgraded to cancer on surgical excision?
- How likely is the finding identified (atypia or LCIS) to progress or develop into cancer if not excised?
- Is the patient's risk for future breast cancer in either breast (not related to a progression from the current lesion) increased because of the history of atypia/LCIS? Think about history of atypia and LCIS as a marker of increased risk, just like a hereditary mutation might indicate a person is at elevated risk.

### ATYPICAL DUCTAL HYPERPLASIA

ADH is a nonobligate precursor lesion, meaning it can, but does not always, progress to cancer. If left unexcised, ADH will eventually progress to in situ or invasive cancer in about 30% of patients.<sup>3,4</sup> ADH is similar to low-grade ductal carcinoma in situ (DCIS), also called stage 0 breast cancer. Both ADH and DCIS are made up of atypical epithelial cells. ADH differs in the extent of disease involving less than 2 mm or fewer than two glands. ADH is the most common of the lesions discussed in this article, identified on 10% of biopsies.<sup>3</sup> Excisional biopsy is recommended when ADH is diagnosed on needle biopsy because of the concern for upgrade to in situ or invasive cancer is significant, reported as 15% to 30%.<sup>3</sup> Upgrading is a

concept that refers to the diagnosis of cancer at the time of surgical excision when no cancer was detected by needle biopsy. Put another way, risk of upgrade indicates the likelihood that needle biopsy missed an already existing adjacent cancer. Relative risk of developing future breast cancer is about fourfold higher for patients diagnosed with atypia.<sup>5</sup> Extent of involvement is related to future cancer risk and patients with focal ADH have lower risk than those with a higher burden of atypia.<sup>6</sup> Due to elevated future breast cancer risk, all patients diagnosed with ADH should receive breast cancer risk counseling and consider risk-reducing medication.

### ATYPICAL LOBULAR HYPERPLASIA

Like ADH, ALH is a nonobligate precursor lesion. These lesions are characterized by disordered proliferation in the terminal ductal lobular unit, with overgrowth that fills and involves less than 50% of the acini of a terminal ductal lobular unit. ALH is relatively rare, occurring in about 1% of needle biopsies.<sup>2</sup> When ALH is found on needle biopsy, surgical excision often is recommended because of the concern for upgrade with excision biopsy. A growing body of data demonstrate that serial imaging (follow-up imaging at 6 and 12 months) is sufficient to monitor ALH found on needle biopsy when the patient has no other high-risk features.<sup>7</sup> Risk of upgrade is relatively low, about 9%.<sup>2</sup> ALH has low potential to develop into a future cancer (2% or less).<sup>6</sup> Lifetime risk of in situ or invasive breast cancer is elevated at least fourfold in patients with a history of ALH.<sup>6</sup> Therefore, breast cancer risk counseling and consideration of risk-reducing medication is indicated.

### LOBULAR CARCINOMA IN SITU

As discussed above, LCIS is histologically similar to ALH in presentation but involves 50% or greater of the acini in a terminal ductal lobular unit. LCIS is seen in 0.6% to 3% of breast ultrasound and core needle biopsies.<sup>2</sup> Studies show that the rate of upgrade to invasive breast cancer on excisional biopsy varies from 6% to 25%.<sup>2,6</sup> Excisional biopsy is recommended for patients with ALH or LCIS found by MRI-guided biopsy.<sup>7</sup> Incidence of DCIS or invasive breast cancer was found to be 11.3% and 19.8% at 10 and 20 years, respectively.<sup>8</sup> Thus, future breast cancer risk in patients

**TABLE 1.** Breast lesions with elevated breast cancer risk

	Primary management	Upstage risk	Future cancer risk	Chemoprevention
ADH	Excisional biopsy recommended	10% to 15% (as high as 30%)	Fourfold increase	Encouraged
ALH	Excisional biopsy vs. serial surveillance	9%	Fourfold increase	Encouraged
LCIS	Excisional biopsy recommended	6% to 25%	Eight- to tenfold increase	Encouraged
PLCIS	Excisional biopsy—clean margins recommended	20% and higher	Insufficient data	Consider—insufficient data
FEA	6- and 12-month serial surveillance	<2%	One- to twofold increase	Not recommended

with a history of LCIS is often quoted to be at least 1% per year for life. The significance of the cumulative annual risk is easily appreciated when considering that predicted lifetime risk of breast cancer for the average 40-year-old is about 13%, but 40% to 50% for a woman of the same age with a diagnosis of LCIS. As for patients with ADH and ALH, patients with LCIS should consider risk assessment counseling and risk-reducing medication. More aggressive screening with breast MRI also may be considered.

### PLEOMORPHIC LOBULAR CARCINOMA IN SITU

Pleomorphic LCIS (PLCIS) is a high-grade in situ lesion that was characterized relatively recently and is quite rare. PLCIS resembles high-grade DCIS in that cells exhibit a higher degree of nuclear pleomorphism (variation in nuclear size and shape). Accurate diagnosis is important because the limited data that exist suggest a 20% or greater upgrade rate to invasive cancer at the time of surgical resection, with high local recurrence risk.<sup>4,6,9</sup> Therefore, surgical excision with the goal of obtaining clean margins is recommended.<sup>2</sup> The aim to obtain clean margins is unique among the lesions reviewed in this article; for atypia and LCIS, the standard of care is reasonable sampling to demonstrate that cancer has not been missed. Because of the rarity and relative novelty of PLCIS, no large prospective trials have been conducted on treatment or prognosis. Additional research is needed to better characterize this lesion and guide treatment with adjuvant radiation and endocrine therapy.

### FLAT EPITHELIAL ATYPIA

Flat epithelial atypia (FEA) is a relatively rare type of atypia often identified with ALH, ADH, LCIS, or invasive cancer. Management is dictated by the higher-risk lesion or as needed to fully vet concerning imaging findings. When FEA is seen in isolation on needle biopsy, it has low likelihood of upgrade on excisional biopsy and has low future malignant potential.<sup>2</sup> Therefore, FEA alone need not be excised.<sup>5,10,11</sup> Current practice is to monitor FEA with serial imaging at 6 and 12 months to document stability. The patient's risk for future breast cancer is not significantly elevated (one- to twofold increase).<sup>4</sup> No risk-reducing medication is recommended for patients with FEA alone.

### RISK PREDICTION MODELS

Risk assessment calculators have been developed to help clinicians make more accurate estimates of breast cancer risk and to guide management. The Gail Breast Risk Assessment Tool and Tyrer-Cuzick Breast Cancer Risk Evaluation Tool estimate a patient's breast cancer risk, providing 5-year, 10-year, and/or lifetime risk.<sup>12</sup> Age, race, childbirth history, breast density, and menopausal status are a few factors assessed by these risk calculators. This information can guide breast cancer screening recommendations and prescription of risk-reducing medication. The Gail tool assesses patient eligibility for risk-reducing medicines, but is not

**TABLE 2. Types of breast biopsies**

#### Needle

- Most often initial biopsy performed
- Samples a relatively small amount of breast tissue
- Performed in radiology based on concerning physical examination or radiographic findings
- May be guided by ultrasound, stereotactic, tomosynthesis, or MRI

#### Excisional

- Usually performed after needle biopsy
- Samples a larger amount of breast tissue than needle biopsy
- Surgical procedure performed to more fully evaluate an area of the breast due to residual concern for cancer
  - Needle biopsy is not concordant with imaging: pathology does not explain radiographic findings
  - Needle biopsy findings show atypia or LCIS and there is concern for missed cancer in the adjacent tissue (that is, upgrade).

validated for women under age 35 years and has limited utility for non-White women and those with a strong family history of breast cancer.<sup>3</sup> The Tyrer-Cuzick tool is useful in predicting risk related to family history of breast cancer and can be used in women under age 35 years. This tool overestimates cancer risk related to atypical hyperplasia, LCIS, and breast density. Both tools can be used to identify patients who might benefit from risk-reducing medications based on 5-year or 10-year breast cancer risk.<sup>12</sup>

### BREAST MRI FOR HEIGHTENED CANCER SCREENING

Women may be at elevated risk of breast cancer due to LCIS, family history of breast cancer, hereditary cancer syndrome, or history of chest (mantle) radiation. When a patient's lifetime risk breast cancer exceeds 20%, consider a screening breast MRI.<sup>13</sup> MRI is preferred for younger patients at significantly elevated risk of breast cancer, most often those with strong family history and hereditary cancer syndromes. Breast cancer screening can start 5 to 10 years before the youngest breast cancer diagnosis in the family but not before age 25 years.<sup>13</sup> For patients starting screening at ages 25 to 29 years, annual breast MRI is the preferred test; for patients age 30 years and older, annual mammogram should be ordered in addition to breast MRI.<sup>13</sup> MRI screening has higher sensitivity than mammogram, but also a higher false-positive rate (biopsies for lesions that do not prove to be cancer) and is costly.<sup>14</sup> Women with a history of atypia alone generally are not recommended for annual screening MRI, although it may be considered for those with atypia and a family history of breast cancer. For women diagnosed with LCIS, MRI may be indicated regardless of family history of breast cancer.

### RISK-REDUCING MEDICATIONS

Endocrine therapies that are used as chemoprevention for patients with elevated breast cancer risk include tamoxifen, raloxifene, exemestane, and anastrozole. Anyone with a

history of ADH, ALH, or LCIS can consider taking a risk-reducing medication, as can anyone whose 5-year risk of breast cancer is greater than 3%.<sup>12</sup> Key features of each medication that influence drug selection are worth reviewing.<sup>15</sup> Therapy should be delayed until after childbearing and typically, none of these medications are considered until patients are at least age 35 years.<sup>15</sup> Premenopausal patients must use an effective nonhormonal contraception.

Selective estrogen receptor modulators (SERMs) such as tamoxifen and raloxifene competitively inhibit estrogen from binding to estrogen receptors. The NSABP P-1 study demonstrated that tamoxifen (20 mg taken daily) was associated with a 50% drop in breast cancers for pre- and postmenopausal women who completed a mean of about 4 years of tamoxifen.<sup>15,16</sup> Adverse reactions to tamoxifen include deep vein thrombosis, pulmonary embolism, and, in postmenopausal women, uterine cancer.<sup>16</sup> Tamoxifen is the only approved treatment option available for premenopausal women and can be recommended for risk reduction in postmenopausal women who have had a hysterectomy.<sup>16</sup> More recently, a small study has suggested that 5 mg of tamoxifen daily for 3 years has similar efficacy and improved tolerance.<sup>17</sup> Prescribing low-dose tamoxifen is not common practice although it is a reasonable alternative for patients struggling to decide between discontinuing therapy or continuing full-dose therapy with bothersome adverse reactions.<sup>17</sup>

Raloxifene (60 mg daily) has been shown to reduce the risk of invasive cancer just slightly less than tamoxifen over the same 5-year course, and is less effective than tamoxifen in reducing risk of in situ disease.<sup>12</sup> Studies with raloxifene have only been done with postmenopausal patients; thus, raloxifene is generally not offered to premenopausal women.

SERMs are associated with a slightly higher risk of a thromboembolic event; therefore, SERMs are contraindicated for those with a history of deep vein thrombosis, stroke, or pulmonary embolism.<sup>15</sup> Evidence is limited to support giving patients with factor V Leiden or prothrombin gene mutation tamoxifen without further increasing their clot risk, although they should receive with proper counseling. Debate continues over whether CYP 2D6 inhibitors, including many of the selective serotonin reuptake inhibitors (SSRIs), reduce the efficacy of tamoxifen. Careful consideration must be taken when prescribing tamoxifen to women on SSRIs.<sup>13</sup> Other common adverse reactions to tamoxifen and raloxifene include vasomotor symptoms, vaginal discharge, and leg cramps.<sup>16</sup>

The aromatase inhibitors anastrozole and exemestane also are options for chemoprevention in postmenopausal high-risk patients.<sup>18</sup> Aromatase inhibitors inhibit the peripheral conversion of androgens to estrogens by blocking the enzyme aromatase. Exemestane (25 mg daily for 5 years) reduces the risk of invasive breast cancer by 65%.<sup>18</sup> Anastrozole (1 mg daily for 5 years) reduced the risk of invasive and in situ breast cancers by more than 50% compared with placebo.<sup>19</sup> This 5-year course of aromatase inhibitors shows continued

risk reduction in contralateral breast cancer beyond 5 years.<sup>18</sup> Common adverse reactions to aromatase inhibitors include a decrease in bone mineral density, arthralgias, vaginal dryness, and vasomotor symptoms.<sup>18</sup> Low bone density does not preclude use of an aromatase inhibitor; however, concurrent treatment with bisphosphonates is recommended for patients with osteoporosis or at high risk by Fracture Risk Assessment Tool (FRAX). Close monitoring with dual energy radiograph absorptiometry (DEXA) scan is recommended for patients before starting an aromatase inhibitor and every 2 years while on therapy.<sup>8</sup> Encourage weight-bearing exercise and a calcium-rich diet. Although endocrine therapy often is given for 10 years to patients with a history of breast cancer, no data exist to support extending therapy beyond 5 years for the purpose of risk reduction.

Lifestyle modifications to manage breast cancer risk include breastfeeding and avoiding hormone replacement therapy.<sup>13</sup> Patients should maintain a healthful body weight, avoid smoking, and participate in 150 minutes per week of moderate-vigorous physical activity.<sup>8,20</sup> Limiting alcohol consumption and animal protein in the diet, particularly red meat and charred/blackened meats, may help reduce breast cancer risk.<sup>8,20</sup>

Anecdotally, some of the most reluctant patients to consider risk-reducing medication are otherwise healthy young women who take no medications and have a healthful lifestyle. These patients may find it difficult to take a daily medication for a problem that seems intangible. Use shared decision-making and, for these young patients especially, use annual follow-up as an opportunity to reconsider a risk-reducing medication. Some patients who have subsequent biopsies or a change in family history may experience a further increase in their breast cancer risk. Other patients may later reconsider medication as 5-year risk rises with age or if their mindset changes toward medication. Fear of adverse reactions deters many patients from starting medication and encouraging a trial to establish tolerability can convince some to start who might otherwise decline. For those with adverse reactions, a conversation balancing the benefits of risk reduction with quality of life is important. Some patients may be eligible to consider an alternate medication either immediately or later. The benefit of lifestyle modification should be particularly emphasized for those unable to tolerate risk-reducing medications.

## DISCUSSION

Breast cancer screening remains an essential component of preventive health. Breast cancer risk management programs most often are available at large medical centers, limiting access for many patients. To ensure all patients receive appropriate counseling, clinicians must be familiar with the nonmalignant breast lesions associated with elevated future breast cancer risk. Patient risk of future breast cancer varies depending on the type of atypia or LCIS and on other factors including family history, childbearing history,



breast density, and lifestyle. Risk prediction models can help provide patients with a more personalized estimate of breast cancer risk and inform decisions about risk-reducing medication and breast cancer screening. Consider risk-reducing medication for appropriate patients with a history of ADH/ALH or LCIS to lower risk of breast cancer. Tamoxifen is recommended for premenopausal women and postmenopausal women without a uterus.<sup>8</sup> Raloxifene, anastrozole, or exemestane are for postmenopausal women.<sup>8</sup> The benefit of risk reduction often outweighs the possible adverse reactions. Encourage patients to make lifestyle choices that mitigate breast cancer risk. Research is ongoing in this field and imperative to help reduce the prevalence of breast cancer. The incidence of breast cancer remains high and affects women often in the prime of their lives. All women at elevated risk of breast cancer should have access to optimal care, including lifestyle education, risk-reducing medication, and appropriate imaging. **JAAPA**

**Earn Category I CME** Credit by reading both CME articles in this issue, reviewing the post-test, then taking the online test at <http://cme.aapa.org>. Successful completion is defined as a cumulative score of at least 70% correct. This material has been reviewed and is approved for 1 hour of clinical Category I (Preapproved) CME credit by the AAPA. The term of approval is for 1 year from the publication date of May 2021.

## REFERENCES

1. American Cancer Society. Cancer facts and figures 2021. [www.cancer.org/content/dam/cancer-org/research/cancer-facts-and-statistics/annual-cancer-facts-and-figures/2021/cancer-facts-and-figures-2021.pdf](http://www.cancer.org/content/dam/cancer-org/research/cancer-facts-and-statistics/annual-cancer-facts-and-figures/2021/cancer-facts-and-figures-2021.pdf). Accessed March 1, 2021.
2. Lewin AA, Mercado CL. Atypical ductal hyperplasia and lobular neoplasia: update and easing of guidelines. *Am J Roentgenol*. 2020;214(2):265-275.
3. Hartmann LC, Degnim AC, Santen RJ, et al. Atypical hyperplasia of the breast—risk assessment and management options. *N Engl J Med*. 2015;372(1):78-89.
4. Ragoth CJ, O'Flynn EAM, Pinker K, et al. Second International Consensus Conference on lesions of uncertain malignant potential in the breast (B3 lesions). *Breast Cancer Res Treat*. 2019;174(2):279-296.
5. Said SM, Visscher DW, Nassar A, et al. Flat epithelial atypia and risk of breast cancer: a Mayo cohort study. *Cancer*. 2015; 121(10):1548-1555.
6. Racz JM, Carter JM, Degnim AC. Lobular neoplasia and atypical ductal hyperplasia on core biopsy: current surgical management recommendations. *Ann Surg Oncol*. 2017;24(10):2848-2854.
7. Weinfurter RJ, Patel B, Laronga C, et al. Magnetic resonance imaging-guided core needle breast biopsies resulting in high-risk histopathologic findings: upstage frequency and lesion characteristics. *Clin Breast Cancer*. 2015;15(3):234-239.
8. National Comprehensive Cancer Network. NCCN clinical practice guidelines in oncology breast cancer risk reduction. Version 1.2020. [www.nccn.org/professionals/physician\\_gls/pdf/breast\\_risk.pdf](http://www.nccn.org/professionals/physician_gls/pdf/breast_risk.pdf). Accessed February 28, 2021.
9. Desai AA, Jimenez RE, Hoskin TL, et al. Treatment Outcomes for pleomorphic lobular carcinoma in situ of the breast. *Ann Surg Oncol*. 2018;25(10):3064-3068.
10. Liu C, Dingee CK, Warburton R, et al. Pure flat epithelial atypia identified on core needle biopsy does not require excision. *Eur J Surg Oncol*. 2020;46(2):235-239.
11. Schiaffino S, Gristina L, Villa A, et al. Flat epithelial atypia: conservative management of patients without residual microcalcifications post-vacuum-assisted breast biopsy. *Br J Radiol*. 2018;91(1081):20170484.
12. Visvanathan K, Fabian CJ, Bantug E, et al. Use of endocrine therapy for breast cancer risk reduction: ASCO clinical practice guideline update. *J Clin Oncol*. 2019;37(33):3152-3165.
13. National Comprehensive Cancer Network. NCCN clinical practice guidelines in oncology breast cancer screening and diagnosis. Version 1.2020. [www.nccn.org/professionals/physician\\_gls/pdf/breast-screening.pdf](http://www.nccn.org/professionals/physician_gls/pdf/breast-screening.pdf). Accessed February 28, 2021.
14. Lee TC, Reyna C, Shaughnessy E, Lewis JD. Screening of populations at high risk for breast cancer. *J Surg Oncol*. 2019;120(5):820-830.
15. US Preventive Services Task Force. Owens DK, Davidson KW, Krist AH, et al. Medication use to reduce risk of breast cancer: US Preventive Services Task Force recommendation statement. *JAMA*. 2019;322(9):857-867.
16. Vogel VG. The NSABP Study of Tamoxifen and Raloxifene (STAR) trial. *Expert Rev Anticancer Ther*. 2009;9(1):51-60.
17. DeCensi A, Puntoni M, Guerrieri-Gonzaga A, et al. Randomized placebo controlled trial of low-dose tamoxifen to prevent local and contralateral recurrence in breast intraepithelial neoplasia. *J Clin Oncol*. 2019;37(19):1629-1637.
18. Goss PE, Ingle JN, Ales-Martinez JE, et al. Exemestane for breast-cancer prevention in postmenopausal women. *N Engl J Med*. 2011;364(25):2381-2391.
19. Cuzick J, Sestak I, Forbes JF, et al. Use of anastrozole for breast cancer prevention (IBIS-II): long-term results of a randomised controlled trial. *Lancet*. 2020;395(10218):117-122.
20. American Cancer Society. *Breast Cancer Facts & Figures 2019-2020*. Atlanta: American Cancer Society, Inc.; 2019.



Visit [www.jaapa.com](http://www.jaapa.com) to read more CME.

**CME** Choose the CME tab. Take tests online!