

Overview of Breast Reconstruction in an Oncologic Setting

Alicia M. Jones, MHS, PA-C

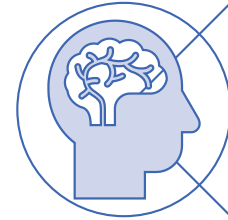Memorial Sloan Kettering Cancer Center

AAPA CME Conference on Demand

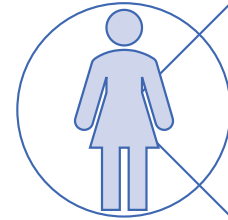
May 2021

Objectives

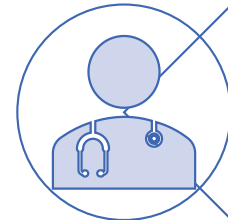
At the end of this presentation, the learner will be able to:



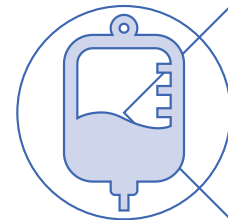
Recognize the differences between implant and autologous based breast reconstruction



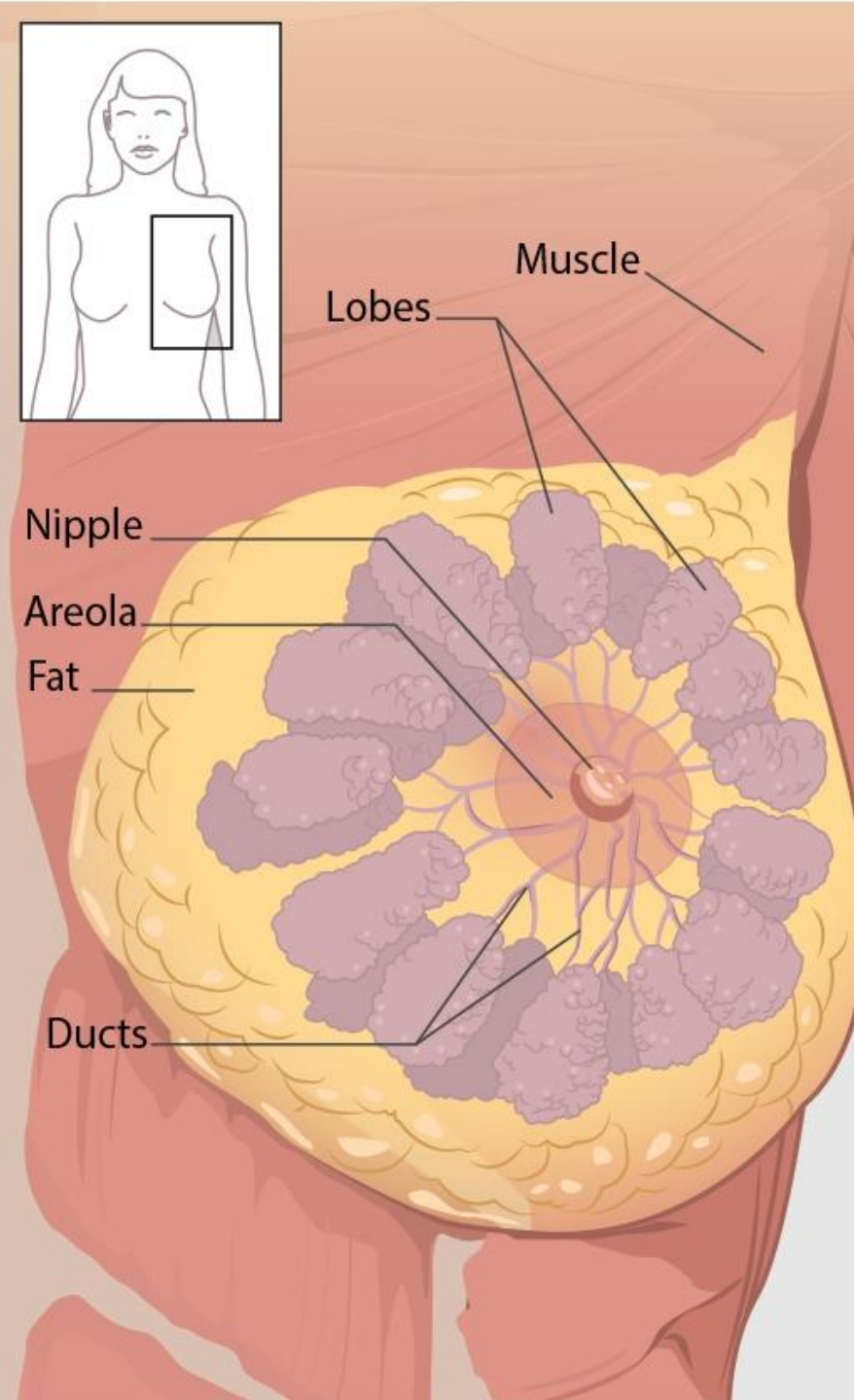
Identify ideal candidates for breast reconstruction and understand the timing around oncologic treatments.



Understand the surveillance for breast cancer in the setting of breast reconstruction



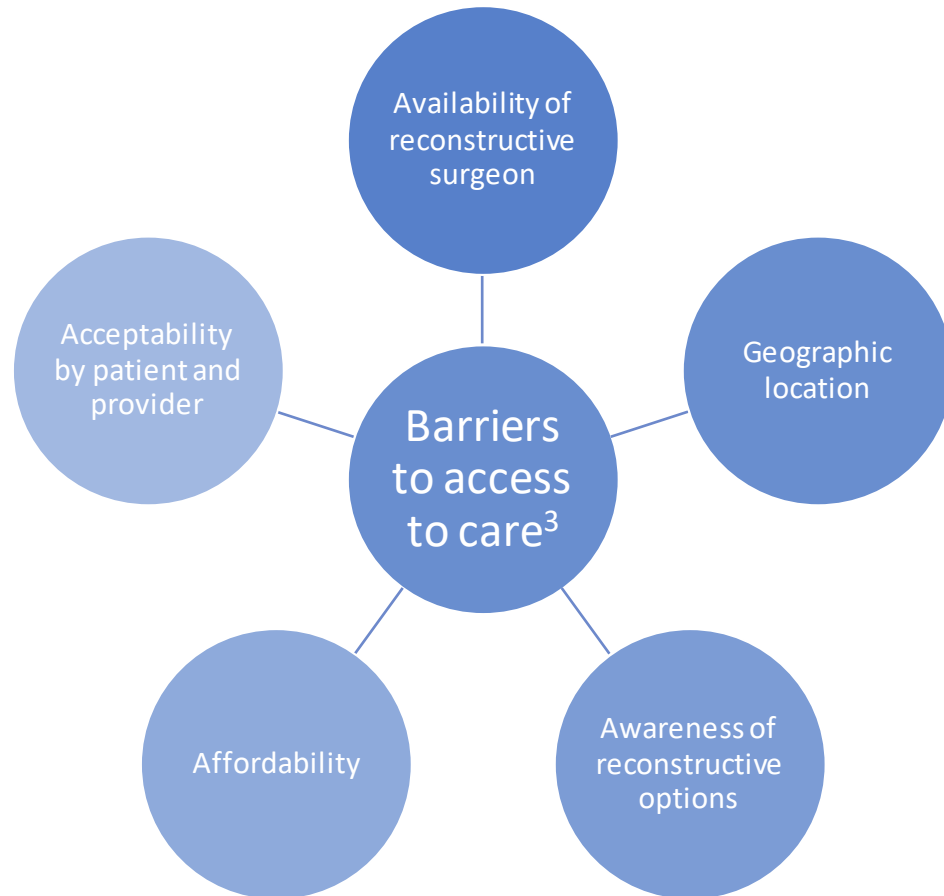
Recognize signs and symptoms of breast implant associated anaplastic large cell lymphoma



Breast Cancer

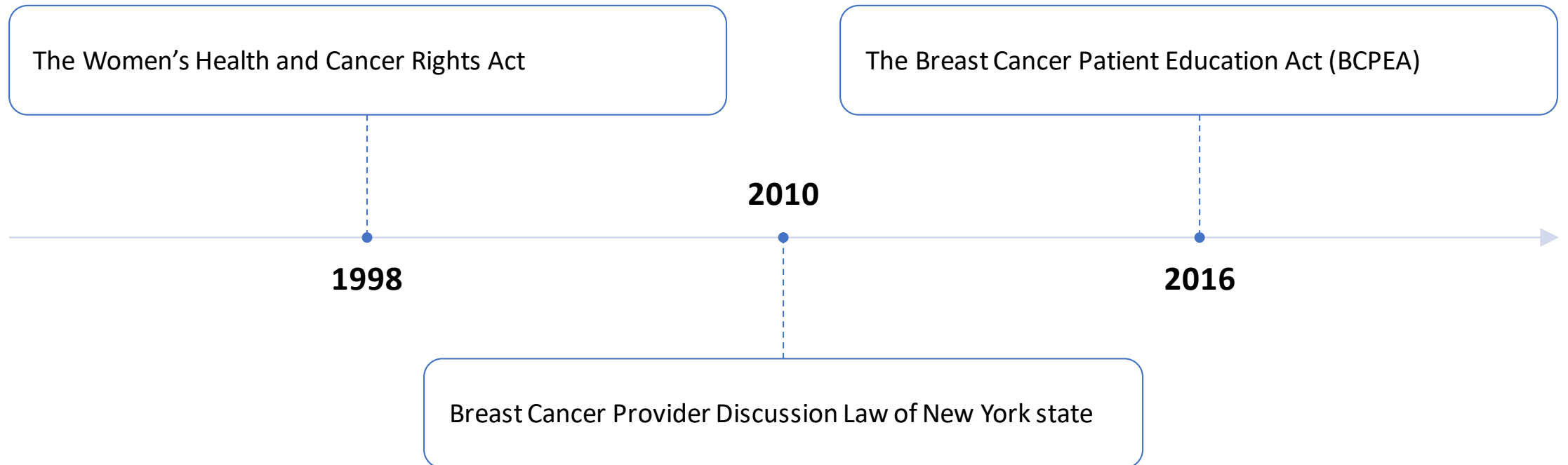
- Second most common cancer in women, after skin cancer
- In 2020, the American Cancer Society estimates
 - 276,480 new cases of invasive breast cancer
 - 48,530 new cases of carcinoma in situ
- Number of breast cancer survivors estimated at 3.5 million

Approximately 25-35% of patients having a mastectomy undergo reconstruction²




- Factors associated with not having immediate reconstruction⁴:
 - lower educational level
 - black and Hispanic race
 - increased age of patient
 - patients with a major comorbidity
 - patients requiring chemotherapy

Policies to improve access to breast reconstruction



In 2019, American Society of Plastic Surgeons (ASPS) reported 107,238 reconstructive breast procedures⁵

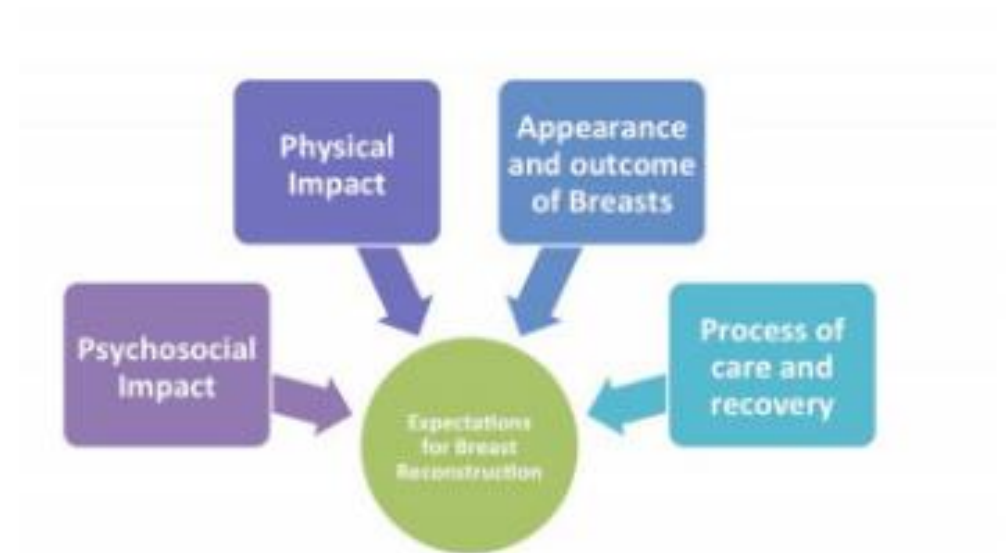


Is breast
reconstruction
safe?

- **Yes!** Breast reconstruction does not increase the risk of breast cancer recurrence
- Breast reconstruction does not delay recurrent breast cancer detection or have a negative impact on prognosis

Benefits of breast reconstruction – why do we do it?

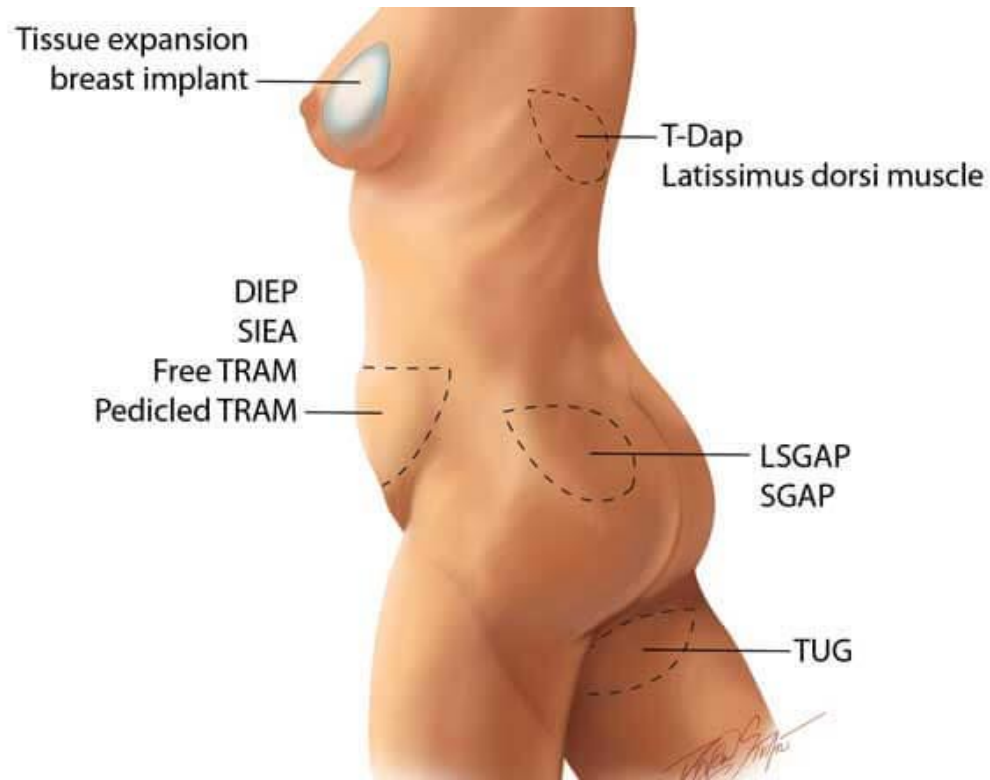
- **Breast reconstructions provide substantial psychosocial benefits for patients undergoing mastectomy**
- Breast Q is one patient reported outcome tool developed by Dr. Andrea Pusic
 - Evaluates psychosocial impact, physical impact, appearance and outcome of breast reconstruction, and the process of care and recovery



Two main ways to reconstruct the breast:

Implant
(prosthetic)
reconstruction

Autologous
reconstruction



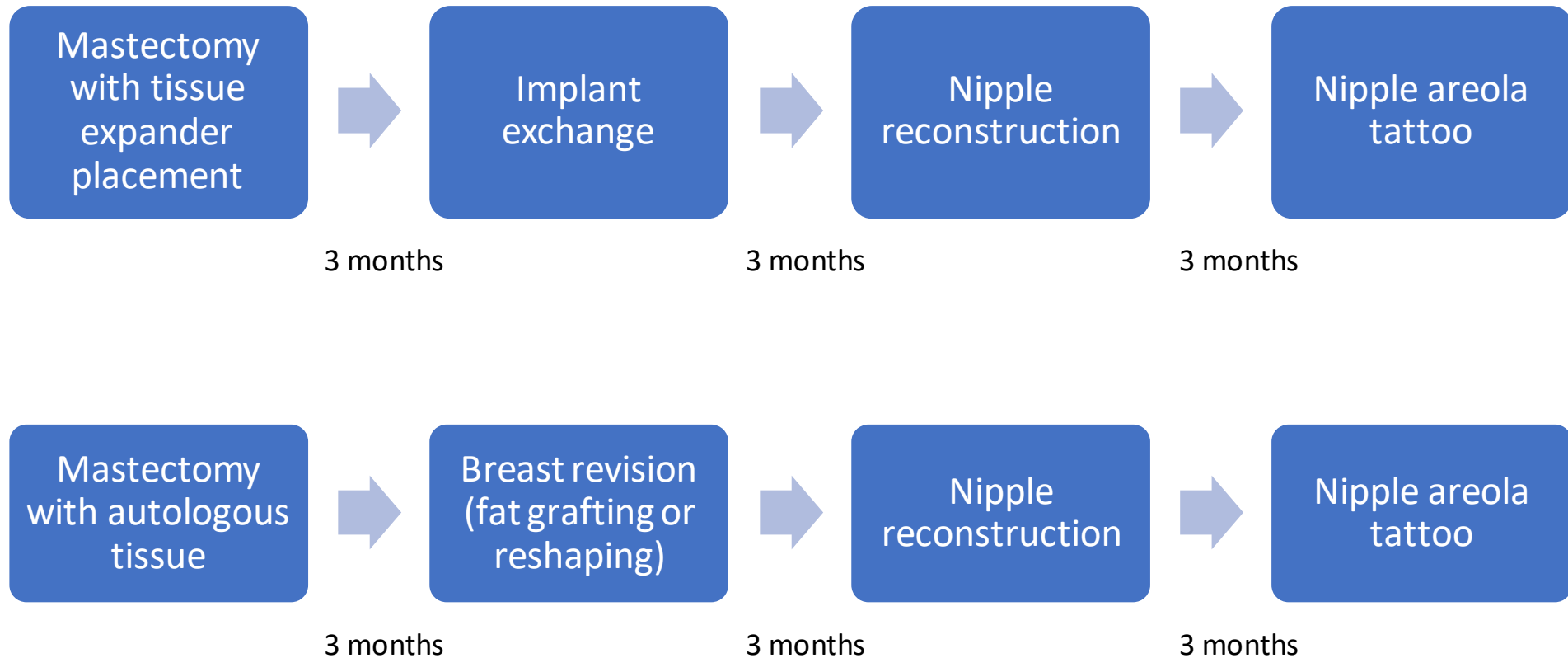
Also take into consideration timing of reconstruction:

Immediate (at the time of mastectomy) vs. delayed

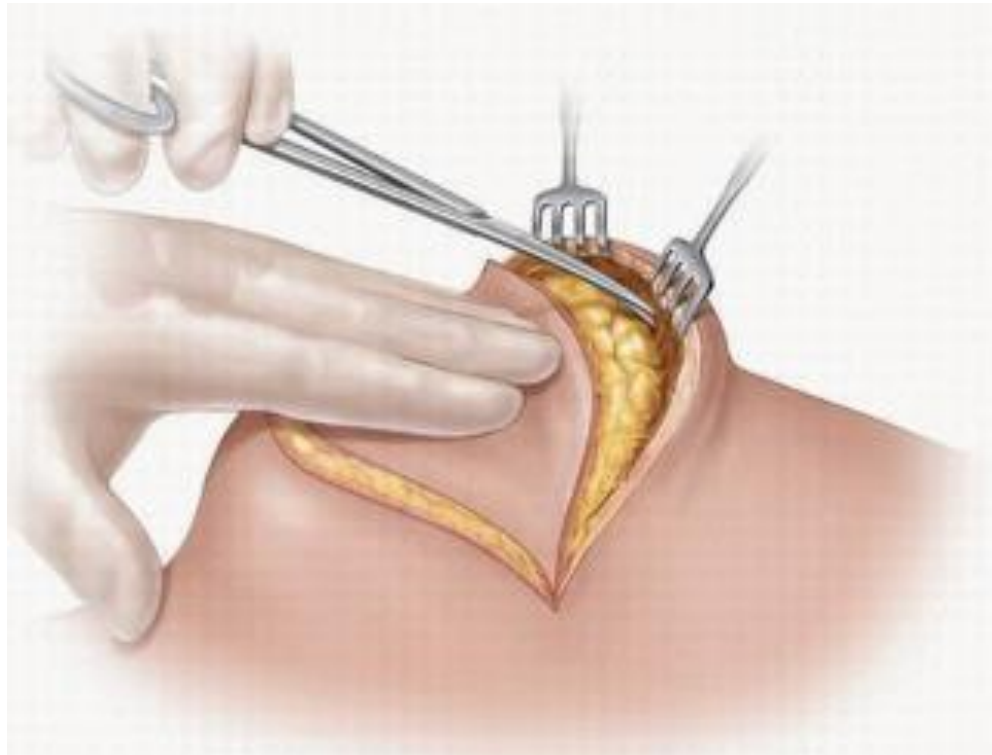Choice of breast reconstruction depends on

- Patient preferences and expectations
- Patient's diagnosis and staging
- Radiation – past history of treatment or need for XRT after surgery
- Unilateral vs. bilateral mastectomy
- Timing
- Body habitus of patient (BMI, size of breast or desired size of breast, donor sites)

Breast Reconstruction is a Process



Mastectomy

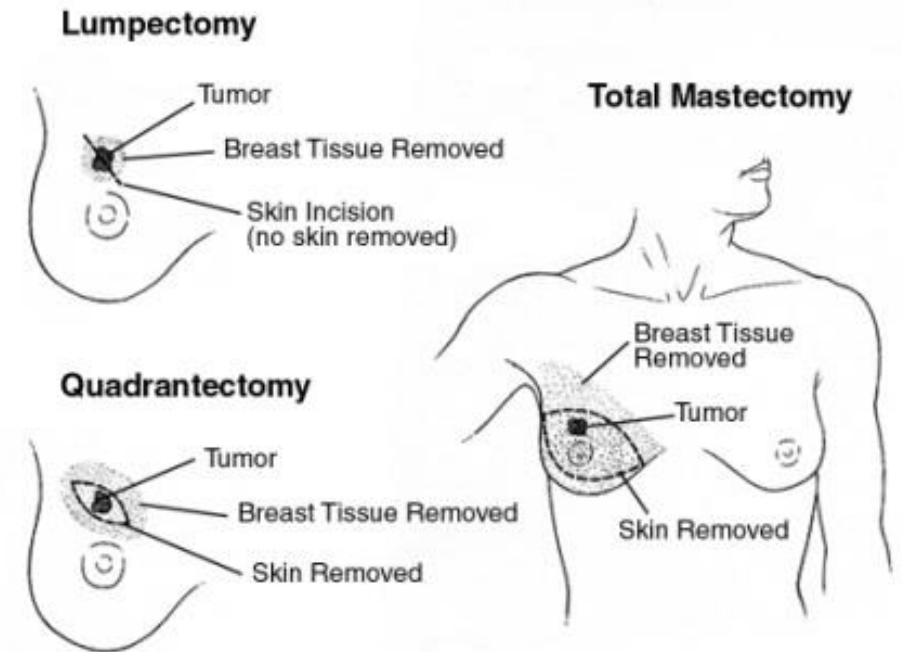


Elevation of mastectomy skin flaps to maintain blood supply

- At the time of the mastectomy, the breast surgeon removes the breast gland through an incision discussed with the plastic surgeon.
 - Blood supply is compromised to the remaining skin
 - Sensation lost to the breast/chest
 - Patients can develop chronic post mastectomy pain syndrome
- Nipple sparing: preserves the entire breast skin envelope (best aesthetic result)
- Skin sparing: preserves inframammary fold and as much native skin as possible

Mastectomy

- Total mastectomy: removal of entire breast with preservation of pec muscle and axillary nodes
- Modified radical: complete removal of the breast with axillary lymph node dissection
- Partial mastectomy (lumpectomy)
 - Will typically need radiation as part of treatment





Implant Based Reconstruction

**SECURE
PLACEMENT**

360° tab orientation
for greater placement
support

PAIRED FOR PRECISION

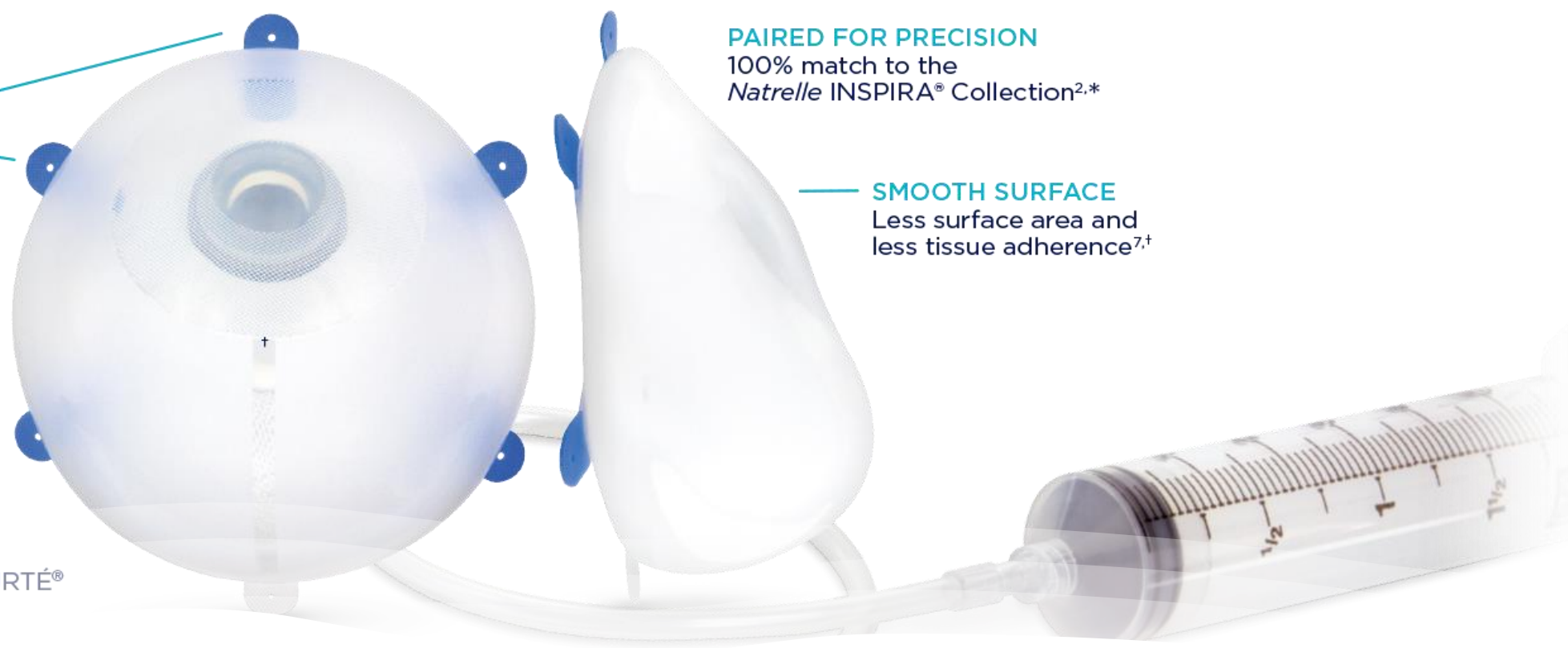100% match to the
Natrelle INSPIRA® Collection^{2,*}

SMOOTH SURFACE

Less surface area and
less tissue adherence^{7,†}

FASTER FILL

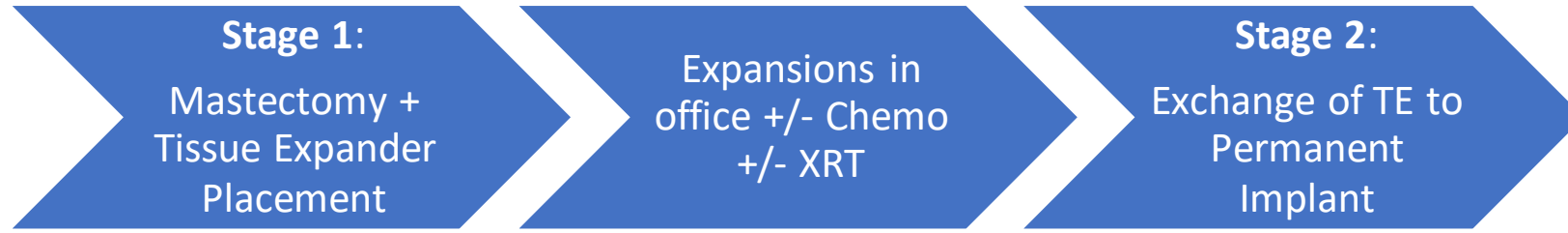
4X faster fill with the *FOURTE®*
Expander Fill System^{8,†,‡}
(included with all *Motiva®*
Tissue Expander)



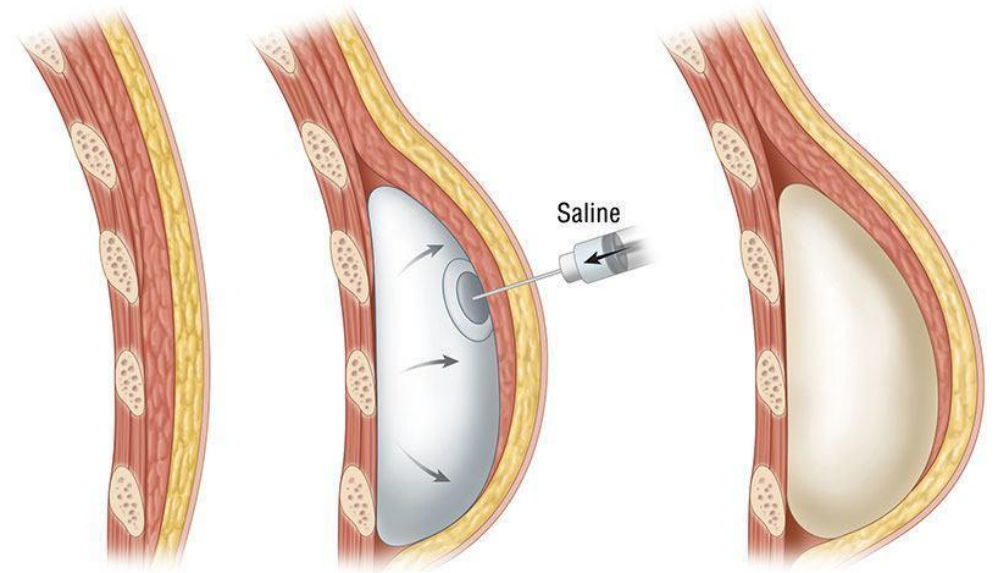
Implant based reconstruction

- Two stage approach with use of tissue expander vs. DTI (direct to implant)
- What is a tissue expander (TE) and why do we use them?

Implant based reconstruction: two stages



- 80% of prosthetic breast reconstruction is performed in 2 stages
 - Stage 1: Tissue expander placement at time of mastectomy
 - Stage 2: Exchange of tissue expander for saline or silicone implant
- Anatomical placement
 - Prepectoral vs. postpectoral



Breast Animation Deformity

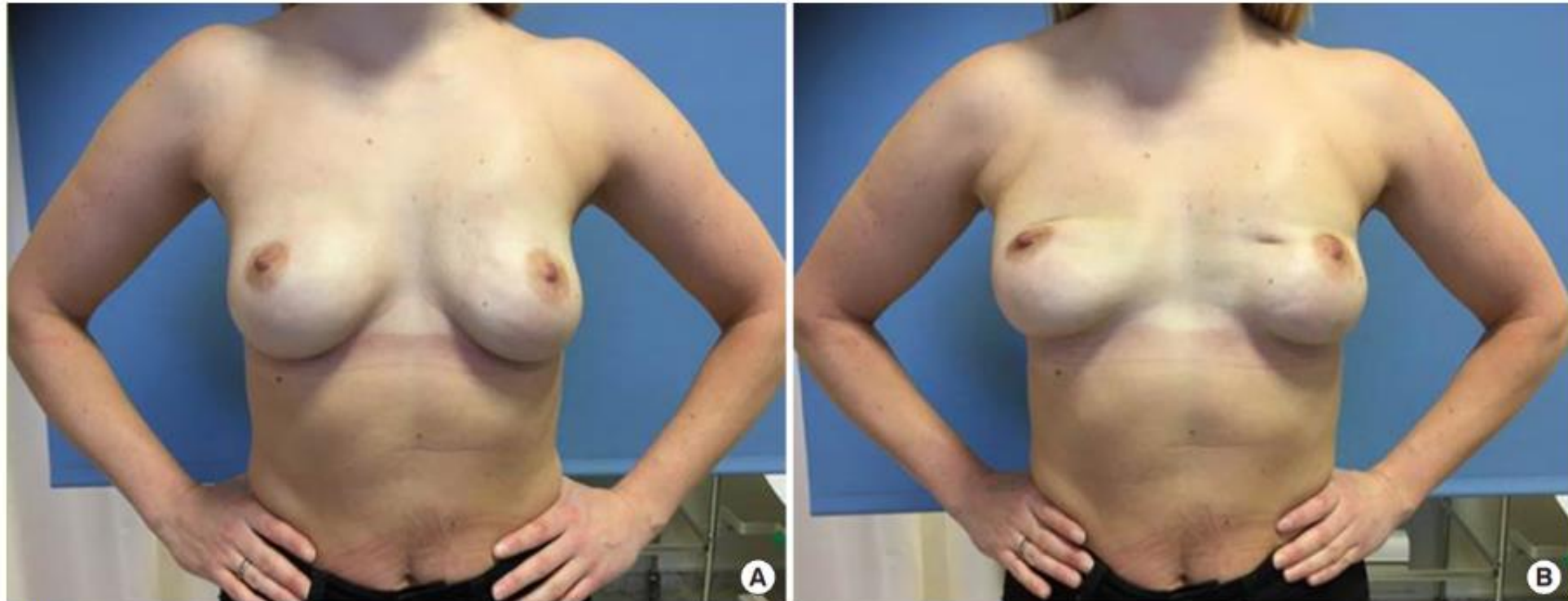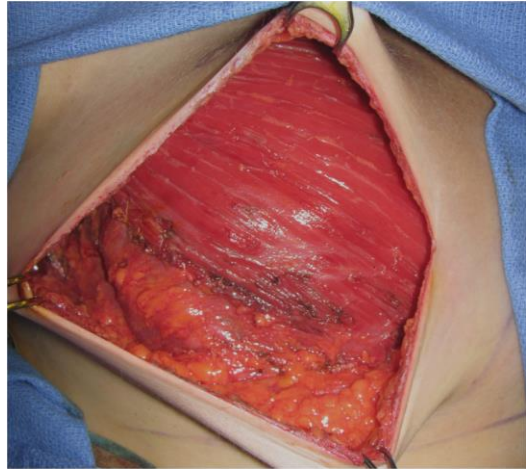


Fig. 3.

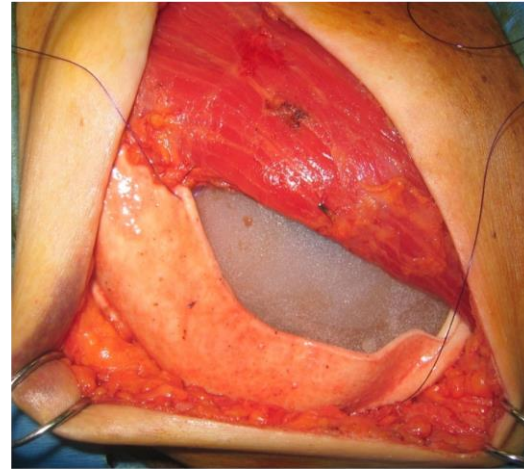
Woman with subpectoral implant placement

The two photographs demonstrate (A) no breast animation deformity at rest and (B) a visible deformity during muscle contraction.

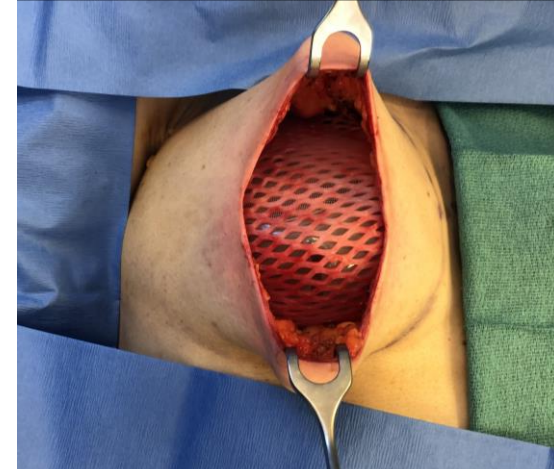
Intraop tissue expander placement



Total muscle coverage

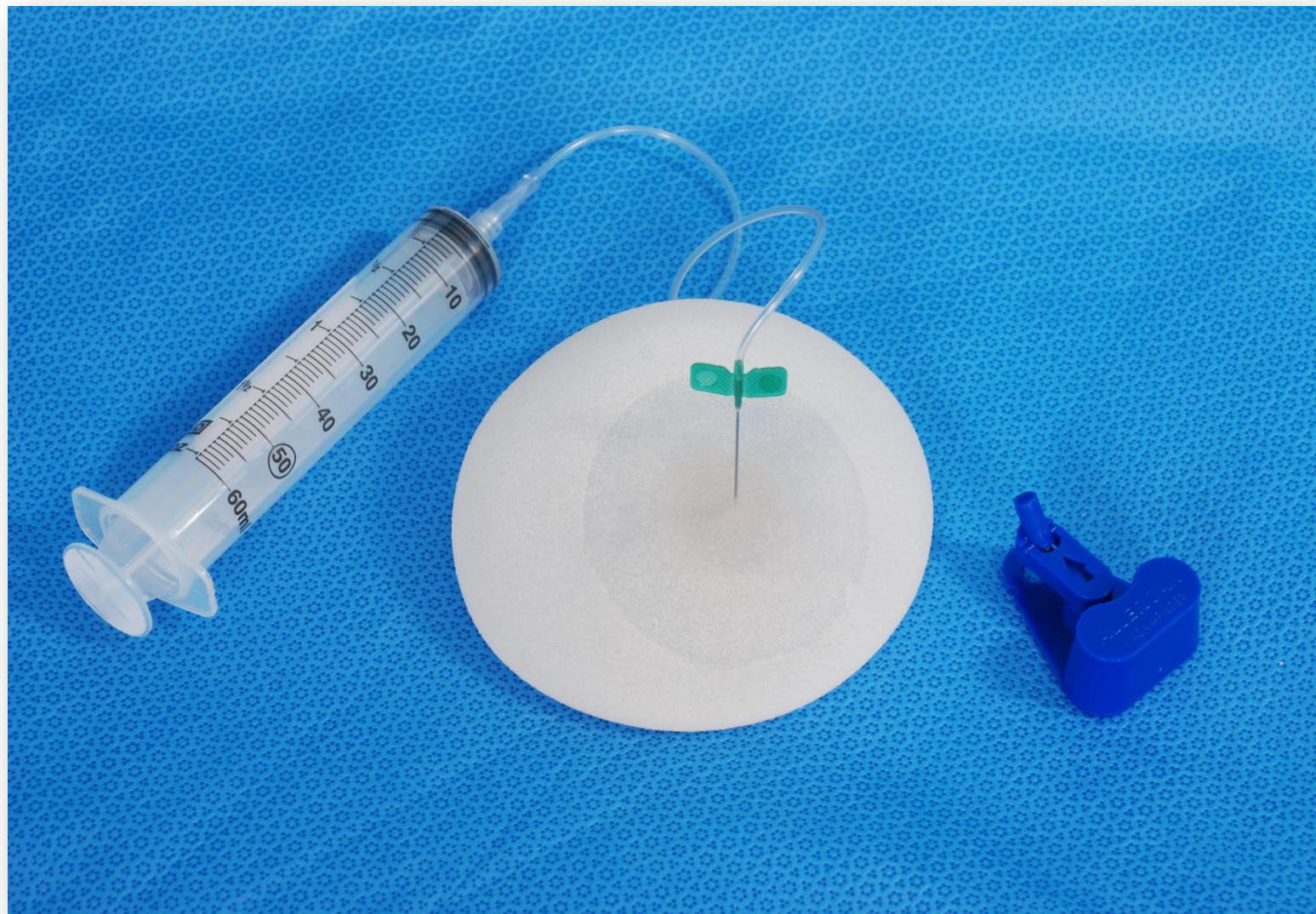


Partial coverage with ADM

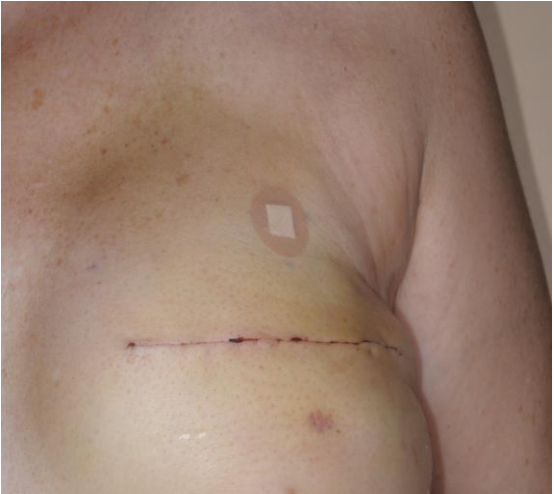
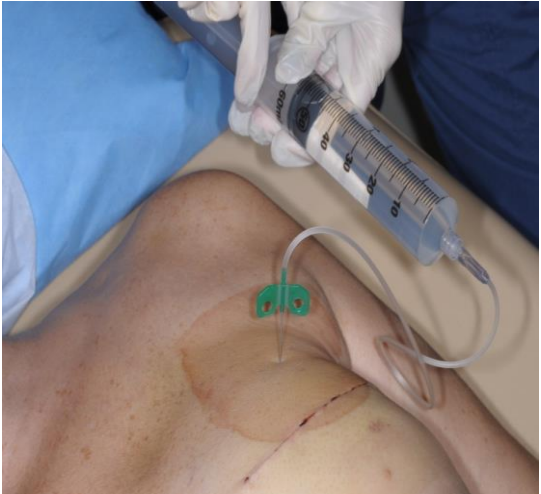
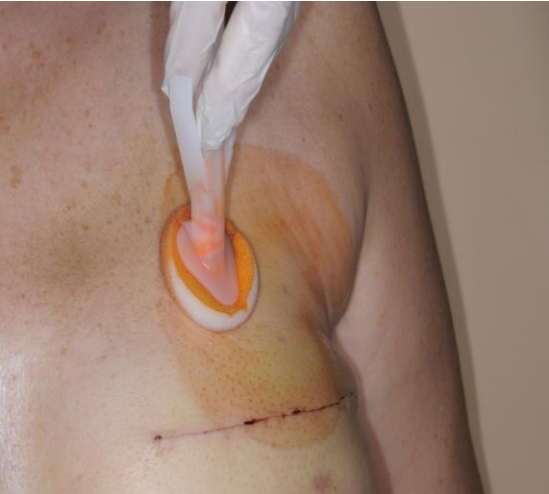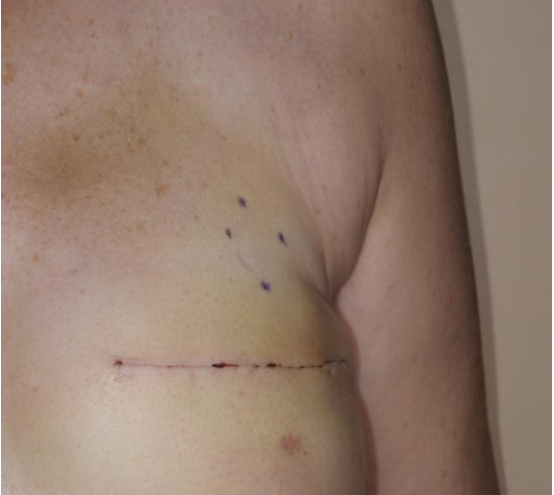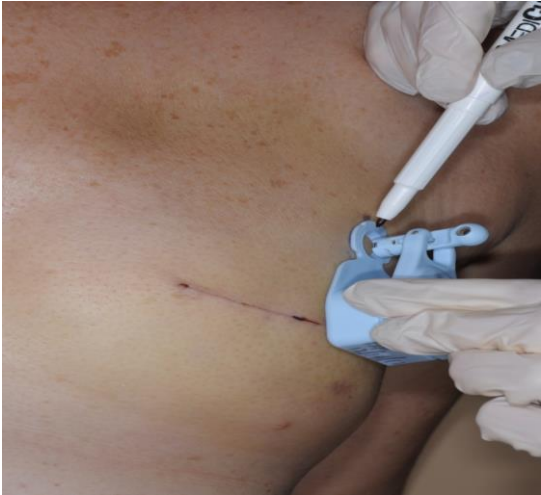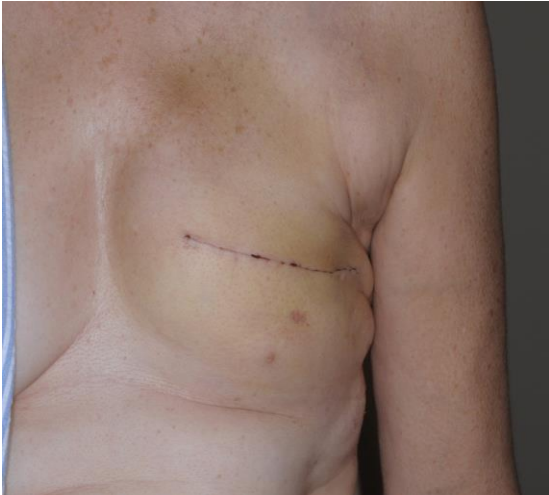Pre-pectoral with ADM

Tissue expander



Tissue expansion in clinic



Stage 2: Implant exchange

- Exchange to permanent implant is performed about 3 months after mastectomy
 - If patient has chemo, we wait 4-6 weeks after treatment for exchange
 - If patient has radiation, we wait 6 months after completion of XRT
- Silicone, saline, textured implants





Saline

- Silicone outer shell
- Filled with saline fluid in the OR
- Rupture: easy to identify, will deflate over 5-7 days
- Shows more rippling



Silicone

- Silicone outer shell
- Filled with silicone
- Rupture: difficult to identify
- **Maintenance MRI to rule out rupture: 5 years after placed, then every 2 years**
- Looks more natural



Textured (Anatomic)

- Silicone outer shell
- Filled with saline or silicone
- **No longer on market due to link to ALCL**
- Originally designed to look the most natural (ptotic) breast

WARNING:

- **Breast implants are not considered lifetime devices. The longer people have them, the greater the chances are that they will develop complications, some of which will require more surgery.**
- **Breast implants have been associated with the development of a cancer of the immune system called breast implant-associated anaplastic large cell lymphoma (BIA-ALCL). This cancer occurs more commonly in patients with textured breast implants than smooth implants, although rates are not well defined. Some patients have died from BIA-ALCL.**
- **Patients receiving breast implants have reported a variety of systemic symptoms such as joint pain, muscle aches, confusion, chronic fatigue, autoimmune diseases and others. Individual patient risk for developing these symptoms has not been well established. Some patients report complete resolution of symptoms when the implants are removed without replacement.**

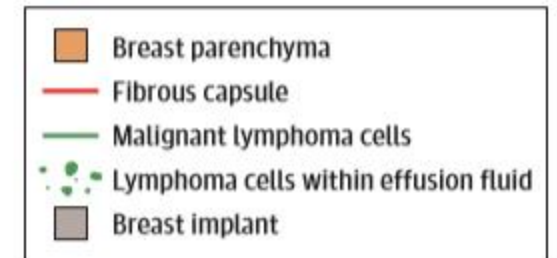
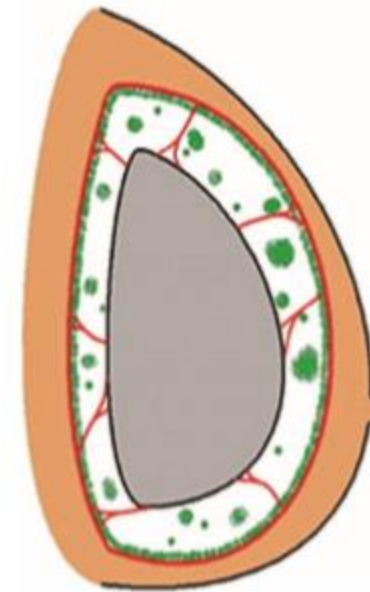
FDA
recommendation
for Black Box
warning on
implants

- Breast implant associated illness
- ALCL (anaplastic large cell lymphoma)

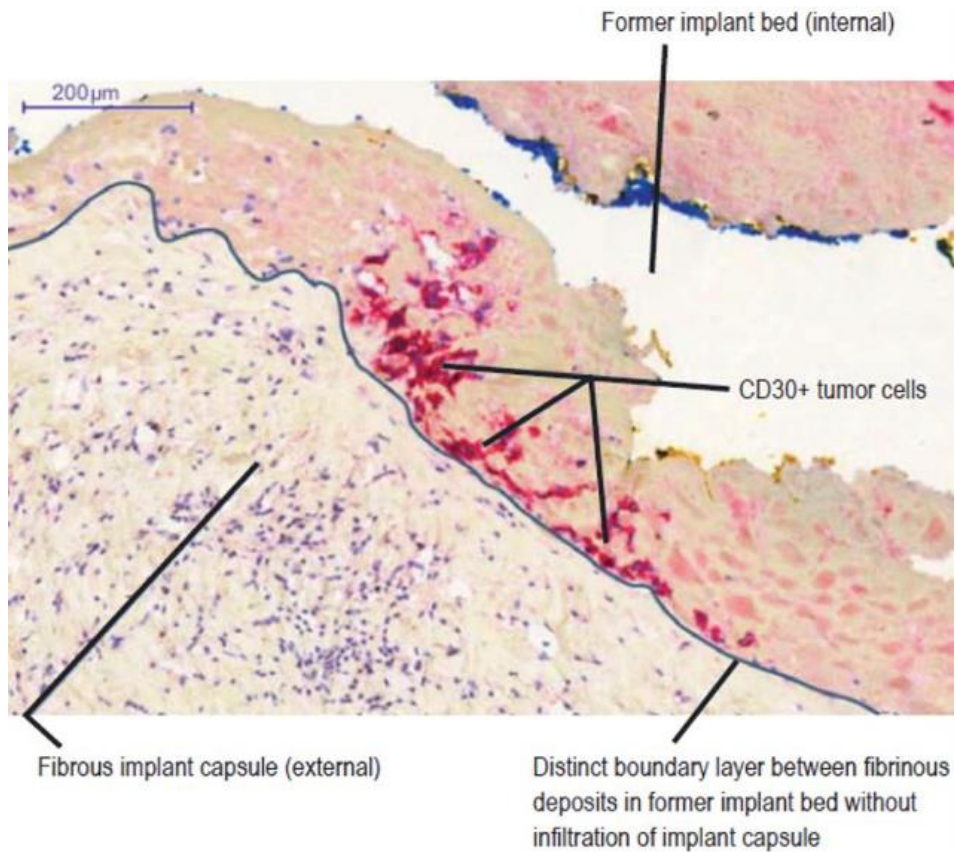
BIA-ALCL (Breast Implant Associated Anaplastic Large Cell Lymphoma)

- A rare subtype of T-cell non-Hodgkins lymphoma found in the capsule (scar) formed around **textured** implants
- Incidence estimations vary
 - Originally reported 1 case per 30,000 women
 - 1 case per 355 women reported May 2020
- Presents as late peri-implant effusion or swelling (fluid collection) in 66% patients or mass/capsule thickening in 8%
- On average, symptoms present 8-10 years from the time of placement of the implant

A Schematic representation



BIA-ALCL (Breast Implant Associated Anaplastic Large Cell Lymphoma)



- Diagnosed by ultrasound and FNA
- Treatment: surgical removal of implant and the surrounding capsule
- Survival rate is 89% at 5 years
- **FDA recommendations:** regular monitoring for symptoms of BIA-ALCL, and if you do not have symptoms, there is **NO** need to remove the implant

Overview of recovery from implant based reconstruction

- Initial surgery of mastectomy with tissue expander placement is about 2-4 hours depending on unilateral vs. bilateral
 - Overnight stay at the hospital
 - 4-6 week recovery
 - JP drain care postop
- Exchange surgery is about 1-2 hour surgery
 - Outpatient procedure
 - Average 2 week recovery

Mastectomy with
tissue expander
placement



3 months

Implant exchange



3 months

3D Nipple areola
tattoo

Preop

**Bilateral implants with 3D nipple
areola tattoo**

Preop

**Right implant reconstruction, no nipple
reconstruction**

Preop

**Bilateral silicone gel implants
with nipple sparing mastectomy**

Implant Complications

In the immediate postop setting

- Hematoma
- Seroma
- Dehiscence/Implant Exposure
- Delayed healing or mastectomy skin necrosis
- Cellulitis

Implant Complications

Long Term Considerations

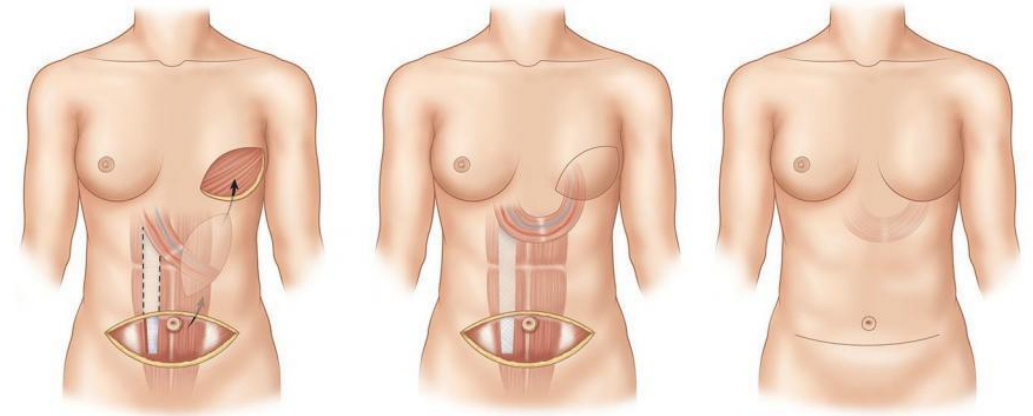
- Capsular Contracture
- Rupture
- Nipple malposition in setting of nipple sparing mastectomy
- Rippling
- Anaplastic Large Cell Lymphoma
- Breast implant associated illness



Autologous Reconstruction

Autologous reconstruction

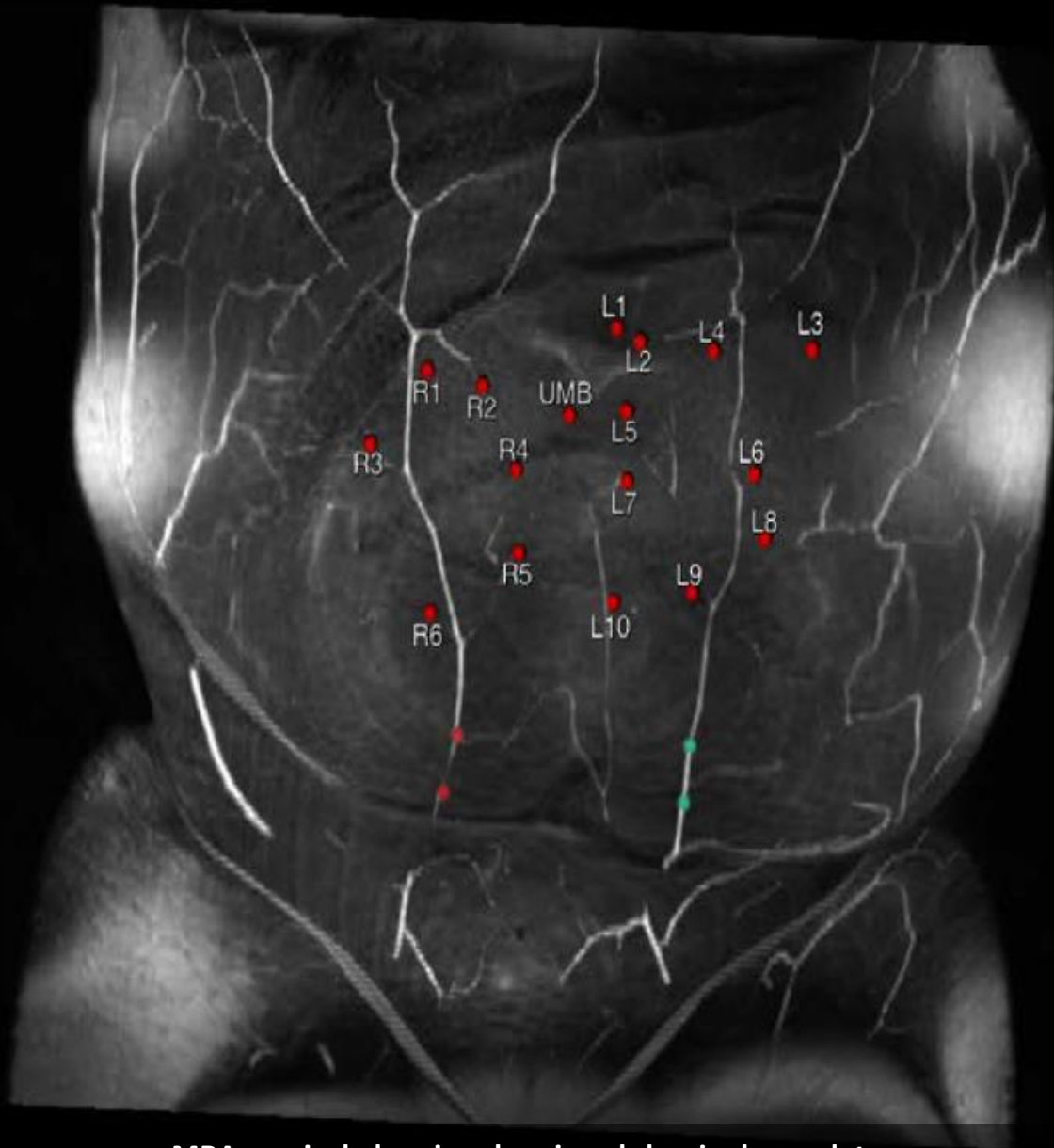
- Breast reconstruction using a patient's own tissue
- “Flap” in plastic surgery is defined as a unit of tissue that is transferred from its original (donor) site in the body to another (recipient) site based on a blood supply
- Introduction of the pedicled transverse rectus abdominis myocutaneous (TRAM) flap in the 1980s
- Technical advances led to the development of free flaps based on perforators (specific blood supply)
 - Free flap involves advanced technique and training in microsurgery



Pedicled TRAM flap for left breast reconstruction

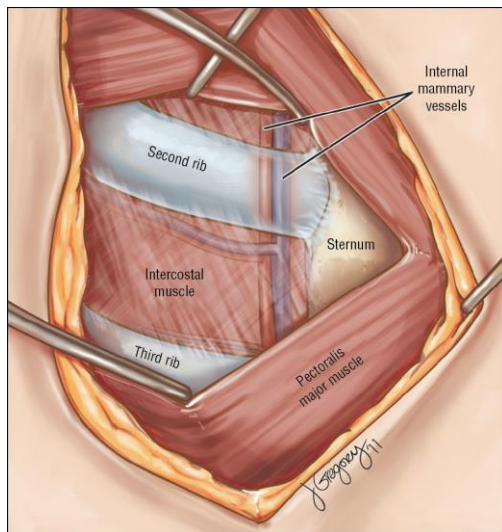
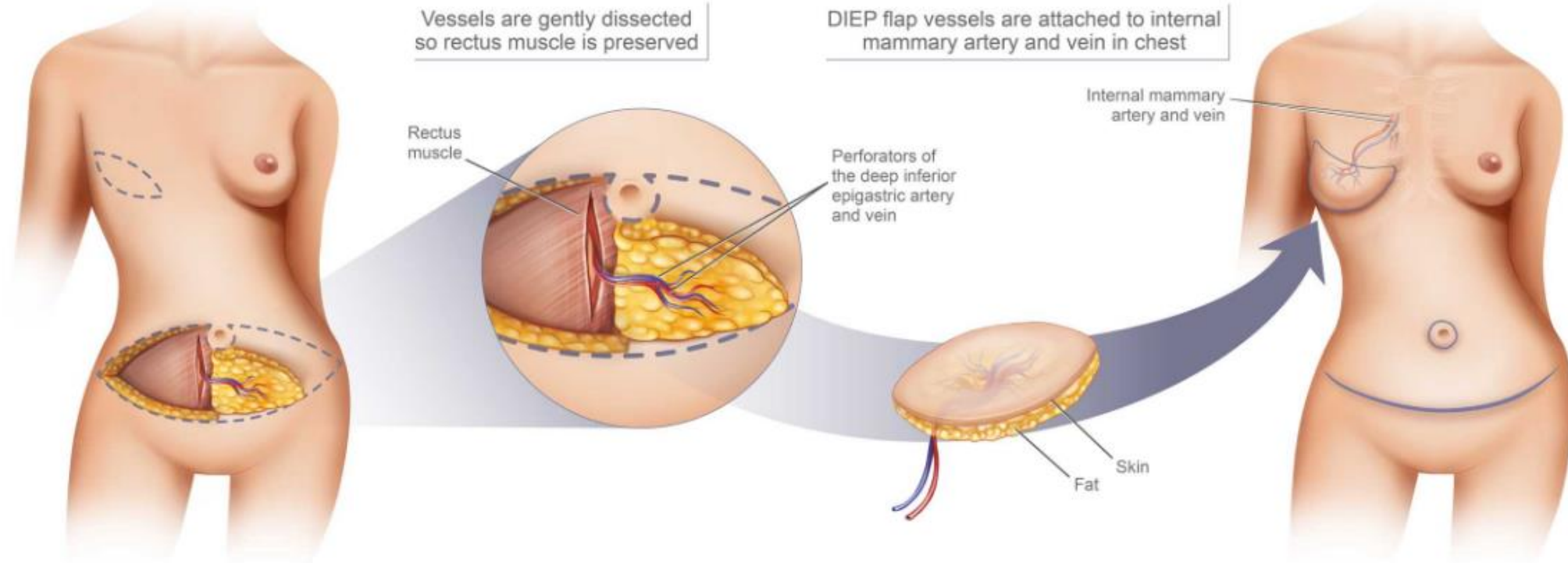
Deep Inferior Epigastric Perforator (DIEP) flap

- This is the most commonly used free flap in breast reconstruction in which we use lower abdominal tissue to reconstruct the breast
- Only skin and fat harvested from the abdomen
 - Decreased abdominal morbidity in comparison to TRAM flap
- Patients usually have preop imaging (MRA or CTA) to look at blood vessels
- Vasculature: DIEP vessels
- Anastomosis to internal mammary vessels (typically)

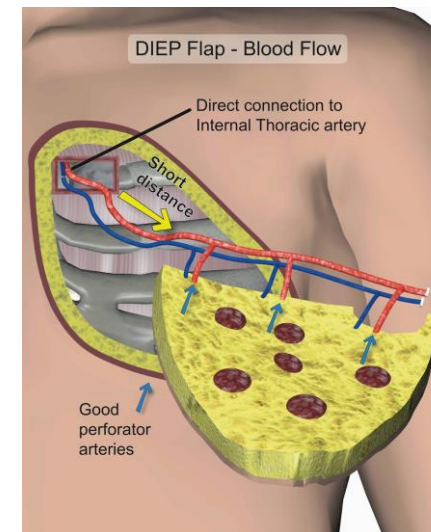


MRA surgical planning showing abdominal vasculature

Deep Inferior Epigastric Perforator (DIEP) Flap



← Internal mammary vessel exposure



Deep Inferior Epigastric Perforator (DIEP) flap

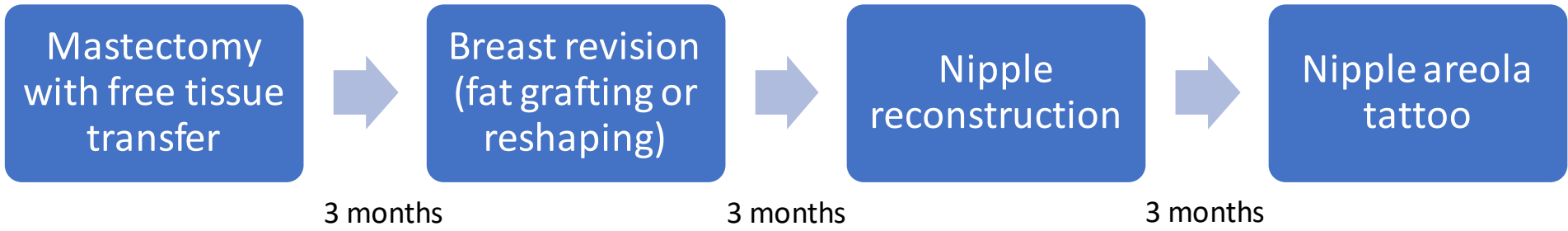
- Indications
 - Patient must have adequate donor site volume
 - Take into consideration previous abdominal surgery
 - Great option if patient has been radiated or needs delayed breast reconstruction
- Contraindication
 - previous abdominoplasty
 - history of clotting disorder
 - lack of adequate tissue volume
 - smoking

Preop

Postop bilateral DIEPs

Overview of recovery from autologous reconstruction

- Surgery is 6-8 hours by skilled microsurgeon
- Admission for 3-5 days
- Pain control – Enhanced Recovery After Surgery (ERAS) Program
 - Abdominal TAP blocks with Exparel
 - Toradol standing postop q 6 hours
 - Minimizing use of narcotics postoperatively



Deep Inferior Epigastric Perforator (DIEP) Flap

Unilateral DIEP reconstruction (right)
and symmetrizing mastopexy (left)

Bilateral DIEP flap reconstruction

Bilateral DIEP flap reconstruction

Unilateral DIEP flap reconstruction
(right)

*Deep Inferior
Epigastric
Perforator
(DIEP) Flap*

Nipple Sparing Mastectomies

Delayed DIEPs

S/P right mastectomy followed by radiation treatment

S/P delayed right DIEP and nipple reconstruction with skin graft and tattoo; left mastopexy

S/P left mastectomy and tissue expander reconstruction followed by radiation treatment

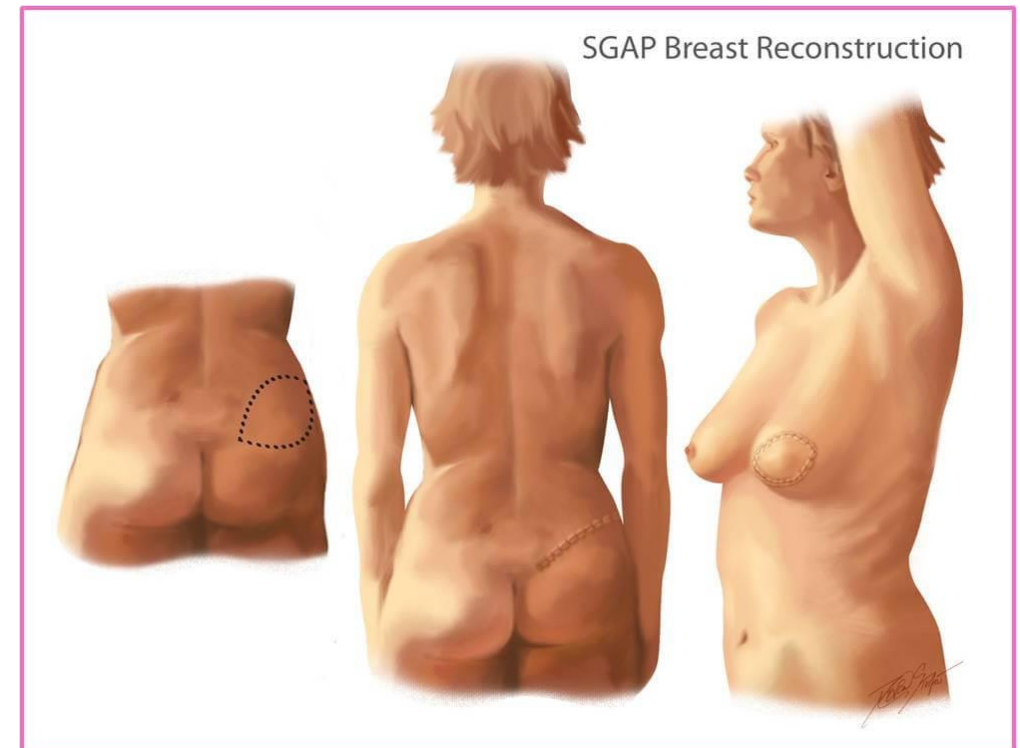
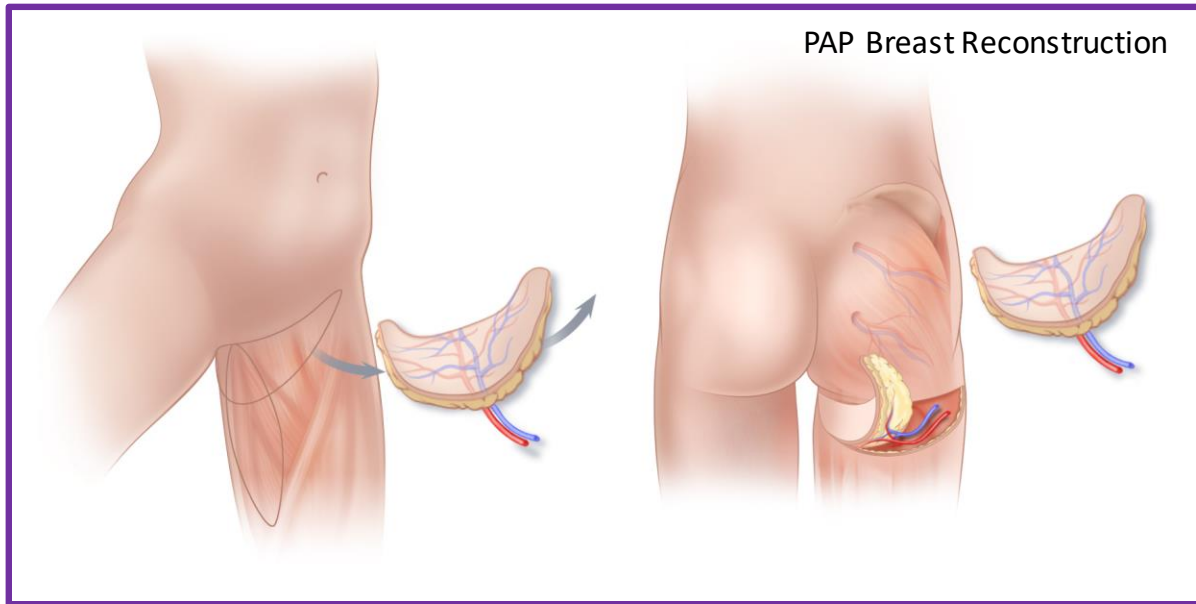
S/P delayed left DIEP flap, nipple reconstruction and tattoo; left mastopexy

Complications with DIEP flaps

- Flap Failure
 - Less than 1% flap failure rate
- Partial Flap Loss or Fat Necrosis
 - More often with pedicled TRAM flaps than DIEPs
- Abdominal bulge or hernia (TRAM or DIEP flap)
- Decreased sensation at donor site

Other free flap donor sites

- PAP (profunda artery perforator) flap
- SGAP (superior gluteal artery perforator flap)
- DUG/TUG (diagonal or transverse upper gracilis)

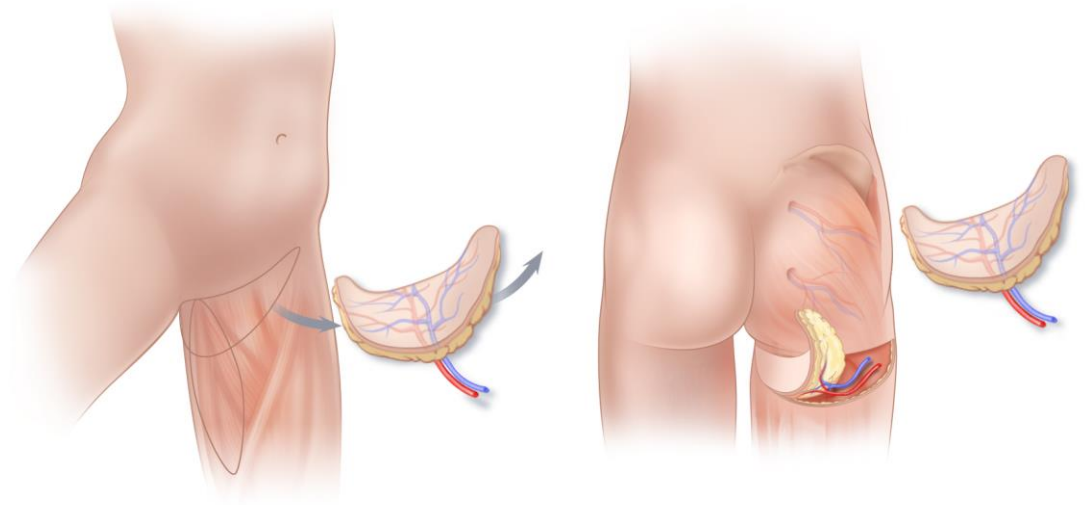



Bilateral SGAP flap

Preop

Postop

Left DUG flap

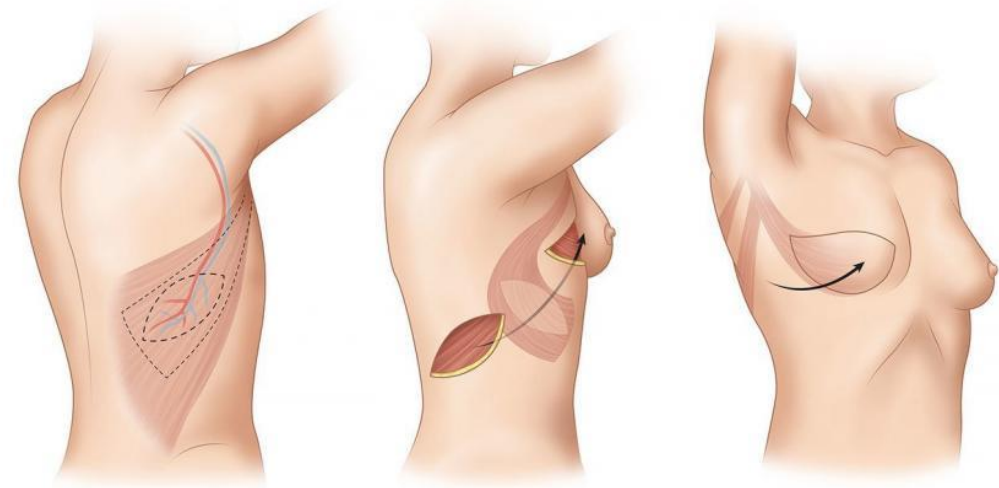




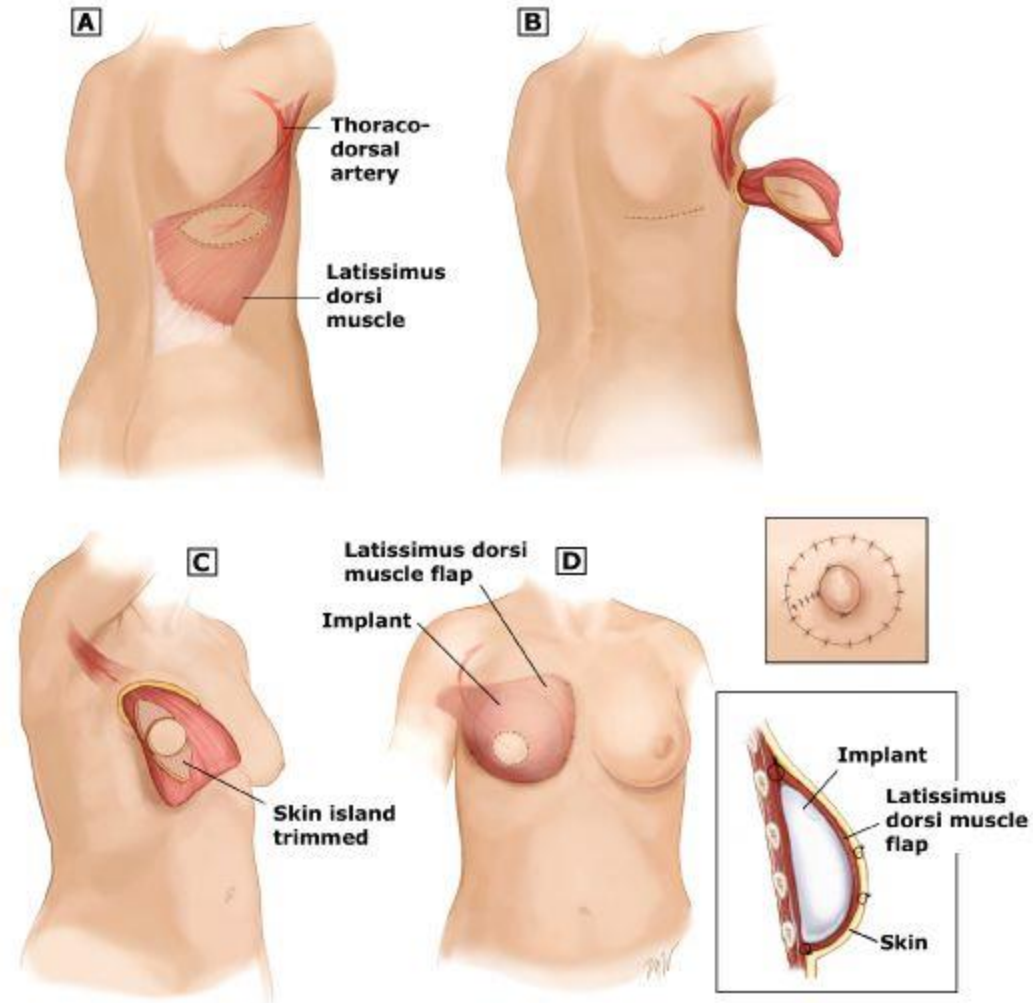
Combination
autologous and implant
based reconstruction

Latissimus dorsi flap with implant

- Typically this is a backup option and not used as a first line option for breast reconstruction
- The latissimus dorsi muscle, fat and skin are rotated based on it's own blood supply. No anastomosis.
- Useful when skin needs to be replaced
- Most common complication is a donor site seroma in the back



Latissimus dorsi flap with implant



- Indications
 - Patients with history of radiation
 - Failed previous breast reconstruction
 - Patients with considerable previous abdominal surgery
 - Lumpectomy defect
- Relative contraindications
 - Prior posterior thoracotomy
 - Patients who need functional latissimus dorsi (elite athletes, rock climbers, wheelchair users, swimmers, golfers)

Latissimus Dorsi Flap with Implant

Preop: left total mastectomy with no reconstruction and treatment with radiation. Hx of abdominoplasty. Now undergoing right prophylactic mastectomy

Postop: left latissimus flap with silicone gel implant, right silicone gel implant

Latissimus Dorsi Flap with Implant



Nipple Reconstruction



Nipple Reconstruction

- Nipple areola complex (NAC) reconstruction is associated with higher aesthetic and general satisfaction than in breast reconstruction without NAC
- Can often be done in the office in a quick procedure

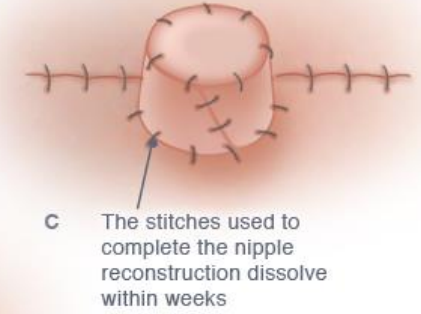
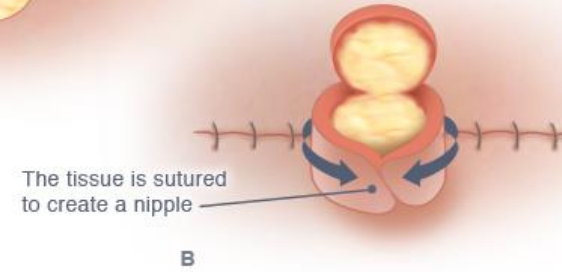
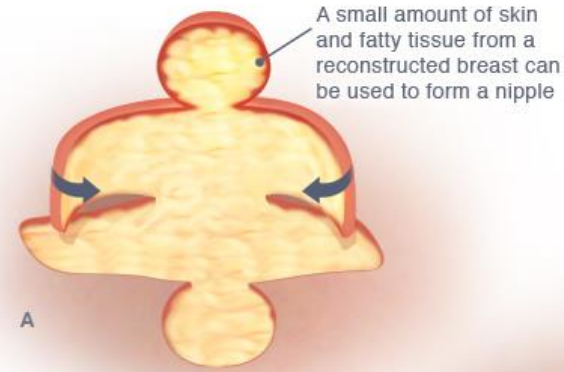
CV Flap (Local
Flap)

Skate Flap with
full thickness
skin graft

Nipple Share

3D Tattoo

Local Flap (CV Flap)



Skate flap with Full Thickness Skin Graft (FTSG)

Before Tattoo

After Tattoo

Intraop

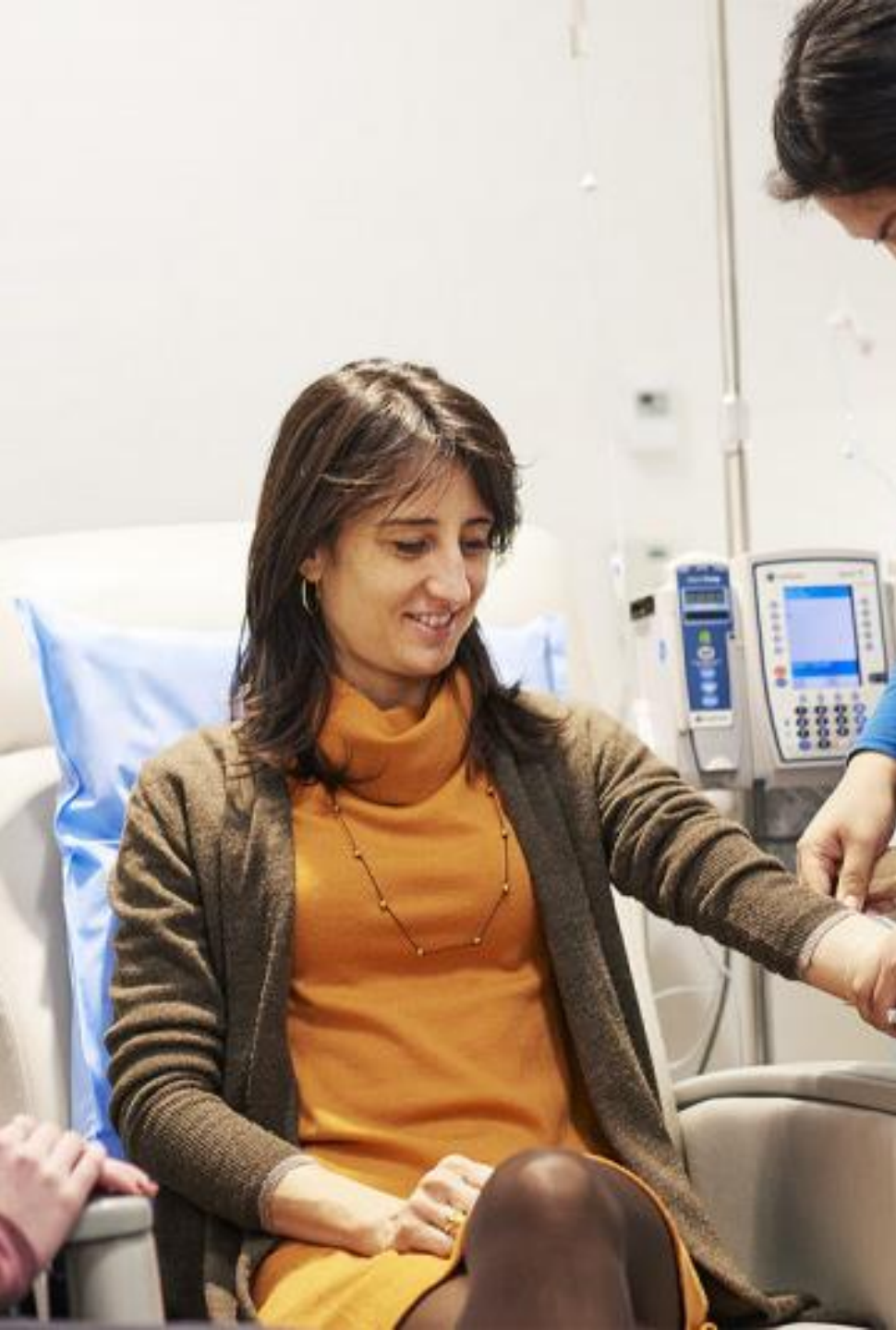Bilateral nipple reconstruction with skate and FTSG

Nipple Share

3D Nipple Areola Tattoo

Quality of Life Outcomes

At 1 year after mastectomy, patients who underwent autologous reconstruction were more satisfied with their breasts and had greater psychosocial and sexual well-being than those who underwent implant reconstruction¹¹



Chemo and Radiation Considerations

- Chemotherapy
 - Start about 4-6 weeks after surgery
 - Postop infection may cause a delay in chemo
- Radiation
 - Higher rates of capsular contracture, infection and painful expansion with **implant** reconstruction
 - Higher rates of skin contracture, fat necrosis, flap atrophy with **autologous** reconstruction
 - However, overall there are less complications related to XRT with autologous recon in comparison to implants
 - Preferred to radiate a tissue expander rather than a DIEP or implant



Effects of Radiation

Radiation to Right
Breast Tissue expander

Right delayed DIEP flap

Left implant based reconstruction,
history of radiation to tissue expander

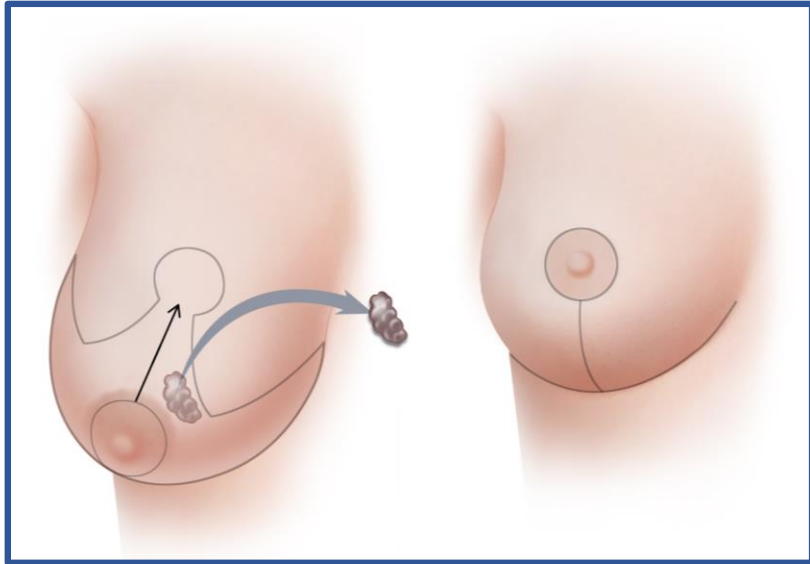


Partial Breast Reconstruction

Partial breast reconstruction

- Breast conservation is the treatment of choice for most stage I and II breast cancers
- Typically with partial mastectomy (lumpectomy) patient will also require radiation for treatment
- Oncoplastic breast reduction is the most common
- If defect is too large or the breast is small, rotational flaps such as latissimus flap or free flaps may be performed
- Fat grafting may also be used to fill small lumpectomy defects

Oncoplastic Breast Reduction



Right oncoplastic reduction, radiation to right breast postop, left breast reduction

Recap

Implant based reconstruction

Advantages

- No other scars on the body
- Use of adjacent tissue of similar color, texture
- Shorter operative time and postoperative recovery surgery (2-4 hours for TE placement)
- Autologous reconstruction is always an option later

Disadvantages

- Not a lifetime device, will need to be replaced at some point
- Requires follow up and monitoring for rupture (MRI)

Autologous breast reconstruction

Advantages

- Most natural form of breast reconstruction
- Higher QOL score 1 year postop
- Lower risk of failure and surgical site infection than implants


Disadvantages

- Another scar on the body
- Longer surgery (6-8 hours) and more recovery
- Longer hospitalization (3-5 days vs 1 day)

Breast Cancer Screening After Mastectomy with Reconstruction

- **Physical exam** remains gold standard for detecting locoregional recurrence after mastectomy
- Fat necrosis can occur in patients with flaps or after fat grafting revision to breast reconstruction
 - This is worked up with **ultrasound, possibly biopsy**
- Multidisciplinary discussion is important
- Studies have shown that postmastectomy imaging in breast reconstruction patient for surveillance did not affect overall survival or disease-free survival

Thank you!



Contact info:

Alicia Jones, MHS, PA-C

Memorial Sloan Kettering Cancer Center

jonesa@mskcc.org

References

1. <https://www.cancer.org/cancer/breast-cancer/about/how-common-is-breast-cancer.html>
2. Morrow M, Li Y, Alderman AK, et al. Access to Breast Reconstruction After Mastectomy and Patient Perspectives on Reconstruction Decision Making. *JAMA Surg.* 2014;149(10):1015–1021. doi:10.1001/jamasurg.2014.548
3. Retrouvey H, Solaja O, Gagliardi AR, Webster F, Zhong T. Barriers of Access to Breast Reconstruction: A Systematic Review. *Plast Reconstr Surg.* 2019;143(3):465e-476e. doi:10.1097/PRS.0000000000005313
4. Wexelman B, Schwartz JA, Lee D, Estabrook A, Ma AM. Socioeconomic and geographic differences in immediate reconstruction after mastectomy in the United States. *Breast J.* 2014 Jul-Aug;20(4):339-46. doi: 10.1111/tbj.12274. Epub 2014 May 26. PMID: 24861537
5. <https://www.plasticsurgery.org/documents/News/Statistics/2019/plastic-surgery-statistics-full-report-2019.pdf>
6. Tsoi, Bernice B.Sc., M.Sc.; Ziolkowski, Natalia I. B.Com., B.Sc., M.D.; Thoma, Achilleas M.D., M.Sc.; Campbell, Kaitryn B.Ed., M.L.I.S.; O'Reilly, Daria B.Sc., M.Sc., Ph.D.; Goeree, Ron B.A., M.A. Safety of Tissue Expander/Implant versus Autologous Abdominal Tissue Breast Reconstruction in Postmastectomy Breast Cancer Patients, *Plastic and Reconstructive Surgery*: February 2014 - Volume 133 - Issue 2 - p 234-249 doi: 10.1097/01.prs.0000436847.94408.11
7. Svee A, Mani M, Sandquist K, et al. Survival and risk of breast cancer recurrence after breast reconstruction with deep inferior epigastric perforator flap. *Br J Surg.* 2018;105(11):1446-1453. doi:10.1002/bjs.10888
8. <https://www.plasticsurgery.org/documents/News/Statistics/2019/plastic-surgery-statistics-full-report-2019.pdf>

References

9. Breast animation deformity. *Arch Plast Surg*. 2019;46(1):7-15. Published online January 15, 2019
DOI: <https://doi.org/10.5999/aps.2018.00479>
10. Eltahir Y, Krabbe-Timmerman IS, Sadok N, Werker PMN, de Bock GH. Outcome of Quality of Life for Women Undergoing Autologous versus Alloplastic Breast Reconstruction following Mastectomy: A Systematic Review and Meta-Analysis. *Plast Reconstr Surg*. 2020;145(5):1109-1123. doi:10.1097/PRS.00000000000006720
11. Pusic AL, Matros E, Fine N, et al. Patient-Reported Outcomes 1 Year After Immediate Breast Reconstruction: Results of the Mastectomy Reconstruction Outcomes Consortium Study. *J Clin Oncol*. 2017;35(22):2499-2506. doi:10.1200/JCO.2016.69.9561
12. Dyrberg et al. Breast animation deformity. *Archives of Plastic Surgery* 2019;46(1):7-15. Published online: January 15, 2019.
DOI: <https://doi.org/10.5999/aps.2018.00479>
13. Wilkins EG, Cederna PS, Lowery JC, et al. Prospective analysis of psychosocial outcomes in breast reconstruction: one-year postoperative results from the Michigan Breast Reconstruction Outcome Study. *Plast Reconstr Surg*. 2000;106(5):1014-1027. doi:10.1097/00006534-200010000-00010
14. <https://www.plarecon.com/what-is-a-flap/>
15. Sisti A, Grimaldi L, Tassinari J, Cuomo R, Fortezza L, Bocchiotti MA, Roviello F, D'Aniello C, Nisi G, Sisti A, et al. Eur J Surg Oncol. 2016 Apr;42(4):441-65. doi: 10.1016/j.ejso.2016.01.003. Epub 2016 Jan 30. Eur J Surg Oncol. 2016. PMID: 26868167 Review.
16. Leberfinger AN, Behar BJ, Williams NC, et al. Breast Implant-Associated Anaplastic Large Cell Lymphoma: A Systematic Review. *JAMA Surg*. 2017;152(12):1161-1168. doi:10.1001/jamasurg.2017.4026

References

17. Cordeiro PG, Ghione P, Ni A, Hu Q, Ganesan N, Galasso N, Dogan A, Horwitz SM. Risk of breast implant associated anaplastic large cell lymphoma (BIA-ALCL) in a cohort of 3546 women prospectively followed long term after reconstruction with textured breast implants. *J Plast Reconstr Aesthet Surg*. 2020 May;73(5):841-846. doi: 10.1016/j.bjps.2019.11.064. Epub 2020 Jan 20. PMID: 32008941; PMCID: PMC7247945.
18. Tsai HC, Yoshida T, Chuang TY, et al. Transversus Abdominis Plane Block: An Updated Review of Anatomy and Techniques. *Biomed Res Int*. 2017;2017:8284363. doi:10.1155/2017/8284363
19. Hammond, D. *Pedicled TRAM Flap Breast Reconstruction*. In Nahabedian, M. *Cosmetic and Reconstructive Breast Surgery*. Saunders Elsevier. 2009
20. Hamdi, M and Hijawi, J. *Breast Reconstruction – Perforator Flaps (DIEP, SIEA)*. In Nahabedian, M. *Cosmetic and Reconstructive Breast Surgery*. Saunders Elsevier. 2009
21. McCarthy, C and Disa, J. *Latissimus Dorsi Breast Reconstruction*. In Nahabedian, M. *Cosmetic and Reconstructive Breast Surgery*. Saunders Elsevier. 2009
22. Shamma RL, Broadwater G, Cason RW, Glener AD, Sergesketter AR, Vernon R, Le E, Wickenheisser VA, Marks C, Hollenbeck ST. Assessing the Utility of Post-Mastectomy Imaging after Breast Reconstruction. *J Am Coll Surg*. 2020 Apr;230(4):605-614.e1. doi: 10.1016/j.jamcollsurg.2020.01.006. Epub 2020 Feb 5. PMID: 32032723.
23. Macadam SA, Bovill ES, Buchel EW, Lennox PA. Evidence-Based Medicine: Autologous Breast Reconstruction. *Plast Reconstr Surg*. 2017 Jan;139(1):204e-229e. doi: 10.1097/PRS.0000000000002855. PMID: 28027256.