

ABCs of ACS in the Hospitalized Patient

Tamara Redden DNP, FNP, AGACNP, CCRN



Disclosures

- I have no relevant disclosures.



Mr. Ross

- 72M CC of substernal chest pressure began 3 hours ago with walking, now a 5/10 in ED
- PMH – DMII, HTN, HLD, emphysema



What to do?

- Obtain data to make a diagnosis
 - 12-ECG, troponin
 - Patient signs and symptoms
 - typical versus atypical
 - history and co-morbidities
- Diagnosis
- Treatment plan
- Consult cardiology
- Assess risk
- What does the evidence say?



ACS Risk Factors

- Male, Age>60
- DMII
- HTN
- HLD
- Other risk factors
 - Personal history of CAD
 - Family history of CAD, especially premature male <55, female <65
 - Autoimmune diseases – Lupus and RA
 - accelerate atherosclerosis and premature heart disease



ACS Risk Scale

- GRACE ACS Risk and Mortality Calculator
 - Age
 - Heart rate (60-100)
 - Systolic BP (100-120)
Creatinine (0.7-1.3)
 - Cardiac arrest at admission
 - ST segment deviation on EKG?
 - Abnormal cardiac enzymes
 - Killip class (signs/symptoms of CHF)



12-ECG

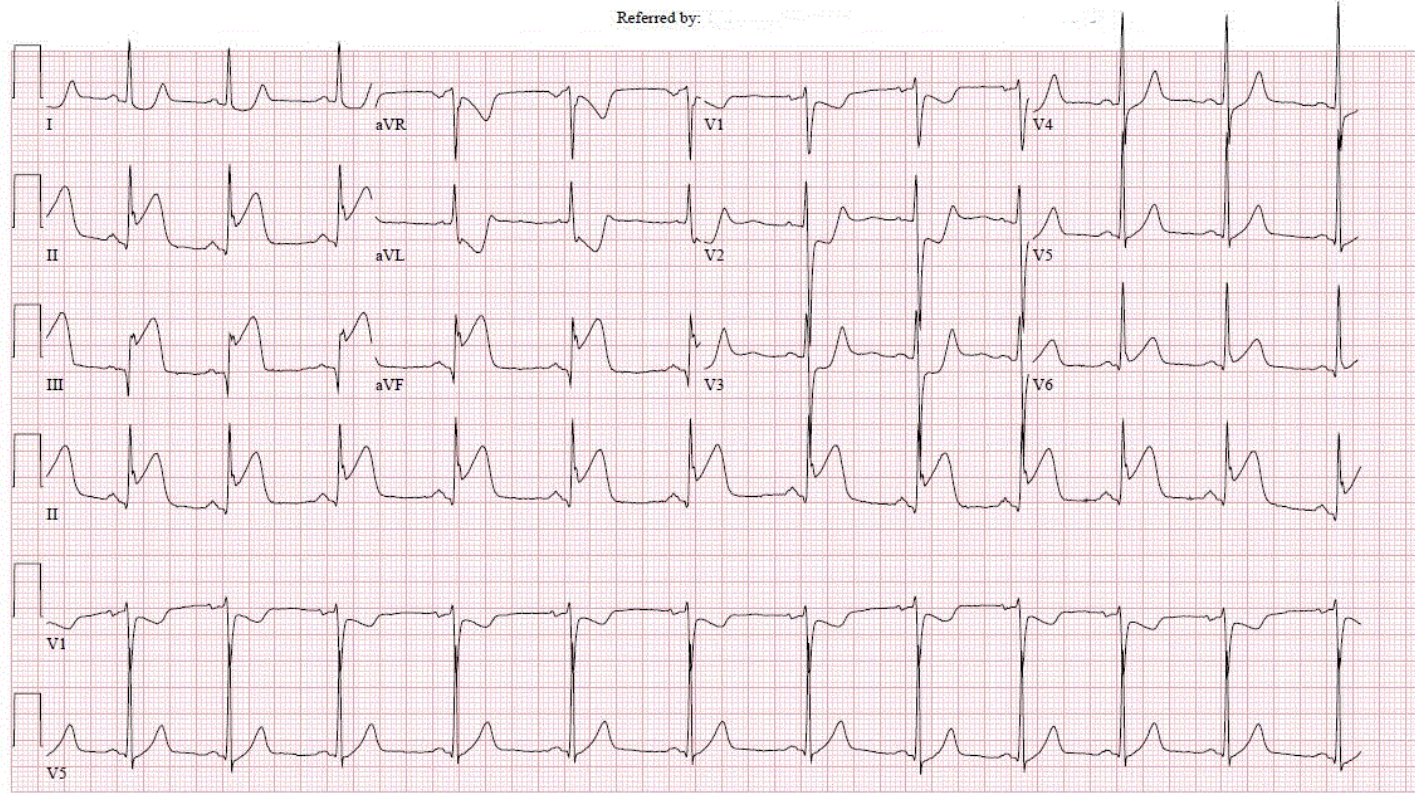
Room: 0kg
Loc:4088

Vent. rate	72	BPM
PR interval	140	ms
QRS duration	90	ms
QT/QTc	382/418	ms
P-R-T axes	49 39 79	

Normal sinus rhythm
ST elevation consider inferior injury or acute infarct
*** ACUTE MI / STEMI ***
Consider right ventricular involvement in acute inferior infarct
Abnormal ECG
When compared with ECG of 05-APR-2019 06:38,
ST elevation now present in Inferior leads
ST now depressed in Anterolateral leads
T wave inversion no longer evident in Inferior leads

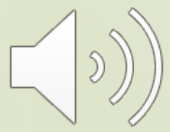Technician ID: 11247
Test ind: Chest Pain

Referred by:



25mm/s 10mm/mV 150Hz 8.0 SP2 12SL 241 CID: 23

EID:11001 EDT: 16:33 18-APR-2019 ORDER: 474659177



12-ECG

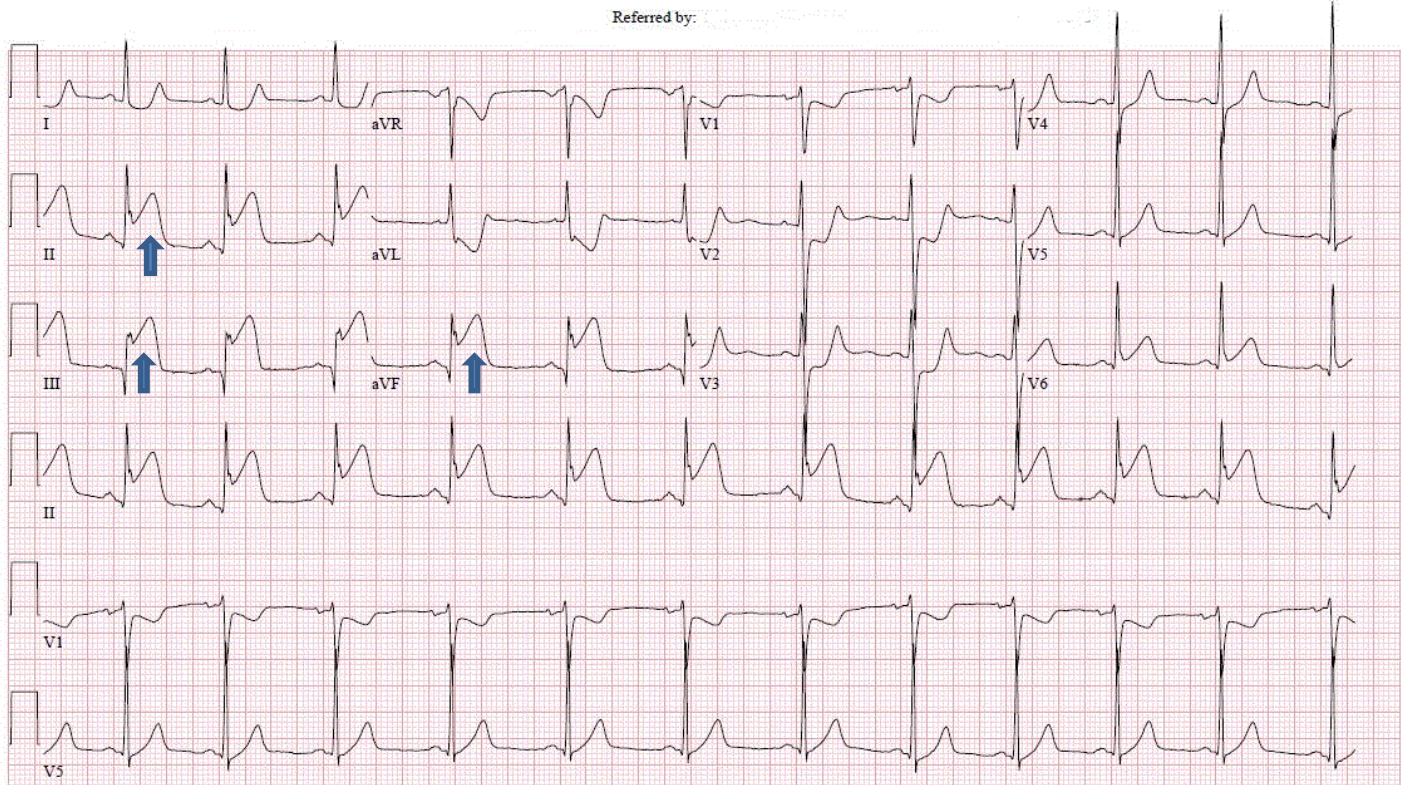
Room: 0kg
Loc:4088

Vent. rate 72 BPM
PR interval 140 ms
QRS duration 90 ms
QT/QTc 382/418 ms
P-R-T axes 49 39 79

Normal sinus rhythm
ST elevation consider inferior injury or acute infarct
***** ACUTE MI / STEMI *****
Consider right ventricular involvement in acute inferior infarct
Abnormal ECG
When compared with ECG of 05-APR-2019 06:38,
ST elevation now present in Inferior leads
ST now depressed in Anterolateral leads
T wave inversion no longer evident in Inferior leads

Technician ID: 11247
Test ind: Chest Pain

Referred by:



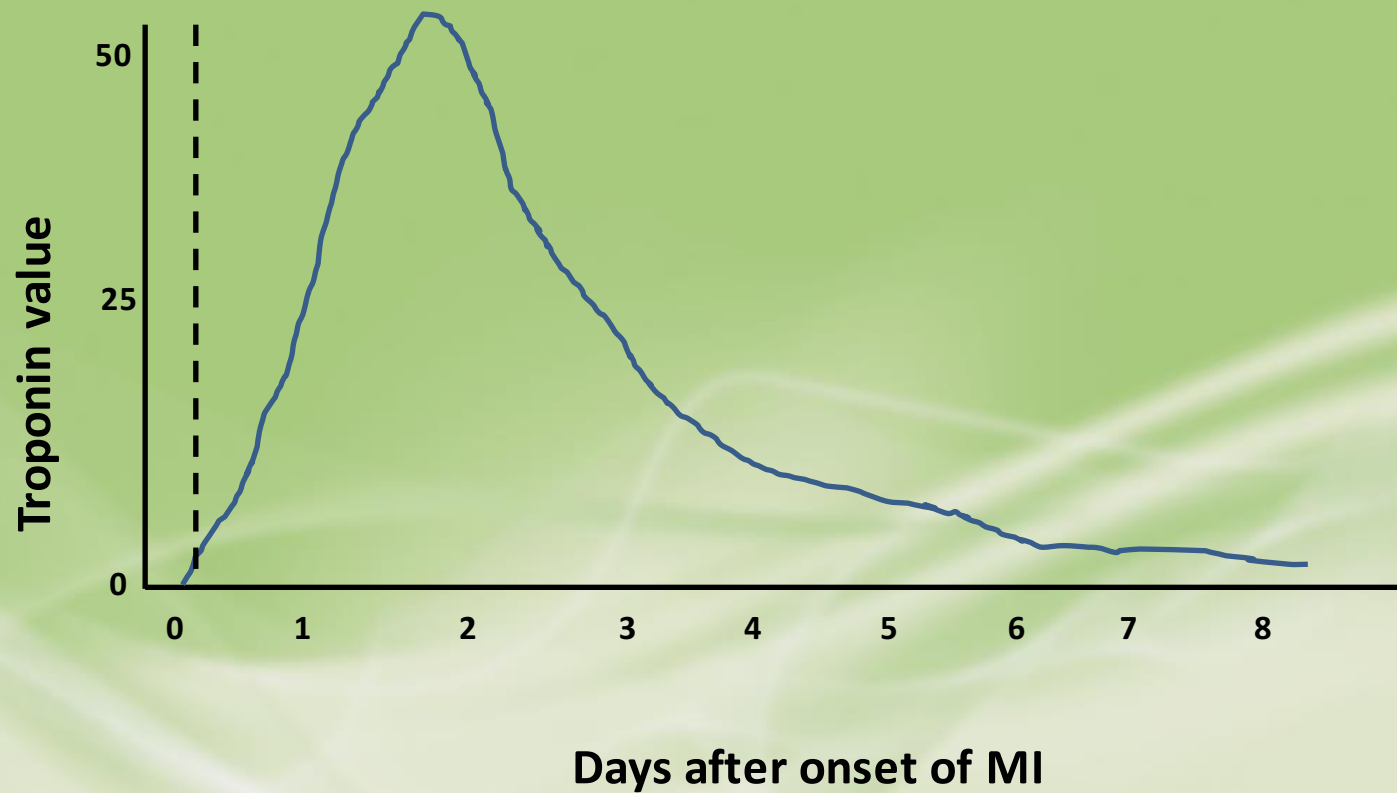
25mm/s 10mm/mV 150Hz 8.0 SP2 12SL 241 CID: 23

EID:11001 EDT: 16:33 18-APR-2019 ORDER: 474659177



Diagnostics

- Troponin



Signs and Symptoms

- CC of substernal chest pressure that began 3 hours ago with walking, now a 5/10
- Classic – ask about chest *discomfort*
 - location
 - type
 - onset with activity
- Concerning symptom that needs immediate intervention
 - ongoing chest discomfort



ACS Guidelines

STEMI

- Immediate medical interventions
 - Aspirin 324mg po
- LHC with door to balloon time 90min

Non-STEMI

- Immediate medical interventions
 - Aspirin 324mg po
- May need LHC and intervention in future



Immediate Medical Interventions

- Aspirin 324mg chewed
- 12-ECG
- Nitro SL, morphine 2-4mg IV for ongoing CP
- Labs
 - Troponin, PT/PTT, BMP, CBC
 - Creatinine, glucose, electrolytes, H&H
 - HA1c, lipids
- Chest x-ray to check for signs of aortic dissection



Brief Physical Examination

- A, B, C
 - Airway, Breathing, Circulation
- Vital signs
- Signs of CHF
 - Jugular venous distension
 - Pulmonary auscultation for rales
- Cardiac for murmurs and gallops
- Neuro for focal defect indicative of stroke
- Upper and lower extremity assessment for pulses
- Systemic hypoperfusion (cool, clammy, pale)



Key History Points

- Allergies
 - Contrast dye
- Bleeding issues
- Upcoming surgeries
- Medications
 - Blood thinners
 - Last taken?
- Previous history of MI, interventions
 - Records
 - *Does this feel the same?*



Take for Left Heart Cath?

Pros

- LHC for intervention on completely occluded vessel responsible for STEMI
- Early intervention to preserve heart muscle and function

Cons

- Complication from LHC
- Adverse reaction to new medication
- Compliance issues
- Insurance issues



Other Interventions

- A – anti-platelets / anti-coagulation loading
 - aspirin
 - clopidogrel / ticagrelor
 - heparin IV drip
- B – beta blocker
- A – ace inhibitor
- S – statin



Mr. Smith

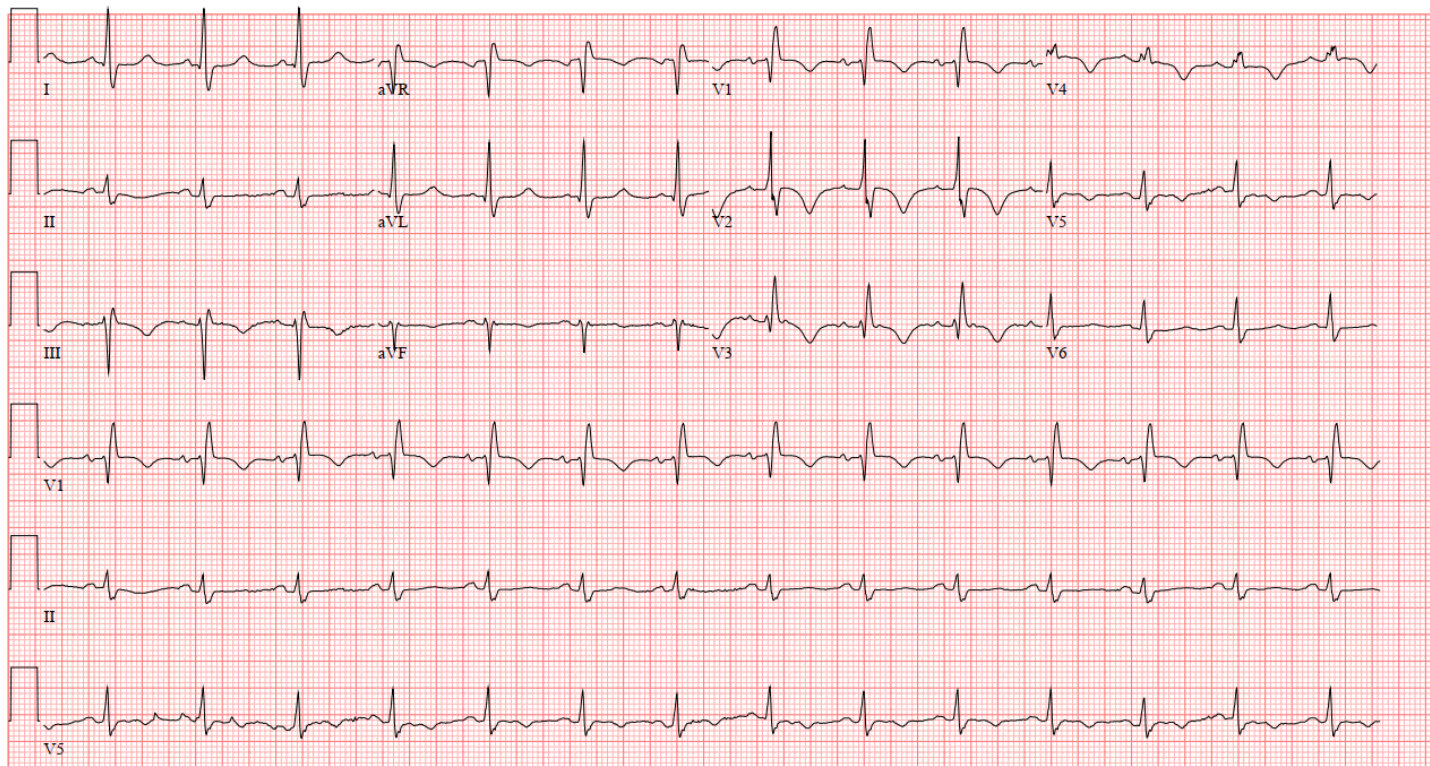
- 56M s/p renal transplant 2 days ago complicated by intra-abdominal hematoma and slow graft function
- PMH – DMI, CAD s/p LAD stent 4 years ago
- Substernal chest pain with ambulation in hallway and elevation of HR to 130s
- T wave inversions on telemetry and 12-ECG
- CP relieved after nitro SL x1 and cessation of activity



12-ECG

Vent. rate	85	BPM	Normal sinus rhythm
PR interval	146	ms	Right bundle branch block
QRS duration	120	ms	T wave abnormality, consider lateral ischemia
QT/QTc	440/523	ms	Abnormal ECG
P-R-T axes	44 -28 -23		When compared with ECG of 20-JAN-2020 21:05,

Technician ID: 11331
Test ind: Chest Pain



25mm/s 10mm/mV 150Hz 9.0.9 12SL 241 CID: 23

EID:12008 EDT: 13:43 26-JAN-2020 ORDER: 599218538 ACCOUNT: 2000326025096

Page 1 of 1



Immediate Medical Interventions

- Aspirin 324mg chewed
- No other anti-platelet, no heparin d/t intra-abdominal hematoma
- Delayed graft function requiring dialysis
- Creat=6.2
- Troponin elevated
- Anemic
- Chest x-ray neg for aortic dissection



Critical Decision Points

Should this patient go for a LHC?

1. No. The risk to the new kidney is too high.
2. Yes. This is evidence of a new blockage that needs to be addressed.
3. Not yet. Initiate medical treatment first, then plan for LHC when new kidney is functioning well.



Take for LHC?

Pros

- Chest discomfort with ST depression with minimal ambulation indicates a blockage
- Blockage needs to be addressed in order to continue recovery

Cons

- Delayed graft function
- Contrast dye from LHC could damage the new kidney
- Patient is anemic and DAPT may make increase bleeding risk



What happened?

- Medical therapy
- Aspirin load and daily
- No DAPT, no heparin
- Metoprolol to improve heart rate control and double product (HR x SBP)
- No ace inhibitor d/t elevated creatinine
- Statin initiated



What happened?

- PO day #4 went into Afib w RVR during walk in hallway, HR 140 – 160s
- ST elevation on telemetry and 12-ECG
- Substernal chest pain with SOB 10/10
- Metoprolol IV, Nitro SL, and morphine 2mg IV
- Urgently take for LHC and DES x1 to LAD placed
 - Dialysis post LHC
 - H&H monitored
- Kept in hospital until new kidney was functioning well



Mrs. Peters

- 78F w sepsis c/o chest discomfort
- ST depression on 12-ECG and troponin elevation
- ECHOcardiogram with reduced EF 40%
- PMH - HTN



Take for Left Heart Cath?

Pros

- Needs LHC to assess for blockage(s) for stent placement or may have multivessel disease and need CABG
- Needs LHC to treat blockage that could have caused abnormal EF on ECHOcardiogram

Cons

- Abnormal EF could be d/t sepsis
- Increased risk of complications d/t age and critical illness



Critical Decision Points

What is the best course of treatment?

1. Take for a LHC d/t ECG changes, troponin elevation, and reduced EF on ECHOcardiogram
2. Wait to take for a LHC until the patient's sepsis has resolved
3. Treat medically and never take for LHC d/t advanced age
4. Treat medically and discuss with patient/family the option of LHC when she has recovered



What happened?

- Treated medically and had no further episodes of CP during recovery
- Underwent stress testing prior to discharge to rehab
- Passed stress test (no ischemia) on optimal medical therapy and with controlled BP
- LHC not performed
- EF had returned to normal on repeat ECHOcardiogram



Questions?



References

Amsterdam, E. A., Wenger, N.K., Brindis, R.G., Casey, Jr, D.E., Ganiats, T.G., Holmes, D.R., Jaffe, A.S., Jneid, H., Kelly, R.F., Kontos, M.C., Levine, G.N., Liebson, P.R., Mukherjee, D., Peterson, E.D., Sabatine, M.S., Smalling, R.W., Zieman, S.J. (2014). AHA/ACC guideline for the management of patients with non–ST-elevation acute coronary syndromes. A report of the American college of cardiology/American heart association task force on practice guidelines. *Circulation*, 130(25).
<https://doi.org/10.1161/CIR.000000000000134>

Elliott M. Antman, E.M., Anbe, D.T., Armstrong, P.W., Bates, E.R., Green, L.A., Hand, M., Hochman, J.S., Krumholz, H.M., Kushner, F.G., Lamas, G.A., Mullany, C.J., Ornato, J.P., Pearle, D.L., Sloan, M.A., Smith, Jr., S.C. (2004)
ACC/AHA guidelines for the management of patients with ST-elevation myocardial infarction a report of the American college of cardiology/American heart association task force on practice guidelines (committee to revise the 1999 guidelines for the management of patients with acute myocardial infarction). *Circulation*, 110(9).
<https://www.ahajournals.org/doi/10.1161/circ.110.9.e82>