

ATYPICAL FEMUR FRACTURES

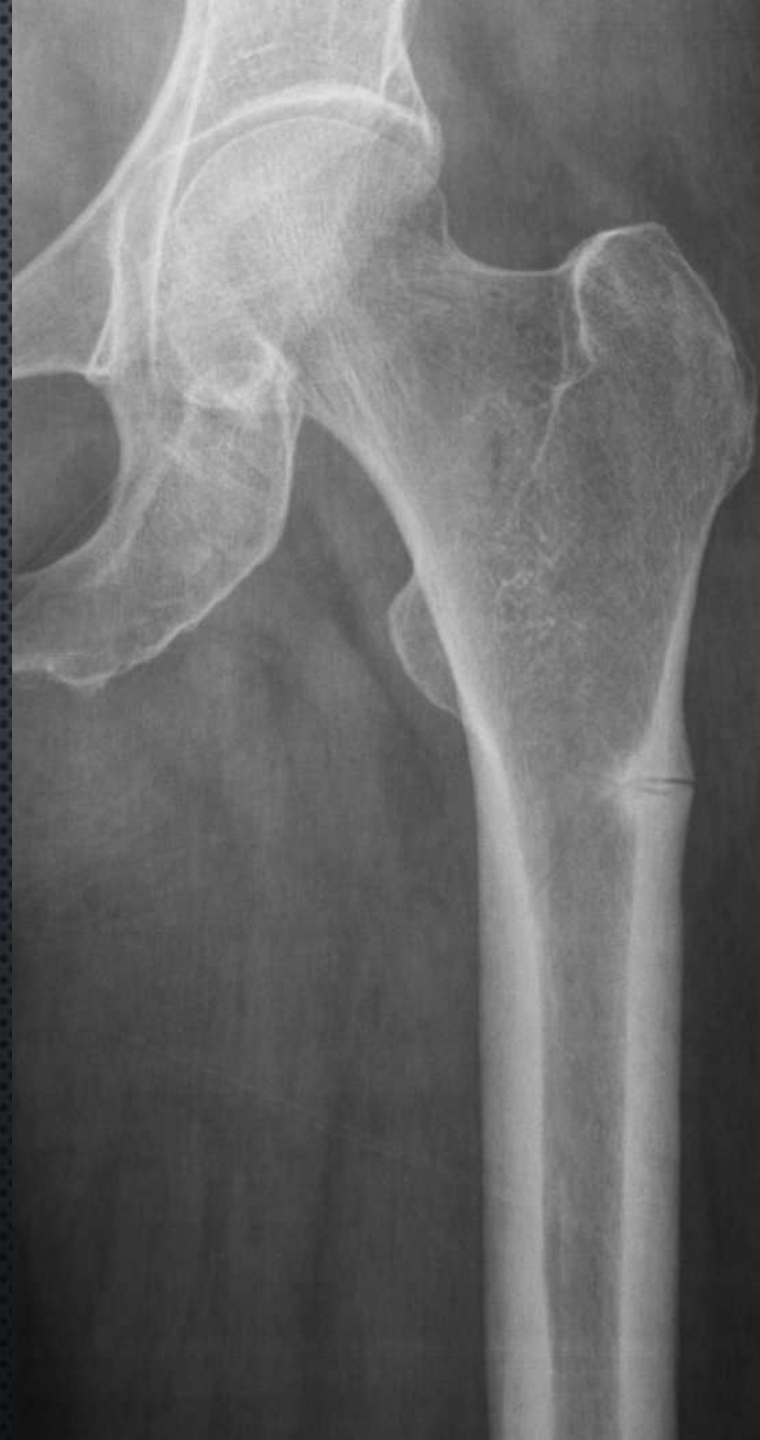2020 PAOS CONFERENCE

DAVID NILSEN, D.O.

BANNER HEALTH

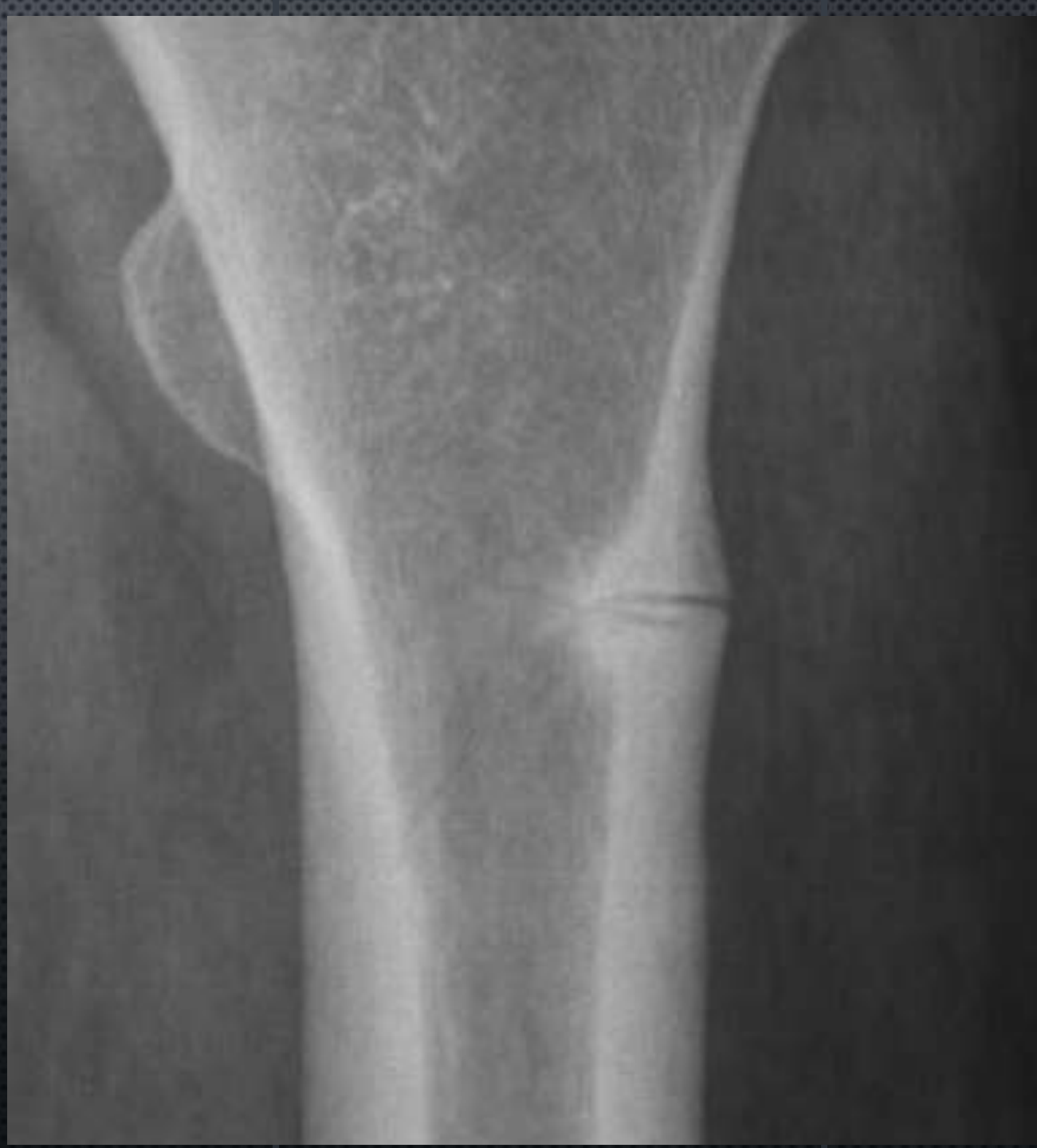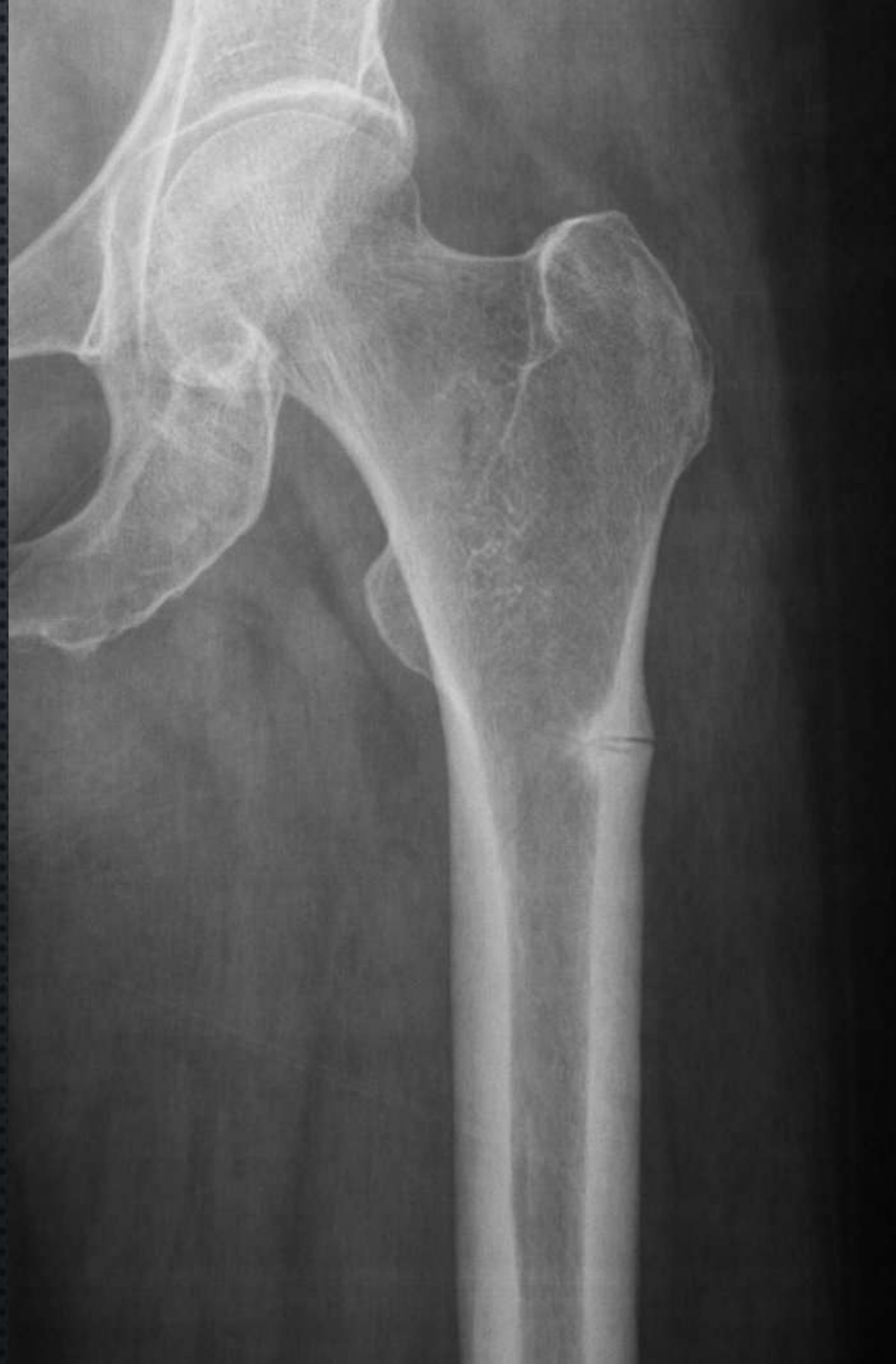DISCLOSURES

- NONE



ATRAUMATIC SUBTROCHANTERIC FRACTURE

- 70YO FEMALE
- COMMUNITY AMBULATOR, AVID BIRDWATCHER, HAS STARTED USING CANE DUE TO PAIN
- THIGH PAIN DEVELOPED OVER LAST 8W
- PMHx: HYPOTHYROID, HTN, OSTEOPOROSIS, DMII CONTROLLED, RHEUMATOID
- MEDS: LEVOTHYROXINE, LOSARTAN, FOSAMAX, METFORMIN, METHOTREXATE, INFlixIMAB



BISPHOSPHONATE RELATED SUBTROCANTERIC FRACTURE

- FIX FX (OF COURSE)
- DISCUSS WITH ALL PATIENTS ON BISPHOSPHONATES
- CHECK CONTRALATERAL SIDE
 - PROPHYLACTIC NAILING
- DRUG HOLIDAY
 - 7YRS? (PCP OR ENDOCRINOLOGIST)

FEMORAL NECK FX COMPLICATED BY HARDWARE

- 82YO MALE WITH MECHANICAL FALL
- HAS HAD 5 KNEE ARTHROPLASTIES WITH 2 INFECTIONS, HAS LARGE STEMMED ENDOPROSTHESIS
- HX CABG, RA, HYPONATREMIA, CHRONIC STEROID USE

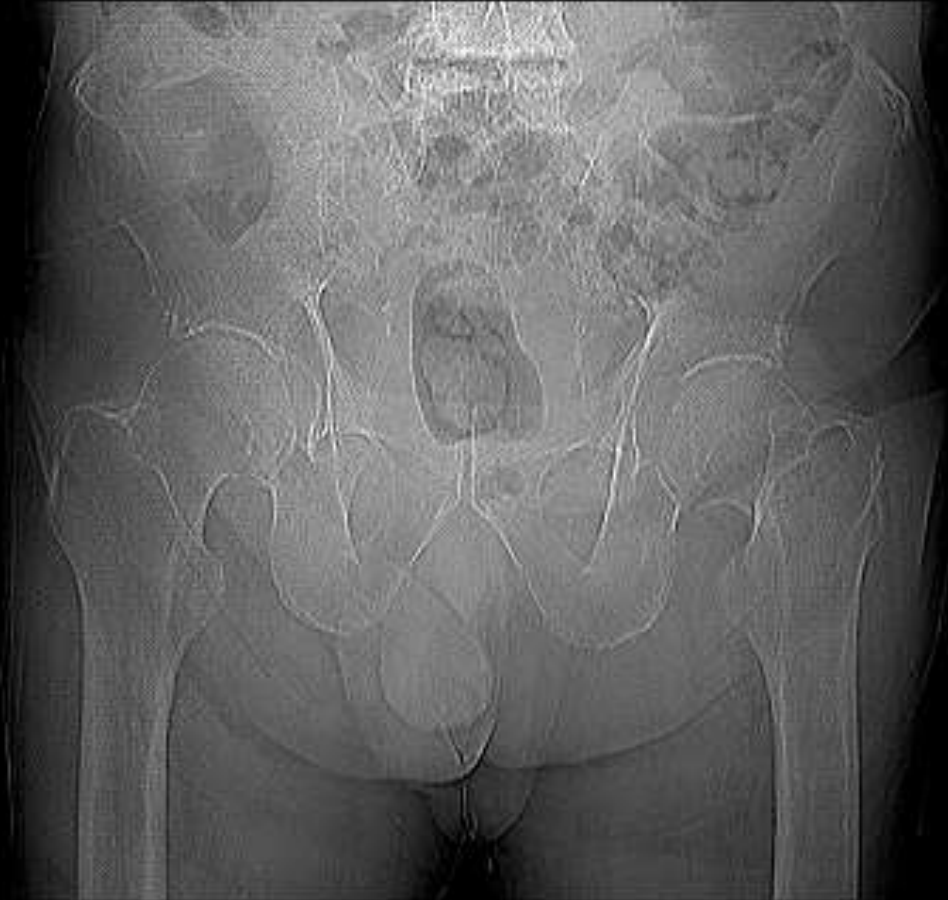
H

CT Pelvis W/O Contrast
2.0(Localizer)

11/22/1937
81 YEAR
M

4/17/2019 3:47:11 PM
38338737

LOC: -162
THK: 2
HFS



R

L

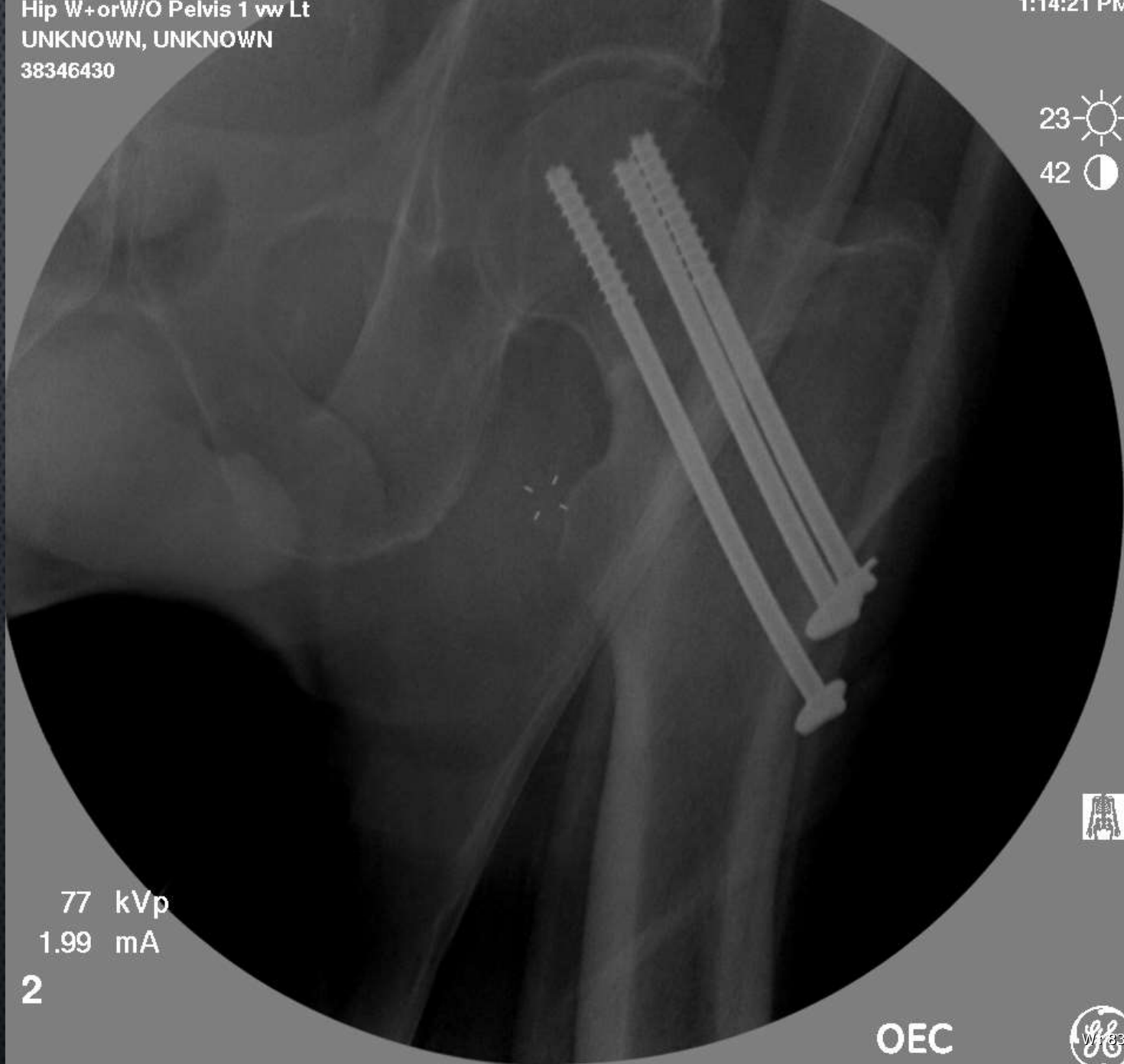RD: 500
Tilt: 0
mA: 50
KVp: 120
Acq no: 1

Z: 1
C: 130
W: 170
DFOV:51.2x51.2cm
Compressed 8:1
IM: 1 SE: 1



Hip W+orW/O Pelvis 1 ww Lt
UNKNOWN, UNKNOWN
38346430

1:14:21 PM
23 ☀️
42 🌙



77 kVp
1.99 mA
2

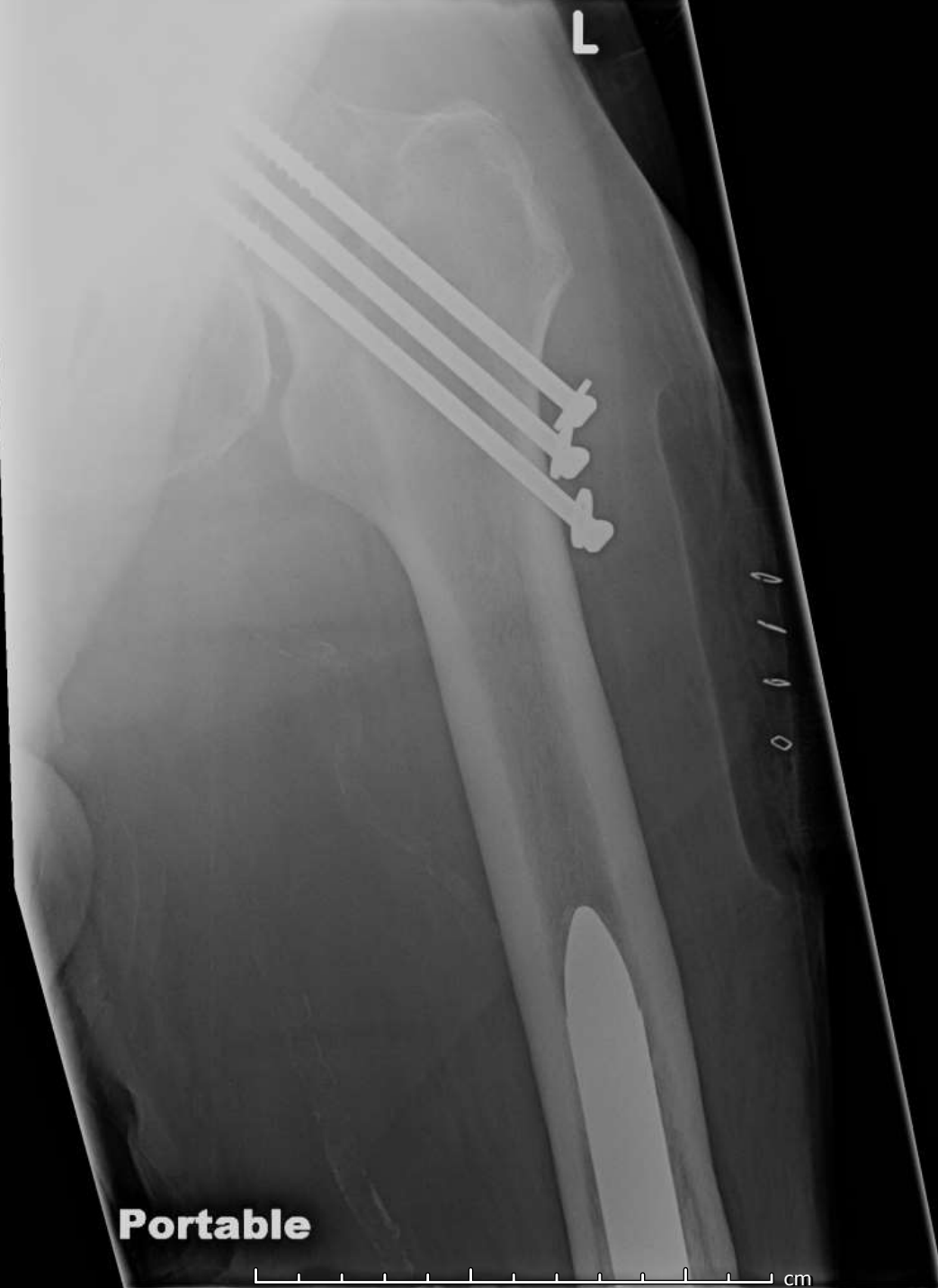

OEC



11/22/1937
81 YEAR
M

Femur 2 or more vws Lt
KNEE LAT
4/19/2019 10:43:03 AM
38352526



Portable

cm

S: 74
Z: 0.51
C: 511
W: 1023
Compressed 32:1
IM: 1005

11/22/1937
81 YEAR
M

IH Hip W+orW/O Pelvis 2-3 vws t

5/2/2019
14643889001

L
MG

Z: 0.34
C: 204
W: 4096
Compressed
IM: 1



NEXT OPTIONS?

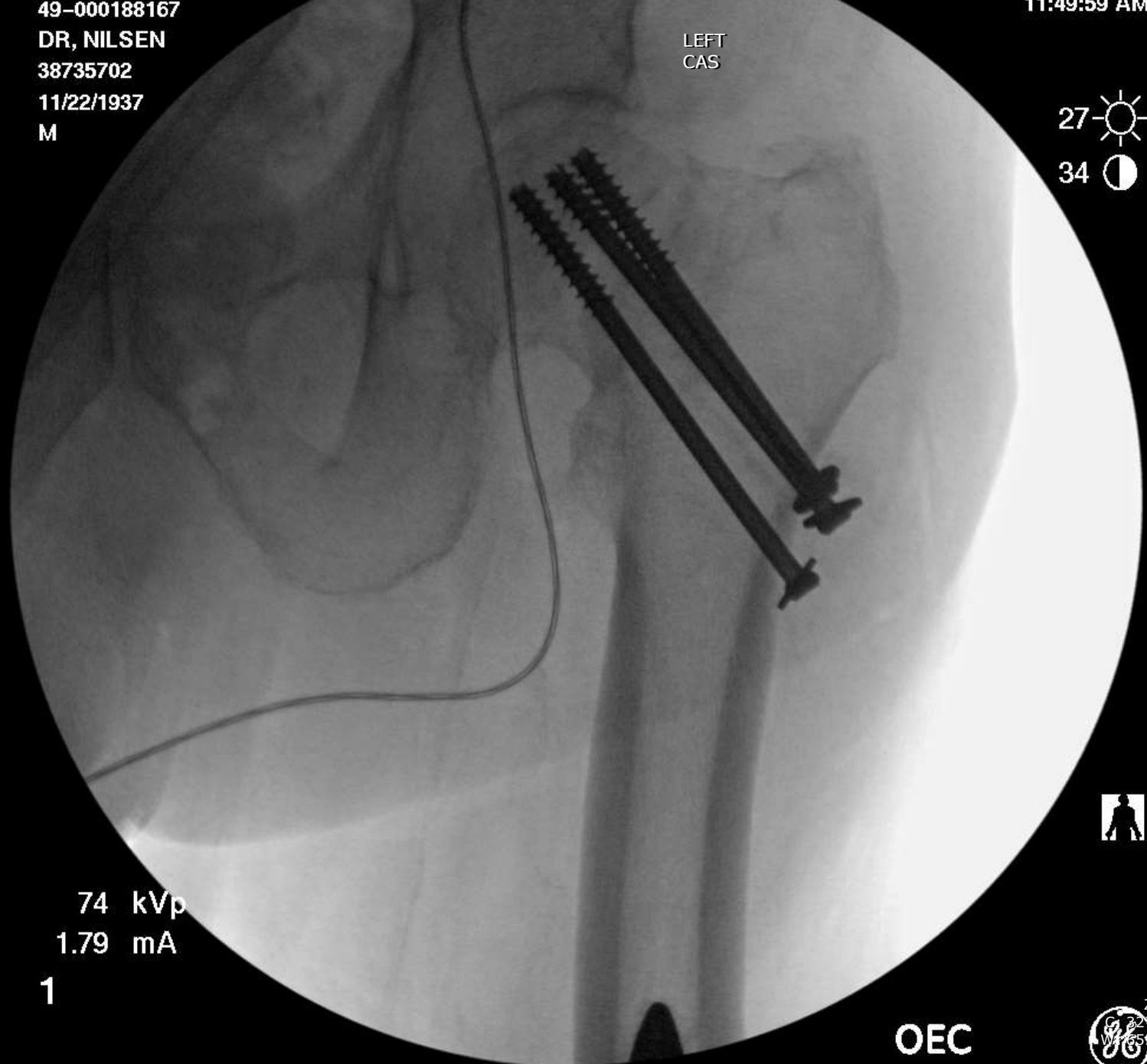
- BLADE PLATE
- SUBSTRATE AUGMENTATION
- REPEAT SCREW FIXATION
- FEMORAL NECK FIXATION DEVICES
- HEMIARTHROPLASY

49-000188167
DR, NILSEN
38735702
11/22/1937
M

11:49:59 AM

LEFT
CAS

27 
34 



74 kVp
1.79 mA

1



OEC



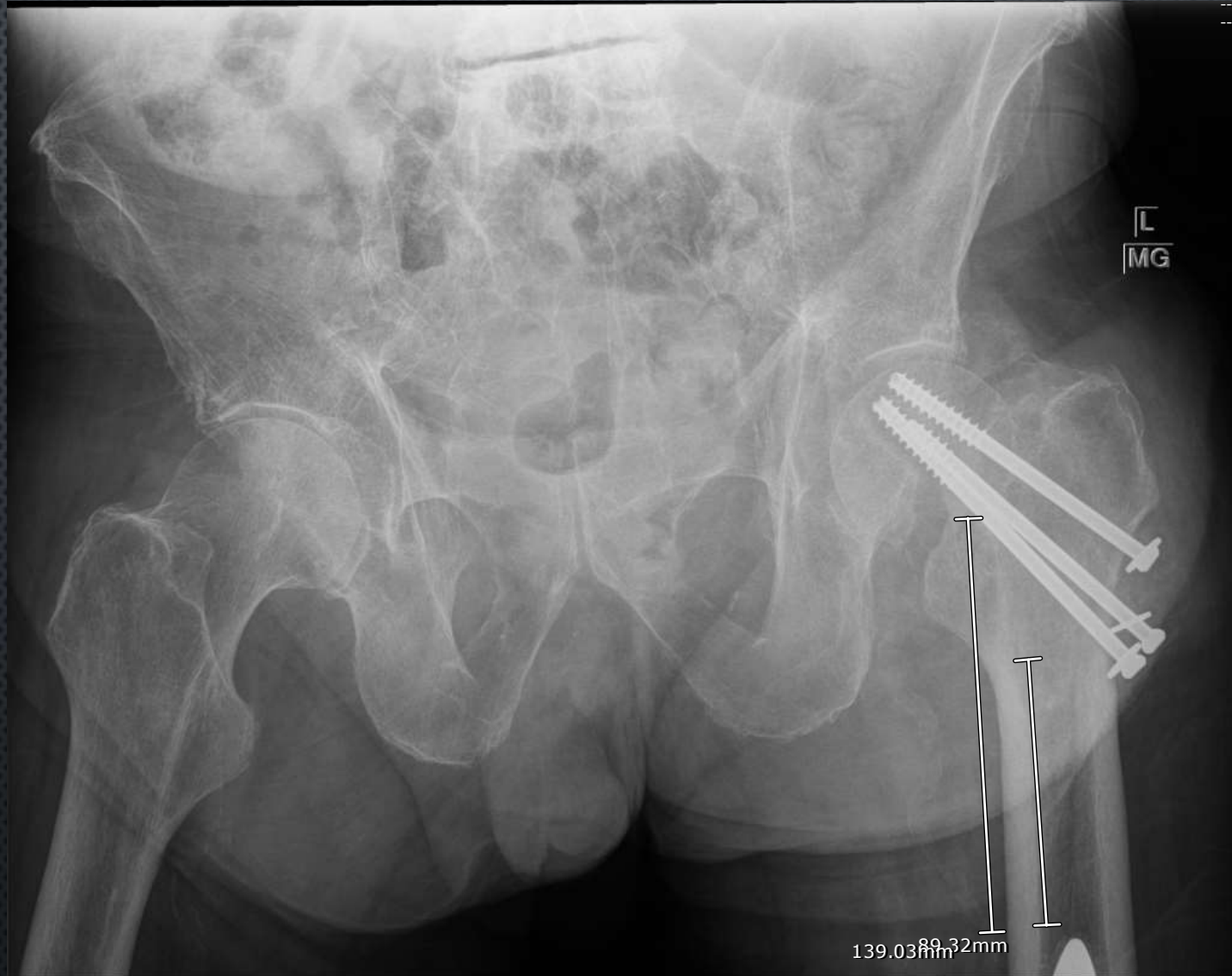11 DAYS LATER.....

- INCREASING PAIN
- LIMITED AMBULATION

11/22/1937
81 YEAR
M

IH Hip W+orW/O Pelvis 2-3 vws Lt

6/25/2019 2:04:13 PM
15148842747

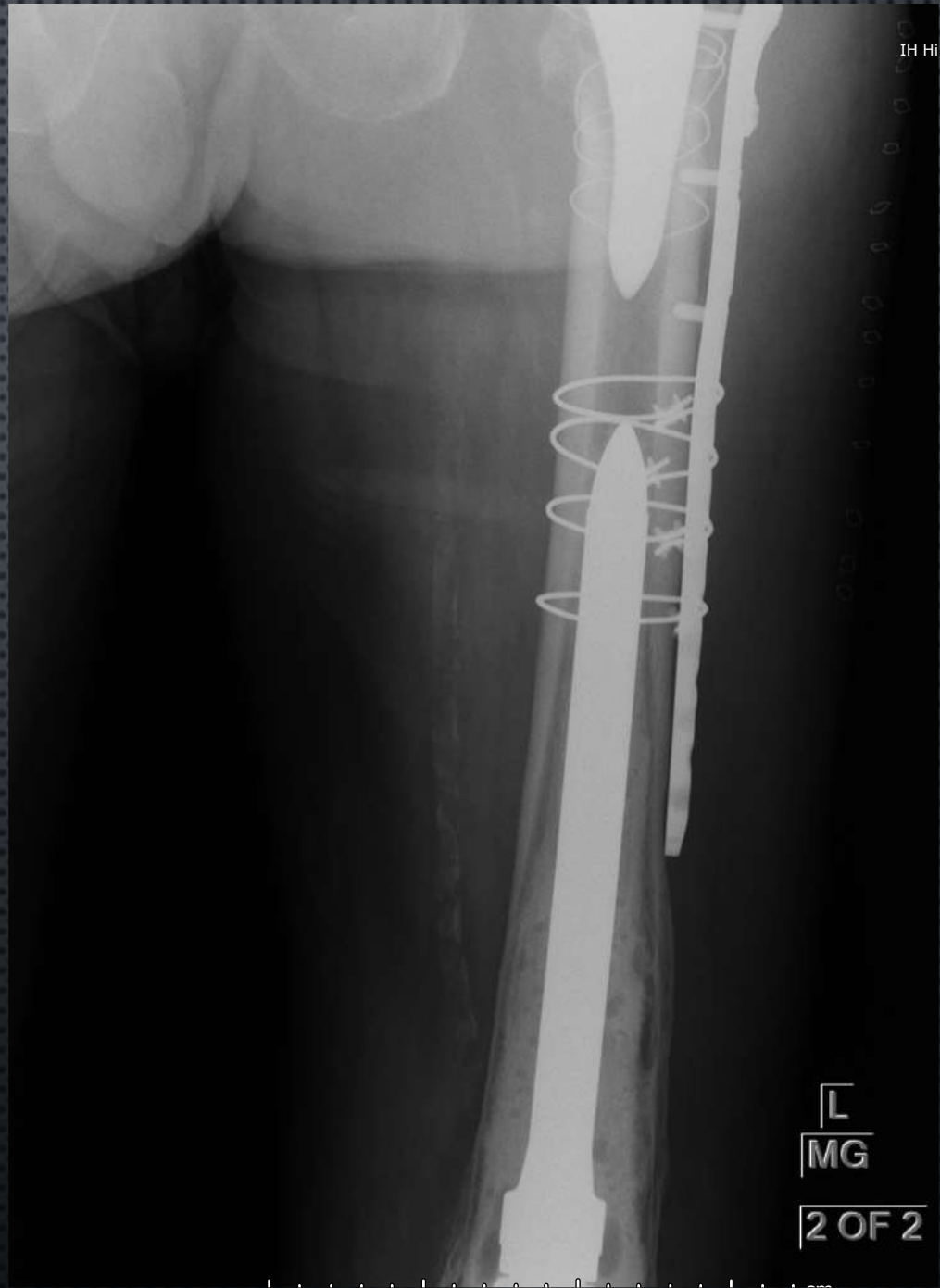
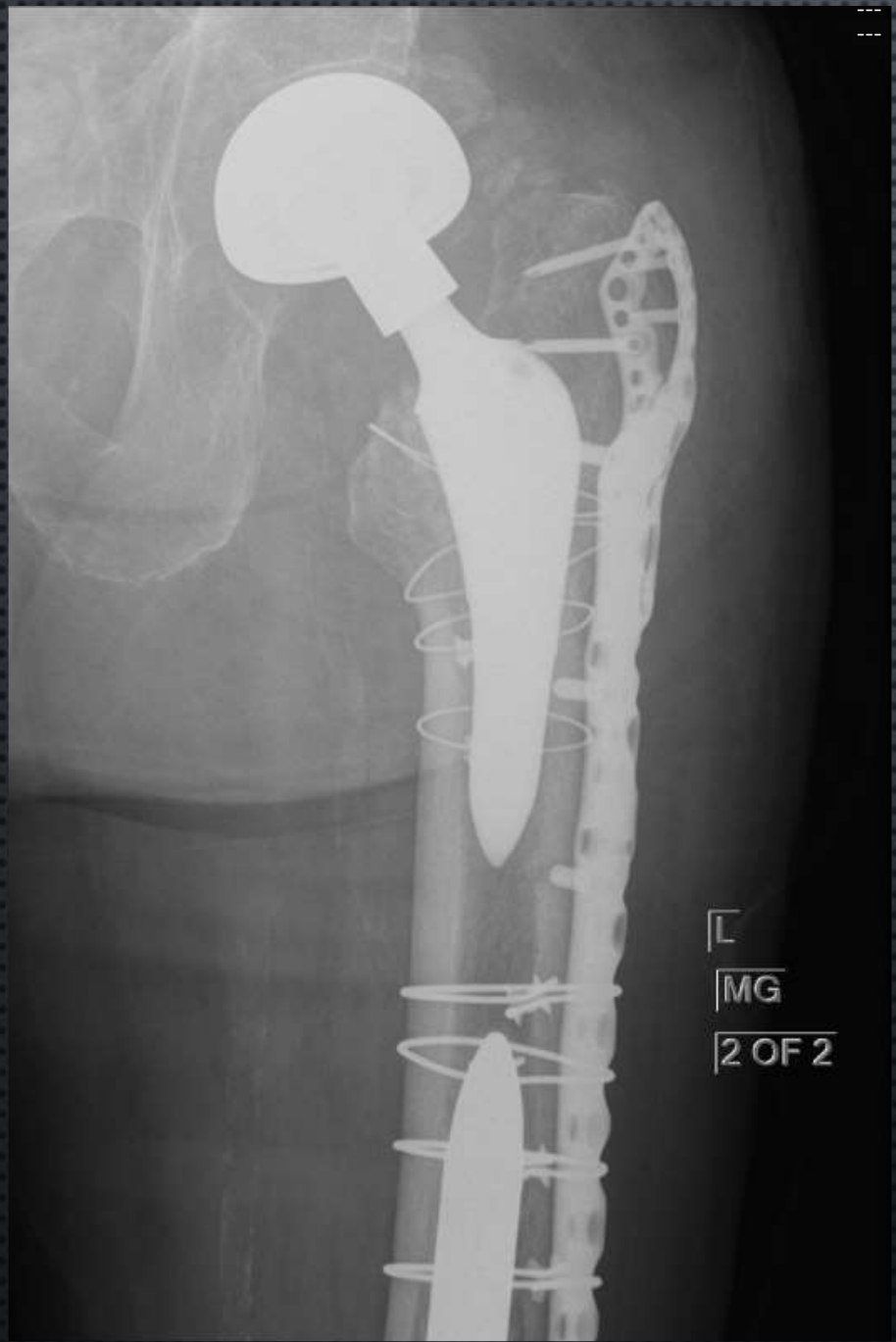
Z: 0.34
C: 2048
W: 4096
Compressed 27:1
IM: 1



NEXT OPTIONS?

- OBSERVATION
- FEMORAL NECK FIXATION DEVICES
- HEMIARTHROPLASTY

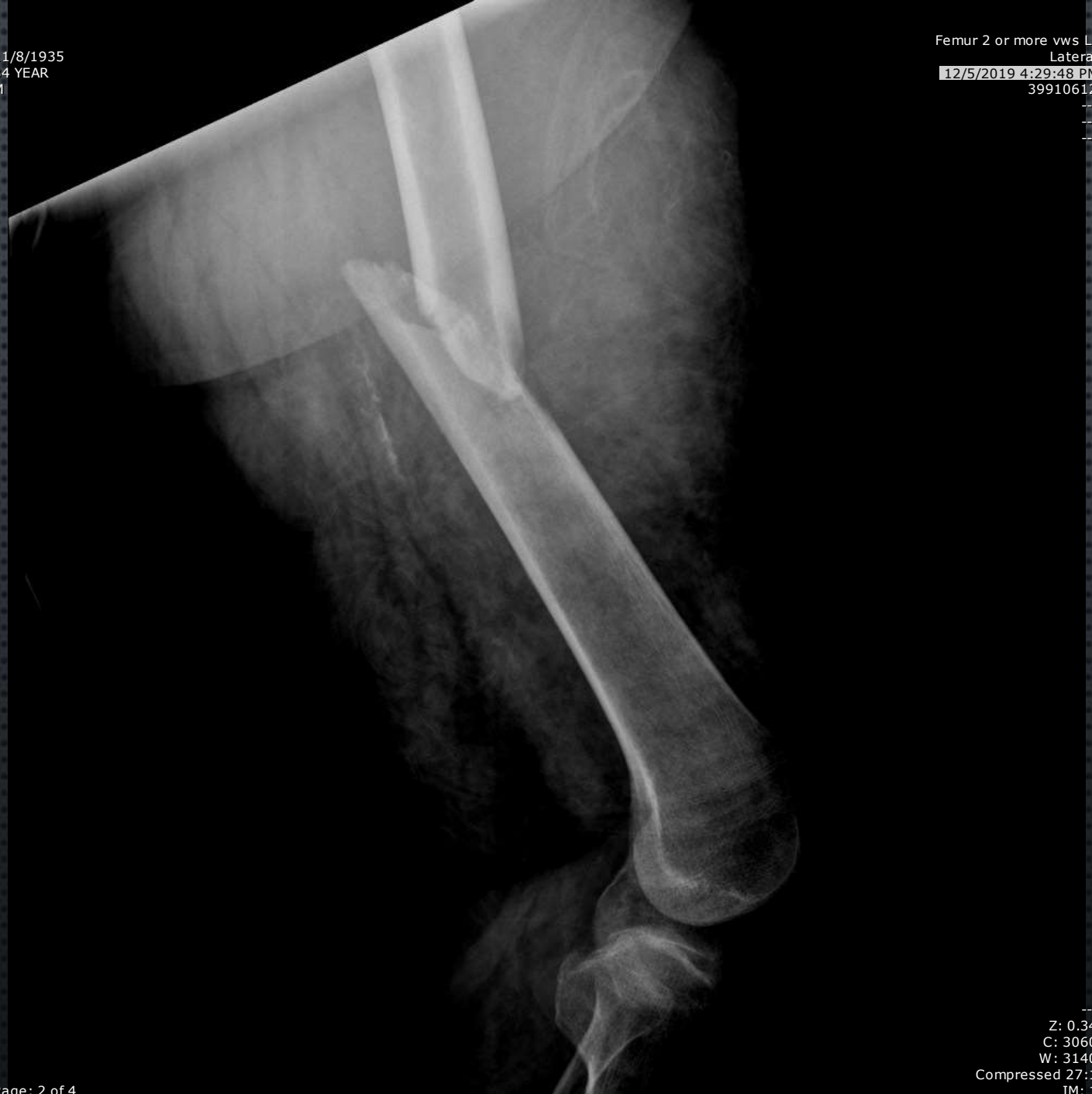


WHAT JUST HAPPENED?

- 84YO MALE WITH THIGH AND SHIN PAIN
- LEG GIVES OUT WHILE IN MY OFFICE WAITING TO BE SEEN
- HX OF PROSTATE CA, CHF

11/8/1935
84 YEAR
M

Femur 2 or more vws Lt
Lateral
12/5/2019 4:29:48 PM
39910612



Z: 0.34
C: 3060
W: 3140
Compressed 27:1
IM: 1

WHAT JUST HAPPENED?

- DIFFERENTIAL?

WHAT JUST HAPPENED?

- RUSSIAN PROVERB:
 - TRUST BUT VERIFY
- ALWAYS READ YOUR OWN FILMS AND MAKE YOUR OWN ASSESSMENTS
- READ THE RAD REPORT **AFTER** YOU'VE FORMED YOUR OWN OPINION

NEXT STEP?

- DIFFERENTIAL?
- CXR
- CAP (CHEST, ABDOMEN, PELVIS)
- BONE SCAN
- MRI

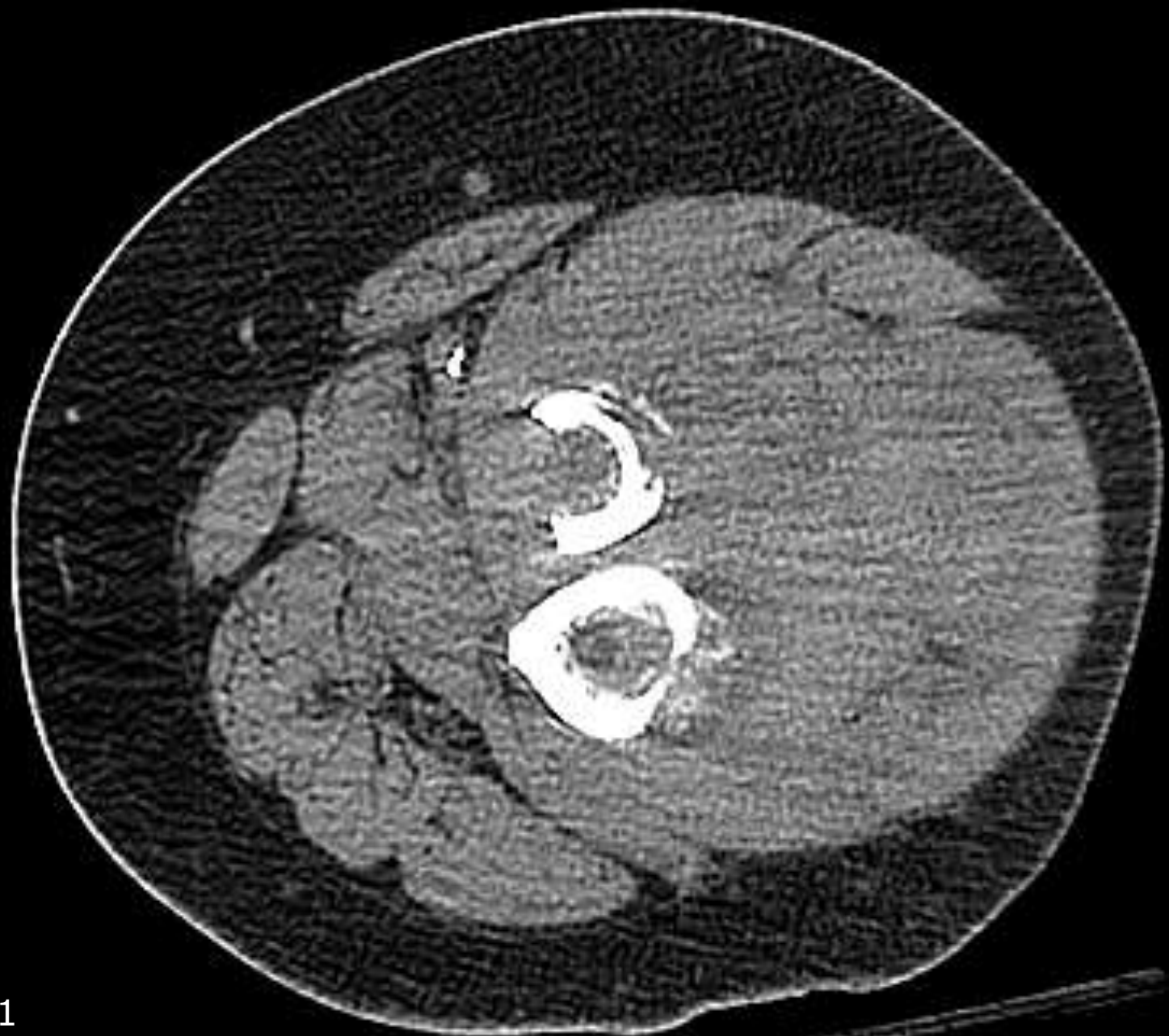
39914637

LOC: 122
THK: 2
FFS

M

R

L



RD: 320.31
Tilt: 0

7.1

M

39914637

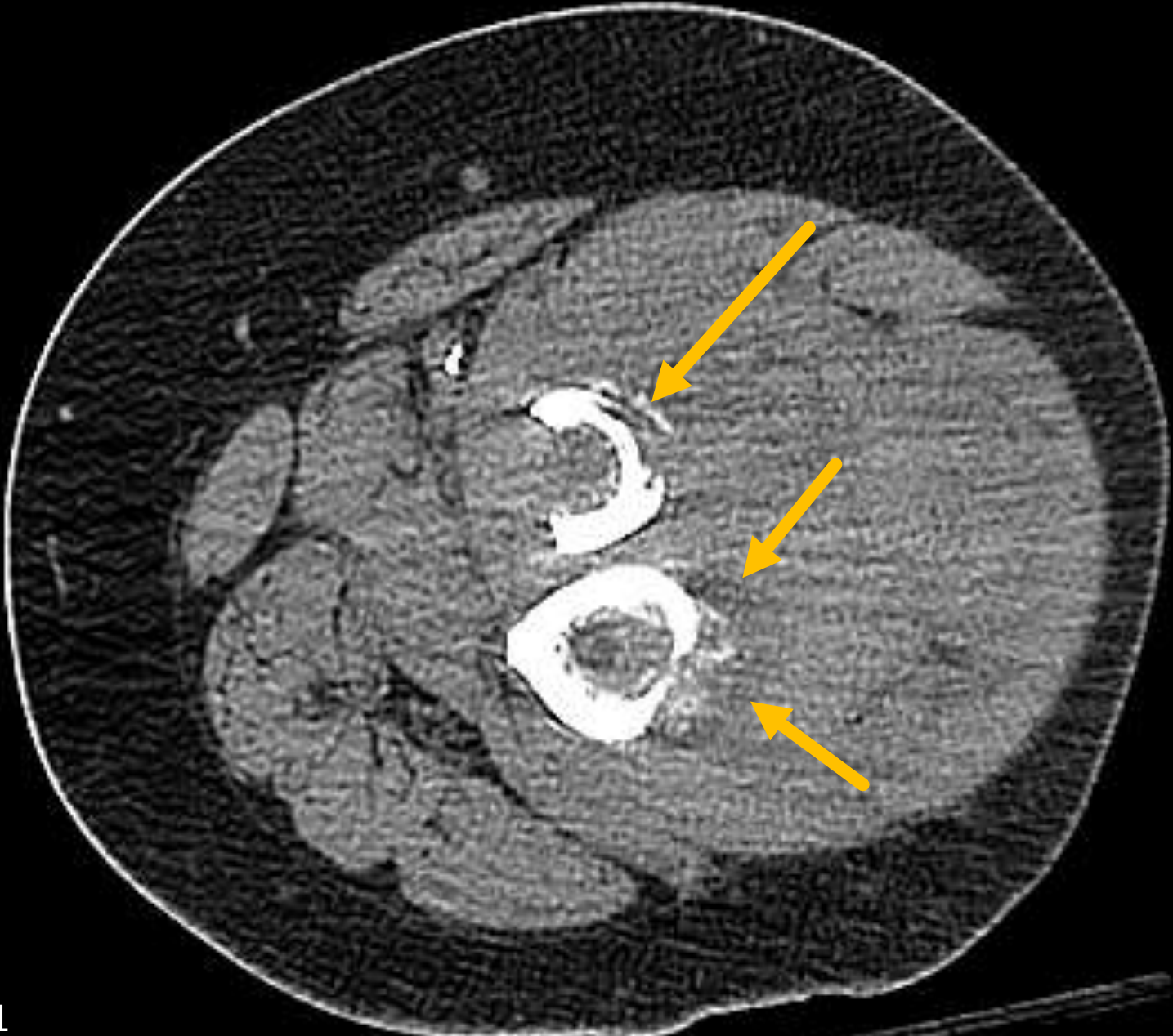
LOC: 122

THK: 2

FFS

R

L



RD: 320.31

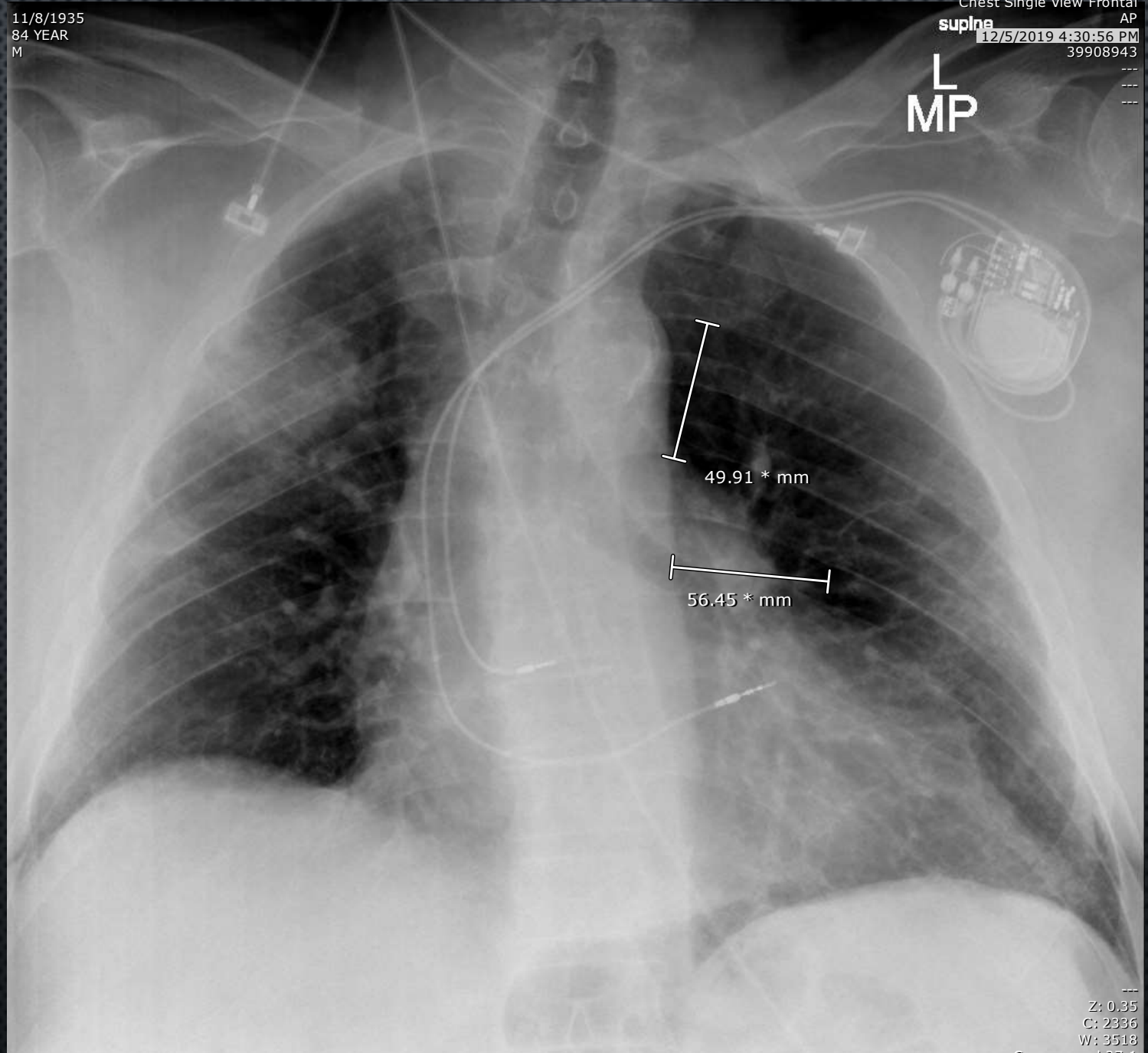
Tilt: 0

7: 1

11/8/1935
84 YEAR
M

Chest Single view Frontal
AP
supine
12/5/2019 4:30:56 PM
39908943

L
MP



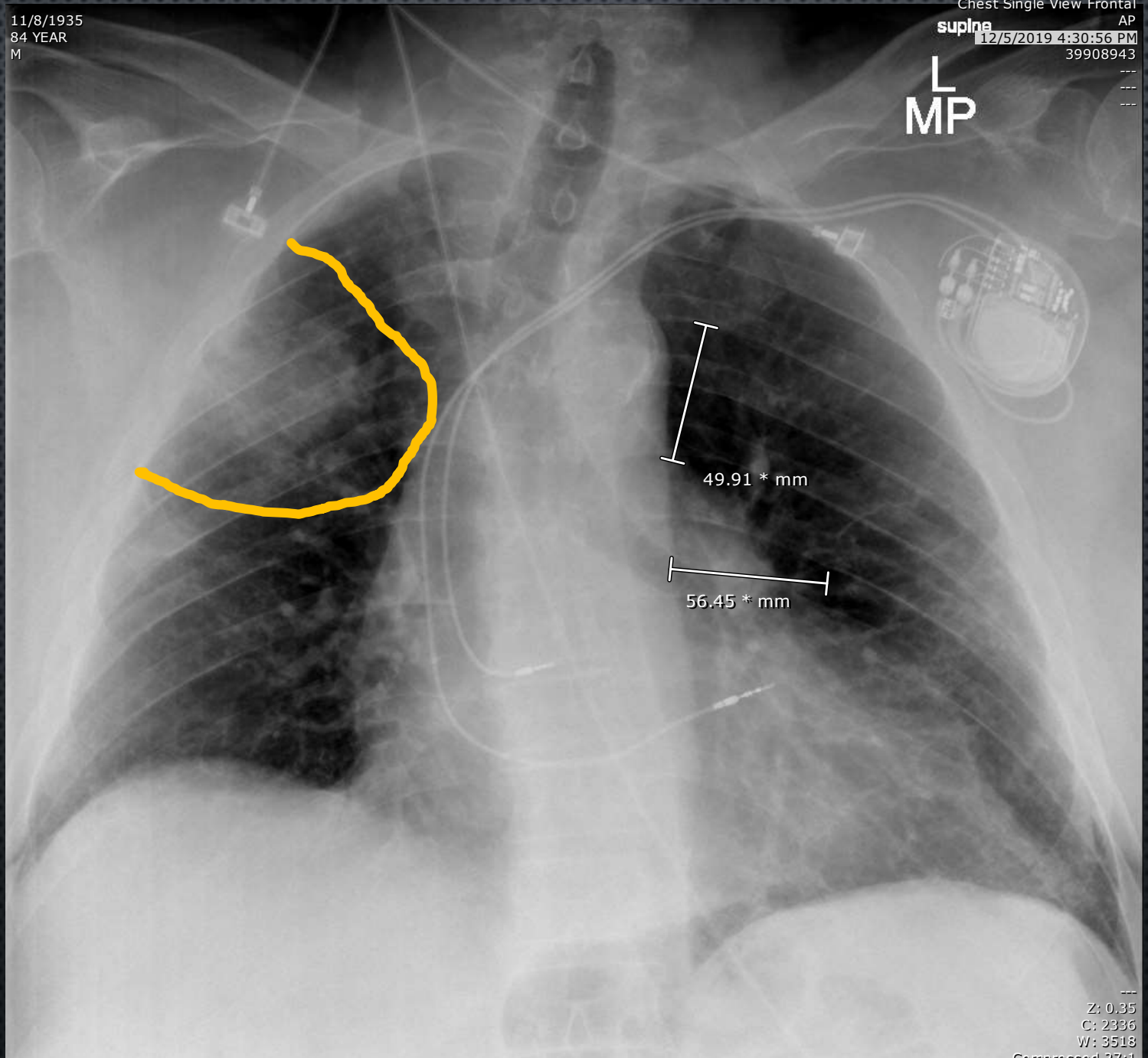
Z: 0.35
C: 2336
W: 3518
Compressed 27:1
IM: 1




11/8/1935
84 YEAR
M

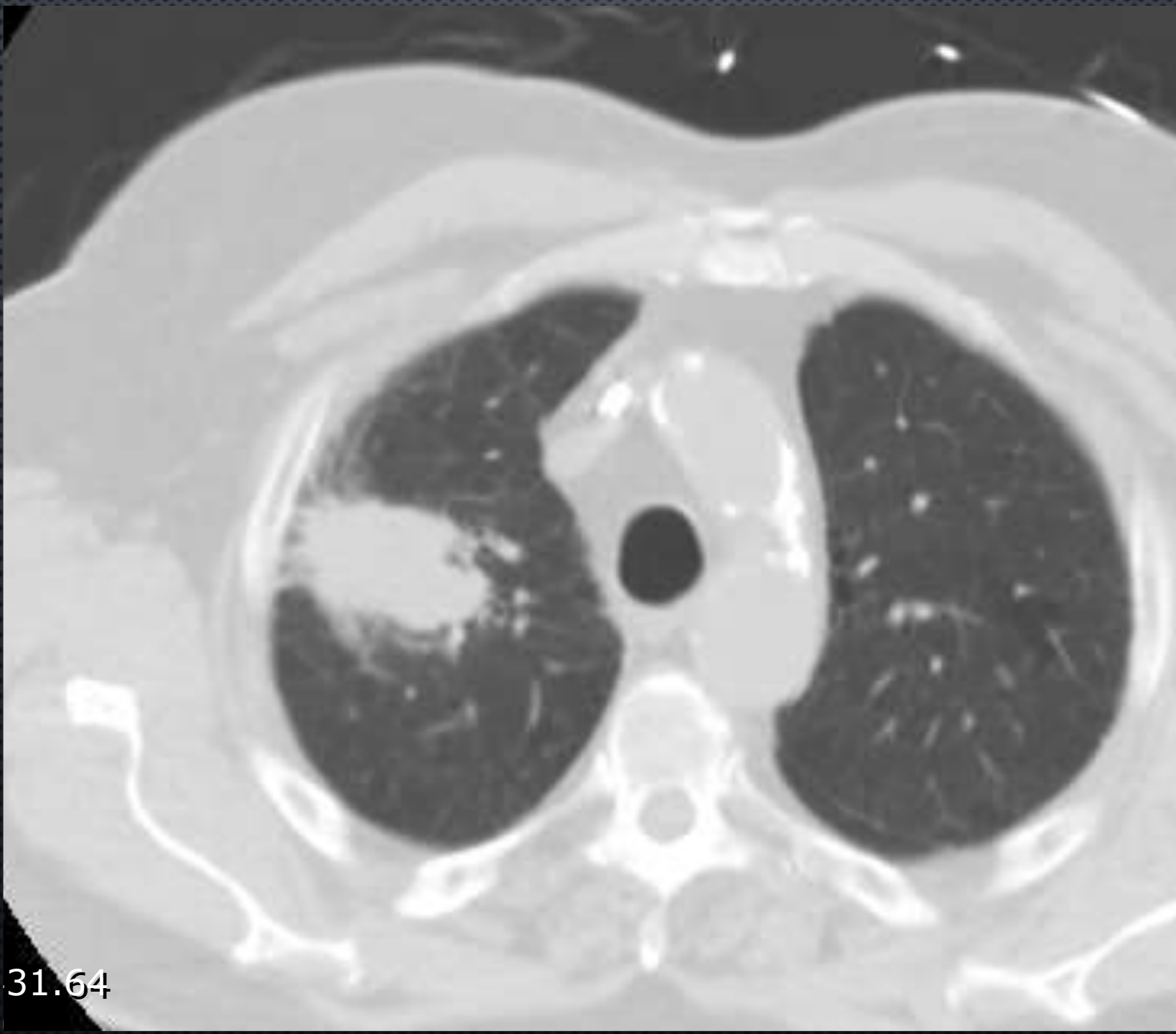
Chest Single View Frontal
AP
supine
12/5/2019 4:30:56 PM
39908943

L
MP



Z: 0.35
C: 2936
W: 3518
Compressed 27:1
IM: 1



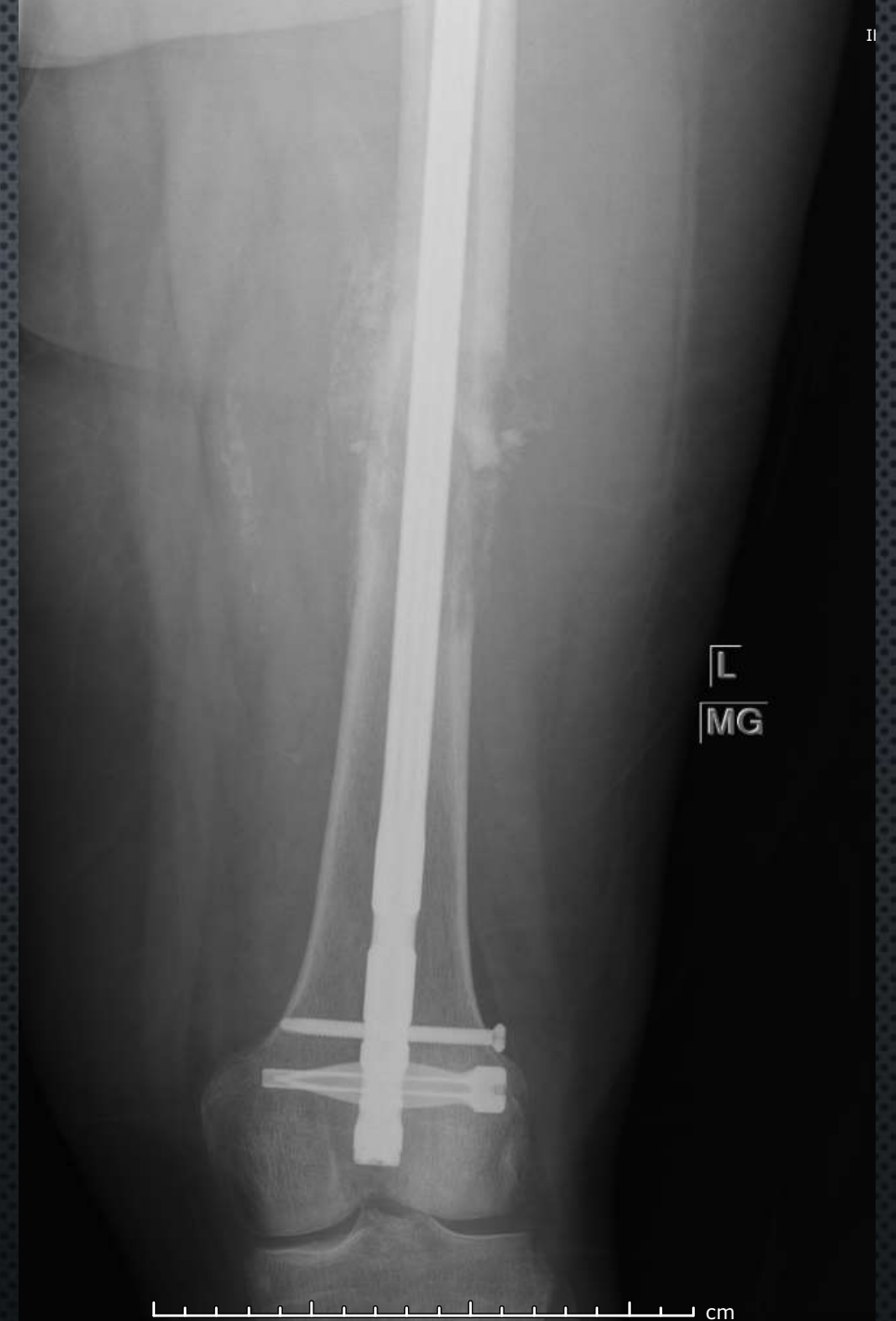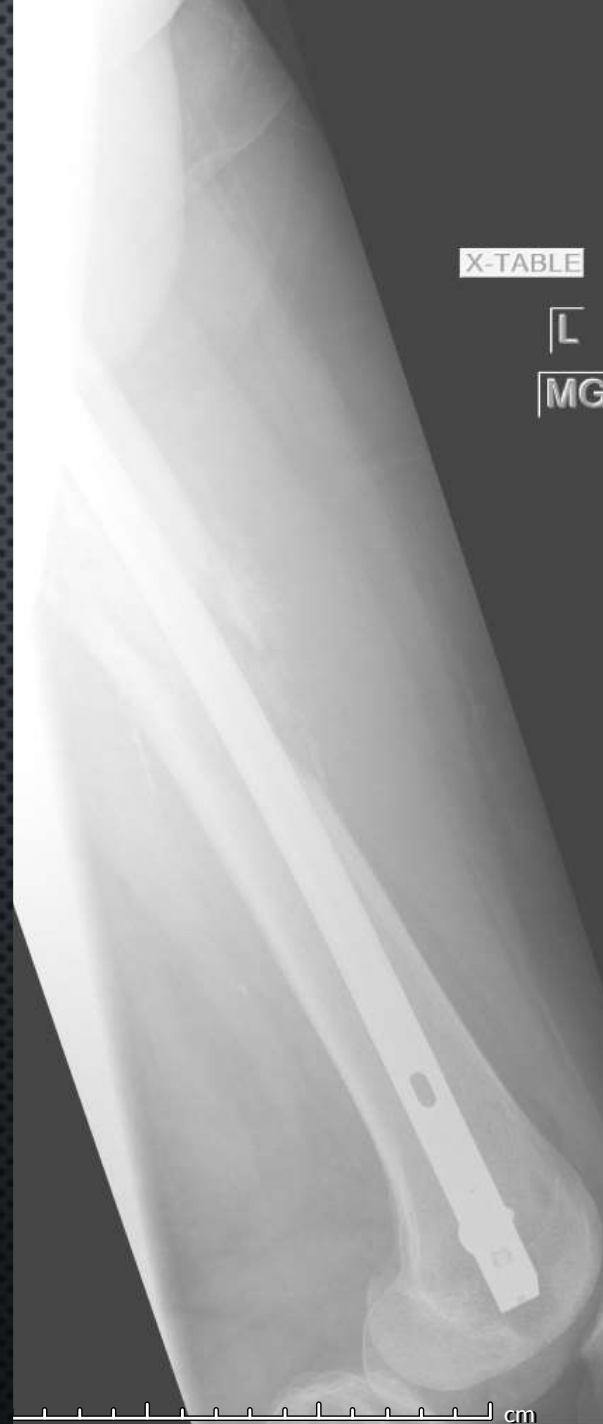


31.64

Femur 2 or more vws Lt
NILSEN, DAVID
39917461

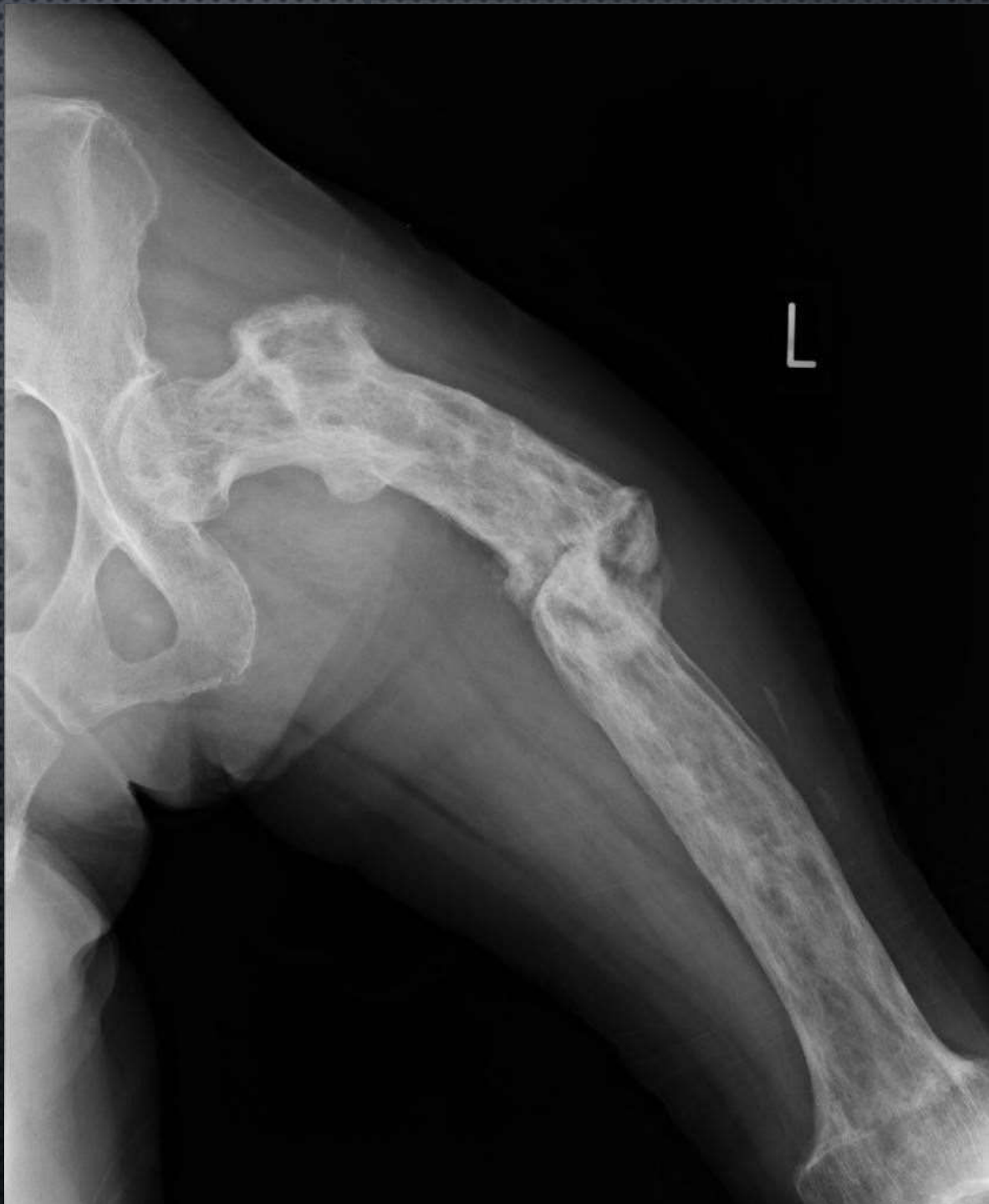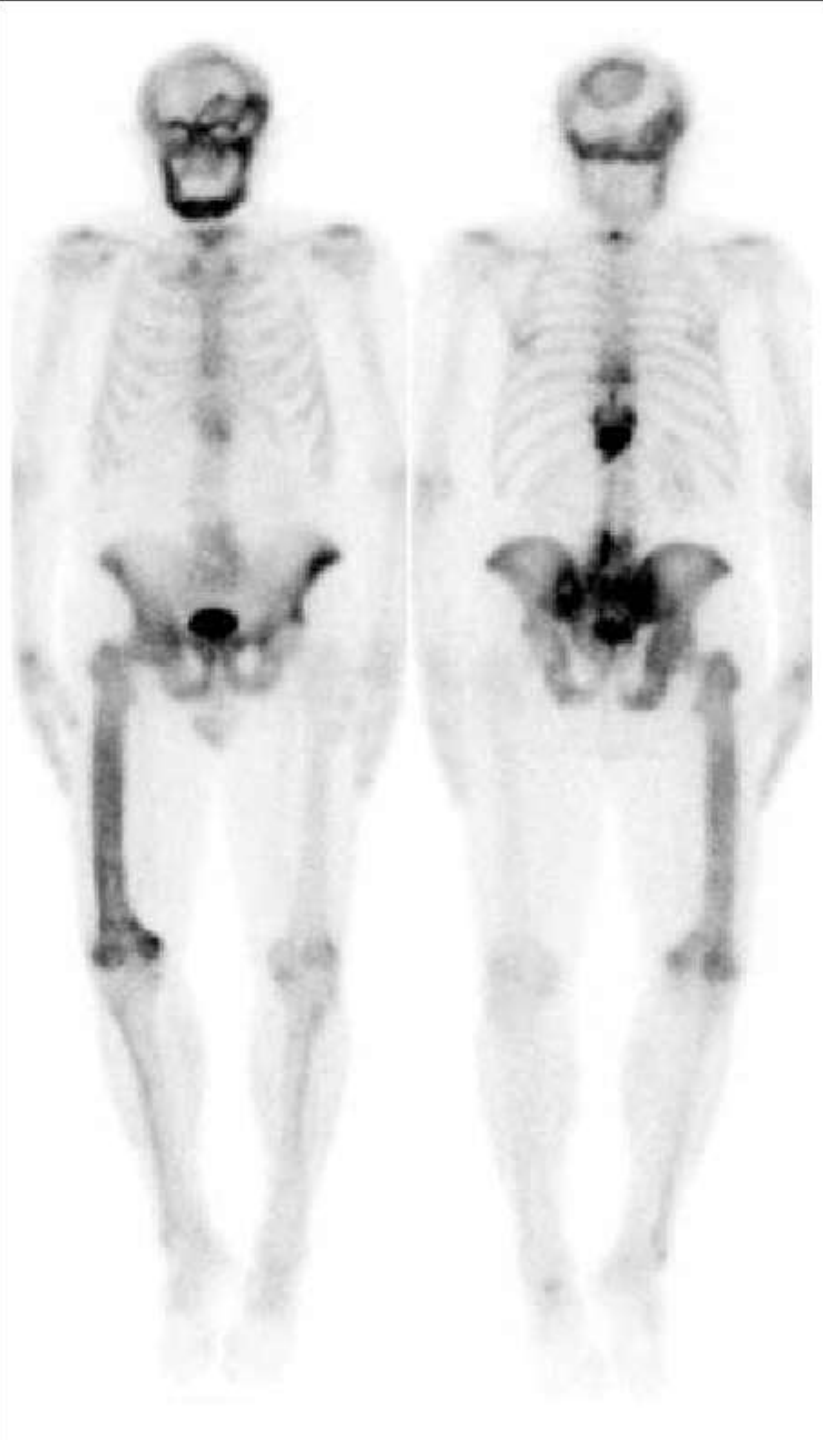
79 kVp
2.09 mA

3



TECHNICAL PEARLS

- JAMSHEEDI
 - ALL THROUGH SAME INCISION
 - AVOID N/V STRUCTURES
- PITUITARY
- KERRISON RONGEUR
- IM NAIL TYPICALLY PREFERRED OVER PLATING
- CERCLAGE USUALLY DISCOURAGED
- STONE GRASPER



PAGET'S DISEASE

- SUBTROCH MOST COMMON, MID SHAFT SECOND MOST
- BONE CAN BE SOFT HYPERDENSE
- NON-UNION CAN BE HIGH; UP TO 40%
- BONE DEFORMITY = FIXATION DIFFICULTY
 - IM NAIL, PLATING, X-FIX, ILIZAROV FRAME

BIBLIOGRAPHY

- DOVE, J. O. H. N. (1980). COMPLETE FRACTURES OF THE FEMUR IN PAGET'S DISEASE OF BONE. THE JOURNAL OF BONE AND JOINT SURGERY. BRITISH VOLUME, 62(1), 12-17.
 - NONUNION RATE 40%. LOCATION OF FXS
- BINDON, B., ADAMS, W., BALASUBRAMANIAN, N., SANDHU, J., & CAMACHO, P. (2018). OSTEOPOROTIC FRACTURES DURING BISPHOSPHONATE DRUG HOLIDAY. *ENDOCRINE PRACTICE*, 24(2), 163-169. BINDON, B., ADAMS, W., BALASUBRAMANIAN, N., SANDHU, J., & CAMACHO, P. (2018). OSTEOPOROTIC FRACTURES DURING BISPHOSPHONATE DRUG HOLIDAY. *ENDOCRINE PRACTICE*, 24(2), 163-169.
 - PEAK INCIDENCE FX HOLIDAY IS YR 4-5.
- ETTINGER, B., MARTIN, S. J., CRANS, G., & PAVO, I. (2004). DIFFERENTIAL EFFECTS OF TERIPARATIDE ON BMD AFTER TREATMENT WITH RALOXIFENE OR ALENDRONATE. *JOURNAL OF BONE AND MINERAL RESEARCH*, 19(5), 745-751. TERIPARATIDE (FORTEO) CONSIDERATION POSTOPERATIVE, IMPROVES BONE TURNOVER MARKERS

