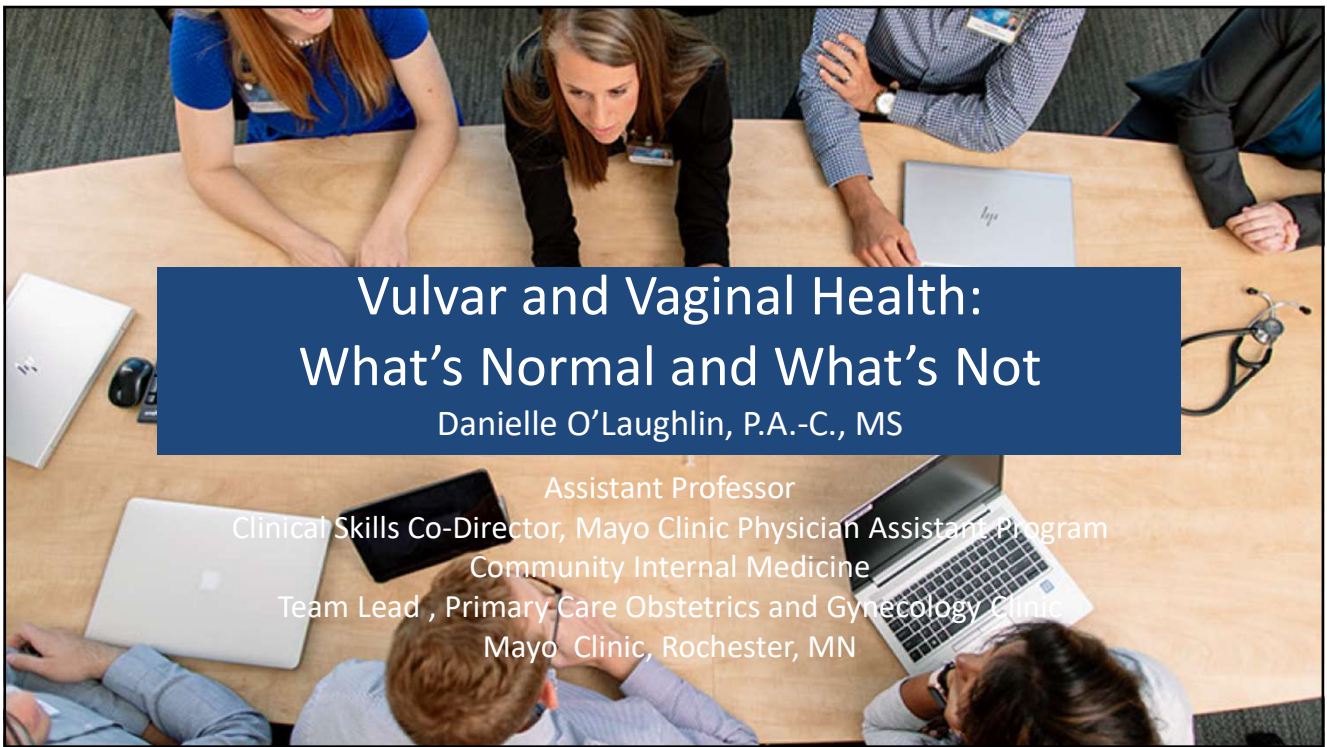

Vulvar and Vaginal Health: What's Normal and What's Not

Danielle O’Laughlin, P.A.-C., MS

Assistant Professor
Clinical Skills Co-Director, Mayo Clinic Physician Assistant Program
Community Internal Medicine
Team Lead , Primary Care Obstetrics and Gynecology Clinic
Mayo Clinic, Rochester, MN

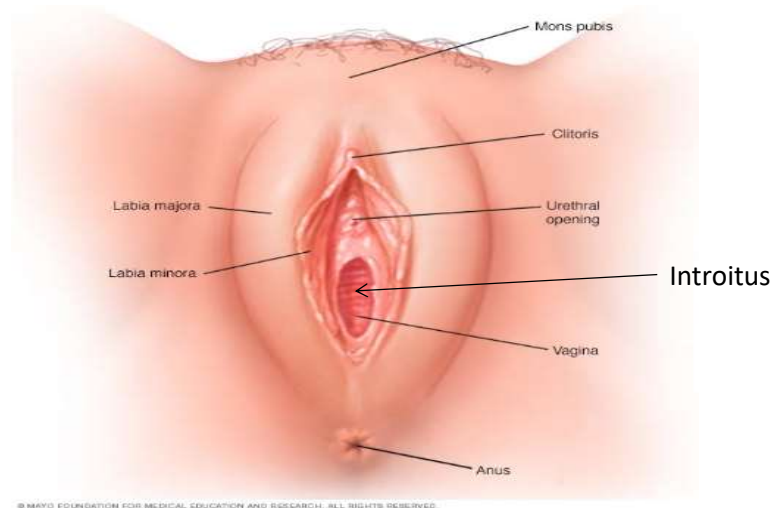
- No Disclosures

Objectives

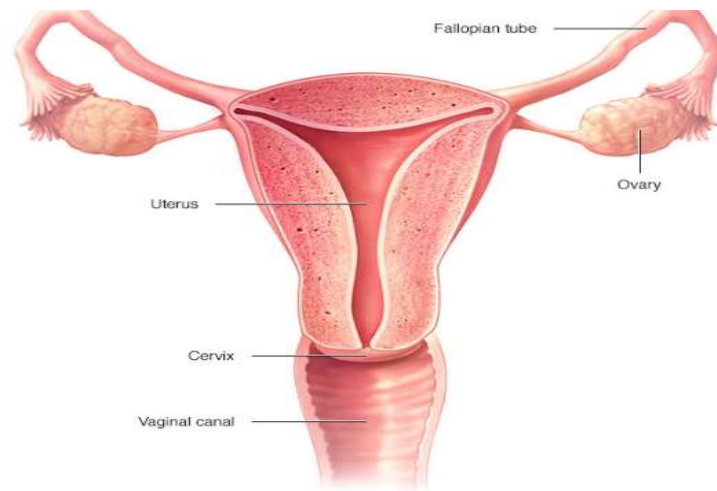
At the end of this presentation, members will be able to:

- Describe normal vulvar and vaginal anatomy and symptoms
- Summarize recommendations for vulvar and vaginal health
- Compare and contrast various pathologic conditions of the vulva and vagina
- Explain the etiology and risks factors of vulvar and vaginal conditions
- Summarize the symptoms, physical exam findings, diagnosis and treatment of vulvar and vaginal conditions
- Apply evidence-based medicine to case-based learning scenarios

Anatomy of the Vulva

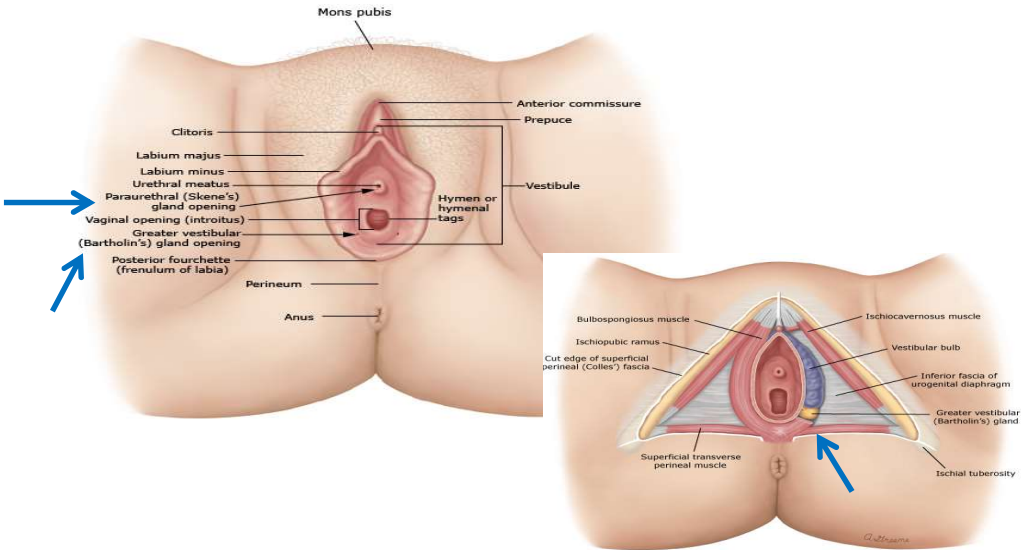


Anatomy of the Vagina

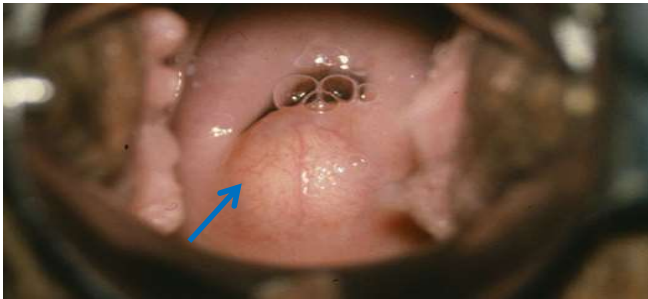


© MAYO FOUNDATION FOR MEDICAL EDUCATION AND RESEARCH. ALL RIGHTS RESERVED.

Glands of the Vulva and Vagina



Cysts/Polyps of the Cervix/Endocervix



Nabothian cyst



Endocervical polyp

Vulvar and Vaginal Symptoms

- *Lactobacillus* predominant
- Normal vaginal pH is 3.5-4.5
- Normal discharge:
 - Physiologic
 - Average woman has 2-3 Tbsp/day
 - Transparent to white, thick, odorless
 - Hormonal
 - Spinnbarkeit near ovulation
 - Increased volume, thicker
 - Stringy, stretchy, whitened
 - Contraception
 - Menopause



Vulvar and Vaginal Symptoms

- Abnormal discharge:
 - Change in color, odor or amount
 - Vulvar/vaginal redness or itching
 - Bleeding between periods, after intercourse or menopause
 - Mass or bulge
 - Pain with intercourse

Vulvar and Vaginal Care

- Wash with warm water ONLY
 - NO SOAP
- Use mineral oil or Vaseline if itching
- Use non irritating lubricants
- Avoid shaving and douching
- Wear wide, white, cotton underwear
 - Wash in very hot water
 - Use ½ laundry soap, double rinse, do NOT hand wash
 - Avoid thong underwear
 - Sleep without underwear, wear loose clothing
- Avoid sex for 1+ week if symptoms of pain/infection

Vulvar and Vaginal Care

- Avoid irritants/allergens:
 - Soaps
 - Pads/tampons
 - Shaving
 - Oral sex
 - Spermicides
 - Lubricants
 - Underwear
 - Sprays
 - Dyes/fragrances
 - Soap in underwear
 - Softeners/bleaches
 - Bubble baths
 - Shampoo
 - Hot tubs/chlorine
 - OTCs, scripts
 - Over cleansing

Vulvar and Vaginal Care

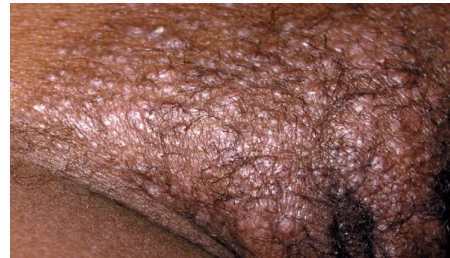- Be sexually responsible
- Get vaccinated
 - HPV and Hep B
- Do Kegel exercises
- Know you medications
- Limit alcohol and avoid tobacco
 - Decreases sexual function/arousal

Case 1

- A 47 y/o G0P0 sexually active female presents with 1 week of “bumps.” She describes intermittent itching/irritation.
- PMH: Major depression, recurrent, mild; exercise-induced asthma; eczema; Chlamydia treated X1
- Medications: sertraline, levonorgestrel IUC, prn albuterol
- Vital signs: WNL

Case 1

- On exam you see the following, what is your diagnosis?
 - A. Condyloma acuminata (warts)
 - B. Genital herpes
 - C. Molluscum contagiosum
 - D. Lichen simplex chronicus
 - E. Lichen planus
 - F. Folliculitis
 - G. Vulvar intraepithelial neoplasia (VIN)
 - H. Paget's disease



Let's discuss further...

Vulvar Conditions

- Condyloma acuminata (warts)
- Genital herpes
- Molluscum contagiosum
- Candidiasis
- Lichen: sclerosis, simplex chronicus, planus

Condyloma acuminata (warts)

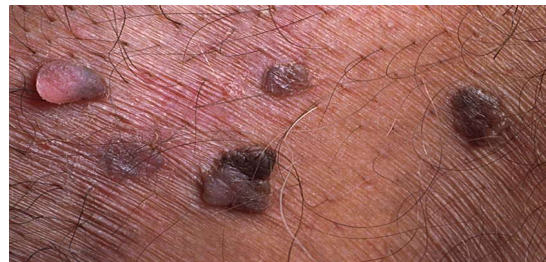- Caused by HPV
 - HPV types:
 - High risk: 16, 18, 31, 33 and 35
 - Low risk: **6 and 11** (most common cause)
 - 40+ strains that affect the genital area
- Risk factors:
 - Sexual activity
 - Cesarean transmission to baby
 - Rapid growth in pregnancy and immunosuppression
 - Smoking

Condyloma acuminata

- Transmission:
 - Direct contact
 - Autoinoculation
 - Fomite transfer
- Incubation months to years
- Symptoms:
 - Asymptomatic
 - Itching
 - Bleeding
 - Dyspareunia

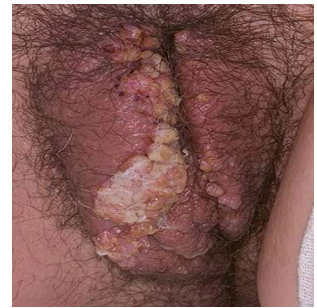Condyloma acuminata

- Physical exam:
 - Solitary or clusters
 - Flesh-colored, pink, salmon red, white, gray or various shades of brown
 - Lesions 1-5 mm
 - Lesion types:
 - 1) Acuminate
 - 2) Papular
 - 3) Flat



Condyloma acuminata

- **Diagnosis:**
 - Clinical assessment
 - Biopsy if concern for pre-cancer/cancer
 - Dermoscopy
- **Prevention:**
 - Condom use
 - Offer STI screening
 - Partner notification
 - 9-valent HPV vaccine protects against HPV types 6, 11, 16, 18, 31, 33, 45, 52 and 58
 - Follow Pap smear guidelines



Condyloma acuminata

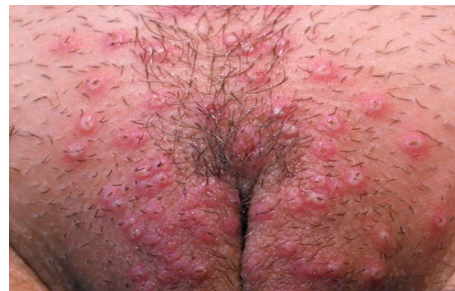- Home Treatment:
 - Podophyllotoxin (0.15% cream or 0.5% solution) bid for 3 days, followed by 5 rest days for 3-6 weeks
 - Contraindicated in pregnancy
 - Avoid sexual activity during treatment
 - Imiquimod (5% cream) 3 times a week at hs and wash with water in the morning until clearance for up to 16 weeks
 - Other options: Sinecatechins (10% ointment); 5-fluorouracil (5% cream); Cidofovir (1% gel), retinoids, sodium nitrite 6% with citric acid 9%

Condyloma acuminata

- Outpatient Treatment:
 - Cryotherapy: 2 freeze-thaw cycles, can be performed in weekly intervals
 - Trichloroacetic acid (80-90% solution) – weekly application
 - Safe in pregnancy
 - Sodium bicarbonate can be used in case of accidental excessive application
 - Other options: Bleomycin injected into warts, electrosurgery/scissors excision/curettage/YAG or carbon dioxide laser, formal surgery, intralesional or systemic interferon, photodynamic therapy with 5-aminolevulinic acid (ALA)

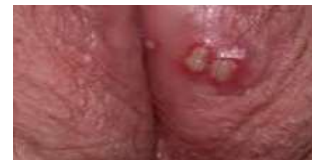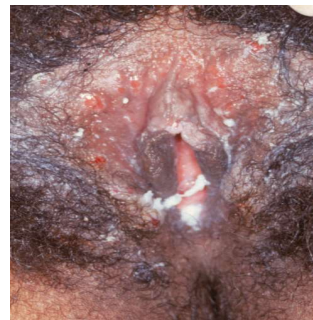Genital Herpes

- Caused by herpes simplex virus (HSV)
 - HSV-1
 - HSV-2 (most cases)
- Risk factors:
 - Sexual activity



Genital Herpes

- Symptoms and physical exam:
 - Asymptomatic
 - Genital ulcers
 - Headache
 - Dysuria
 - Fever
 - Lymphadenopathy
- Diagnosis:
 - PCR test for lesions
 - Serology for non lesions (HSV1 and HSV2)

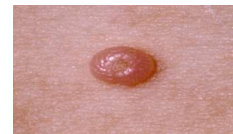
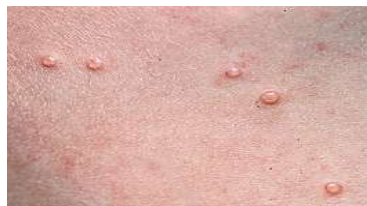
Genital Herpes

- Treatment:
 - **Acyclovir** 400 mg po tid for 7–10 days
 - **Acyclovir** 200 mg po 5X a day for 7–10 days
 - **Famciclovir** 250 mg po tid for 7–10 days
 - **Valacyclovir** 1 g po bid for 7–10 days
- Treatment can be extended if healing is incomplete after 10 days

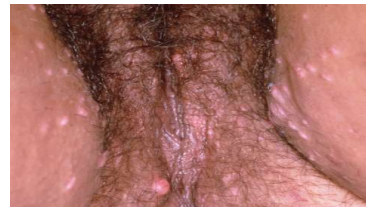Molluscum contagiosum

- Caused by a DNA poxvirus
- Risk factors:
 - Skin to skin contact, autoinoculation, sexual transmission, swimming pools via fomites
 - Consider immunodeficiency (HIV) with widespread disease (5-18%)



Molluscum contagiosum

- Symptoms:
 - Asymptomatic
 - Surrounding irritation or itching
- Physical exam:
 - Smooth, firm papules with a central umbilication
 - Most common on the mons pubis, genitalia, perineum, inner thigh, lower abdomen
 - Papules may persist for months up to 2 years



Molluscum contagiosum

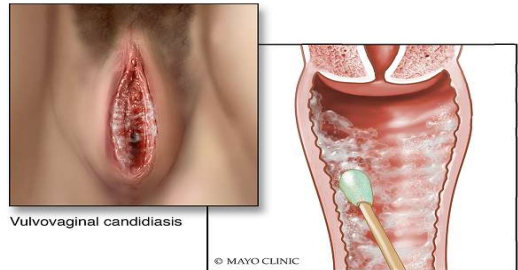
- Diagnosis:
 - Clinical
 - Freezing with liquid nitrogen increases visibility of umbilication
 - Light microscopy of an extracted central core can confirm molluscum bodies/Henderson-Paterson bodies
 - Wright's stain or methylene blue
 - Skin biopsy

Molluscum contagiosum

- Treatment:
 - Self-limited in immunocompetent
 - Avoid communal bathing/sharing towels
 - Avoid shaving (can cause autoinoculation)
 - Consider screening for other STDs
 - First-line Therapies:
 - Cryotherapy applied for 6-10 seconds
 - Curettage
 - Podophyllotoxin 0.5%
 - BID for 3 consecutive days per week; continued for up to 4 weeks
 - Other therapies: Imiquimod, potassium hydroxide, salicylic acid, topical retinoids, Cantharidin (generally not used on the genitals)

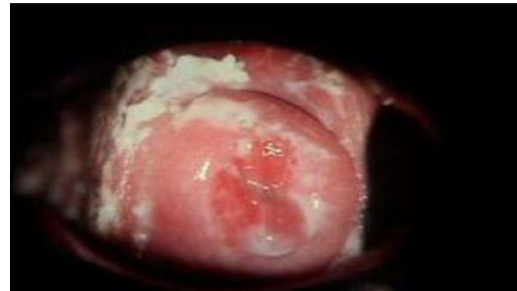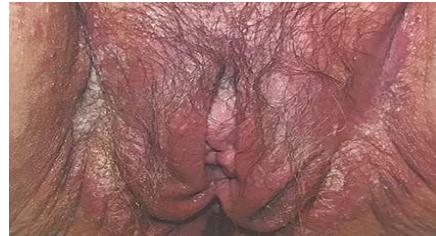Candidiasis vaginitis

- Caused by a fungus (most common *Candida albicans*)
 - Can affect vulva and vagina
- Risk factors:
 - Change in vaginal pH
 - OCPs
 - Pregnancy
 - DM
 - Antibiotics
- Common during the reproductive years
 - 50% will have 2+ infections



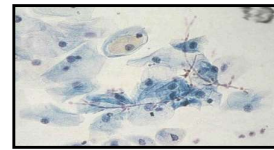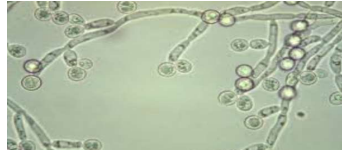Candidiasis vaginitis

- **Symptoms:**
 - Thin to thick white discharge
 - Itching
 - Irritation
 - Soreness
 - Burning
 - External dysuria
 - Dyspareunia
- **Physical exam:**
 - Vulvar redness
 - Swelling of labia
 - Excoriations of vulva
 - Fissures
 - White discharge



Candidiasis vaginitis

- Diagnosis:
 - Vaginal pH <4.5
 - Positive spores and hyphae on KOH prep (shish-kabob look; spores singly or in clusters)
 - Positive candida culture
 - *Candida albicans*, *glabrata* or *parapsilosis*



Candidiasis vaginitis

- OTC treatment:
 - Butoconazole 2% cream 5 g intravaginally for 3 days
 - Clotrimazole 1% cream 5 g intravaginally for 7–14 day OR 2% for 3 days
 - Miconazole 2% cream 5 g intravaginally for 7 days OR 4% for 3 days
 - Miconazole 100 mg vaginal suppository, one suppository for 7 days OR 200 mg for 3 days OR 1,200 mg for 1 day
 - Tioconazole 6.5% ointment 5 g intravaginally in a single application

Candidiasis vaginitis

- Prescription treatment:
 - Butoconazole 2% cream (single dose bioadhesive product) 5 g intravaginally for 1 day
 - Nystatin 100,000-unit vaginal tab, one tab for 14 days
 - Terconazole 0.4% cream 5 g intravaginally for 7 days
Or 0.8% for 3 days
 - Terconazole 80 mg vaginal suppository, one suppository for 3 days
 - Fluconazole 150 mg po tablet, one tab in single dose

Candidiasis vaginitis

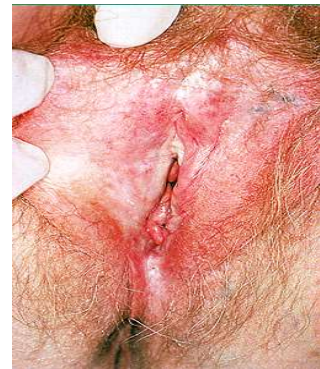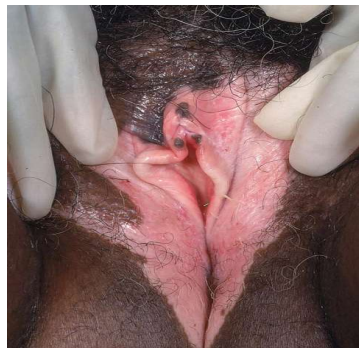- Treatment considerations:
 - Pregnancy
 - 7 day topical agent
 - Compromised host
 - 7-14 day topical therapy
 - Partner treatment not recommended

Lichen sclerosis

- Caused by a chronic inflammatory disorder; most likely auto-immune
 - Affects 1 in 70
 - Peak onset: postmenopausal (avg age at dx 51)
 - Pre-pubertal (15%)
- Risk factors: other auto-immune disorders (thyroid, alopecia areata, vitiligo, pernicious anemia, DM, SLE, lichen planus), genetic, hormonal
- 2-6% chance of developing squamous cell carcinoma of the vulva (may co-exist with VIN)

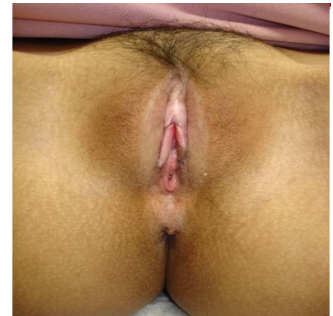Lichen sclerosis

- Symptoms:
 - Asymptomatic
 - Itching
 - Pain
 - Dyspareunia



Lichen sclerosus

- Physical exam:
 - Whitened, thin areas of skin
 - Hemorrhage
 - Scarring (narrowing of the vaginal opening, destruction of the labia minora, clitoris scarred over -phimosis)
 - NO vaginal involvement
- Diagnosis:
 - Vulvar biopsy

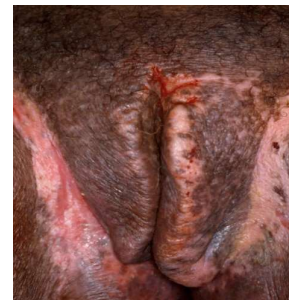
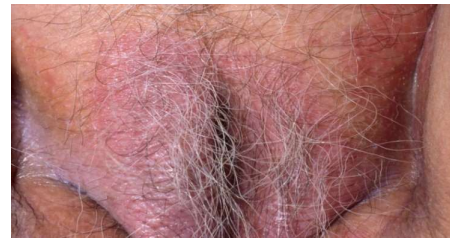
Lichen sclerosis

- Treatment:
 - Clobetasol propionate 0.05% ointment applied qd until active disease has resolved
 - After improvement decrease to 1-3/week
 - Topical estrogen
 - Follow up in 2-3 months
 - Biopsy non-healing ulcerations

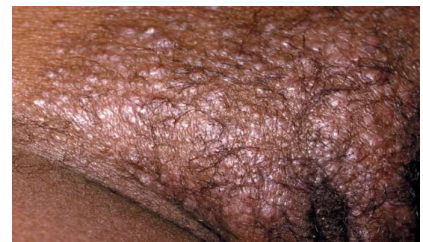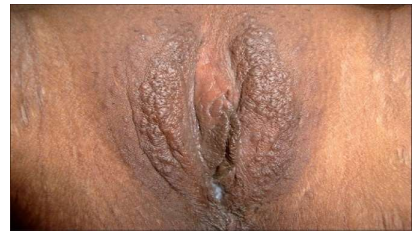Lichen simplex chronicus (LSC) (squamous cell hyperplasia)

- Caused by chronic rubbing/scratching results in thickened skin
- Most common in middle aged to elderly
- Risk factors:
 - Atopic dermatitis
 - Other pruritic skin conditions
 - Psychologic factor



Lichen simplex chronicus

- Symptoms and physical exam:
 - Leathery, scaly plaques of lichenified skin
 - Normal skin markings are exaggerated
 - Plaques may be erythematous or hyper/hypopigmented
 - Co-existing papules (prurigo nodularis)
- Diagnosis:
 - Clinical (areas that can be reached)
 - Skin biopsy



Lichen simplex chronicus

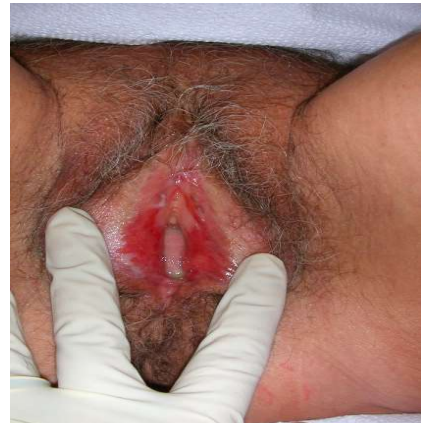- Treatment:
 - Break the itch-scratch cycle
 - Antihistamines, skin lubricants, emollients, barriers
 - Rule out other causes of itching
 - Psychological evaluation/treatment
 - High-potency/superpotent topical steroid applied bid with or without occlusion
 - Clobetasol 0.05% cream
 - Betamethasone 0.05% cream
 - Consider flurandrenolide tape (corticosteroid impregnated tape) - reminder to not scratch

Lichen Planus

- Caused by an inflammatory, autoimmune disorder of the skin/mucous membranes
 - Affects postmenopausal (1%)
 - Typically involves mouth/oral mucosa
 - 25% with vulvovaginal involvement
- Risk factors:
 - Idiopathic
 - Drug-related

Lichen Planus

- Symptoms:
 - Itching
 - Burning pain
 - Bleeding after intercourse
 - Copious yellow discharge
 - Destruction of the vulvovaginal architecture



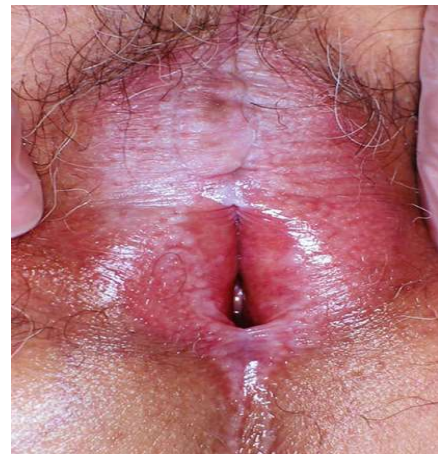Lichen Planus

Physical exam:

- Glassy, bright red erosions and ulceration of the vulva/vagina
- White striae or border (Wickham's striae)
- Papulosquamous or hypertrophic lesions
- Scarring of the vulva
- Obliteration of the vagina (in severe cases)
- Easy tearing and bleeding

Diagnosis:

Biopsy

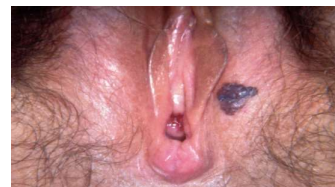
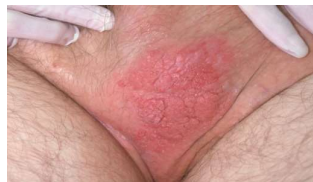
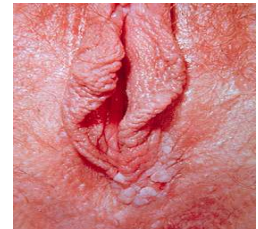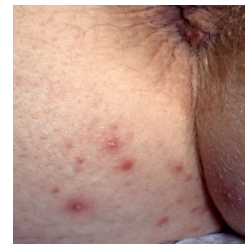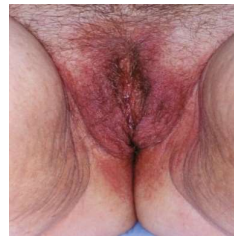Lichen Planus

- Treatment:
 - Fluocinonide 0.05% or clobetasol propionate 0.05% qd
 - Intravaginal hydrocortisone suppositories
 - Corticosteroid ointment applied to a vaginal dilator and inserted into the vagina
 - Other therapies: UV light, oral corticosteroids, tacrolimus, pimecrolimus, topical cyclosporine
 - Referral to dermatology

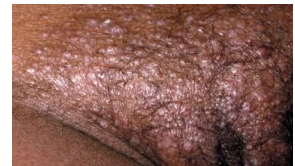Other Vulvar Conditions

- Folliculitis
- Contact dermatitis
- Vulvar intraepithelial neoplasia (VIN)
- Melanoma
- Paget's disease



Back to Case 1...

- Patient clues:
 - PMH of eczema and major depression
 - Middle aged
 - PE with thickened lichenified plaques with exaggerated skin markings and co-existing papules (prurigo nodularis)
- Diagnostic biopsy shows...



Lichen Simplex Chronicus

Treatment and patient education:

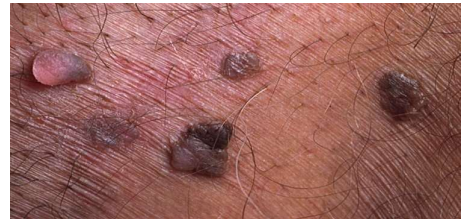- Antihistamine
- Skin lubricants/emollients
- Pyschologic re-evaluation
- High-potency/superpotent topical steroid cream
 - Flurandrenolide tape
 - Do NOT scratch

Case 2

- A 27 y/o G0P0 sexually active female presents with 2 weeks of “bumps.” She describes intermittent itching/irritation.
- PMH: abnormal pap 3 months prior showed normal cytology but was positive for HPV 6 and 11; colposcopy performed and unremarkable
- SH: + tobacco, smokes ½ ppd
- Medications: multivitamin, subdermal contraceptive implant
- Vital signs: WNL

Case 2

- On exam you see the following, what is your diagnosis?
 - A. Condyloma acuminata (warts)
 - B. Genital herpes
 - C. Molluscum contagiosum
 - D. Lichen simplex chronicus
 - E. Lichen planus
 - F. Folliculitis
 - G. Vulvar intraepithelial neoplasia (VIN)
 - H. Paget's disease



Case 2

Condyloma acuminata (warts)

Treatment and patient education:

- Trichloroacetic acid (80-90% solution) – weekly application
 - Offer STI screening
 - Partner notification
 - Condom use
 - Consider HPV vaccine
- Follow-up Pap smear (per guidelines)

Case 3

- A 36 y/o G1P1 sexually active female postpartum week 8, breastfeeding on OCPs presents with 2 weeks of “vaginal discharge.” She describes intermittent itching/irritation and dyspareunia.
- PMH: Celiac disease
- Medications: prenatal vitamin, norgestimate/ethinyl estradiol
- Vital signs: WNL

Case 3

- What is your diagnosis?
 - A. Genitourinary syndrome of menopause
 - B. Bacterial vaginitis
 - C. Candidiasis vaginitis
 - D. Trichomoniasis vaginitis
 - E. Desquamative inflammatory vaginitis
 - F. Other STI

Let's discuss further...

Vaginal Conditions

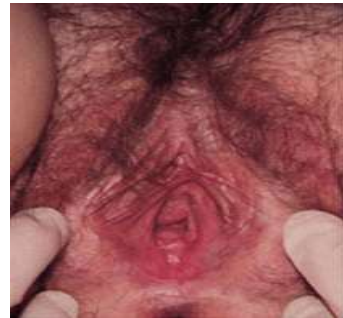- Genitourinary syndrome of menopause
- Bacterial Vaginitis
- Trichomoniasis Vaginitis
- Desquamative inflammatory vaginitis

Genitourinary syndrome of menopause (atrophic vaginitis/vaginal atrophy)

- Caused by a low estrogen state
 - Vaginal pH rises
- Risk factors:
 - Menopause (affects 50+%; only 25% seek treatment)
 - Primary ovarian insufficiency
 - Chemotherapy
 - Pelvic irradiation
 - Hypothalamic amenorrhea
 - Hyperprolactinemia
 - Lactation
 - Medications (OCP, aromatase inhibitors, tamoxifen, gonadotropin-releasing hormone agonists or antagonists)

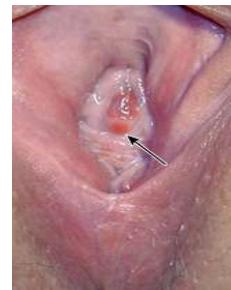Genitourinary syndrome of menopause

- Symptoms:
 - Dryness
 - Soreness/irritation
 - Itching
 - Thin, watery, yellow or gray discharge
 - Dyspareunia
 - Vulvodynia
 - Vaginal spotting
 - Urinary urgency and frequency
 - Incontinence
 - Recurrent UTI
 - Dysuria



Genitourinary syndrome of menopause

- Physical exam:
 - Labial thinning
 - Phimosis of the clitoral prepuce
 - Pale, dry vulva/vagina
 - Shortened or narrow vagina
 - Diminished vaginal rugae
 - Serosanguineous or watery discharge
 - Vulvovaginal erythema +/- bleeding (small punctate hemorrhages)
 - Atrophy of the cervix
 - Urethral caruncle (soft, smooth, bright red eversion of urethra)



Genitourinary syndrome of menopause

- Diagnosis:
 - Clinical
 - Vaginal pH 4.5 or greater
 - Wet prep (rule out infection)
 - Urinalysis (rule out infection)
 - Vulvar biopsy

Genitourinary syndrome of menopause

- Treatment:
 - Moisturizers
 - Water-based products available as liquids or gels
 - Used qd or every few days for maintenance
 - Oil-based lubricants may degrade condoms
 - Lubricants
 - Water-based or silicone-based products
 - Silicone based lubricants last longer but can impair erections
 - Silicone-based lubricants should not be used with silicone-coated sex aids
 - Used for comfort with sexual activity
 - Topical lidocaine ointment/gel to relieve insertional pain
 - Applied to the introitus 5-10 mins before sexual activity

Genitourinary syndrome of menopause

- Treatment continued:
 - For moisturizers/lubricants:
 - Apply to the intoitus and/or partner at time of sexual activity
 - Repeat during sexual activity as needed
 - If irritation/burning/stinging switch products
 - Avoid products with warming properties (contain capsaicin), flavors and known irritants such as glycerin, parabens and propylene glycol
 - Can be used with hormones

Genitourinary syndrome of menopause

- Treatment continued:
 - Hormones (creams, tablets, rings, patches, orals):
 - Discuss risks/benefits, age, length of treatment, type of hormone
 - Risks:
 - Combined therapy 5+ yrs is associated with increased risk of breast cancer
 - DVT risk
 - Ischemic stroke (not hemorrhagic)
 - Decreased sex drive (possible lower free testosterone)
 - Cognition (data mixed)
 - Benefits: (oral/transdermal)
 - Treatment of hot flashes
 - Reduces mood instability/concentration difficulties, improves quality of life
 - Slows development of atherosclerosis
 - Reduces bone loss/fracture risk
 - Associated with reduced risk of DM2

Genitourinary syndrome of menopause

- Types of estrogen (oral/transdermal):
 - Conjugated equine estrogen
 - Synthetic conjugated estrogen A and B
 - Ethinyl estradiol preparation: norethindrone acetate/ethinyl estradiol
 - 17 beta estradiol: estradiol
 - Bioidentical estrogens

Genitourinary syndrome of menopause

- Types of estrogen (topical):
 - Estradiol 0.01% vaginal cream 2-4 g/day for 1-2 weeks, then 1 g 1-3 times/week
 - Conjugated estrogen (0.625mg/g) cream 0.5g 2 times/week
 - Estradiol (0.010 mg) tab/d x 2 wk, then 2 times/week
 - Estradiol ring (2mg) every 3 months

Genitourinary syndrome of menopause

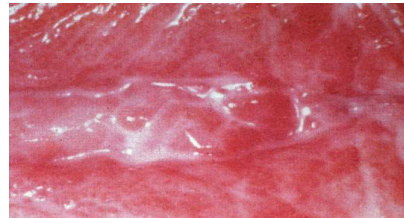
- Types of progesterone (oral):
 - Micronized progesterone
 - Synthetic progestin
 - Medroxyprogesterone acetate [MPA]
 - Norethindrone
- Avoid transdermal - unpredictable absorption
- Levonorgestrel IUC (off-label)

Genitourinary syndrome of menopause

- How long?:
 - Shortest interval
 - Lowest dose for symptom management
 - Normal menopause
 - Limit to 3-5 years
 - Surgical menopause
 - Until age of menopause

Bacterial Vaginitis (BV)
(Gardnerella or Hemophilis vaginalis)

- Caused by a change of vaginal flora; reduction of lactobacilli and increase of coccobacilli and other organisms
 - Rise of pH > 4.5
- Most common cause of abnormal discharge
- Incidence (age 14-49):
 - 29% of women
 - 50% African American



Bacterial Vaginitis

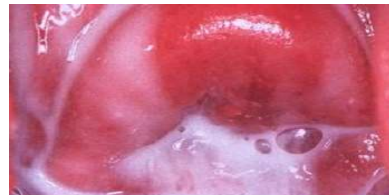- Common organisms:
 - Gardnerella vaginalis
 - Prevotella species
 - Porphyromonas species
 - Bacteroides species
 - Peptostreptococcus species
 - Mycoplasma hominis
 - Ureaplasma urealyticum
 - Mobiluncus species

Bacterial Vaginitis

- Risk factors:
 - Multiple or new sex partners
 - Douching
 - Cigarette smoking
 - Poverty

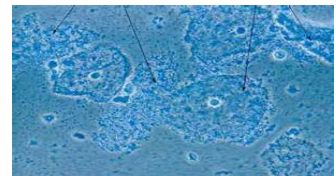
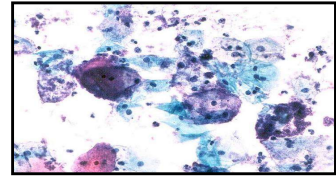
Bacterial Vaginitis

- Symptoms and physical exam:
 - Fishy odor, especially after intercourse
 - Thin, off-white discharge
 - Rare: dysuria, dyspareunia, pruritus, erythema, vaginal inflammation



Bacterial Vaginosis

- **Diagnosis:**
 - Gram Stain (Nugent score)—gold standard
 - Amsel Criteria: must have 3 out of 4
 - Thin, off-white discharge
 - pH greater than 4.5
 - Positive whiff test (10% KOH added to discharge)
 - Clue cells (cocci/bacilli on the surface of epithelial cells) on saline wet mount
- **Tests NOT to be used: vaginal culture, Pap smear**



Bacterial Vaginosis

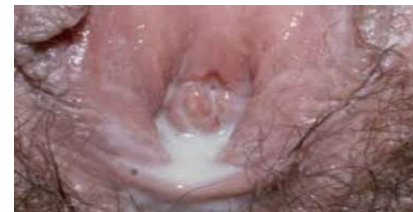- Infection consequences:
 - Higher risks of:
 - STIs (HSV-2, HPV, HIV, gonorrhea, chlamydia, trichomonas)
 - PID and infertility
 - Cervicitis and endometritis
 - Cystitis
 - Post-gyn surgery and postpartum infections
 - Preterm delivery
 - CIN

Bacterial Vaginitis

- **Treatment:**
 - Metronidazole (oral or vaginal)
 - 500 mg po bid x 7 days OR 0.75% gel 5 gm qd x 5 days
 - Clindamycin cream 2%
 - 1 applicator (5g) vaginally hs x 7 days (oil based = avoid condoms up to 5 days after use)
 - Avoid alcohol on metronidazole
- **Treatment in pregnancy:**
 - Metronidazole 500 mg po bid x 7 days OR 250 mg po tid x 7 days
 - Clindamycin 300 mg po bid x 7 days

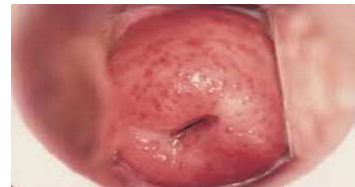Trichomoniasis Vaginitis

- Caused by a protozoan infection (Trichomoniasis vaginalis)
 - Vaginal pH >5.0
- Can cause preterm delivery
- Risk factors:
 - Sexual activity



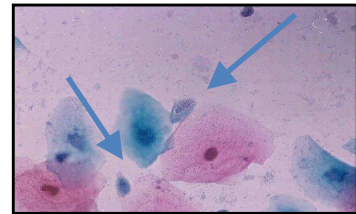
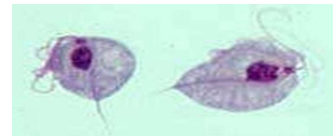
Trichomoniasis Vaginitis

- Symptoms and physical exam:
 - 70-85% asymptomatic
 - Discharge (odorous, frothy, clear-yellow-green)
 - Dyspareunia or lower abdominal pain
 - Bleeding after intercourse
 - Soreness (vulva/vagina)
 - Itching
 - Burning
 - External dysuria and frequency
 - Vaginal erythema
 - Vulvar dermatitis
 - Cervicovaginitis (strawberry cervix)



Trichomoniasis Vaginitis

- Diagnosis:
 - Saline microscopy
 - Pear-shaped with red granules and slit-like nucleus
 - Lack of chromatin structure of stripped nuclei
 - Vaginal pH >5.0
 - Rapid antigen and nucleic acid amplification test (NAAT)



Trichomoniasis Vaginitis

- Treatment:
 - Metronidazole 2 g po in a single dose
 - Tinidazole 2 g po in a single dose
- Avoid alcohol
- Abstinence of alcohol should continue for 24 hrs after metronidazole or 72 hrs after tinidazole

Desquamative Inflammatory Vaginitis (DIV)

- Cause unknown (possible bacterial overgrowth, vaginal atrophy, lichen planus variant)
 - Occurs in 8% with persistent vaginitis
- Risk factors:
 - Hypoestrogenic state (postpartum, breastfeeding, peri/postmenopause, OCPs)

Desquamative Inflammatory Vaginitis

- Symptoms and physical exam:
 - Copious discharge (yellow or brown)
 - Burning of vagina
 - Severe dyspareunia/postcoital bleeding
 - Severe introital/vaginal erythema
- Diagnosis:
 - White blood cells on saline microscopy
 - Vaginal cultures
 - Increased vaginal pH > 4.5

Desquamative Inflammatory Vaginitis

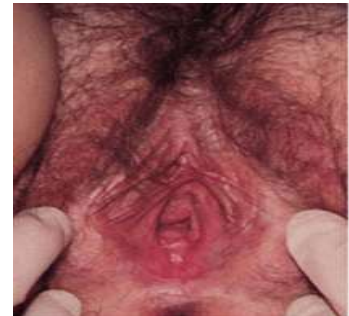- Treatment:
 - Clindamycin cream 2% vaginal cream 5 gm/d x 4 weeks OR
 - Hydrocortisone 10% vaginal cream, 3 gm/d x 4 weeks
 - Other hydrocortisone creams, rectal and vaginal suppositories can be used as alternatives
 - Estrogen to prevent reoccurrence

Other Vaginal Conditions

- STIs
 - Gonorrhea
 - Chlamydia
- Foreign body/retained tampon
- Cervicitis/endometritis
- PID

Back to Case 3...

- Patient clues:
 - Postpartum week 8 and breastfeeding
 - On OCP
 - PE with a pale, dry vulva, thinning of the vulvar skin and diminished vaginal rugae
- Vaginal pH is 5.5; wet prep is normal
- **Diagnostic biopsy shows...**



Genitourinary syndrome of menopause

Treatment and patient education:

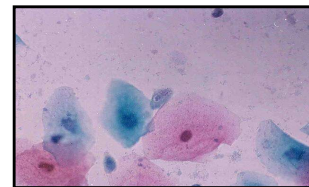
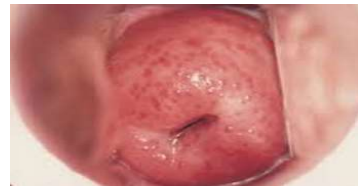- Moisturizers/lubricants
- Consider short term topical estrogen (no systemic symptoms)
 - Symptoms will likely improve with time
 - Re-evaluate

Case 4

- A 19 y/o G0P0 sexually active female presents with 1 week of “vaginal discharge.” She describes intermittent itching/irritation and dyspareunia. She describes discharge as odorous and yellow-green.
- PMH: ADD
- Medications: levonorgestrel IUC
- Vital signs: WNL

Case 4

- On exam you see, what is your diagnosis?
 - A. Genitourinary syndrome of menopause
 - B. Bacterial vaginitis
 - C. Candidiasis vaginitis
 - D. Trichomoniasis Vaginitis
 - E. Desquamative inflammatory vaginitis
 - F. Other STI



Trichomoniasis Vaginitis

Treatment and patient education:

- Metronidazole or Tinidazole
- Avoid alcohol (24 hrs after metronidazole or 72 hrs after tinidazole)

Summary

- Not all discharge is abnormal
- Obtain a thorough history
 - Ask about vulvovaginal symptoms
- Do the physical exam
- 1+ condition may be causing symptoms
- Recurrence is common, treatment and patient education is needed
- Discuss prevention and vulvar/vaginal care recommendations

	Normal	Bacterial Vaginosis	Yeast Vaginitis	Trichomoniasis
Frequency	20% mixed BV/yeast	29-50%+ (30% recurrence @ 1 mo)	25+% (50% lifetime recurrence)	2-5+%
Symptoms		Fishy odor, no itch	Itch , thick/cheesy discharge	
Vaginal signs, discharge	White, opaque pale	Watery, fishy , thin, milky white, malodor, NO inflammation	Clumpy, white , thick, discharge, vulvar inflammation	Frothy, gray or yellow-green, malodorous, bright cervical inflammation
KOH "whiff"	Negative	Positive	Negative	Often positive
Saline micro	Lactobacilli and epithelial cells	Clue cells , few WBC's 70-80% sensitive	Negative, few WBC's	Motile flagellated protozoa, many WBC's 70% sensitive
KOH micro	Negative	Negative	Pseudohyphae or budding yeast 70% sensitive	Negative
Vaginal pH	3.5-4.5	>4.5	Normal (usually <4.5)	>4.5-5
Culture / PCR	60% have Gardnerella spp., 40% have Candida spp.	Culture poor predictive value, often Gardnerella spp. PCR poor predictive value	Often Candida spp.	PCR test specific

References

- Allahna, E, Miguel, R.D.V., Cherpes, T.L, Klebanoff, M.A., Gallo, M.F., Turner, A.N. (2015). Risk of bacterial vaginosis among women with herpes simplex virus type 2 infection: A systemic review and meta-analysis. *The Journal of Infectious Diseases, J Infect Dis.* (2015) doi: 10.1093/infdis/jiv017.
- Allsworth, J. a. P., JF (2007). "Prevalence of bacterial vaginosis." *Obstetrics & Gynecology* 109(1): 114-120.
- Bodnar, L., Krohn, MA, and Simhan, HN (2009). "Maternal Vitamin d Deficiency is Associated with Bacterial Vaginosis in the First Trimester of Pregnancy." *The Journal of Nutrition* 139: 1157-1161.
- Burgin, S., Craft, N., Goldsmith, L. (2019). Lichen simplex chronicus. VisualDx. <https://www.visualdx.com/visualdx/diagnosis/lichen+simplex+chronicus?moduleId=101&diagnosisId=51861#top>
- Center for Disease Control and Prevention. (2010). Diseases characterized by vaginal discharge: Sexually transmitted diseases guidelines. <http://www.cdc.gov/std/treatment/2010/vaginal-discharge.htm>
- Centers for vulvovaginal disorders. <http://www.cvvd.org/>
- Cohen, J., Lin, W., Hocker, S., Tan, B., Burgin, S. (2019)1. VisualDx. <https://www.visualdx.com/visualdx/diagnosis/melanoma?moduleId=101&diagnosisId=51936#view=images>
- Cooper, S., Arnold, S. (2019). Vulvar lichen sclerosis. Up-To-Date. https://www.uptodate.com/contents/vulvar-lichen-sclerosis?search=lichen%20sclerosis&source=search_result&selectedTitle=1~57&usage_type=default&display_rank=1
- Crum, C., Nucci, M., Howitt B., Granter, S., Parast, M., Boyd T. Diagnostic Gynecologic and Obstetric Pathology. Philadelphia, PA: Elsevier; 2018. ISBN: 978-0-323-44732-4.
- Hill, G. (1993). "The microbiology of bacterial vaginosis." *The American Journal of Obstetrics and Gynecology* 169(2S): 450-454.
- Holschneider, C. 2019. Vulvar intraepithelial neoplasia. UpToDate. https://www.uptodate.com/contents/vulvar-intraepithelial-neoplasia?search=Vulvar%20intraepithelial%20neoplasia&source=search_result&selectedTitle=1~38&usage_type=default&display_rank=1
- Isaacs, S. Molluscum contagiosum. (2019). Up-To-Date. https://www.uptodate.com/contents/molluscum-contagiosum?search=molluscum%20contagiosum&source=search_result&selectedTitle=1~60&usage_type=default&display_rank=1#H5283428
- Kim, J., Willig, J., Goldsmith, L. (2019). Bacterial vaginosis. VisualDx. <https://www.visualdx.com/visualdx/diagnosis/bacterial+vaginosis?moduleId=101&diagnosisId=52763>
- Laufer, M. (2019). Benign cervical lesions and congenital anomalies of the cervix. UpToDate. https://www.uptodate.com/contents/benign-cervical-lesions-and-congenital-anomalies-of-the-cervix?search=nabothian%20cyst§ionRank=1&usage_type=default&anchor=H13&source=machineLearning&selectedTitle=1~4&display_rank=1#H14

References

- Lazenby, G., Thurman, A., Soper, D. (2019). Vulvar abscess. UpToDate. https://www.uptodate.com/contents/vulvar-abscess?search=skene%20gland%20cyst§ionRank=1&usage_type=default&anchor=H15317576&source=machineLearning&selectedTitle=1~150&display_rank=1#H15317576
- Nyirjesy, P. (2014). Management of persistent vaginitis. *Obstetrics & Gynecology* 124(6): 1135-1146.
- Mayo Clinic , Vagina: What's normal, what's not. <https://www.mayoclinic.org/healthy-lifestyle/womens-health/in-depth/vagina/art-20046562>
- Mayo Clinic. Genital warts. <https://www.mayoclinic.org/diseases-conditions/genital-warts/symptoms-causes/syc-20355234>
- Miller, M. (2014). Recurrent vulvovaginitis: Tips for treating a common condition. *Contemporaryobgyn.net*. 22-27.
- Reiter, S. (2013). Barriers to effective treatment of vaginal atrophy with local estrogen therapy. *International Journal of General Medicine*: 6, 153-158.
- Secor, R. (2011). *Vaginitis Update 2011: Prevention and Management of Chronic Recurrent Infections*. NPACE, New Orleans.
- Singh, G., Burgin, S. (2019). Extramammary Paget Disease. VisualDx. <https://www.visualdx.com/visualdx/diagnosis/extramammary+paget+disease?moduleId=101&diagnosisId=52100>
- Soba, B., Skvac, M., Maticic, M. (2015). Trichomoniasis: a brief review of diagnostic methods and our experience with real-time PCR for detecting infection. *Acta Dermatovenerologica*:24, 7-10.
- Sobel, J. (2019). Candida vulvovaginitis: Clinical manifestations and diagnosis. Up-To-Date. https://www.uptodate.com/contents/candida-vulvovaginitis-clinical-manifestations-and-diagnosis?search=Candidiasis%20vaginitis&source=search_result&selectedTitle=2~150&usage_type=default&display_rank=2
- Sood, R., Faubion, S.S., Kuhle, C.L., Thielen, J., Shuster, L.T. (2014). Prescribing menopausal hormone therapy; an evidenced-based approach. *International Journal of Women's Health*: 6, 47-57.
- Vedak, P., Burgin, S. (2019). Allergic contact dermatitis. <https://www.visualdx.com/visualdx/diagnosis/allergic+contact+dermatitis?moduleId=101&diagnosisId=51384#synopsis>
- Vedak, P., Burgin, S. (2019). Folliculitis. VisualDx. <https://www.visualdx.com/visualdx/diagnosis/folliculitis?moduleId=101&diagnosisId=51583#synopsis>
- Vedak, P., Burgin, S. (2018). Genital wart – Anogenital in Female Adult. *VisualDx*. https://www.visualdx.com/visualdx/diagnosis/genital+wart?moduleId=9&diagnosisId=52510&lang=en_US#view=text
- Workowski, K., Berman, S (2010). "Centers for Disease Control and Prevention (CDC). Sexually transmitted diseases treatment guidelines." *MMWR Recommendations and Reports* 59.
- Uphold, CR, Graham, MV. (2003). *Clinical Guidelines in Family Practice*. 714-716.

Questions

- Danielle O’Laughlin, P.A.-C., MS
 - Clinical Skills Co-Director, Mayo Clinic PA Program
 - Community Internal Medicine
 - Team Lead, Primary Care Obstetrics and Gynecology Clinic
 - Mayo Clinic, Rochester, MN
- Contact Information
 - olaughlin.danielle@mayo.edu

