



# My Tummy Hurts: Differentiating Pediatric Abdominal Pain Requiring a Surgical Consult

**Anna C. Shafer, MMSc, PA-C**  
Surgical Hospitalist,  
Texas Children's Hospital West Campus  
Instructor, Surgery and Pediatrics,  
Baylor College of Medicine

# Disclosures

- None

## Learning Objectives

- Identify key differences in the history of pediatric patients with abdominal pain.
- Identify physical exam findings pertaining to surgical etiologies of pediatric abdominal pain.
- Choose the appropriate diagnostic imaging and laboratory tests to aid in the diagnosis of pediatric abdominal pain.
- Recognize common causes of pediatric abdominal pain necessitating surgical treatment.

## Case 1

A 3-week-old breastfed female is brought to the pediatric urgent care by her dad with concerns of multiple episodes of spinach green emesis over the past 3 days. Dad states that prior to this she was in her usual state of good health.

Until proven otherwise, bilious emesis in the infant  
is....

- Malrotation and Volvulus

- Pyloric Stenosis
- Intussusception
- Appendicitis
- Testicular Torsion

## Malrotation

- Intestinal nonrotation or malrotation around the superior mesenteric artery
- Congenital abnormal rotation of the bowel – usually small and large – within the peritoneal cavity
- Failure of normal sequence of rotation and fixation in bowel

# Malrotation

- Normal intestinal rotation around the SMA
  - Between 5-10 weeks
    - Intestines herniate through umbilical cord
    - Duodenojejunal loop rotates 180 degrees counterclockwise
    - Cecocolic loop rotates 90 degrees counterclockwise
    - Wide base created for mesentery through midgut rotation

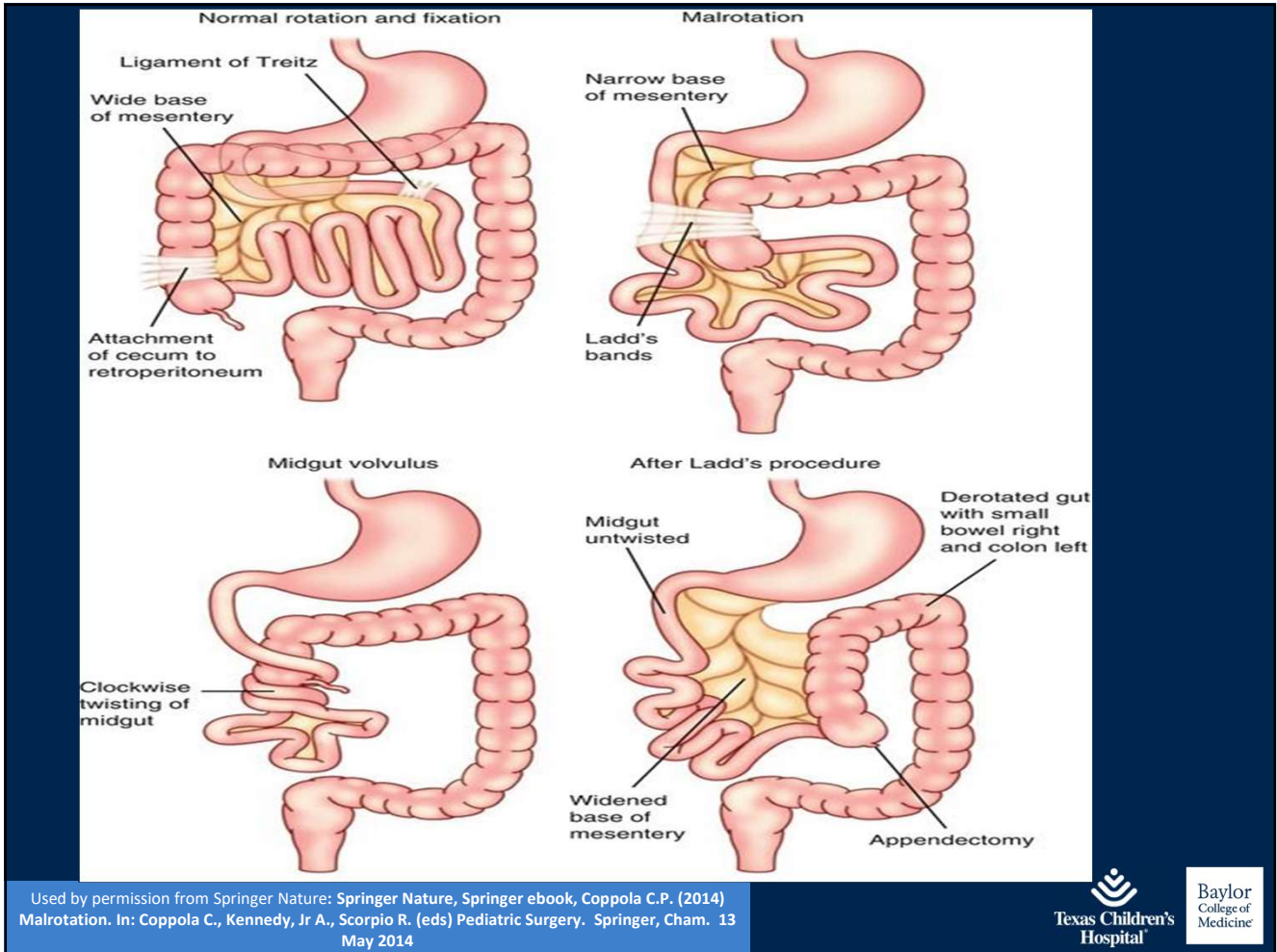


## Malrotation

- Normal intestinal rotation around the SMA
  - 10 weeks
    - Bowel returns to abdominal cavity
    - Duodenojejunal loop rotates and additional 90 degrees
    - Cecocolic loop turns 180 degrees more

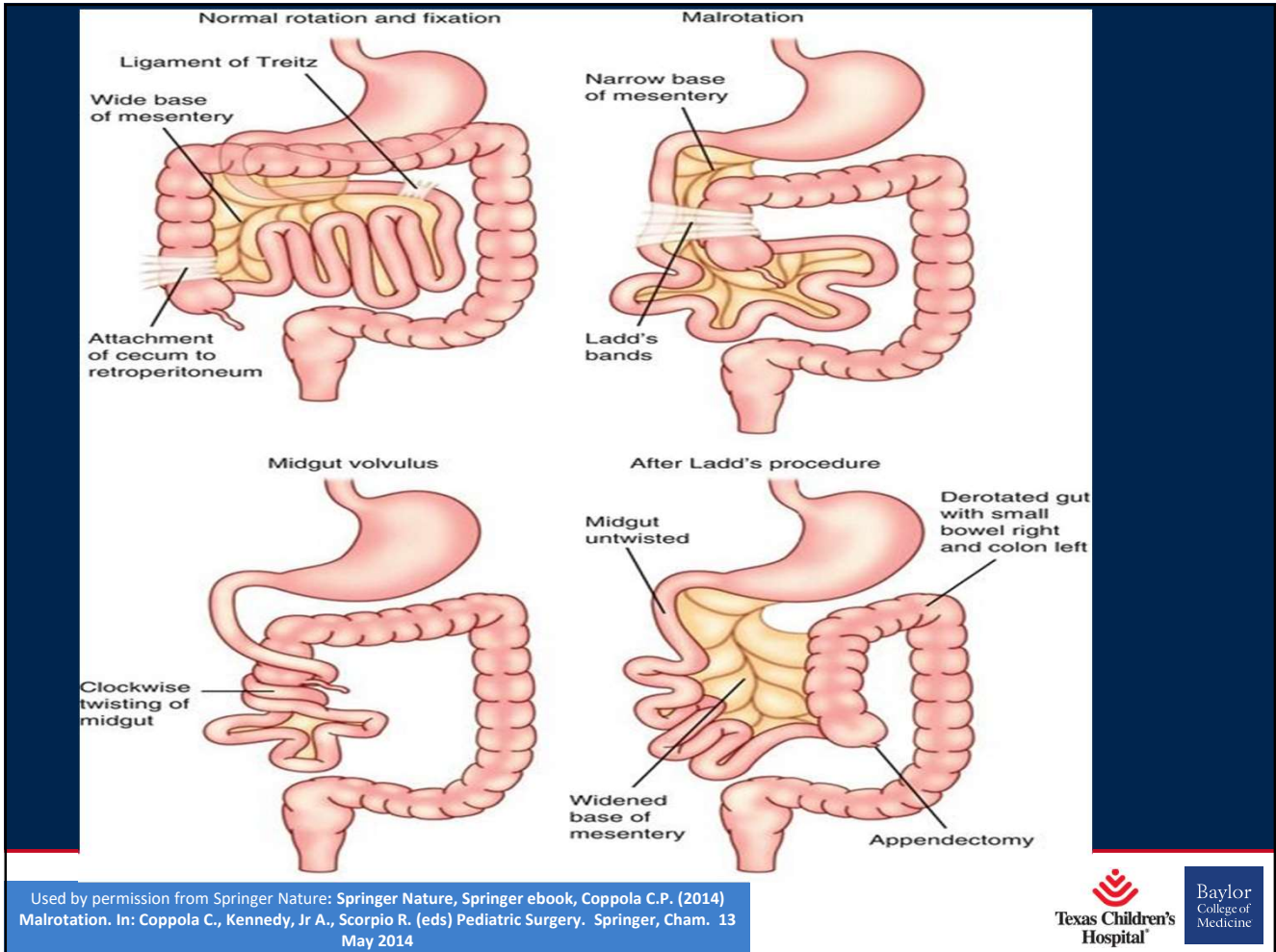
# Malrotation

- Nonrotation vs. incomplete rotation



## Malrotation and Volvulus / Obstruction

- Malrotation leads to a predisposition for volvulus / obstruction
- Compression from bands from cecum to lateral abdominal wall (Ladd's bands)
- Small bowel volvulus – secondary from a predisposition from a narrowed mesenteric base - can lead to ischemia of the midgut from SMA occlusion



## Prevalence & Presentation

- 1 in 500 live births
- Male to Female ratio 2:1
- Up to 40% present within the first week of life
- 50% of patients diagnosed by 1 month
- 75% present within the first year

# Risk Factor

- Heterotaxy Syndrome

## History

- Classic newborn presentation symptom:
- Bilious vomiting
- Other symptoms in newborn: pain, irritability, other nonspecific symptoms (anorexia, nausea, failure to thrive, change in stooling patterns)
- Late symptoms: rectal bleeding, signs / symptoms of shock, signs / symptoms of peritonitis



# History

- Classic newborn presentation symptom:
- Bilious vomiting
- Other symptoms in newborn: pain, irritability, other nonspecific symptoms (anorexia, nausea, failure to thrive, change in stooling patterns)

# History

- In older patient
- Less likely to have bilious vomiting
  - Recurrent episodes of unexplained abdominal pain, irritability, vomiting
  - Failure to thrive
  - Incidental finding

## Physical Exam

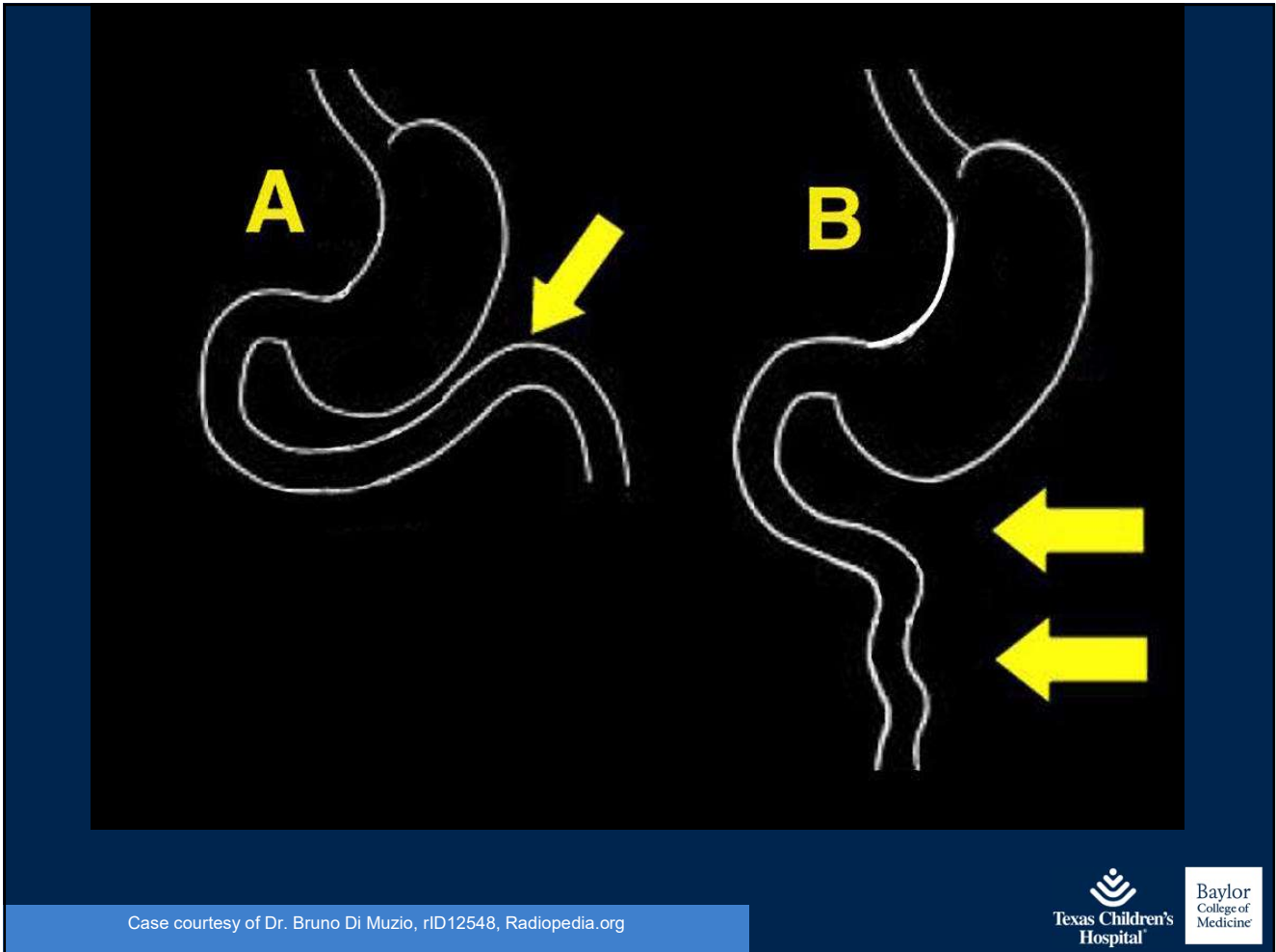
- +/- hemodynamic instability
- Hydration status – mucous membranes, fontanel
- +/- abdominal distension
- +/- abdominal tenderness
- +/- peritonitis

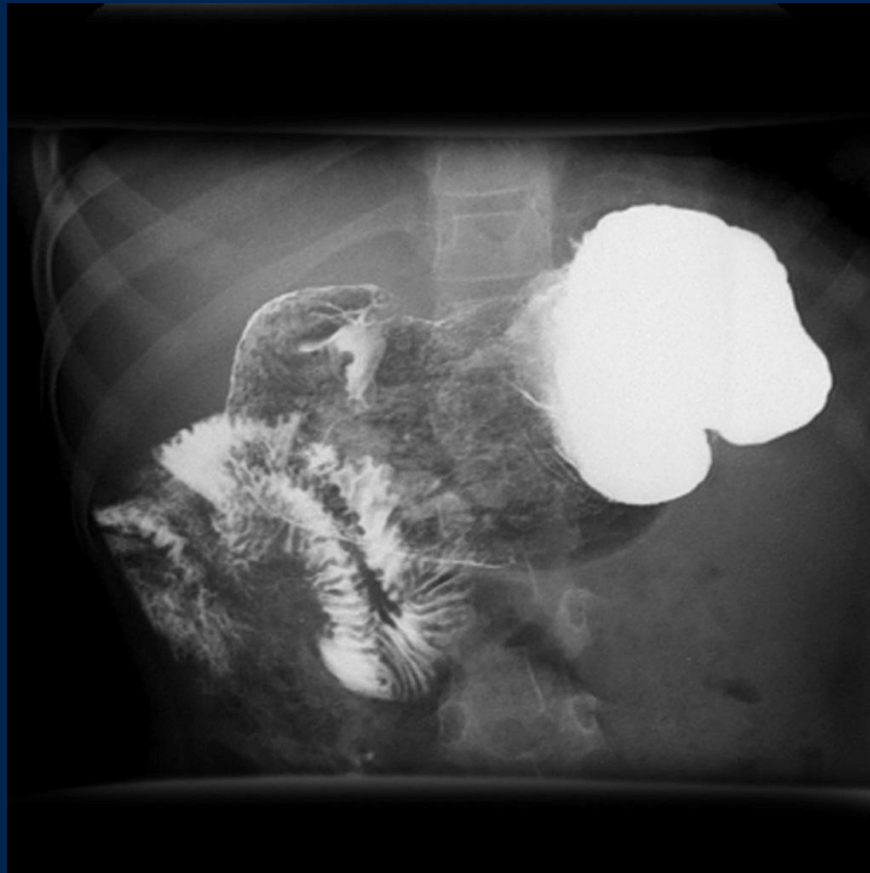## Physical Exam

- Late findings: peritonitis, rectal bleeding, hypovolemic shock

## Imaging

- Gold Standard: Upper GI
  - Can give contrast via PO or NG tube
  - Critical landmark – duodenal jejunal junction
  - Normal rotation – duodenal jejunal junction lies to the left of the spine



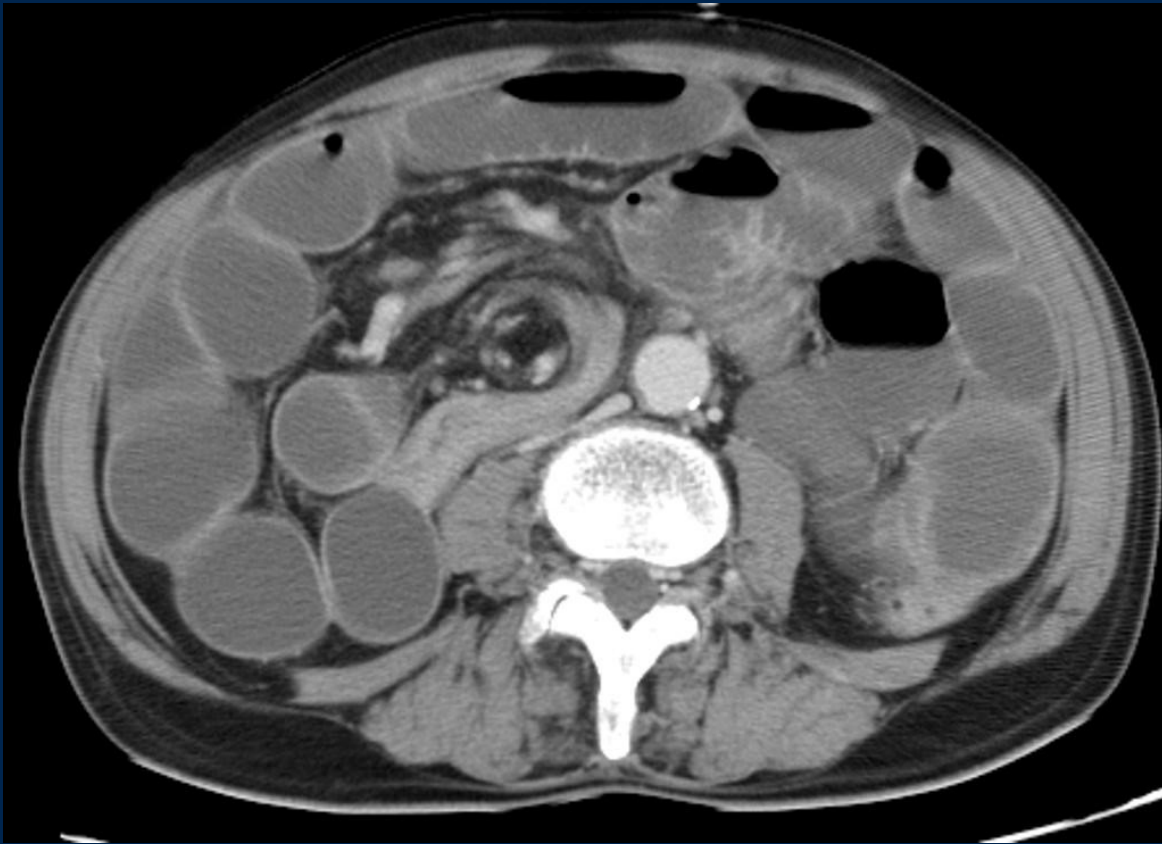


Case courtesy of A. Prof Frank Gaillard, rID8029, Radiopedia.org

## Imaging

- KUB – can be normal or abnormal
- US or CT - reversal of normal SMA and vein relationship – with midgut volvulus “whirlpool sign”





Case courtesy of Dr Laughlin Dawes , Radiopaedia.org, rID: 8490

## Initial Treatment

- NPO
- NG tube for decompression
- Correct fluid / electrolyte deficits

## Surgical Consult

- Definitive treatment – Ladd’s procedure
  - Reduction of the volvulus
  - Division of the Ladd bands
  - Division of mesenteric bands – widening of the mesenteric base
  - Small intestine on right side of abdomen, large intestine on left
  - Incidental appendectomy

## Case 2

A 3-year-old male is brought to the pediatric primary care clinic by his mother. She states that for the past day he will have episodes of abdominal pain where he will cry and draw his legs up to his chest. He will then have pain free periods; however, these are becoming fewer. Of note, he had a cold 1 week ago.

- Malrotation and Volvulus

- Intussusception

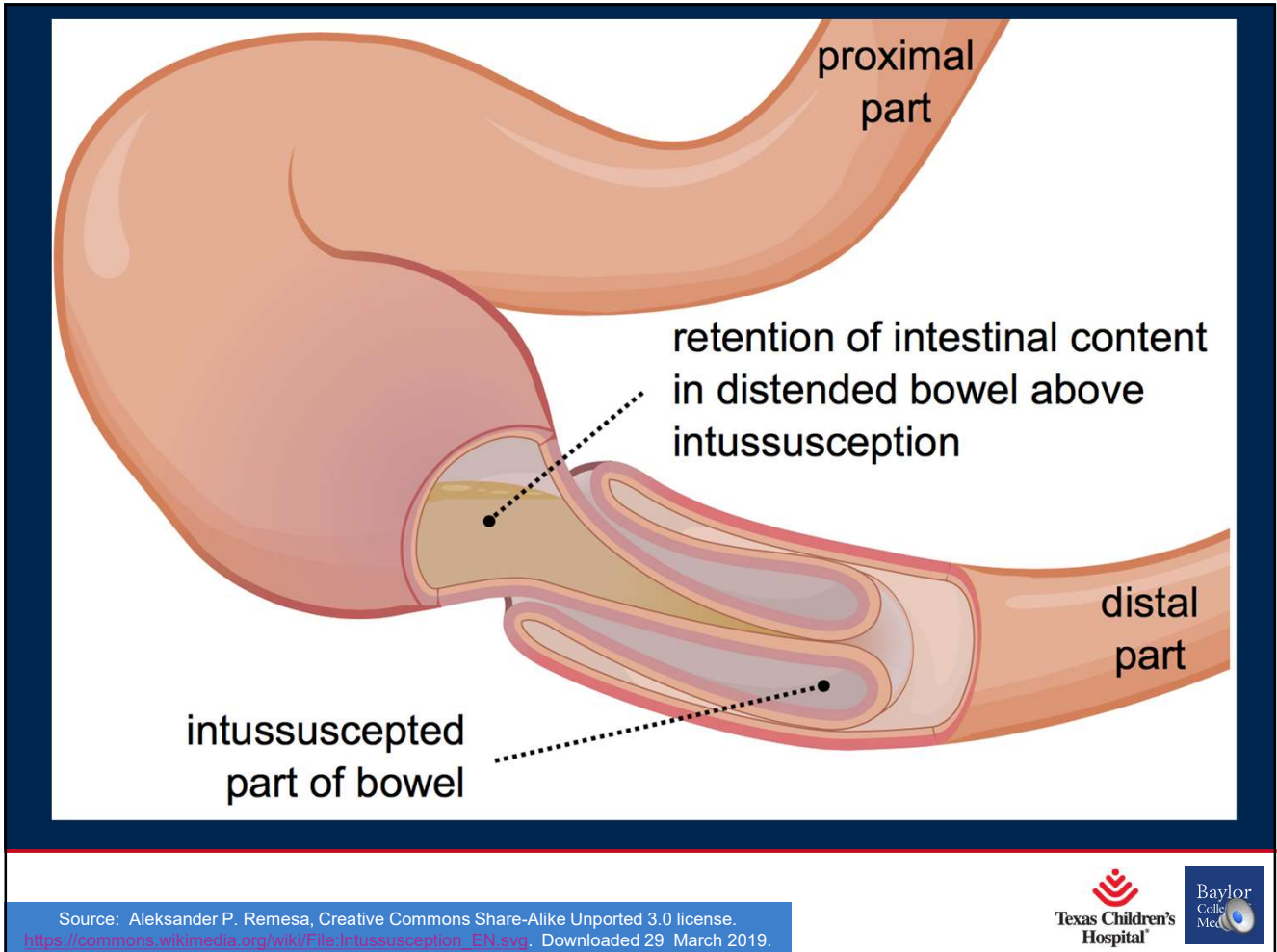
- Pyloric Stenosis

- Appendicitis

- Testicular Torsion

# Intussusception

- Common cause of bowel obstruction in children
- Segment of bowel (intussusceptum) invaginates or telescopes into the distal bowel (intussusciens)



# Intussusception

- Compresses Vessels
  - Initially – venous congestion, bowel wall edema



# Intussusception

- Compresses Vessels
  - Eventually – can compromise arterial blood supply – intestinal ischemia, bowel necrosis, bowel perforation

## Epidemiology

- Usually infants / toddlers
- Males 2-3x more frequently than females
- 1 case per 1000-2000 live births

## Pathophysiology

- Usually ileocolic – 90% of intussusception
- Can be small bowel / small bowel
  - Rare
  - Found in older children or infants less than 3 months
  - Usually associated with other medical conditions

# Primary Idiopathic Intussusception vs. Secondary Intussusception

## Primary Idiopathic Intussusception

- Idiopathic – 90% of pediatric intussusception
- Usually following a viral illness – URI or GI – more frequent in spring / autumn
- Viral illness causes hypertrophied lymphatic tissue in bowel wall, which acts as a lead point
- More cases of idiopathic intussusception in kids under the age of 2
- Usually at ileocecal junction

## Secondary Intussusception

- 2% - 12% of cases
- Identifiable lead point
  - Anatomic: Meckel's diverticula, appendicitis
  - Tumors – lipomas, lymphomas, etc.
  - Genetic – Cystic fibrosis, hamartomas from Peutz-Jeghers
  - Infectious
  - Vascular
  - Traumatic
  - Foreign Body
  - Post surgical

## Secondary Intussusception

- Risk increases after age 3
- Most common Pathologies:
  - Meckel's diverticulum
  - Lymphoma
  - Polyps

## Presentation

- Classic Triad
  - Intermittent abdominal pain
  - Red current jelly stools – blood and mucous
  - Palpable “sausage shaped” abdominal mass
- Occurs in less than 20% of patients



## Presentation

- Classical Presentation
  - Young Child
  - Recent Viral Illness
  - Intermittent “colicky” abdominal pain – drawing knees to chest
  - Vomiting / Diarrhea
  - Palpable “sausage shaped” abdominal mass

## Presentation

- In differential for patients with intermittent abdominal pain, vomiting, bloody stools, palpable abdominal mass, lethargy, altered mental status

## Timeline of presentation

Symptom	Early Onset	Late Presentation
Vitals	Stable	Shock presentation
Emesis	Non bilious	Bilious
Abdominal Exam	Normal – possible sausage shaped mass	Tender, distended, peritonitis
Stools	No change	Red bloody

## Physical Exam

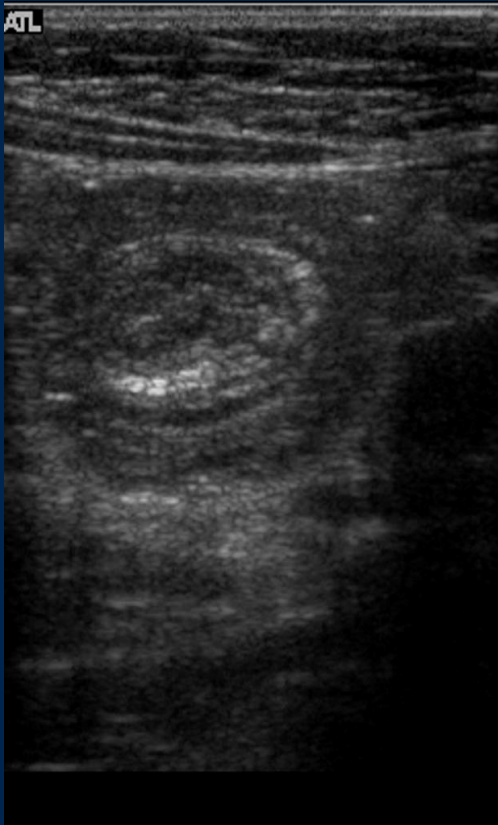
- Abdominal exam
  - Can be normal between episodes
  - Peristaltic rushes
  - Sausage shape abdominal mass – usually in RUQ
  - Dance sign – flat appearance or emptiness in RLQ

## Diagnostic Studies

- Labs
  - CBC and Chemistries helpful but not indicative
  - Guaiac + or -

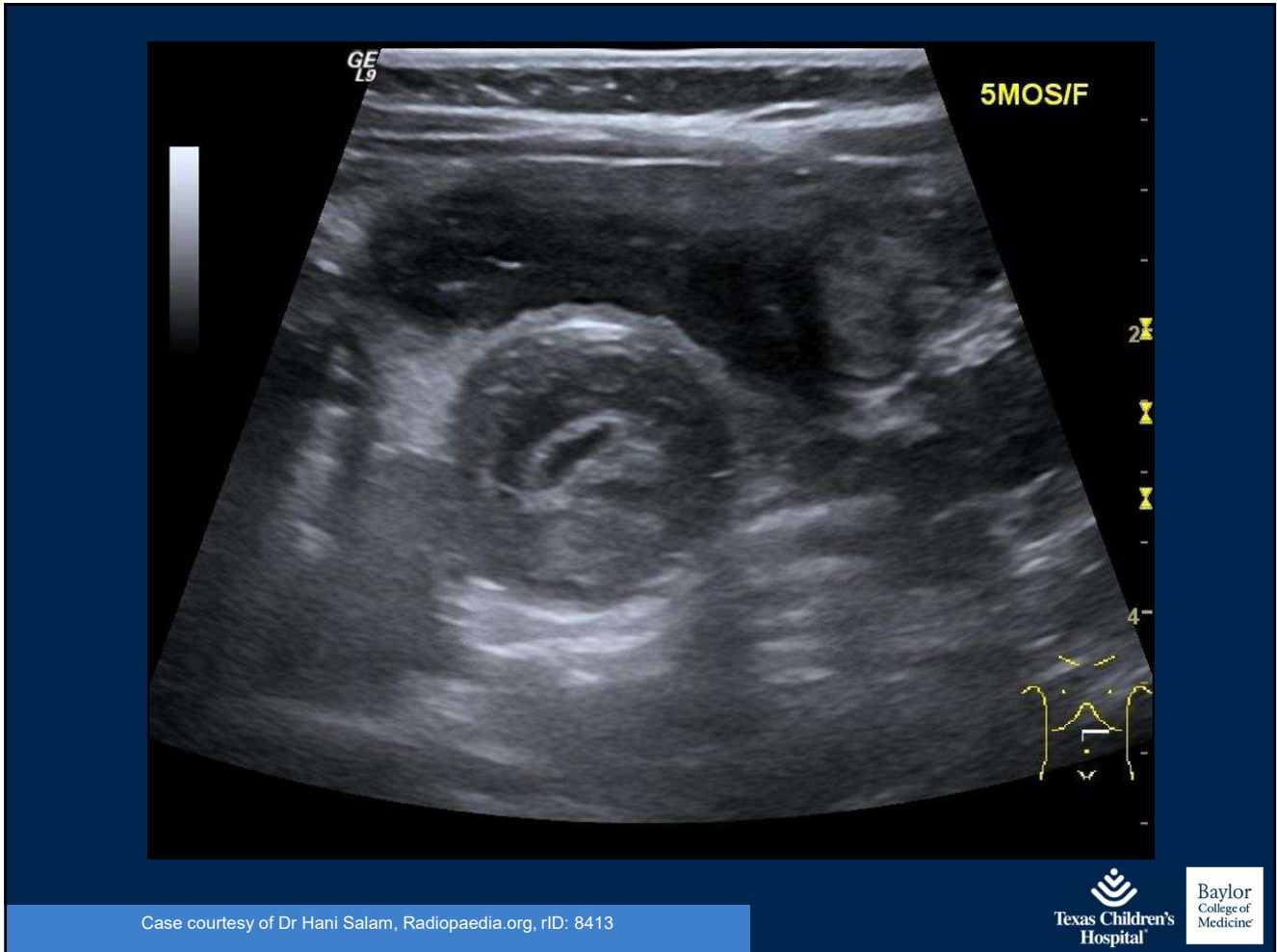
## Diagnostic Studies

- Ultrasound
  - Imaging modality of choice – sensitive, specific, decreased cost, no radiation
  - Operator dependent
  - Target sign – transverse plane – mesenteric fat and bowel wall telescoping
  - Pseudokidney sign – longitudinal plane



Case courtesy of Dr Behrang Amini , Radiopaedia.org, rID: 3456





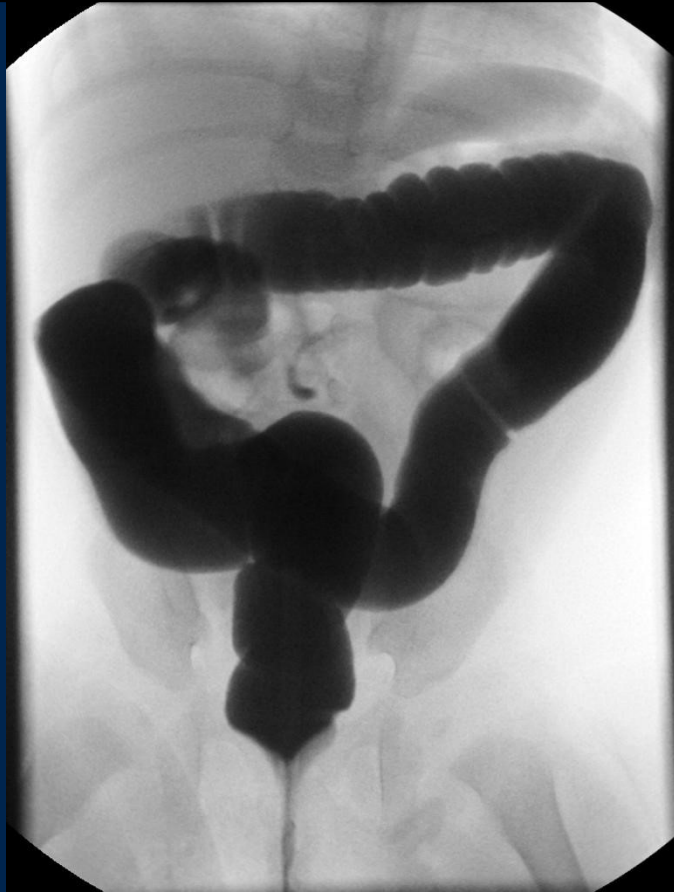

## Other Imaging

- Abdominal X-ray – ½ of patients will have an observable mass or an obstructive gas pattern
  - Always check for free air
- CT
  - Provides diagnosis, but expensive and high radiation

## Contrast Enema

- Can be used as both a diagnostic and therapeutic treatment – however, includes risk of radiation



Case courtesy of Dr. Hani Salam, r1D8413, Radiopedia.org



## Surgical Consult

- If patient stable – nonoperative reduction with radiology – performed under ultrasound or fluoroscopic guidance
  - Pneumatic enema – air insufflation
  - Hydrostatic enema – barium or water
  - Surgeon on standby
- If patient unstable or nonoperative reduction fails – to OR for surgical reduction

## Case 3

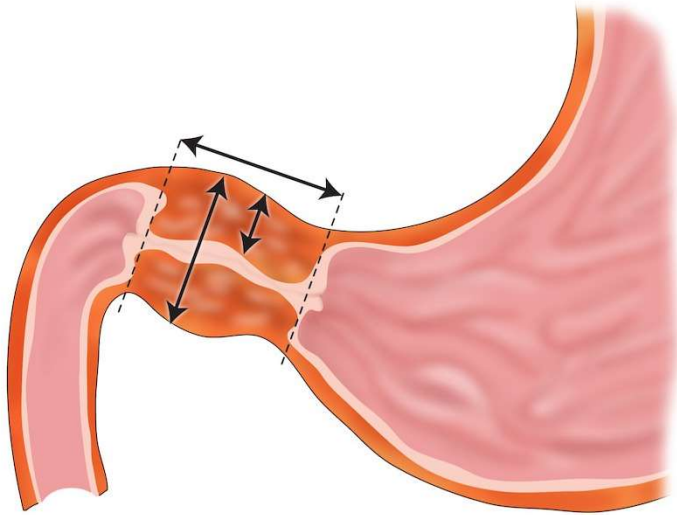
A 5-week-old formula fed male is brought to the primary care clinic by his mother. She is concerned because 2 weeks ago he started to have significant spit ups with each feeding. Over the subsequent 2 weeks mom has changed his formula numerous times, but his emesis has progressed and now is projectile after each feed.

- Malrotation and Volvulus
- Intussusception
- Pyloric Stenosis
- Appendicitis
- Testicular Torsion

## Pyloric Stenosis

- Infantile hypertrophic pyloric stenosis
- Hypertrophy and hyperplasia of the pyloric smooth muscle
- Result – narrow and elongated pyloric channel
- Normal release of pyloric sphincter impaired resulting in vomiting, failure to thrive, dehydration

### Pyloric stenosis



Normal values \*

- Length: <15mm
- Single muscle thickness: <3mm
- Pyloric width: <7mm

\* values vary somewhat from publication to publication

*F Gaillard*  
2010  
Radiopaedia.org CC-NC-SA-BY

Case courtesy of A. Prof Frank Gaillard, rID8145, Radiopaedia.org





# Pyloric Stenosis

- Epidemiology
  - Occurs in 2-4 per 1000 live births in the West
  - Boys 4x more likely than girls
  - Usually diagnosed between 3-8 weeks

# Pyloric Stenosis

- Presentation
  - Usually between 3-10 weeks
  - Nonbilious nonbloody emesis
    - Textbook - projectile
  - Wide initial differential
    - Overfeeding, gastroesophageal reflux, milk protein allergy, intestinal rotational anomalies, obstruction
  - Eventual weight loss, dehydration
  - Increased fussiness

# Pyloric Stenosis

- Physical Exam
  - Hydration status
    - Depressed fontanel
    - Dry mucosa
    - Oliguria
    - Constipation

# Pyloric Stenosis

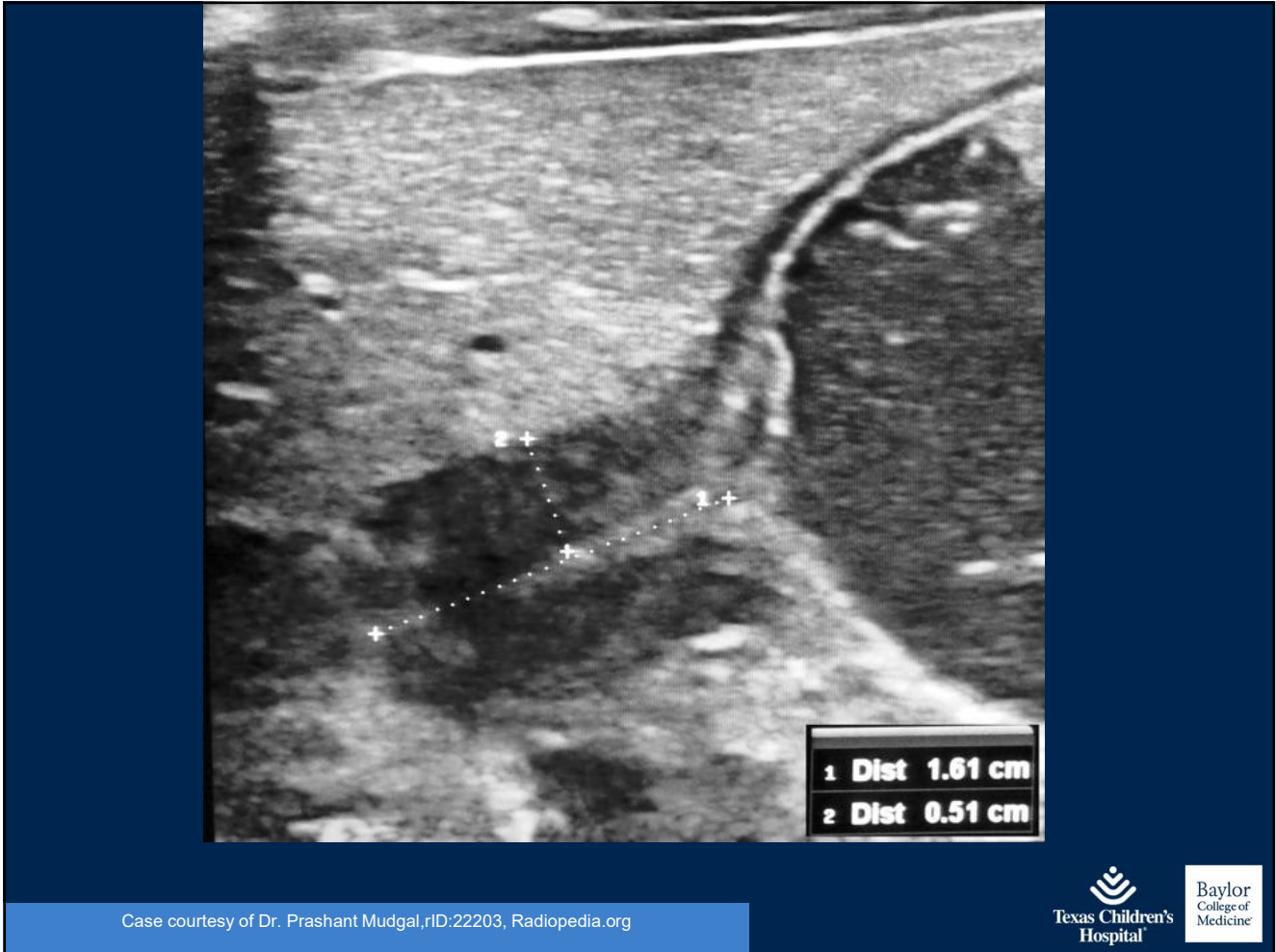- Physical Exam
  - Abdominal exam
    - “The Olive Sign” – to adequately palpate this can take upwards of 20 minutes
      - Best done when resting or sleeping, so that abdominal wall is completely relaxed
      - Consider using a pacifier with sweeties
      - Flex hips/lift up legs

# Pyloric Stenosis

- Labs
  - Chemistries – metabolic alkalosis
    - Low Chloride
    - High Bicarb

# Pyloric Stenosis

- Imaging
  - Ultrasound
    - Looking at length of pyloric channel and thickness of pyloric muscle – Channel  $> 15\text{mm}$  long, Muscle  $> 3\text{mm}$  thick
    - Target sign in transverse view
    - Nipple and cervix signs



# Pyloric Stenosis

- Imaging
  - Diagnostic measurements
  - Mnemonic “Number pi” – 3.1415
    - Pyloric muscle thickness, single muscular wall on transverse image  $> 3\text{mm}$
    - Pyloric transverse diameter  $> 14$
    - Length in longitudinal measurement  $> 15\text{mm}$



# Pyloric Stenosis

- Imaging
  - UGI – can be used when US not available
    - “Beak sign”

## Surgical Consult

- Remember – this is a medical emergency not a surgical one
- Hydrate hydrate hydrate
- Correct electrolyte imbalances
- NPO
- Definitive treatment – pyloromyotomy (laparoscopic vs. open)

## Case 4

A 6-year-old female is brought to the urgent care by her mother with a 2-day history of abdominal pain, nausea and vomiting. Pain initially started at the umbilicus and has now transitioned to the right lower quadrant. Worse with walking and movement. Tried Pepto-Bismol and Motrin without relief. Subjective fever at home.

- Malrotation and Volvulus
- Intussusception
- Pyloric Stenosis
- Appendicitis
- Testicular Torsion

# APPENDICITIS

OBTURATOR SIGN AND PSOAS SIGN

ROVSIING SIGN

TENDERNESS AT MCBURNEY'S POINT: 1/3 OF THE DISTANCE FROM THE ASIS TO THE UMBILICUS

IT STARTED WITH PERIUMBILICAL PAIN AND THEN MOVED TO THE RLQ!

USUALLY CAUSED BY FECALITHS OR LYMPHOID HYPERPLASIA

WWW.MEDCOMIC.COM

© 2016 JORGE MUNIZ

Jorge Muniz PA-C, Medcomic.com

Texas Children's Hospital

Baylor College of Medicine

# Appendicitis

- Most common pediatric abdominal surgical emergency
- Peak incidence – 2<sup>nd</sup> decade
- Male : Female 1.4 :1
- Increased presentation in summer months
  - Increased perforation in winter months

# Appendicitis

- Pathophysiology
  - Obstructed appendiceal lumen
  - Lack of washout causes distension, bacterial overgrowth
  - Mucosal barrier of appendix is overwhelmed – bacteria breaks through barrier causing infection

# Appendicitis

- Pathophysiology
  - Distension cause increased intraluminal pressure
  - Stimulation of the 8<sup>th</sup> – 10<sup>th</sup> visceral afferent thoracic nerves = periumbilical pain
  - Pressure increases – tissue ischemia, mucosal compromise, transmural inflammation
  - Inflammation to parietal peritoneum – localized pain
    - fever/nausea/emesis/anorexia
  - Eventual gangrene and perforation



# Appendicitis

- History
  - Initial periumbilical pain migrating to RLQ
  - Nausea / vomiting
  - Anorexia
  - Fever
  - Diarrhea
  - Signs of peritoneal irritation (pain with movement, etc)

# Appendicitis

- History
  - Kids are poor historians
  - In pediatric patient, most telling sign - initial periumbilical pain migrating to RLQ
  - Under age 3 – increased risk of perforation

# Appendicitis

- Physical Exam
  - Tenderness to palpation and guarding in RLQ
  - McBurney's sign – most reliable exam finding – tenderness to palpation over McBurney's point (1/3 of distance from right ASIS to umbilicus)
  - Hypoactive bowel sounds
  - Percussive and rebound tenderness

# Appendicitis

- Physical Exam
  - Rovsing – palpate LLQ – positive when patient feels referred pain in RLQ
  - Obturator – pain with internal rotation of right hip when flexed at knee and hip
  - Psoas – positive if pain with extension of right hip

# Appendicitis

- Scoring Systems
  - Alvarado
  - Pediatric Appendicitis Score (PAS)

# Appendicitis

- Scoring systems - Alvarado

<b>Migration of Pain</b>	<b>1</b>
Anorexia	1
Nausea / Vomiting	1
RLQ tenderness	2
Rebound Pain	1
Increased temp (>37.3 C)	1
Leukocytosis (> 10,000)	2
Polymorphoneuclear Neutrophilia	1
<b>Total</b>	<b>10</b>

# Appendicitis

- Alvarado Score
  - Developed for adult population
  - Scoring
    - 1-4 negative for appendicitis
    - 5-8 further diagnostic studies required
    - 9 – 10 appendicitis

# Appendicitis

- Scoring systems – Pediatric Appendicitis Score (PAS)

<b>Migration of Pain</b>	<b>1</b>
Anorexia	1
Nausea / Vomiting	1
RLQ tenderness	2
Cough / hopping / percussion tenderness in RLQ	2
Increased in temperature	1
Leukocytosis (> 10,000)	1
Polymorphoneuclear Neutrophilia > 75%	1
<b>Total</b>	<b>10</b>



# Appendicitis

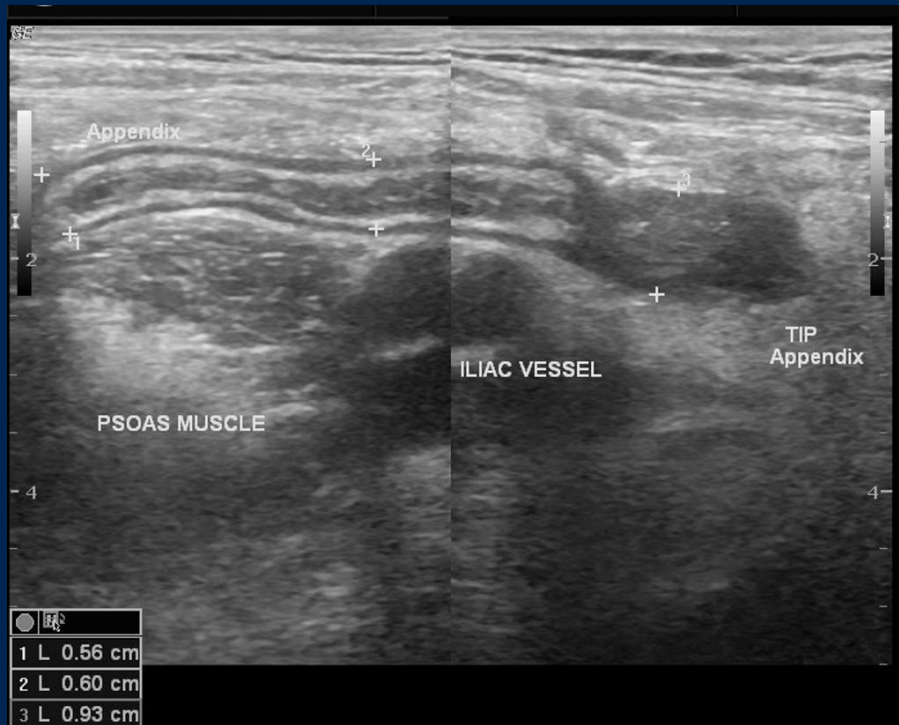- PAS Score
  - Sensitivity – 97%
  - Specificity – 97.6%
  - Scoring
    - 1-3 negative for appendicitis
    - 4-7 further diagnostic studies required
    - 8-10 appendicitis

# Appendicitis

- Labs
  - CBC
    - Elevated WBC
    - Left shift
  - CMP
  - ANC – WBC and ANC elevated in 96% of patient with acute appendicitis
  - CRP – less sensitive in first 24 hours, but more sensitive than WBC in patients with 24 – 48 hours of symptoms

# Imaging

- US
  - Increased diameter
  - Wall thickening
  - Irregular wall – rigid / non-compressible
  - Absence of air in appendiceal lumen
  - Periappendiceal fat stranding
  - Appendicolith
  - Free Fluid



Case courtesy of Dr Maulik S Patel, Radiopaedia.org, rID: 16327

# Imaging

- CT
  - Oral and IV contrast are the gold standard

## Surgical Consult

- NPO
- Immediately start on antibiotics – broad spectrum geared towards intestinal flora
- Hydrate
- Pain control

## Surgical Consult

- Definitive treatment – appendectomy (laparoscopic vs open)
- If abscess present – possible IR drainage of abscess, followed by antibiotics and then interval appendectomy

## Case 5

A 12-year-old male is brought to urgent care by his grandmother with concerns of abdominal pain, nausea and vomiting. Abdominal exam is benign. What key exam do you need to perform?



- Malrotation and Volvulus
- Intussusception
- Pyloric Stenosis
- Appendicitis
- Testicular Torsion

**TESTICULAR TORSION**

SURGICAL EMERGENCY THAT REQUIRES INTERVENTION WITHIN 6 HOURS

TWISTING OF THE TESTIS AND SPERMATIC CORD RESULTS IN ISCHEMIA

ACUTE PAIN AND SWELLING

DOPPLER ULTRASOUND DEMONSTRATES DECREASED BLOOD FLOW

WWW.MEDCOMIC.COM © 2015 JORGE MUNIZ

Jorge Muniz, Medcomic.com

Texas Children's Hospital Baylor College of Medicine

## Testicular Torsion

- Twisting of the spermatic cord resulting in compromised venous and arterial flow
- Predisposition from the bell clapper deformity
  - Occurs in 17% of males, 40% bilaterally
  - High abnormal attachment of tunica vaginalis allows the spermatic cord to rotate freely resulting in torsion

## Testicular Torsion

- Eventually can lead to irreversible testicular damage – loss of testicle
- Diagnosis within 6 hours for viability of the testicle
- 32% of pediatric torsion result in orchiectomy

## Testicular Torsion

- 16% of cases in patients presenting to ER with acute scrotum
- Peak incidence age 12-18 years
- Left testicle more common than right

## History

- Sudden onset scrotal pain – usually less than 24 hours – can wake from sleep
- Scrotal edema
- Scrotal erythema
- Also can present as abdominal pain
- Nausea / vomiting – in about 1/3 of patients
- Late in process, pain can resolve as testis necrosis occurs

## Physical Exam

- Ideally patient supine with knees opened laterally (butterfly)

## Physical Exam

- Scrotal swelling
- Horizontal lie of testicle
- Erythema
- Tenderness on palpation



## Signs and Symptoms

- Loss of Cremasteric reflex – lightly touch the inner thigh and look for retraction of the testicle
- Negative Prehn's sign – no improvement of pain with elevation of testicle

# Imaging

- Diagnosis made by color Doppler ultrasound

## Surgical Consult

- Immediately to OR for testicular de-torsion, orchiectomy vs. orchiopexy, and contralateral orchiopexy

# Bibliography

## Bibliography for images listed on slides

- Al-Salem, A. (2017) Acute Scrotum. In: An Illustrated Guide to Pediatric Urology. Springer, Cham. doi: [http://doi.org/10.1007/978-3-319-44182-5\\_29](http://doi.org/10.1007/978-3-319-44182-5_29)
- Al-Salem, A. (2014) Intestinal Malrotation. In: An Illustrated Guide to Pediatric Surgery. Springer, Cham. doi: [https://doi.org/10.1007/978-3-319-06665-3\\_25](https://doi.org/10.1007/978-3-319-06665-3_25)
- Al-Salem, A. (2014) Intussusception. In: An Illustrated Guide to Pediatric Surgery. Springer, Cham. doi: [https://doi.org/10.1007/978-3-319-06665-3\\_24](https://doi.org/10.1007/978-3-319-06665-3_24)
- Applegate, K. E. (2009). Evidence-based diagnosis of malrotation and volvulus. *Pediatric Radiology*, 39(S2), 161-163. doi:10.1007/s00247-009-1177-x
- Bachur, R., Callahan, M., Monuteaux, M., & Rangel, S., (2015). *The Journal of Pediatrics*, 166(5), 1134-1139. Doi:10.106/j.peds.2015.01.034
- Bowker, B., & Rascati, S. Intussusception. *Journal of the American Academy of Physician Assistants*, 31(1), 48-49
- Diaz, E. C., Kimball, D., & Gong, E. M. (2014). Acute Scrotal Pain in Pediatric Emergency Medicine: Assessment, Diagnosis, Management, and Treatment. *Clinical Pediatric Emergency Medicine*, 15(3), 248-260. doi:10.1016/j.cpem.2014.08.002
- Goldman, R., Carter, S., Stephens, D., Antoon, R., Mounstephen, W., & Langer, J. (2008). Prospective Valiation of the Pediatric Appendicitis Score. *The Journal of Pediatrics*, 154(2):308-9. Doi:10.1016/j.peds.2008.01.033
- Krader, C. (2017). What's new about pediatric appendicitis. *Contemporary Pediatrics*, 34(10), 18-19.
- Mafi M., Lima M. (2017) Acute Appendicitis. In: Lima M. (eds) Pediatric Digestive Surgery. Spring, Cham. doi: [https://doi.org/10.1007/978-3-319-4025-4\\_20](https://doi.org/10.1007/978-3-319-4025-4_20)
- Pandya, S., & Heiss, K. (2102). Pyloric Stenosis in Pediatric Surgery. *Surgical Clinics of North America*, 92, 527-539. Doi:10.1016/j.suc.2012.03.006
- Pepper, V., Stanfill, A., & Pearl, R. (2012). Diagnosis and Management of Pediatric Appendicitis, Intussusception, and Meckel Diverticulum. *Surgical Clinics of North America*, 92, 505-526. Doi:10.1016/j.suc.2012.03.011
- Qaquish, N, Muzio, B., et al. Hypertrophic pyloric stenosis (ultrasound measurements mnemonic). <https://radiopaedia.org/articles/hypertrophic-pyloric-stenosis-ultrasound-measurements-mnemonic-1?lang=us>
- Reinburg, O. (2017) Pyloric Stenosis. In: Lima M. (eds) Pediatric Digestive Surgeries. Springer, Cham. doi: [https://doi.org/10.1007/978-3-319-4025-4\\_14](https://doi.org/10.1007/978-3-319-4025-4_14)
- Samuel, M. (2002). Pediatric Appendicitis Score. *Journal of Pediatric Surgery*, 37(6), 877-881. Doi:10.1053/jpsu.2002.32893
- Shalaby, M. S., Kuti, K., & Walker, G. (2013). Intestinal malrotation and volvulus in infants and children. *Bmj*, 347(Nov26 2), doi:10.1136/bmj.f6949
- Taghavi, K., Powell, E., & Patel, B. (2017). The treatment of pyloric stenosis: Evolution in practice. *Journal of Paediatrics and Child Health*, 53(11). Doi:10.111/jpc/13736
- Taylor, N., Cass, D., & Holland, A. (2013). Infantile hypertrophic pyloric stenosis: Has anything changed? *Journal of Paediatrics and Child Health*, 33, 33-37.
- Wang, J. (2013). Testicular Torsion. *Urological Science*, (23), 85-86. <http://dx.doi.org/10.10106/j.urols.2012.07.009>
- Waseem, M., & Rosenberg, H.K. (2008) Intussusception. *Pediatric Emergency Care*, 24(11). 793-800.

# Questions ?

## Contact Information

Anna C. Shafer, MMSc, PA-C  
[acshafer@texaschildrens.org](mailto:acshafer@texaschildrens.org)

