

Pediatric Urology:

The Nuts and Bolts for any
Pediatric Provider



Kaitly Colon-Sanchez, MPAS, PA-C
Department of Pediatric Urology

Disclosures

- None

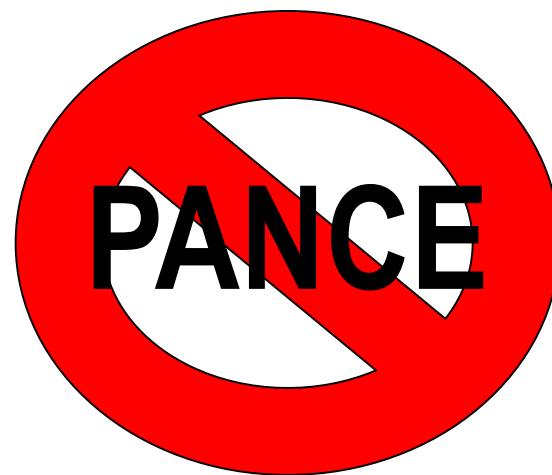
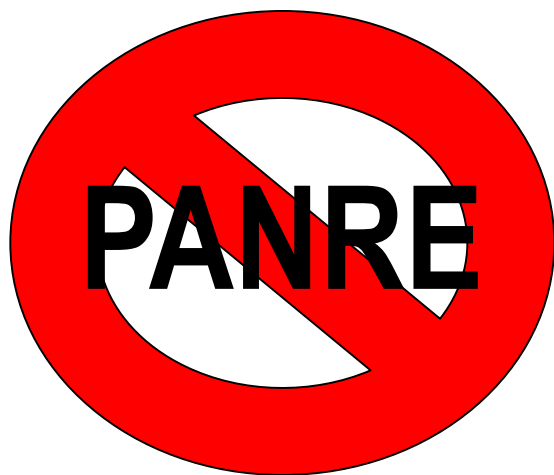
Objectives

- Understand the presentation and initial evaluation of common pediatric urological conditions
- Recognize pediatric urological emergencies
- Perform a detailed GU exam with emphasis on scrotal and penile anatomy
- Discuss management of frequently encountered pediatric urological conditions



***The most important exam
of your life!!!!***



Male GU Examination

- Can be awkward/uncomfortable
- What am I even looking at?
- Should I touch it?
- Is that normal?



Male GU Examination

STEP 1 – THE PENIS

- It is NOT X-rated....

...Please EXAMINE carefully 😊



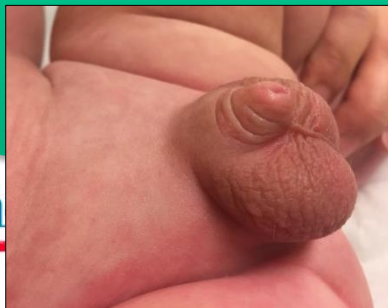Male GU Examination - INSPECT

PENILE SHAFT

Can you see the penile shaft? Concealed?

Rule out Micropenis

Look for Curvature

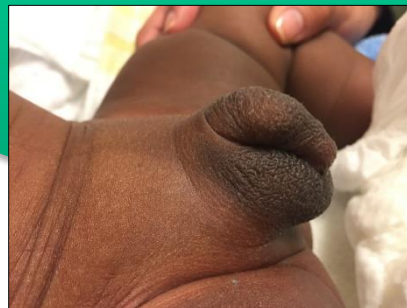

GLANS

Where is it in relationship to the foreskin?

Is it torsed?

Where is the meatus?



SKIN SURFACE

Is the prepuce tight? Hooded?

Crease at the penopubic junction?

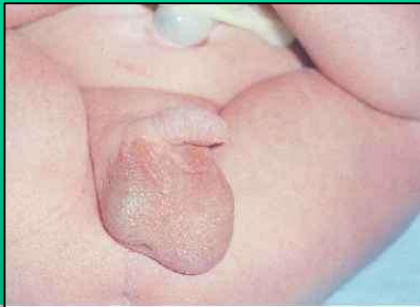Scrotal Webbing? Ventral skin wasting?



Male GU Examination - INSPECT

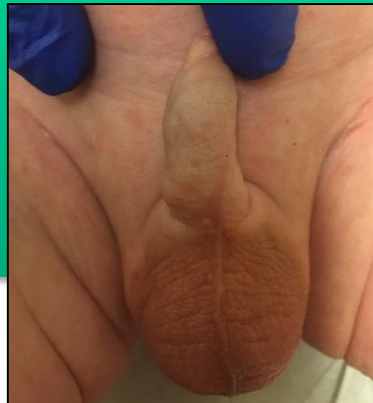SCROTUM

Are they equal?
Is one larger than the other?
Are they both large?



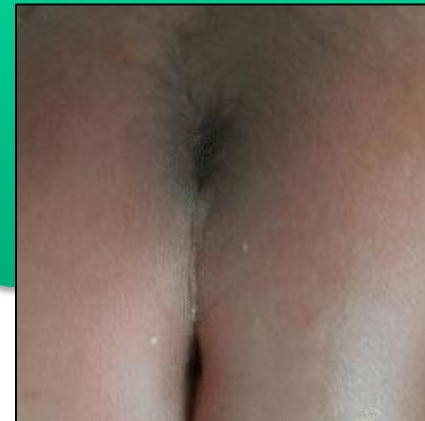
MEDIAN RAPHE

Is it straight?
Is it wandering?
Proximal?
Distal?



SACRUM

Is there a dimple?
Tuft of hair?
Is the gluteal cleft straight?



Male GU Examination

Palpate – Yes, you need to touch it!

PENIS

Pull the foreskin back
– be gentle?

Adhesions versus skin
bridge versus phimosis

Is there a buried or
concealed penis?

Does the glans come
out if you push on the
base of the penis?

SCROTUM

Is there fluid?

Bag of worms?

Is the testicle even
there?

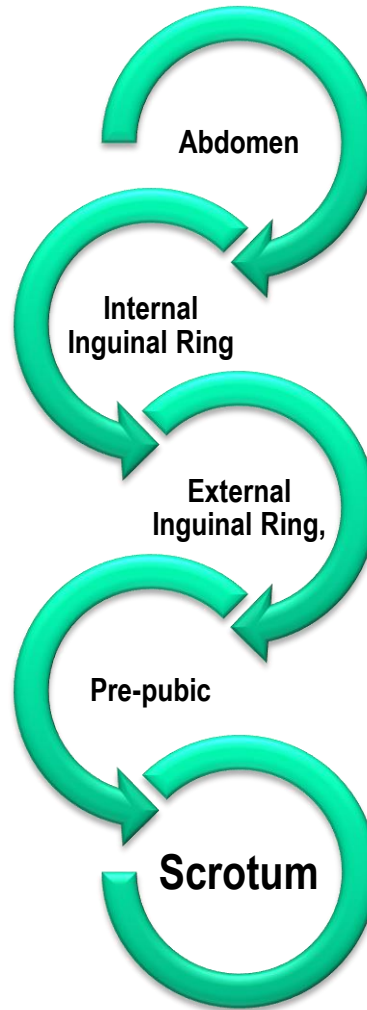
SACRUM

Is there a sacral defect



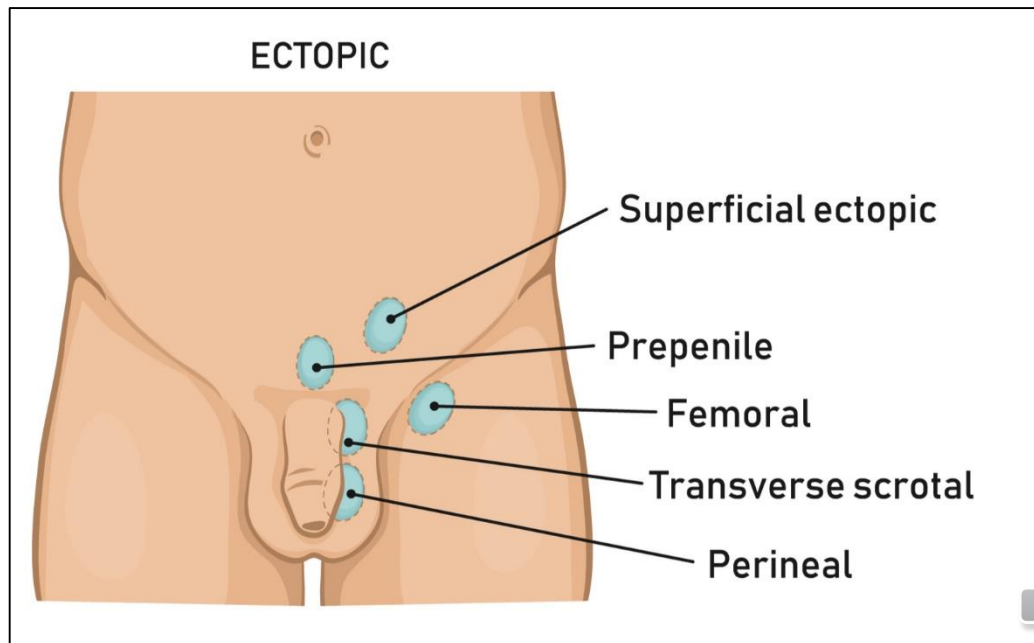
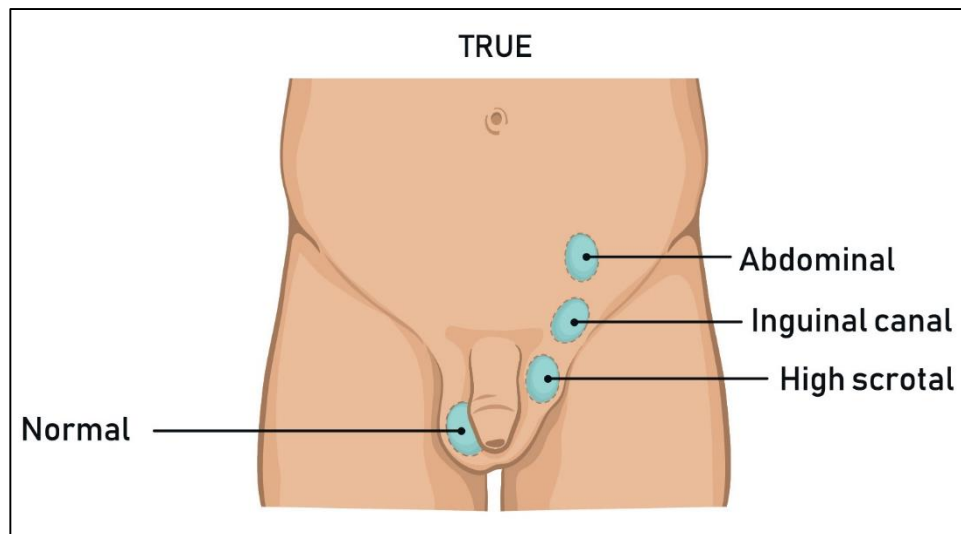
Testicular descent pathway

- Typically occurs between 28-40 weeks gestation (third trimester)



Undescended Testicle

- Cryptorchidism
 - Failure of descent from abdomen to scrotum
- Common in pre-maturity (3-5%, 15% bilateral)
 - Important to age-adjust
- Spontaneous descent occurs by age 3-6 months (age adjusted)
- Palpable vs. Non- Palpable
- Bilateral non-palpable
 - Confirmed Phenotypic males
 - Think possible DSD – need urgent urology consult



Undescended Testicles - Diagnosis

- Physical Exam
 - Patient position
 - Laying down
 - Legs straight versus butterfly open position
 - Look at the scrotum
 - Sometimes can see them, but don't just look, you need to feel them in the scrotum
 - Flattened scrotum
 - Can be challenging
 - Child Laughing/crying
 - Hand on pubic bone can help
 - Keeps the testes from retracting upward
 - Flat hand rolling back and forth can help distinguish between testicle and LN



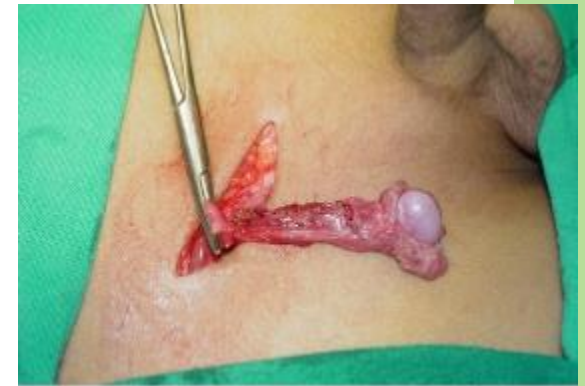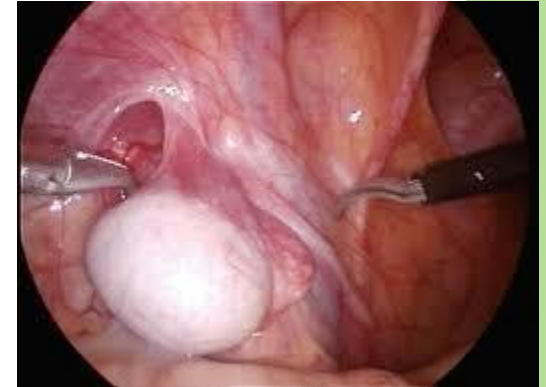Undescended Testicles – Diagnosis

- Imaging
 - NONE
 - 2014 AUA Guidelines on UDT
 - “Providers should not perform US or other imagining modalities in the evaluation of boys with cryptorchidism prior to referral as theses studies rarely assist in decision making.”
 - TUS order only if testicles are non-palpable in a patient with increased BMI that has increased pelvic girth (fat pad)
- Referral
 - After 6 months of age if there is no spontaneous descent



Undescended Testicles – Treatment

- Surgery – Orchidopexy (6 – 18 mos)
 - Risks of UDT
 - Testicular mass, infertility, inguinal hernia, testicular torsion, trauma
- Non- Palpable
 - Exam under anesthesia
 - Diagnostic Laparoscopy
 - Fowler – Stephens (1 vs 2 stage)
- Palpable
 - Inguinal vs. Scrotal
 - If hernia is identified will repair at the same time
- Three quadrant scrotal orchidopexy with permanent suture vs close hiatus
- No straddling activities for 2 weeks



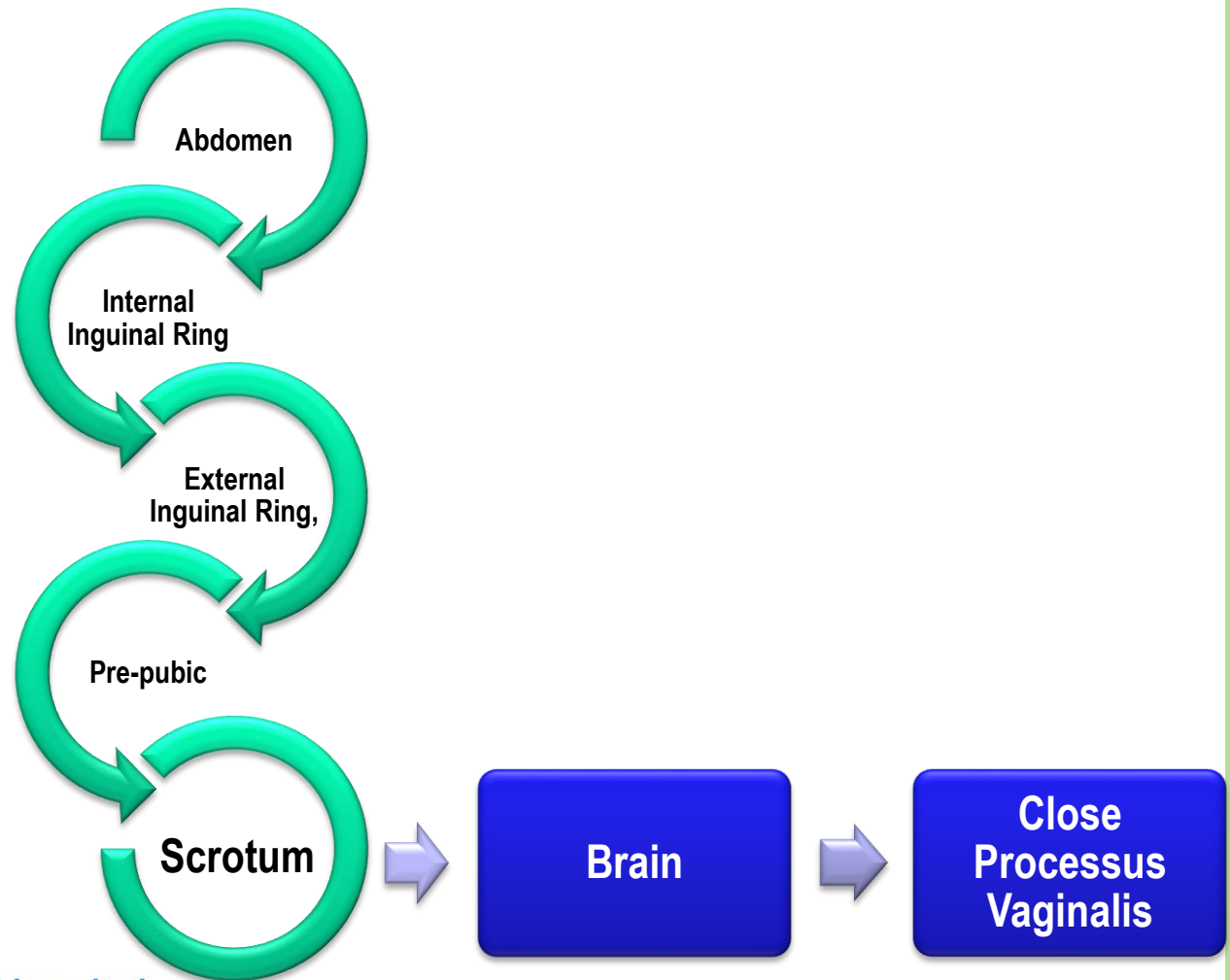
Retractile Testicles

- Not a truly UDT
- Cremasteric muscles responsible for the up and down movement of the testicles
 - Cold/anxious/laughing/crying/touch inner thigh
 - When stronger than the weight of the testicles
- Testicles found in the inguinal canal and can be brought down into the scrotum
 - Fatigue the cremasteric muscles testicles stay in the scrotum
- 90% of retractile testes come down and stay in the scrotum
- 10% of retractile testes become UDT - orchidopexy
- Follow up every 6 months to on year



Testicular descent pathway

- Typically occurs between 28-40 weeks gestation



Hydrocele:

Accumulation of fluid in the scrotum

Communicating

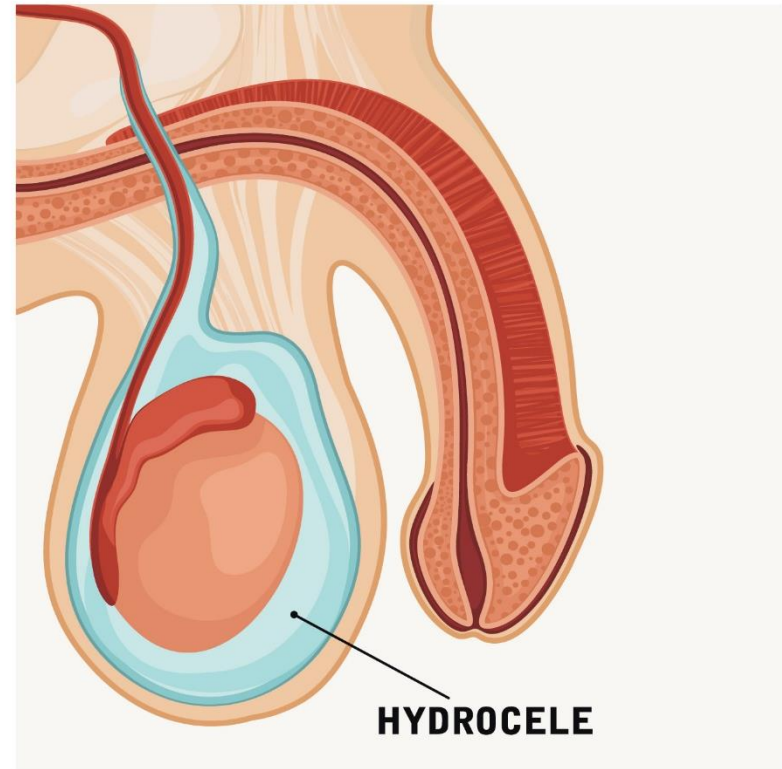
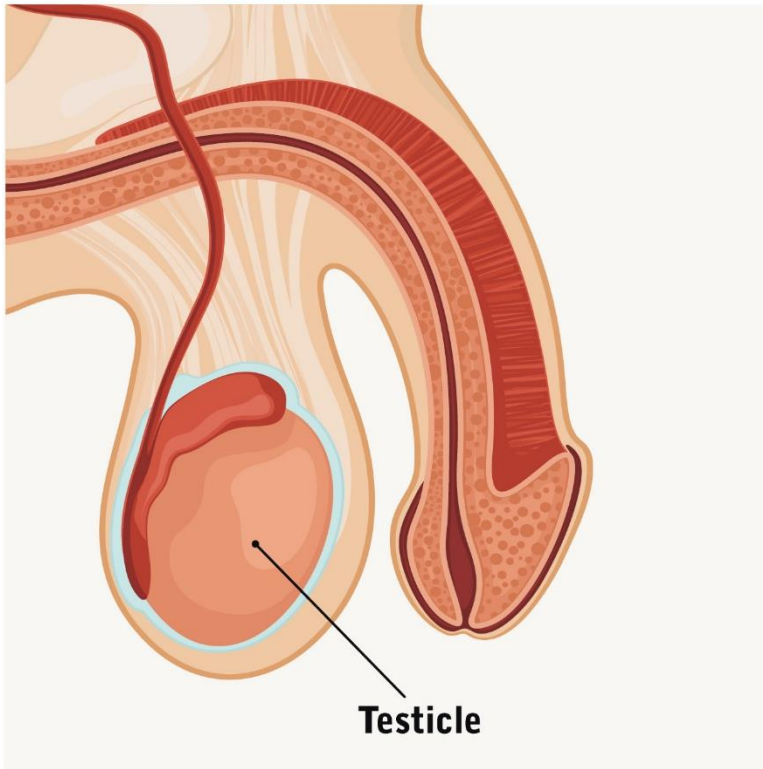
- Open patent process small enough for fluid to fill the scrotum, not large enough for a bowel content
 - Due to open process vaginalis at risk for inguinal hernia
- Congenital Defect

Non-communicating

- No connection to peritoneum
- Mostly in adolescents and adults
- Fluid comes from the mesothelial lining of the tunica vaginalis
 - Inflammation of the testis/epididymis (Trauma, infection)
- Acquired
- Self-limiting (within first year of life)



Hydrocele



Hydrocele

HPI/Physical Exam

Communicating

- Changes in size throughout the day
- Smaller in AM than PM
- Physical exam
 - Can be reduced
 - Silk Glove Sign
 - Layers of processes vaginalis can be felt around the spermatic cord feeling like “silk rubbing on silk” without a lump.
 - Transillumination
 - Does not help distinguish hernia/hydrocele

Non-Communicating

- Does not change size
- Traumatic event
 - Surgery
 - Contact
 - Epididymitis
 - Torsed Appendage
- Physical Exam
 - Fluid cannot be reduced



Hydrocele

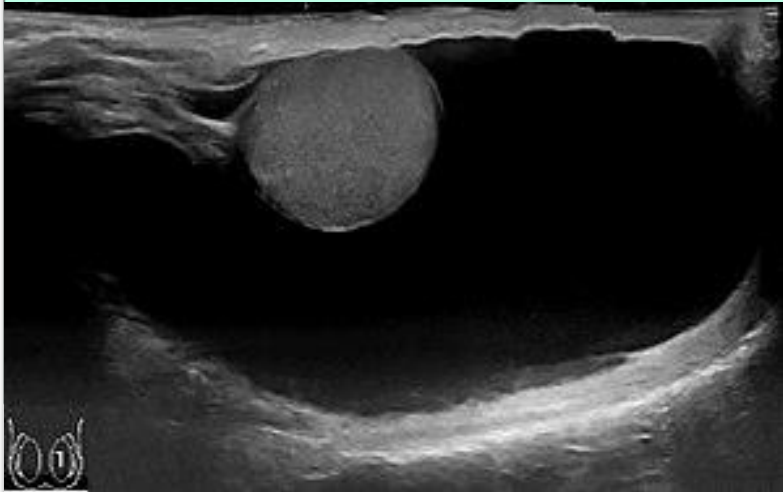
Diagnosis/Referral

Communicating

- Imaging
 - None
- Referral
 - After six months

Non-Communicating

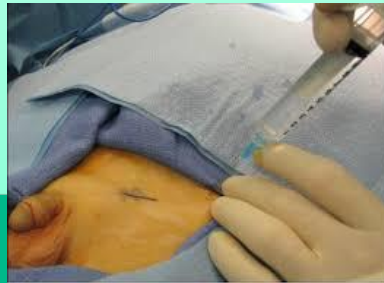- Imaging
 - TUS when testicle cannot be palpated
 - Ensure no malignancy causing hydrocele
- Referral
 - Complaints of discomfort
 - Concerns of appearance
 - Cannot feel testicle
 - Scrotal size continues to change



Hydrocelectomy

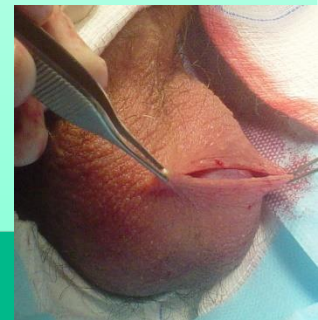Communicating

- Inguinal Incision
 - Separate spermatic cord from the hydrocele/hernia sac
 - Risk of injury to vas/vessels (1%)
- No straddling toys for 2 wks
- Risk of recurrence



Non-Communicating

- Scrotal incision
 - Open and evert tunica vaginalis
 - Risk of injury to vas/vessels
- No straddling activities for 2 wks
- Risk of recurrence

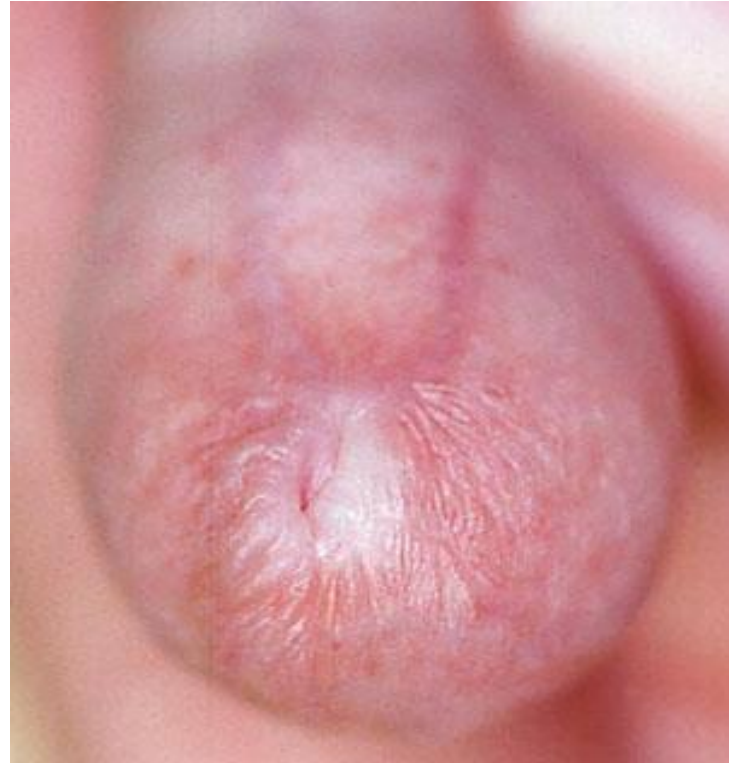
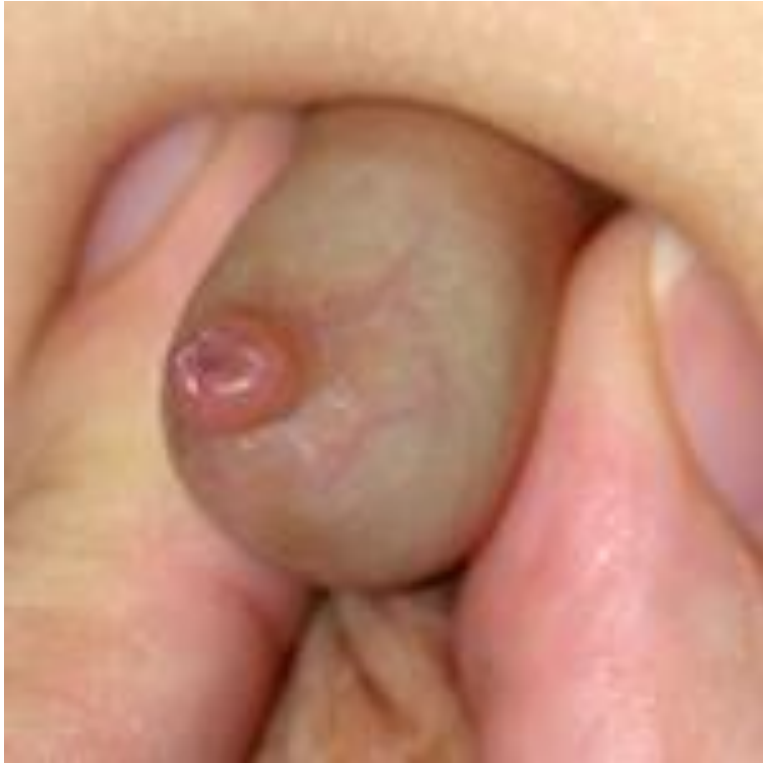

Phimosis

- From the Greek phimos (muzzle) – a condition where the foreskin cannot be fully retracted over the glans penis
 - Congenital (physiologic)
 - Newborn
 - Pathologic



Phimosis



Phimosis

When Does the Foreskin Retract?

Age	Percentage of Boys Able to Retract Foreskin
At birth	4%
At 6 month	20%
At 3 years	90%
At 17 years	99%

Choe et al. 2005. *emedicine*; Steadman, Ellsworth. *Urologic Nursing* 2006



Phimosis

- How Does the Foreskin Retract?
 - Smegma
 - Erections
 - Medications



Phimosis

- Smegma
 - It is not PUS
 - It is not an infection
 - It is NORMAL



Phimosis - Smegma

- **Smegma** (Greek smēgma, "soap") -combination of exfoliated (shed) epithelial cells, transudated skin oils, and moisture.
- Males and females produce smegma
- In males, smegma helps keep the glans moist and facilitates sexual intercourse by acting as a lubricant.
- No evidence that smegma causes penile cancer, but its presence over a long period of time may irritate and inflame the penis, which may increase the risk of cancer.



Phimosis - Diagnosis

- HPI – parental concern of tight foreskin, ballooning prior to voiding
- Physical Exam
 - Tight foreskin that cannot be retracted
- Imaging
 - None



Phimosis - Treatment

- Topical steroid cream
 - 0.05% clobetasol proprionate
 - 0.05% betamethasone **
 - 0.1% betamethasone
 - 1% hydrocortisone
 - Diclofenac sodium
- Efficacy ranges from 65-95%
- Betamethasone 0.05% applied BID for 4 wks has shown consistently good results, but 0.05% clobetasol which is less-potent also very effective
- Some studies show optimal time of betamethasone use is at least 8 weeks.
- Can use for multiple rounds of treatment of phimosis for those not seeking circumcisions.



Phimosis - Treatment

- Concerns with topical steroids
 - Systemic absorption and suppression of hypothalamic-pituitary-adrenal axis
 - Increased risk if underlying inflammation, use over a larger area, prolonged use and use of occlusive dressing
 - Use of steroid ointment not extensively studied in children < 3 yrs of age and thus use with caution
- When to refer
 - When patient has failed at least **6 weeks** of consistent medical management
- Surgery
 - Circumcision



Balanitis/Balanoposthitis

- Infection of the foreskin/glans
- Painful voiding
- Associated with uncircumcised males with poor hygiene due to urine trapping



Balanitis/Balanoposthitis - Treatment

- Antibiotic treatment
 - Mupiricin ointment
- Treat phimosis
 - Betamethasone
- Chronic infections
 - May lead to Balanitis Xerotica Obliterans (BXO)
 - May warrant Circumcision



Circumcision

- Neonatal Circumcisions
 - AAP and CDC recommend Neonatal Circumcisions
 - Under 12 months
 - Decreases the risks of UTI in 1 in 10 newborns
 - Decreases risk of penile cancer
 - Decreases transmission of STDs
 - This benefit can be negated with sexual practices



Circumcision – Who should get it?

- Neonates
- Patients who have true phimosis and have failed medical treatment
- Patients with recurrent balanitis/balanoposthitis
- Patients with recurrent UTI (confirmed with UCx)
 - Rule out any GU anatomical anomalies



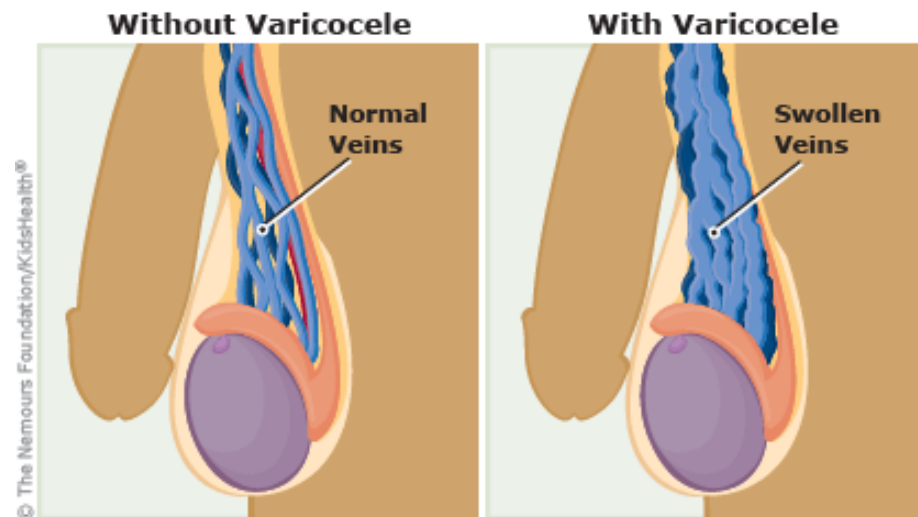
Circumcision - Complications

- Removing too much or too little foreskin
- Meatal Stenosis
- Penile Adhesions
 - Inner shaft skin adheres to the glans
 - Self limiting
 - Can be lysed in the office with use of topical anesthetic, but high risk of recurrence
- Penile Skin Bridge
 - Penile shaft skin will reattach to the glans
 - Will not go away
 - Small ones can be done in the office
 - Larger, thicker skin bridges need to go to the OR
- Trapped penis (cicatrix)



Varicocele

- Dilation of the pampiniform venous plexus and internal spermatic vein.
- Adolescents (15%)
- Typically on the Left side (90%)
 - Left renal vein has a higher pressure than the inferior vena cava
- Concerns of fertility due to association with abnormal testicular growth
 - 85% of adult males with uncorrected varicoceles are fertile



Varicocele - Diagnosis

- HPI
 - Typically noticed by patient, at time by provider during annual exam
 - Rarely painful
- Physical Exam
 - “Bag of Worms”
 - Prominent with standing and decreases when supine
 - Grade I – Palpable only with a Valsalva
 - Grade II – Palpable without any Valsalva maneuver
 - Grade III – Visible to the examiners eye
 - Testicular size should be noted



Varicocele - Diagnosis

- Imaging
 - If concerned with difference in testicular size then TUS is indicated
 - If Varicocele on the right testicle obtain a RUS
 - Rule out an intra-abdominal process such as a tumor compressing the right spermatic vein
- When to Refer
 - Difference in testicular size
 - Painful Varicocele
 - Greater than a grade 2 varicocele



Varicocele – Treatment

- Non – Surgical
 - Physical exams and TUS (every 6 months until end of puberty)
 - Check there is no more than 20% testicular volume difference and adequate testicular growth
 - Tighter fitted underwear can help
- Surgical - Varicocelectomy
 - Greater than 20% testicular volume difference
 - Painful varicocele
 - Inguinal vs Laparoscopic
 - No straddle activities for 2 weeks post op
 - Risk of recurrence, hydrocele formation, testicular atrophy



Scrotal Masses

- Rare
- Uncommon in newborns
 - Most likely teratomas
 - In children benign
 - Excision is generally curative
- Asymptomatic
- Discovered on routine physical exam



Scrotal Masses - Diagnosis

- HPI – none in younger patients. Adolescents may describe something hard in the testicles
- Physical exam
 - Firm nodule/mass on the testicle
 - Can be on the epididymis
 - Can be completely independent from the testicle



Scrotal Masses – Diagnosis

- Imaging – TUS
- Bloodwork
 - AFP
 - B-HCG
 - LDH
- Urology Referral



Testicular Self Examination

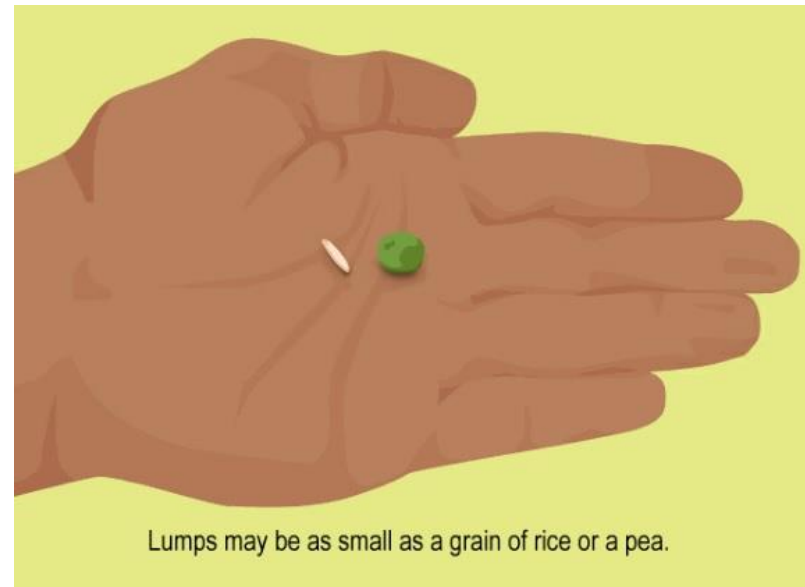
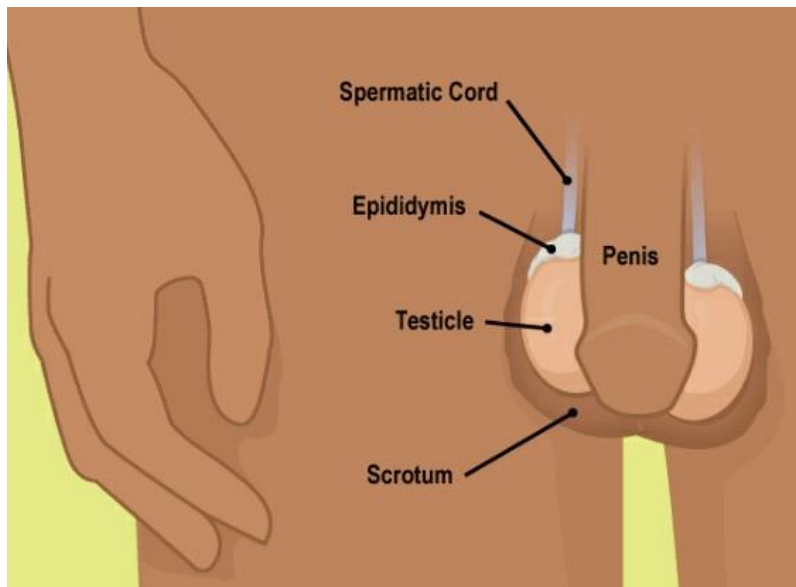
- Monthly
- Should start at 11/12 years old
- Helps patient become familiar with what is normal
 - Making it easier to tell if something is different in the future
- Hand out should be given detailing step by step technique



Testicular Self Examination

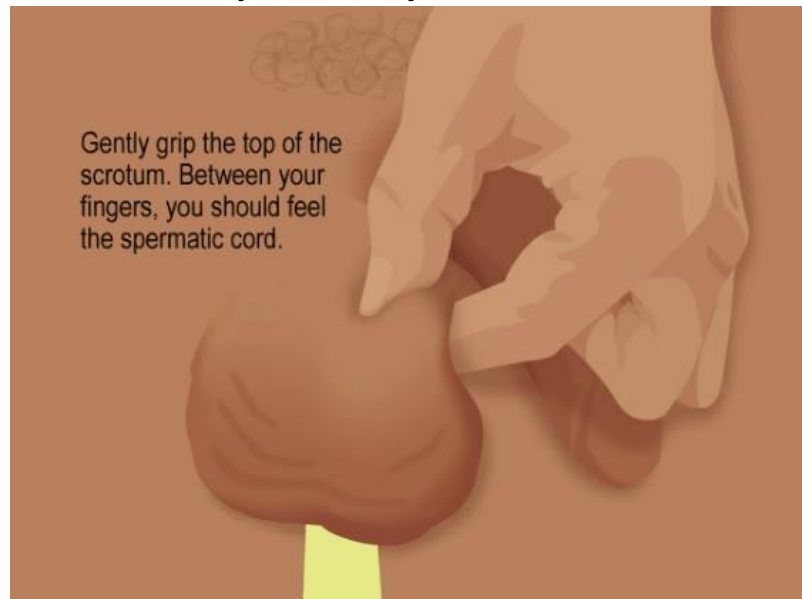
■ Step 1: Getting Started

- Choose the right time to do your exam. It's best to do it during or just after a hot shower or bath. The scrotum (skin that covers the testicles) is most relaxed then, which makes it easier to feel the testicles for lumps.
- Lumps may be as small as a piece of rice or a pea.



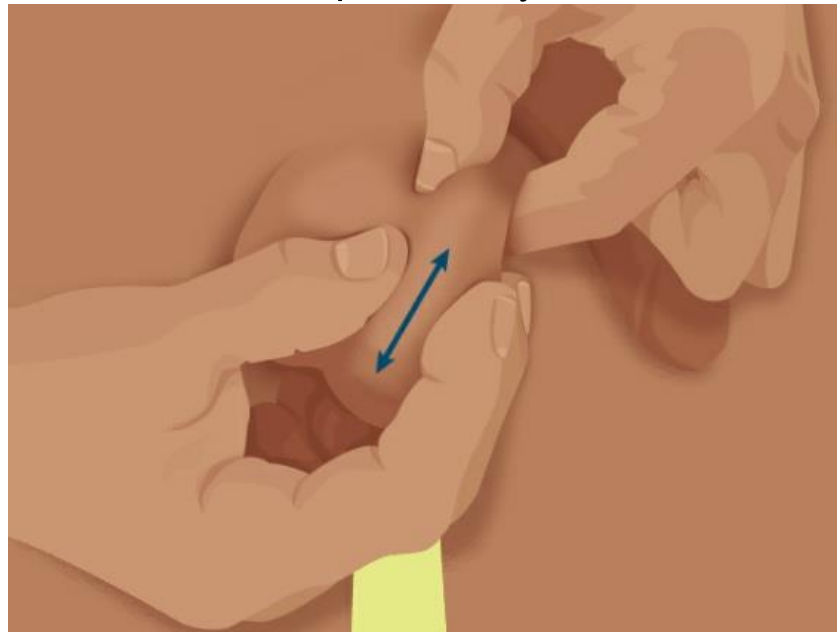
Testicular Self Examination

- Step 2: Hand Placement
 - Examine one testicle at a time.
 - Start by gently gripping the top of the scrotum, with your thumb on top and your fingers underneath. Pinch gently so that the testicle stays put and won't move during the exam.
 - Between your fingers, you should feel the spermatic cord. This connects the testicle to the rest of your body.



Testicular Self Examination

- Step 3: Feel for Lumps
 - With your free hand, glide your thumb and fingers along both sides of the testicle, from top to bottom. Feel for any lumps or bumps.
 - Then, glide your fingers over the front and back of the testicle.
 - On the back at the top, you should feel the epididymis, a tube that carries sperm. This is a normal lump and may feel tender to the touch.



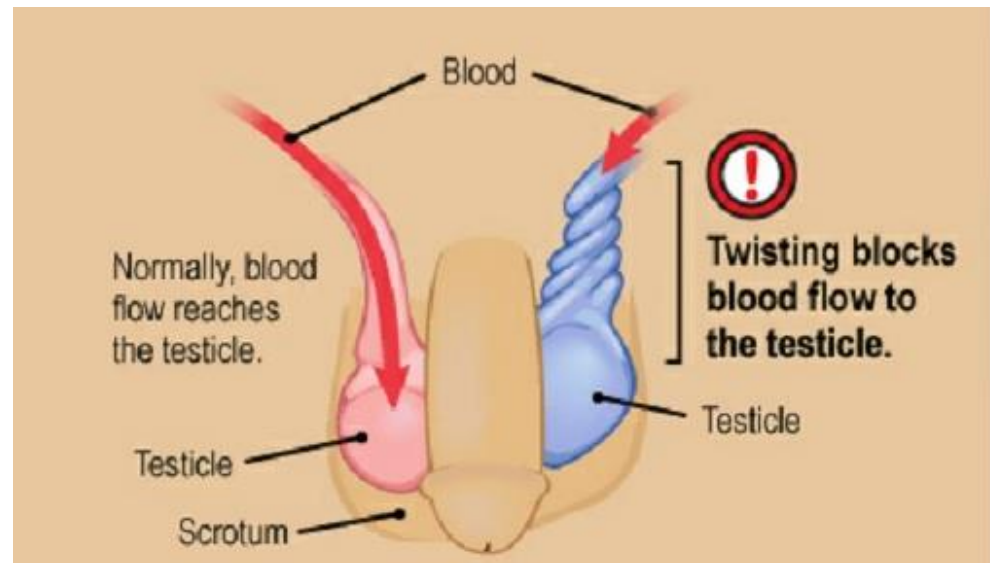
Urological Emergencies

- Testicular Torsion
- Torsed Appendage
- Epididymitis
 - Chemical
 - Bacterial
- Paraphimosis
- Testicular Rupture



Testicular Torsion

- Acute pain, scrotal swelling
- Mostly occurs in adolescents
- Associated with Nausea/Vomiting
- Testicular pain can radiate to the groin/abdomen
- Associated with Bell clapper's deformity



Testicular Torsion - Diagnosis

- Physical Exam
 - Patient uncomfortable/restless
 - Scrotal edema
 - High riding testicle, sometimes lays horizontal
 - Lack of cremasteric reflex
 - Abdominal pain
- UA – negative
- Imaging
 - TUS
 - Demonstrates lack of blood flow to the testicle



Testicular Torsion - Treatment

- Manual Detorsion
 - Does not replace surgery
 - May help relieve some ischemia
- Immediate Surgery
- Time Sensitive
 - After 4 to 6 hours from onset, the testicle can be saved 90% of the time
 - After 12 hours, this drops to 50%
 - After 24 hours, the testicle can be saved only 10% of the time.



Testicular Torsion - Treatment

- Scrotal exploration, detorsion and bilateral orchidopexy
- No straddling activity for two weeks postop



Epididymitis

- Accounts for 20% of acute scrotal pain
- Associated with Adolescents, <1% in prepubertal males
- Gradual onset of testicular pain
- Pain with movement

Epididymitis



Bacterial

- Patients usually sexually active
- Urethral discharge may be present
 - Thin and Watery – Chlamydia
 - Thick and creamy – *Neisseria gonorrhoea*



Chemical

- Associated with underlying voiding dysfunction



Epididymitis - Diagnosis

- Physical Examination
 - Physically Uncomfortable
 - Early presentation
 - Enlarged and tender epididymis
 - Able to distinguish pain to posterior aspect of testicle
 - Late presentation
 - Entire testicle enlarged and tender
 - Unable to distinguish between epididymis versus testicle
 - Difficult to distinguish from testicular torsion

Epididymitis – Diagnosis

- Imaging
 - TUS
- Urinalysis
 - Usually reveals leukocytes
 - Culture swab may reveal infectious agent

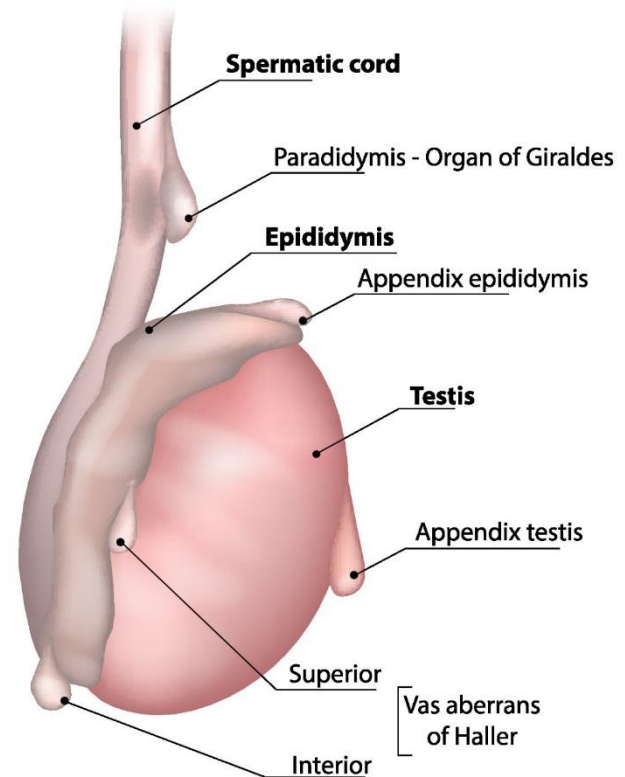
Epididymitis - Treatment

- NSAIDs for pain
- Treat the Bacterial infection
- If no bacterial infection then
 - Encourage frequent voiding
 - Encourage increased water intake
- Scrotal support
- Follow up with Pediatric Urology in 7-10 days

Torsed Appendage

- Usually gradual onset of testicular pain
- No associated with nausea/vomiting
- Can be as painful as a torsion
- Pain worse with movement

Torsion of Appendix Testis



Torsed Appendage - Diagnosis

- Physical Examination
 - Patient is uncomfortable
 - Ambulating with legs straddled
 - Scrotal swelling and tenderness
 - Associated with length of pain onset
 - Cremasteric reflex is present
 - “Blue Dot” sign can be present
- Imaging
 - TUS

Torsed Appendage - Treatment

- Rest
- NSAIDS
- Will improve over time



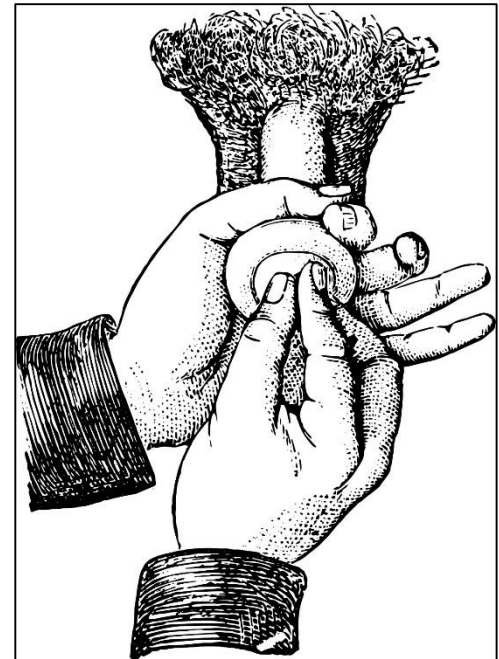Paraphimosis

- Constriction of the glans by the foreskin
- Lymphatics obstructed causing lymphedema to the glans
- Painful
- Emergency due to the ischemia caused to the glans



Paraphimosis - Treatment

- Sprinkle Sucralose/Mannitol
- Manual pressure to the glans with applied force to reduce foreskin
- May need a penile block versus sedation for this procedure
- Refer to Urology
 - Circumcision indicated after swelling has decreased



Testicular Rupture

- Associated with Blunt Trauma to the testicle
- Immediate swelling and pain that does not improve
- Requires Surgery



Female GU Concerns

- Labial Adhesions
- Urethral Prolapse



Labial Adhesions

- Labia minor adhered together
- Associated with low levels of estrogen
- Treatment options
 - Estrogen cream: twice daily for 4-6 weeks
 - Side effects: breast budding, pubic hair development
 - Refer to Pediatric Urology
 - Dense adhesions
 - Becomes symptomatic
 - UTIs, dribbling, chronic rash
 - Manual lysis of adhesions in office with topical anesthetic versus OR
 - Risk of recurrence



Urethral Prolapse

- Urethral mucosa extends beyond meatus
- Mostly seen in African American Females
- HPI
 - Blood spotting on underwear
- Physical exam
 - Patients presents with donut appearance
- Treatment
 - Steroid cream
 - Estrogen cream
 - Surgical reduction and excision if failed medical therapy



THANK YOU!



References

- McDougal, W. Scott, et al. *Campbell-Walsh Urology Eleventh Edition Review*. Elsevier, 2016.
- Baskin, L. S., Kogan, B. A., & Stock, J. A. (2019). *Handbook of pediatric urology*. Philadelphia, PA: Wolters Kluwer.
- <https://www.auanet.org/guidelines/cryptorchidism-guideline>
- Concodora, Charles W., et al. "Checklist Assessment Tool to Evaluate Suitability and Success of Neonatal Clamp Circumcision: A Prospective Study." *Journal of Pediatric Urology*, vol. 12, no. 4, 2016, doi:10.1016/j.jpuro.2016.05.028
- Lee, Chan Ho, and Sang Don Lee. "Effect of Topical Steroid (0.05% Clobetasol Propionate) Treatment in Children With Severe Phimosis." *Korean Journal of Urology*, vol. 54, no. 9, 2013, p. 624., doi:10.4111/kju.2013.54.9.624.
- Letendre, Julien, et al. "Topical Triamcinolone for Persistent Phimosis." *Journal of Urology*, vol. 182, no. 4S, 2009, pp. 1759–1764., doi:10.1016/j.juro.2009.03.016.
- Nascimento, Fabio J., et al. "Topical Betamethasone and Hyaluronidase in the Treatment of Phimosis in Boys: a Double-Blind, Randomized, Placebo-Controlled Trial." *International Braz j Urol*, vol. 37, no. 3, 2011, pp. 314–319., doi:10.1590/s1677-55382011000300004.
- Häggström, M (2014). "Medical gallery of Mikael Häggström 2014". *WikiJournal of Medicine* 1 (2). doi:10.15347/wjm/2014.008. ISSN 2002-4436. Creative Commons CC0 1.0 Universal Public Domain Dedication. Used with permission.
- "Circumcision Policy Statement." *Pediatrics*, vol. 130, no. 3, 2012, pp. 585–586., doi:10.1542/peds.2012-1989.
- "Information for providers counseling male patients and parents regarding male circumcision and the prevention of HIV infection, STIs, and other health outcomes." <https://stacks.cdc.gov/view/cdc/58456>
- (Sexology(New York) 1970;37(2): 50-53; Van Howe et al. J Eur Acad D Dermatol Venereol 2006 ; 20(9): 1046-54)
- https://www.researchgate.net/figure/The-most-frequent-locations-of-true-and-ectopic-undescended-testis_fig1_327915634



Contact Information

Kaity Colon-Sanchez, MPAS, PA-C

Nemours Children's Hospital

13535 Nemours Parkway

Orlando, FL 32827

Kaity.Sanchez@nemours.org

407-650-7260 (office)

407-687-3171 (mobile)

