

Introduction to Point-of-Care Ultrasound

Mike Breunig, PA-C

Disclosures:

None

Intro to POCUS

Learning Objectives

- Explain the basics of ultrasound physics.
- Summarize scope and indications for Point-of-Care Ultrasound (POCUS) of the heart and lungs.
- Interpret POCUS images of the heart and lungs.
- Contrast evidence for standard of care with POCUS.
- Discuss the effect POCUS has on diagnostic evaluation, prognostication, and treatment of acute cardiopulmonary pathology.



Case Based
(3 Real Patients)

POCUS Basics

Definition

- A goal directed, bedside ultrasound exam performed by a clinician used to answer a specific diagnostic question.
 - Extension of our physical exam
- Uses:

Heart	Vascular access	Cardiac arrest
Lungs	Procedural guidance	Aorta
Kidneys	Ocular	Gallbladder
DVT	Skin & Soft Tissue	Nerve blocks
MSK	Respiratory failure	Appendicitis
Hypotension	Trauma	Small bowel obstruction
Pregnancy	Bladder	Genitourinary

POCUS Basics

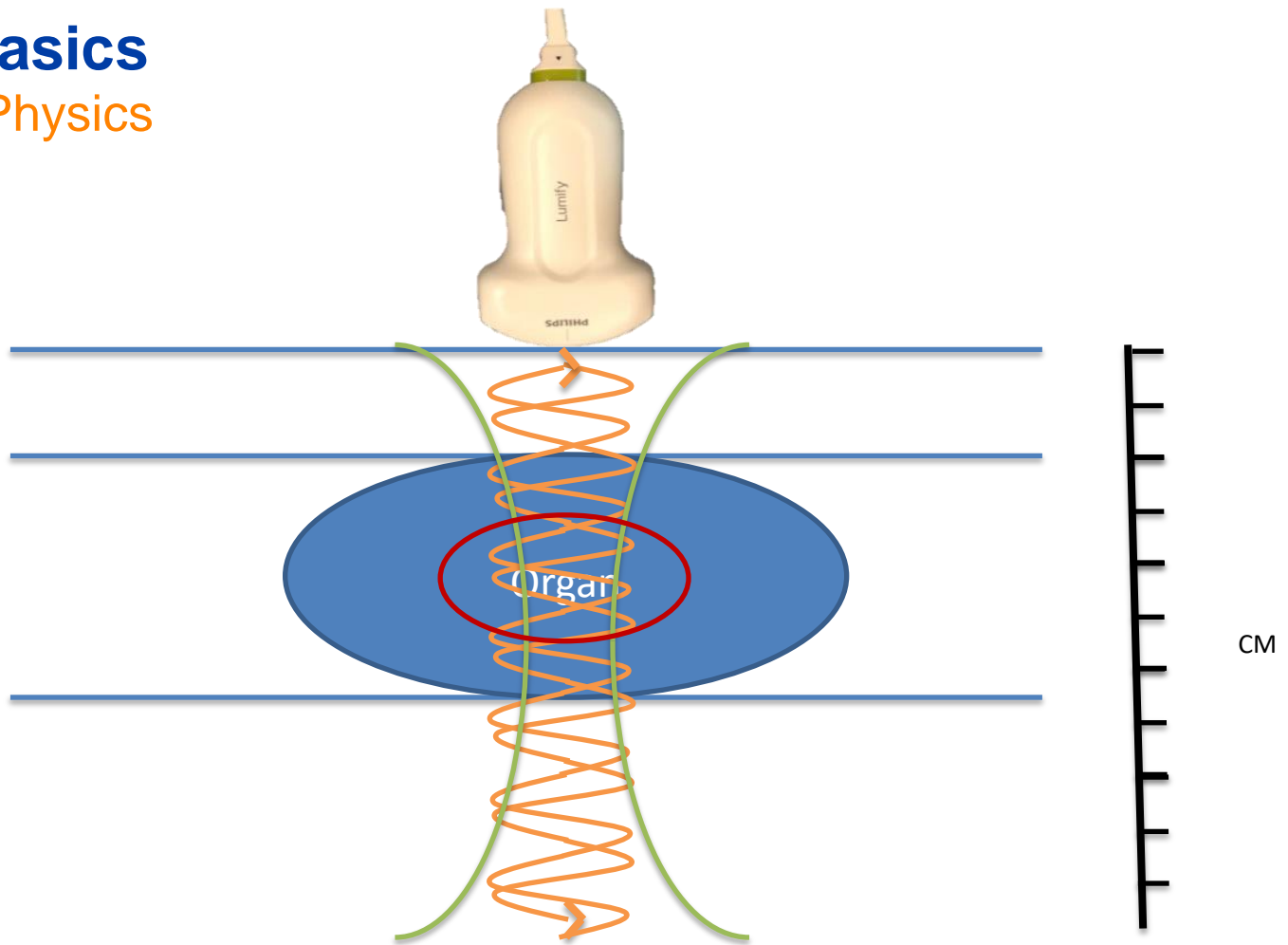
Definition

- A goal directed, bedside ultrasound exam performed by a clinician used to answer a specific diagnostic question.
 - Extension of our physical exam
- Uses:

Heart	Vascular access	Cardiac arrest
Lungs	Procedural guidance	Aorta
Kidneys	Ocular	Gallbladder
DVT	Skin & Soft Tissue	Nerve blocks
MSK	Respiratory failure	Appendicitis
Hypotension	Trauma	Small bowel obstruction
Pregnancy	Bladder	Genitourinary

POCUS Basics

Ultrasound Physics



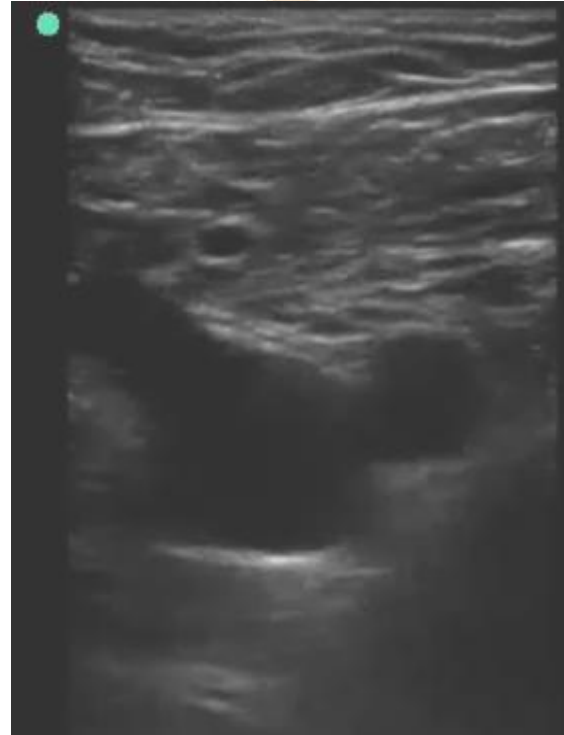
POCUS Basics

Gray Scale

Black (anechoic) = Fluid

White (hyperechoic) = Strong reflectors (pleura, bone, fascia, etc).

Gray (isoechoic) = organs, tissues.

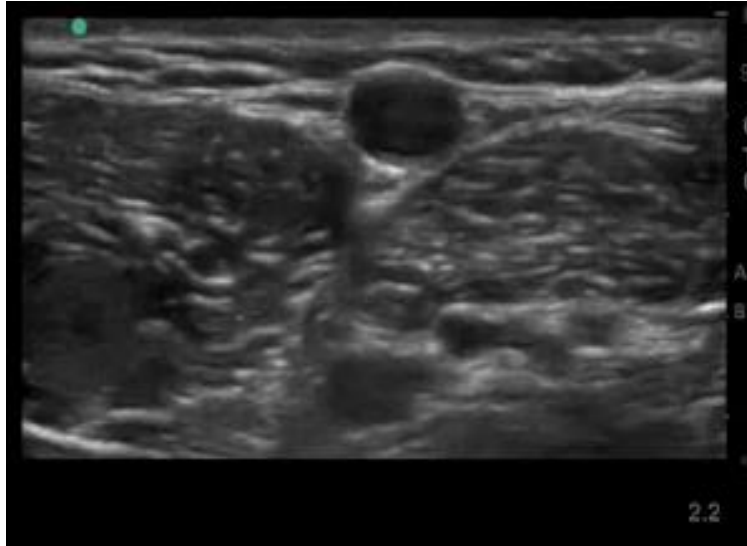


POCUS Basics

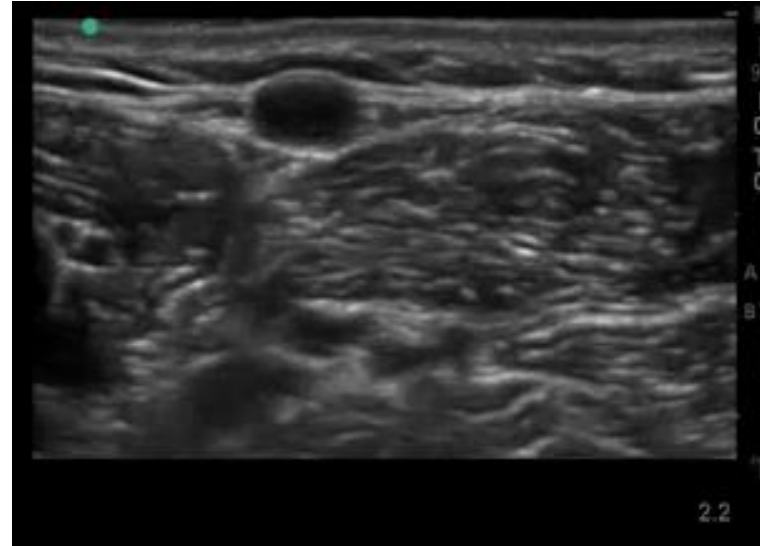
Gain

- Amplitude of the ultrasound waves.

Down
Gain

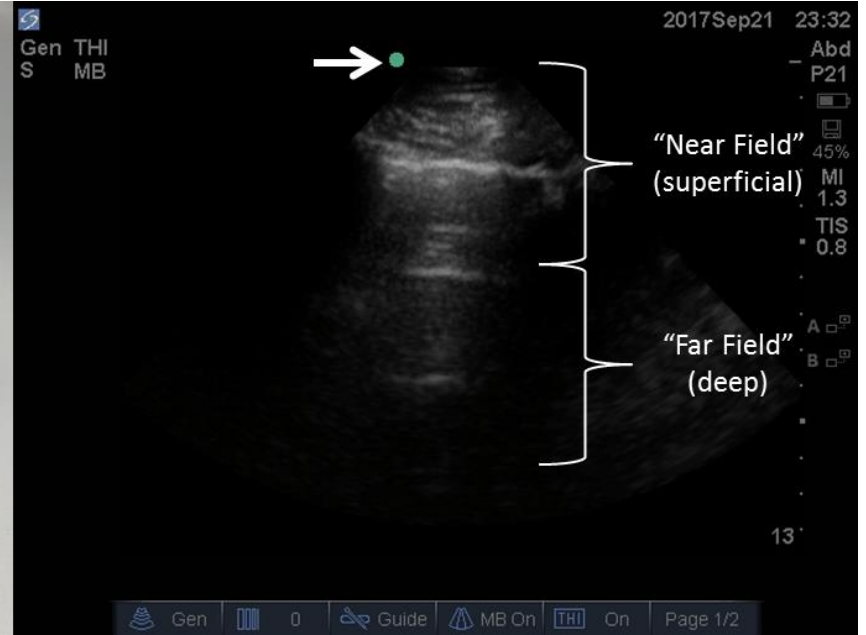


Up
Gain



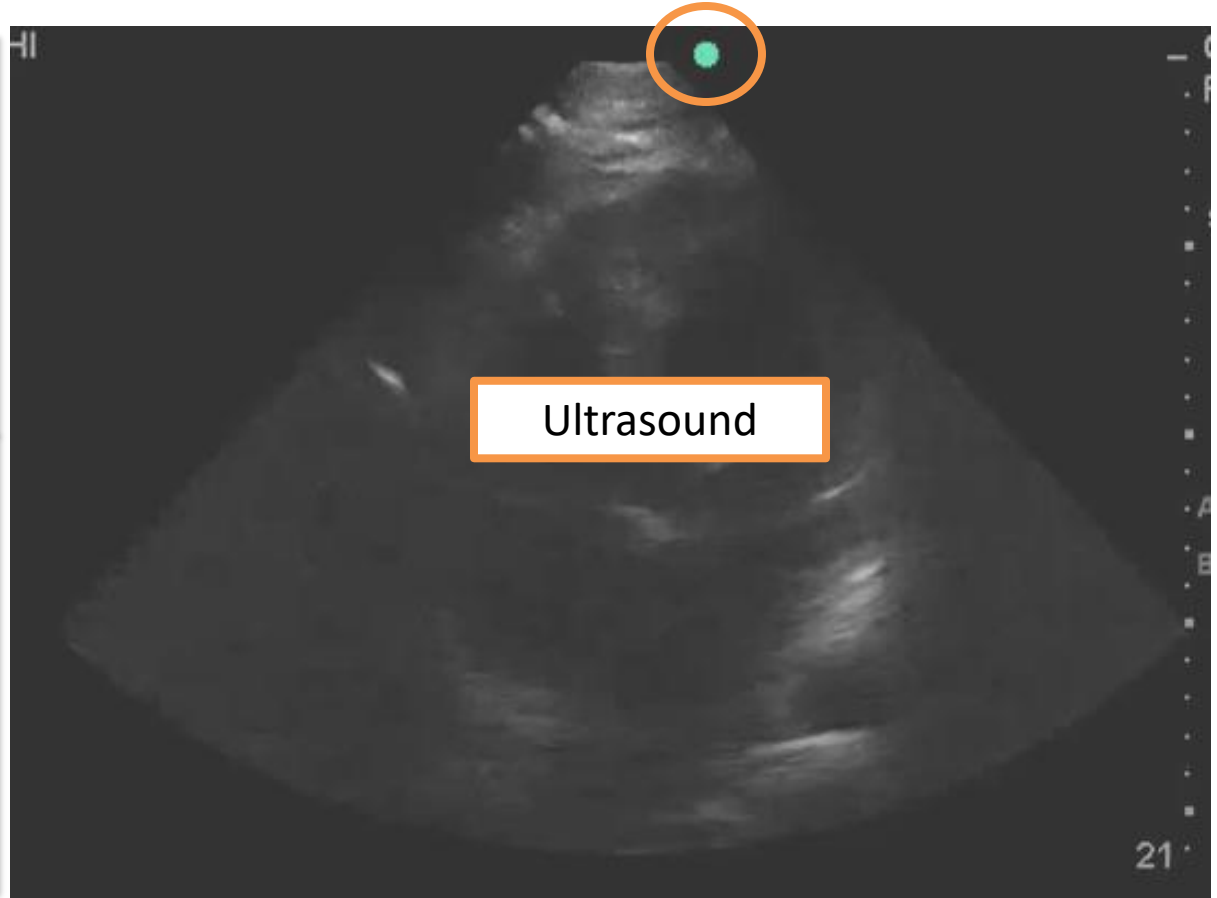
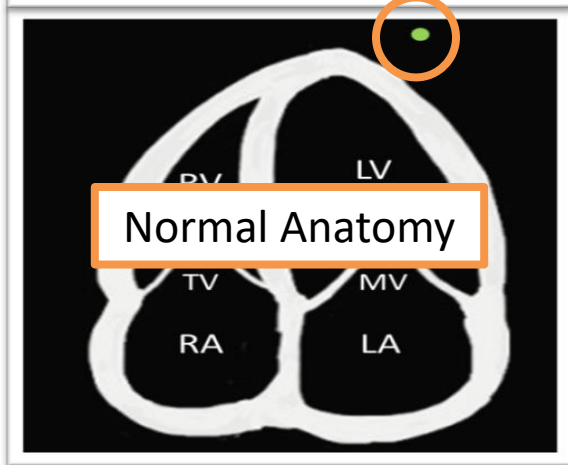
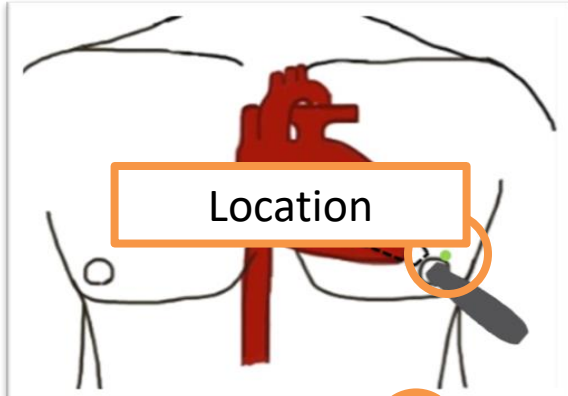
POCUS Basics

Orientation



POCUS Basics

Orientation



Case 1

HPI

- A 78 year-old gentleman presents to the emergency department for evaluation shortness of breath, progressing over 3 – 4 days.
- He endorses cough, but denies sputum production. Denies fever or rigors. Denies hemoptysis.

Case 1

History

- Past Medical / Surgical History:
 - COPD
 - Hypertension
 - Obesity
- Social History:
 - 60 pack year history of smoking
- Family History:
 - Father – Lung cancer

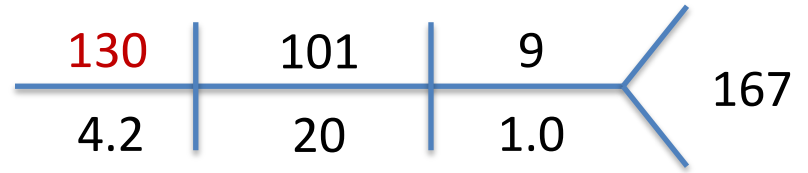
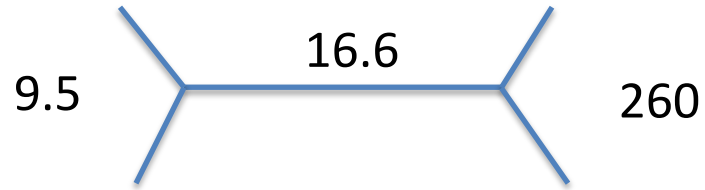
Case 1

Objective Findings

- Vital Signs:
 - HR 92, BP 156/52, SpO2 84% on room air, RR 28, Tmax 37.0 Celsius.
- Physical Exam:
 - Mild distress. Diffuse wheezing throughout all lung fields.
 - Body habitus impairs JVD assessment. 2+ pitting edema of the legs, which he states is “chronic”.

Case 1

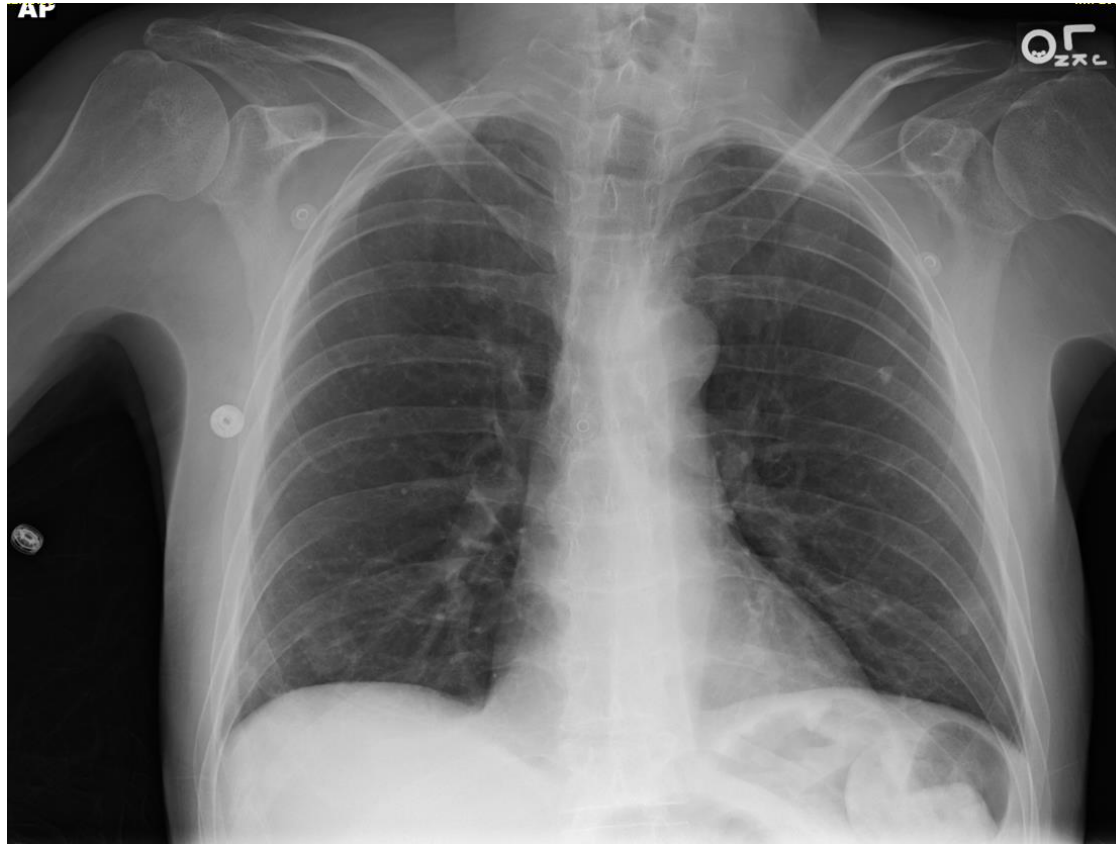
Labs



- Lactate 1.7

Case 1

Chest X-ray



Case 1

ED Course

- Presumptive Diagnosis: Acute COPD Exacerbation.
- Treatment:
 - Ipratropium/albuterol nebulizers
 - Prednisone
 - Levofloxacin
- Admitted to the hospital.

Case 1

Reflection Question

You admit the patient to the hospital, based on the information provided, what is your next step in caring for this patient?

- a) Continue treatment for COPD exacerbation.
- b) Obtain CTA chest to rule out PE, given normal chest x-ray.
- c) Obtain an influenza swab and start empiric Oseltamivir.
- d) Complete a POCUS examination of the heart and lungs to assist with evaluation.

Case 1

Reflection Question

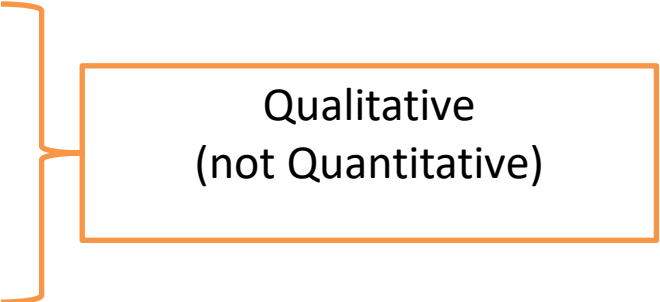
You admit the patient to the hospital, based on the information provided, what is your next step in caring for this patient?

- a) Continue treatment for COPD exacerbation.
- b) Obtain CTA chest to rule out PE, given normal chest x-ray.
- c) Obtain an influenza swab and start empiric Oseltamivir.
- d) Complete a POCUS examination of the heart and lungs to assist with evaluation.**

Focused Cardiac Ultrasound

Introduction

- Scope:
 - LV size / systolic function
 - RV size / systolic function
 - IVC size and respiratory variation
 - Pericardial effusions / Cardiac Tamponade
- Indications:
 - Hypotension
 - Respiratory Failure
 - Intravascular volume assessment



Qualitative
(not Quantitative)

Focused Cardiac Ultrasound

Cardinal Views

- Parasternal Long Axis (PLAX)
- Parasternal Short Axis (PSAX)
- Apical 4 Chamber (A4C)
- Subcostal 4 Chamber (S4C)
- Inferior Vena Cava (IVC)

Focused Cardiac Ultrasound

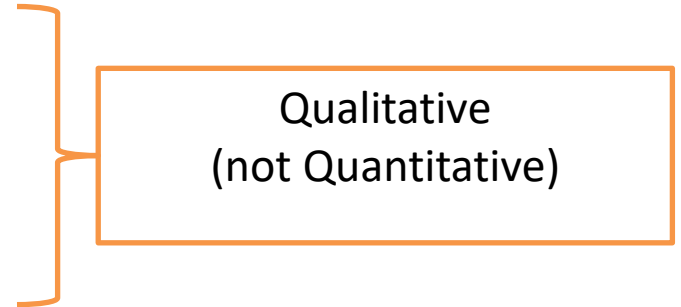
Cardinal Views

- **Parasternal Long Axis (PLAX)**
- **Parasternal Short Axis (PSAX)**
- Apical 4 Chamber (A4C)
- Subcostal 4 Chamber (S4C)
- **Inferior Vena Cava (IVC)**

Focused Cardiac Ultrasound

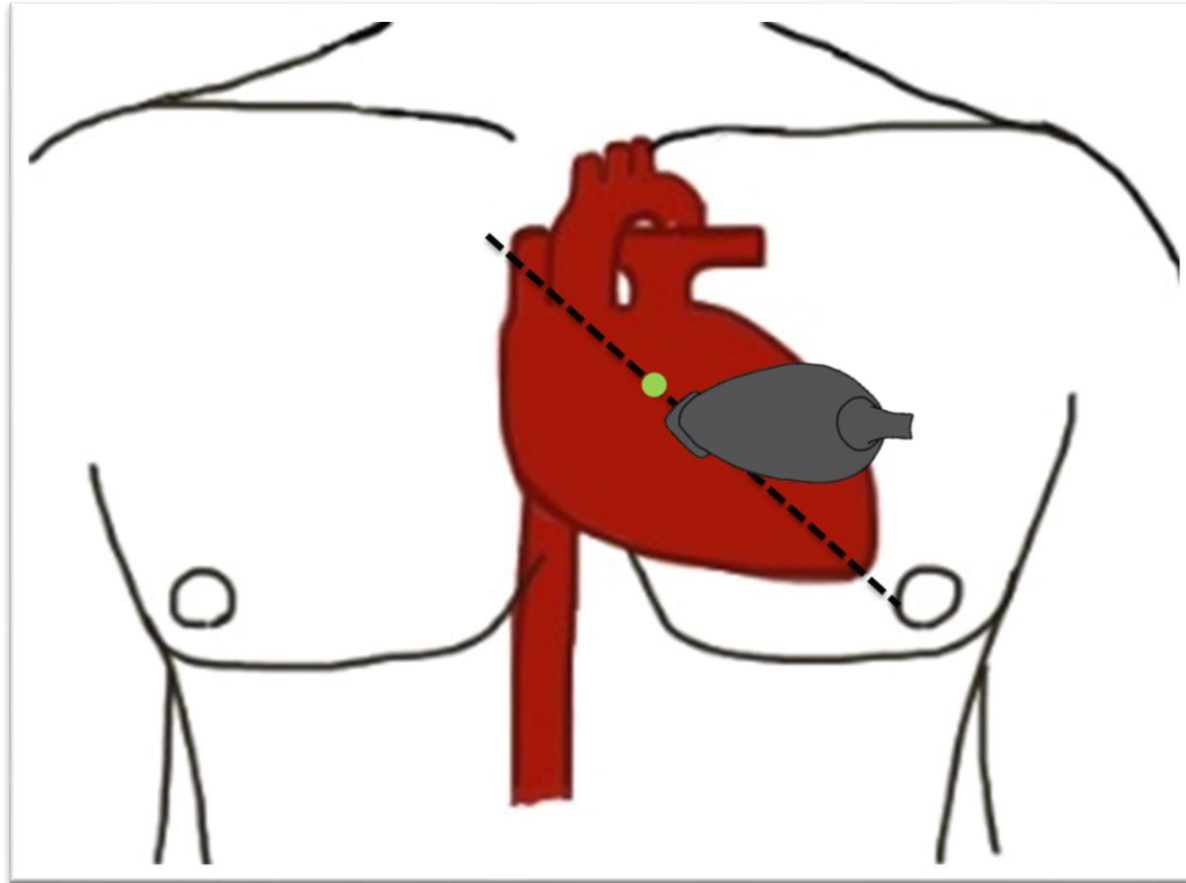
Cardinal Views

- Qualitative assessment of Left Ventricular Systolic Function
 - 1) Endocardial excursion
 - 2) Myocardial thickening
 - 3) E point septal separation (EPSS)
- LV systolic function interpretation
 - Hyperdynamic
 - Normal
 - Reduced / Severely reduced



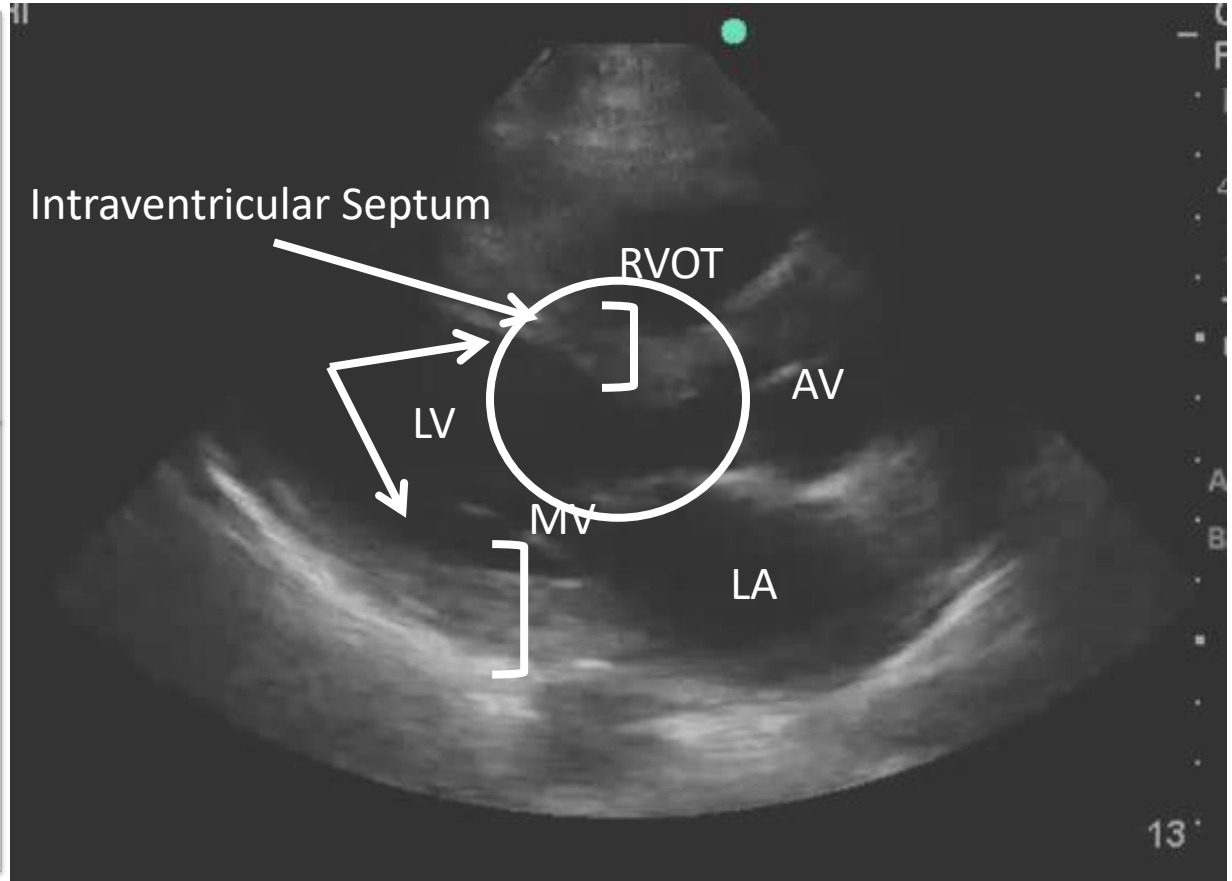
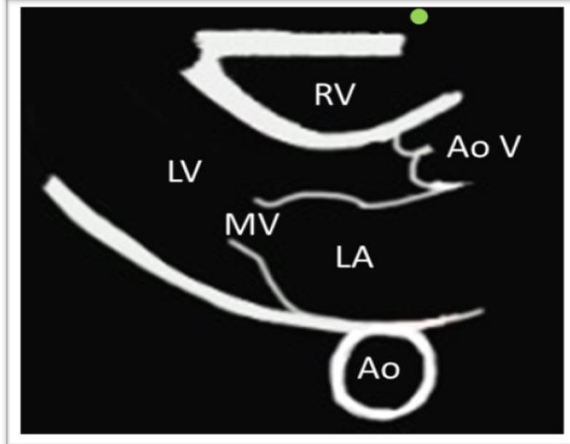
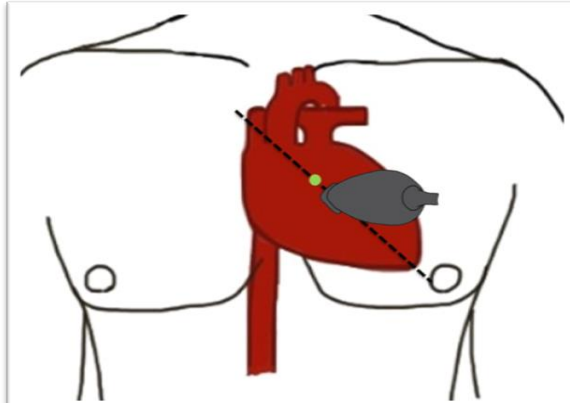
Focused Cardiac Ultrasound

Parasternal Long Axis (PLAX)



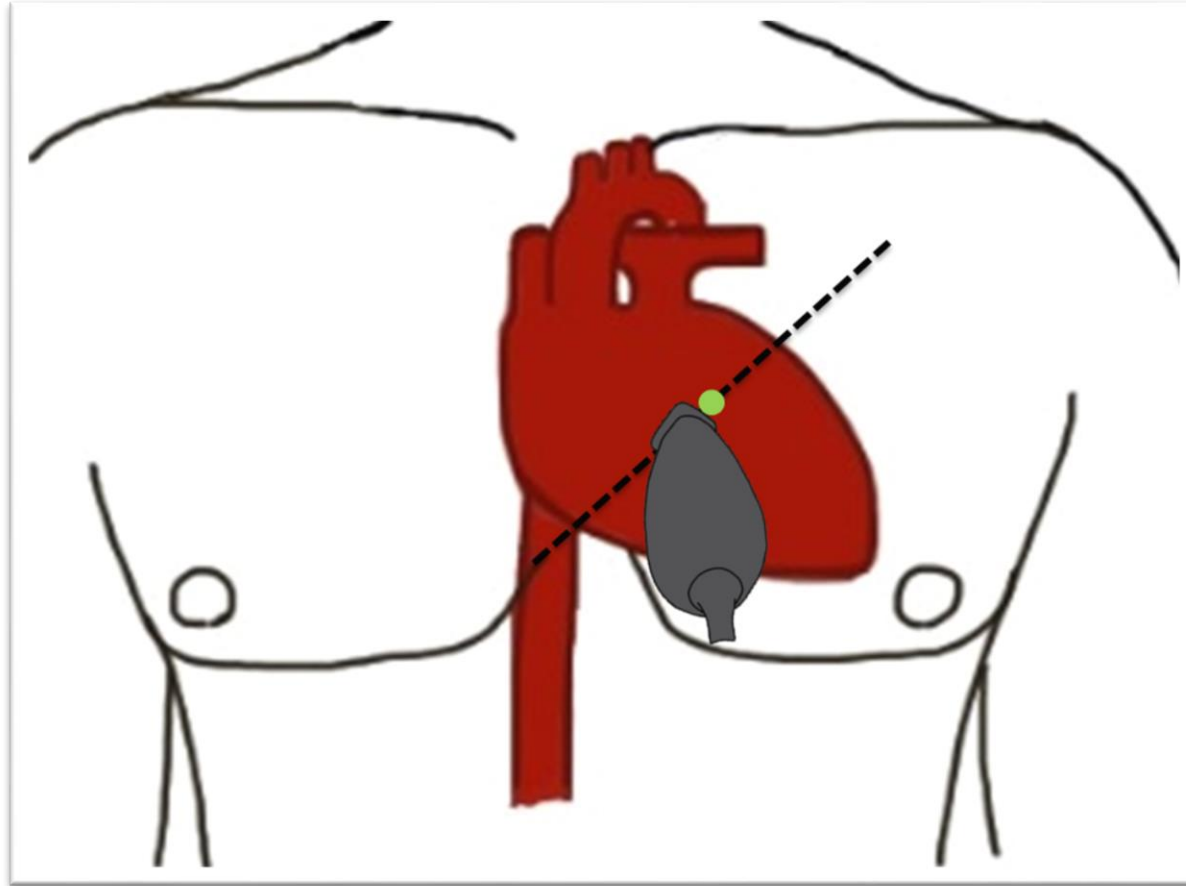
Focused Cardiac Ultrasound

Parasternal Long Axis (PLAX)



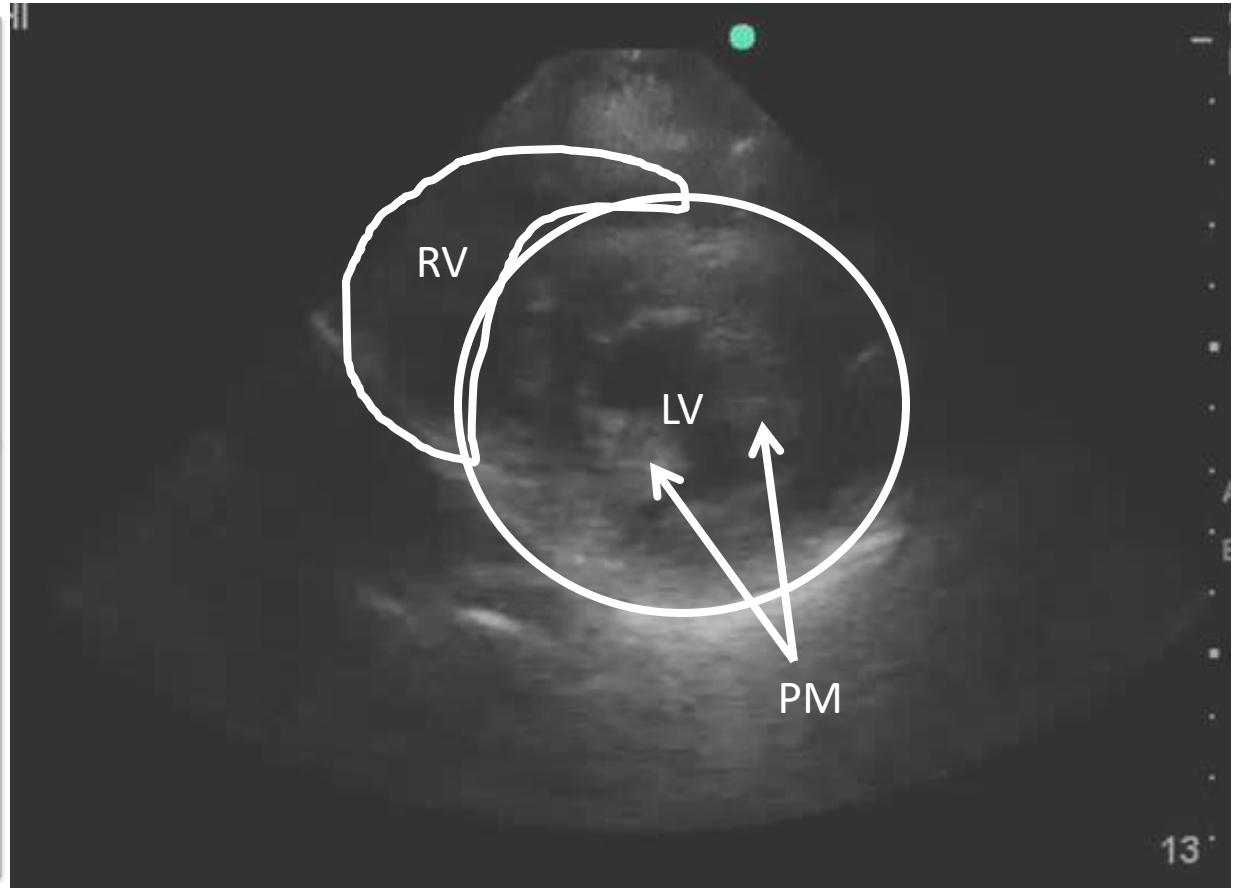
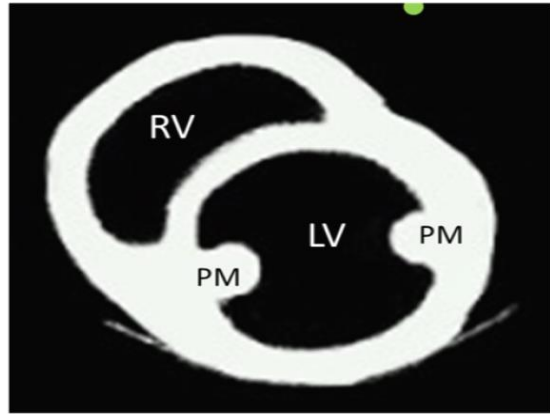
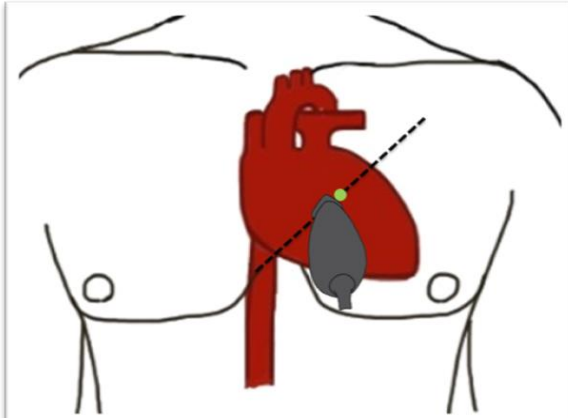
Focused Cardiac Ultrasound

Parasternal Short Axis (PSAX)



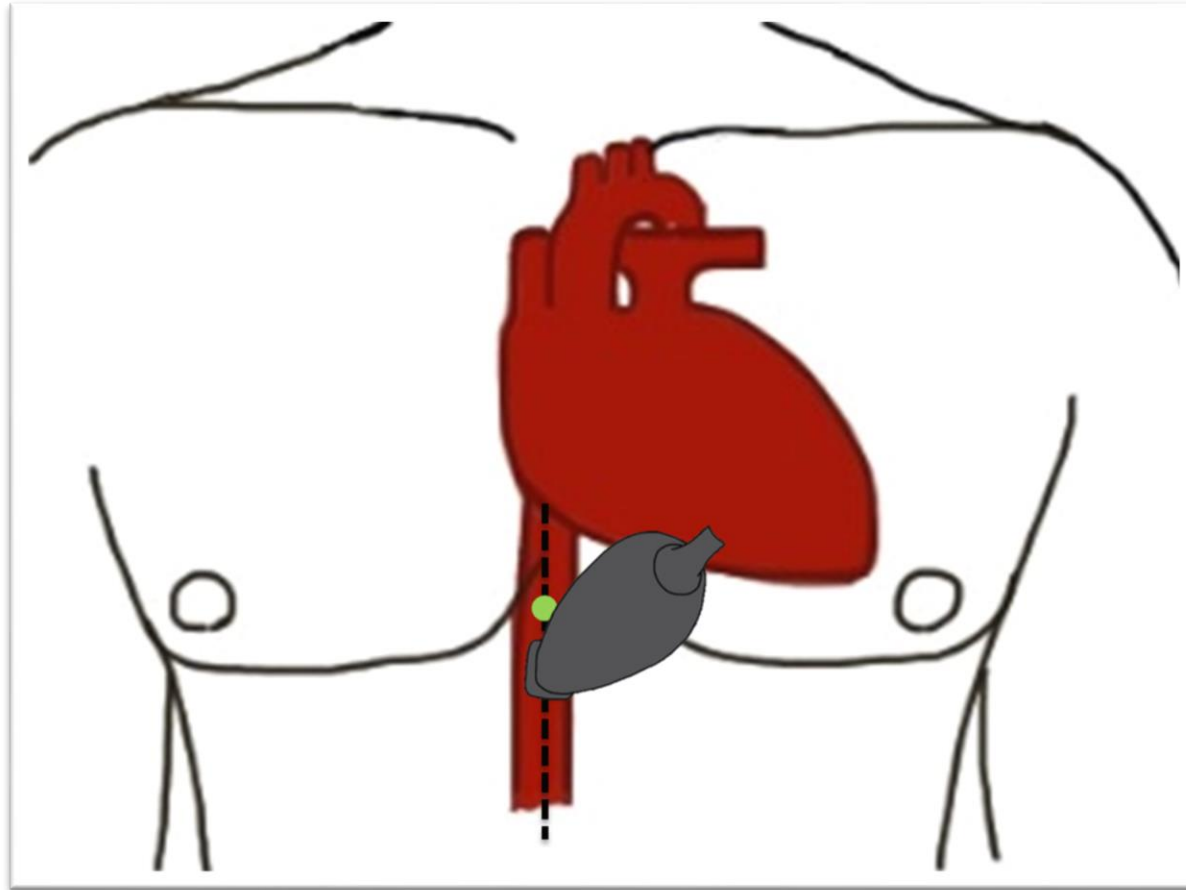
Focused Cardiac Ultrasound

Parasternal Short Axis (PSAX)



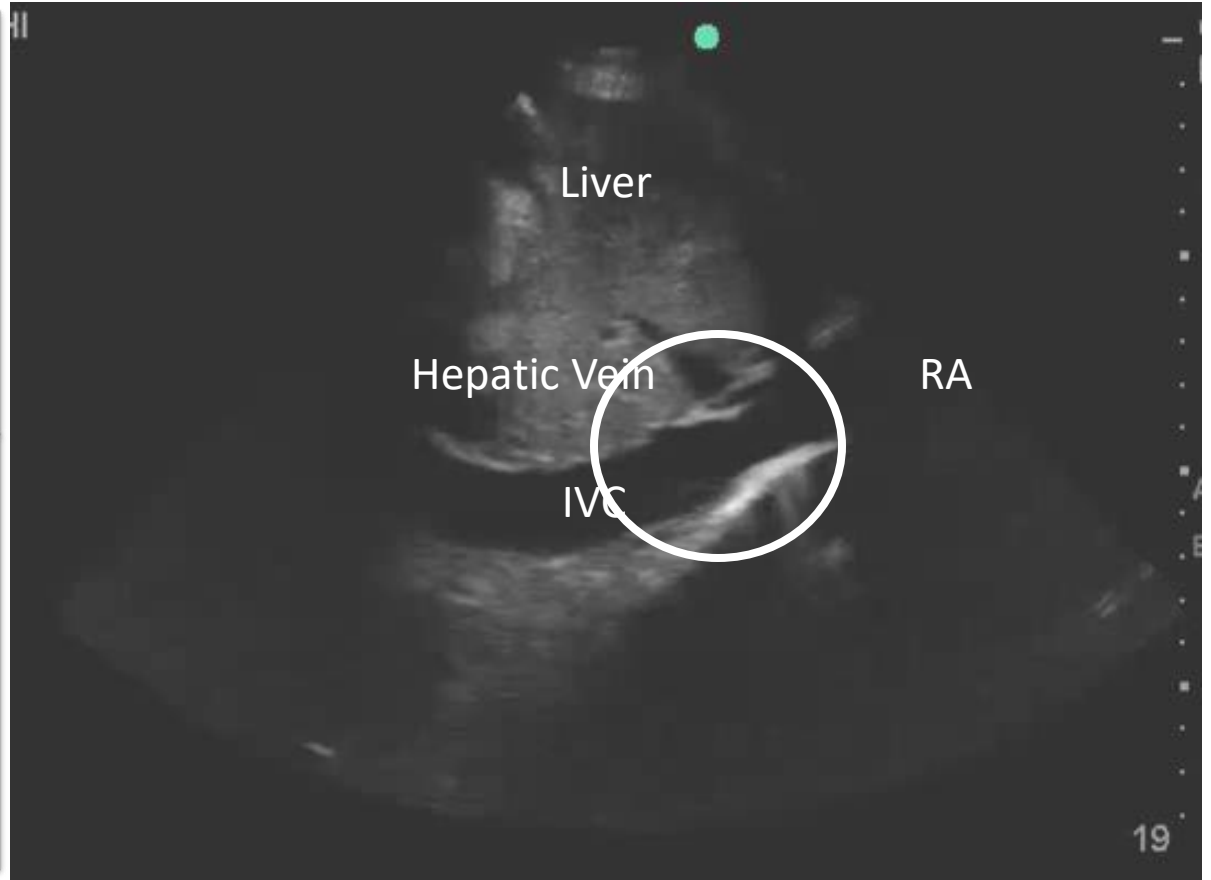
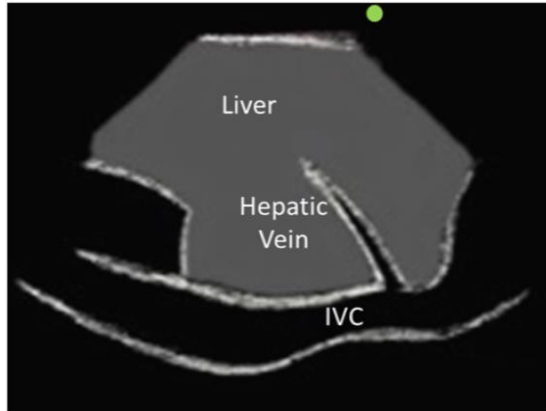
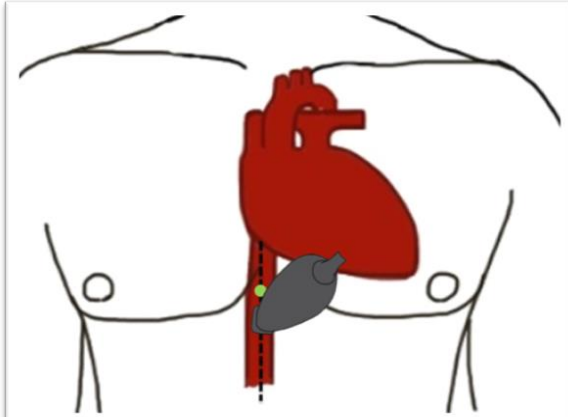
Focused Cardiac Ultrasound

Inferior Vena Cava (IVC)



Focused Cardiac Ultrasound

Inferior Vena Cava (IVC)



Focused Cardiac Ultrasound

IVC Interpretation

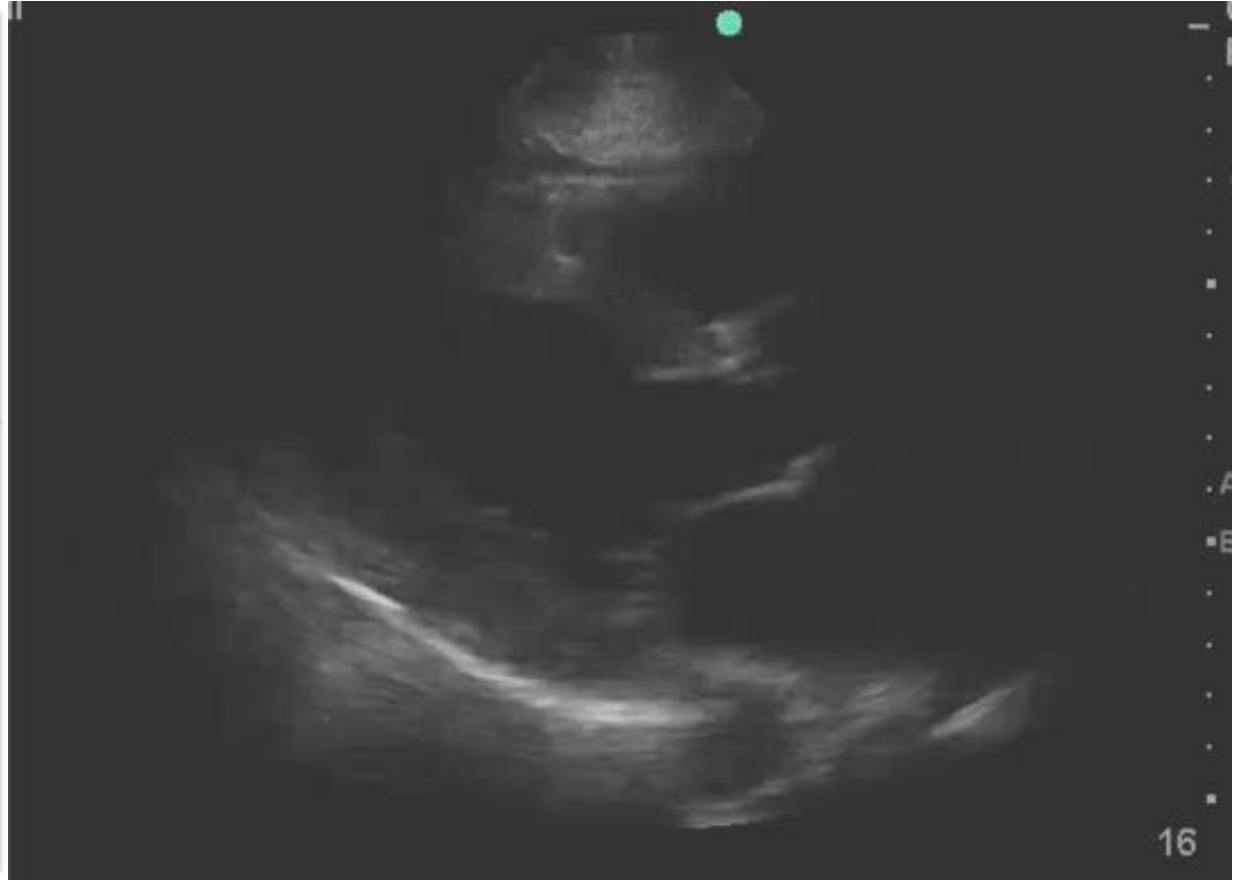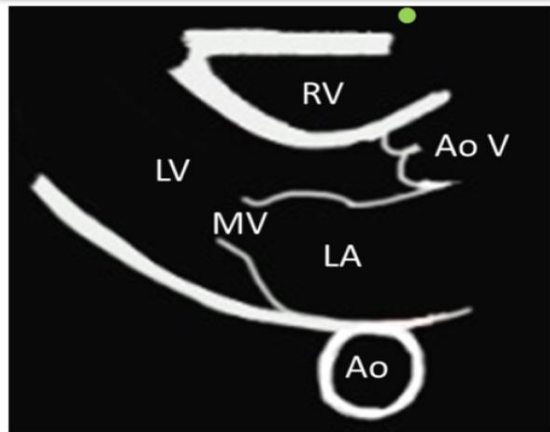
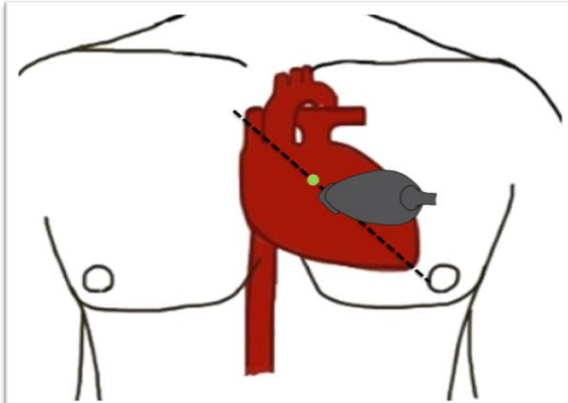
- IVC is a surrogate marker for RA pressure / CVP.

IVC Findings	CVP	
IVC < 2.1 cm, with > 50% collapse	3 (range 0 – 5)	Probable Hypovolemia
IVC < 2.1 cm, with < 50% collapse IVC > 2.1 cm, with > 50% collapse	8 (range 5 – 10)	
IVC > 2.1 cm, with < 50% collapse	15 (range 10 – 20)	*Possible Hypervolemia

- In conjunction with LV and RV size/function, can help determine intravascular volume status.

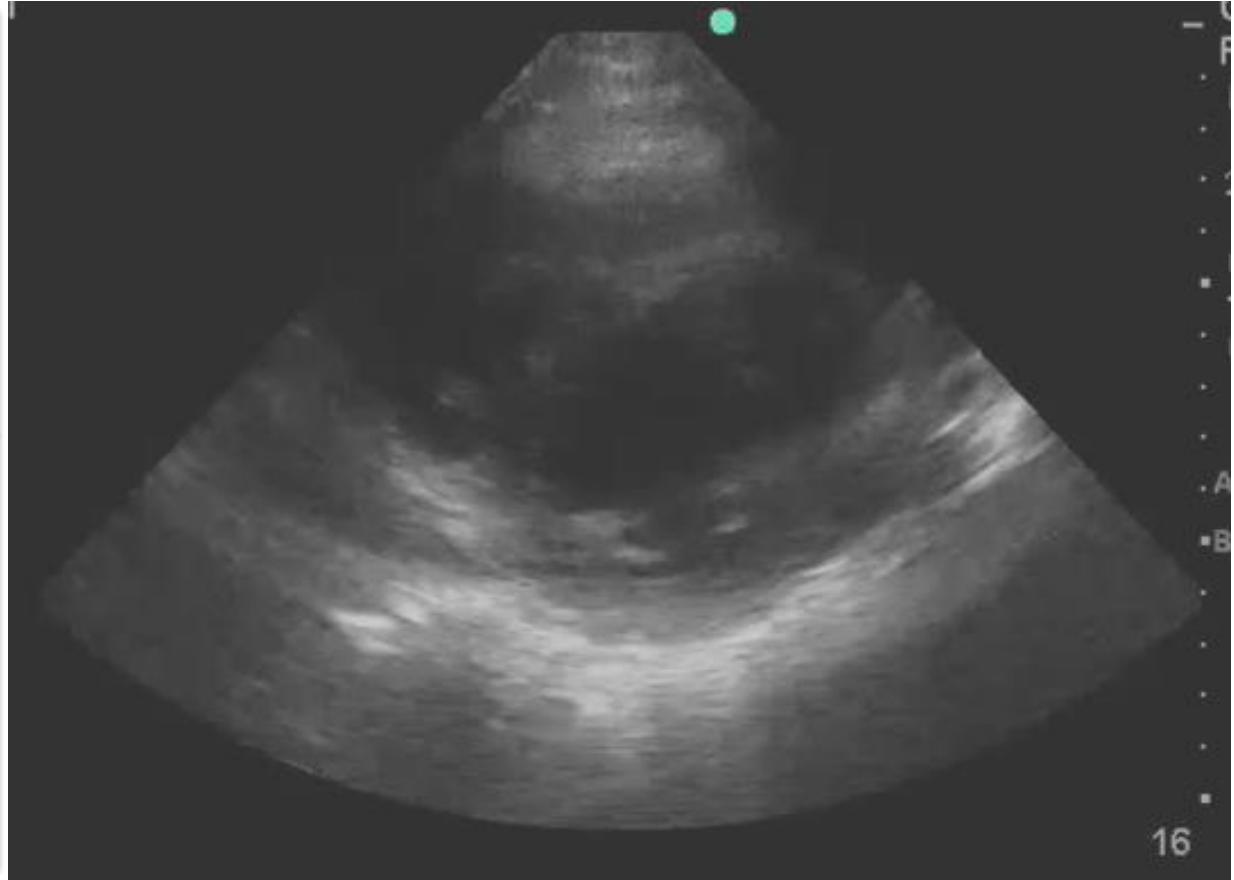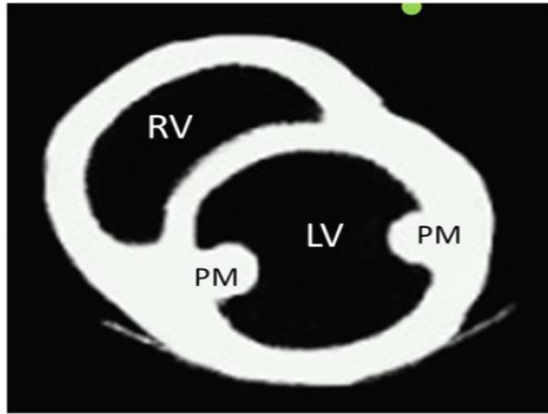
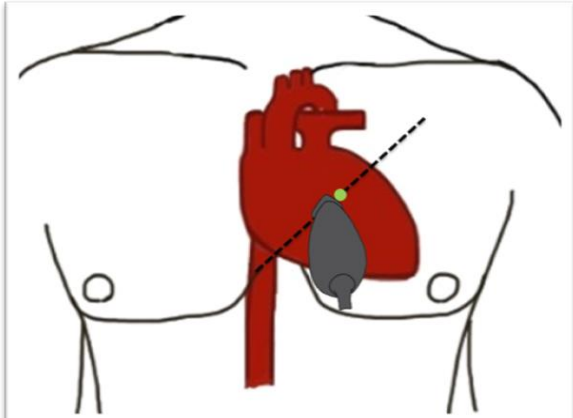
Case 1

Parasternal Long Axis (PLAX)



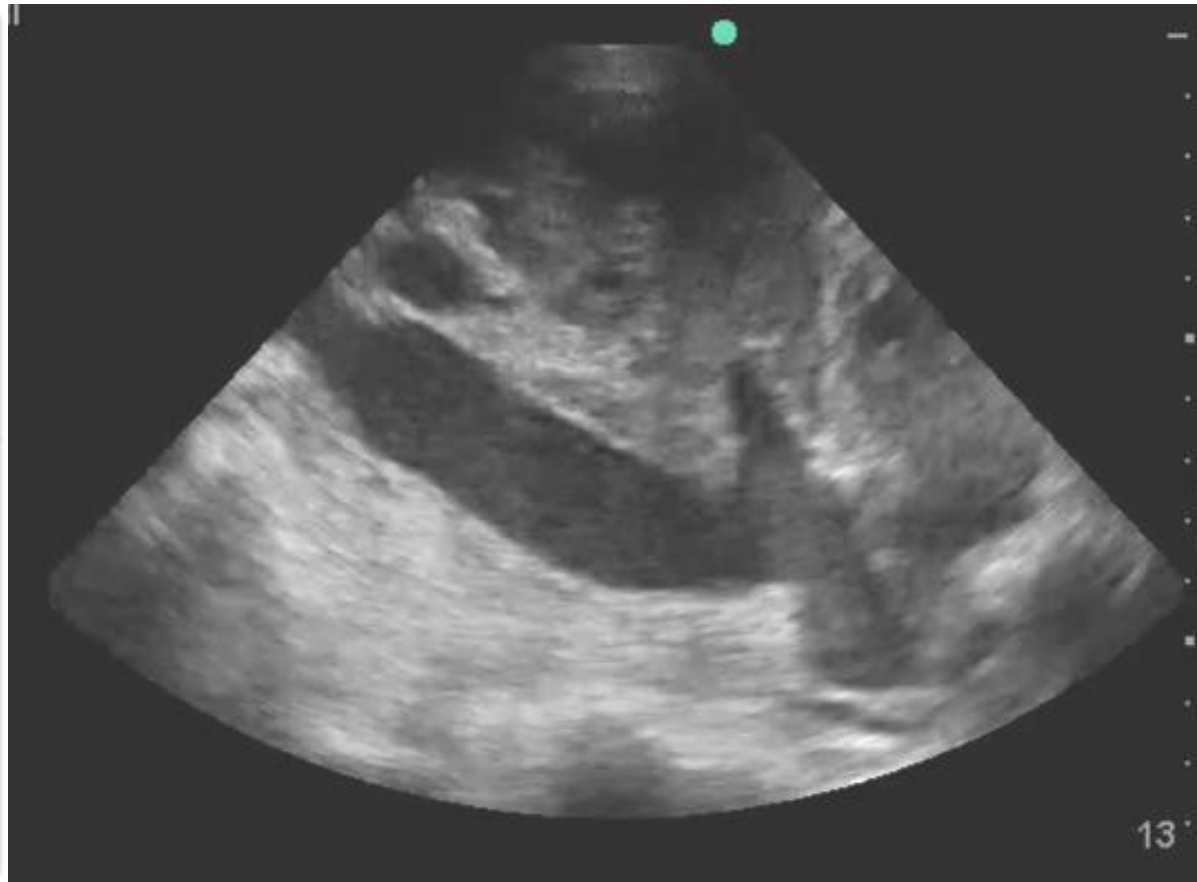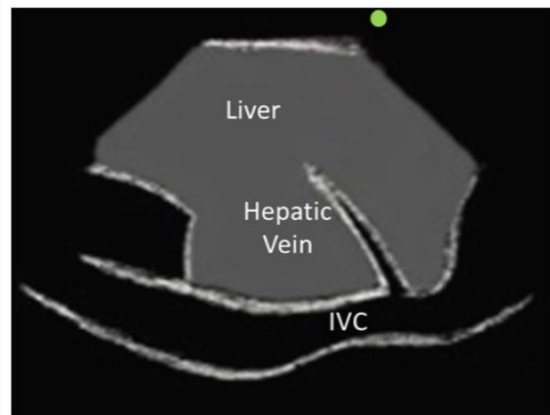
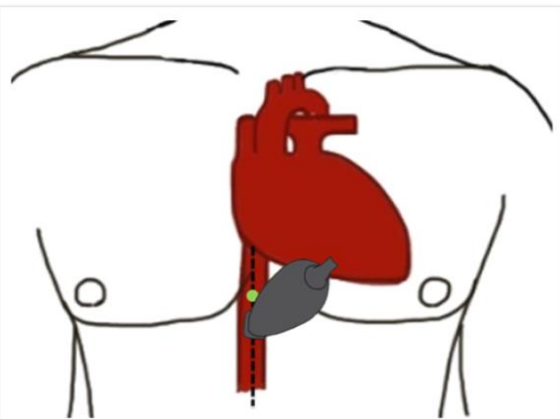
Case 1

Parasternal Short Axis (PSAX)



Case 1

Inferior Vena Cava (IVC)



Case 1

Reflection Question

Based on the FoCUS obtained, what is the patient's qualitative LV function?

- a) Hyperdynamic
- b) Normal
- c) Reduced

Case 1

Reflection Question

Based on the FoCUS obtained, what is the patient's qualitative LV function?

- a) Hyperdynamic
- b) Normal
- c) Reduced**

Focused Cardiac Ultrasound

Accuracy of Non-Cardiologists

- Cardiologist vs Non-Cardiologists assessment of LV function
 - Quantitative Assessment: $K = 0.75 - 0.84$
 - Qualitative Assessment: 82 – 100%

- Moore CL, Rose GA, Tayal VS, et al. Determination of Left Ventricular Function by Emergency Physician Echocardiography of Hypotensive Patients. *Acad Emerg Med.* 2002;9:186-193.
- Secko MA, Lazar JM, Saliccioli LA, Stone MB. Can Junior Emergency Physicians Use E-Point Septal Separation to Accurately Estimate Left Ventricular Function in Acutely Dyspneic Patients? *Acad Emerg Med.* 2011;18:1223-1226.
- Melamed R, Sprenkel MD, Ulstad VK, Herzog CA, Leatherman JW. Assessment of Left Ventricular Function by Intensivists Using Hand-Held Echocardiography. *CHEST.* 2009;135:1416-1420.
- Lemola K, Yamoda E, Jegasla D, Keber RE. A Hand-Carried Personal Ultrasound Device for Rapid Evaluation of Left Ventricular Function: Use After Limited Echo Training. *Echocardiography.* 2003;4(20):309-312.

Lung Ultrasound

Introduction

- Scope:
 - Pulmonary edema
 - Consolidation/Pneumonia
 - Pleural effusions
 - Pneumothorax
 - PE, Asthma, COPD (in the absence of other findings)
- Indications:
 - Hypoxia / Dyspnea.
 - Cough
 - Assessing volume status / Fluid resuscitation.

Lung Ultrasound

Introduction

Relevance of Lung Ultrasound in the Diagnosis of Acute Respiratory Failure*

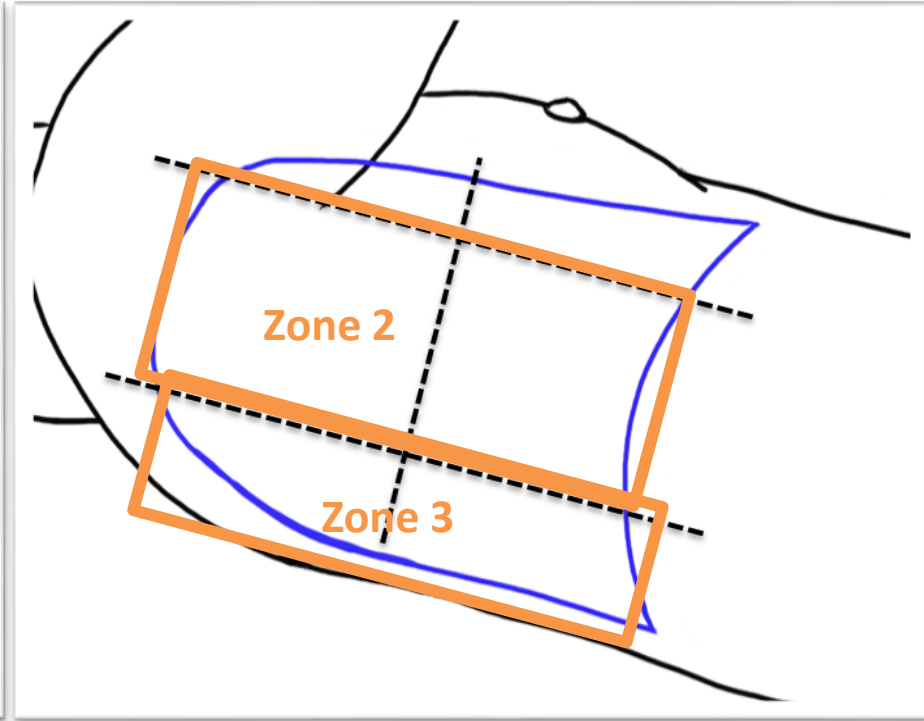
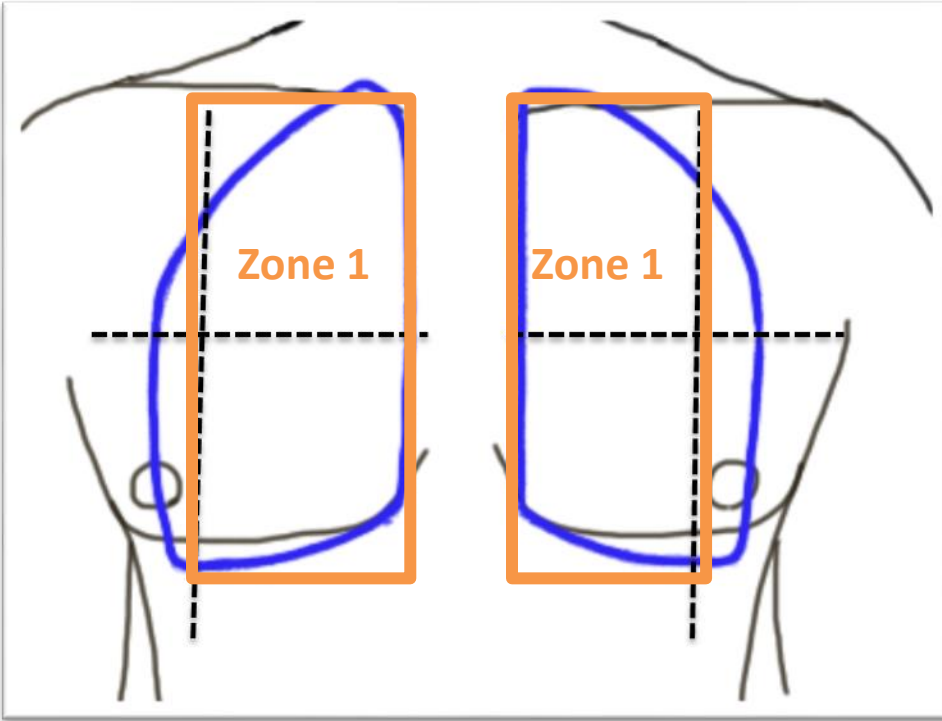
The BLUE Protocol

Daniel A. Lichtenstein, MD, FCCP; and Gilbert A. Mezière, MD

- Lung ultrasound provided the correct diagnosis in **90.5%** of cases.

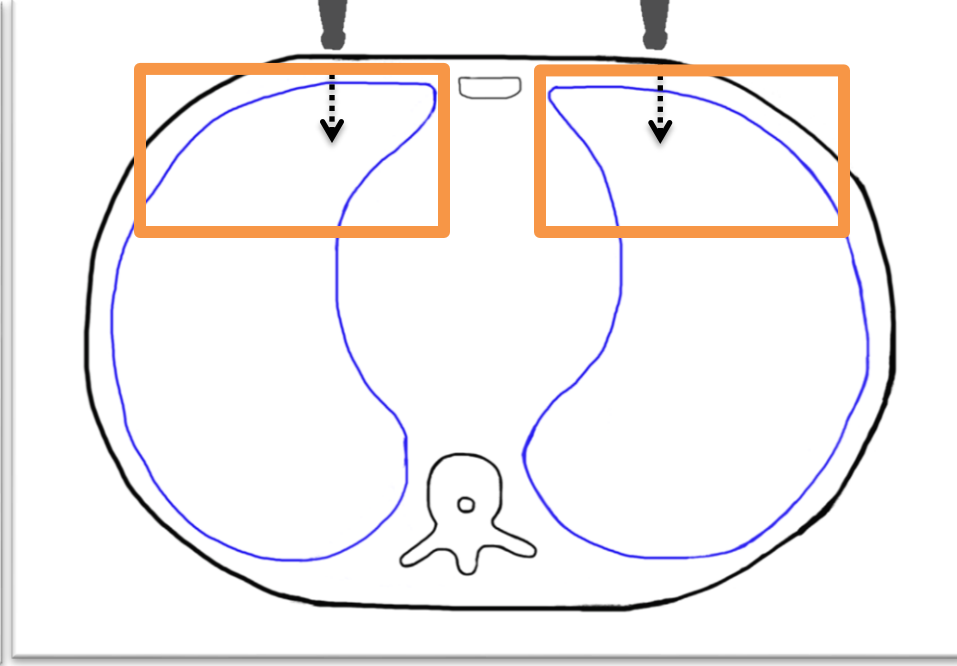
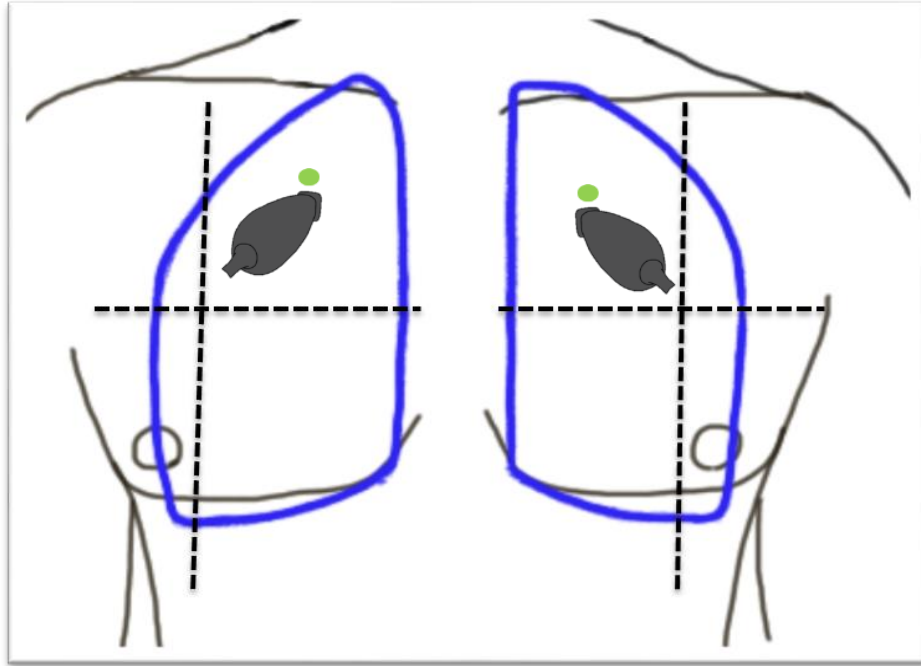
Lung Ultrasound

Image Acquisition



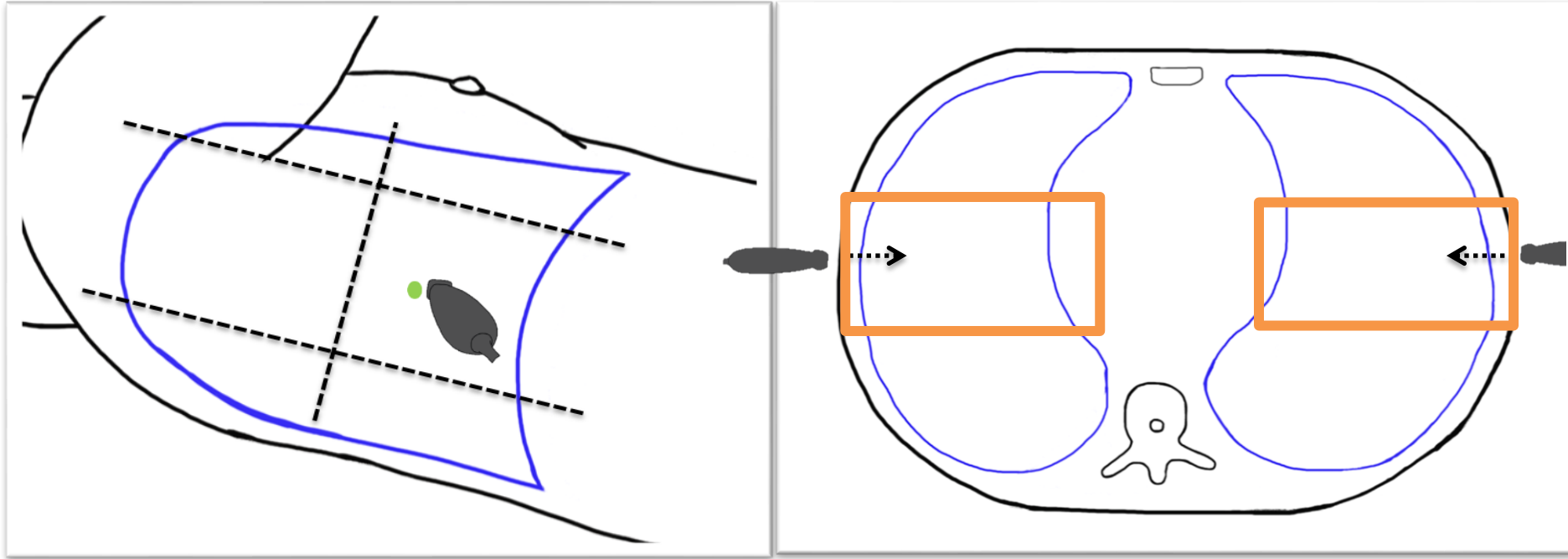
Lung Ultrasound

Image Acquisition – Zone 1



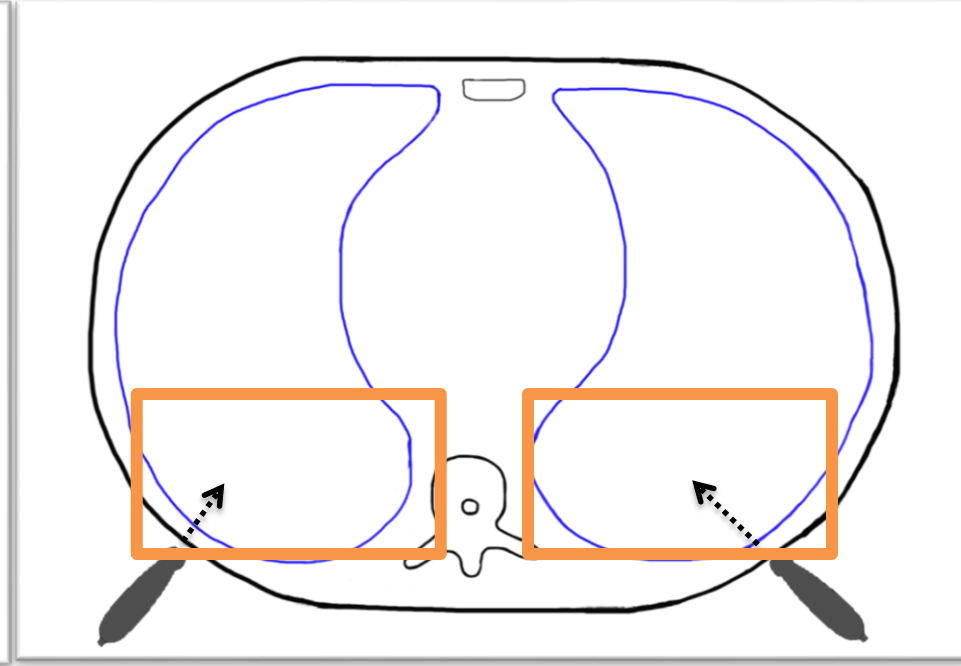
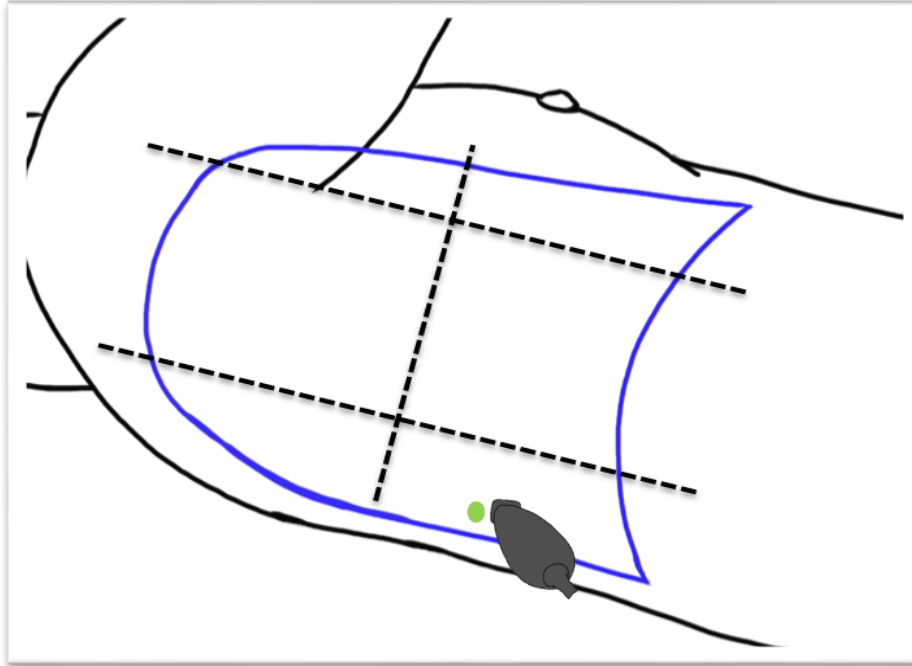
Lung Ultrasound

Image Acquisition – Zone 2



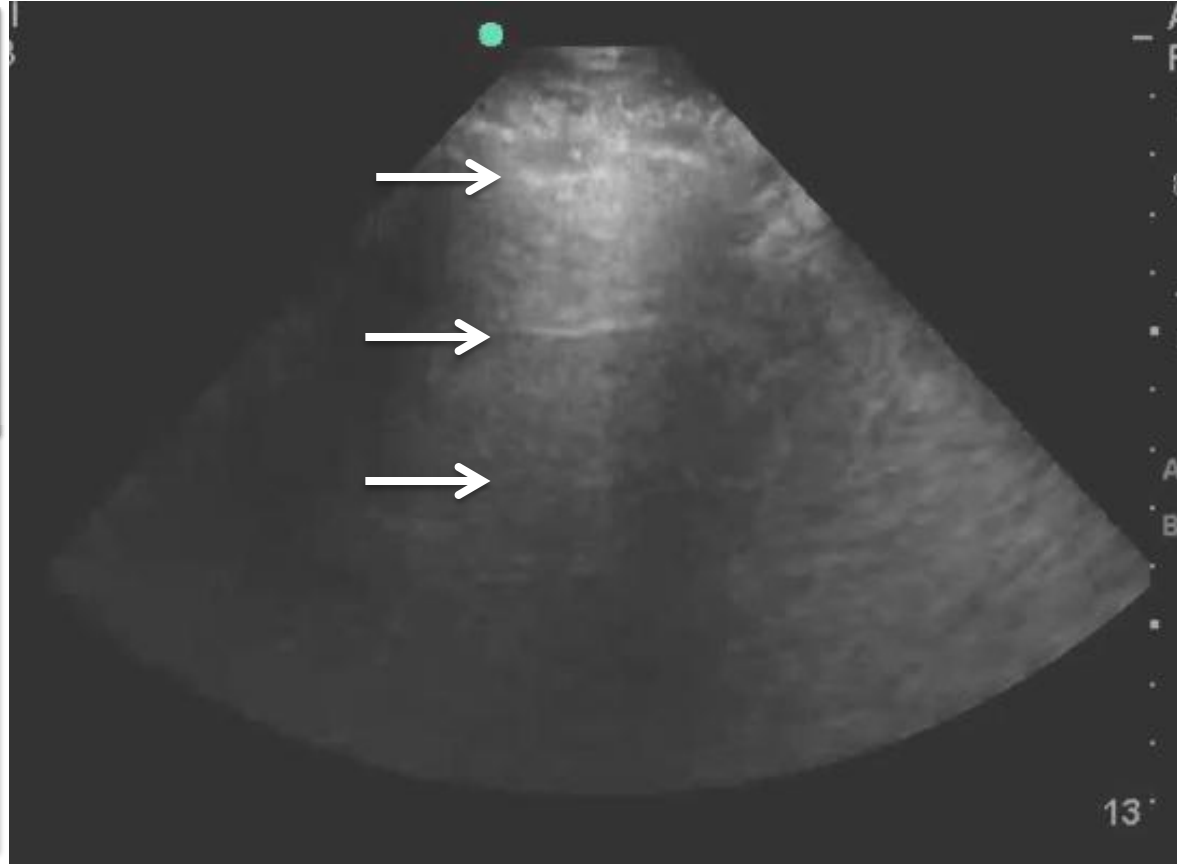
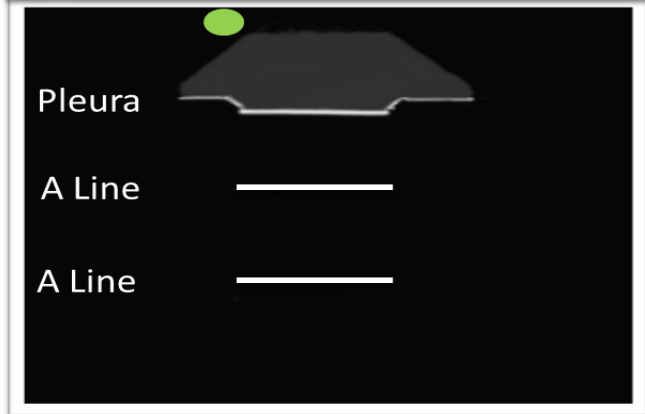
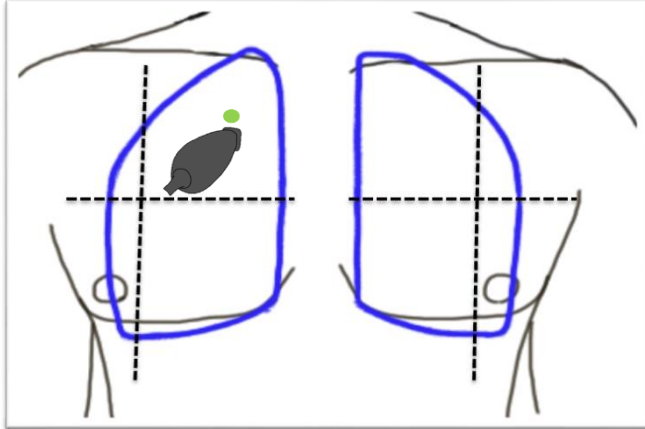
Lung Ultrasound

Image Acquisition – Zone 3



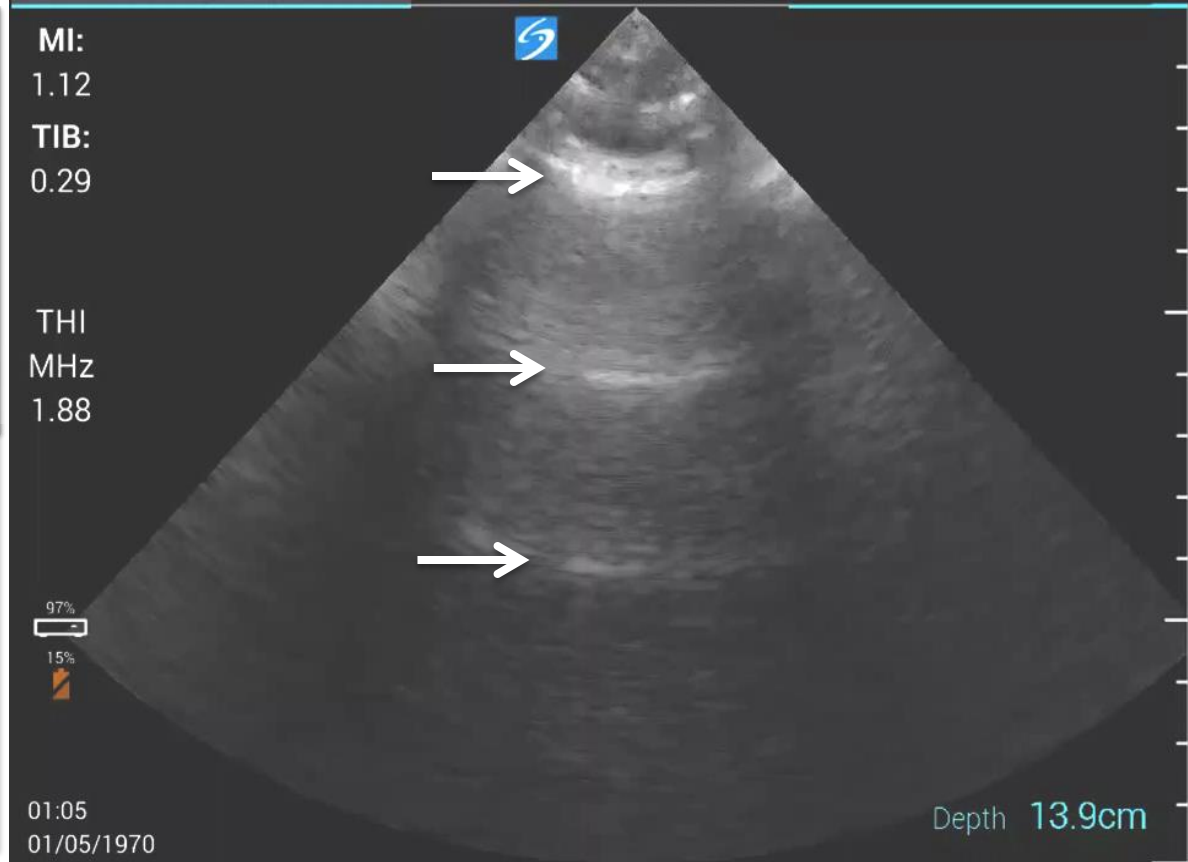
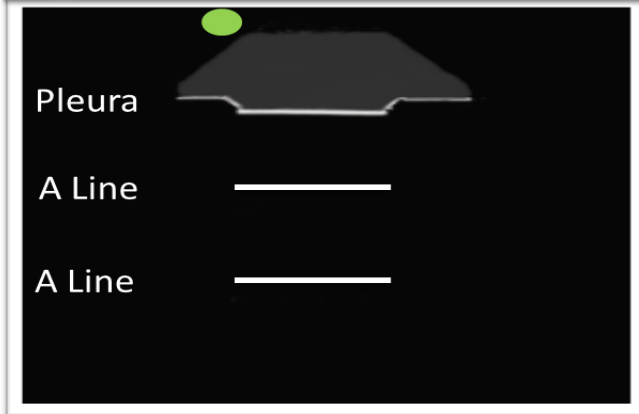
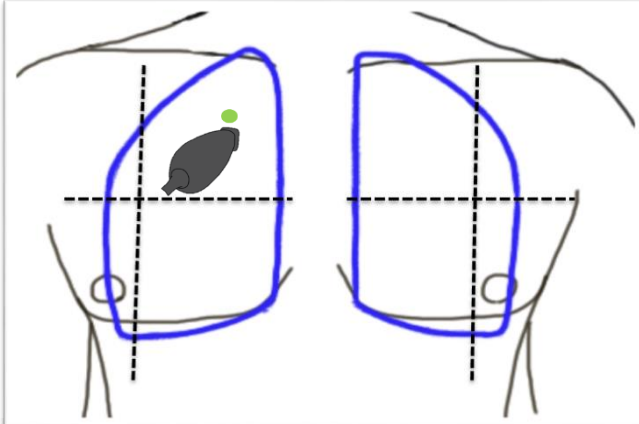
Lung Ultrasound

A Lines + Lung Sliding



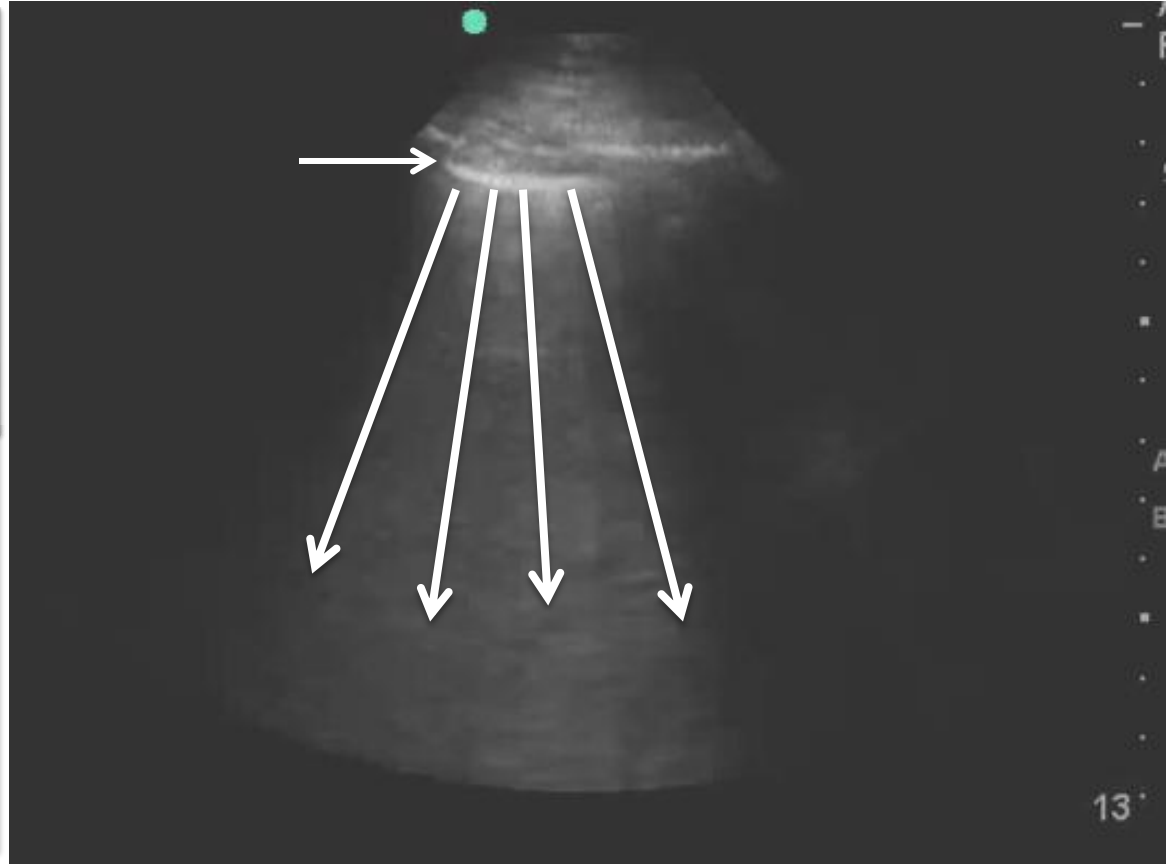
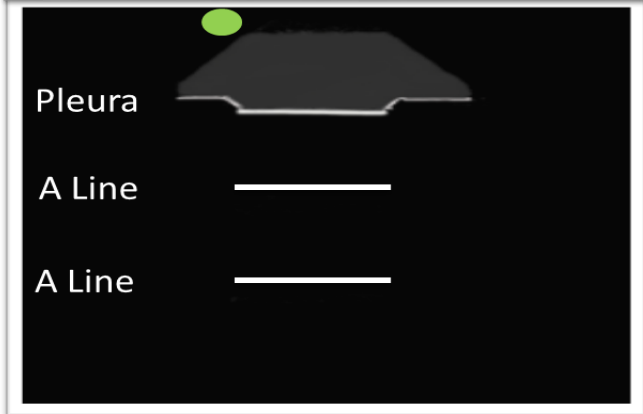
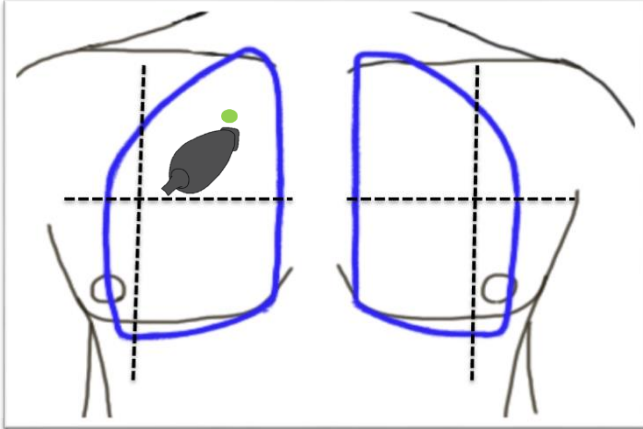
Lung Ultrasound

Absent Lung Sliding



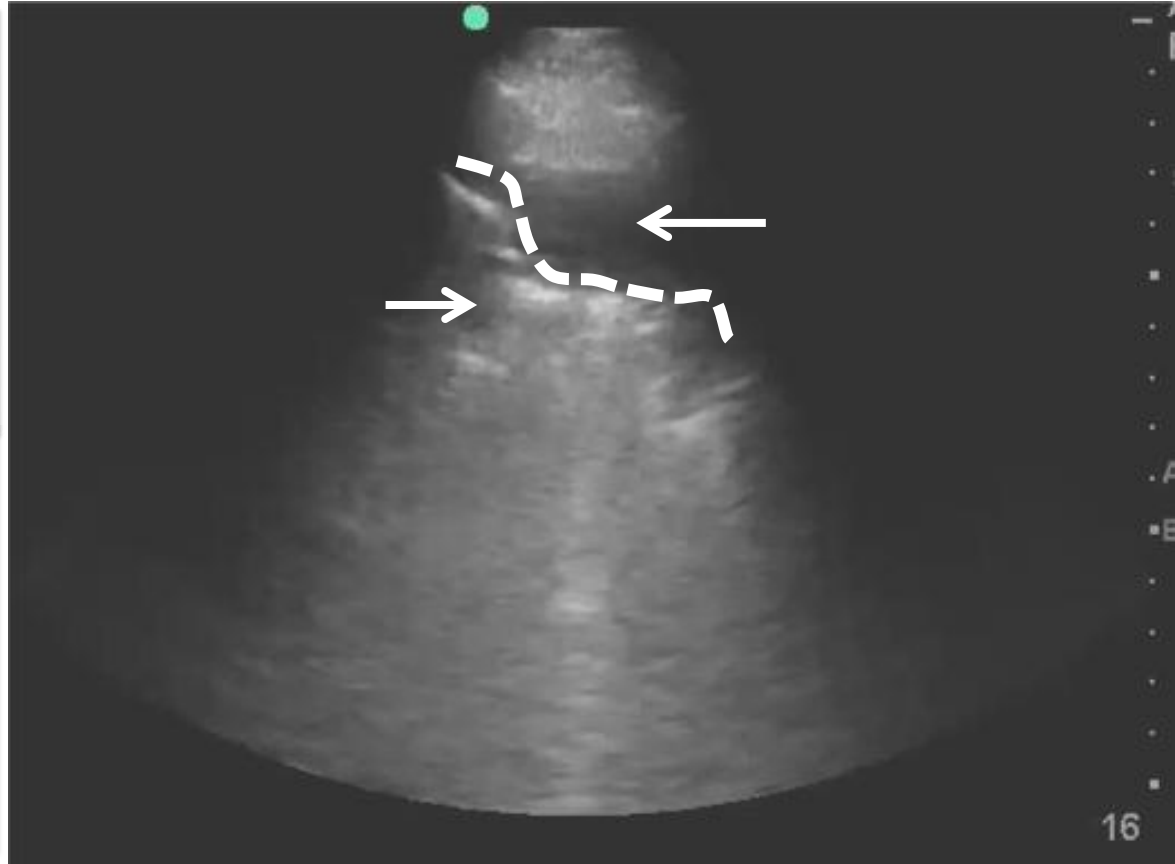
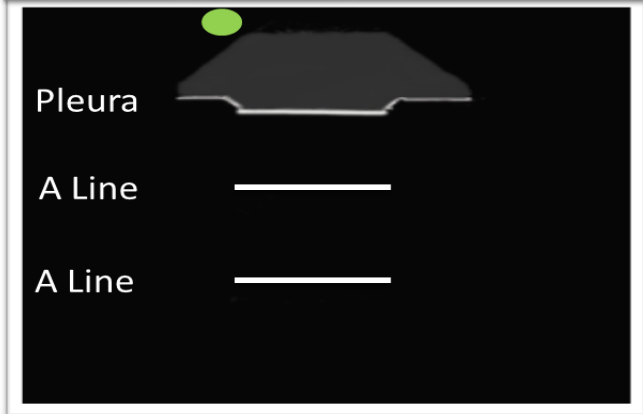
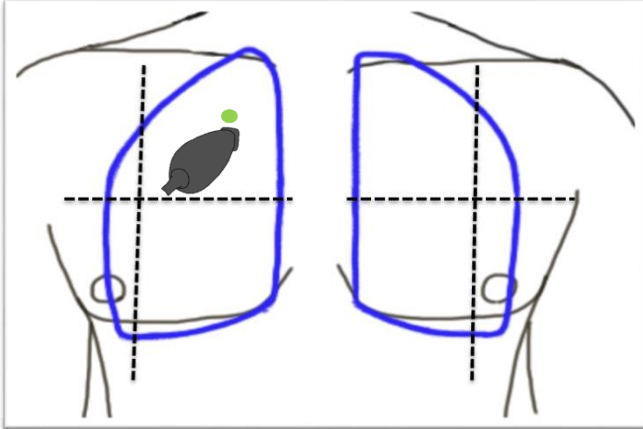
Lung Ultrasound

B Lines



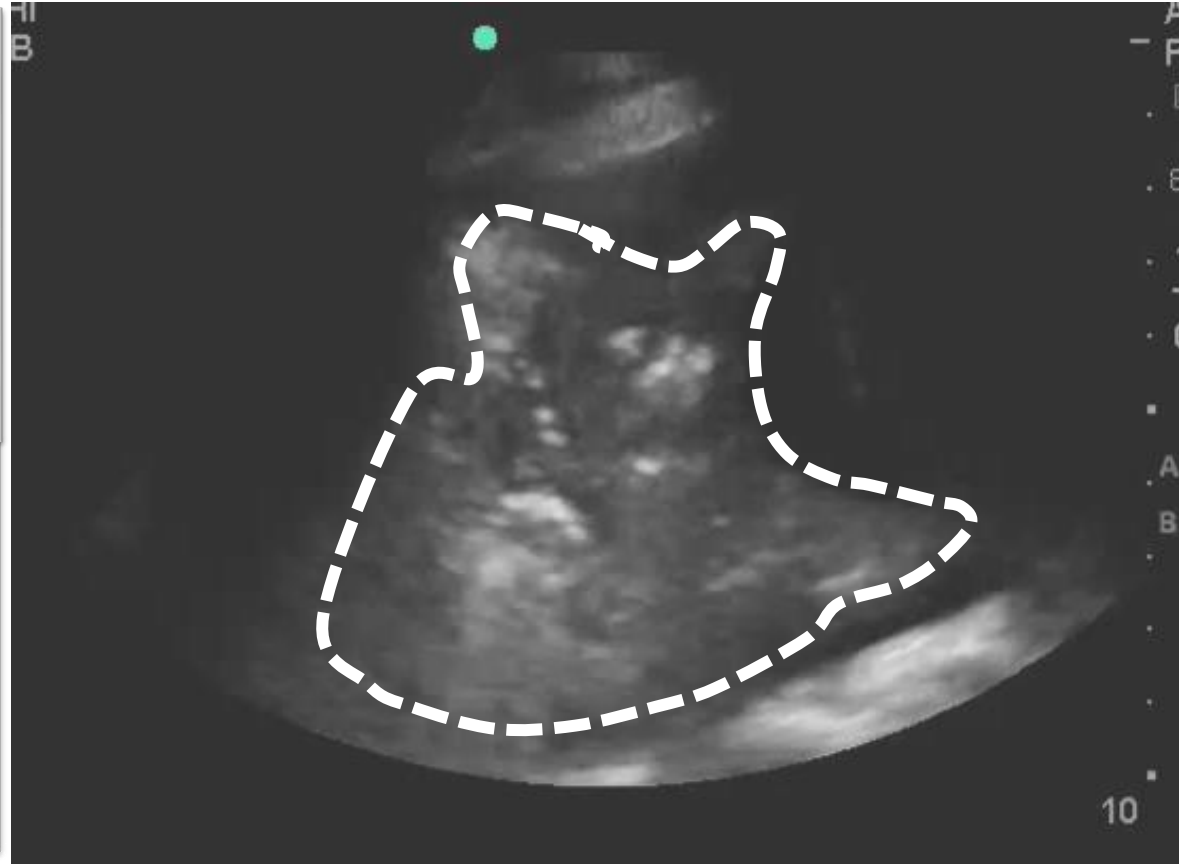
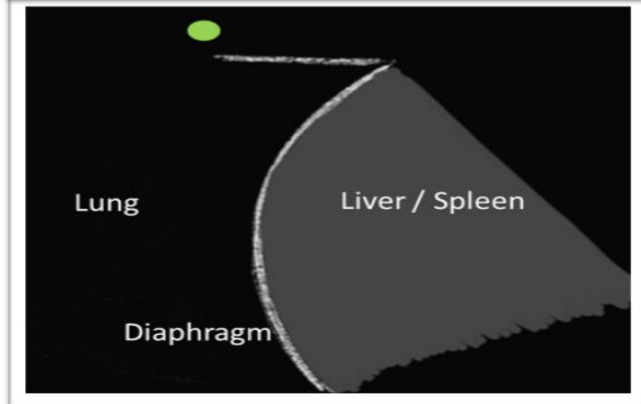
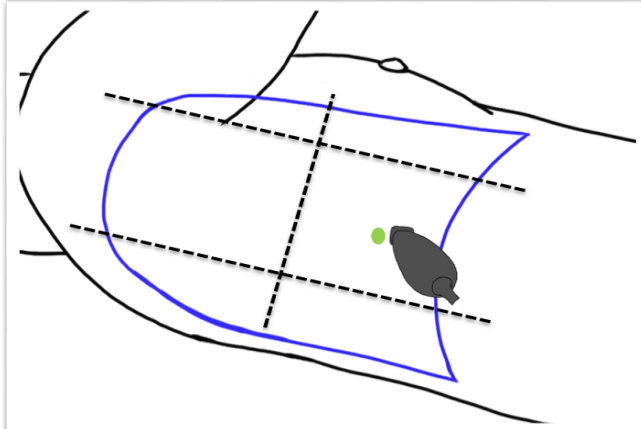
Lung Ultrasound

Consolidation



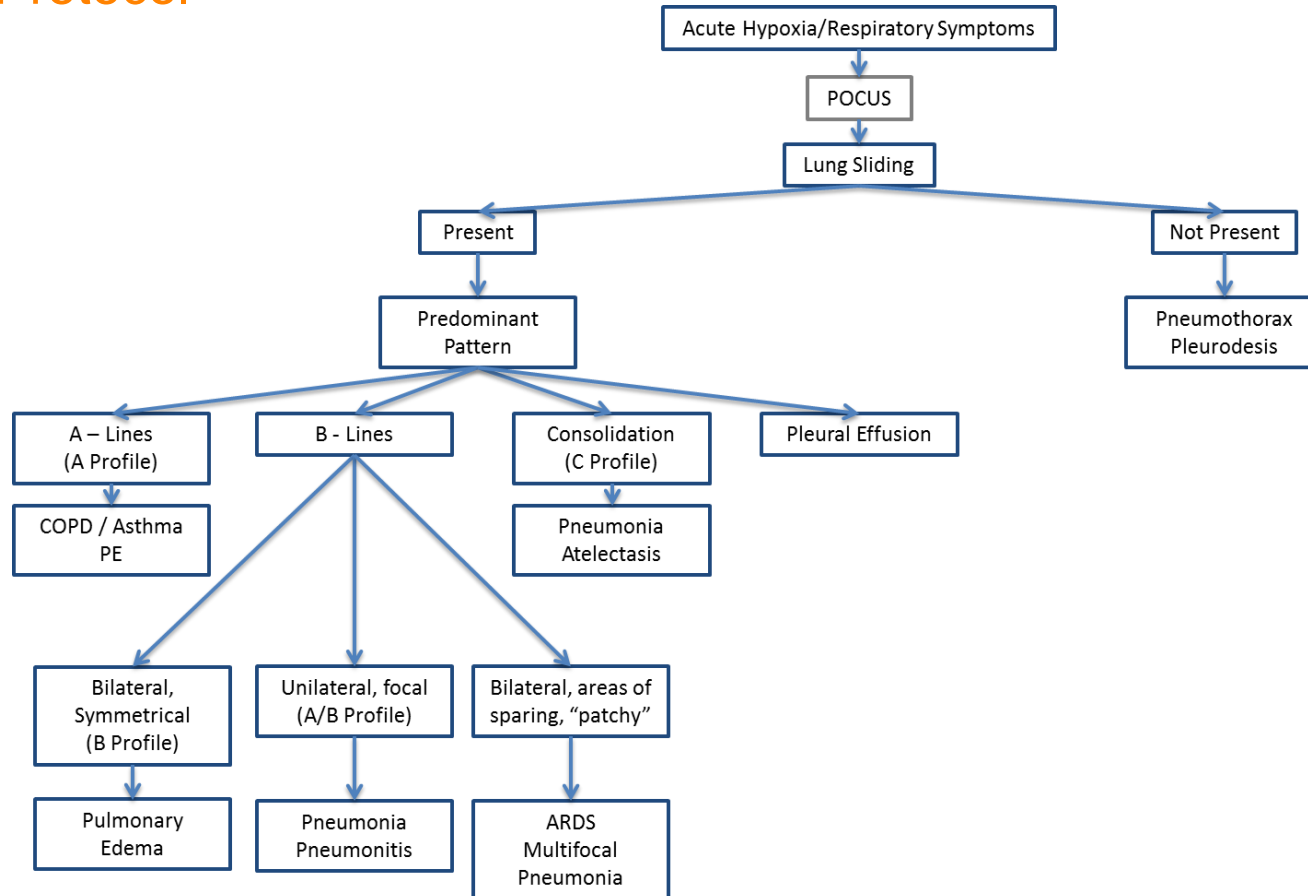
Lung Ultrasound

Consolidation



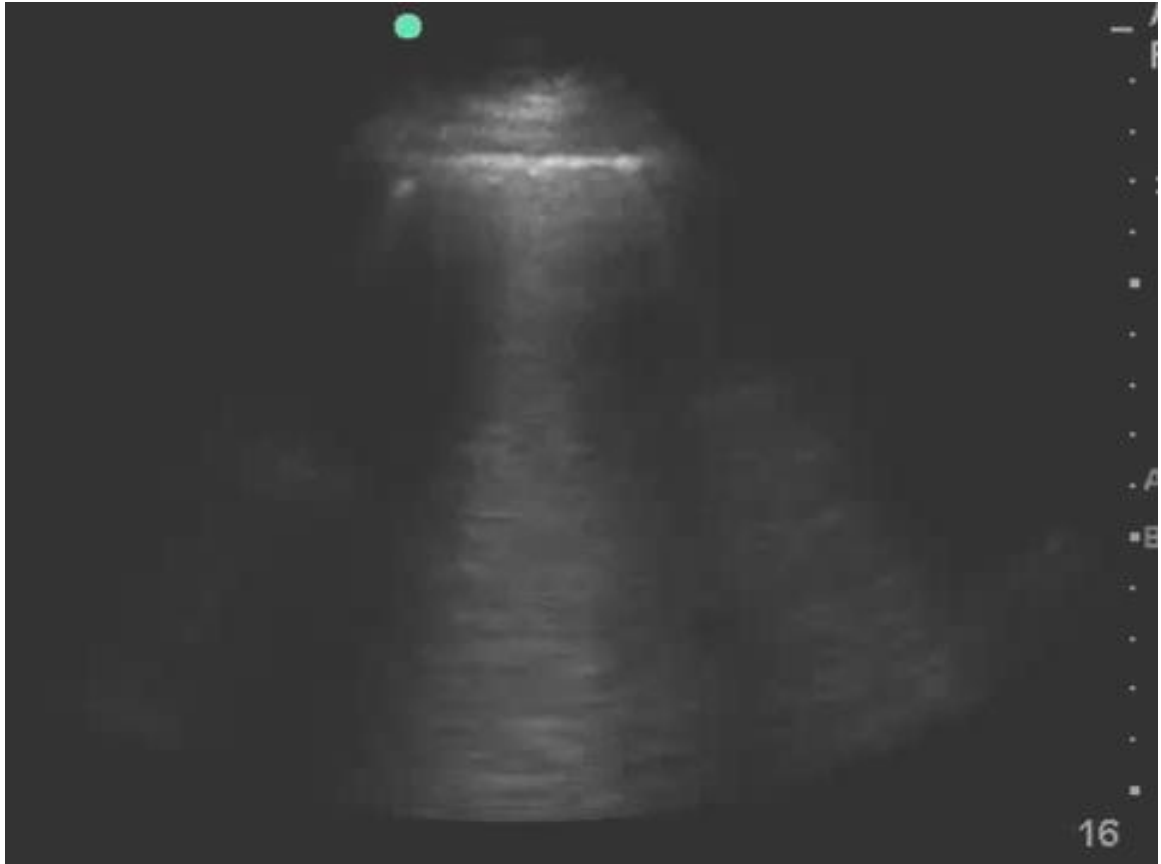
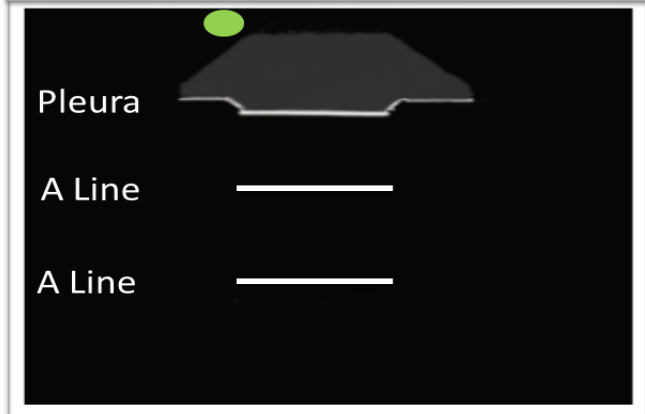
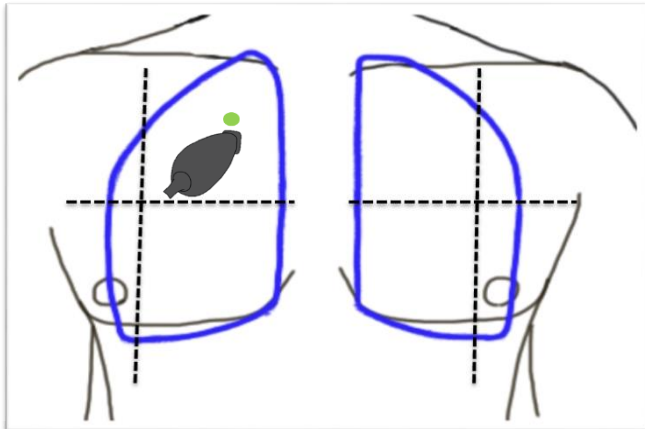
Lung Ultrasound

BLUE Protocol



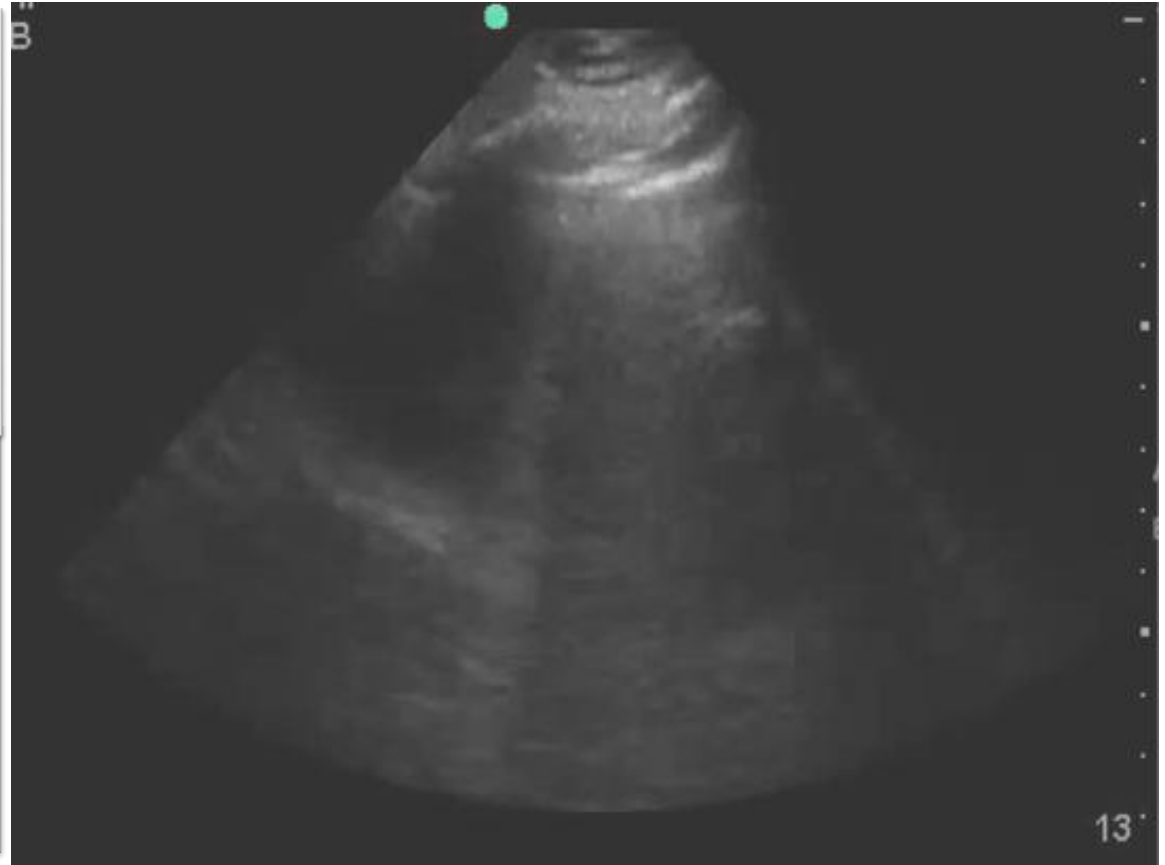
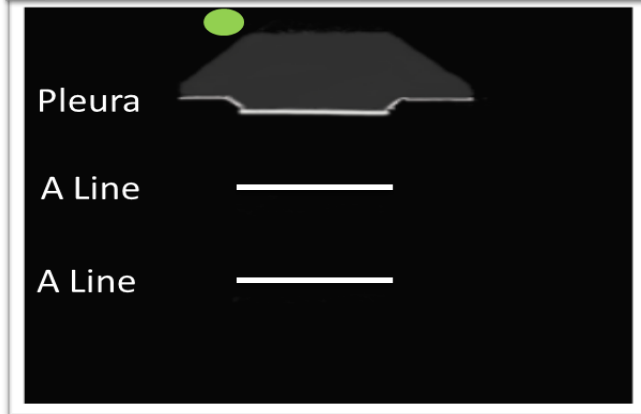
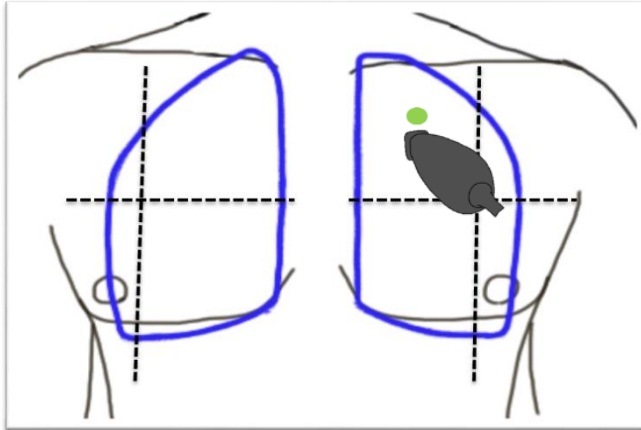
Case 1

Lung Ultrasound – Right Apex



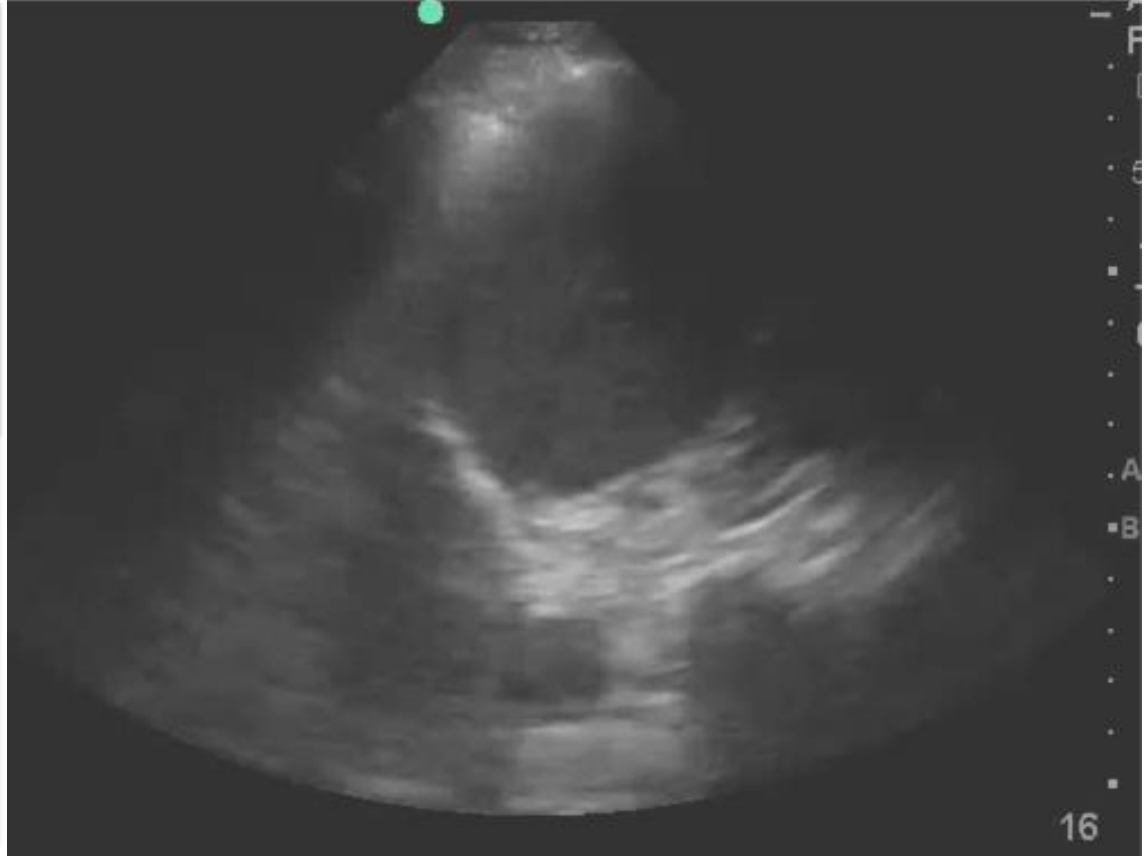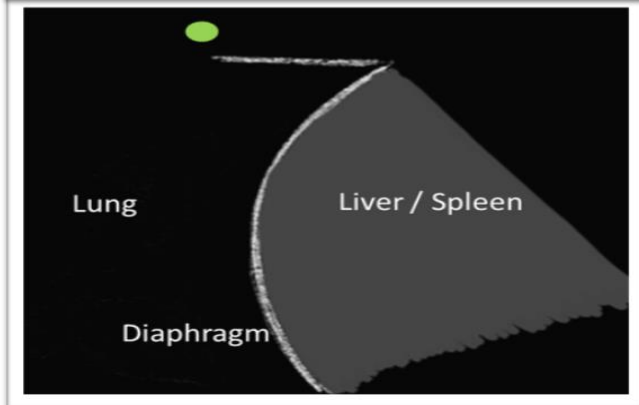
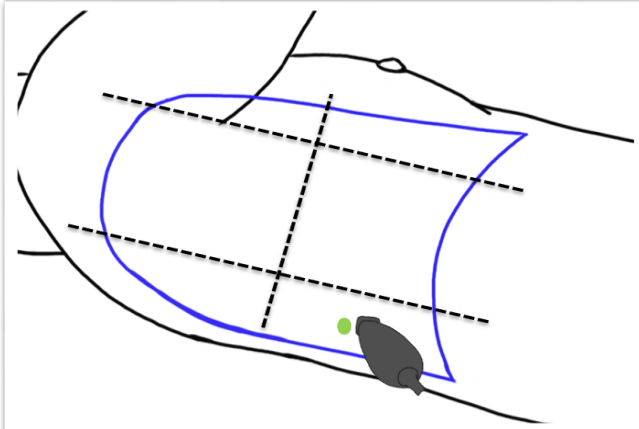
Case 1

Lung Ultrasound – Left Apex



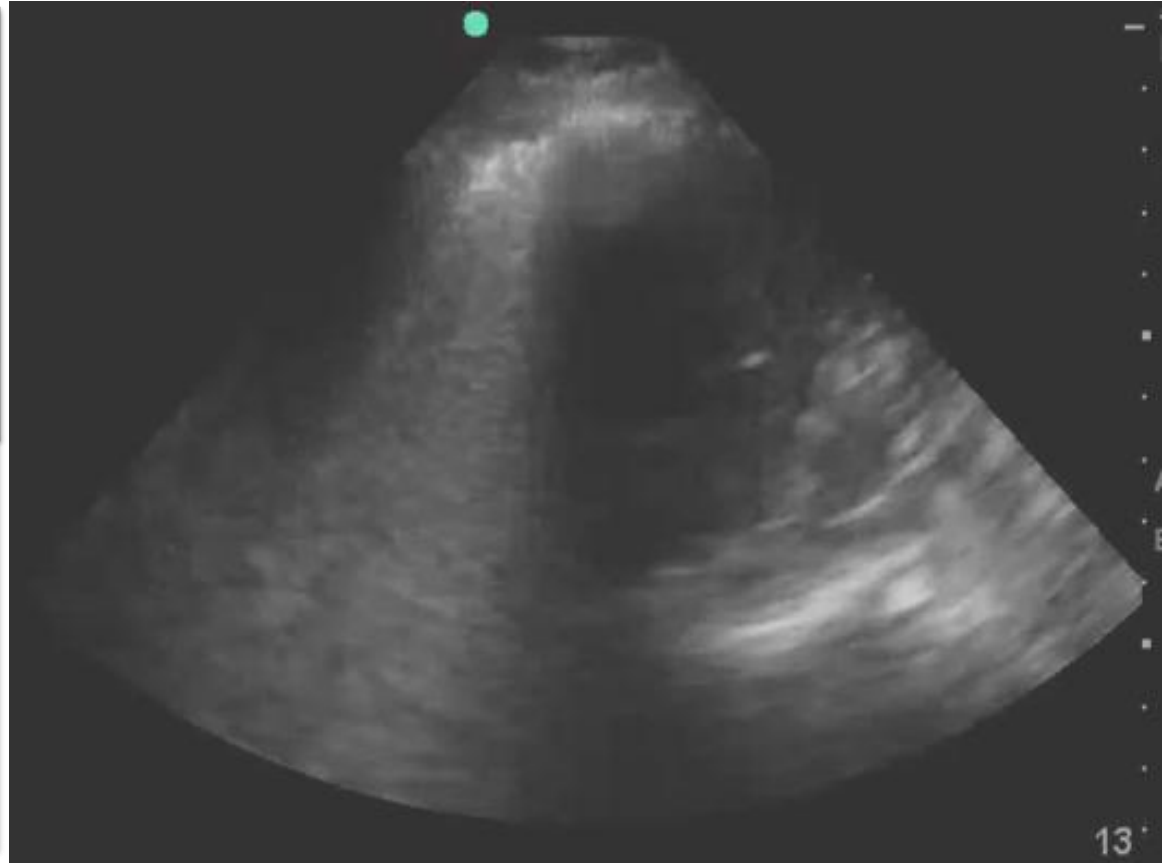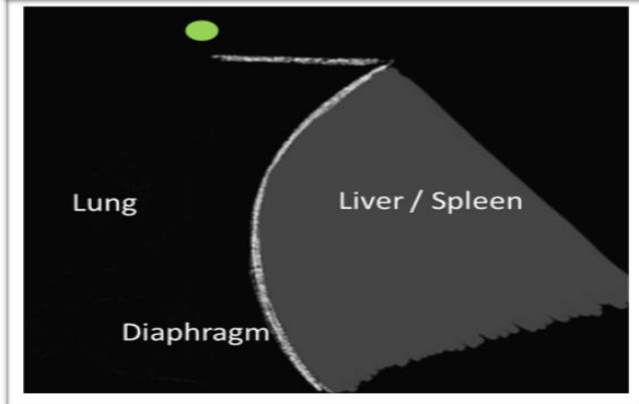
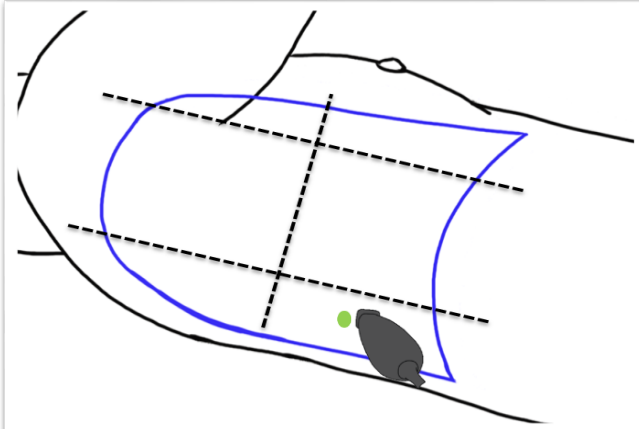
Case 1

Lung Ultrasound – Right Base



Case 1

Lung Ultrasound – Left Base



Case 1

Reflection Question

The findings on POCUS are most suggestive of which of the following?

- a) COPD exacerbation
- b) Pneumonia
- c) Pulmonary edema
- d) Pneumothorax

Case 1

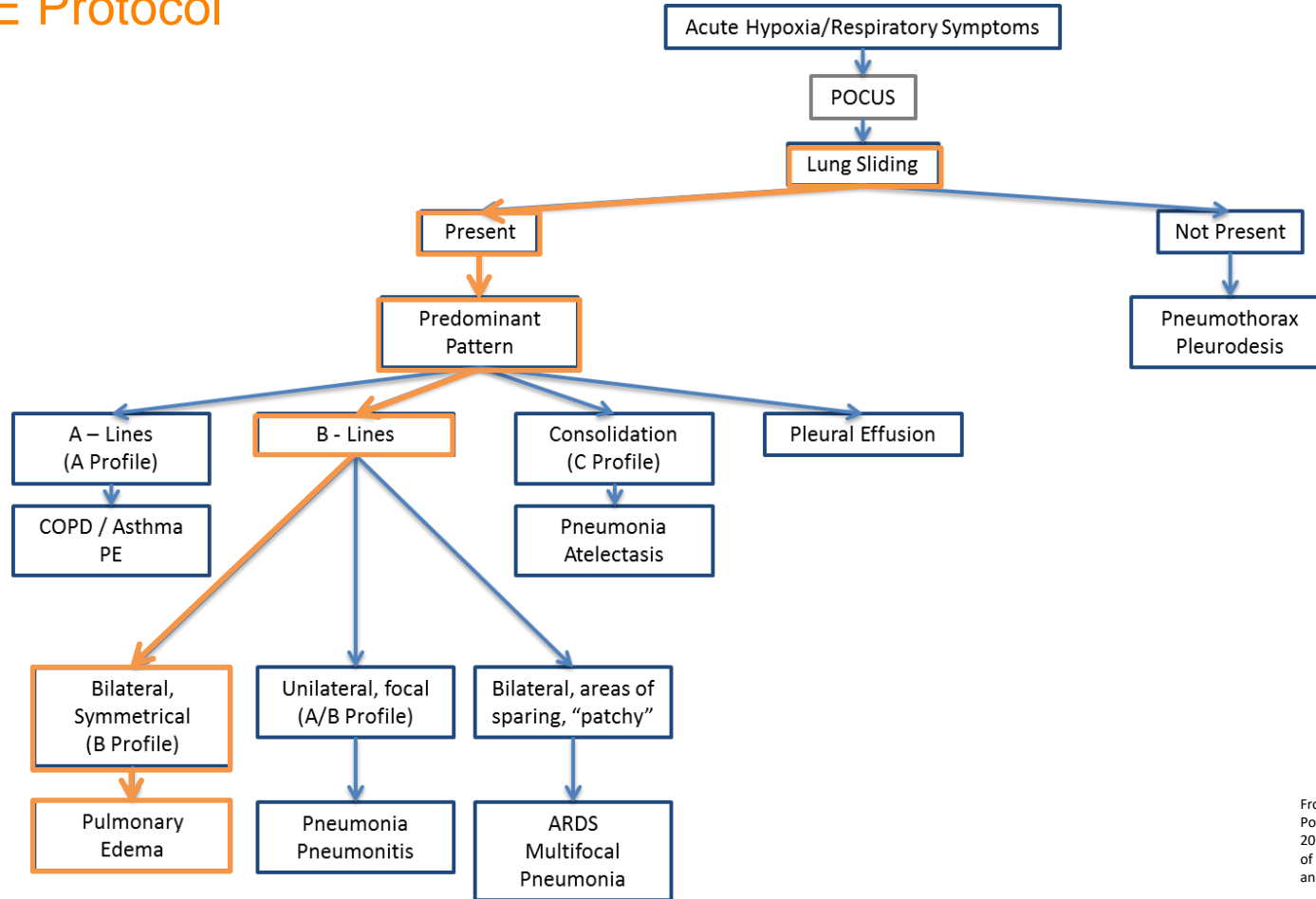
Reflection Question

The findings on POCUS are most suggestive of which of the following?

- a) COPD exacerbation
- b) Pneumonia
- c) Pulmonary edema**
- d) Pneumothorax

Case 1

BLUE Protocol



Case 1

Conclusion

- Based on POCUS he was diagnosed with acute decompensated systolic heart failure.
 - Diuretics started.
 - Steroids / Antibiotics stopped.
- Formal Echocardiogram
 - LVEF 34%.
- Discharged several days later
 - Diuretics, beta blocker, ACE-I.
 - Cardiology follow up.

Case 1

Conclusion

- Diagnosing CHF
 - In patients admitted for dyspnea, where the final diagnosis was CHF exacerbation, CHF was missed on initial presentation in 33.5% of cases.
 - In patients presenting for dyspnea and a history of CHF and COPD, correct diagnosis (CHF exacerbation vs COPD exacerbation) was made in 52% of cases.

- Collins SP, Lindsell CJ, Peacock WF, Eckert DC, Askew J, Storrow AB. Clinical Characteristics of emergency department heart failure patients initially diagnosed as non-heart failure. BMC Emergency Medicine. 2006;6:11. doi:10.1186/1471-227X-6-11.
- Russell FM, Ehrman RR, Cosby K, Ansari A, Tseeng S, Christain E, Bailitz J. Diagnosing acute heart failure in patients with undifferentiated dyspnea: a lung and cardiac ultrasound (LuCUS) protocol. Academic Emergency Medicine. 2015;22:182-191.

POCUS & CHF

Literature Review

- Diagnosing Acute Heart Failure in the Emergency Department: A Systematic Review and Meta-analysis
 - History and Physical Exam

Table 1
Pooled Test Performance Characteristics for History and Physical Examination Findings

	No. of Studies	No. of Patients	% AHF (95% CI)	Sensitivity, % (95% CI)	Specificity, % (95% CI)	LR+ (95% CI)	LR- (95% CI)
Symptoms							
Orthopnea ^{7,8,14,16,19,21,36,48,49,53-55,58,60,65}	15	5,430	45.5 (44.2–46.9)	52.1 (50.1–54.0)	70.5 (68.8–72.1)	1.9 (1.4–2.5)	0.74 (0.64–0.85)
PND ^{7,8,14,35,48,51,53,59,64}	9	2,216	44.8 (42.8–46.9)	46.2 (43.7–48.6)	73.9 (71.9–75.9)	1.6 (1.2–2.1)	0.79 (0.71–0.88)
Dyspnea at rest ^{20,51,55,61}	4	2,038	37.9 (35.9–40.0)	54.6 (51.2–58.0)	49.6 (46.9–52.3)	1.1 (0.9–1.4)	0.88 (0.74–1.04)
Absence of productive cough ^{7,8,12,36,49,59,62}	7	2,414	43.0 (41.0–45.0)	82.0 (79.6–84.4)	25.8 (23.5–28.2)	1.13 (1.02–1.26)	0.6 (0.5–0.8)
Examination findings							
S3 ^{7,8,14,15,20,53-55,57-60,64,65}	14	5,900	45.2 (44.0–46.5)	12.7 (11.5–14.0)	97.7 (97.2–98.2)	4.0 (2.7–5.9)	0.91 (0.88–0.95)
JVD ^{7,8,12,14-16,18,19,21,25,36,48,51,53-55,57-61,64,65}	23	8,012	47.8 (46.7–48.9)	37.2 (35.7–38.7)	87.0 (85.9–88.0)	2.8 (1.7–4.5)	0.76 (0.69–0.84)
Hepatojugular reflex ^{55,59,61,65}	4	1,209	60.4 (57.6–63.1)	14.1 (11.9–16.6)	93.4 (91.2–95.2)	2.2 (1.3–3.7)	0.91 (0.88–0.94)
Leg edema ^{7,8,10,12,14,15,16,18,19-21,23,25,48,49,51,53-55,57-62,65}	26	9,626	47.2 (46.2–48.2)	51.9 (50.5–53.4)	75.2 (74.0–76.4)	1.9 (1.6–2.3)	0.68 (0.61–0.75)
Murmur ^{7,12,51,54,55,58,62,65}	8	4,004	45.3 (43.8–46.8)	27.8 (25.8–29.9)	83.2 (81.6–84.8)	1.9 (0.9–3.9)	0.93 (0.79–1.08)
Rales ^{7,8,10,12,15,18-21,23,25,36,48,51,53-55,58-61,65}	22	8,775	48.2 (47.1–49.2)	62.3 (60.8–63.7)	68.1 (66.7–69.4)	1.8 (1.5–2.1)	0.60 (0.51–0.69)
Wheezing ^{7,8,12,15,20,23,36,48,53,55,58,59,65}	13	6,970	44.2 (43.0–45.3)	22.3 (20.9–23.8)	64.0 (62.5–65.4)	0.6 (0.5–0.8)	1.19 (1.10–1.30)
Absent fever ^{7,23,36,49,59,62,63}	7	3,197	43.6 (41.9–45.3)	92.4 (90.9–93.8)	20.6 (18.8–22.5)	1.14 (1.02–1.27)	0.4 (0.3–0.6)

POCUS & CHF

Literature Review

- Diagnosing Acute Heart Failure in the Emergency Department: A Systematic Review and Meta-analysis
 - Chest X-ray: Sensitivity **56.9%**, Specificity 89.2%.

Table 2
Pooled Test Performance Characteristics for Chest Radiograph and Electrocardiogram Findings

	No. of Studies	No. of Patients	% AHF (95% CI)	Sensitivity, % (95%CI)	Specificity, % (95%CI)	LR+ (95% CI)	LR- (95% CI)
Chest radiograph							
Kerley B-lines ^{38,72}	2	814	46.8 (43.4–50.2)	9.2 (6.5–12.5)	98.8 (97.3–99.6)	6.5 (2.6–16.2)	0.88 (0.69–1.13)
Interstitial edema ^{15,66,72}	3	2,001	48.3 (46.2–50.5)	31.1 (28.2–34.2)	95.1 (93.6–96.3)	6.4 (3.4–12.2)	0.73 (0.68–0.78)
Cephalization ^{8,57,64,66,72}	5	1,338	54.0 (51.3–56.6)	44.7 (41.1–48.4)	94.6 (92.6–96.3)	5.6 (2.9–10.4)	0.53 (0.39–0.72)
Alveolar edema ^{15,66,72}	3	2,001	48.3 (46.2–50.5)	5.7 (4.7–6.9)	98.9 (98.4–99.3)	5.3 (3.3–8.5)	0.95 (0.94–0.97)
Pulmonary edema ^{*7,8,12,14,16,18–21,23,36,54,57,58,64}	15	4,393	46.6 (45.1–48.1)	56.9 (54.7–59.1)	89.2 (87.9–90.4)	4.8 (3.6–6.4)	0.48 (0.39–0.58)
Pleural effusion ^{12,20,58,60,72}	5	1,326	55.1 (52.4–57.8)	16.3 (13.7–19.2)	92.8 (90.4–94.7)	2.4 (1.6–3.6)	0.89 (0.80–0.99)
Enlarged cardiac silhouette ^{8,12,15,18,20,21,54,58,60,64–66}	12	3,515	51.7 (49.4–52.7)	74.7 (72.9–76.5)	61.7 (59.4–63.9)	2.3 (1.6–3.4)	0.43 (0.36–0.51)

LR+ = positive likelihood ratio; LR- = negative likelihood ratio.
*Refers to generalized pulmonary edema in studies that did not report specifically on both "alveolar edema" and "interstitial edema."

POCUS & CHF

Literature Review

- Diagnosing Acute Heart Failure in the Emergency Department: A Systematic Review and Meta-analysis
 - Lung Ultrasound: Sensitivity 85.3%, Specificity 92.7%.

Table 5
Pooled Test Performance Characteristics for Lung US and Bedside Echocardiography Findings

	<i>N</i>	<i>n</i>	% AHF (95% CI)	Sensitivity % (95% CI)	Specificity % (95% CI)	LR+ (95% CI)	LR- (95% CI)
Lung US							
Positive B-line scan* ^{23, 24, 48, 62, 63, 81, 90, 91}	8	1914	48.2 (46.0–50.5)	85.3 (82.8–87.5)	92.7 (90.9–94.3)	7.4 (4.2–12.8)	0.16 (0.05–0.51)
Pleural effusion(s) ^{63,90}	2	155	40.7 (33.2–48.5)	63.5 (50.4–75.3)	71.7 (61.4–80.6)	2.0 (1.4–2.8)	0.49 (0.22–1.10)
Bedside echocardiography							
Restrictive mitral pattern* ²⁰	1	125	43.2 (34.9–52.0)	81.5 (68.6–90.7)	90.1 (80.7–95.9)	8.3 (4.0–16.9)	0.21 (0.12–0.36)
Reduced EF ^{20,48,63}	3	325	41.2 (36.0–46.7)	80.6 (72.9–86.9)	80.6 (74.3–86.0)	4.1 (2.4–7.2)	0.24 (0.17–0.35)
Increased LV end-diastolic dimension ^{†,21}	1	84	58.3 (47.7–68.3)	79.6 (65.7–89.7)	68.6 (50.7–83.1)	2.5 (1.5–4.2)	0.30 (0.16–0.54)

Lung ultrasound: *defined as ≥ 2 bilateral lung zones with ≥ 3 B-lines per intercostal space.

Bedside echocardiography: *defined as E/A ratio > 2 or E/A between 1 and 2 and deceleration time (DT) < 130 msec; DT < 130 msec alone if atrial fibrillation. [†]Defined as LVEDD > 28.6 mm/mm².

AHF = acute heart failure; EF = ejection fraction; LV = left ventricular; LR = likelihood ratio; *N* = number of studies; *n* = number of patients; US = ultrasound.

POCUS & CHF

Literature Review

- Diagnosing Acute Heart Failure in the Emergency Department: A Systematic Review and Meta-analysis
 - Lung Ultrasound: Sensitivity 85.3%, Specificity 92.7%.

“Bedside lung US and echocardiography appear to be the **most useful test** for affirming the presence of AHF.”

Lung Ultrasound

Literature Review

- Pulmonary Edema – Chest X-Ray vs Lung Ultrasound:

	Chest X-Ray	Lung Ultrasound
Sensitivity	56.9%	85.3 – 92.1%
Specificity	89.2%	92%
+ LR	5.2	12.38
- LR	0.48	0.06

- Alrajab S, Yousef AM, Akkus N, Caldito G. Pleural ultrasonography versus chest radiography for the diagnosis of pneumothorax: review of the literature and meta-analysis. *Critical Care* 2013, 17:R208.
- Martindale JL, Wakai A, Collins SP, et al. Diagnosing Acute Heart Failure in the Emergency Department: A Systematic Review and Meta-analysis. *Acad Emerg Med*. 2016 Mar;23(3):223-42. doi: 10.1111/acem.12878. Epub 2016 Feb 13.
- Al Deeb M, Barbic S, Featherstone R, Dankoff J, Barbic D. Point-of-Care ultrasonography for the diagnosis of acute cardiogenic pulmonary edema in patients presenting with acute dyspnea: a systematic review and meta-analysis. *Acad Emerg Med*. 2014 Aug;21(8):843-52. doi: 10.1111/acem.12435

Lung Ultrasound

Literature Review

- Pneumothorax – Chest X-Ray vs Lung Ultrasound:

	Chest X-Ray	Lung Ultrasound
Sensitivity	50.2%	90.9%
Specificity	99%	99%
+ LR	50	50.5
- LR	0.51	0.09

- Alrajhi K, Yoo MY, Vaillancourt C. Test Characteristics of Ultrasonography for the Detection of Pneumothorax: a Systematic Review and Meta-analysis. CHEST 2012; 141(3):703–708.
- Alrajab S, Yousef AM, Akkus N, Caldito G. Pleural ultrasonography versus chest radiography for the diagnosis of pneumothorax: review of the literature and meta-analysis. Critical Care 2013, 17:R208.

Lung Ultrasound

Literature Review

- Pneumonia – Chest X-Ray vs Lung Ultrasound:

	Chest X-Ray	Lung Ultrasound
Sensitivity	38 - 64%	85 – 96%
Specificity	93%	93 – 96%
+ LR	9.14	12.14
- LR	0.39	0.16

- N. Xirouchaki, E. Magkanas, K. Vaporidi, et al.: Lung ultrasound in critically ill patients: comparison with bedside chest radiography. *Intensive Care Med.* 37:1488-1493 2011
- Alzaharani SA, Al-Salamah MA, Al-Madani WH, et al. Systematic review and meta-analysis for the use of ultrasound versus radiology in diagnosing of pneumonia. *Crit Ultrasound J* (2017) 9:6.
- Pereda MA, Chavez MA, Hooper-Miele CC, et al. Lung Ultrasound for the Diagnosis of Pneumonia in Children: A Meta-analysis. *Pediatrics.* 135: 714-722.

Lung Ultrasound

Literature Review

- Pleural Effusion – Chest X-Ray vs Lung Ultrasound:

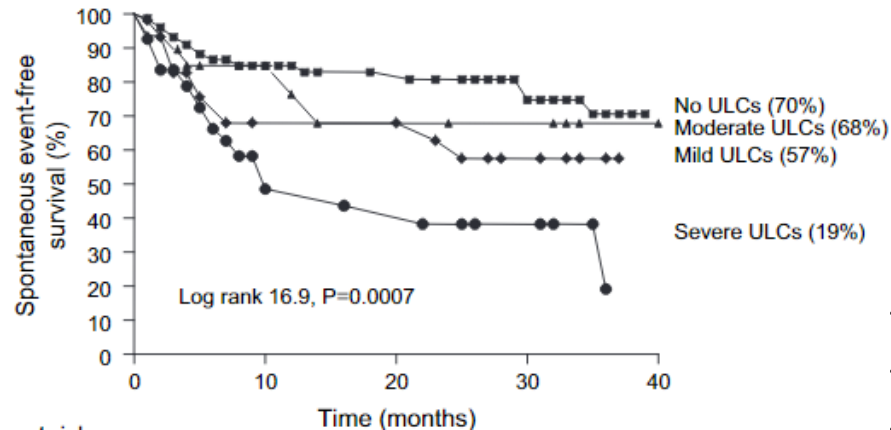
	Chest X-Ray	Lung Ultrasound
Sensitivity	51%	94%
Specificity	91%	98%
+ LR	5.6	47
- LR	0.54	0.06

- Yousefifard M, Baikpour M, Ghelichkhani P, Asady H, Shahsavari NK, Moghadas JA, Hosseini M, Safari S. Screening Performance Characteristics of Ultrasonography and Radiography in Detection of Pleural Effusion: a Meta-Analysis. Emerg (Tehran). 2016;4(1):1-10.

POCUS & CHF

Literature Review

- Readmission Rate:
 - Dilated, non-collapsing IVC on discharge predicts hospital readmission rates
- Prognosis:
 - Number of B Lines is correlated to mortality rates (HR 2.349)



- Carbone F, Bovio M, Ferrando F, Scarrone A, et al. Inferior vena cava parameters predict re-admission in ischemic heart failure. *Eur J Clin Invest.* 2014;44(4):341-349.
- Laffin L, Patel A, Saha N et al. Focused Cardiac ultrasound as a predictor of readmission in acute decompensated heart failure. *Diabetes Obes Metab.* 2018;20(6):1335-1336
- Frassi F, Gargani L, Tesorio P, et al. Prognostic Value of Extravascular Lung Water Assessed with Ultrasound Lung Comets by Chest Sonography in Patients with Dyspnea and/or Chest Pain. *Journal of Cardiac Failure.* 2007;13(10):830-835.

Case 2

HPI

- A 62 year-old female presented to the ED for evaluation of shortness of breath, cough, and left sided pleuritic chest pain.
- Symptoms began acutely 24 hours ago, and have progressed.

Case 2

History

- Past Medical / Surgical History:
 - Left ventricular diastolic heart failure
 - Hypertension
 - Obesity
- Social History:
 - N/A
- Family History:
 - N/A

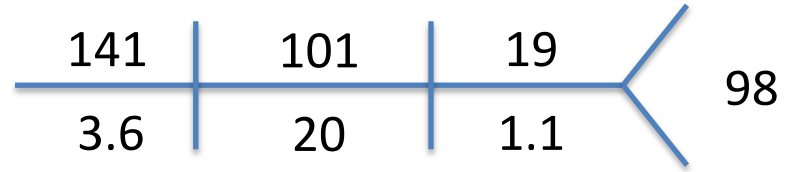
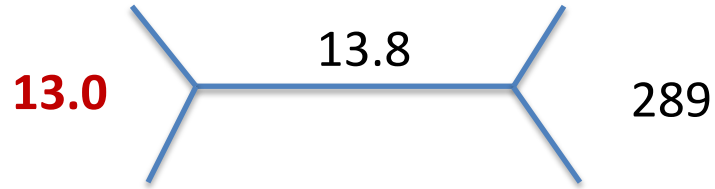
Case 2

Objective Findings

- Vital Signs:
 - HR 92, BP 156/52, SpO2 **87%** on room air, RR 19, Tmax 37.4 Celsius.
- Physical Exam:
 - Respirations even and non-labored. Dense crackles in the left lower base, otherwise clear to auscultation.
 - Remainder of examination normal

Case 2

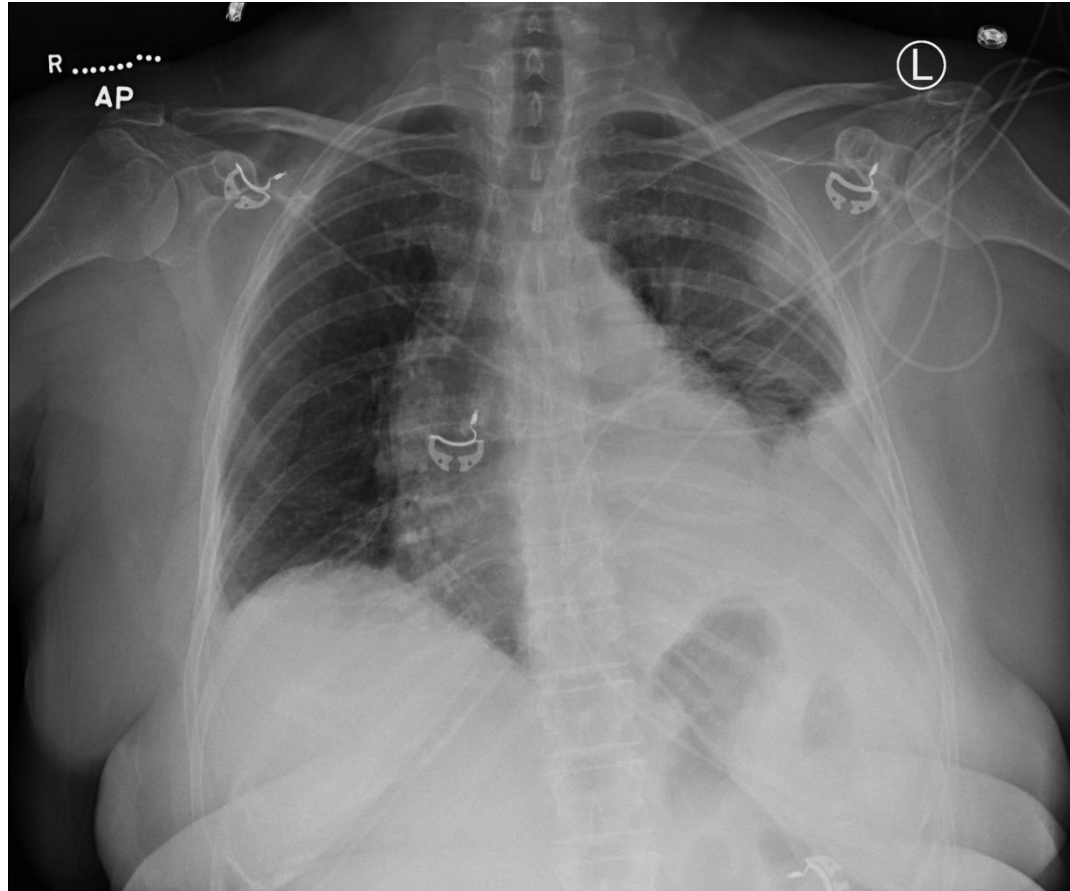
Labs



- Lactate 1.7

Case 2

Chest X-ray



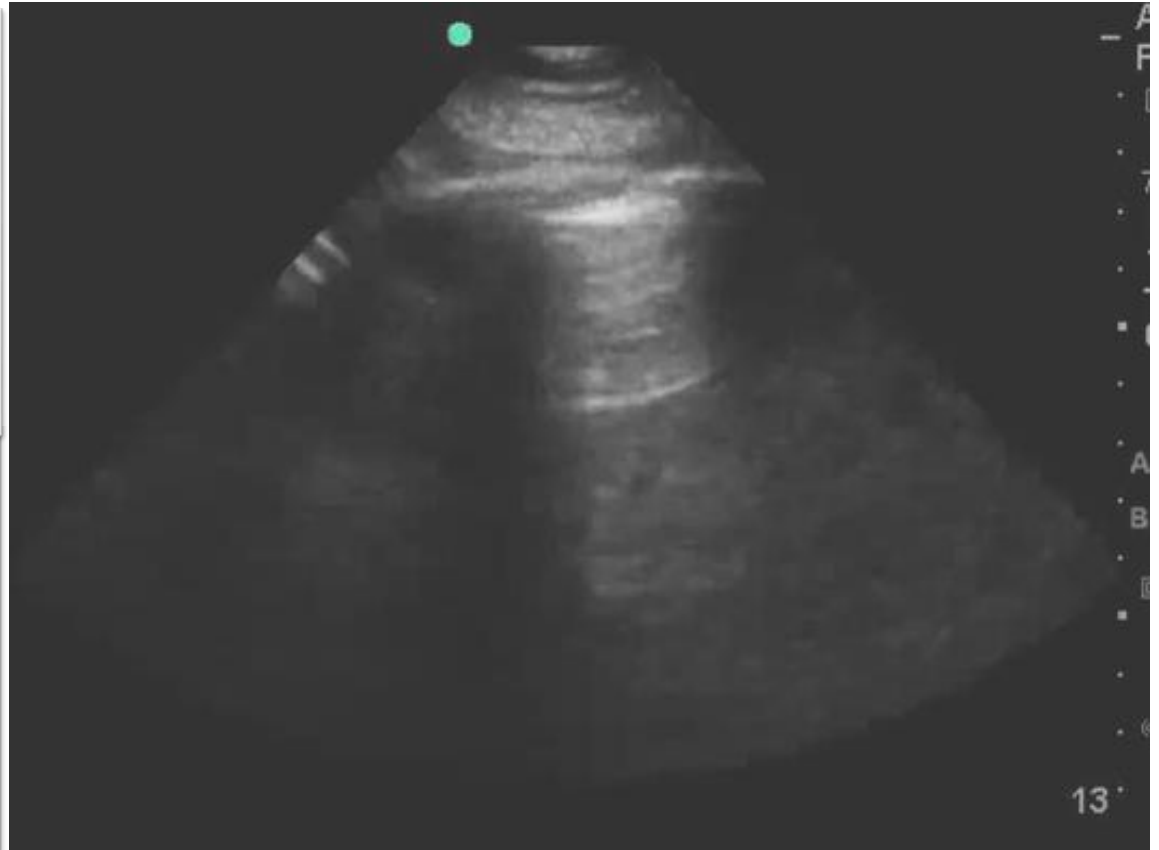
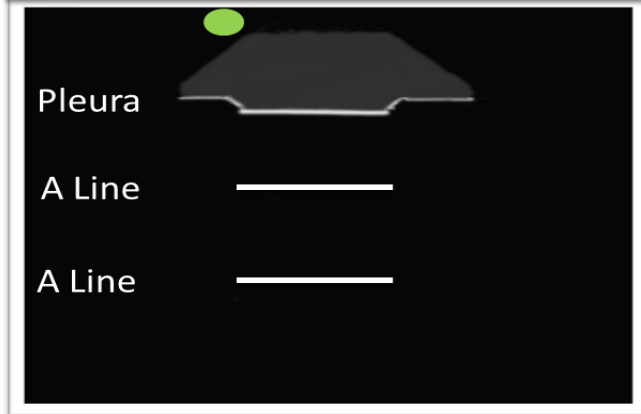
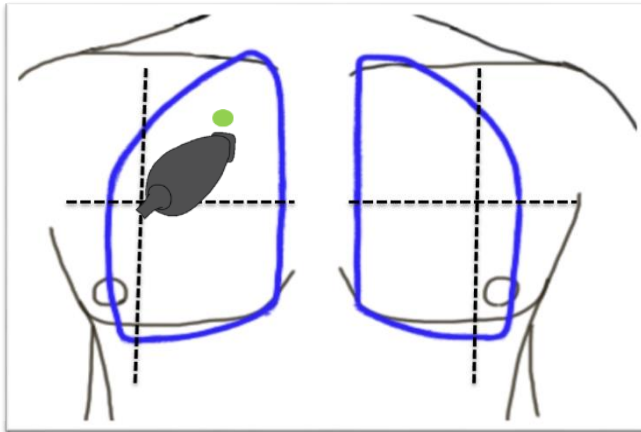
Case 2

ED / Hospital Course

- Diagnosis: Community acquired pneumonia
- Treatment:
 - Antibiotics: Ceftriaxone + Azithromycin
 - IV Fluids: 3 L lactated ringers total since hospitalization
- RN Call:
 - Increased shortness of breath, tachypnea (RR 28), and oxygen requirements (from 2 L/min to 6 L/min nasal cannula).
 - Significant left sided pleuritic chest pain

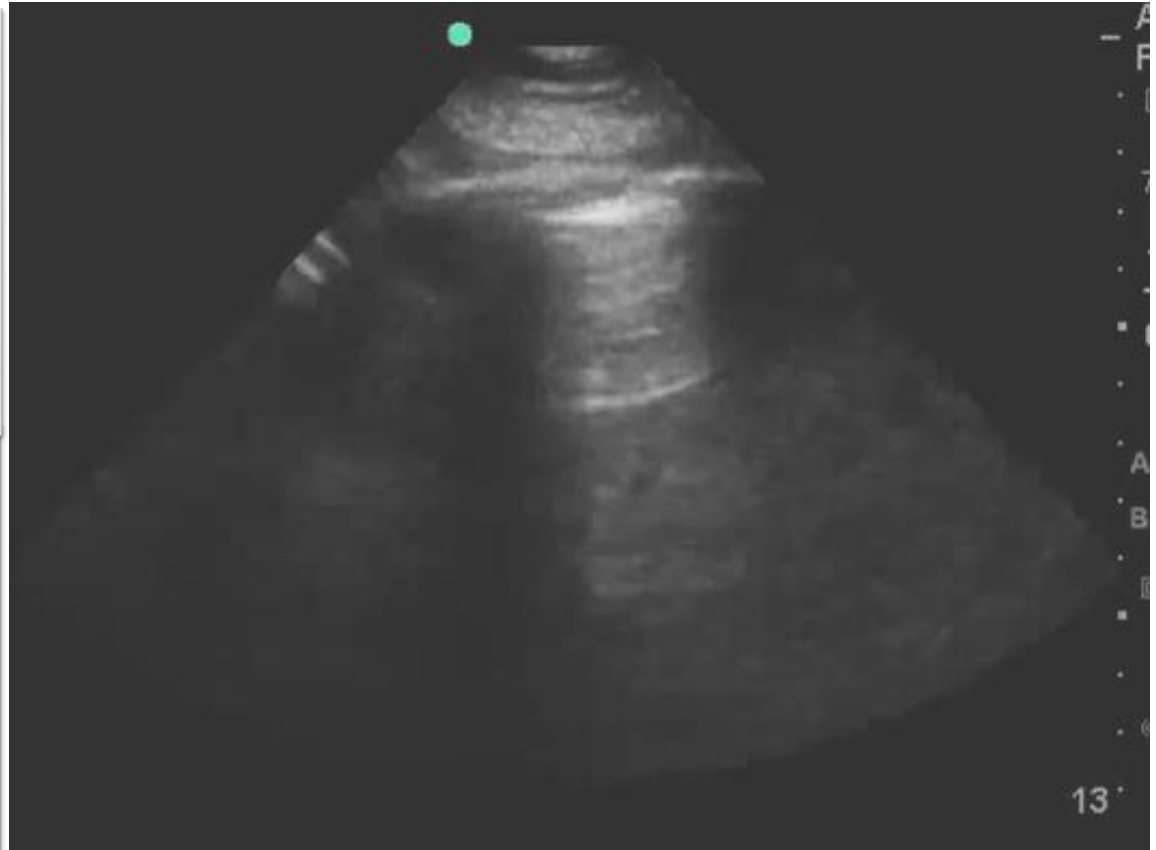
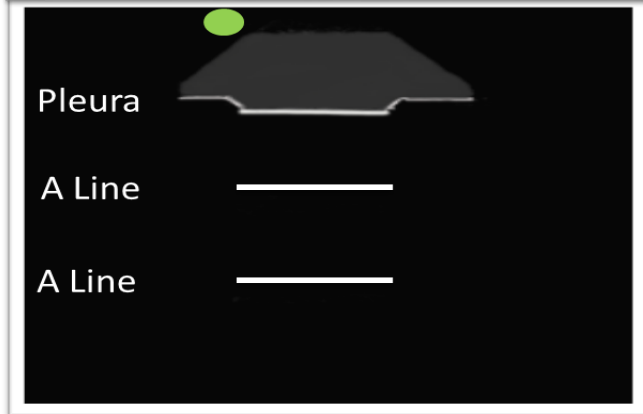
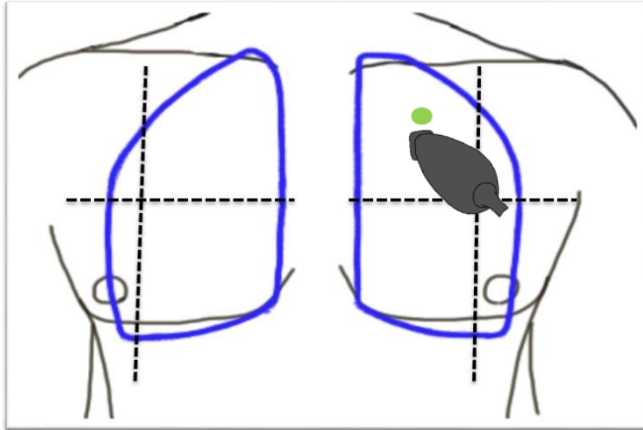
Case 2

Lung Ultrasound – Right Apex



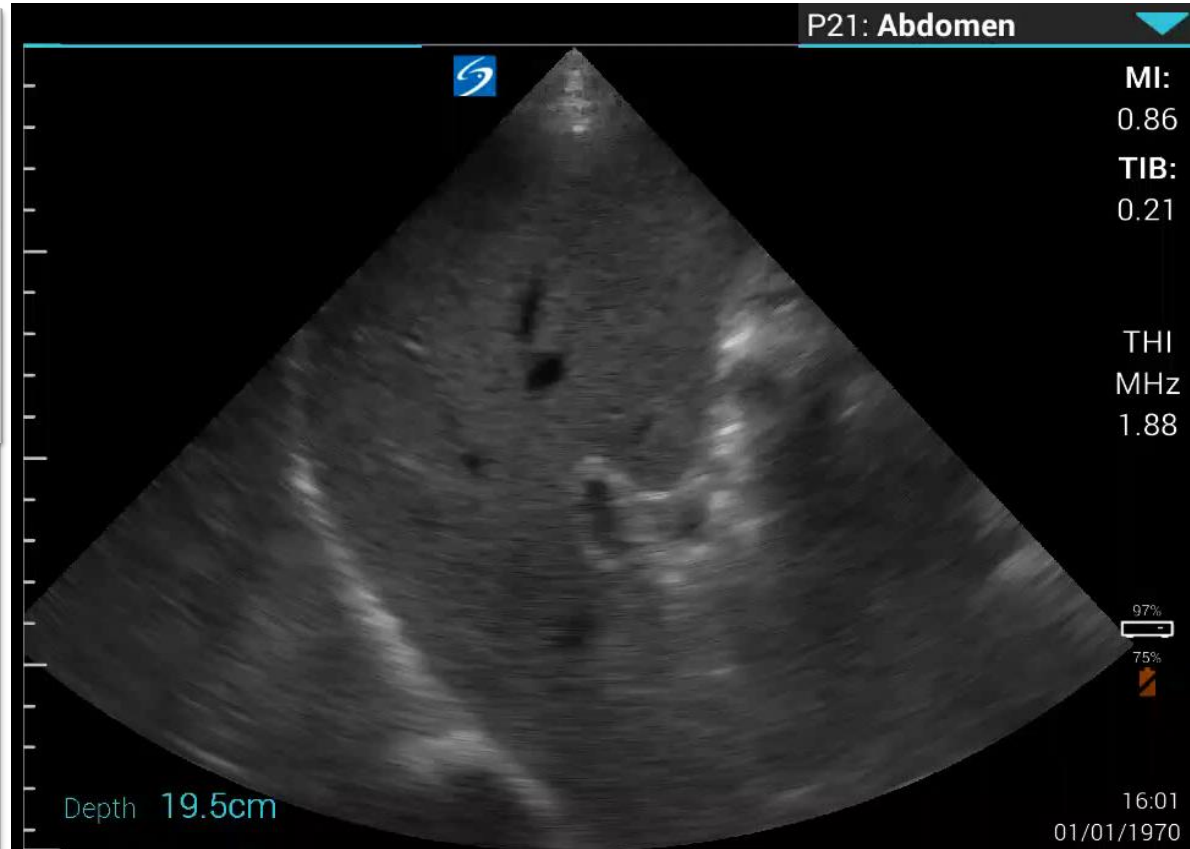
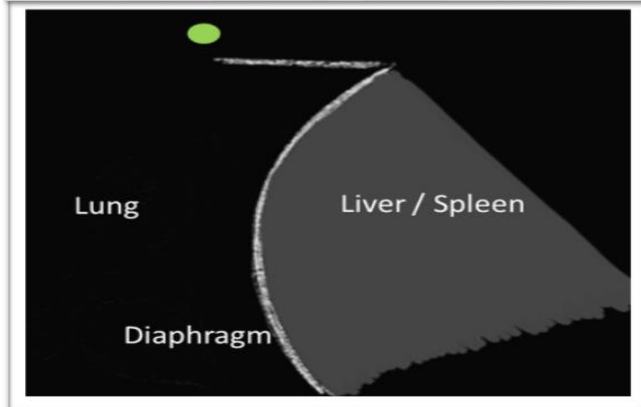
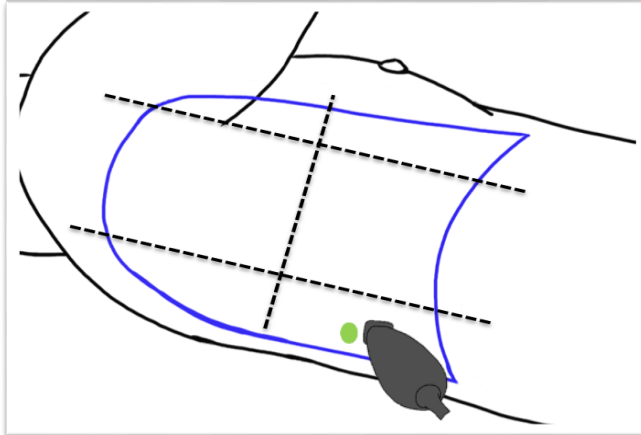
Case 2

Lung Ultrasound – Left Apex



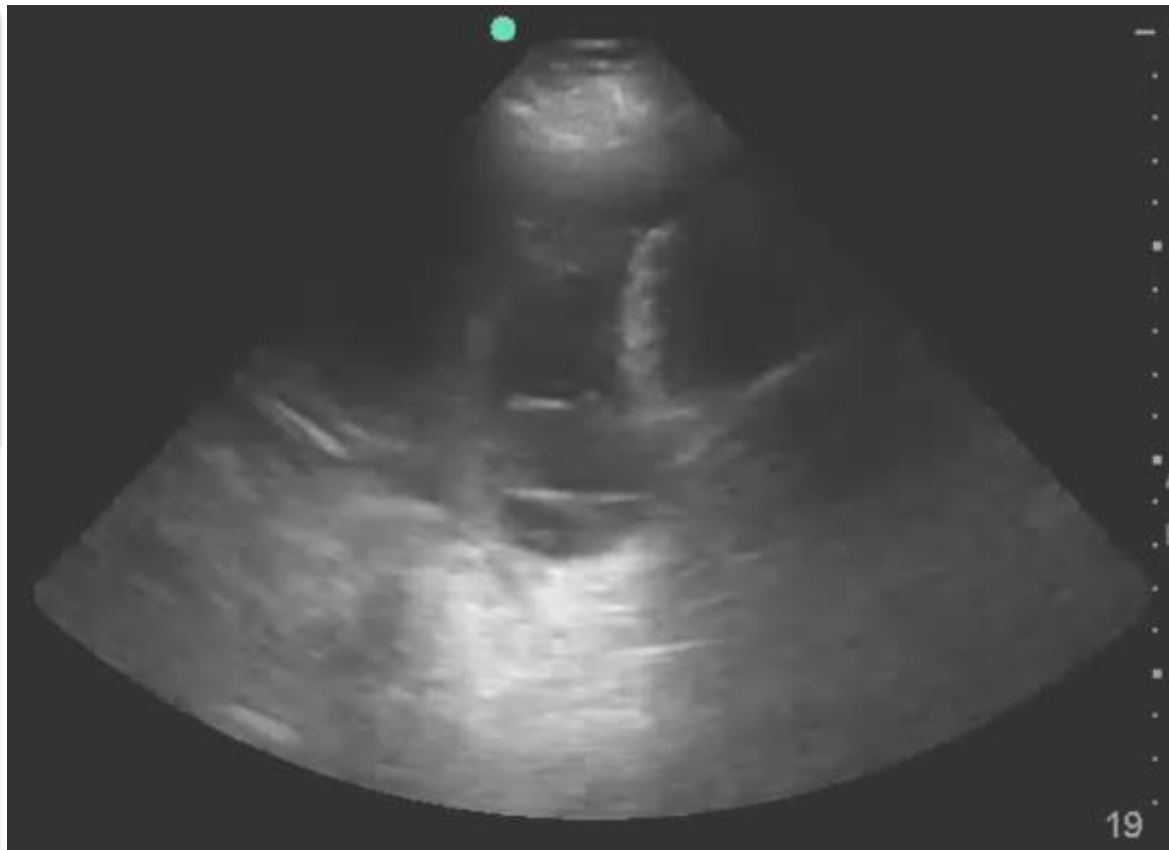
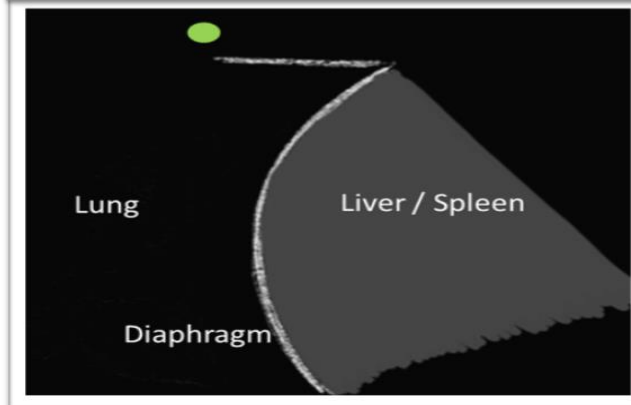
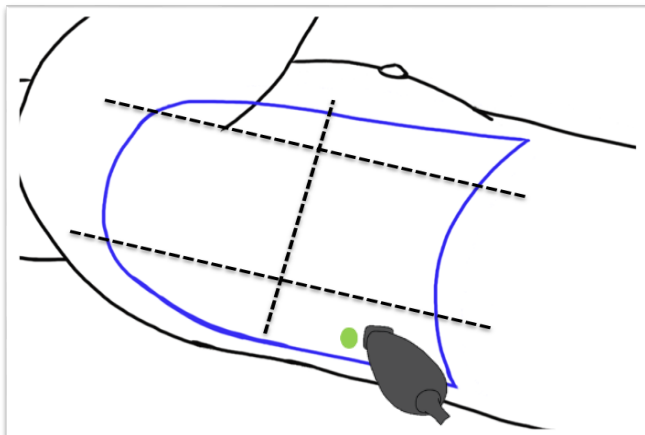
Case 2

Lung Ultrasound – Right Base



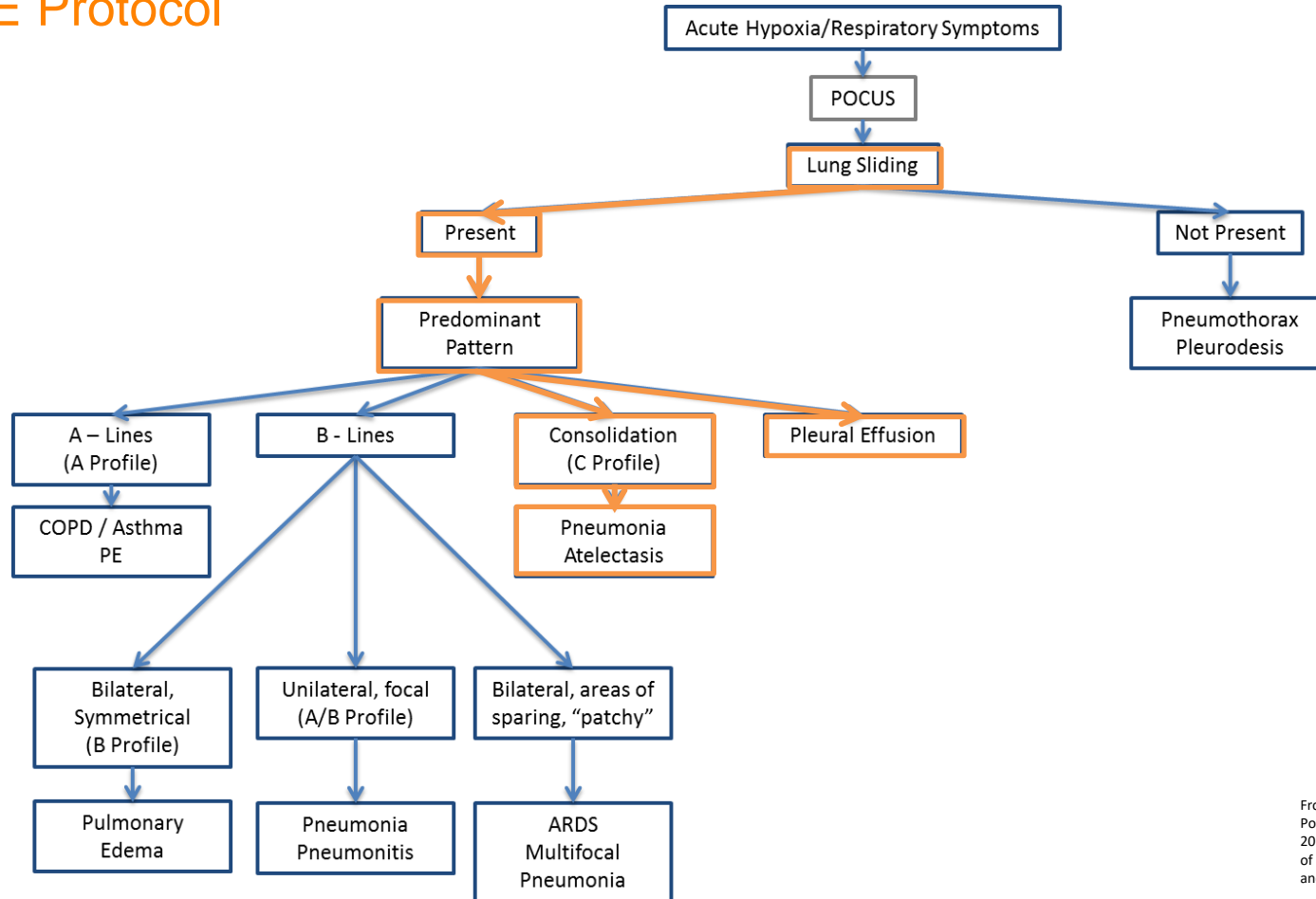
Case 2

Lung Ultrasound – Left Base



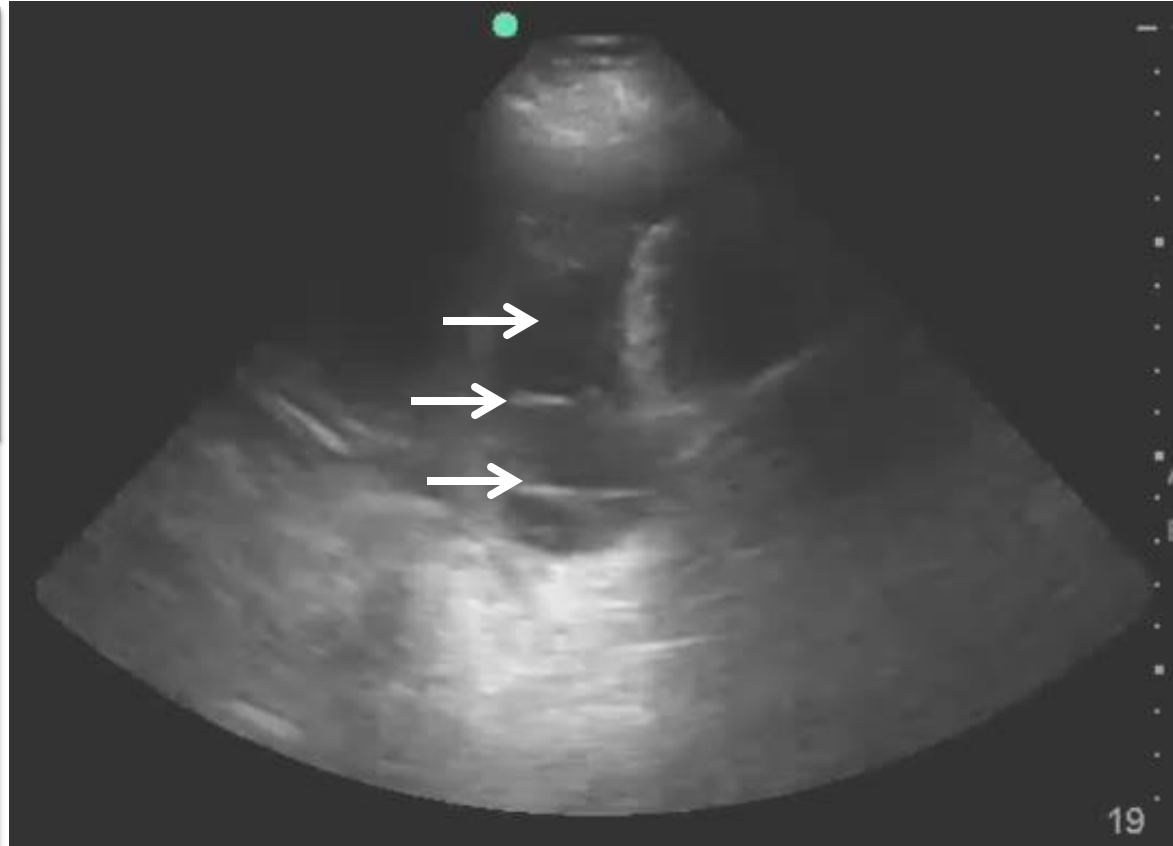
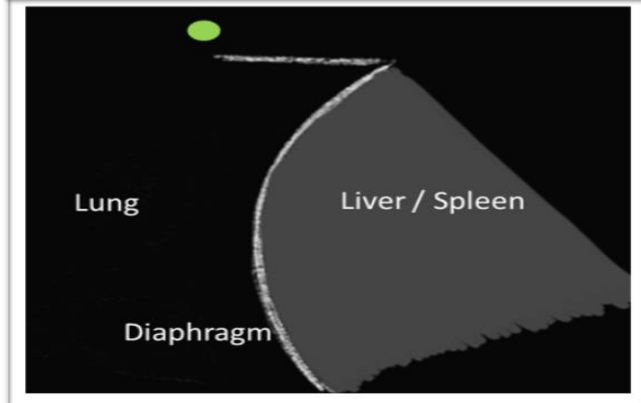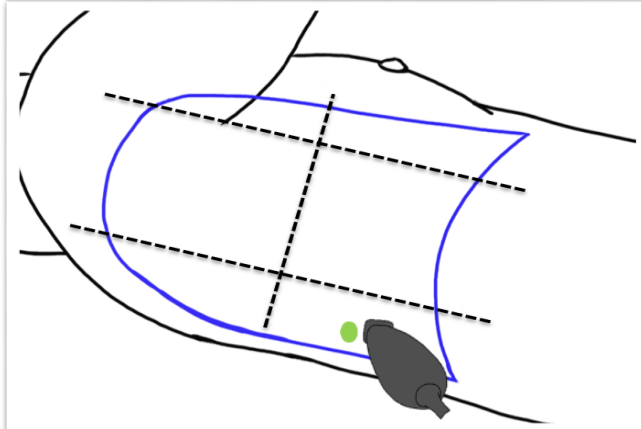
Case 2

BLUE Protocol



Case 2

Lung Ultrasound – Left Base



Case 2

Conclusion

- Based on POCUS she was diagnosed with complicated parapneumonic effusion, and probable empyema
 - Antibiotics were expanded to include anaerobic coverage.
 - STAT CT chest confirmed findings consistent with empyema.
 - Diagnostic / therapeutic thoracentesis with tube thoracostomy performed overnight.
 - VATS procedure performed 2 days later.

Lung Ultrasound & Pleural Effusion

Literature Review

- In the setting of parapneumonic effusion, Chest X-ray misses up to 10% of effusions warranting thoracentesis.
- Chest X-Ray only identifies only 70% loculated effusions, while POCUS identifies 94% (compared to CT)
- The American Association for Thoracic Surgery consensus guidelines for the management of empyema recommends routine use of ultrasound for evaluation of pleural space infections.

- Himelman R, Callen P. The Prognostic Value of Loculations in Parapneumonic Pleural Effusions. *Chest*. 1986; 90: 852–56.
- Svigals P, Chopra A, Rvenel J, Nietert P, Huggins J. The accuracy of pleural ultrasonography in diagnosing complicated parapneumonic pleural effusions. *Thorax*. 2017;72(1): 94-95.
- Shen K, Bribriescio A, Crabtree T, Denlinger C, Eby J, Eiken P, Jones D, Keshavjee S, Maldonado F, Paul S, Kozower B. The American Association for Thoracic Surgery consensus guidelines for the management of empyema. *The Journal of Thoracic and Cardiovascular Surgery*. 2017;153(6):129-146.

Case 3

HPI

- A 75 year-old gentleman, initially hospitalized for right lower extremity cellulitis, develops acute onset shortness of breath and relative hypotension on hospital day 3.
- Endorses:
 - Lightheadedness
 - Shortness of breath, cough, and yellowish sputum
 - Severe substernal chest pain, left sided.

Case 3

History

- Past Medical History:
 - CAD
 - Hypertension
 - Hyperlipidemia
 - Diabetes mellitus type II.
- Past Social History:
 - Smoker (50 pack years).
 - Daily alcohol use.

Case 3

Objective Findings

- Vital Signs:
 - HR 98, BP 98/51 (from 168/90), SpO2 81% on room air, RR 38, Tmax 37.7 Celcius.
- Physical Exam:
 - Mental – Alert, oriented. Moderate acute distress, appears uncomfortable.
 - Heart – Regular rhythm and rate.
 - Lungs – Course crackles at the bases (Left > Right).
 - Right lower extremity – erythema and swelling.

Case 3

Differential Diagnosis

- Hospital-Acquired Pneumonia
- Acute coronary syndrome
- Pulmonary edema
- Pleural effusions
- Pulmonary Embolism
- Pneumothorax

Focused Cardiac Ultrasound

Cardinal Views

- Parasternal Long Axis (PLAX)
- Parasternal Short Axis (PSAX)
- Apical 4 Chamber (A4C)
- Subcostal 4 Chamber (S4C)
- Inferior Vena Cava (IVC)

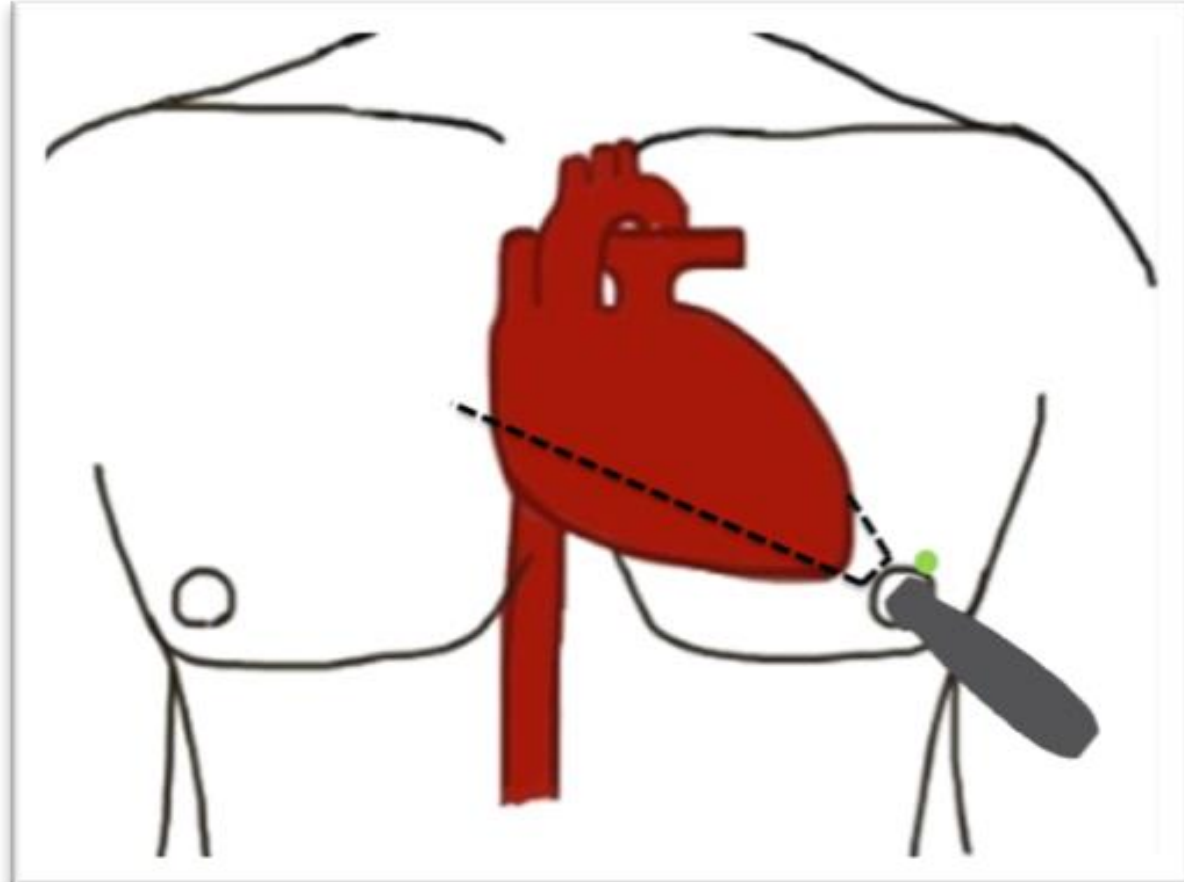
Focused Cardiac Ultrasound

Cardinal Views

- Parasternal Long Axis (PLAX)
- Parasternal Short Axis (PSAX)
- **Apical 4 Chamber (A4C)**
- **Subcostal 4 Chamber (S4C)**
- Inferior Vena Cava (IVC)

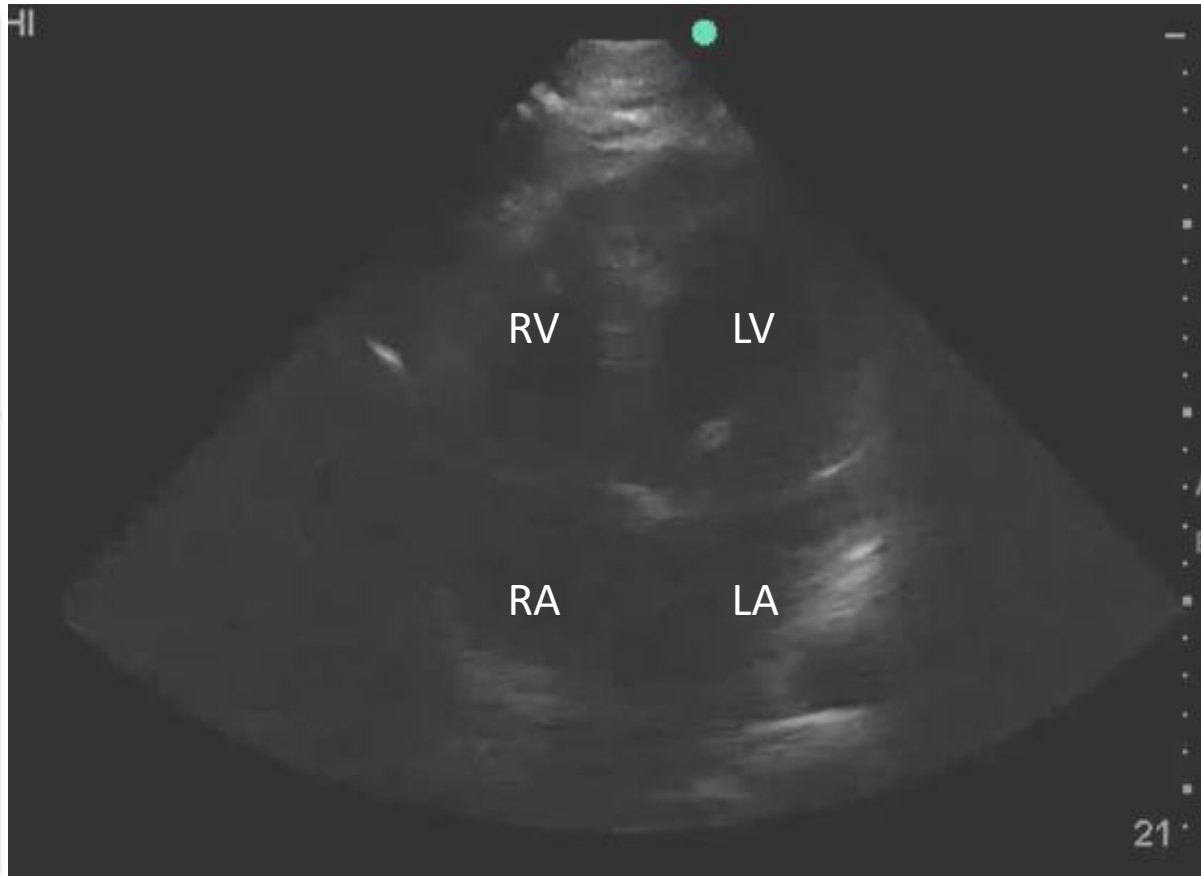
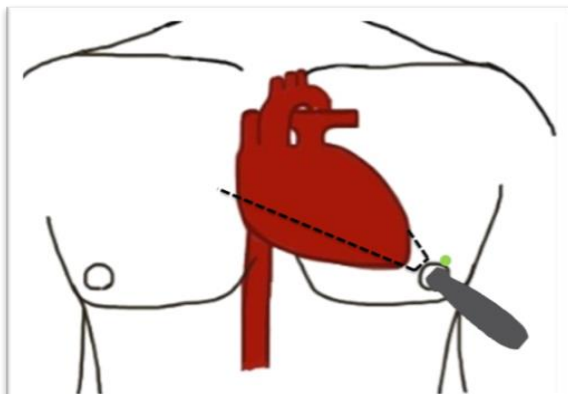
Focused Cardiac Ultrasound

Apical Four Chamber (A4C)



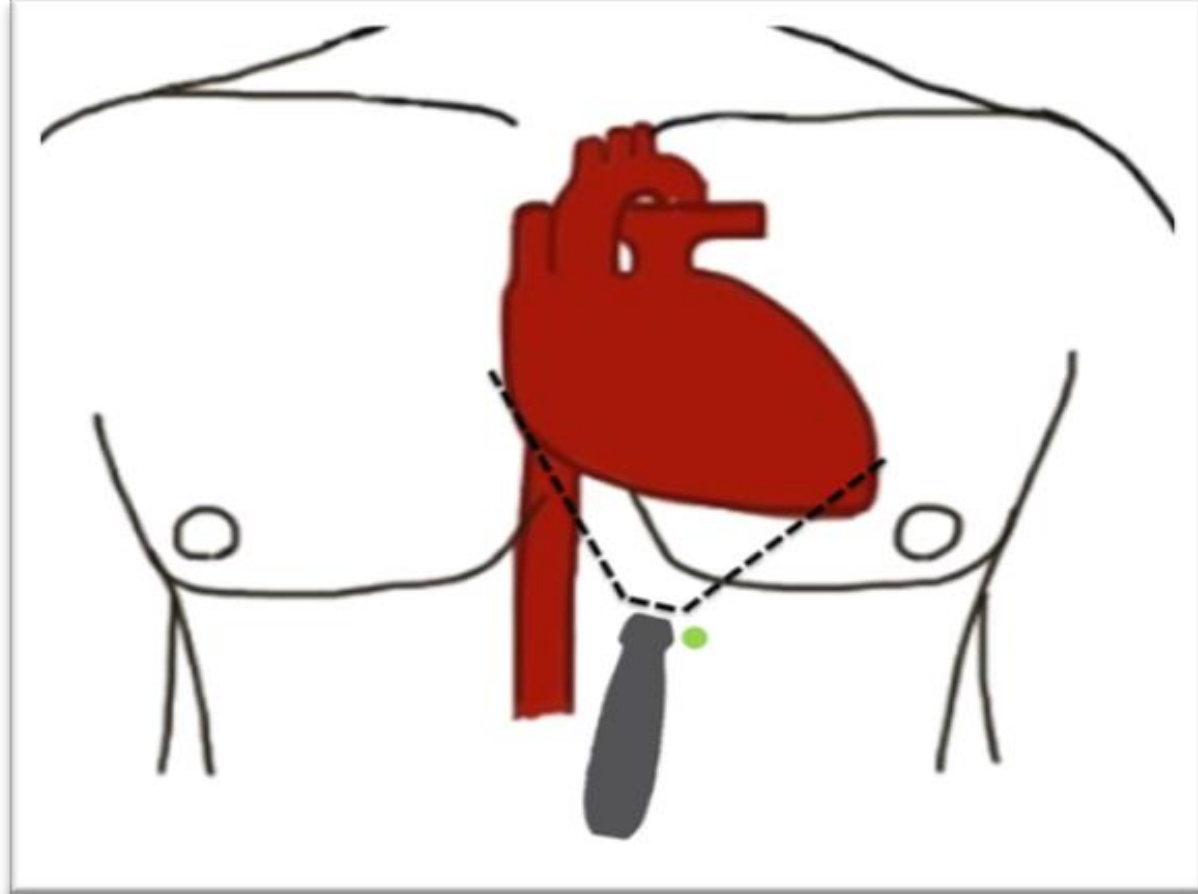
Focused Cardiac Ultrasound

Apical Four Chamber (A4C)



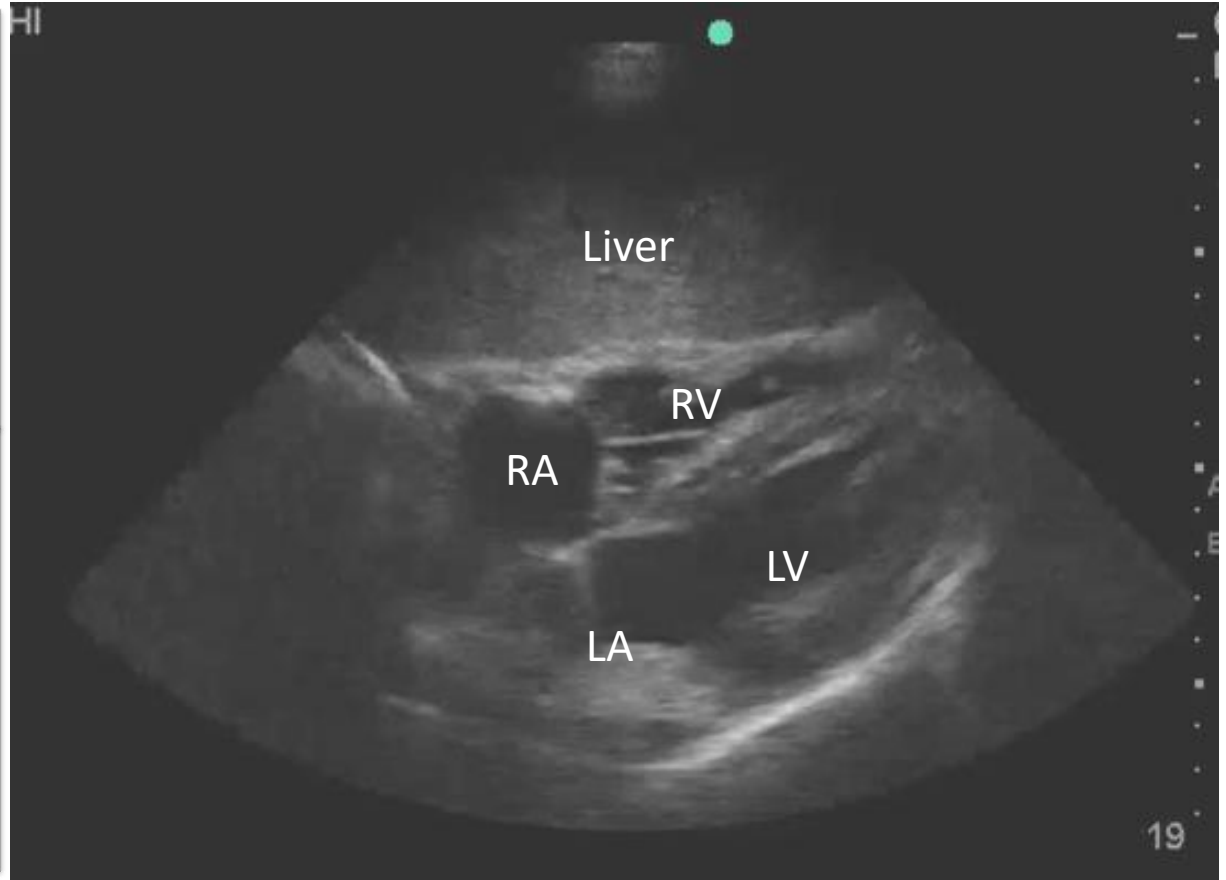
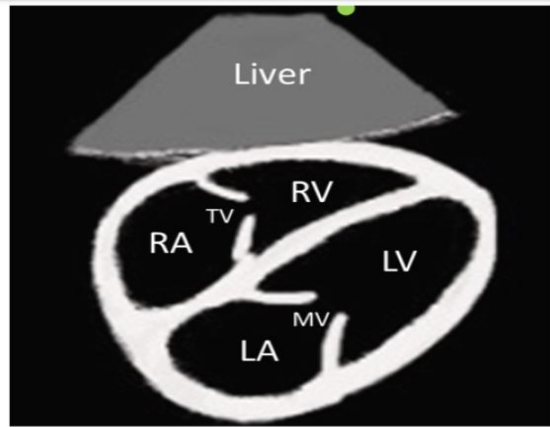
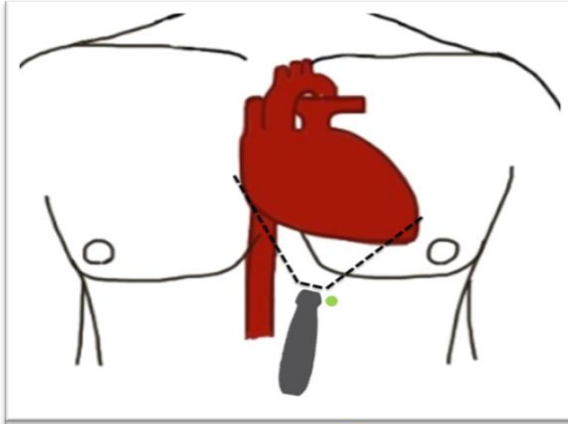
Focused Cardiac Ultrasound

Subcostal Four Chamber (S4C)



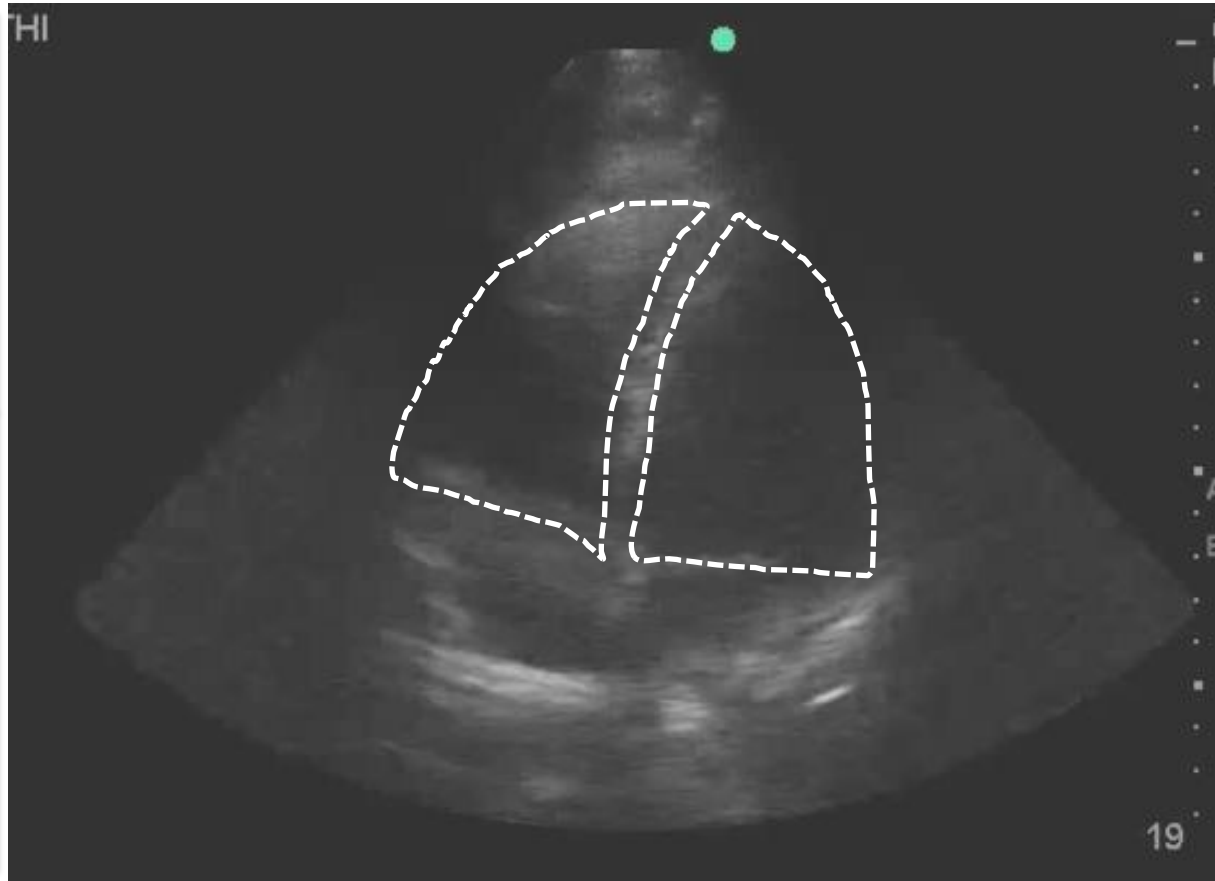
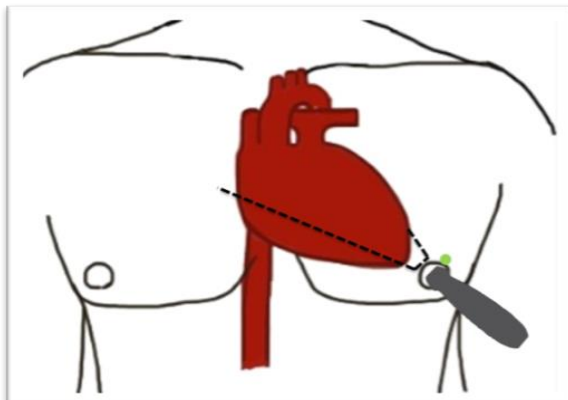
Focused Cardiac Ultrasound

Subcostal Four Chamber (S4C)



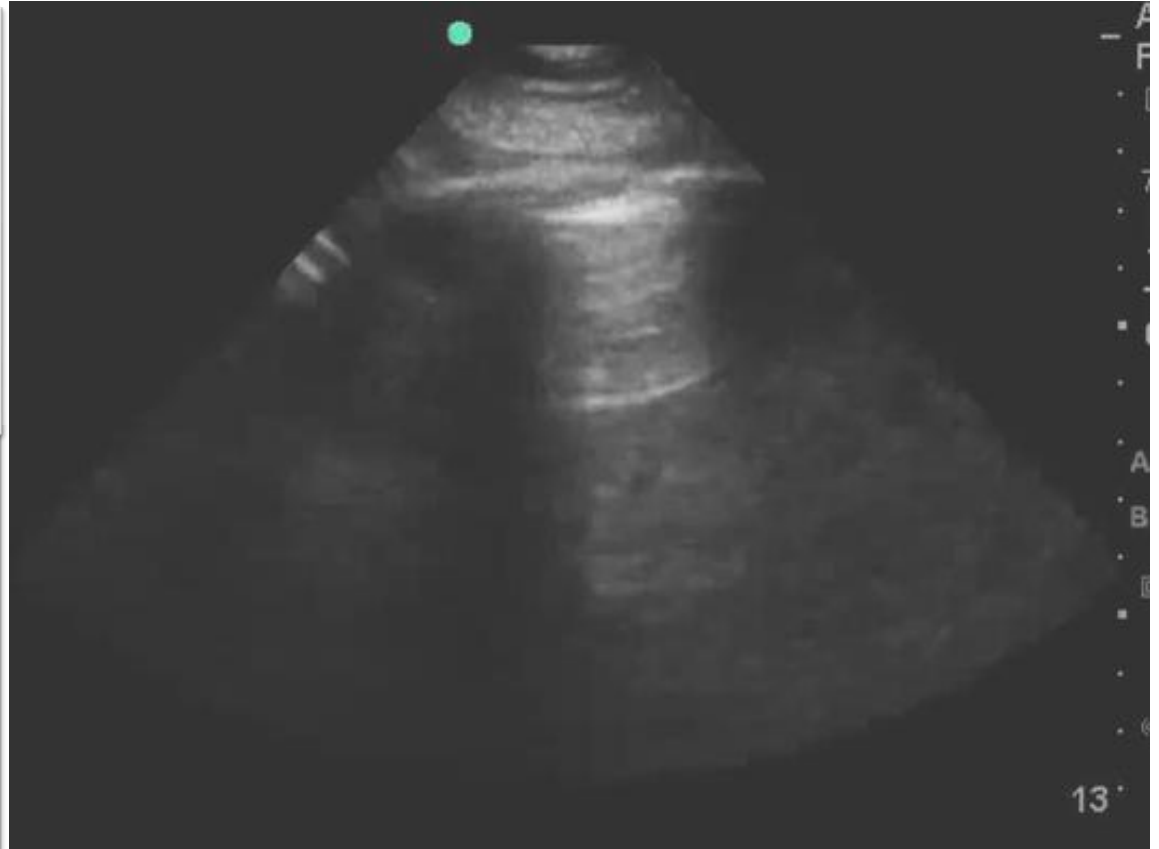
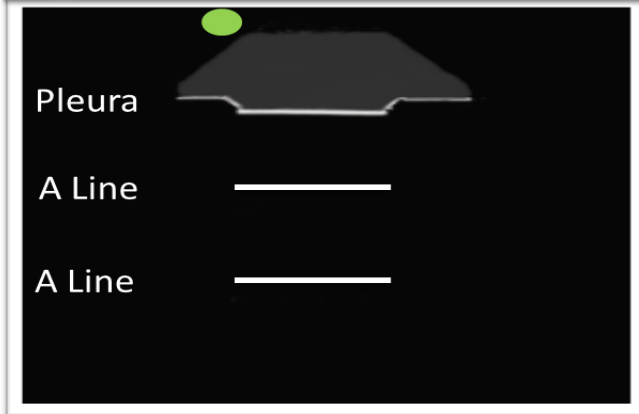
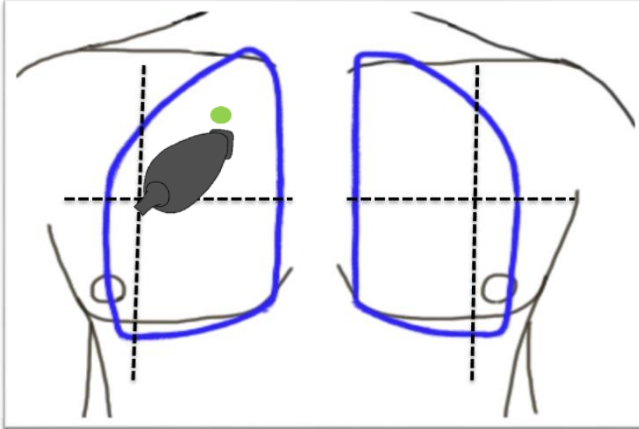
Case 3

Apical Four Chamber (A4C)



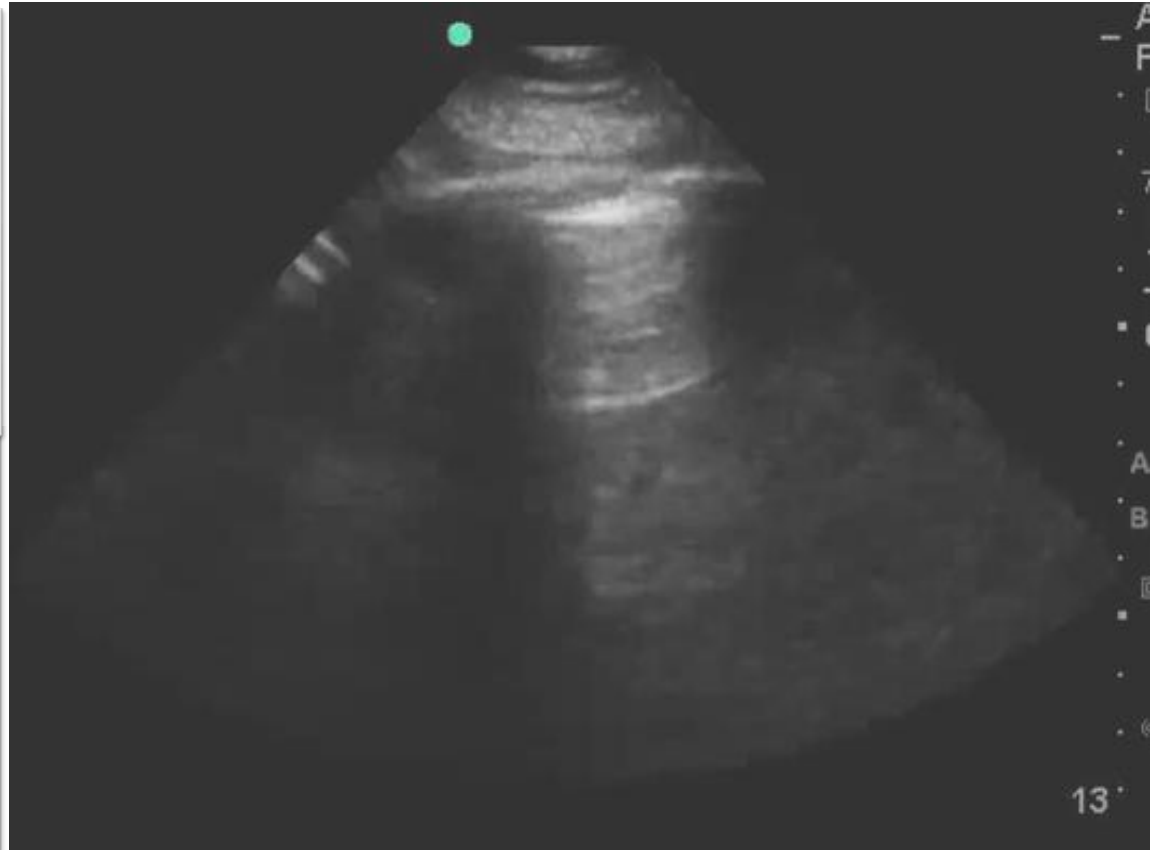
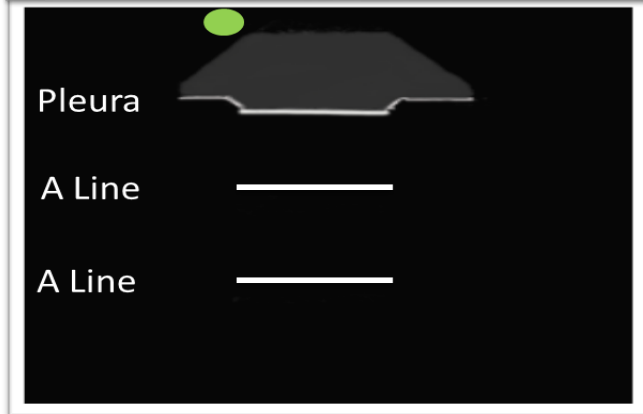
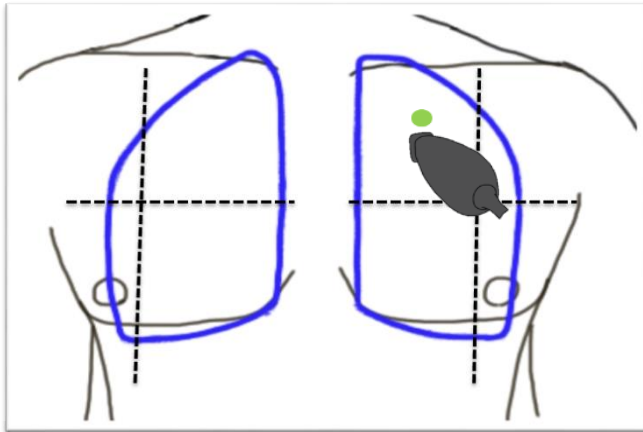
Case 2

Lung Ultrasound – Right Apex



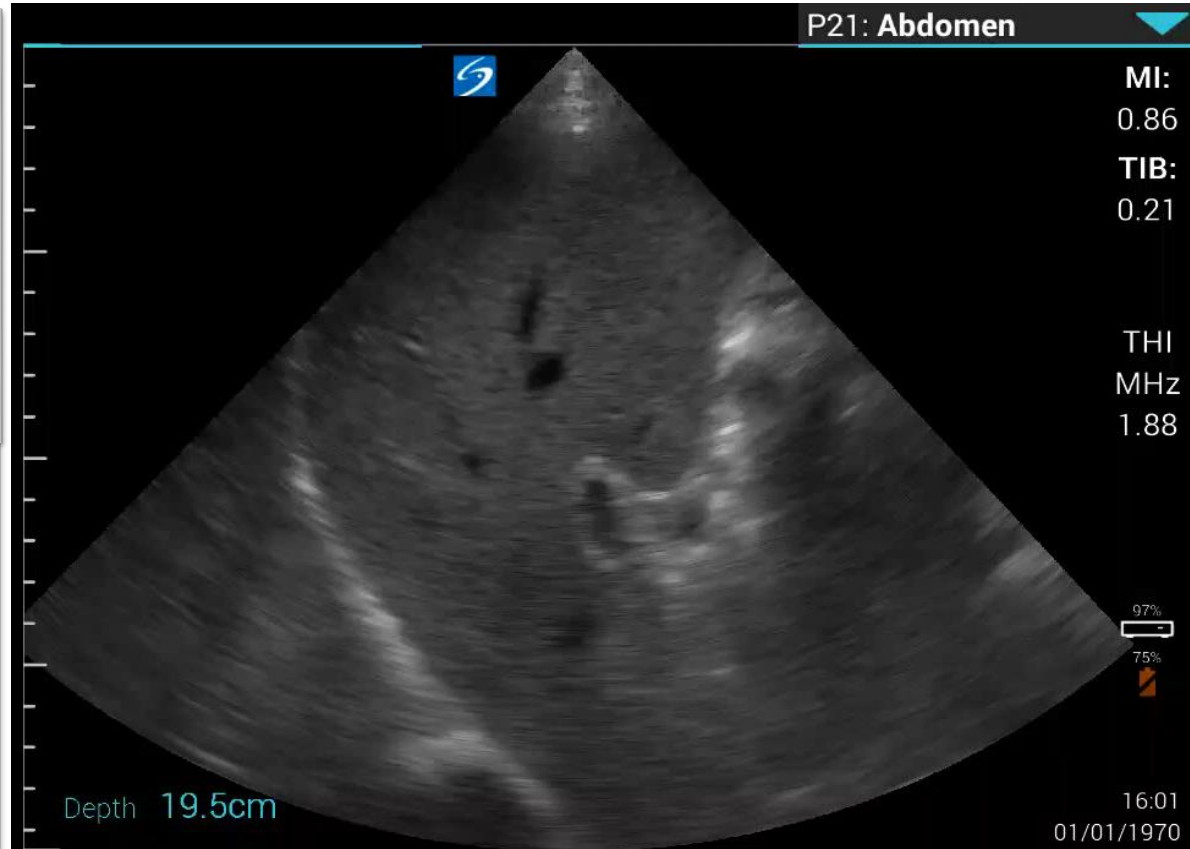
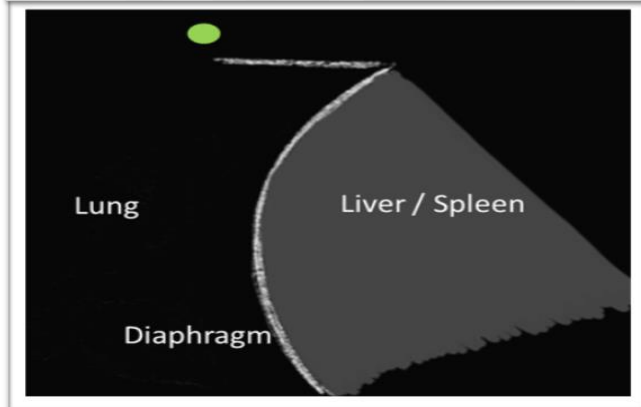
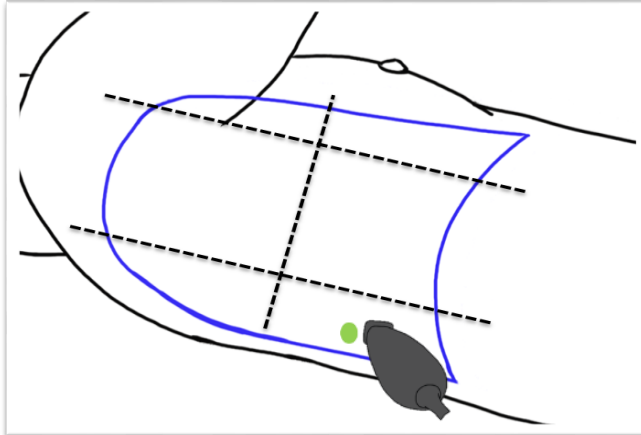
Case 2

Lung Ultrasound – Left Apex



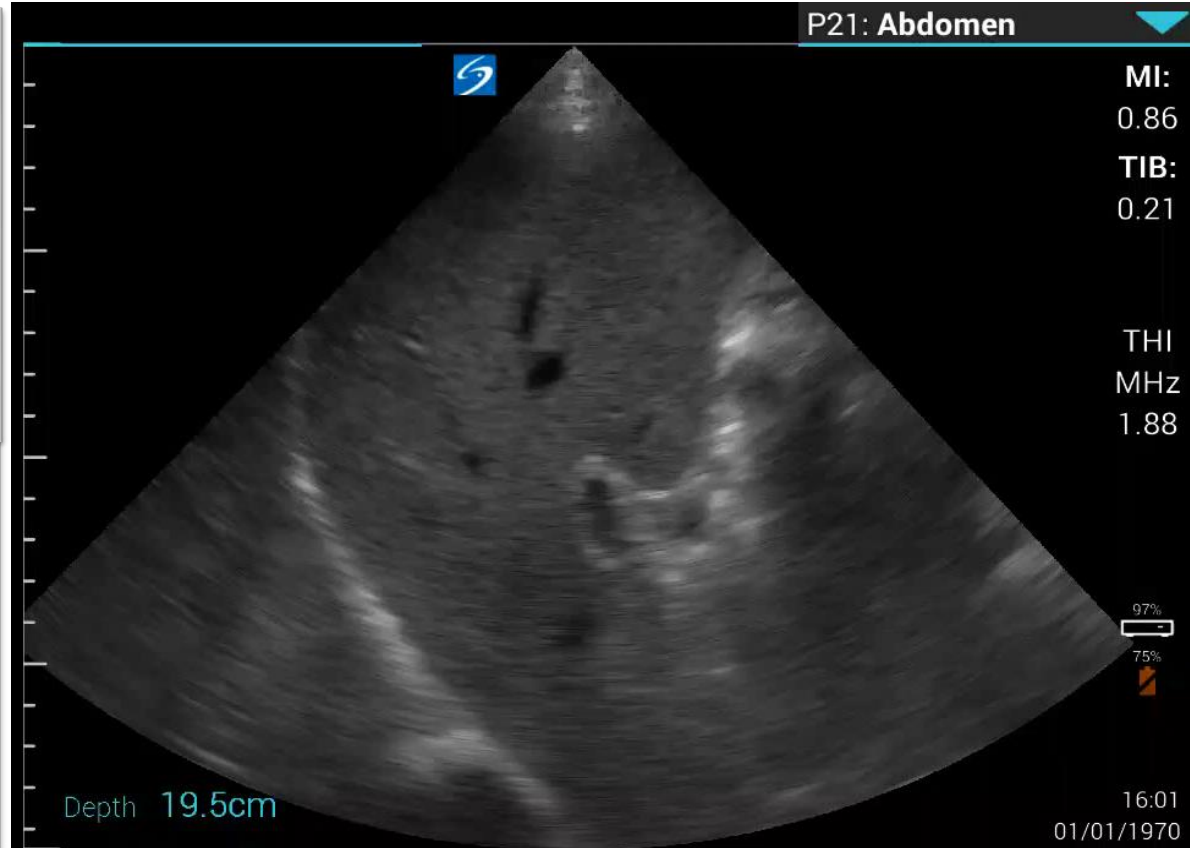
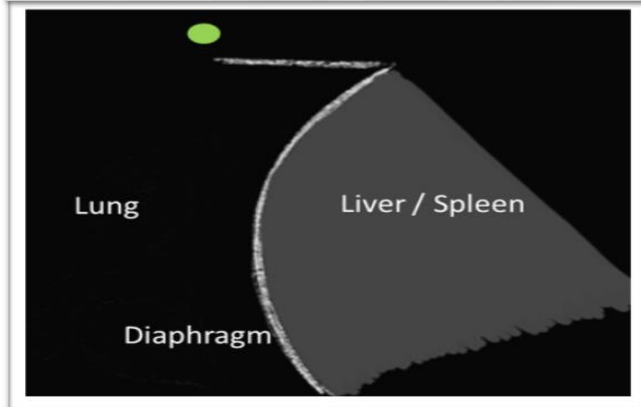
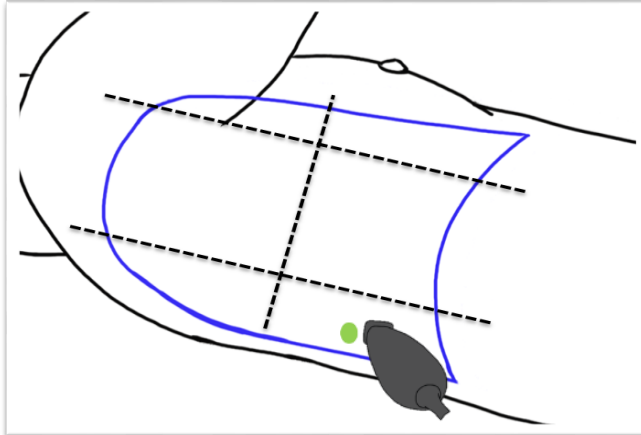
Case 2

Lung Ultrasound – Right Base



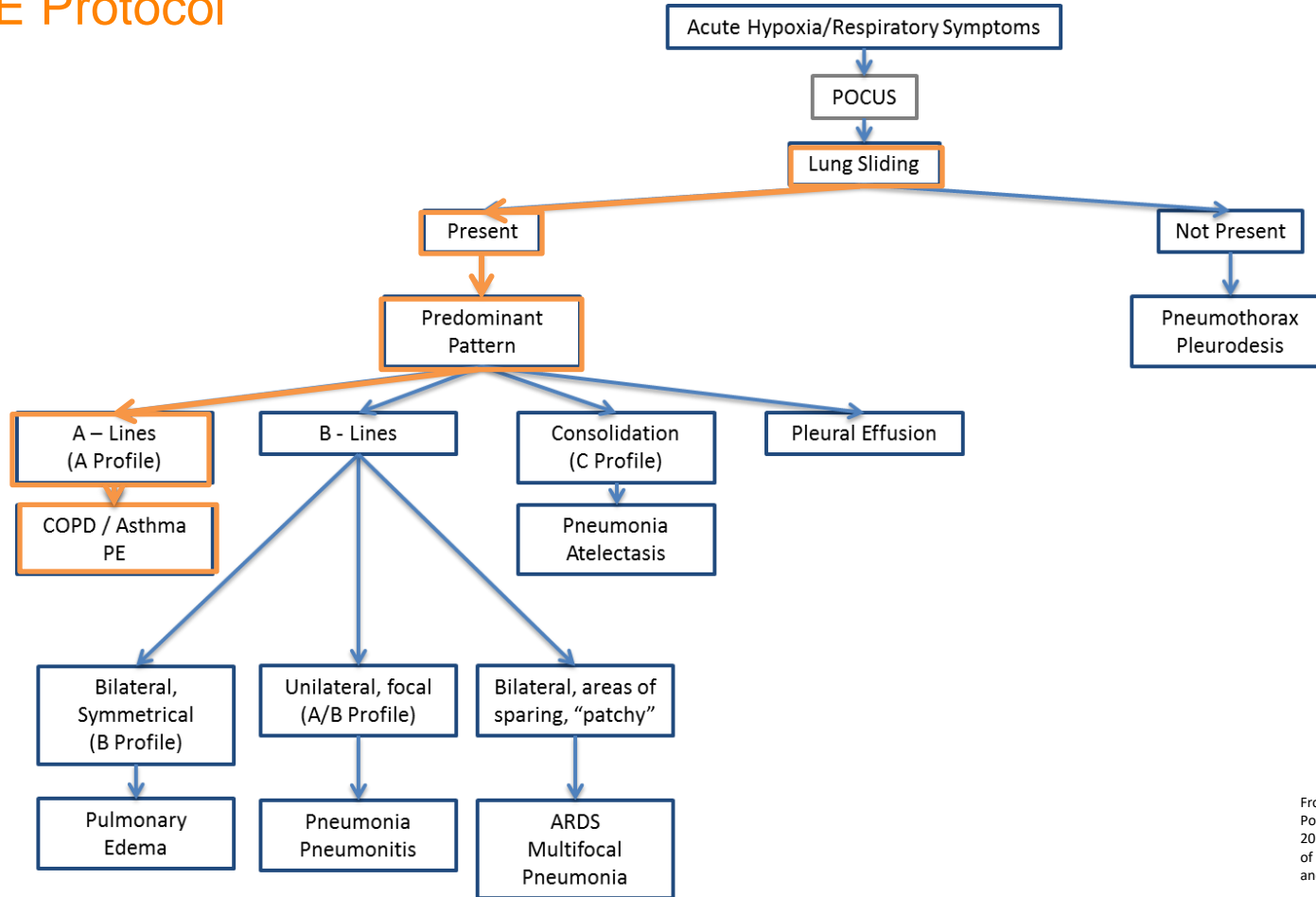
Case 2

Lung Ultrasound – Left Base



Case 3

BLUE Protocol



Vascular Ultrasound

Proximal Lower Extremity DVT Exam

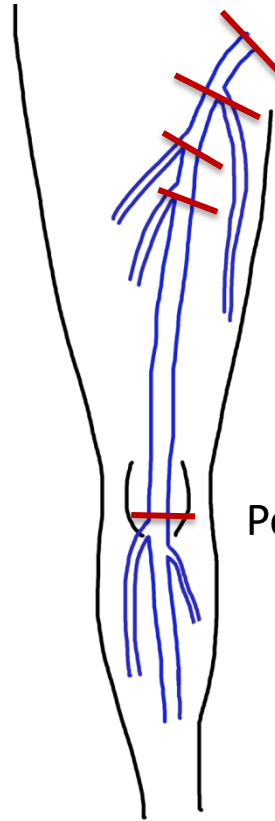
- Compressive ultrasonography
 - Compressible veins = Normal
 - Non-compressible veins = abnormal (probable DVT)
- 2 point vs 3 point vs 5 point exam vs compression every 1-2 cm.

Vascular Ultrasound

Proximal Lower Extremity DVT Exam

Common Femoral Vein – Greater saphenous vein anastomosis

Bifurcation of the Common Femoral Vein into the superficial and deep femoral veins



Common Femoral Vein

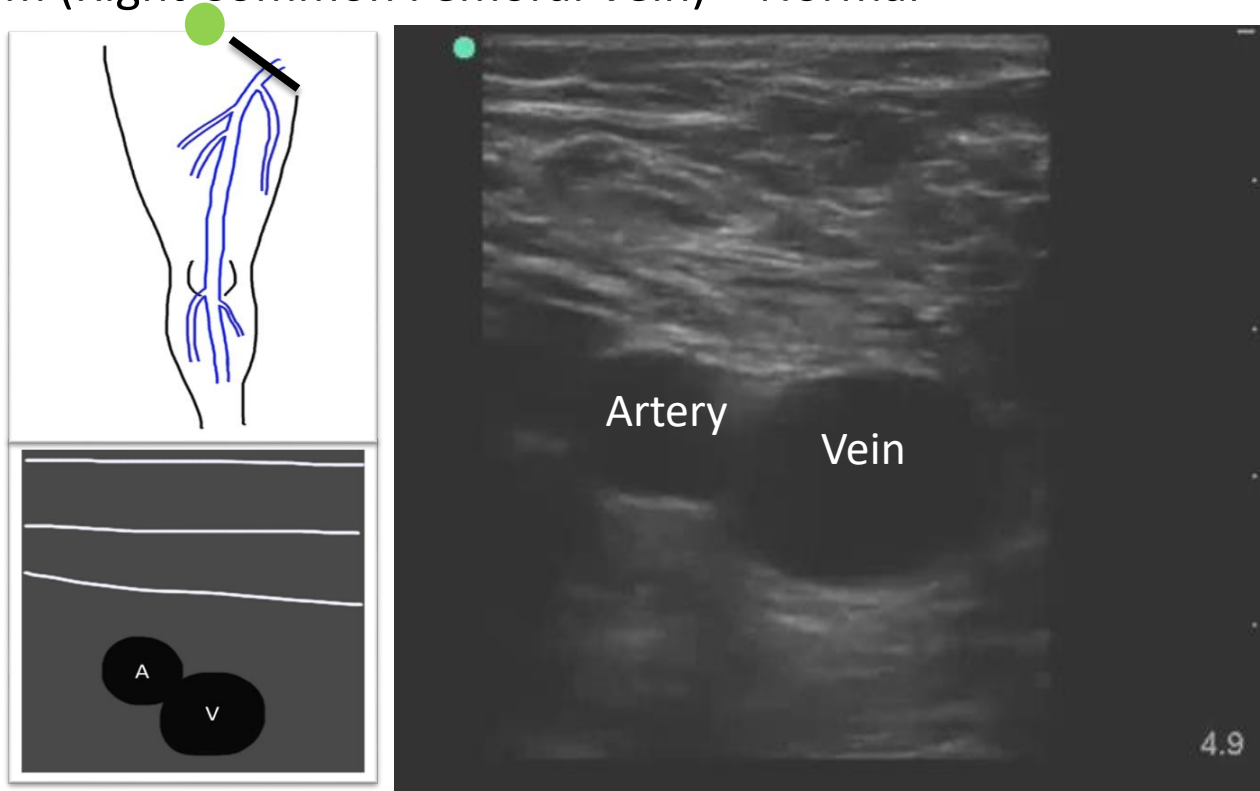
Common Femoral Vein – Lateral perforator anastomosis

Popliteal vein

Vascular Ultrasound

Proximal Lower Extremity DVT Exam

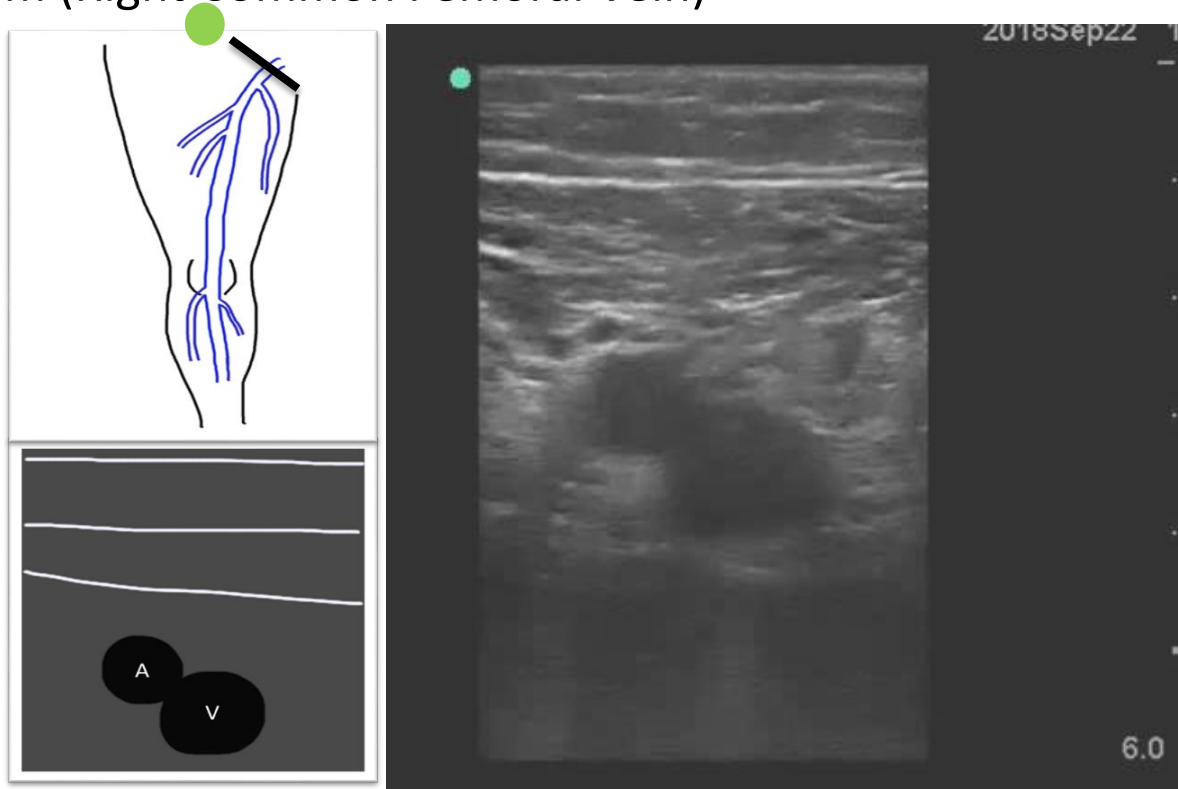
- DVT Exam (Right Common Femoral Vein) – Normal



Case 3

Proximal Lower Extremity DVT Exam

- DVT Exam (Right Common Femoral Vein)



Case 3

Conclusion

- POCUS
 - Acute RV enlargement + A line predominant Pattern + RLE DVT.
- Patient transferred to the ICU with suspicion for obstructive shock from PE.
 - CTA chest demonstrated bilateral saddle emboli.
 - Thrombolytics administered, with improvement in patients clinical status.

Venous Thromboembolic Disease

Literature Review

- DVT
 - Sensitivity: 96.1%
 - Specificity: 96.8%
- Multi-organ (Heart, Lung, DVT) POCUS for PE
 - Sensitivity: 90%
 - Specificity: 86.2%

****Not a replacement for CT****

- Pomero F, Dentali F, Borretta V, Bonzini M, Melchio, Douketis, JD, Fenoglio. Accuracy of emergency physician-performed ultrasonography in the diagnosis of deep-vein thrombosis: a systematic review, meta-analysis. *Thromb Haemost* 2013; 109(01): 137-145.
- Nazerian P, Vanni S, Volpicelli G, et al. Accuracy of point-of-care multiorgan ultrasonography for the diagnosis of pulmonary embolism. *Chest*. 2014;145(5):950-957.

Conclusion

POCUS is Awesome

- Physics
- Case 1
 - POCUS > CXR (and H&P) for diagnosis pulmonary pathology.
 - POCUS can help with discharge planning / risk stratification.
- Case 2
 - POCUS > CXR for characterizing pleural space pathology.
 - POCUS is recommended by the American Thoracic Society for evaluating pleural space infections.
- Case 3
 - POCUS is accurate for diagnosis of DVT and can aid in identifying PE.

Advanced POCUS

Questions?

Breunig.michael@mayo.edu