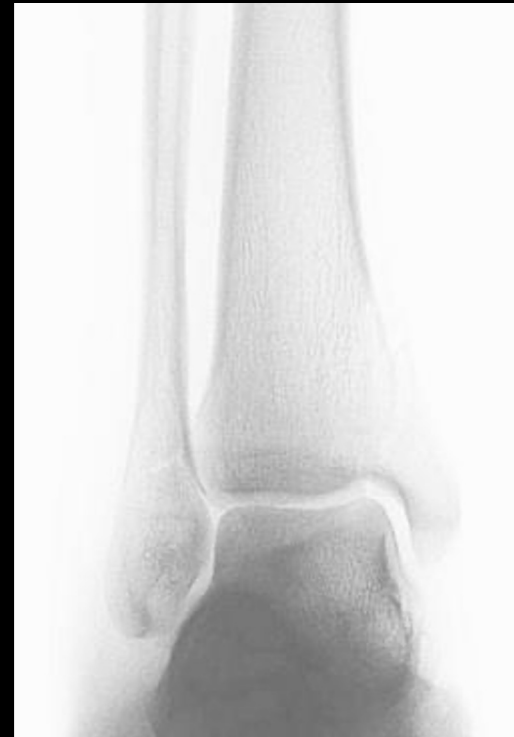
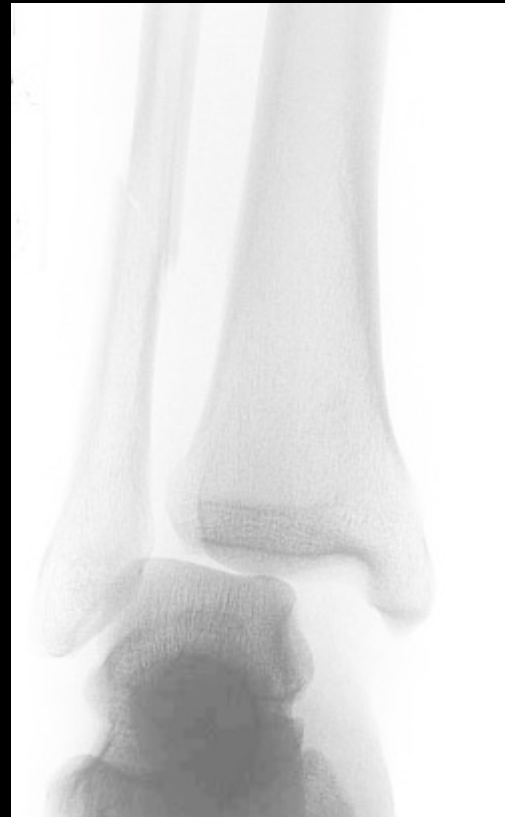
F&A Management and Evaluation of Bimalleolar Equivalent Ankle Injuries

Phillip Schneider, MD

Chief, Orthopaedic Surgery and Podiatry
Blanchfield ACH
Ft. Campbell, KY



Disclosures

- I have no actual or potential conflict of interest in relation to this program/presentation.

F&A Management and Evaluation of Bimalleolar Equivalent Ankle Injuries



Phillip Schneider, MD

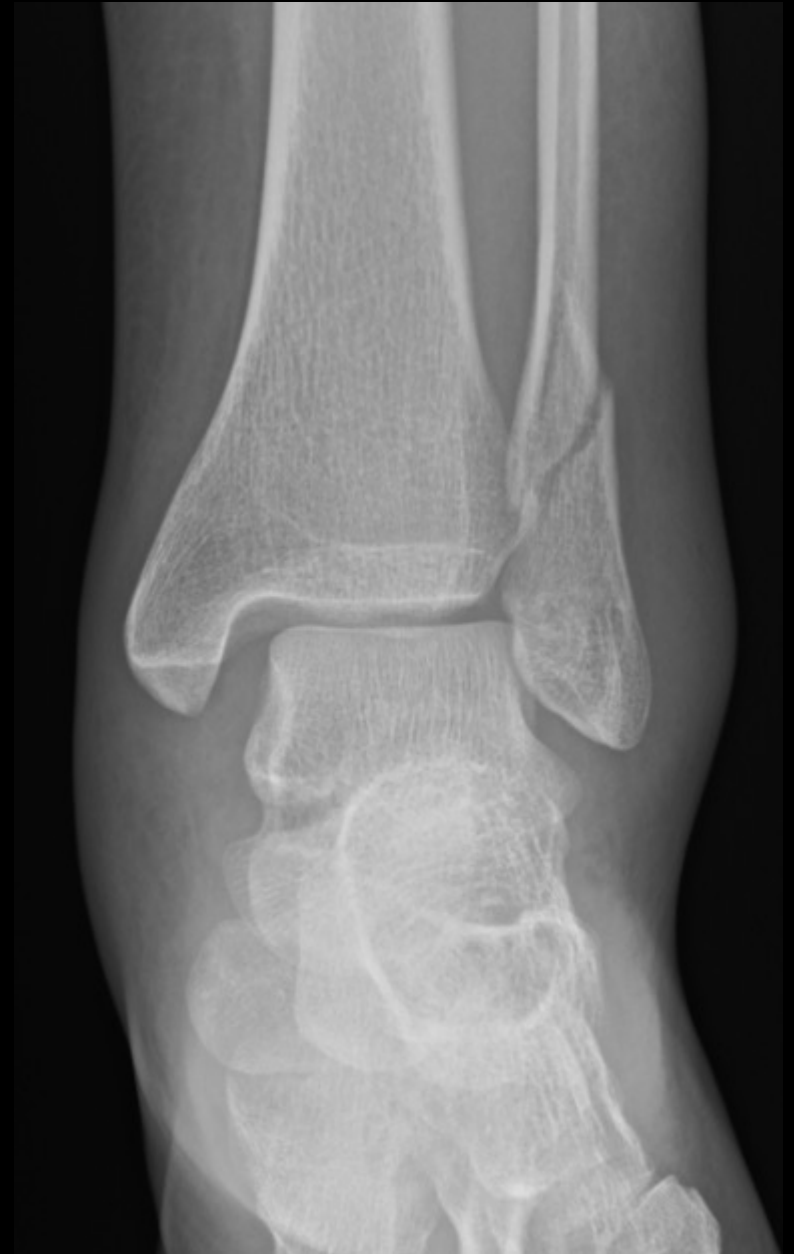

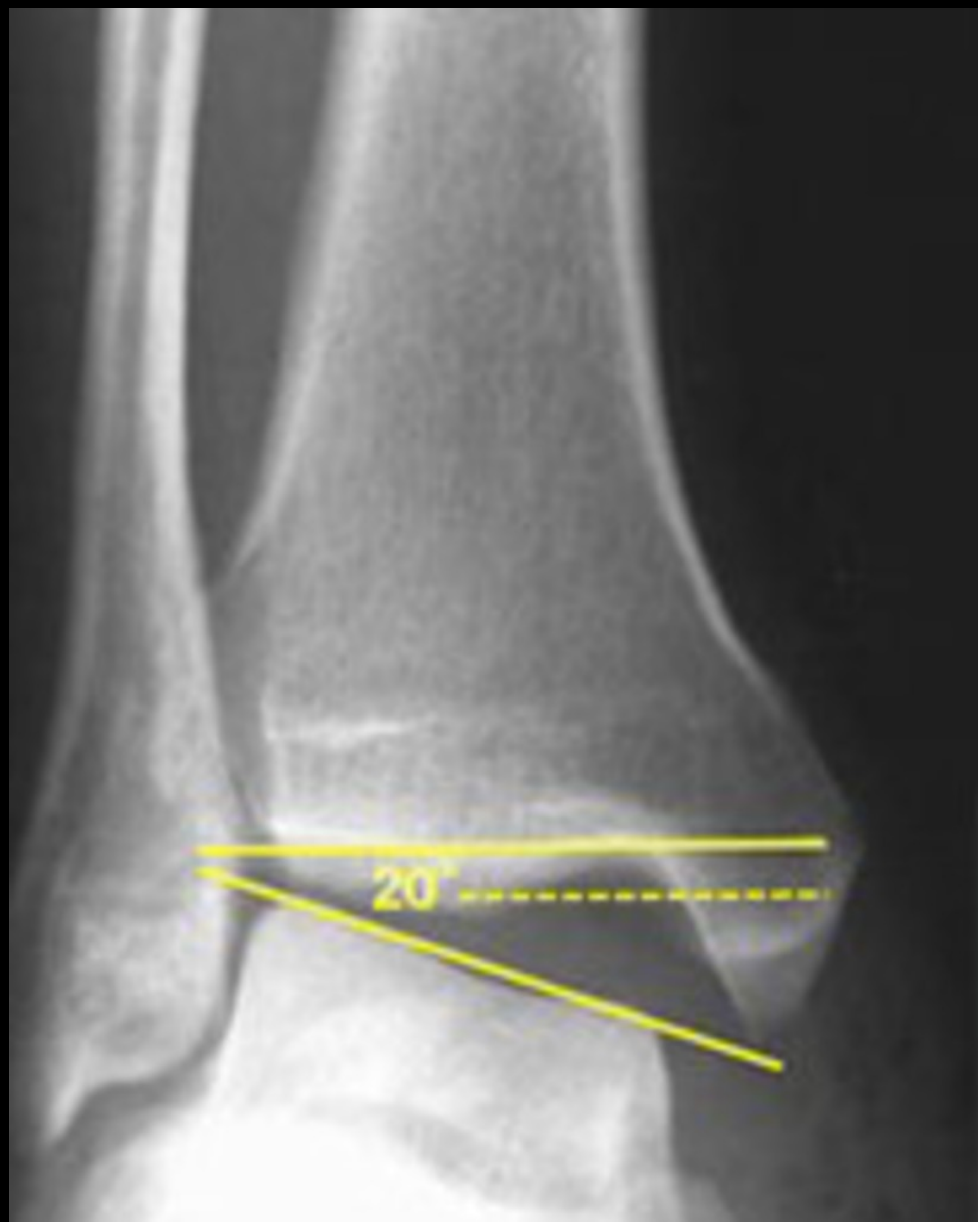PAOS 2023

ORTHO IN INDY

What is a bimalleolar equivalent ankle fracture?

- Fracture of the lateral malleolus (fibula) with presence of a medial ligamentous (deltoid) injury.
- Last stage of SER IV ankle fracture results in either medial mal fracture or deltoid injury





Clinical Evaluation:

HISTORY

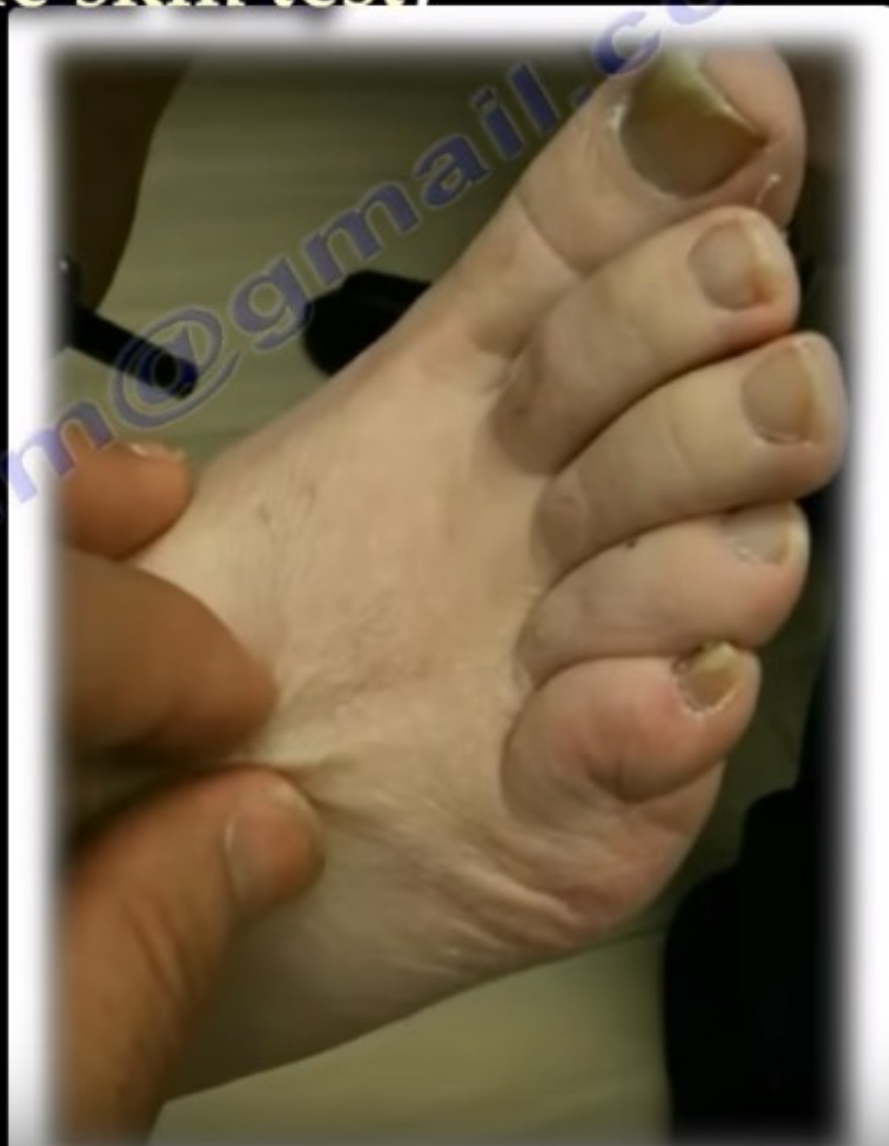- Mechanism
- Timing
- Soft-tissue injury
- Bone quality
- Comorbidities
- Associated Injuries

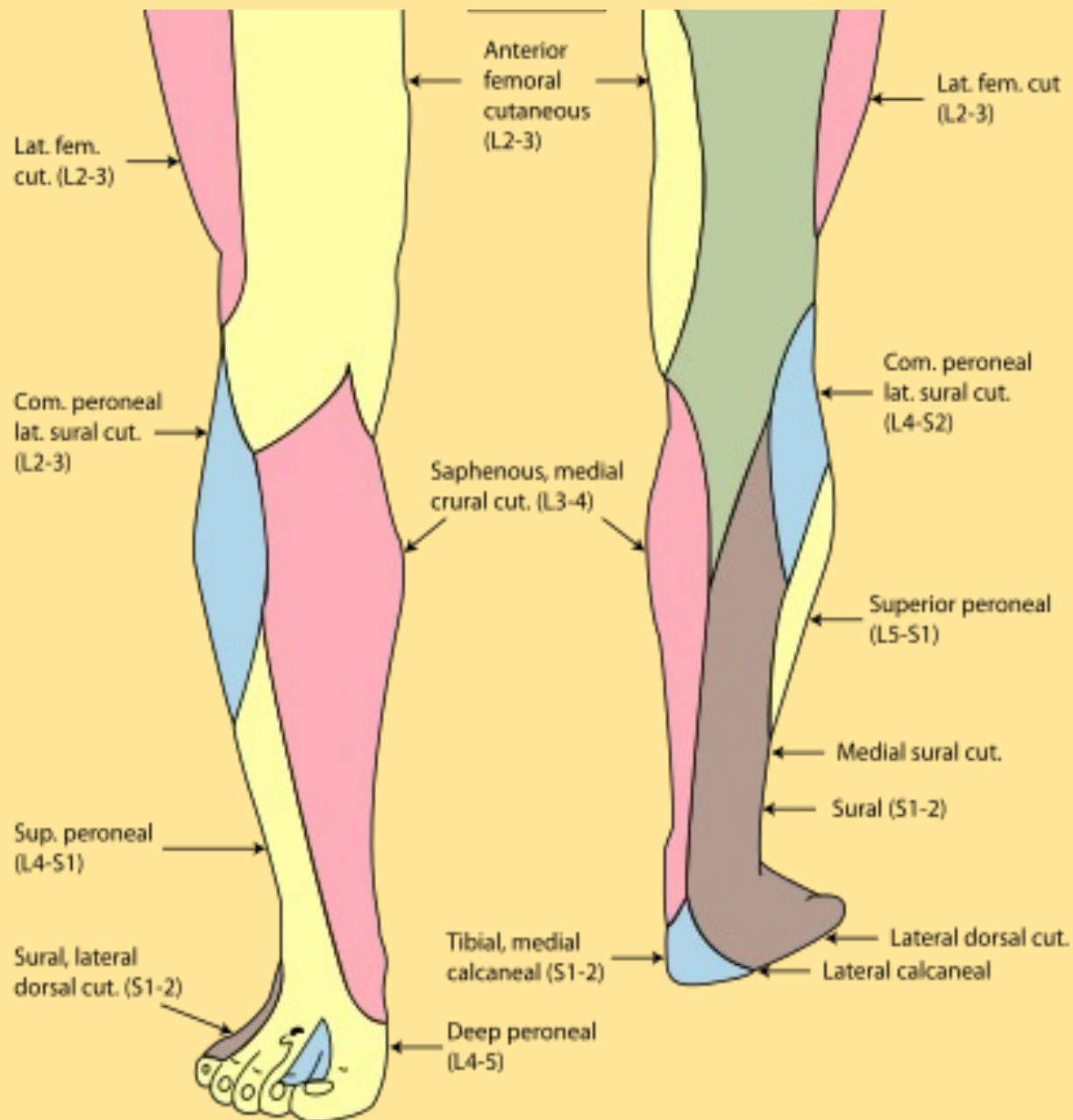
PHYSICAL EXAM

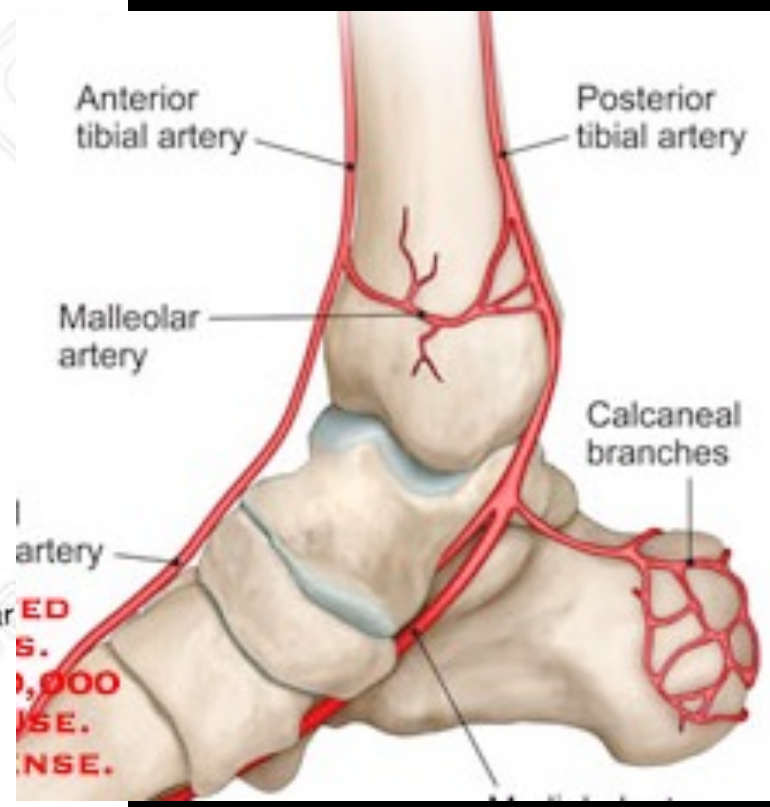
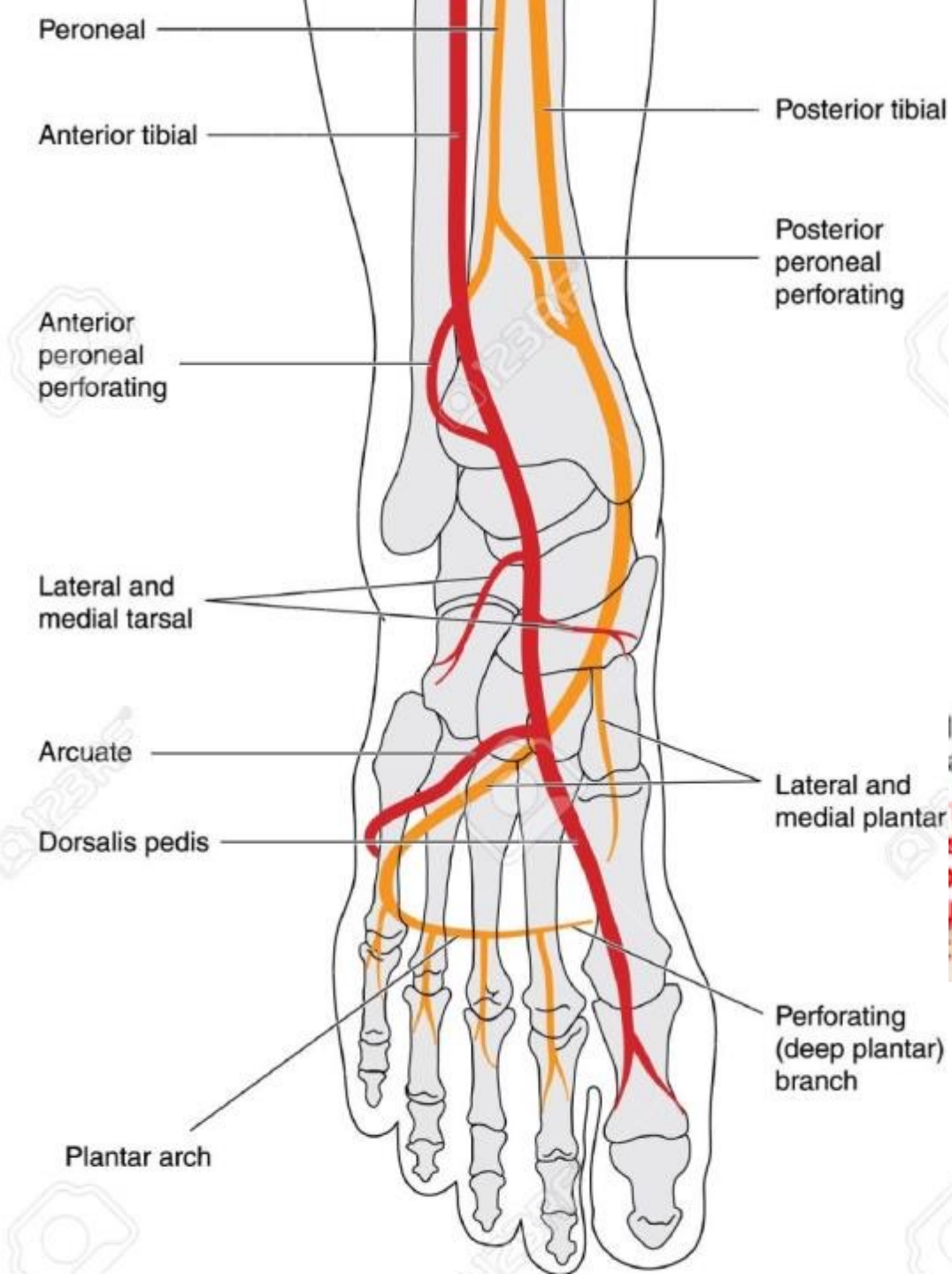
- Skin
- Nerves
- Vasculature
- Pain
- Deformity

Swelling of the Ankle and Leg (wrinkle skin test)

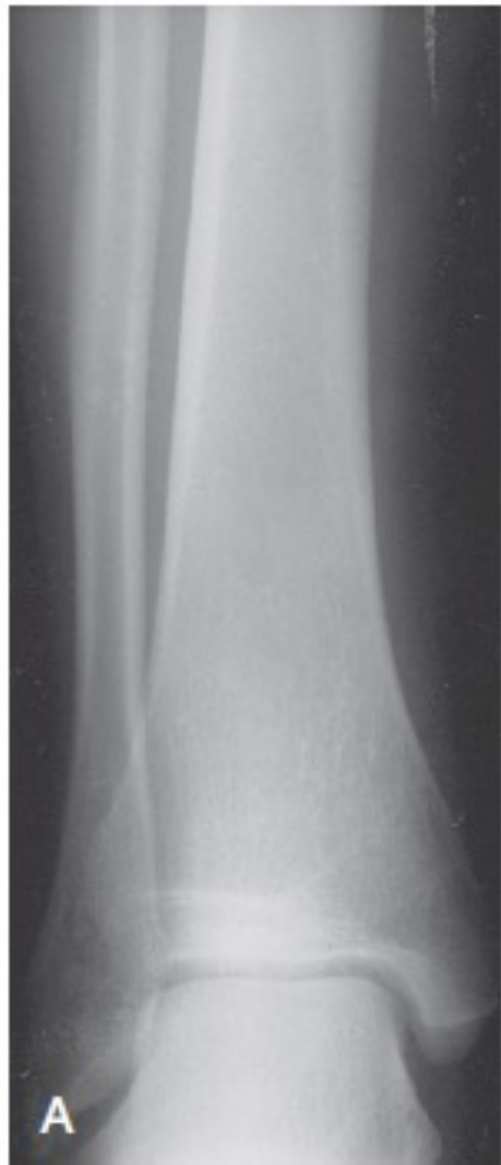We wait until the soft tissue condition is better and the skin wrinkles before internal fixation.



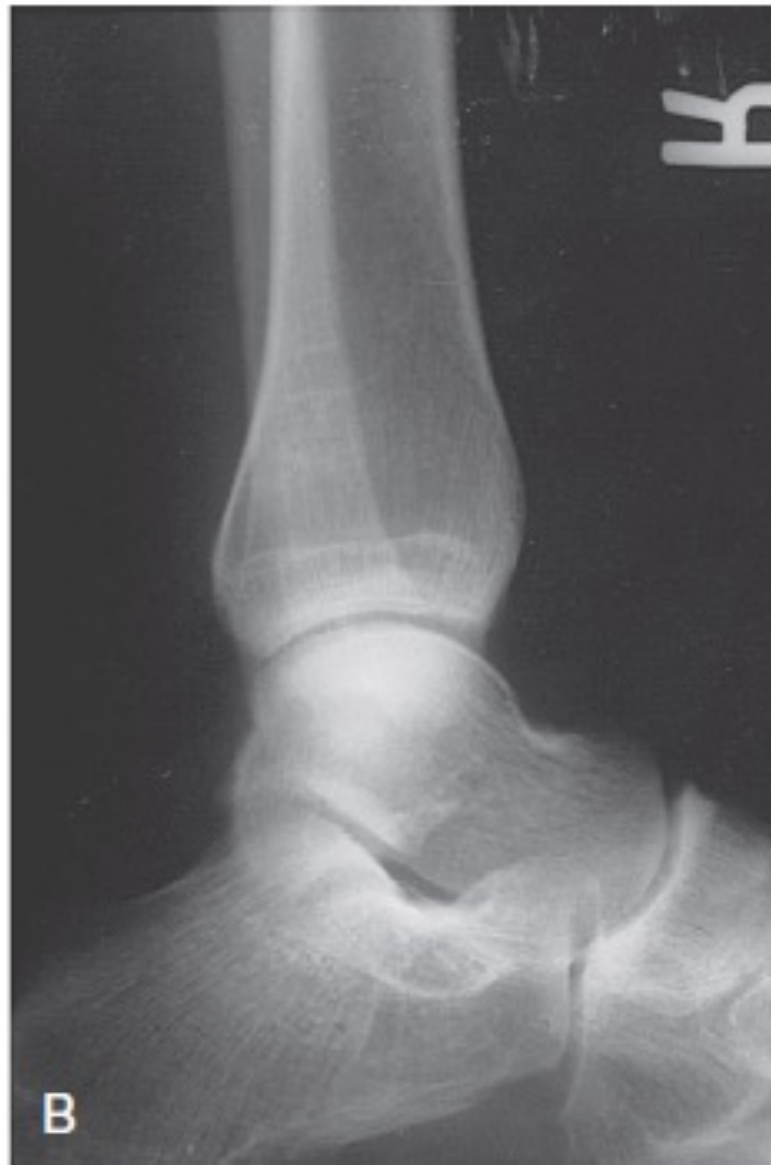



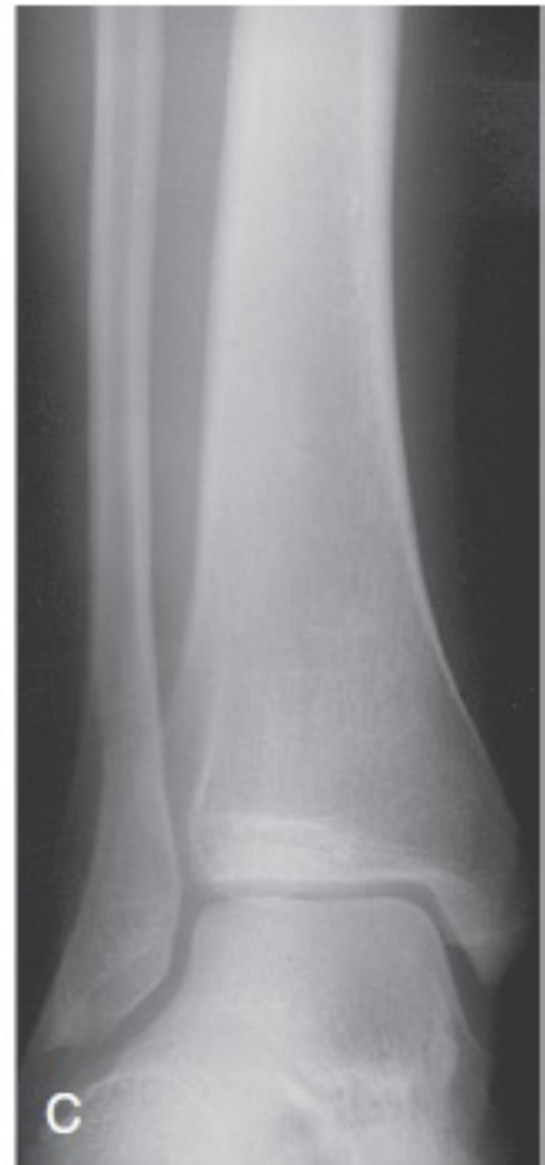Radiographic Evaluation



AP



Lateral

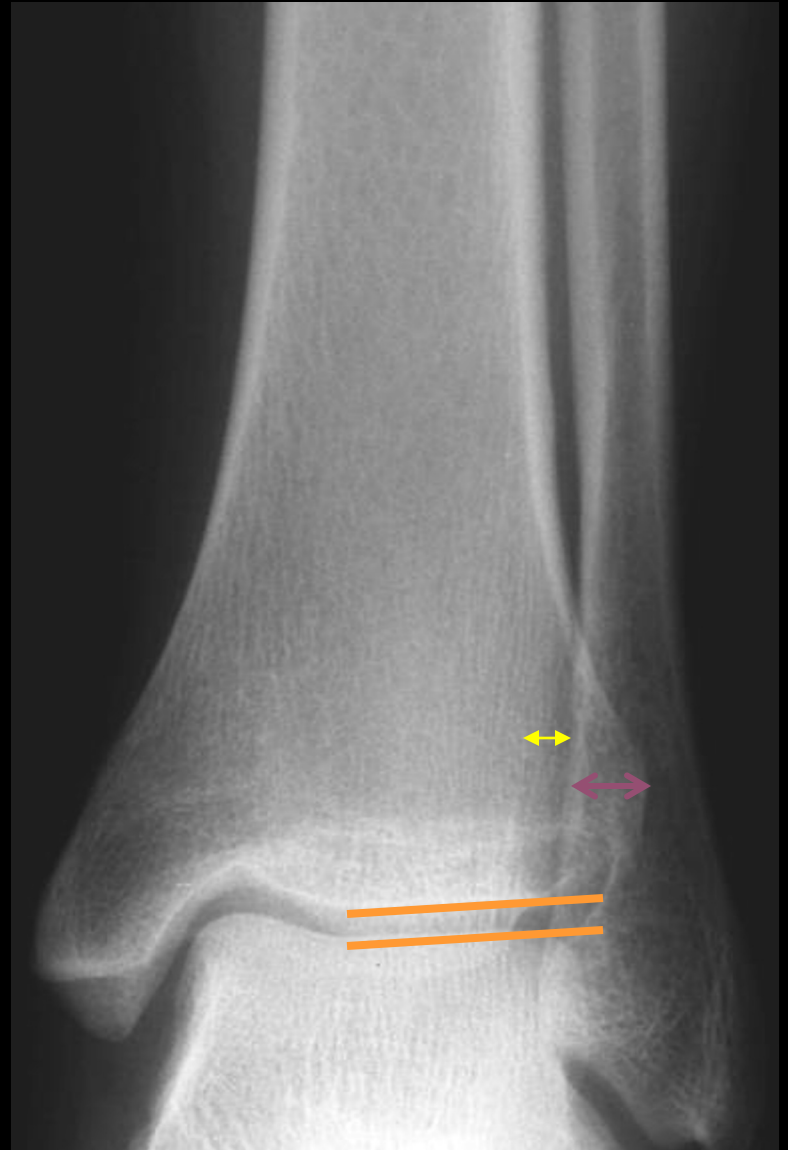

Mortise

Evaluation: Radiographic Anteroposterior View

- Tibiofibular overlap ~ 10mm
- Tibiofibular clear space <5mm
- Talar tilt

Comparison
Radiograph?



Evaluation: Radiographic Mortise View

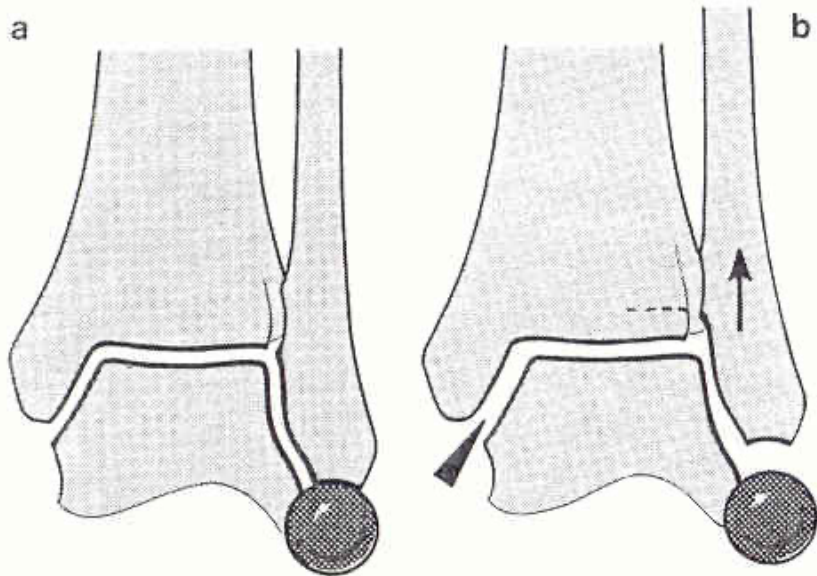
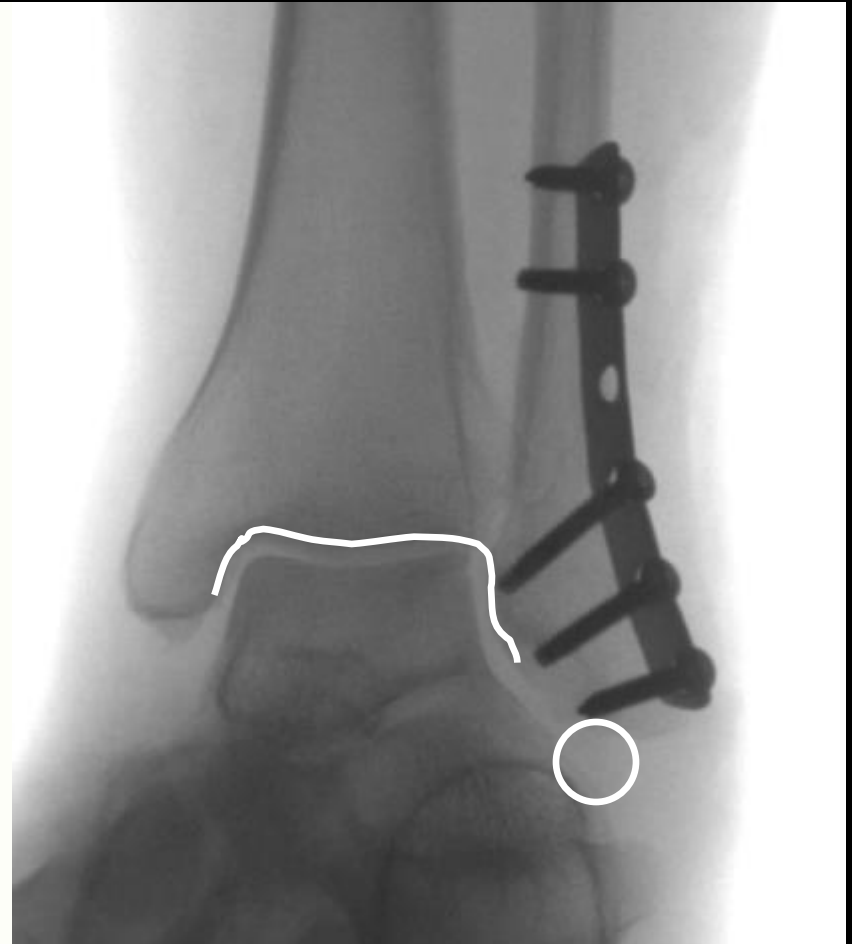


Fig. 3 a and b. The radiology of the sprung mortise

a. Sprung mortise:

1. Irregular width of joint space; widening medially;
2. "Spike" of fibula too proximal;
3. *Broken line* from the lateral part of the articular surface of the talus to the distal fibula

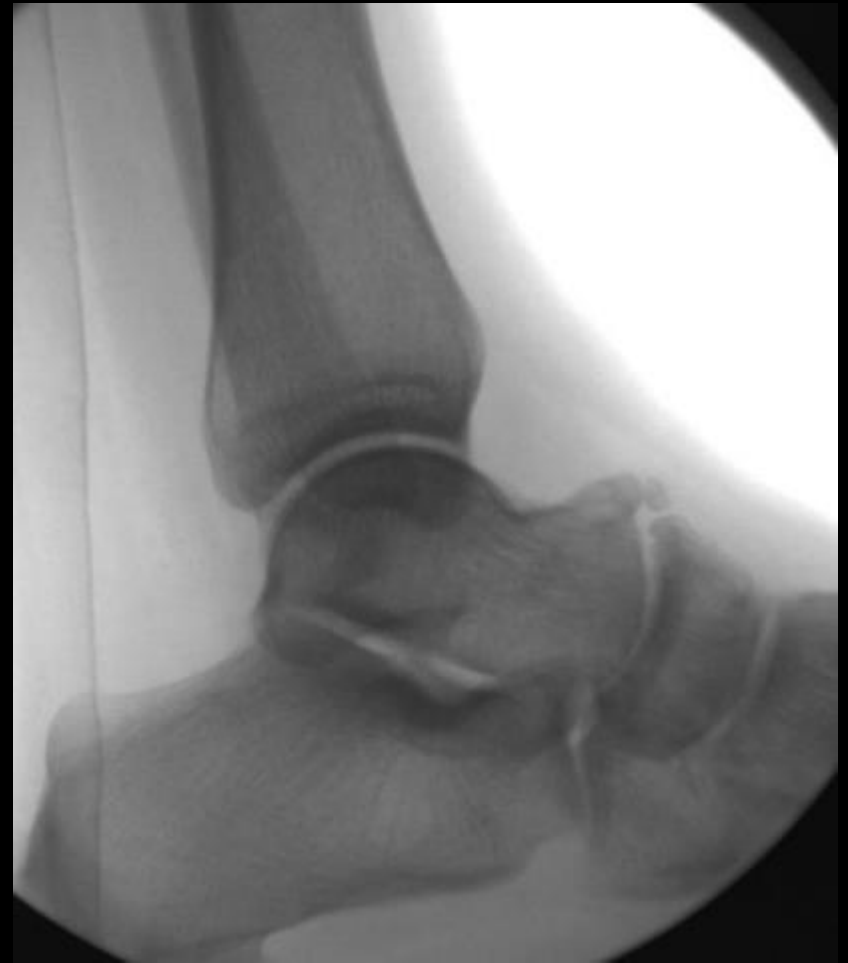b. Normal ankle joint



FIBULAR LENGTH: 1. Shenton's Line of the ankle
2. The dime test

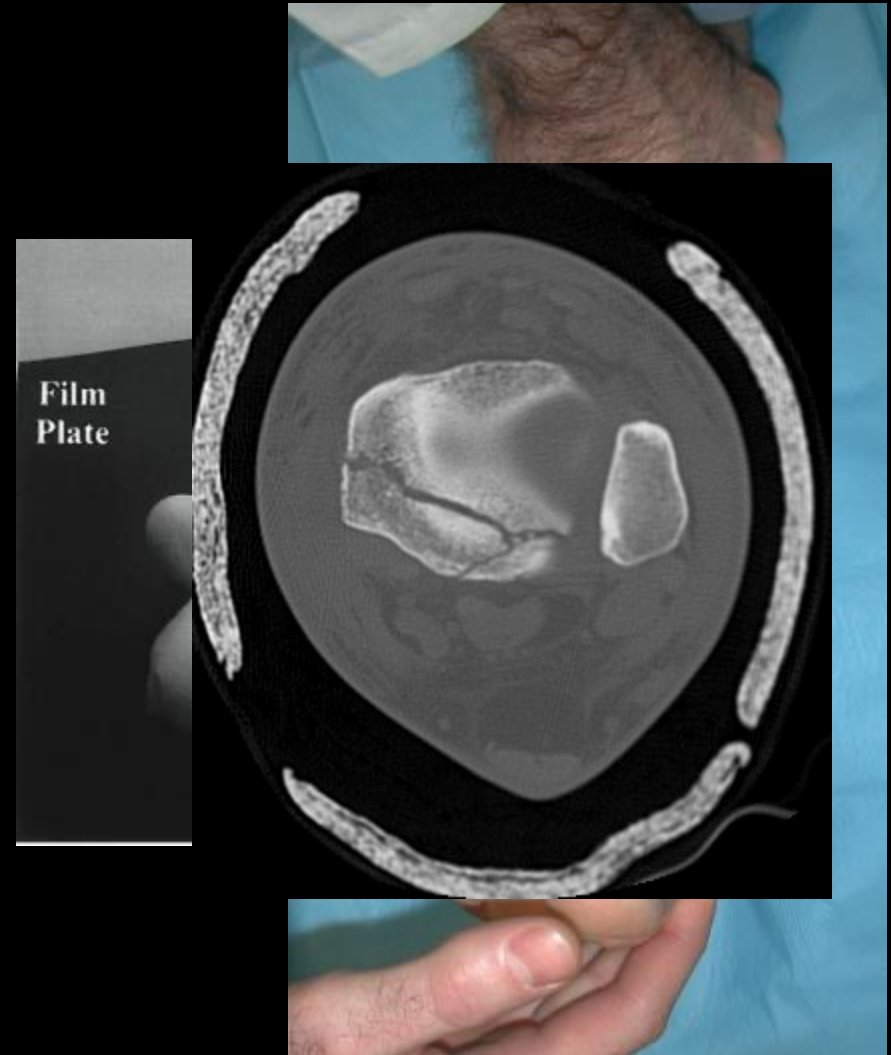
Evaluation: Radiographic Lateral View

- Posterior malleolus fx
- Talar subluxation
- Distal fibular translation &/or angulation
- Syndesmotic relationship
- Associated or occult injuries
 - Lateral process talus
 - Posterior process talus
 - Anterior process calcaneus



Evaluation: Radiographic Other Imaging Modalities

- **Stress Views**
 - Gravity
 - Manual
- **CT**
 - Articular involvement
 - Posterior malleolus
- **MRI**
 - Ligament and tendon injury
 - Talar dome lesions
 - Syndesmosis injuries



Lauge-Hansen

- Cadaveric study
- First word: position of foot at time of injury
- Second word: force applied to foot relative to tibia at time of injury

Types:

SER

SAD

PER

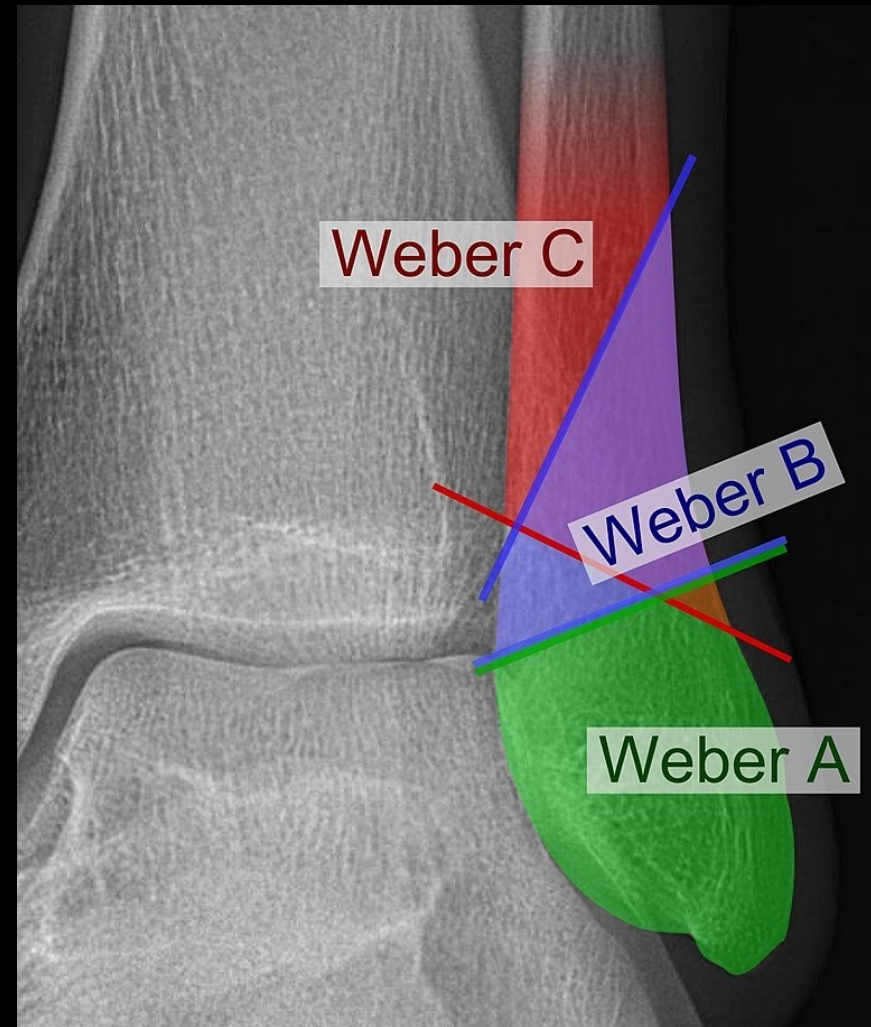
PAB

Lauge-Hansen

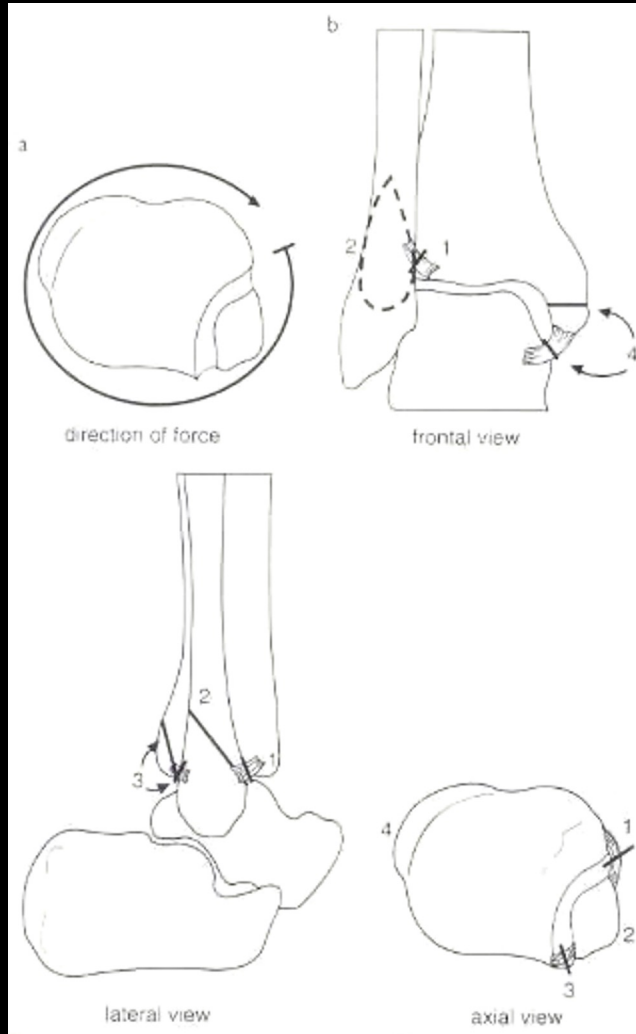
- Several stages per type
- Imperfect system:
 - Not every fracture fits exactly into one category
 - Even mechanism → specific pattern has been questioned
 - Inter and intraobserver variation not ideal
 - Still useful and widely used

Danis-Weber

- Location of the fibular fracture
 - A - infrasyndesmotic (generally not associated with ankle instability)
 - B - transsyndesmotic
 - C - suprasyndesmotic



Supination-External Rotation



Stage 1- AITFL

Stage 2- Fibula fx

Stage 3- PITFL
or PM fx

Stage 4- Deltoid
or MM fx

70% of ankle fractures

Stage 2

Supination-External Rotation
Stage 2: Stable



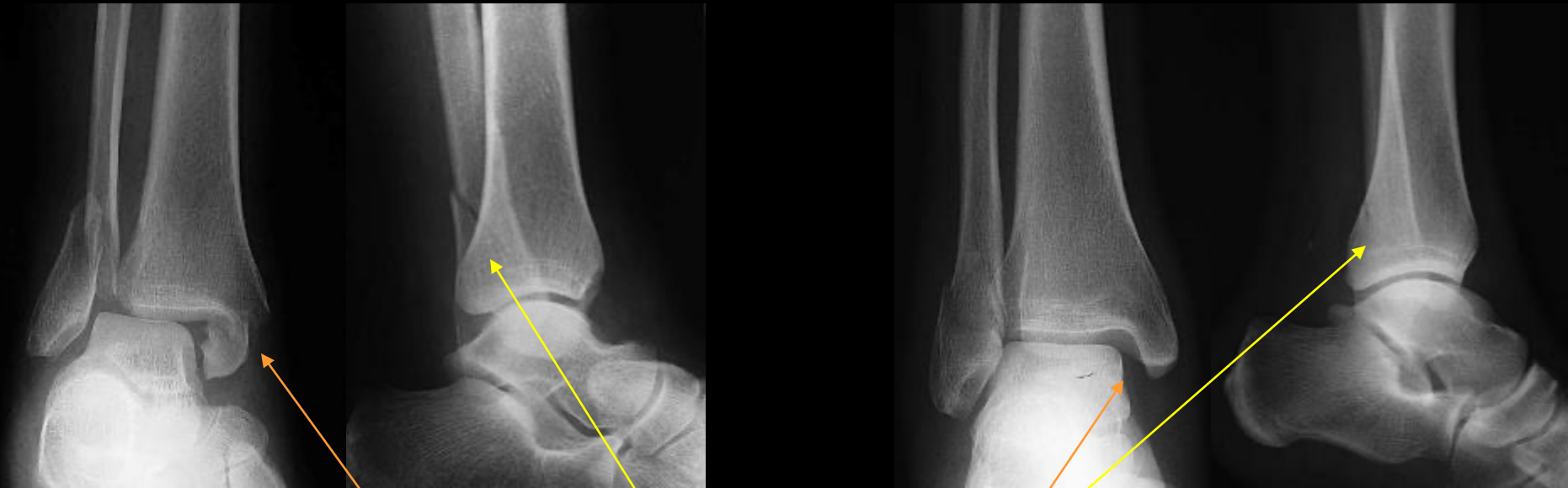Lateral Injury: classic posterosuperior → anteroinferior fibula fracture

Medial Injury: Stability maintained

Standard: Closed management

Stage 4

Supination-External Rotation Stage 4: Unstable



Lateral Injury: classic posterosuperior → anteroinferior fibula fracture

Medial Injury: medial malleolar fracture &*/or DELTOID ligament injury

Standard: Surgical management

SER-2 vs SER-4: How to Decide?

- Michelson. *Clin Orthop Rel Res* 2001

GOAL: TO EVALUATE DEEP DELTOID [i.e. INSTABILITY]

METHOD: ~~MEDIAL TENDERNESS~~

~~MEDIAL SWELLING~~

~~MEDIAL ECCHYMOSIS~~

STRESS VIEWS- GRAVITY OR MANUAL

- Park *J Orthop Trauma* 2006

Gravity Stress Exam

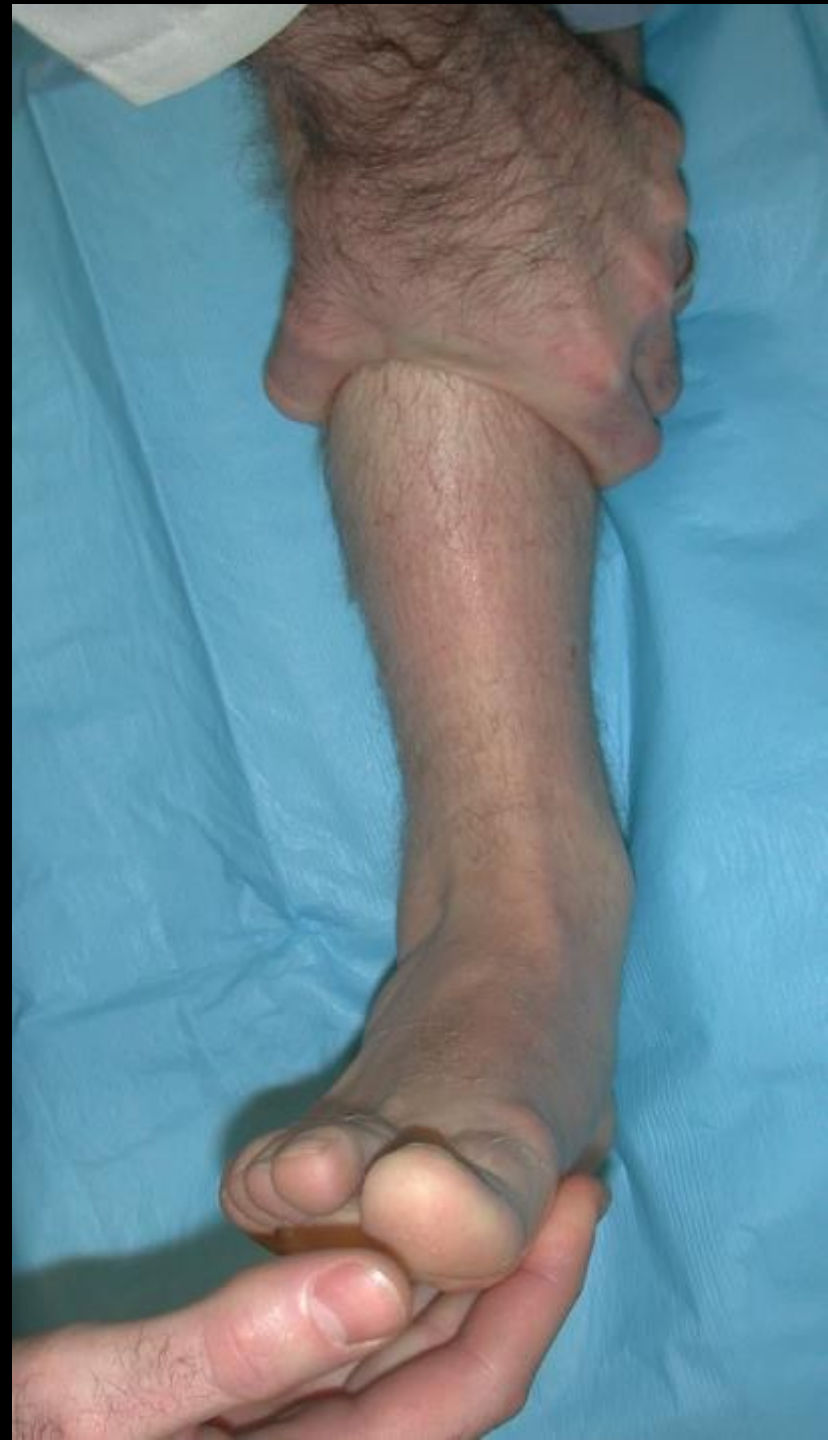

**Film
Plate**

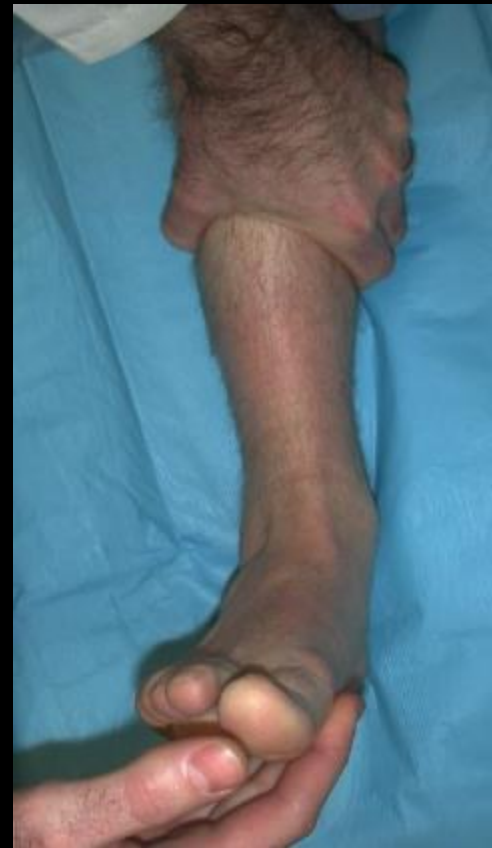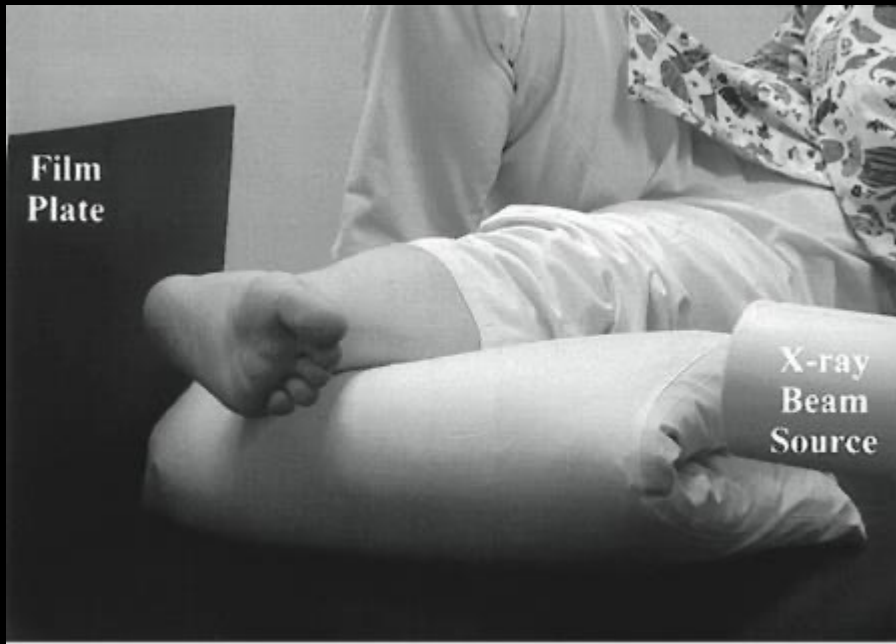**X-ray
Beam
Source**

Manual Stress Exam

15 deg IR with 10# force



versus

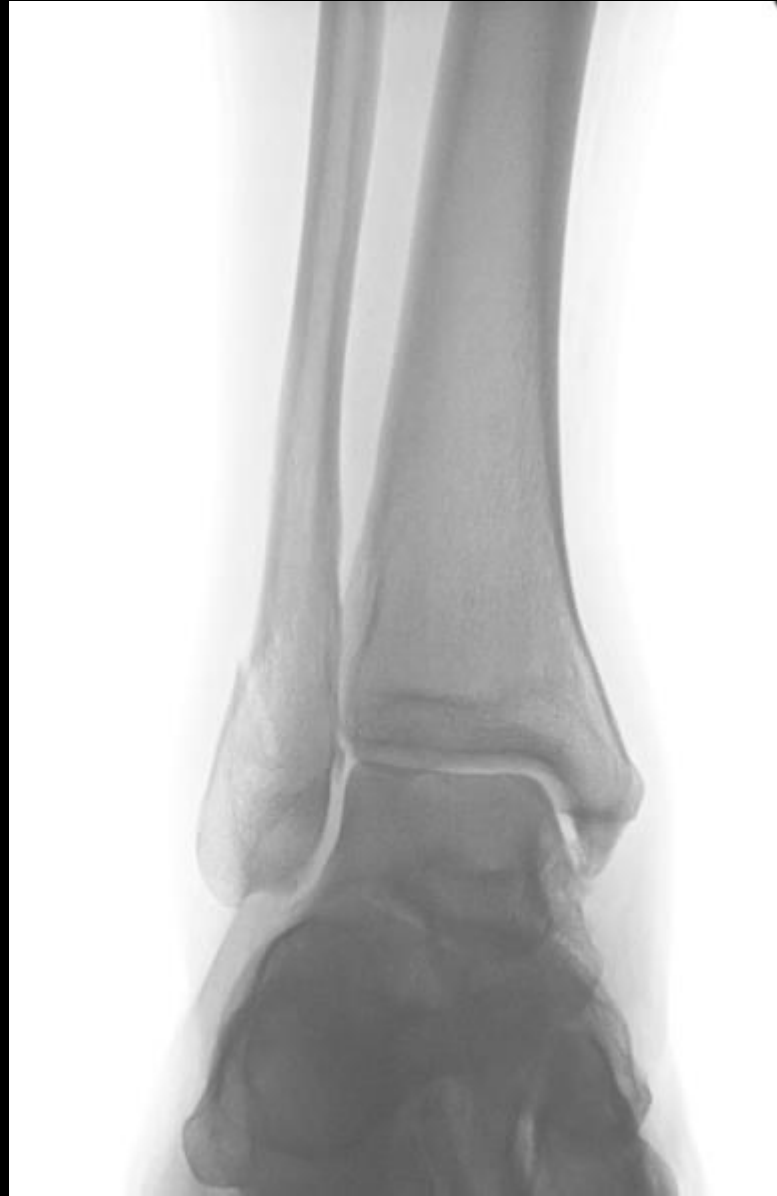

- Both are effective
- Gravity stress requires XR education
- Manual stress requires time and more radiation exposure
- Manual more painful

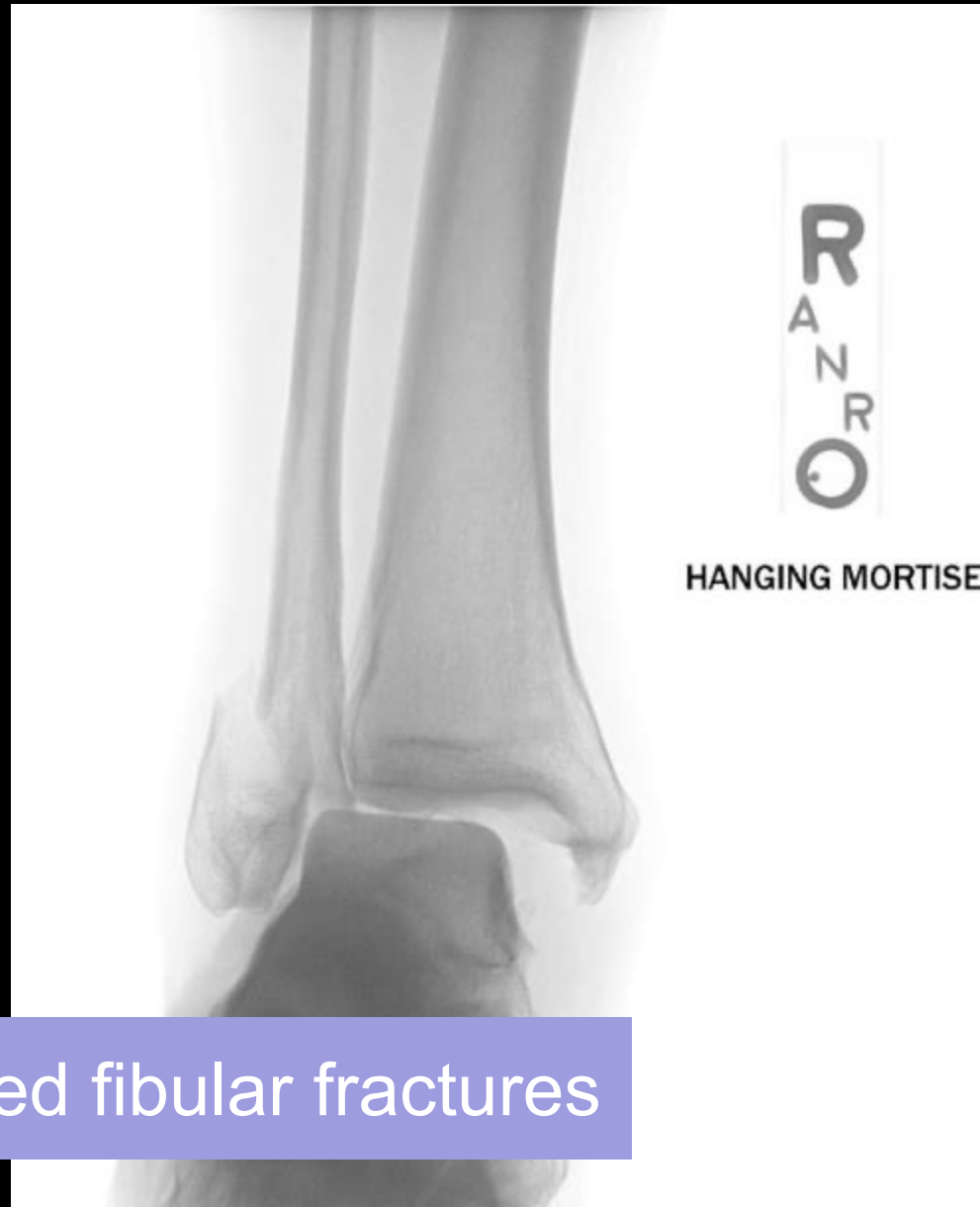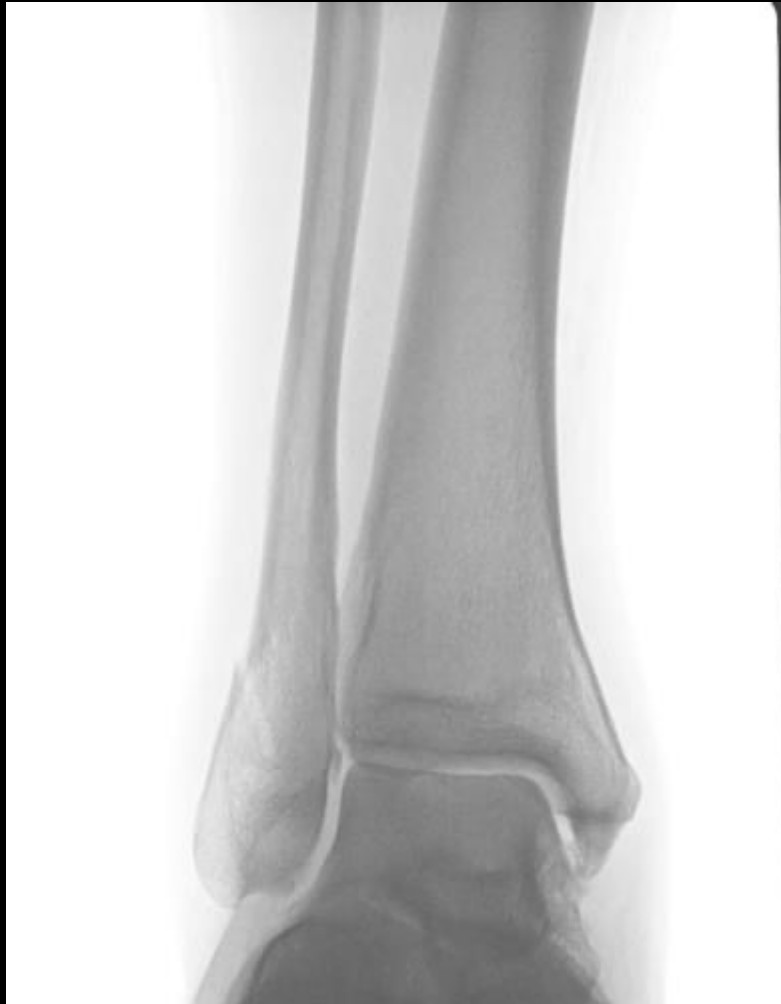Schock et al. JBJS 89B: 1055-59, 2007.
LeBa et al. FAS 8(3): 175-9, 2015.

SER-2 vs. SER-4: How To Decide?

SER-2 vs. SER-4: How To Decide?



SER-2 vs. SER-4: How To Decide?



Indication to fix isolated fibular fractures

How accurate are our stress evaluations?

- Seidel et al Foot Ankle Int 2017

-92 patients prospectively evaluated with weight bearing stress and gravity stress yielding 3 groups

1. Neg GS and WBS → gravity stable, no/short immobilization needed
2. WBS stable and GS unstable → gravity borderline, immobilize
3. Unstable on WBS → unstable, operative

-No functional or radiographic difference at 2 years follow-up between the “gravity stable” or “gravity borderline”

= Gravity stress may overrate the need for operative fixation

MRI?

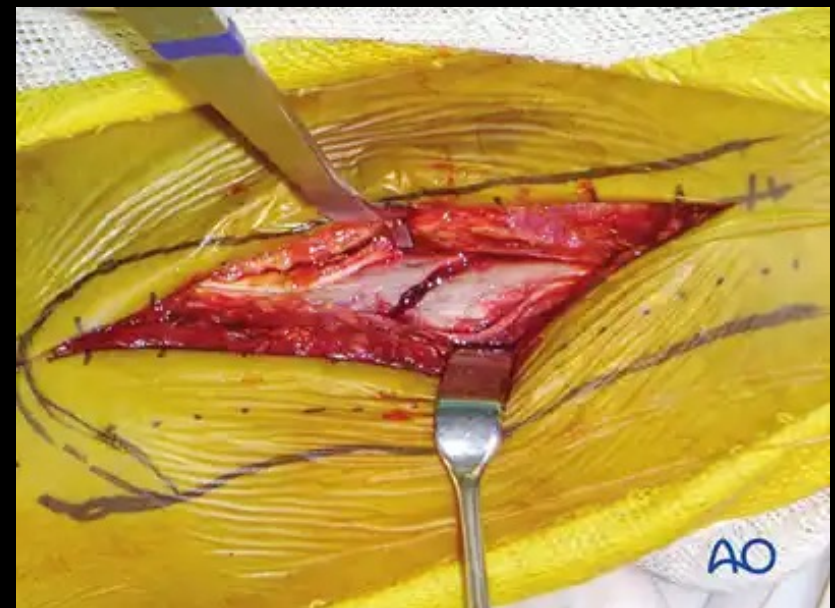
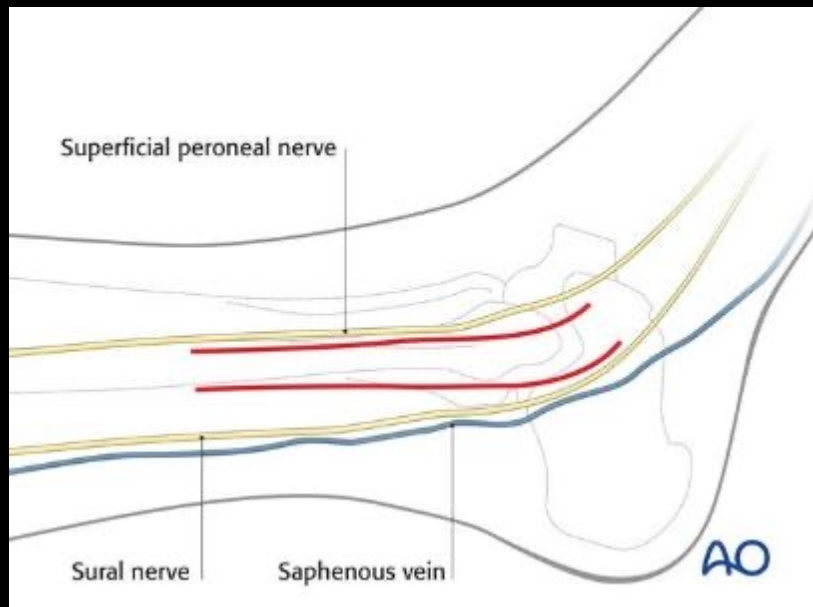
- Nortunen. JBJS 2014
 - 61 pts with isolated lateral mal fxs
 - All had at least partial injury to deltoid
 - Degree of injury DID NOT correlate with instability based on manual stress radiography

Nonoperative Management

- Many stable (SER-2) fractures can be managed nonoperatively
 - CAM boot
 - Cast
 - Splint
- Weight-Bearing
 - Most can be WBAT
- Weekly follow-up for a few weeks
 - WB radiographs to evaluate for displacement, which would necessitate surgery (if appropriate surgical candidate)

Surgical Management

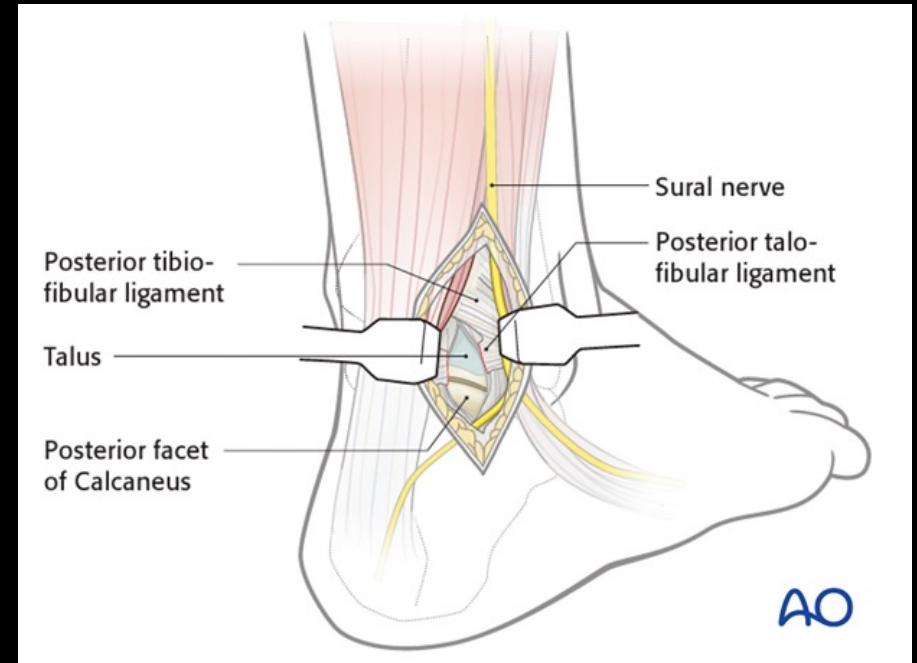
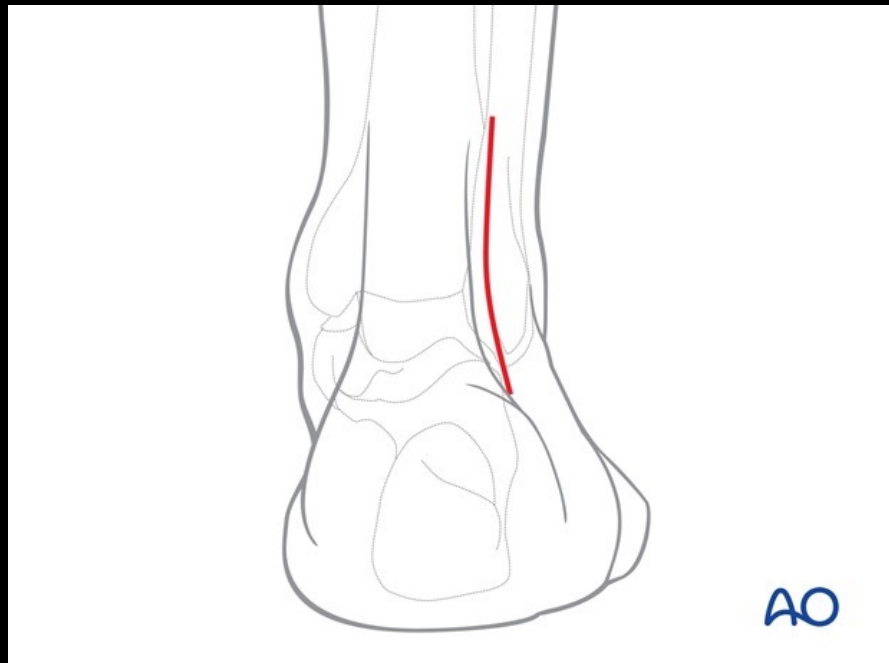
- Often proceed with surgical fixation of fibula first
- Lateral or PL approach



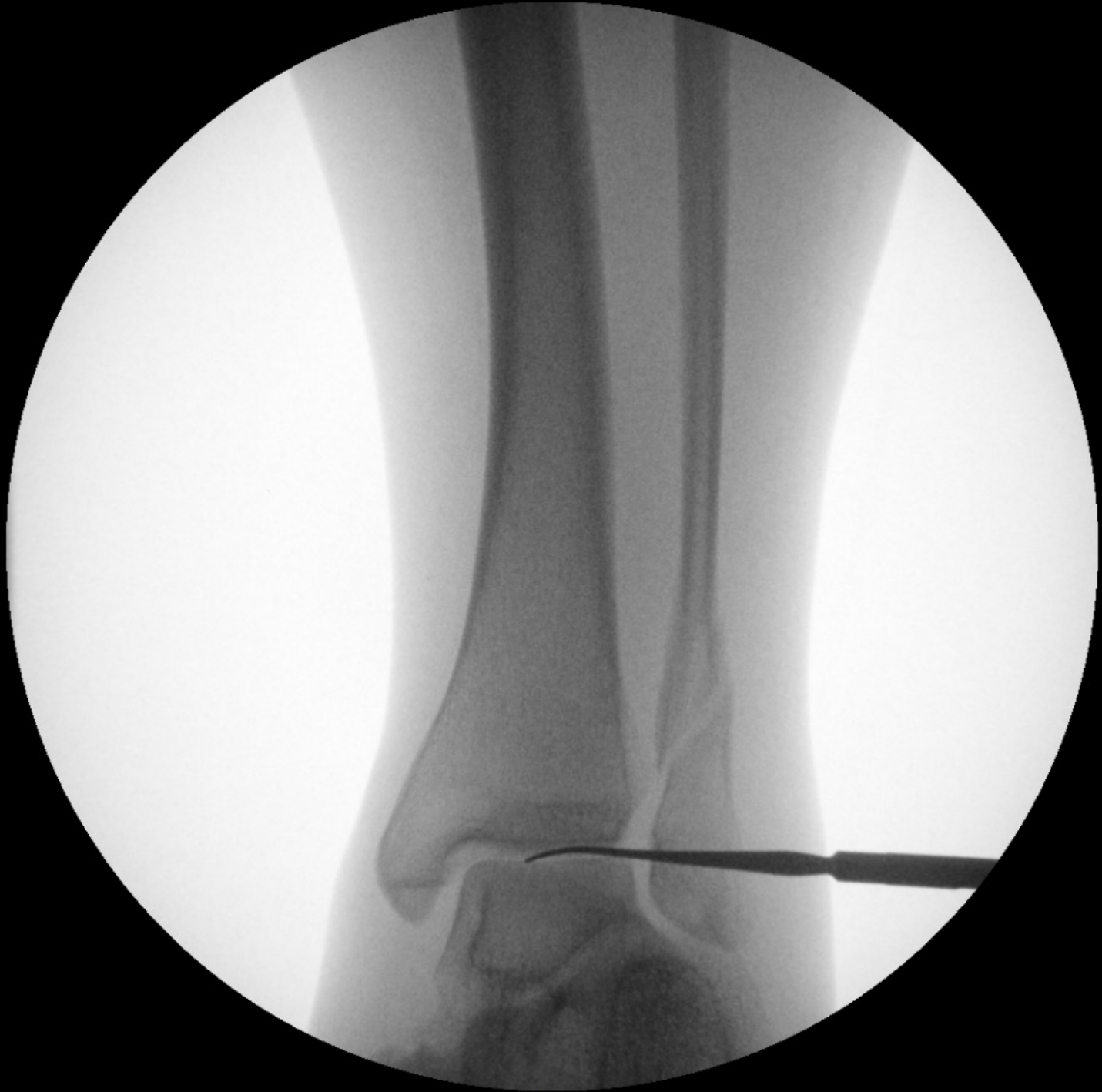Lateral Approach

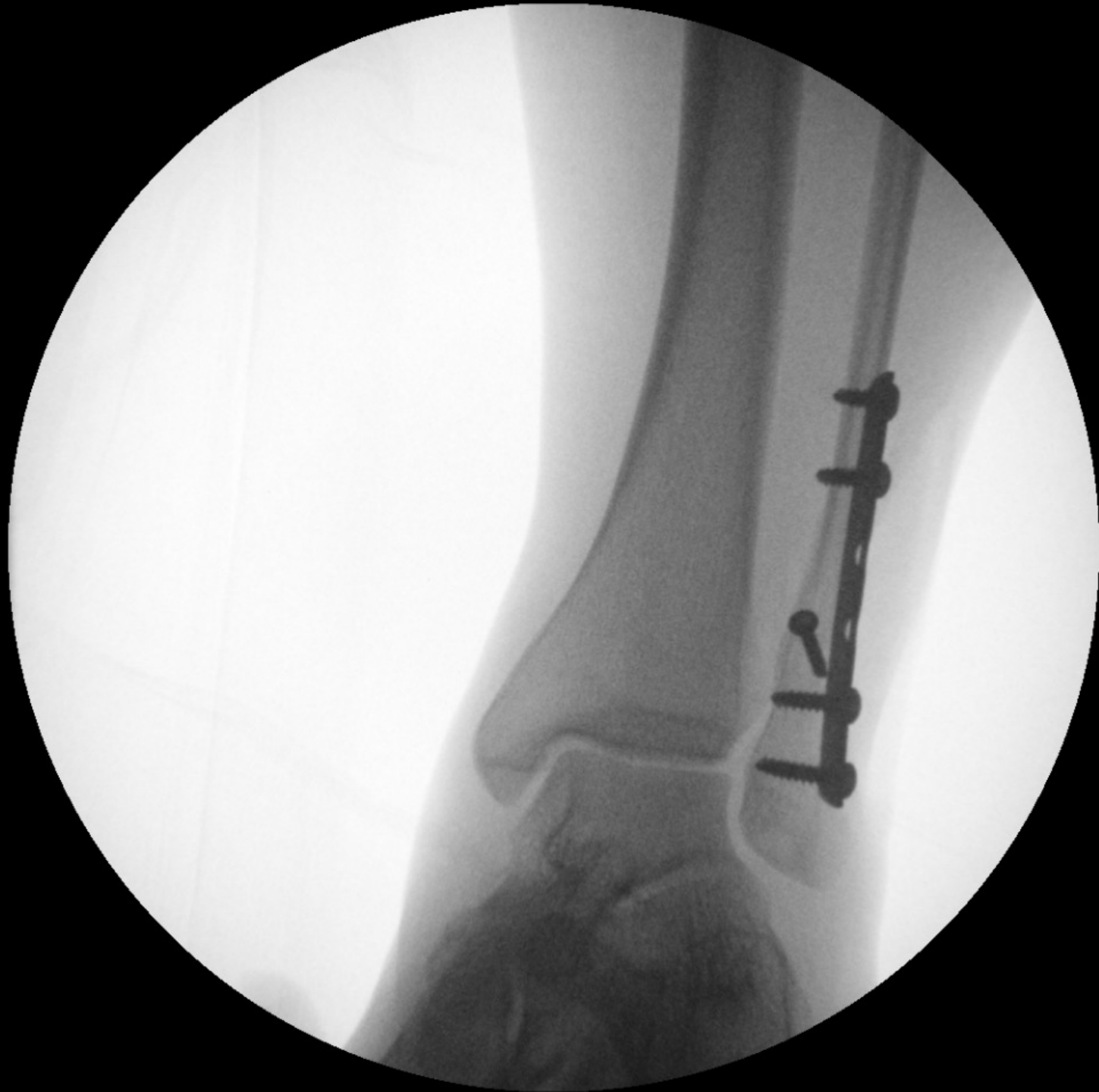Surgical Management

- Often proceed with surgical fixation of fibula first
- Lateral or PL approach



Posterolateral Approach

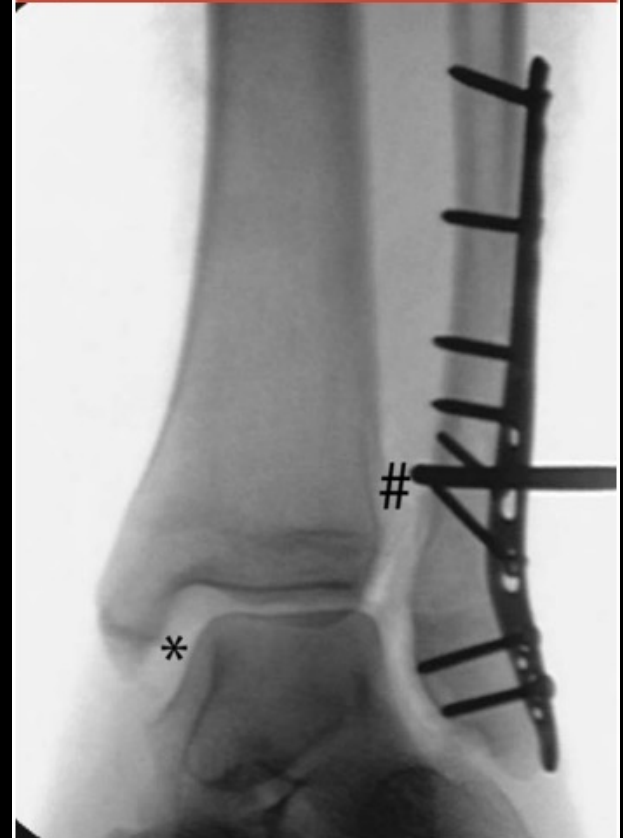



Surgical Management

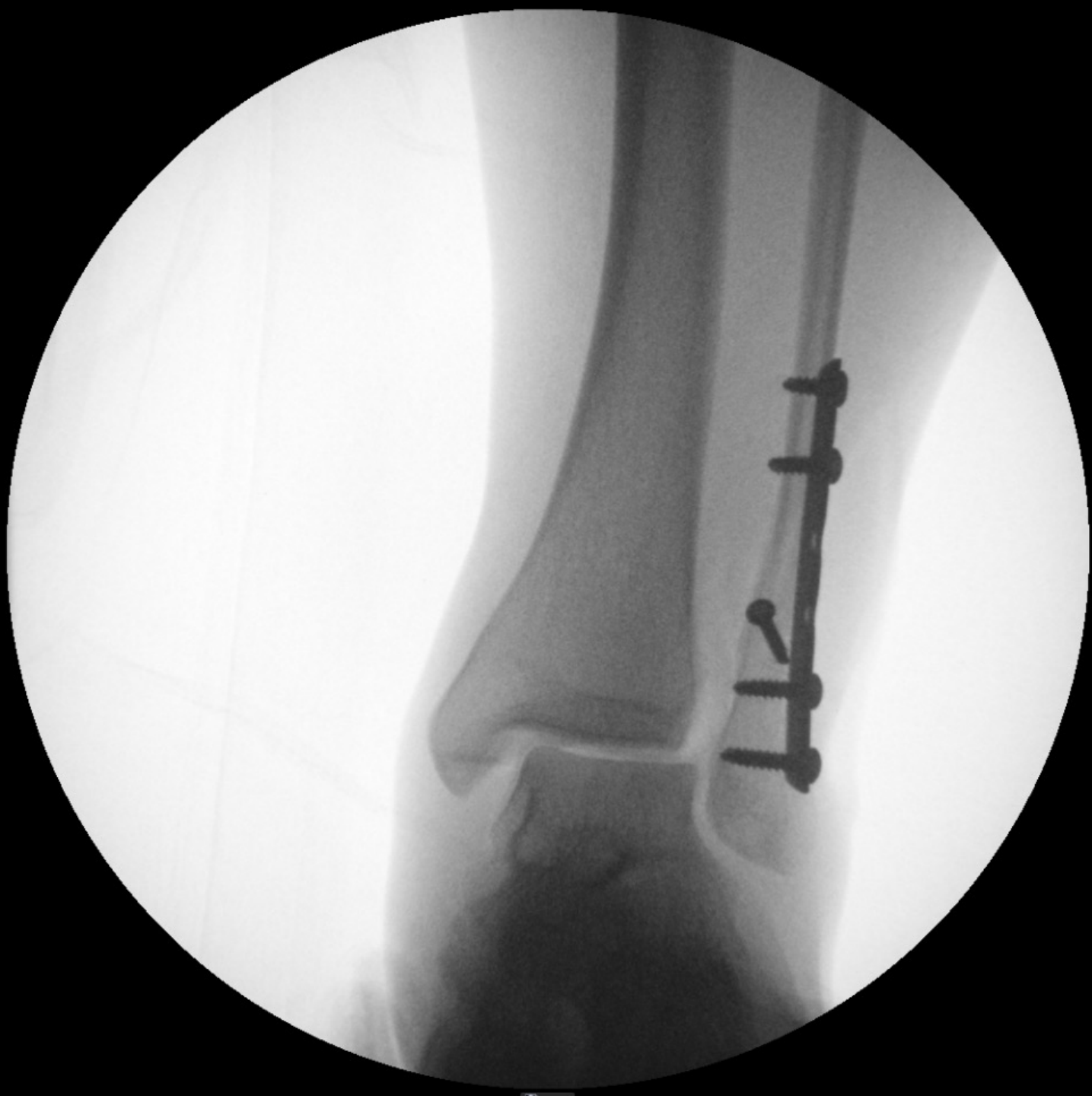- After fibular fixation, need to assess syndesmosis
 - Cotton Test- lateral distracting force on fibula to visualize widening on tib-fib or increased medial clear space
 - Dorsiflexion ER- similar to manual stress radiograph

Figure 2

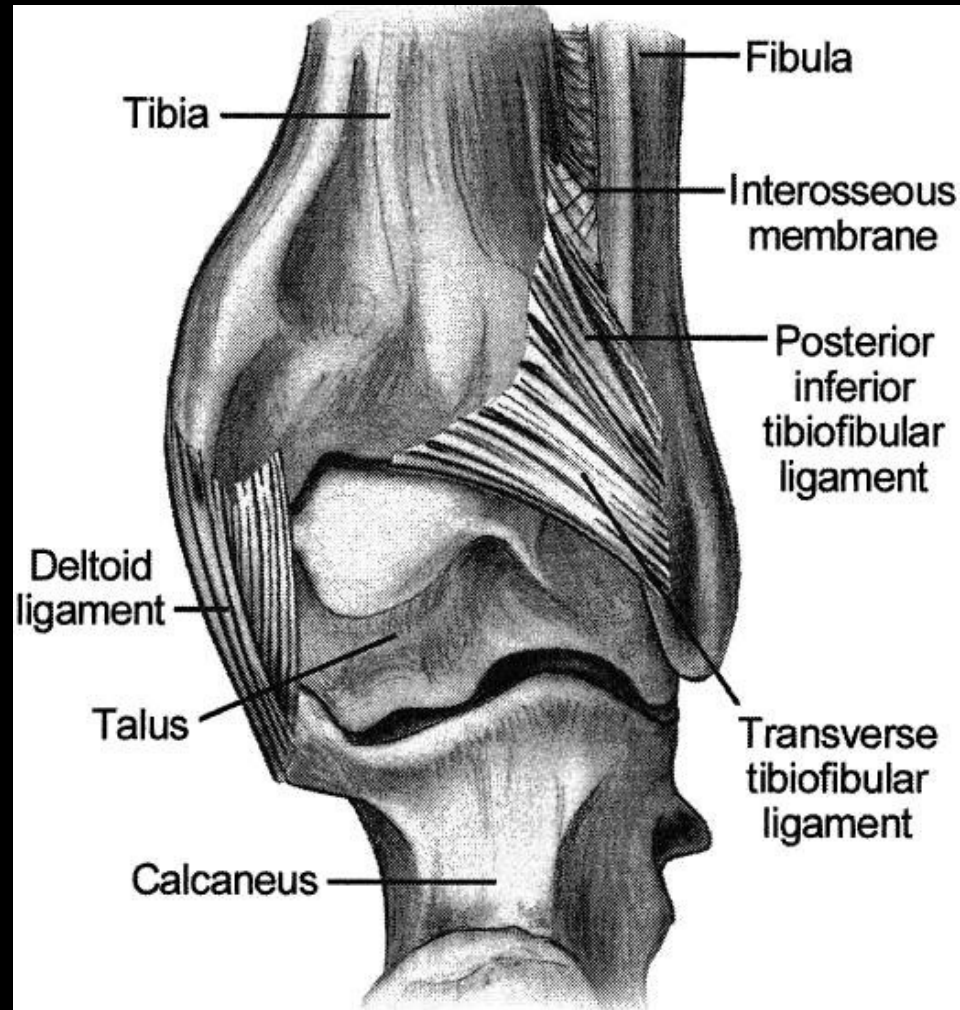
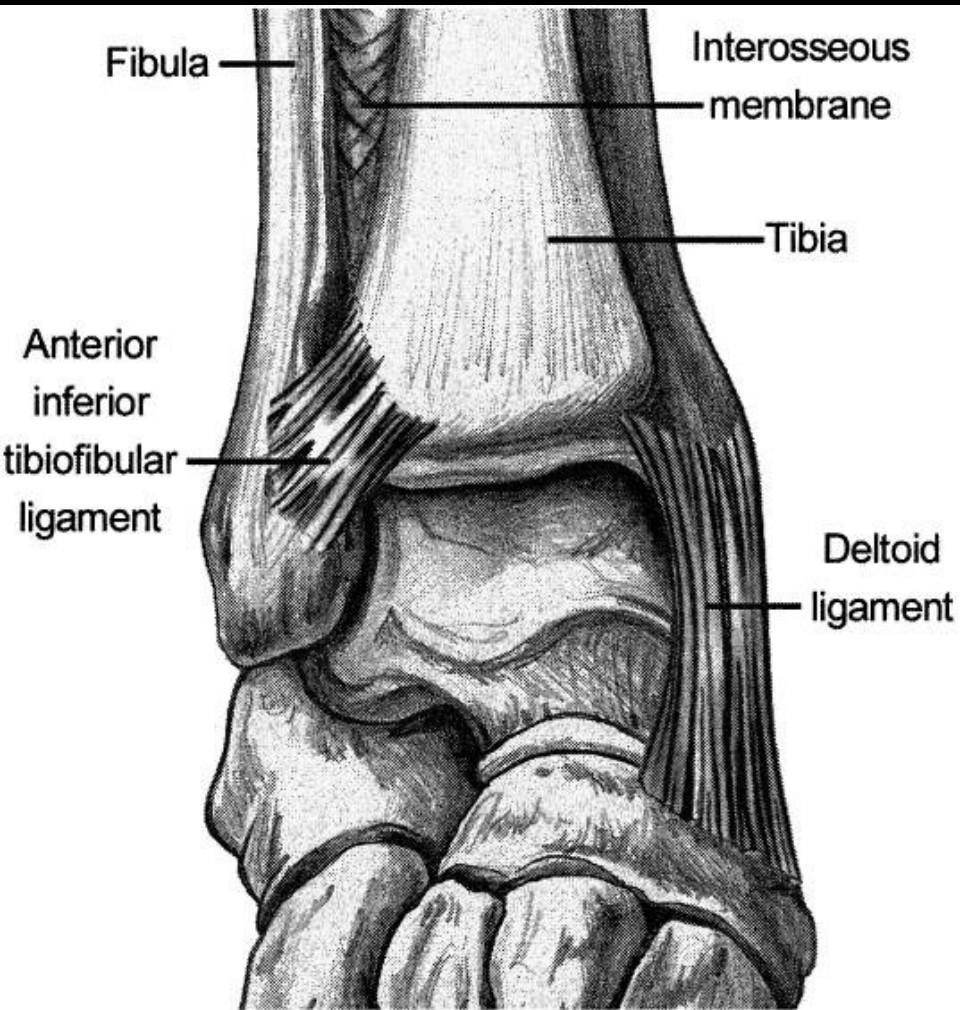


AP radiograph of the ankle after fibular fixation demonstrating a syndesmotic injury. Translation of the fibula (ie, Cotton test) produces demonstrable widening of the medial clear space (*) and syndesmotic space (#).





Syndesmotic Injury



Syndesmosis



IF INSTABILITY PRESENT → OPERATIVE INTERVENTION

**OBTAINING & MAINTAINING ANATOMIC REDUCTION
REDUCES LONG TERM DISABILITY & IMPROVES OUTCOMES**

Leeds JBJS 1984

Weening JOT 2005

Syndesmosis: Instability

- How do you determine if instability is present?
- When do you perform the manual stress test?

Syndesmosis: Instability

- How do you determine if instability is present?
 - Manual Stress Test
- When do you perform the manual stress test?
 - After you have fixed the other indicated components of the fracture

Syndesmosis



IF INSTABILITY PRESENT → OPERATIVE INTERVENTION

OBTAINING & MAINTAINING ANATOMIC REDUCTION
REDUCES LONG TERM DISABILITY & IMPROVES sMFA

Leeds JBJS 1984

Weening JOT 2005

Syndesmosis: Obtaining a Reduction

- Incidence of malreduction based on CT scan “standard”: >50%
 - *Gardner et al. FAI 27: 788-92, 2006.*
- Ways to ensure appropriate reduction:
 - Direct visualization
 - *FAI 30: 419-26, 2009*
 - Radiographic imaging in multiple planes
 - *Injury 35: 814-18, 2004.*

Improved Reduction of the Tibio-Fibular Syndesmosis with Tightrope compared to Screw Fixation: Results of a Randomized Controlled Study.

Sanders D¹, Schneider P², Taylor M¹, Tieszer C³, Lawendy AR⁴.

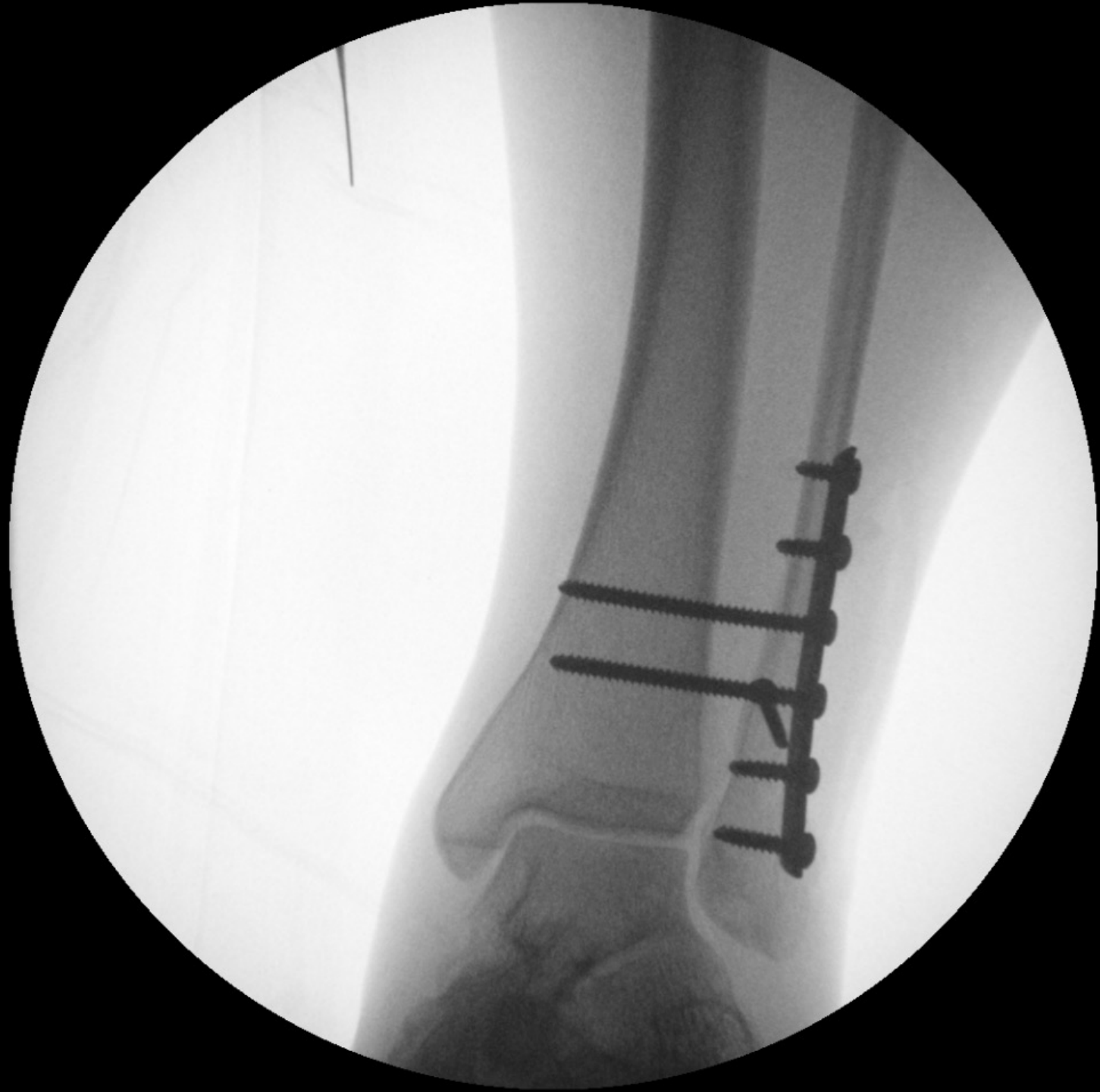- N=103
- Tightrope (one knotless Tightrope) or screw fixation (two 3.5 mm cortical positional screws placed across 3 cortices)
- Malreduction based on 3 mo CT
- T- 15% & S- 39%
- Functional outcome measures demonstrated significant improvements over time, but no differences between fixation groups.

Cost analysis of ankle syndesmosis internal fixation.

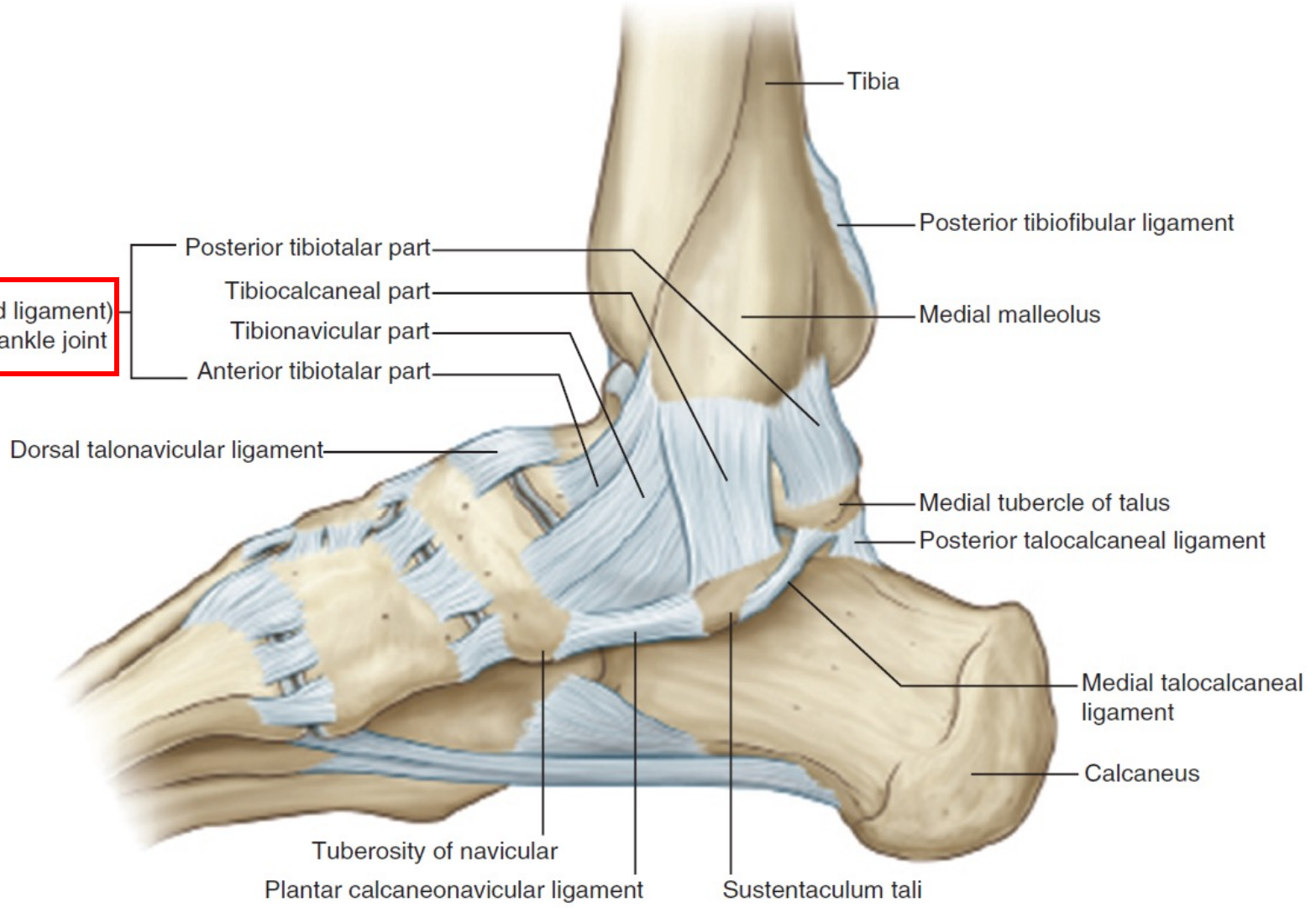
Weber AC¹, Hull MG¹, Johnson AJ¹, Henn RF 3rd¹.

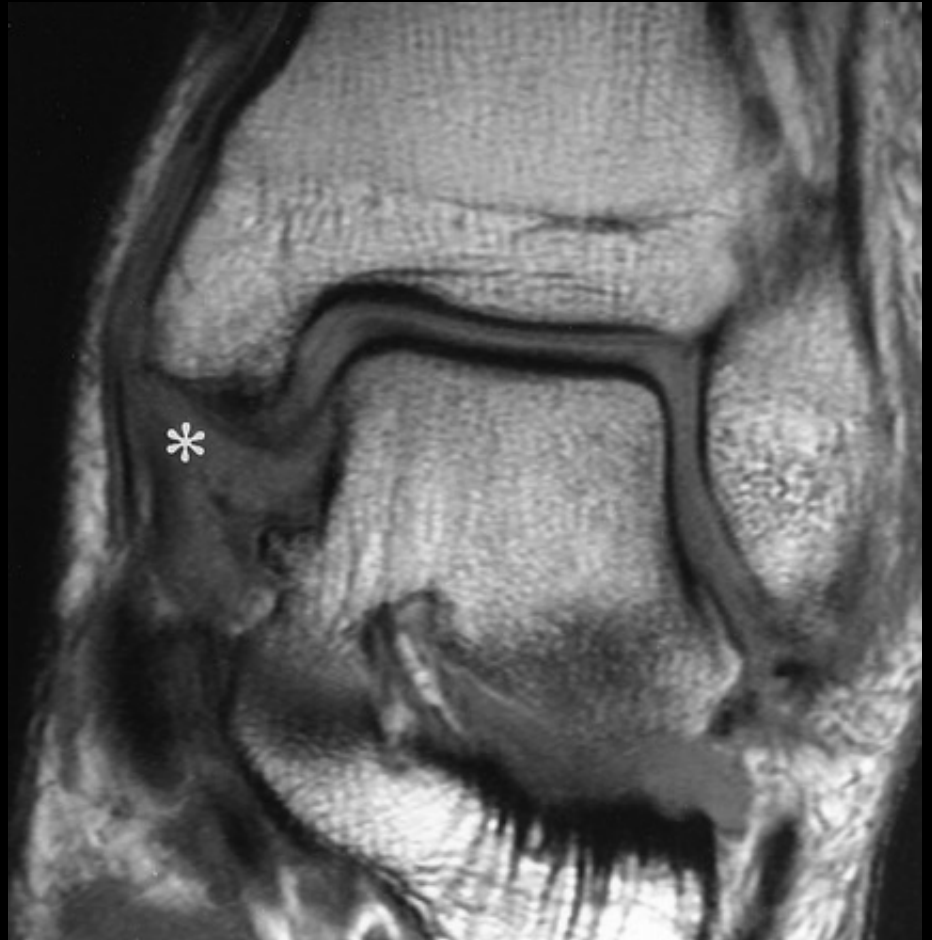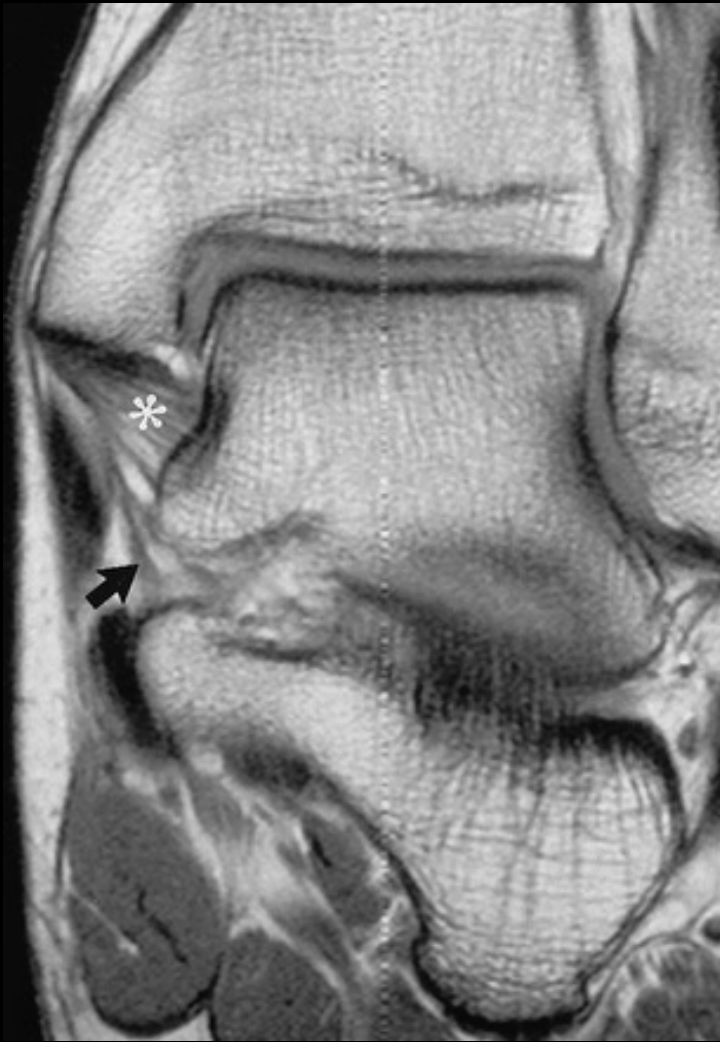- Cost equivalence was achieved at an 18 to 53% syndesmotic screw removal rate
- When screws removed 100% of the time, suture button fixation was more economical by \$85,000-\$194,656 per 100 ankles.
- When hardware was never removed, suture button fixation was more expensive by \$169,844-\$295,500 per 100 ankles.





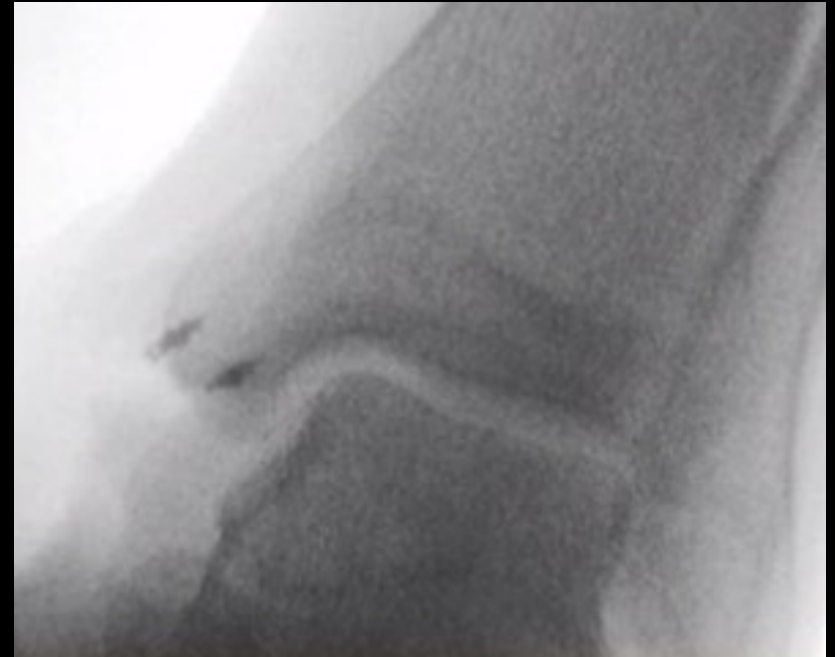Medial ligament (deltoid ligament) of the ankle joint





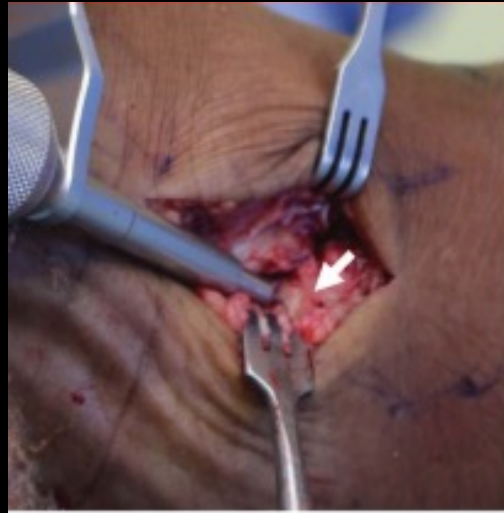Surgical Management

- Deltoid Ligament Repair
 - Multiple techniques involving repair primarily with suture anchors to medial malleolus and/or talus based upon intraoperative findings

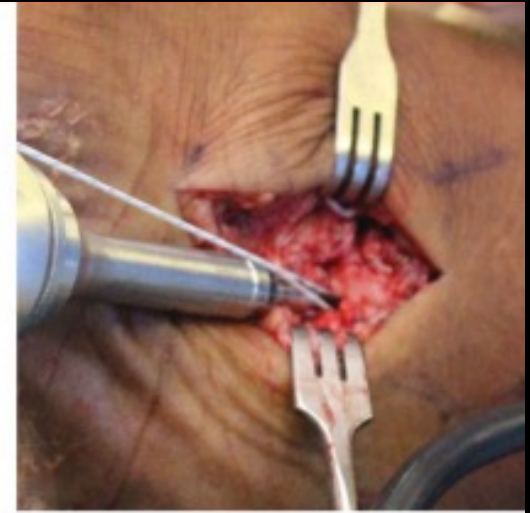

Surgical Management

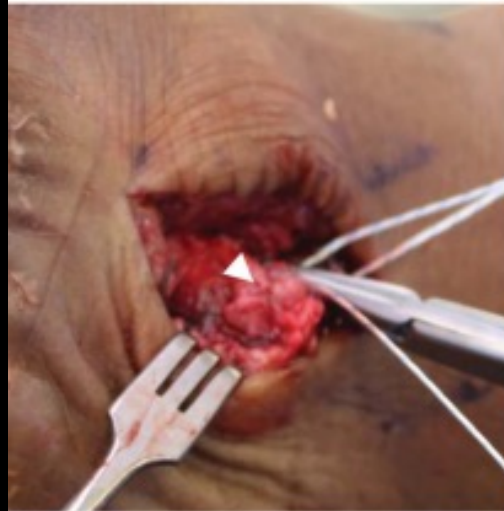- Deltoid Ligament Repair



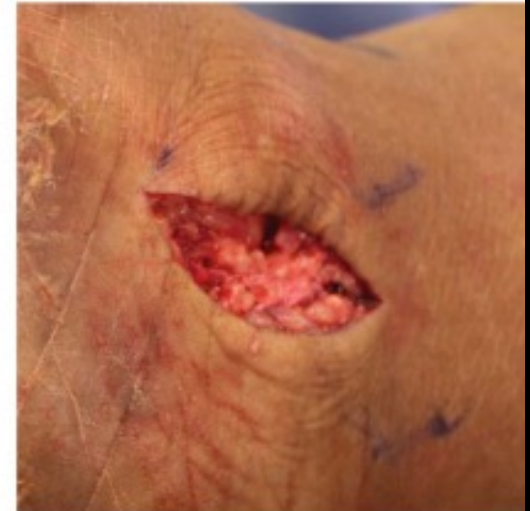A



B



C




D

Deltoid Ligament Repair Worth it?

- High quality studies lacking

The Role of Deltoid Ligament Repair in Ankle Fractures With Syndesmotic Instability: A Systematic Review

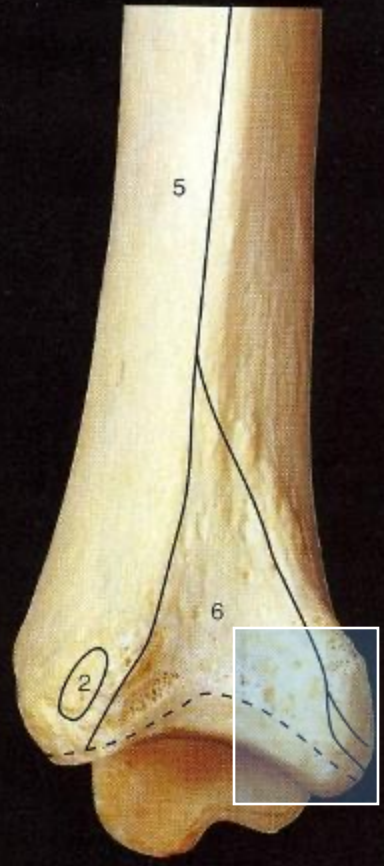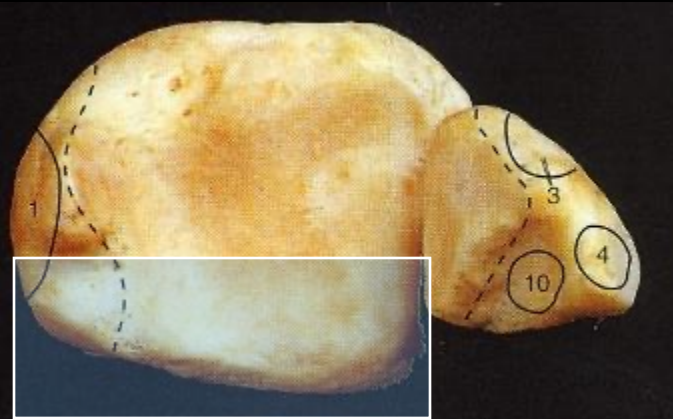
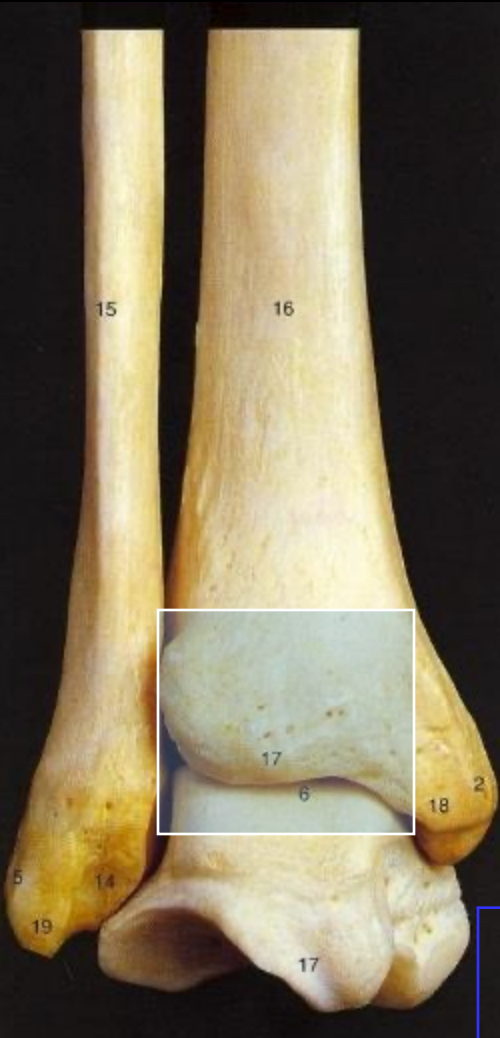Julian Wang, MD¹, Devon Stride, MD, MSc², Nolan S. Horner, MD³, Bradley Petrisor, MD, FRCSC⁴, Herman Johal, MD, FRCSC⁵, Moin Khan, MD, MSc, FRCSC⁵, Bashar Alolabi, MD, MSc, FRCSC⁵



Deltoid ligament repair

- Lower syndesmotic malreduction rates (0%-9% vs 20%-35%, $p \leq .05$)
- Fewer implant removals (5.8% vs 41% $p \leq .05$)
- Longer operating time by 16-20 minutes ($p \leq .05$)
- No significant difference for pain, function, ROM, MCS, and complication rate ($p \leq .05$).

Posterior Malleolus Fractures



Function:
Stability- prevents posterior translation of talus & enhances syndesmotic stability

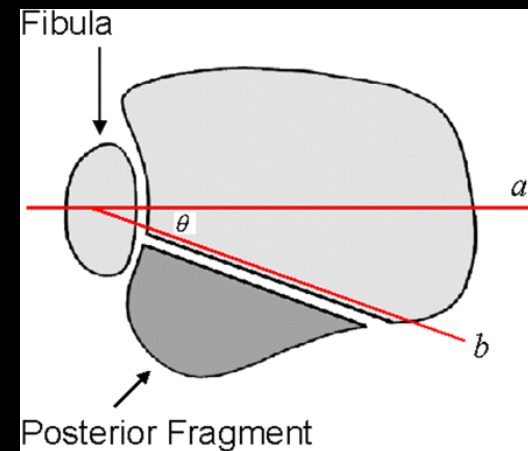
Weight bearing- increases surface area of ankle joint

Posterior Malleolus Fractures: Radiographic Evaluation

- Fracture pattern:
 - Variable
 - Difficult to assess on standard lateral radiograph
 - External rotation lateral view [Decoster *FAI* 2000]
 - CT scan [Haraguchi *JBJS* 2006]

Posterior Malleolus Fracture: Radiographic Evaluation

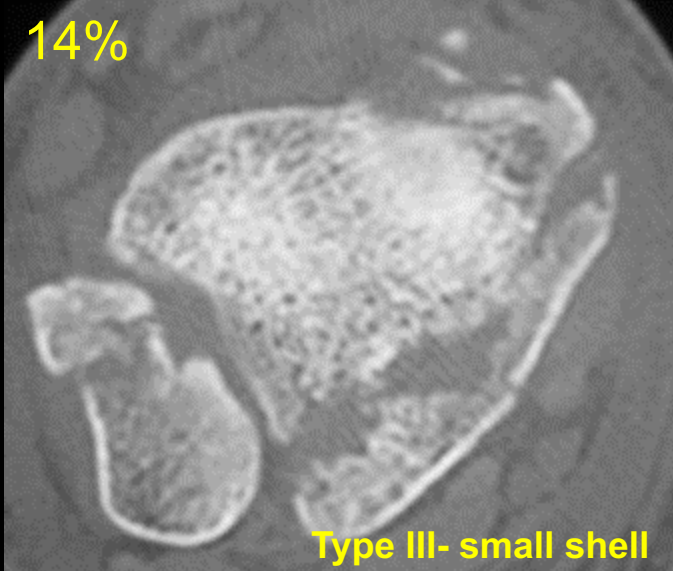
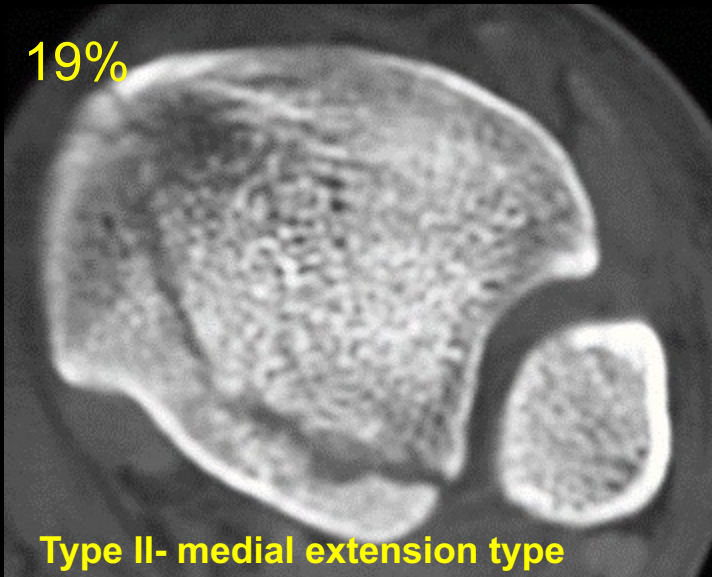
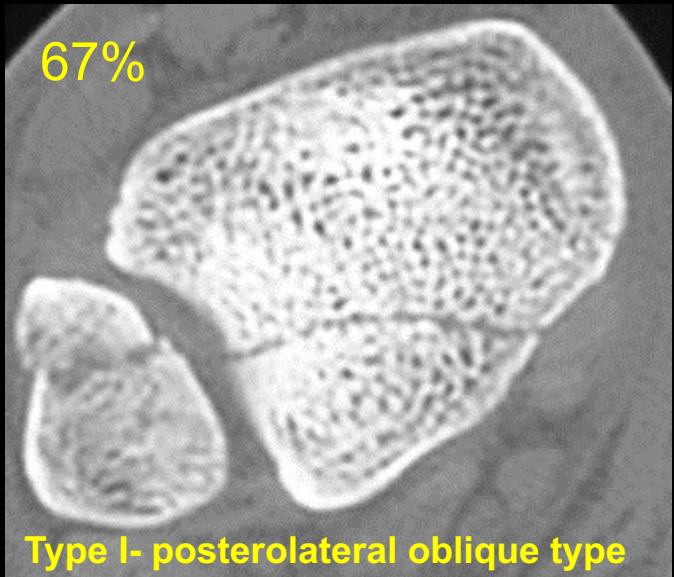
- Indication for fixation: $> 25\%$ joint surface on lateral
- Problem: Fragment size hard to determine on lateral view
 - Reason: Fracture orientation not purely in coronal plane
 - Nearly always associated with the pull of the posterior tib-fib ligament
 - larger laterally than medially
 - obliquely oriented
 - involves the incisura



Haraguchi et al. JBJS 2006

...but other fracture patterns have also been defined

Posterior Malleolus Fracture



3 common PM fracture patterns

Posterior Malleolus Fractures: Indications for Fixation

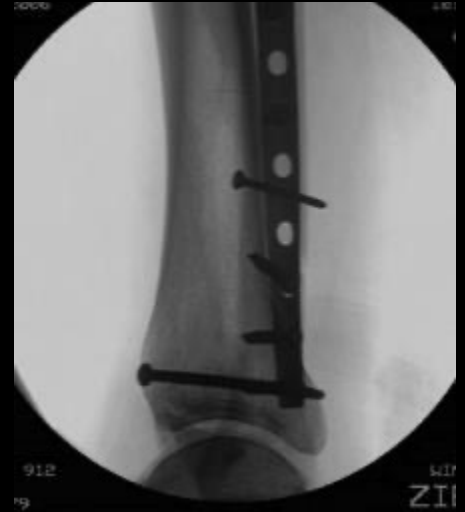
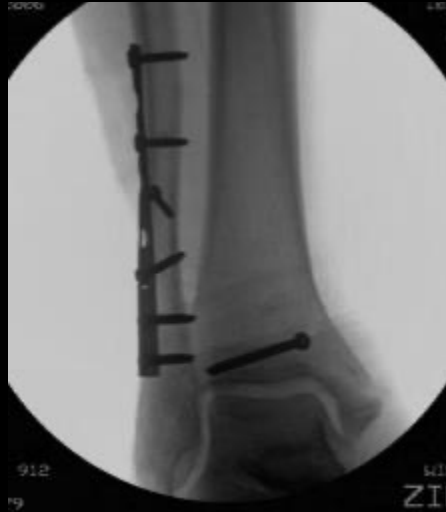- **Stability**
 - Posterior translation of talus*
 - ER of talus [syndesmotic widening]
- **Articular congruence**
 - Stress = Force/Area
 - Excessive stress → posttraumatic arthritis
 - Maximize area for stress distribution**

*fibula and anterior tibiofibular ligament act as primary restraint [Raasch JBJS 1992]

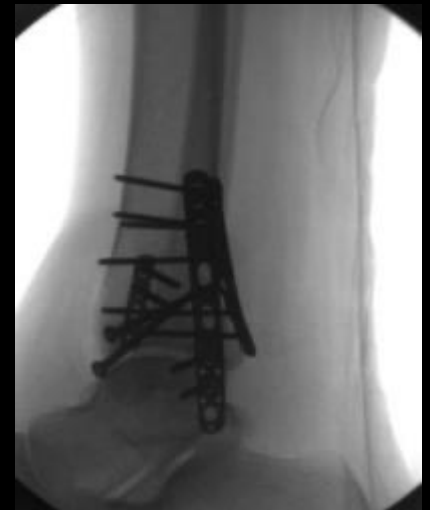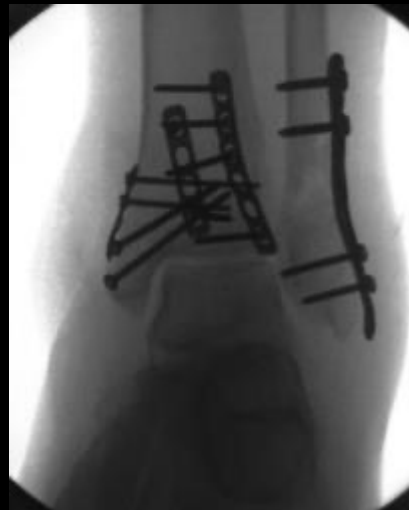**contact stress changes significantly with posterior malleolar size >33% [Hartford CORR 1995]

Posterior Malleolus Fracture: Fixation

- Screws



- Plates



Outcomes for Ankle Fractures

Horisberger et al. J Orthop Trauma 2009

- Fracture severity influences the rate of development and the latency time to endstage ankle arthritis.
- The occurrence of postop complications has a negative influence on long-term results.
- The patient's age at the time of injury correlated negatively with the OA latency time (i.e. if you are older when you sustain an ankle fracture, you are more likely to develop end-stage OA sooner than if you had been younger).

Outcome

- Specific findings in the history noted to have an adverse effect on outcome include:
 - Advanced age
 - Osteoporosis
 - Diabetes mellitus
 - Peripheral vascular disease
 - Female sex
 - High American Society of Anesthesiology (ASA) class

- Ganesh et al. JBJS 87A: 1712-1718, 2005
- Egol et al. JBJS 88: 974-979, 2006
- SooHoo et al. JBJS 91A: 1042-1049, 2009

Outcome

Bhandari et al. J Orthop Trauma 18: 338-45, 2004.

- Social factors noted to be independent predictors of lower physical function postoperatively
 - Smoking
 - Alcohol use
 - Lower level of education

Complications

- **Perioperative**
 - Malreduction
 - Inadequate fixation
 - Intra-articular hardware penetration
- **Early Postoperative**
 - Wound edge dehiscence/necrosis
 - Infection
 - Compartment syndrome
- **Late**
 - Stiffness
 - Distal tibiofibular synostosis
 - Malunion
 - Nonunion
 - Post-traumatic arthritis
 - Hardware related complications
 - Complex regional pain syndrome

DVT prophylaxis

Effect of Chemical Thromboprophylaxis on the Rate of Venous Thromboembolism After Treatment of Foot and Ankle Fractures

Xin Zheng, MD^{1,2}, Dong-Ya Li, MD¹, Yufan Wangyang, MD³, Xing-Chen Zhang, PhD¹, Kai-Jin Guo, MD¹, Feng-Chao Zhao, MD¹, Yong Pang, MD¹, and Yi-Xin Chen, MD²

Foot & Ankle International
Volume 37, Issue 11, November 2016, Pages 1218-1224
© The Author(s) 2016, Article Reuse Guidelines
<https://doi.org/10.1177/1071100716658953>

- N=814
- LMWH v. Placebo
- Routine anticoagulant prophylaxis **was not** found to be necessary for patients with foot and ankle fractures

Questions/Comments

