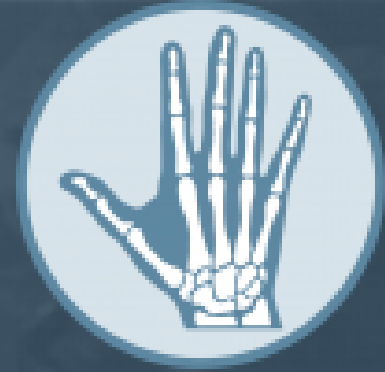



# Terrible Triad Injuries

Jordan Grier, MD

OrthoCarolina Hand and Upper Extremity Center

PAOS Extremities in the Carolinas Conference

5/6/2023





# Disclosures

- None



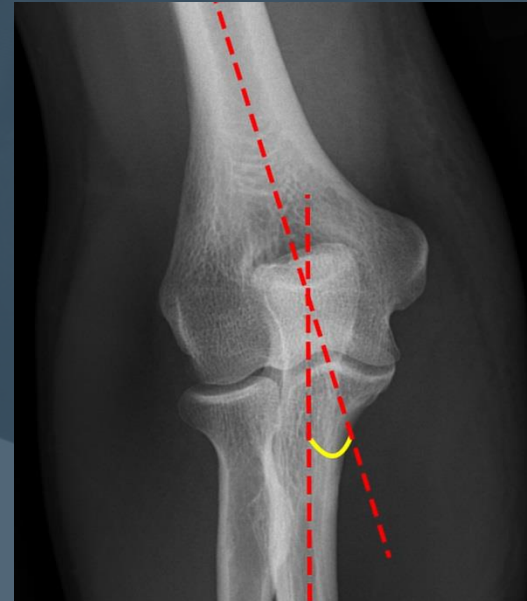
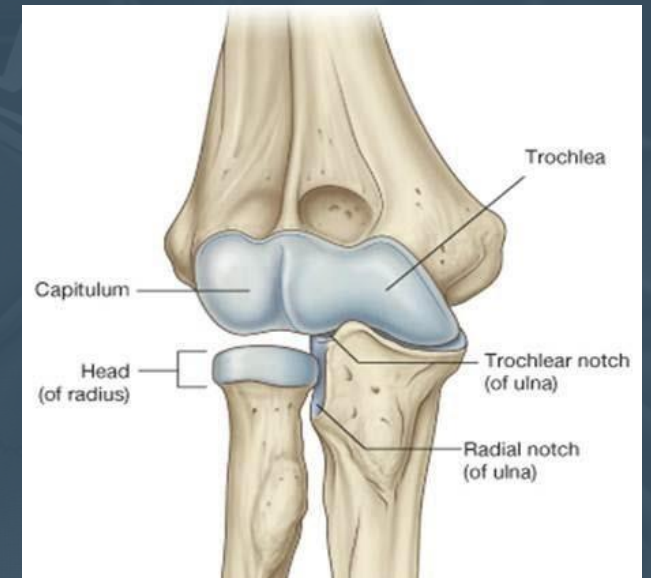# Outline

- Anatomy
- Mechanism of Injury
- Elements of terrible triad injury
- Injury Management
  - Coronoid
  - Radial Head
  - LUCL



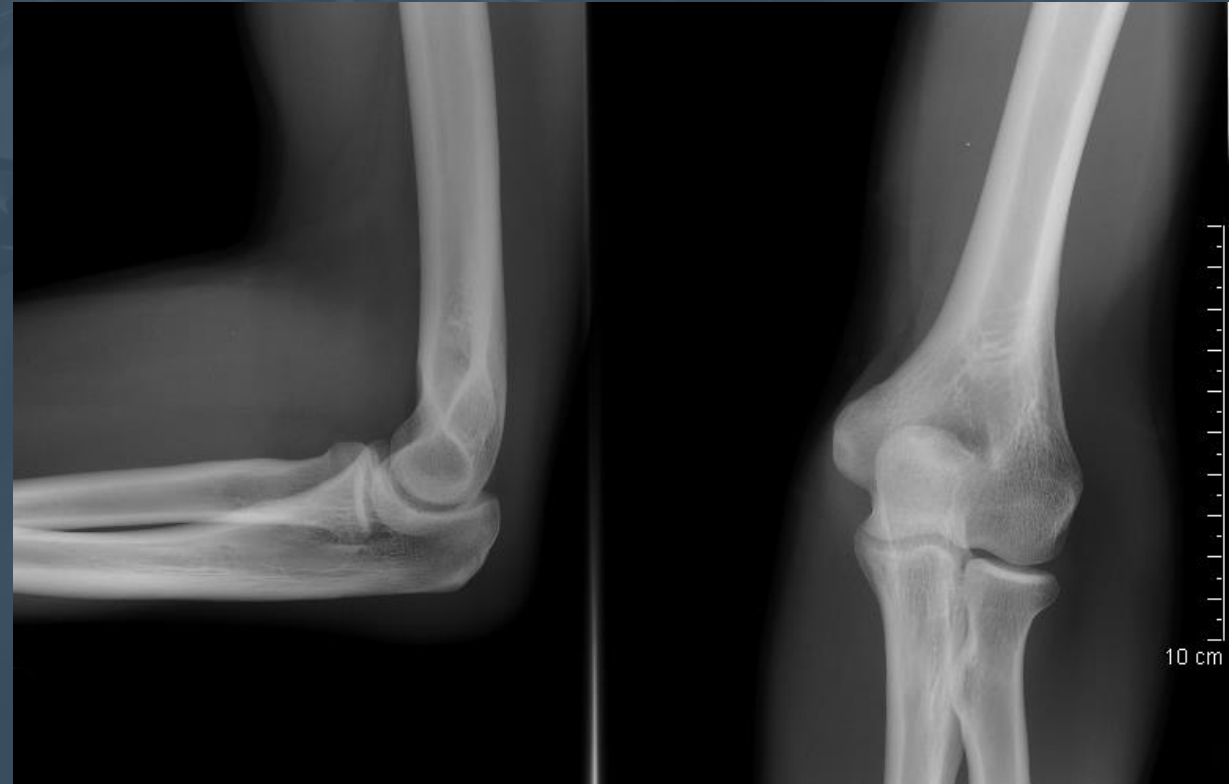# Elbow Anatomy

- 3 articulations
  - ulnohumeral – trochoid (hinge)
  - radiocapitellar – gingylmoid (pivot)
  - proximal radioulnar
- Normal ROM
  - flexion/extension 0-150
  - pronosupination 90-90
- Functional ROM
  - flexion/extension 30-130
  - pronosupination 50-50



# Elbow Stability

- Highly congruous joint, therefore inherently stable
- 2<sup>nd</sup> most commonly dislocated joint in adults
- Stability provided by static and dynamic restraints



# Anatomy – Primary Stabilizers

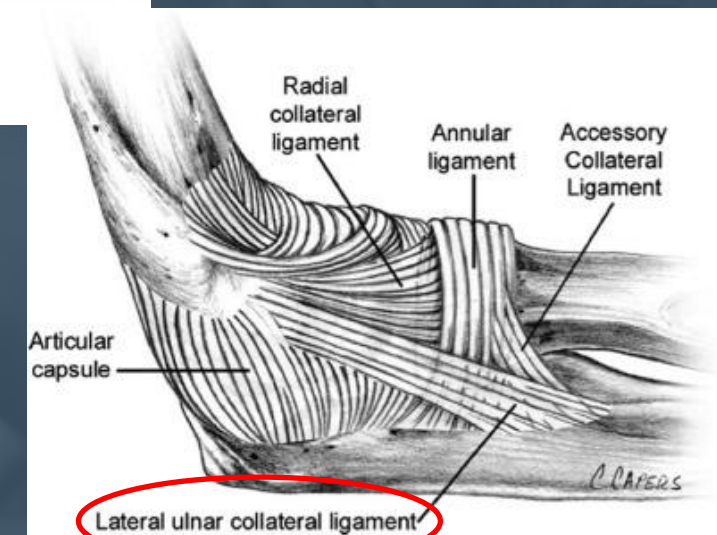
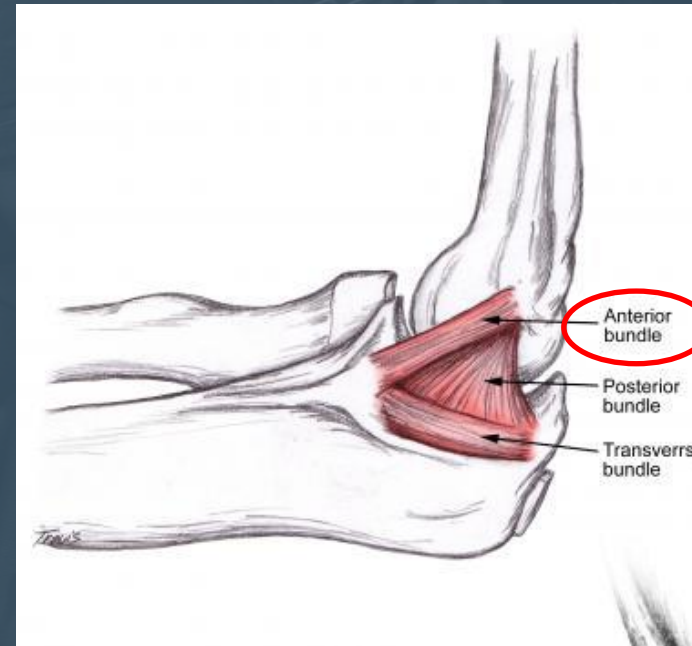
- Ulnohumeral joint via the coronoid

- Medial collateral ligament

- Anterior bundle (valgus restraint)
- Posterior bundle
- Transverse bundle

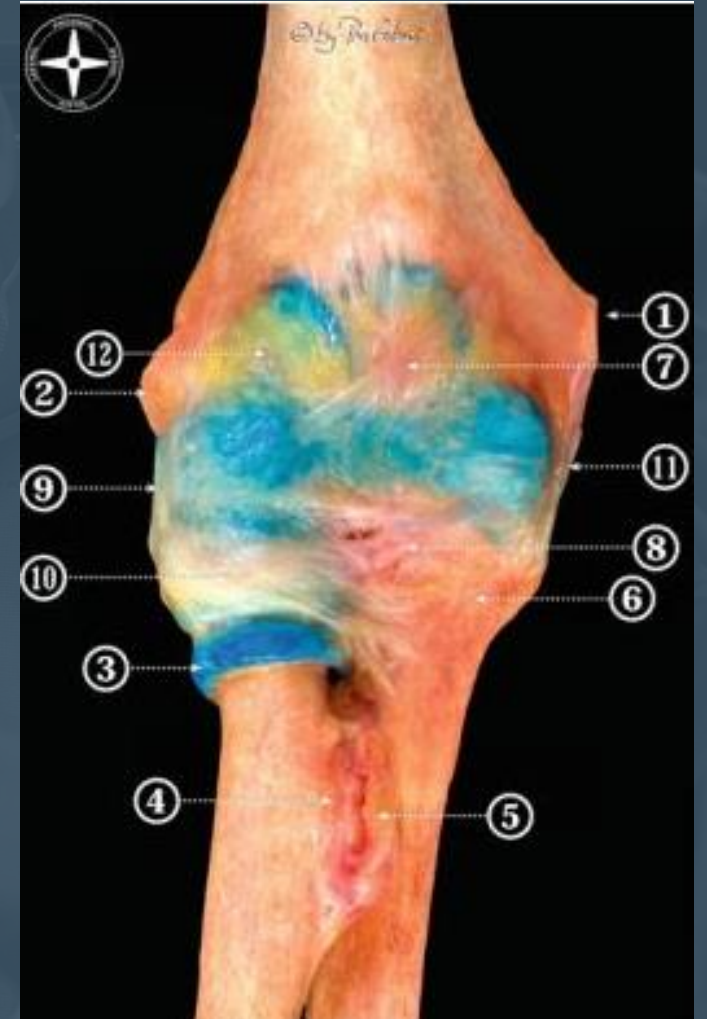
- Lateral collateral ligament complex

- Radial collateral ligament
- Lateral ulnar collateral ligament
  - (varus/ER restraint)
- Accessory collateral ligament
- Annular ligament (PRUJ)



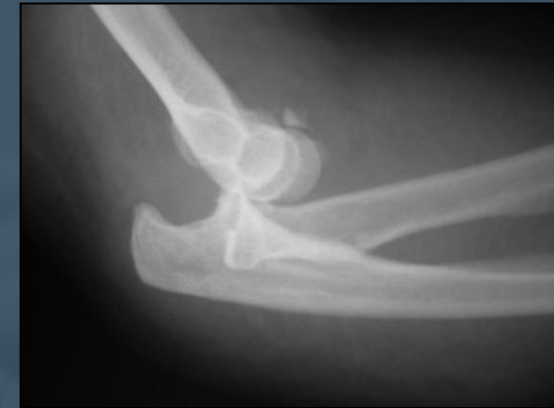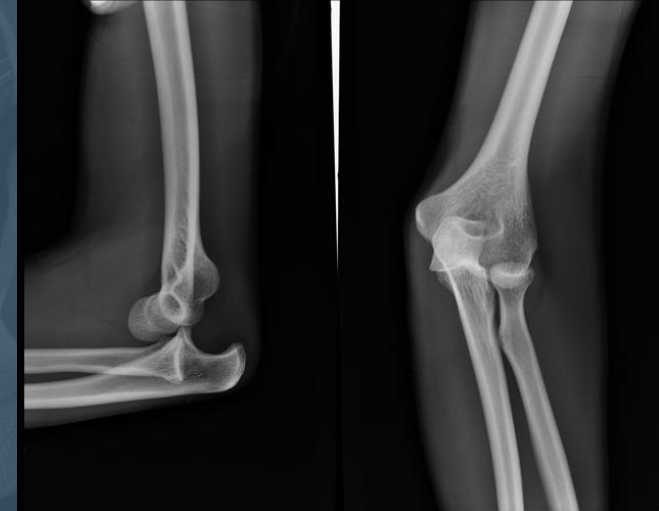# Anatomy – Secondary Stabilizers

- Radial head (via radiocapitellar joint)
  - Provides 30% of valgus stability
- Capsule
  - Most important in extension
  - Maximal distension at 70-80 degrees
- Common flexor/extensor origins
- Dynamic stabilizers
  - Elbow extensors - triceps, anconeus
  - Elbow flexors - biceps, brachialis



# Traumatic Elbow Instability

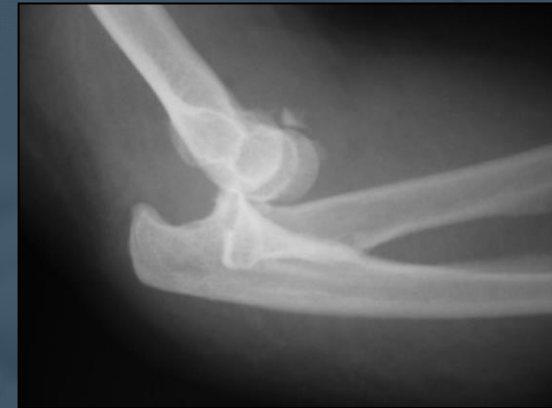- Simple Elbow Dislocation
  - No associated fractures
- Complex Elbow Dislocation
  - Transolecranon Fracture-Dislocation
    - Axial load
  - Valgus Posterolateral Rotatory Injury
    - Axial load + supination + valgus
  - Varus Posteromedial Rotatory Injury
    - Axial load + pronation + varus





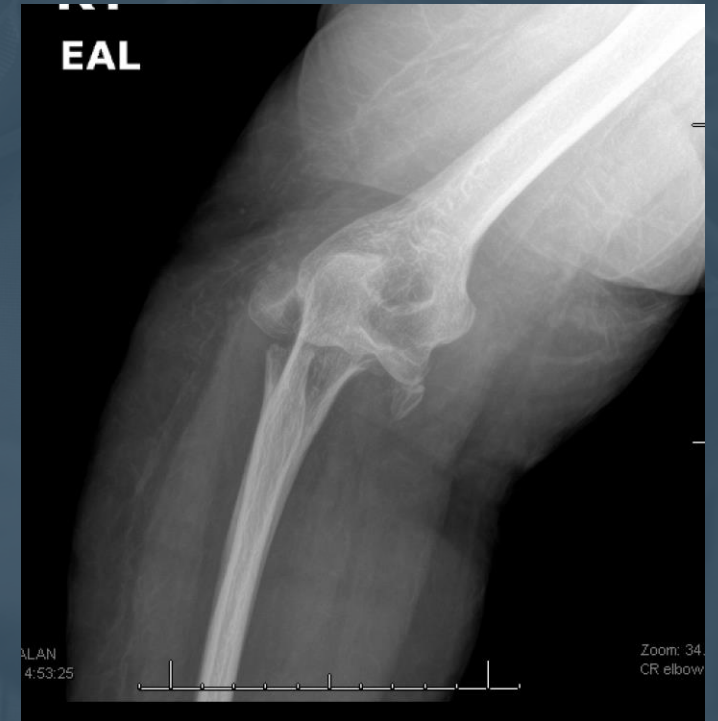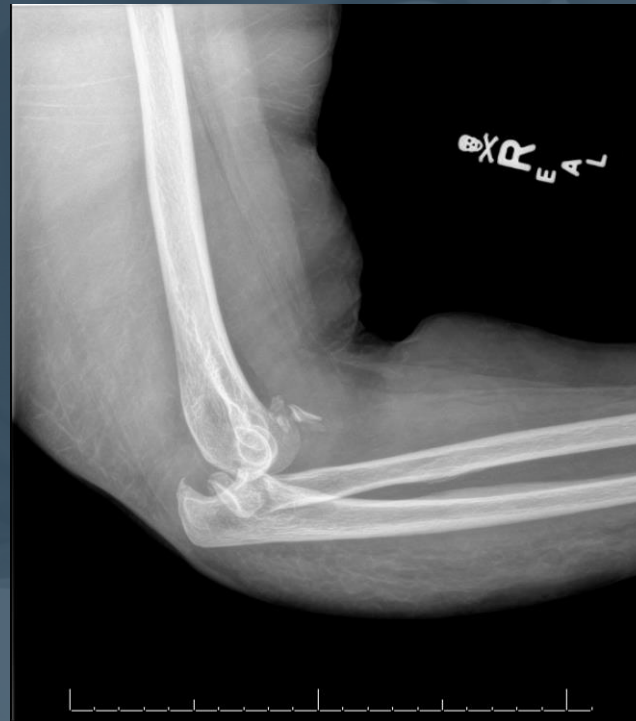# Traumatic Elbow Instability

- Simple Elbow Dislocation
  - No associated fractures
- Complex Elbow Dislocation
  - Transolecranon Fracture-Dislocation
    - Axial load
  - Valgus Posterolateral Rotatory Injury
    - Axial load + supination + valgus
  - Varus Posteromedial Rotatory Injury
    - Axial load + pronation + varus



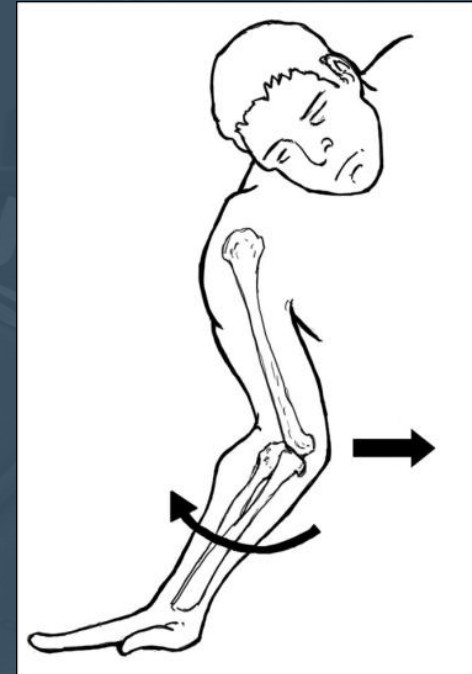
# “Terrible Triad” Injuries

- Elbow dislocation with radial head fracture and coronoid fracture
- Involved structures
  - Radial Head
  - LUCL
  - Coronoid
  - UCL



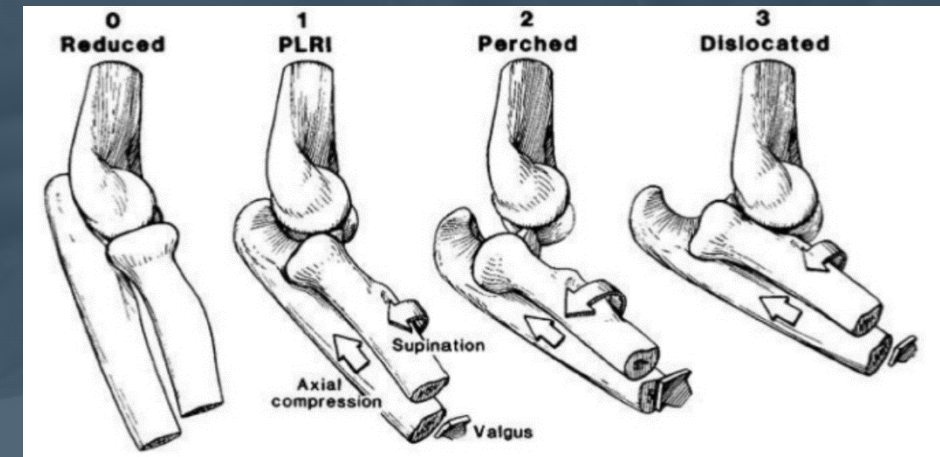
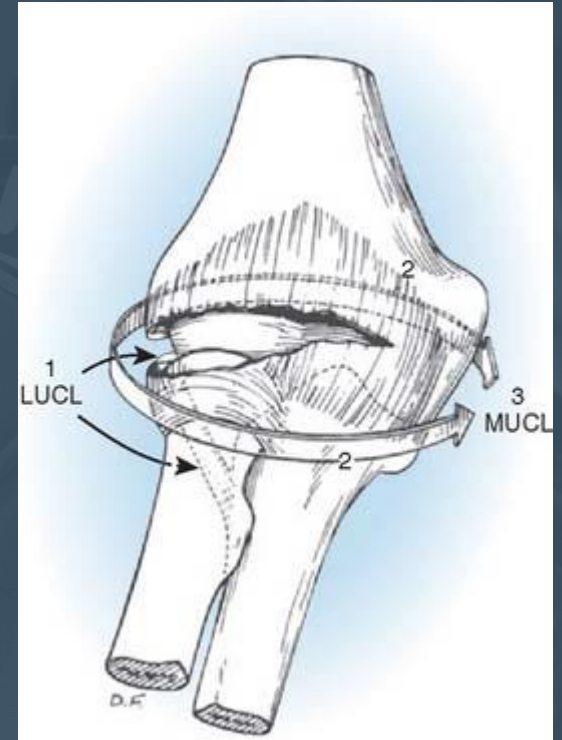
# Mechanism of Injury

- Axial load w/ supination and valgus
  - Most common pattern
- IR of body relative to planted, outstretched hand



# Pattern of Soft Tissue Disruption

- Described by O'Driscoll et al., 1992, *CORR*
- Stages
  1. LUCL disrupted (PLRI)
  2. Anterior/posterior capsule disrupted
  - 3A. Posterior band MCL disrupted
  - 3B. Anterior/posterior MCL bands disrupted



# Terrible Triad Injuries

- Radial Head
  - ORIF vs Arthroplasty vs Excision
- LUCL
  - LUCL Repair
- Coronoid
  - ORIF vs Anterior Capsular Repair vs Excision
- UCL
  - Fix?
- Supplementary Fixation
  - Static or Dynamic Ex-Fix vs Transarticular pinning



# Terrible Triad Injuries – Initial Management

- Urgent reduction similar to simple dislocation
- Range in flexion/extension w/ forearm pronated
  - If unstable at  $> 30^\circ$  flexion, surgery advised
- Examine DRUJ
  - Essex-Lopresti Injury
- Splint elbow at  $90^\circ$  in pronation
  - “Point thumb toward intact ligament”
- CT scan to evaluate coronoid fracture (and radial head fracture)



# Terrible Triad Injuries – Definitive Management

- **Nonoperative treatment – rare**
  - Small radial head fx, coronoid tip fx only
  - Immobilize 2 weeks
  - Conservative rehab
- **Operative management (Pugh et al., 2004, *JBJS*)**
  1. Coronoid fixation
  2. Radial head fixation/replace
  3. LUCL repair / reconstruction
  4. (MCL repair / reconstruction)





---

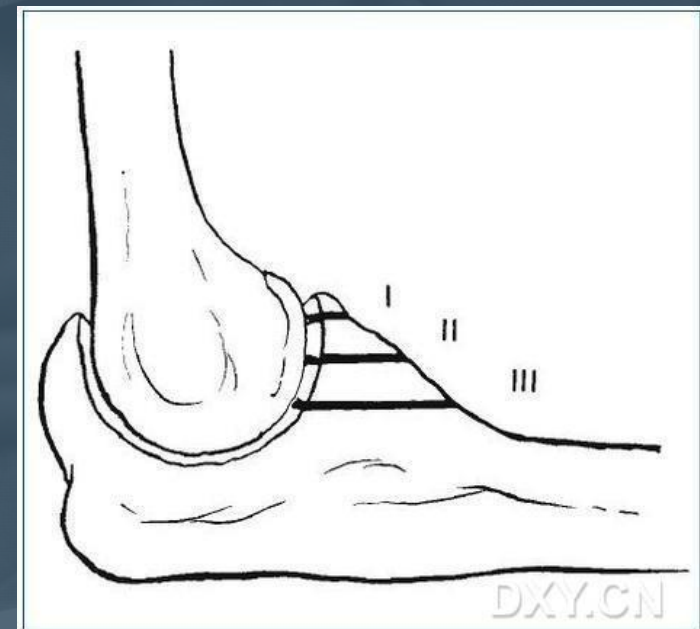
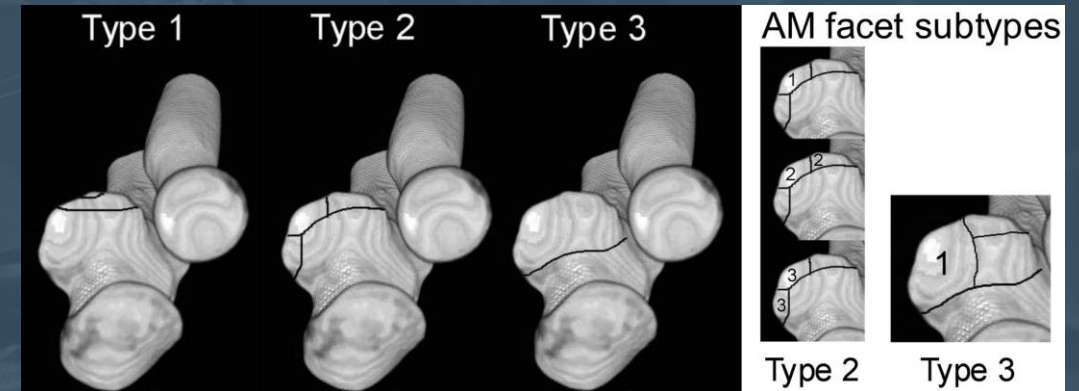
# Coronoid Fractures





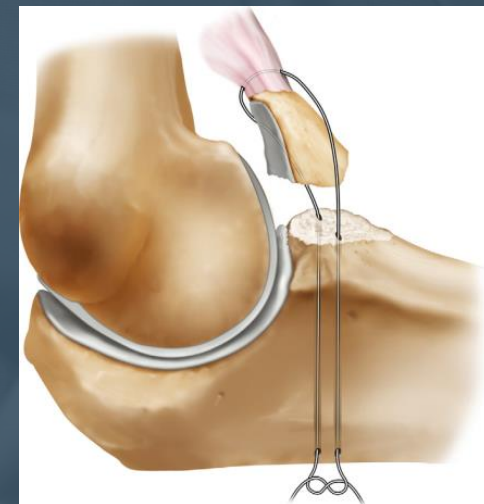
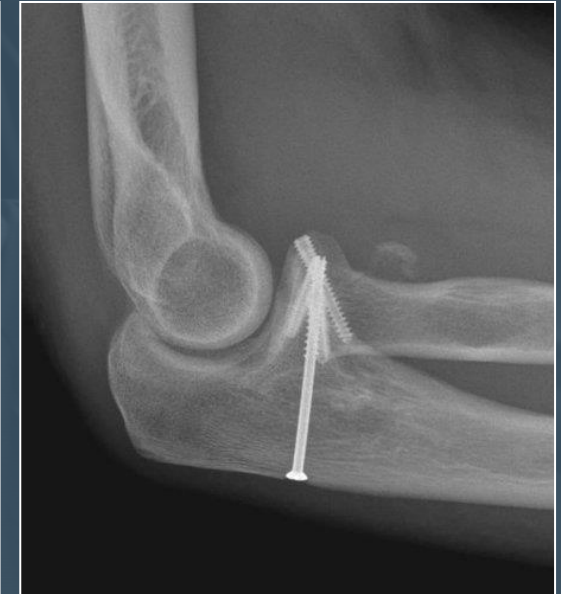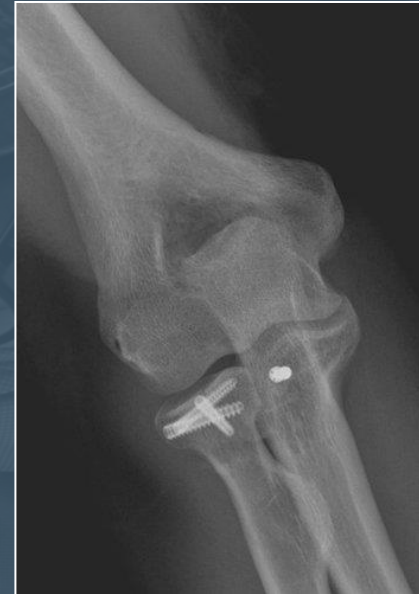# Coronoid Fractures

- Tip
  - Associated with PLRI (valgus instability)
- Anteromedial facet
  - Associated with PMRI (varus instability)
- Base
- Morrey classification
  - I. Small tip avulsion
  - II. <50% coronoid height
  - III. >50% coronoid height



# Coronoid Fractures – Fixation

- If radial head arthroplasty → excise head first to gain exposure
- Fixation options
  - Screws (large fragments)
    - Cannulated or no—cannulated headed screws
  - Suture lasso (small/comminuted)
    - Garrigues, Ruch, et al., 2011 *JBJS*





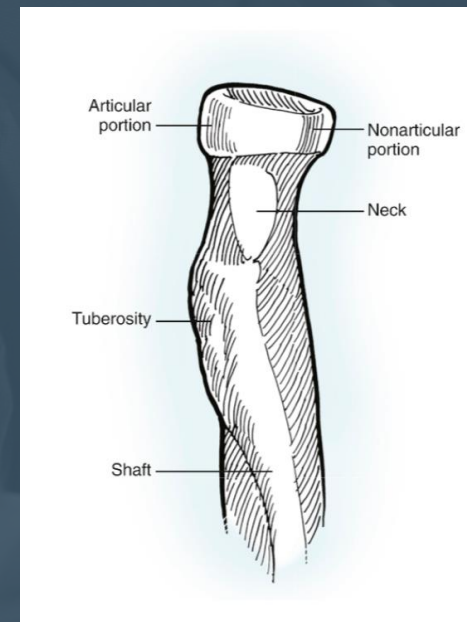
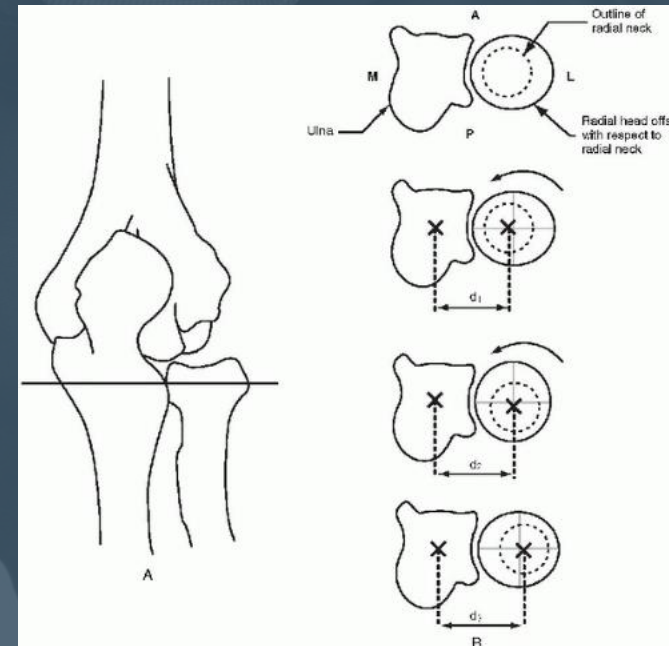
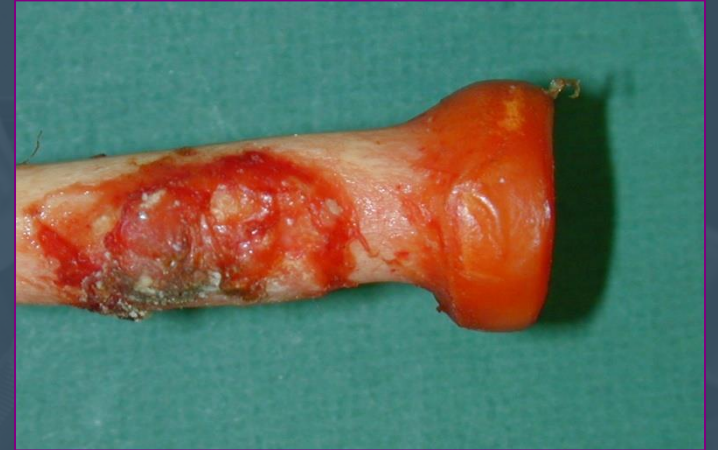
---

# Radial Head Fractures



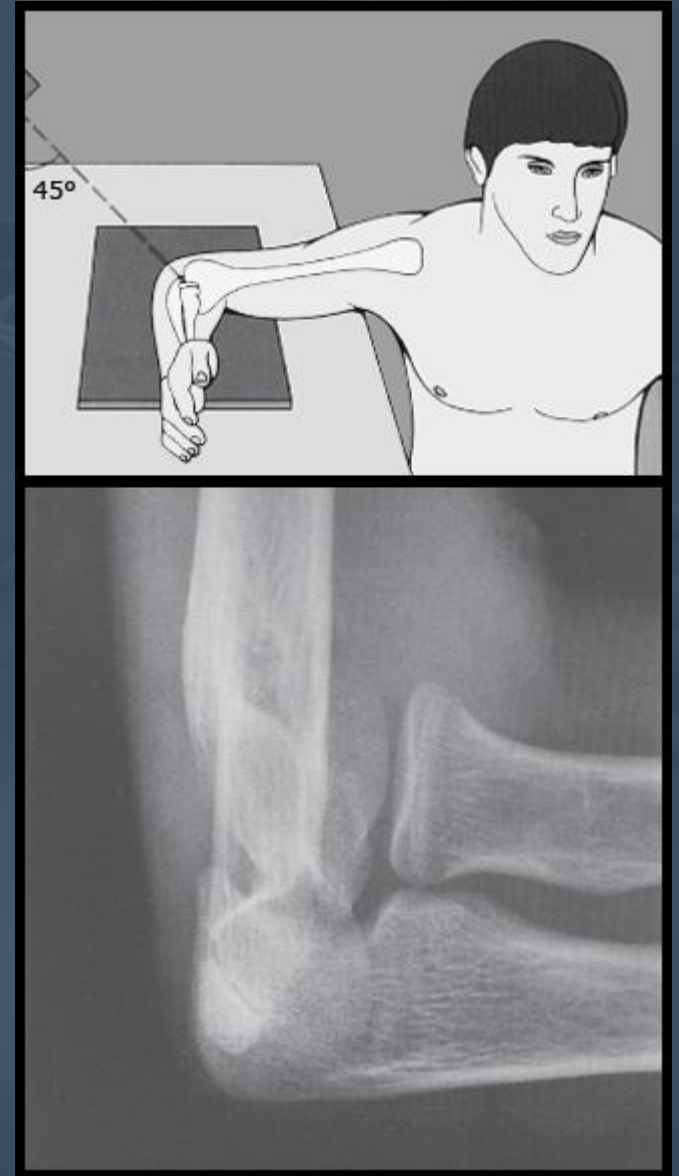# Radial Head Anatomy

- Circular, concave dish that articulates with spherical capitellum
- Dish has greater radius of curvature than capitellum, leading to moderate constraint
- Dish has variable offset, angle from axis of neck
- Margin of the radial head that articulates with the ulna is elliptical
  - \*\*Relevant to arthroplasty selection
  - Slight radial displacement of radius with pronation
- Anterolateral 1/3 has no cartilage



# Evaluation

- Mechanism
- Associated injuries
  - Wrist → Essex-Lopresti
- Prior trauma/surgery
  
- Evaluate elbow instability
  - Valgus stress @30 degrees with arm pronated
  
- Radiographs: AP, lateral
  - Greenspan view: 45°
  
- CT scan



Greenspan View



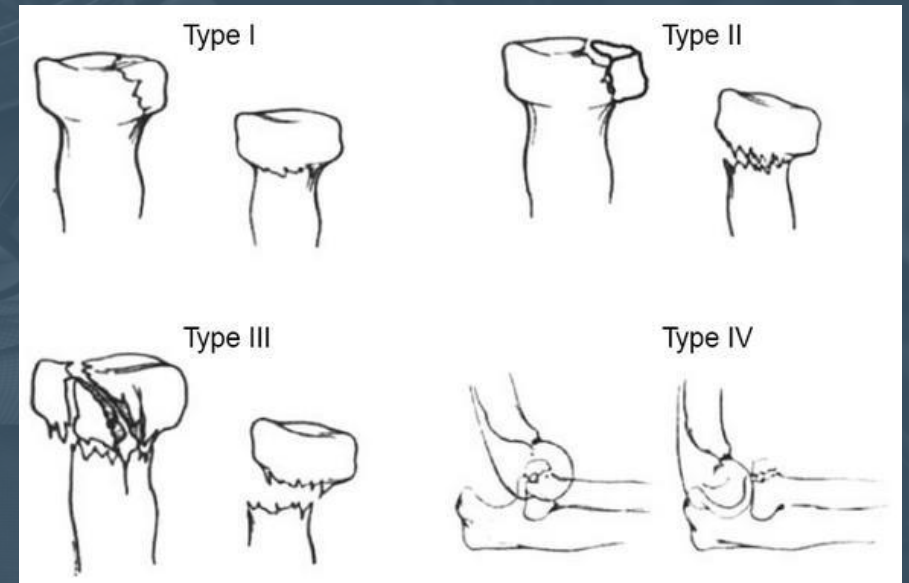
# Radial Head Fracture – Mason Classification

**Table 1**

**Mason Classification\***

Type I	Minimally displaced fracture, no mechanical block to forearm rotation, intra-articular displacement <2 mm
Type II	Fracture displaced >2 mm or angulated, possible mechanical block to forearm rotation
Type III	Severely comminuted fracture, mechanical block to motion
Type IV <sup>22</sup>	Radial fracture with associated elbow dislocation

\* As modified by Hotchkiss.<sup>19</sup>



- \*Also, Type I → II if there is >30% articular surface involvement (Morrey and Sanchez-Sotelo, 2009)

# Radial Head Fracture – Mason Type I

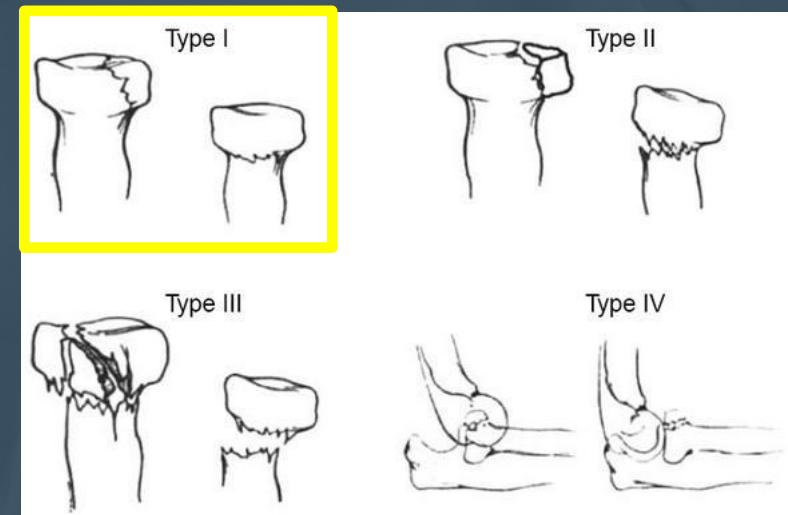
- No mechanical block to motion – **NONOPERATIVE TX**
- **SHORT** period of immobilization
- **EARLY** progression of range of motion

**Table 1**

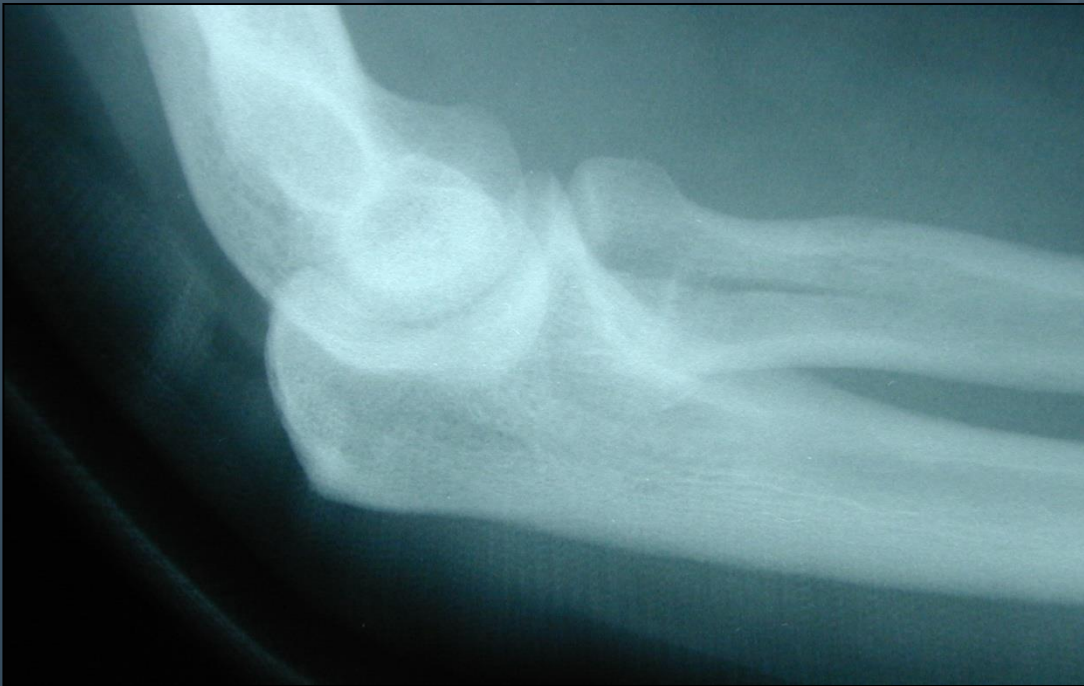**Mason Classification\***

Type I	Minimally displaced fracture, no mechanical block to forearm rotation, intra-articular displacement <2 mm
Type II	Fracture displaced >2 mm or angulated, possible mechanical block to forearm rotation
Type III	Severely comminuted fracture, mechanical block to motion
Type IV <sup>22</sup>	Radial fracture with associated elbow dislocation

\* As modified by Hotchkiss.<sup>19</sup>



# Radial Head Fracture – Mason Type II



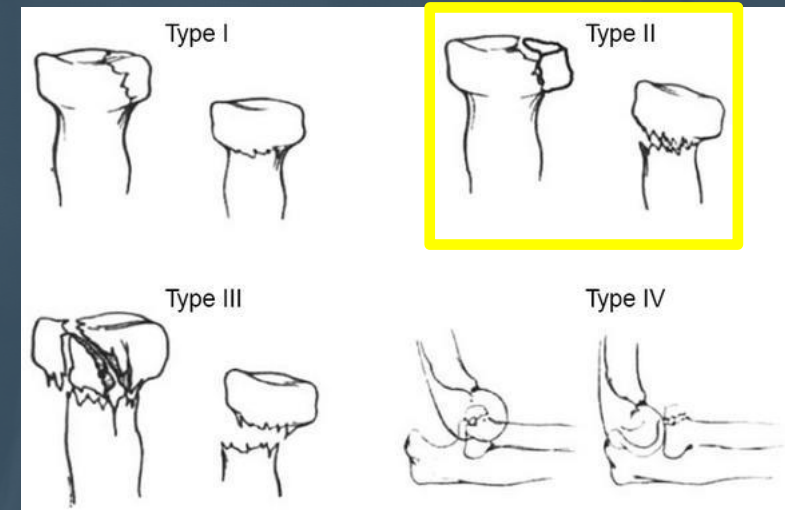
- Management: usually ORIF

**Table 1**

**Mason Classification\***

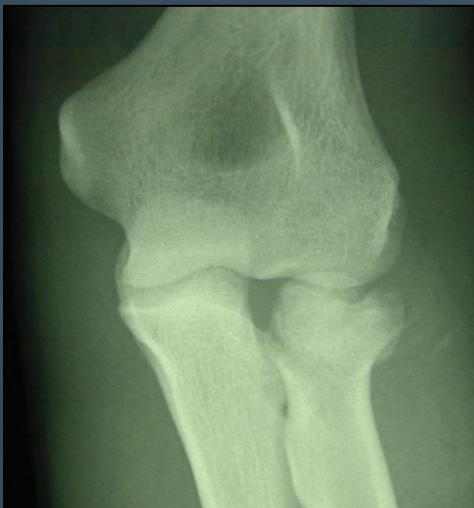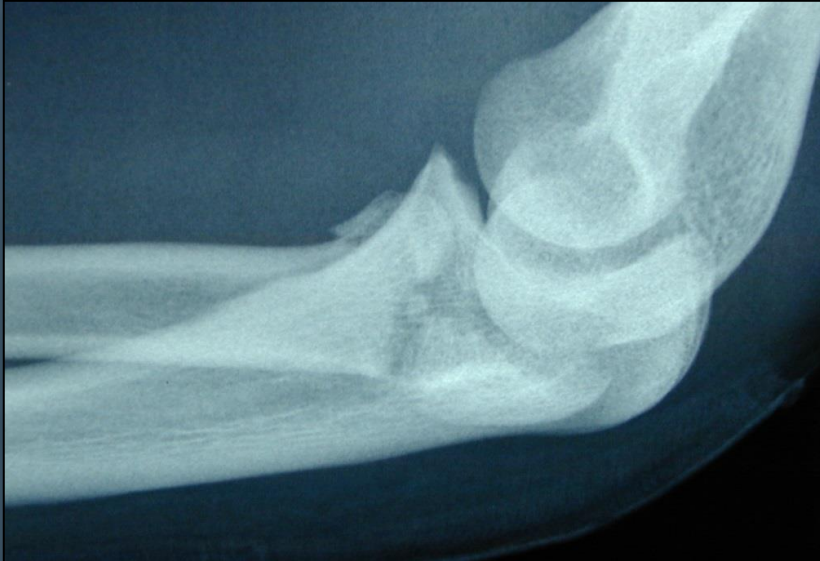Type I	Minimally displaced fracture, no mechanical block to forearm rotation, intra-articular displacement <2 mm
Type II	Fracture displaced >2 mm or angulated, possible mechanical block to forearm rotation
Type III	Severely comminuted fracture, mechanical block to motion
Type IV <sup>22</sup>	Radial fracture with associated elbow dislocation

\* As modified by Hotchkiss.<sup>19</sup>





# Radial Head Fracture – Mason Type III



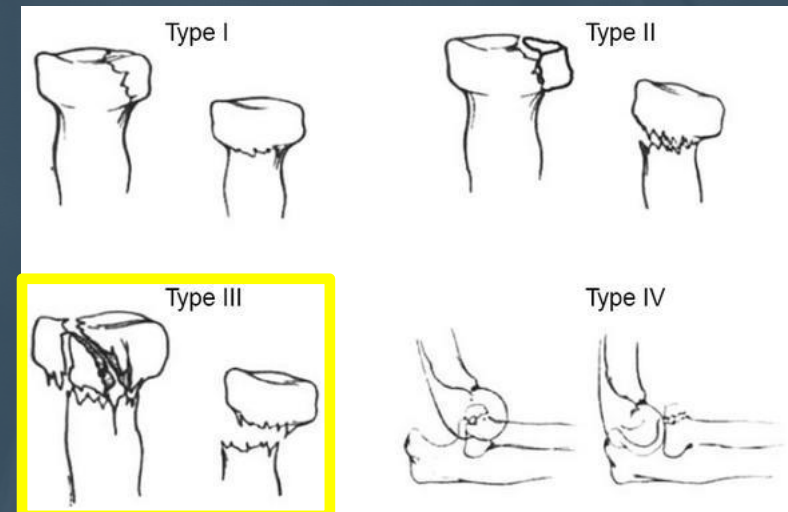
- Management: ORIF vs radial head replacement

**Table 1**

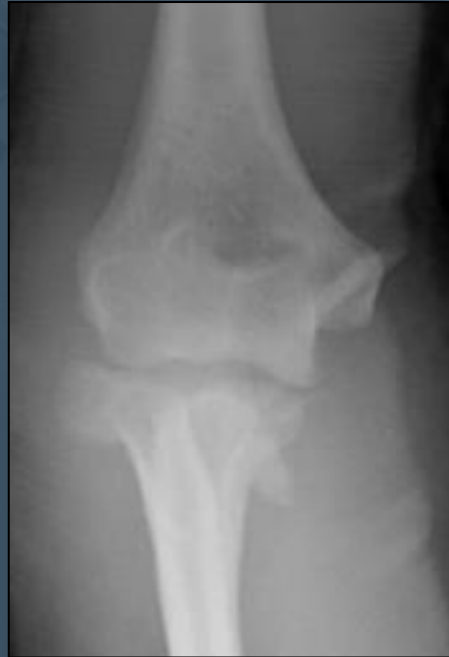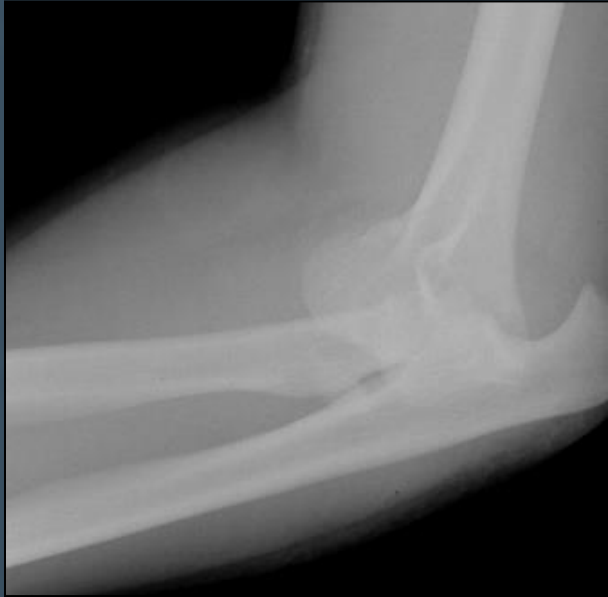**Mason Classification\***

Type I	Minimally displaced fracture, no mechanical block to forearm rotation, intra-articular displacement <2 mm
Type II	Fracture displaced >2 mm or angulated, possible mechanical block to forearm rotation
Type III	Severely comminuted fracture, mechanical block to motion
Type IV <sup>22</sup>	Radial fracture with associated elbow dislocation

\* As modified by Hotchkiss.<sup>19</sup>



# Radial Head Fracture – Mason Type IV



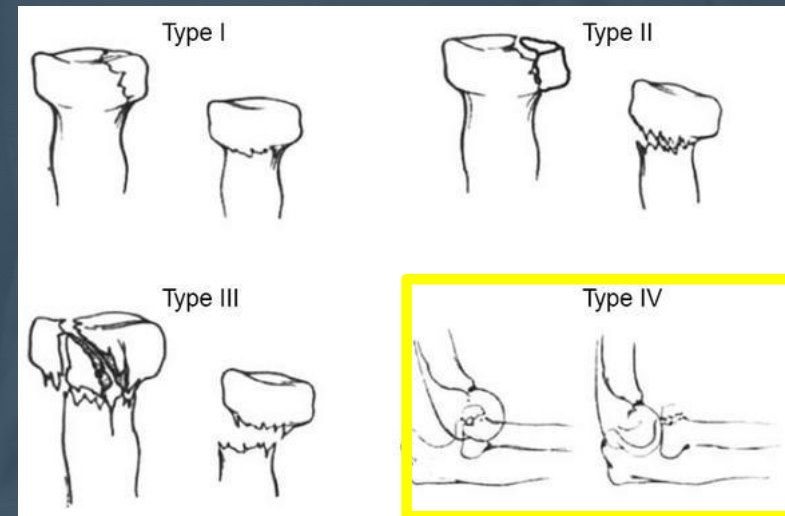
**Table 1**

**Mason Classification\***

Type I	Minimally displaced fracture, no mechanical block to forearm rotation, intra-articular displacement <2 mm
Type II	Fracture displaced >2 mm or angulated, possible mechanical block to forearm rotation
Type III	Severely comminuted fracture, mechanical block to motion
Type IV <sup>22</sup>	Radial fracture with associated elbow dislocation

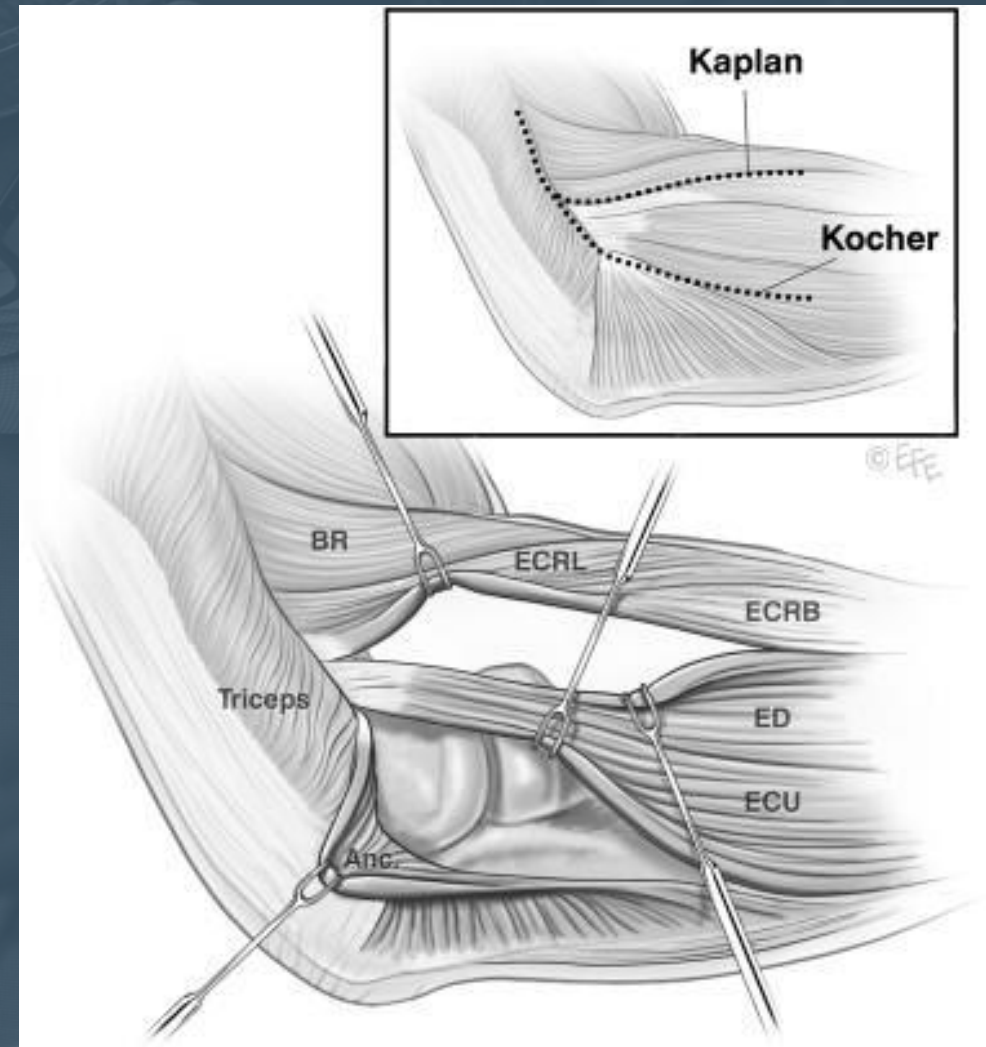
\* As modified by Hotchkiss.<sup>19</sup>

- Management: depends on radial head pattern ORIF vs radial head replacement vs non-op

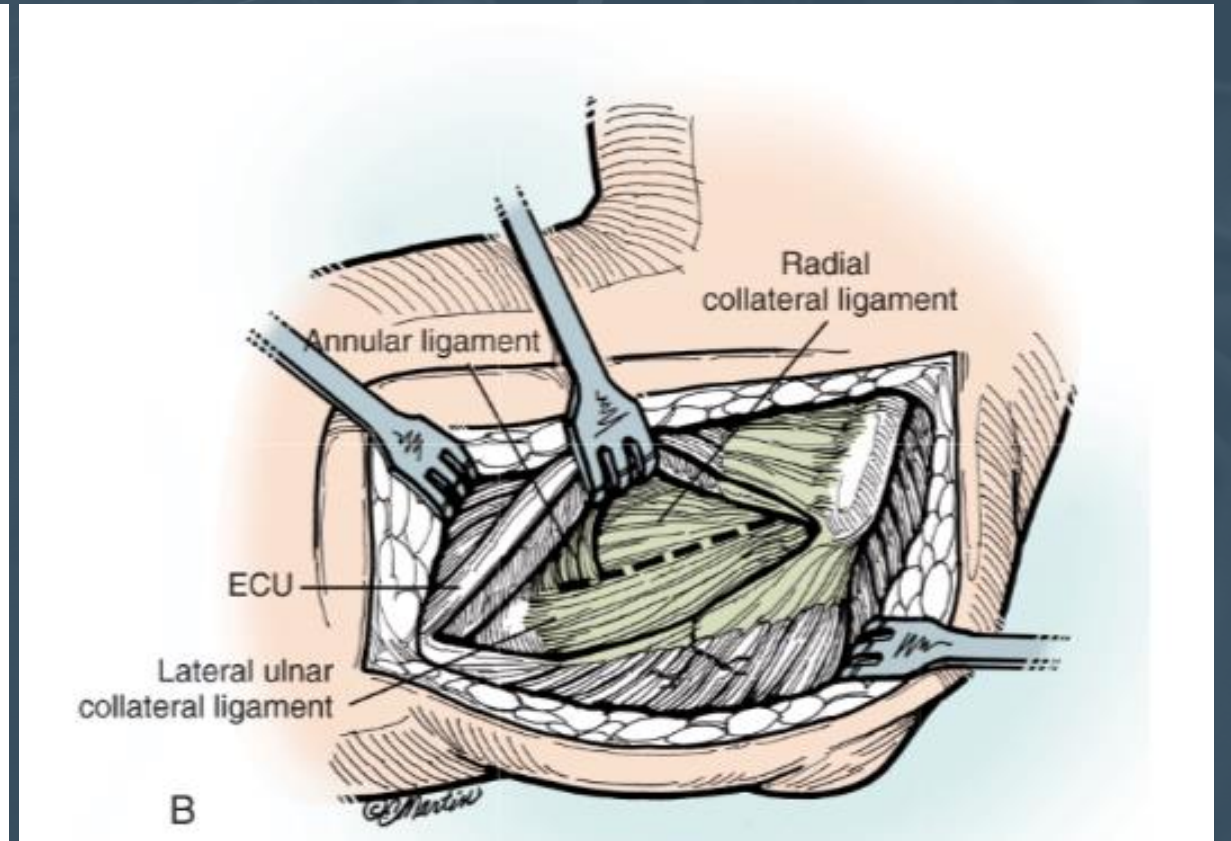
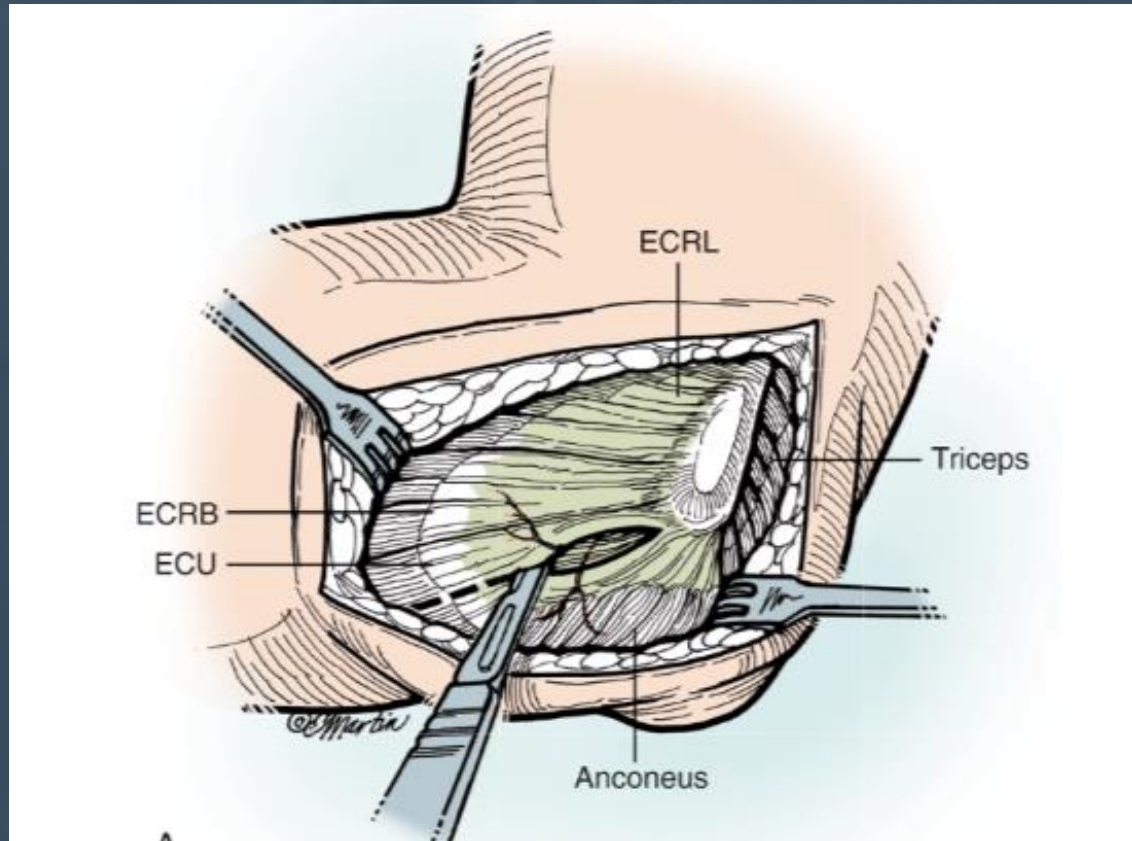


# Surgical Approaches

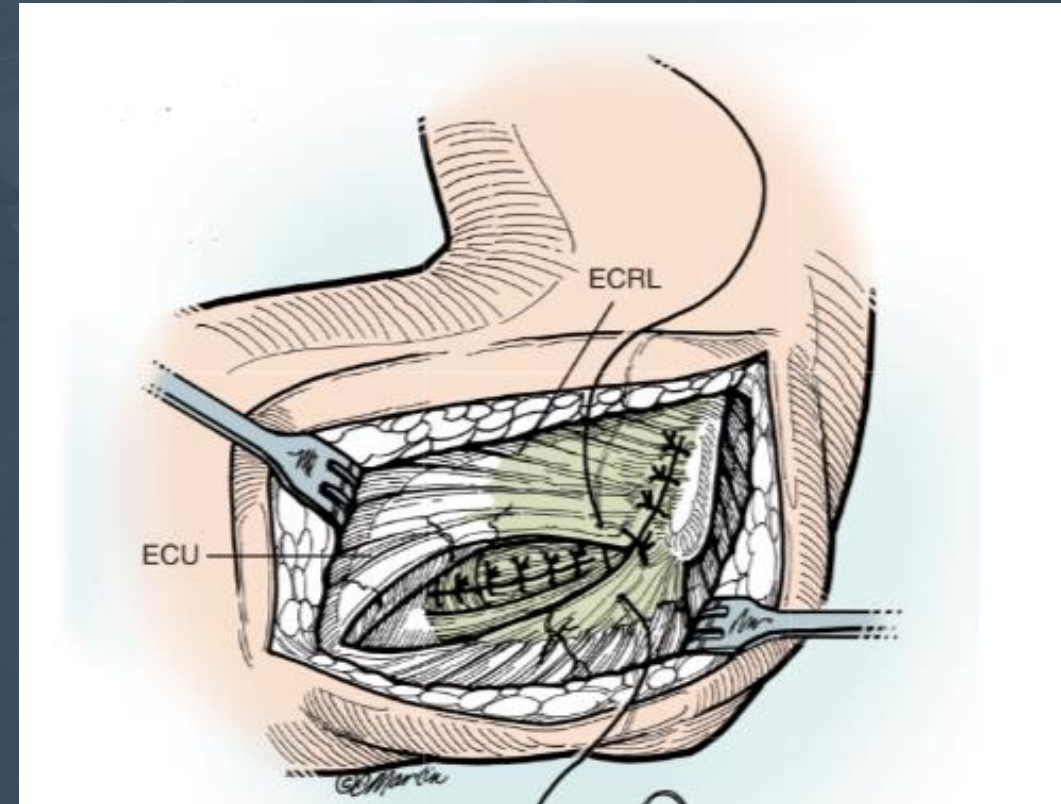
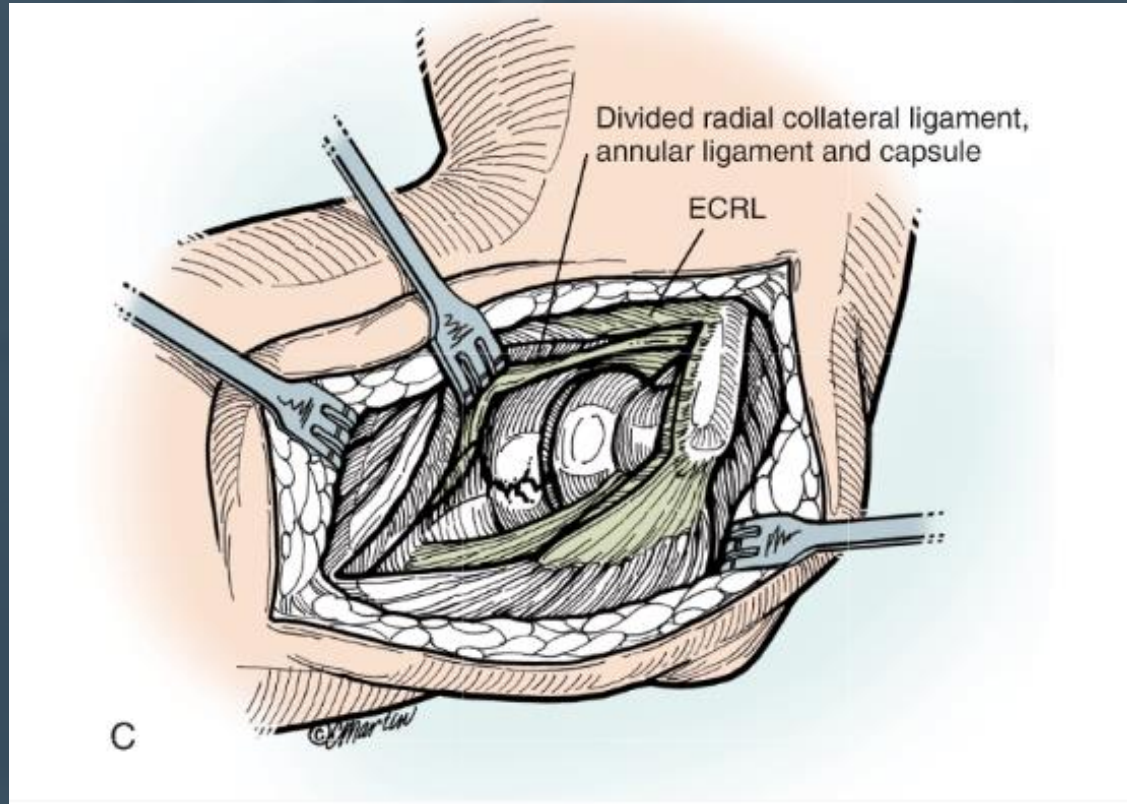
- Kaplan Approach
- Kocher Approach
- EDC Split / 50 yd line



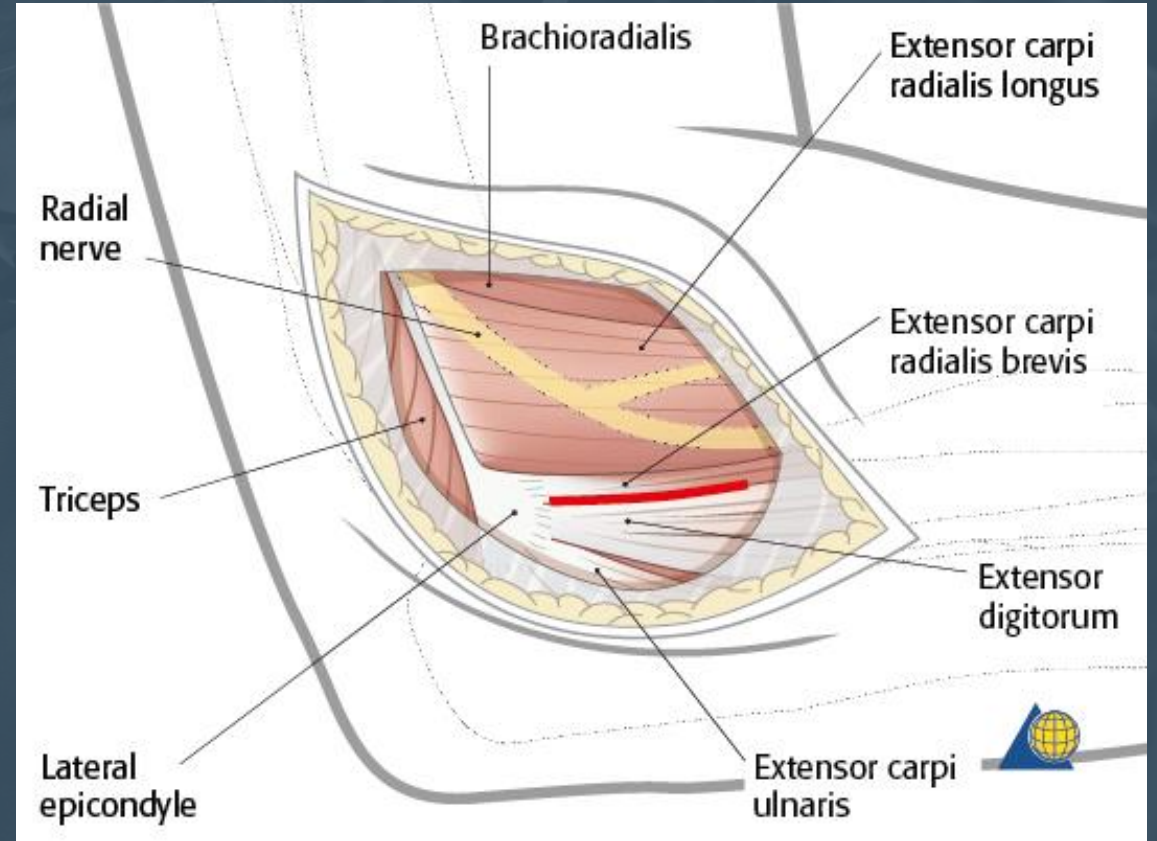
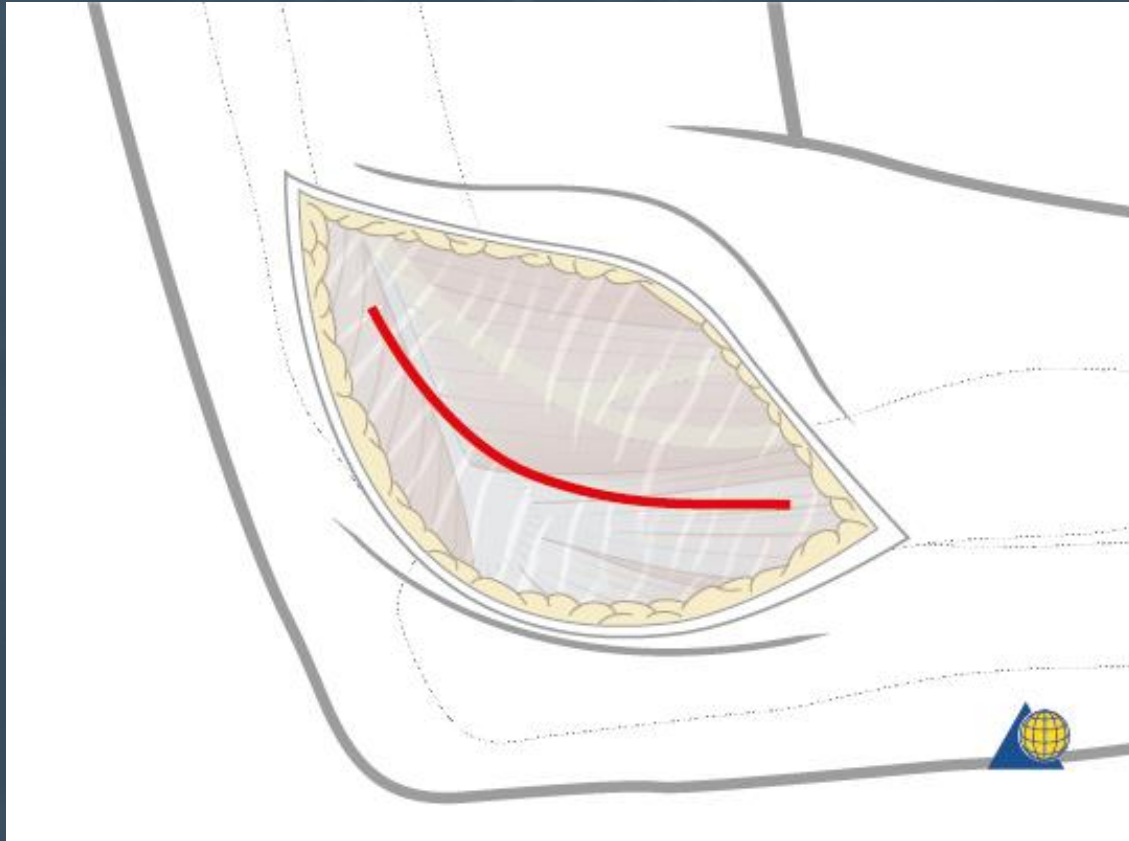
# Kocher Approach



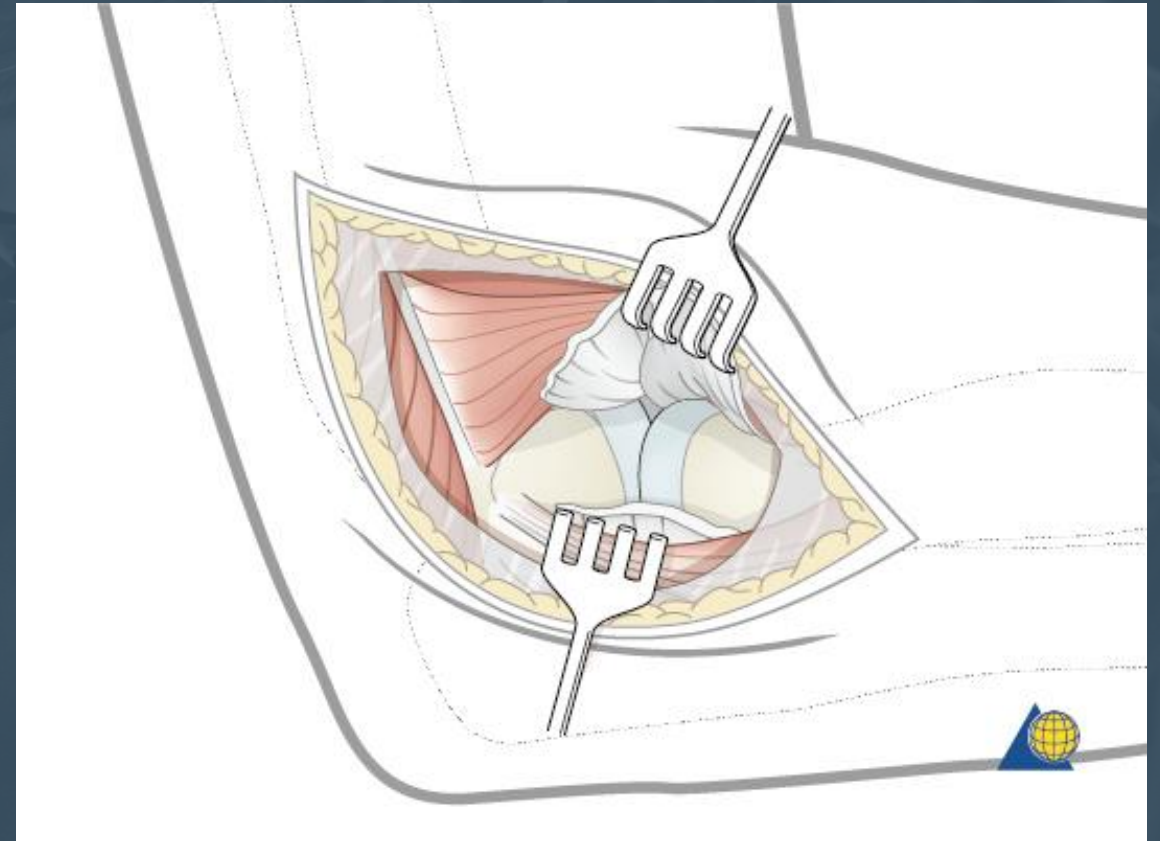
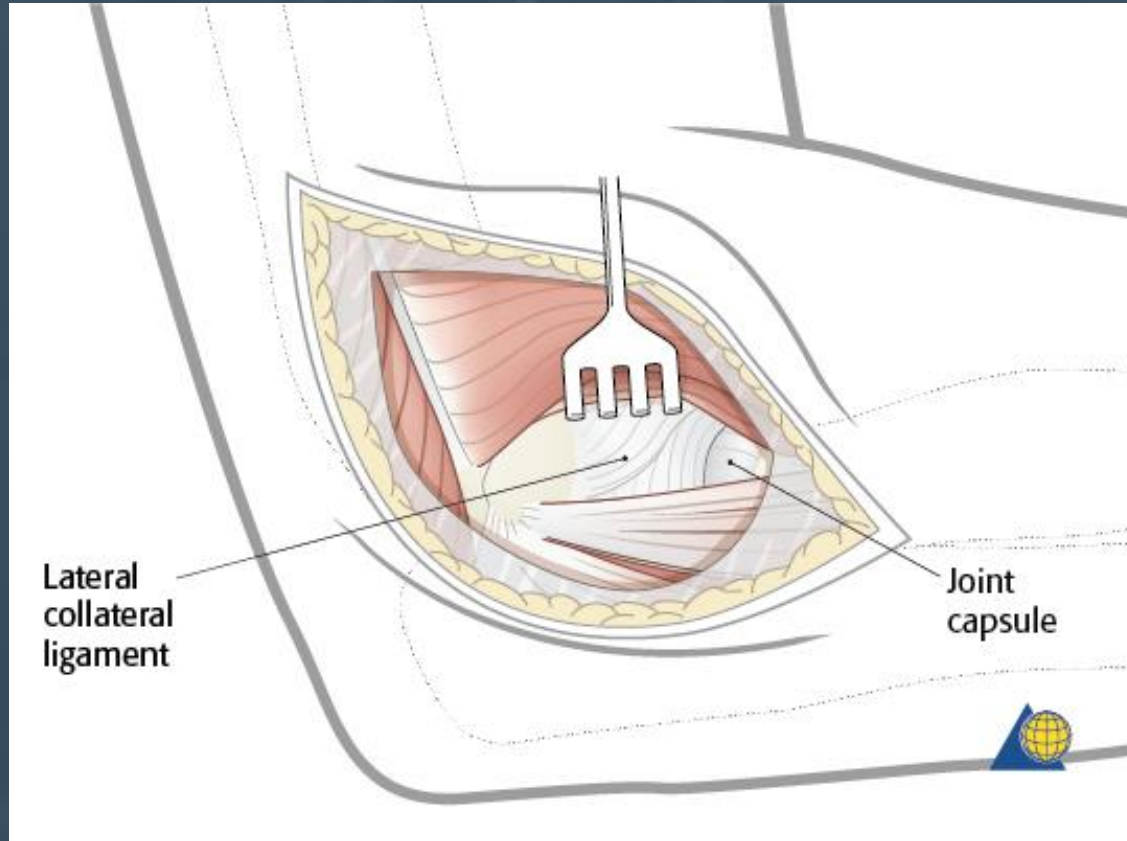
# Kocher Approach



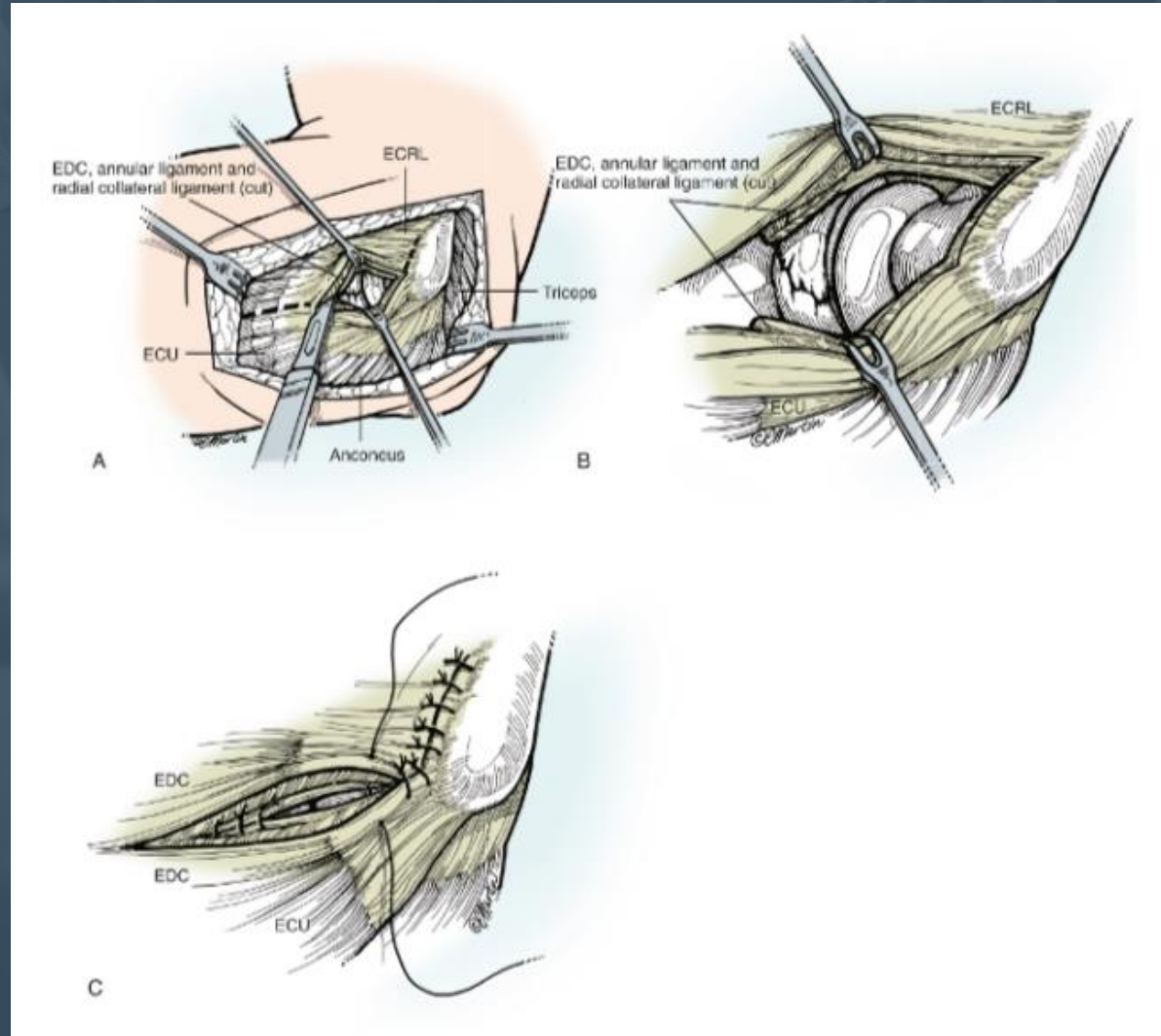
# Kaplan Approach



# Kaplan Approach



# EDC Splint (“50 yard line”) Approach



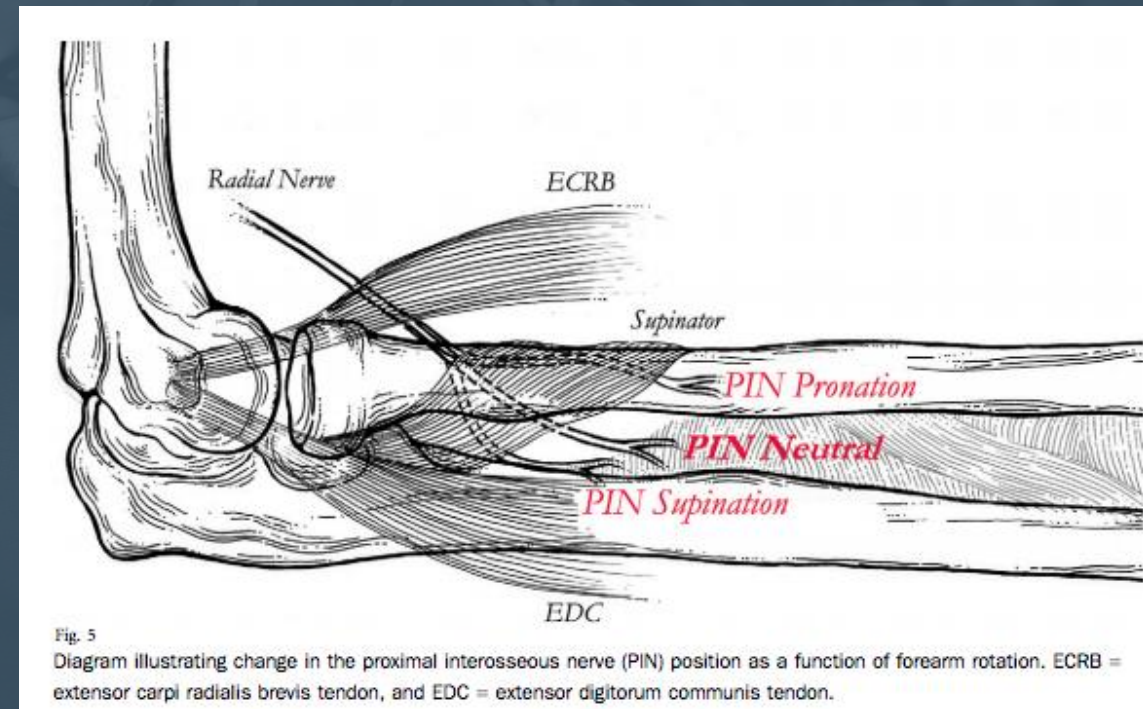


## Variations in the Anatomic Relations of the Posterior Interosseous Nerve Associated with Proximal Forearm Trauma

By Ryan P. Calfee, MD, Joyce M. Wilson, MD, and Ambrose H.W. Wong, BA

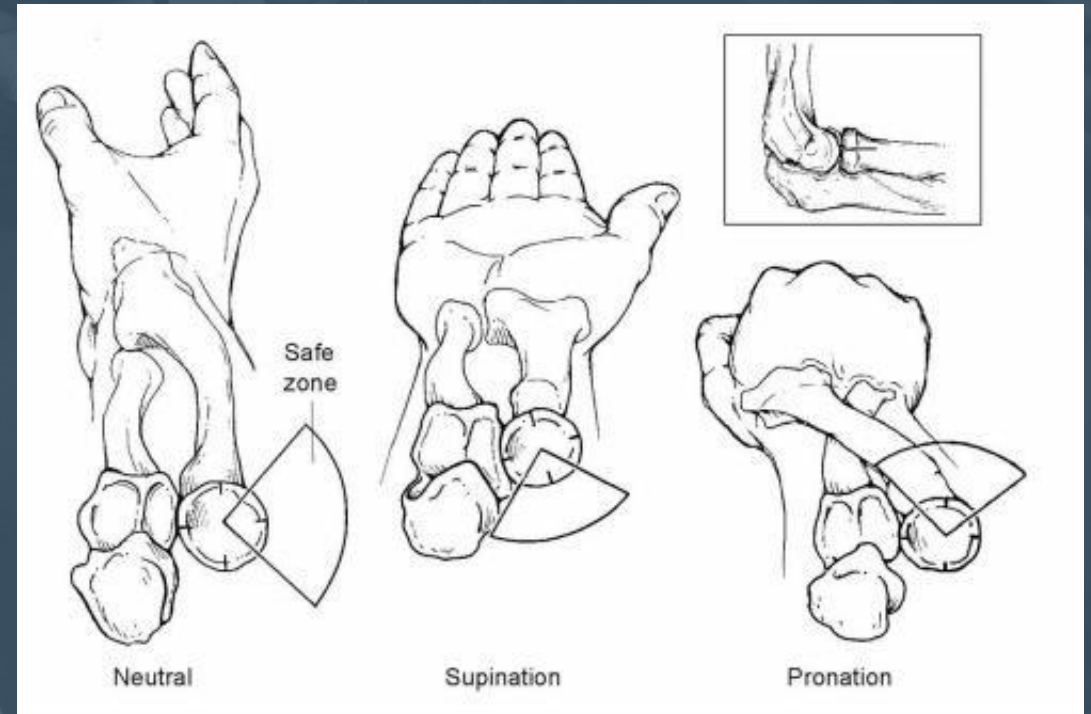
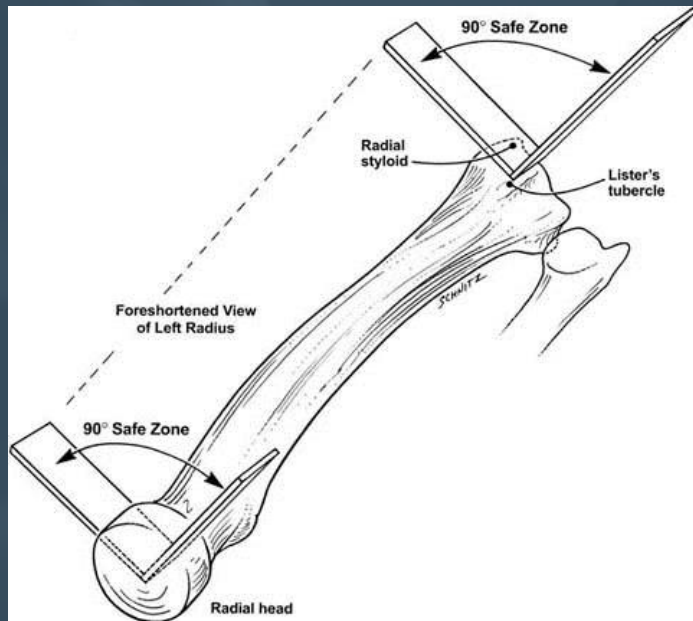
Investigation performed at Washington University Medical Center, St. Louis, Missouri

- Distance from radiocapitellar joint to PIN:
  - Supination: 3.2 cm (1.7 - 4.5)
  - Neutral: 4.2 cm (2.5 – 6.2)
  - Pronation: 5.6 cm (3.1 – 7.4)
- PIN in direct contact with radial diaphysis in 5/20 specimens




# The “Safe Zone”

- 90-100° arc centered on equator in neutral position
- Radial head – Lister’s tubercle



# Fixation Strategies

- 0.035 K-wires
- Mini-fragment fixation
- Headless screws
- Recon plates
- Pre-contoured plates
- Locking plates



# OPEN REDUCTION AND INTERNAL FIXATION OF FRACTURES OF THE RADIAL HEAD

BY DAVID RING, MD, JAIME QUINTERO, MD, AND JESSE B. JUPITER, MD

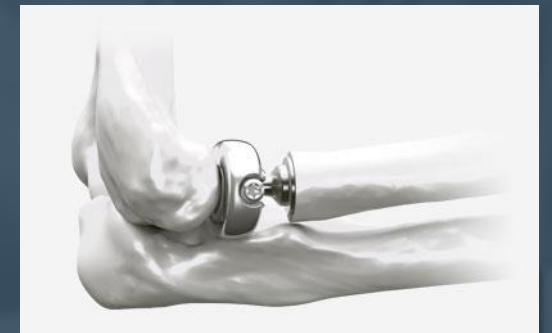*Investigation performed at Massachusetts General Hospital, Boston, Massachusetts, and Hospital Universitario Clínica San Rafael, Bogota, Colombia*

- 56 patients:
- 30 Mason II
  - 15/30 comminuted
- 26 Mason III
  - 14/26 with >3 fragments
  - 12/26 with 2 or fragments
- Outcomes
  - Mason II w/ comminution:
    - Unsatisfactory: 4/15
  - Mason II w/o comminution:
    - Unsatisfactory: 0/15
  - Mason III w/ >3 fragments:
    - Unsatisfactory: 13/14
  - Mason III w <3 fragments:
    - Unsatisfactory: 1/12



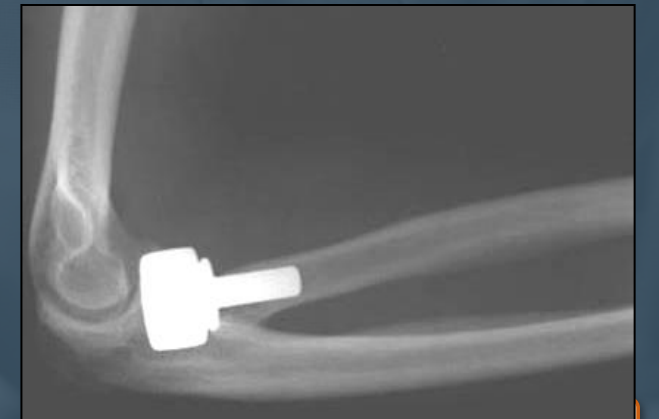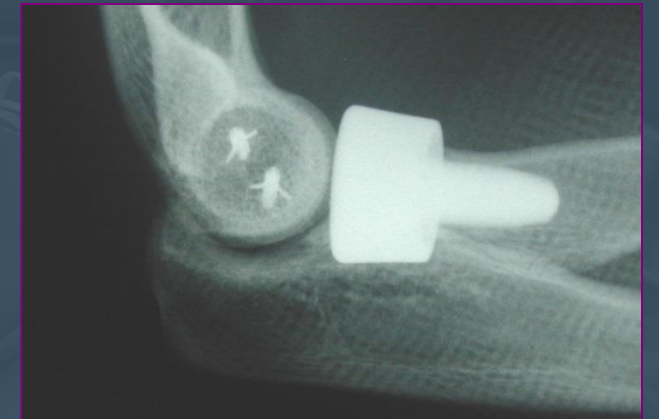
# Radial Head Arthroplasty

- Unreconstructable radial heads / unstable elbow (Mason III-IV)
- >30% articular surface involvement
- >3 fracture fragments



# Radial Head Arthroplasty

- Metallic >> silicone
- Smooth (loose) vs press-fit stem options
- Modularity: avoid head / shaft mismatch
- Must preserve or repair LUCL
- Particularly helpful if instability is present
- Excise enough bone for stable neck base



# Radial Head Arthroplasty

---

## Pearls

- Try to match diameter and height using excised radial head
- Choose one size down
- Prosthesis should articulate at PRUJ, 2mm distal to coronoid
- Translate radial neck laterally to place implant

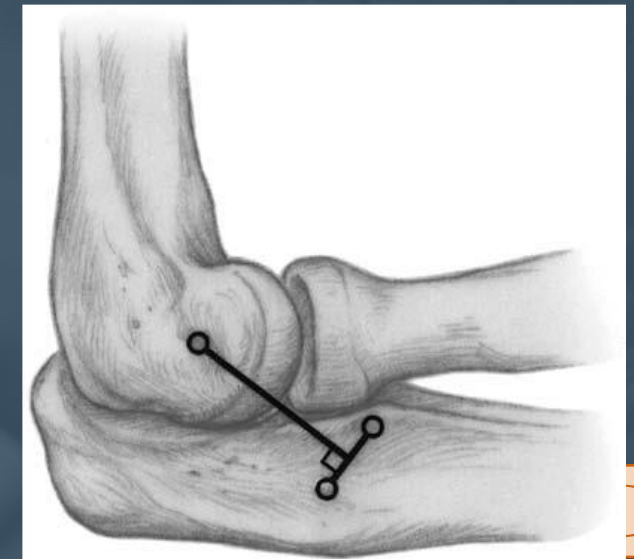
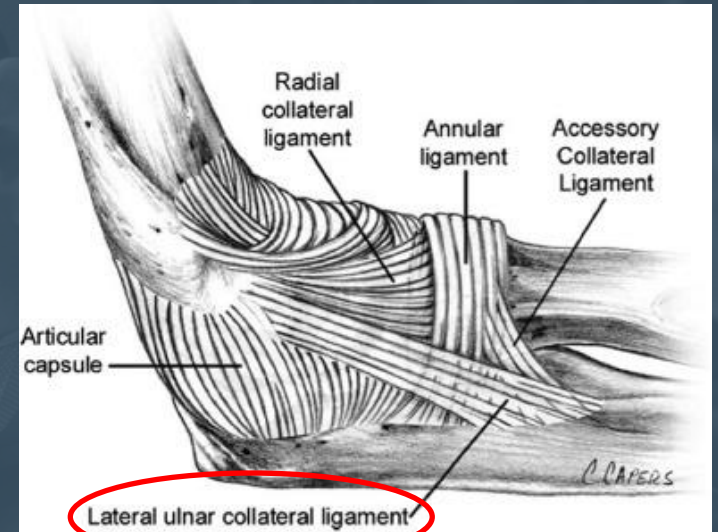
## Pitfalls

- Don't choose size based on gap between radial head and capitellum → results in overlengthening due to incompetent lateral ligaments
- Avoid Hohmanns around radial neck to protect PIN
- Don't overstuff!



# Lateral Collateral Ligament Complex Injuries

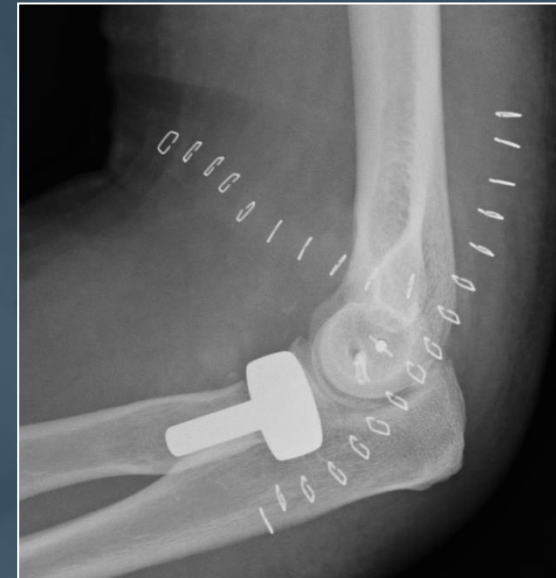
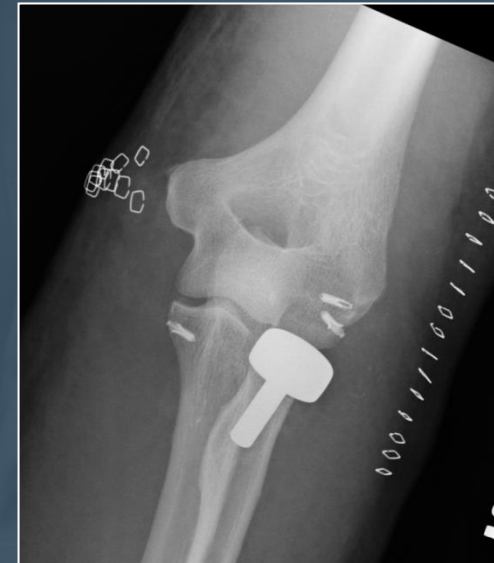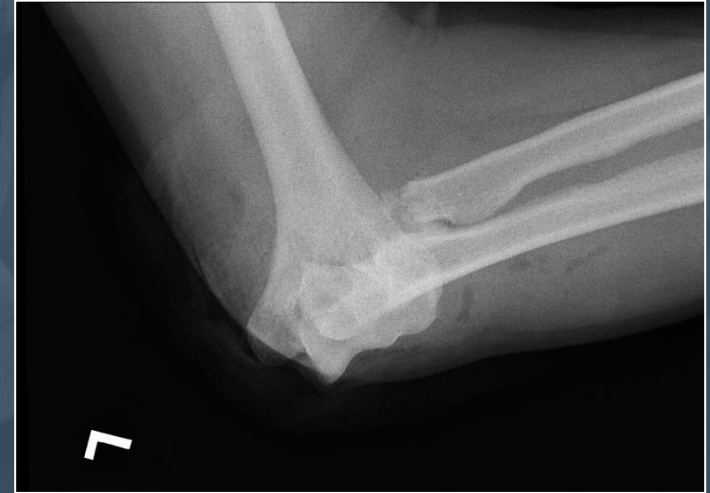- Usually avulsed from humeral origin
- Repair with transosseous sutures or suture anchor at isometric point
  - Distal to lateral epicondyle
  - Tie with elbow in 90° elbow flexion
  - UCL intact: repair LUCL in pronation
  - UCL disrupted: repair in supination





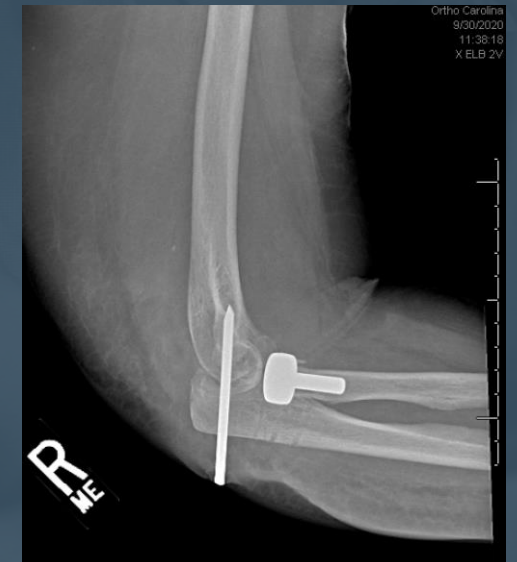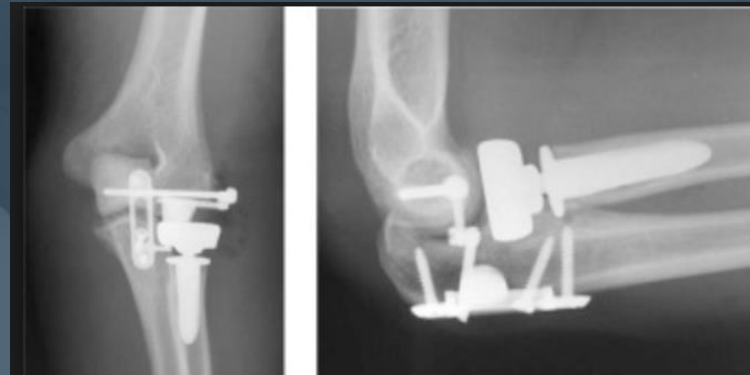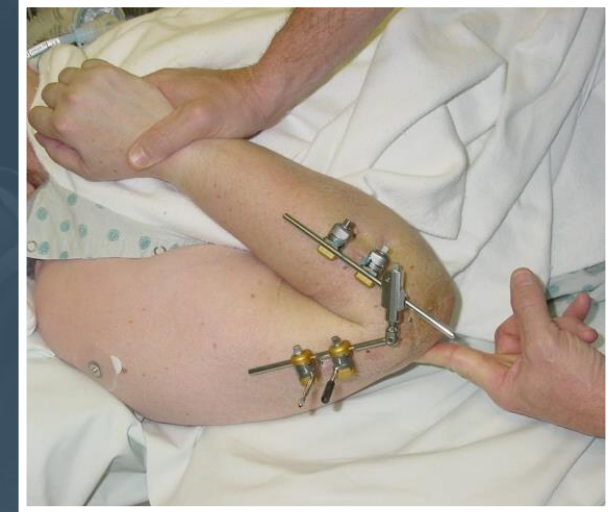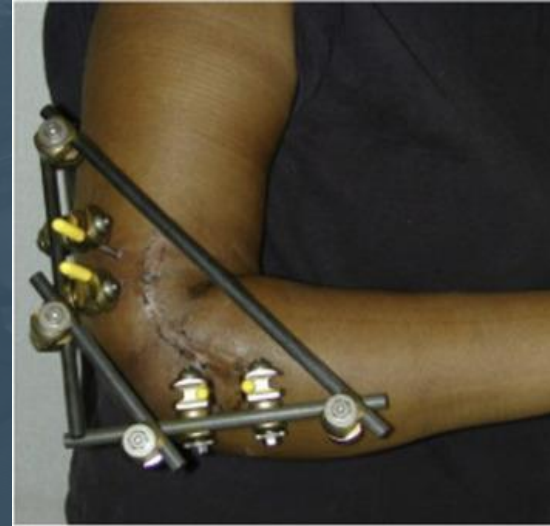# Medial Collateral Ligament Complex Injuries

- Perform “hanging arm test” after addressing coronoid and lateral structures
- If still unstable – UCL repair
  - Beware ulnar nerve
  - Suture anchor – usually avulsed from origin



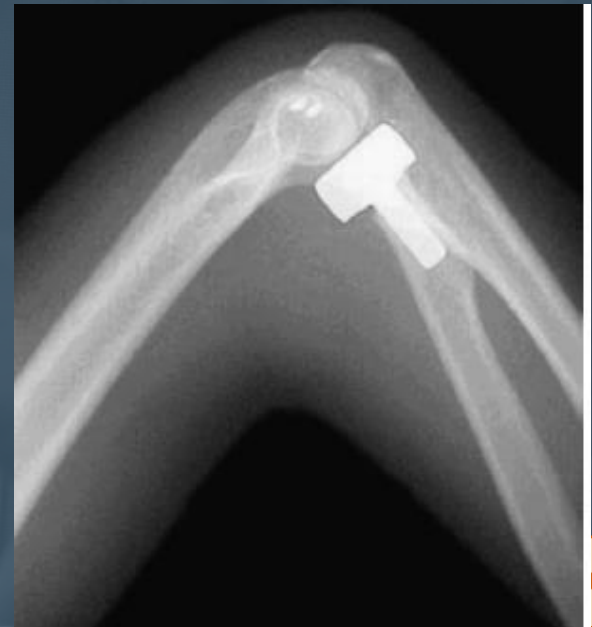# Supplementary Fixation

- Persistent instability following fixation and ligament repairs
- Static External Fixator
- Hinged External Fixator
- Internal Joint Stabilizer
- Transarticular Pinning



# Postoperative Rehabilitation

- Splint x 3-5 days
  - Splint in pronation unless MCL is repaired (then neutral)
- **Supine overhead motion protocol**
  - A/AROM, pro/sup @ 90
- Hinged elbow brace commonly used, but may not improve stability\*
- **Avoid shoulder abduction**
  - Leads to varus stress @ elbow
- Progressive static splinting @ 6-12 wks PRN



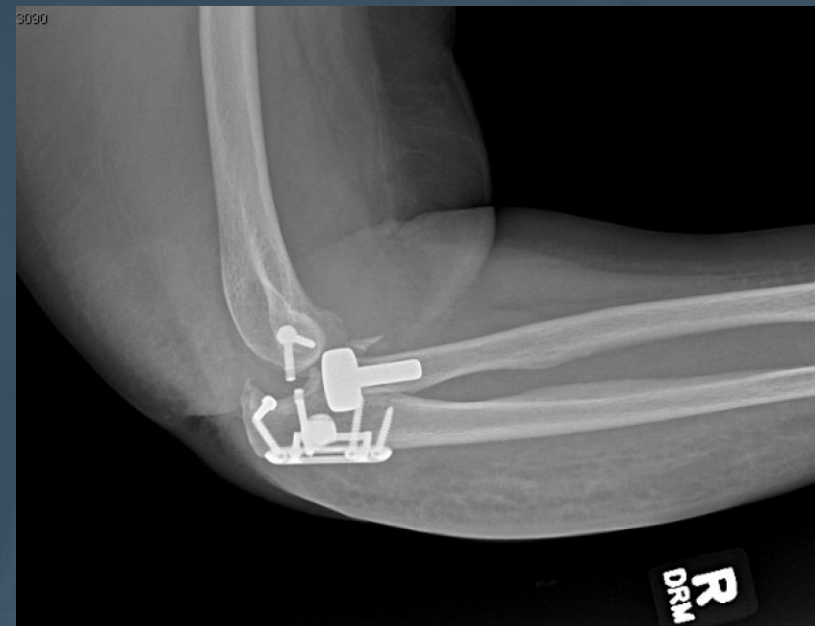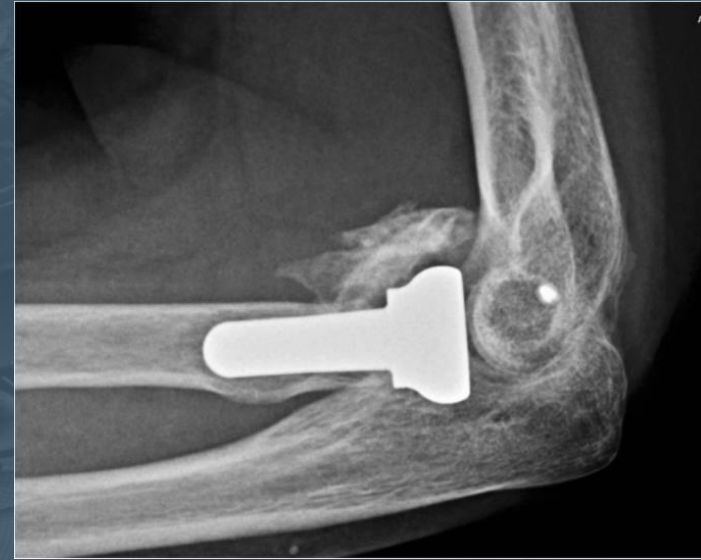# Complications

- Short-term

- Infection
- Nerve dysfunction
- Recurrent instability or re-dislocation
- CRPS
- HO

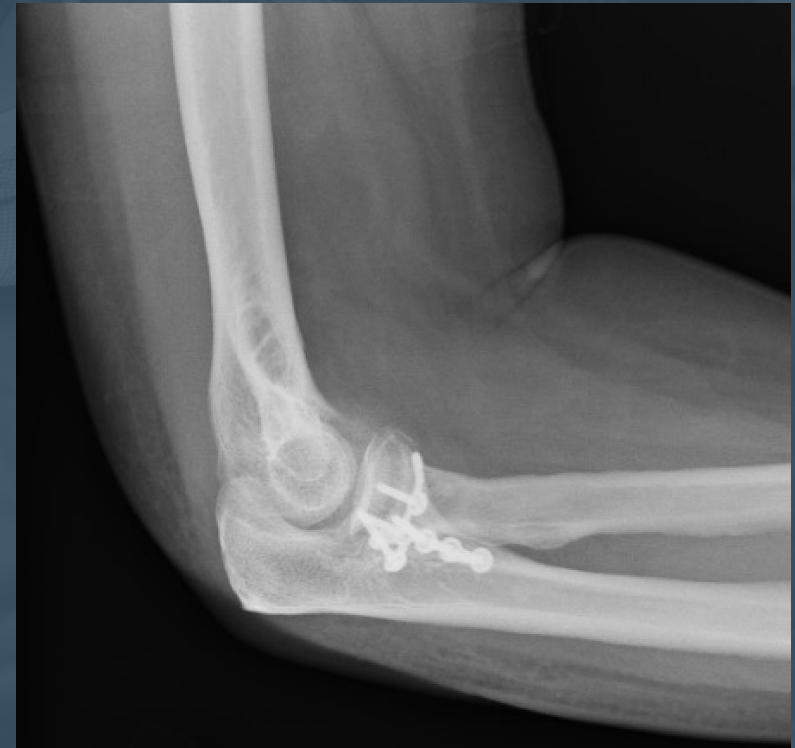- Long-term

- Post-traumatic arthritis
- Stiffness
- Recurrent instability



# Terrible Triad: Take Home Points

- **Recognize injury pattern**
  - PLRI vs PMRI
  - CT can be very helpful for preop plan
- **Treatment algorithm:**
  - Start Lateral
    - Rigid fixation or arthroplasty radial head
    - LCL repair
  - Coronoid fixation
    - Anteromedial facet critical for PMRI pattern
      - Medial buttress plate needed
  - (Anterior capsule repair)
  - (MCL)
  - Ex-fix (hinged or static) or internal joint stabilizer PRN
    - Have available!
- **Rehab:** Early, supine overhead motion protocol





**Thank You!**

**Jordan Grier, MD**

**Cell: 440-487-2422**

**Office: 704-323-3822**

**Email: [jordan.grier@orthocarolina.com](mailto:jordan.grier@orthocarolina.com)**

