

Orthopaedic Fracture Management

**Orthopaedic Fracture Management
MSK Galaxy Course**

**Chuck Dowell, MS, PA-C, ATC
Colorado Springs Orthopaedic Group**

Faculty Disclosures

Orthopaedic Educational Services, Inc.

Financial
Intellectual Property

American Academy of Physician Assistants

Financial
MSK Injection and Lower Extremity PE Workshop Director, Guide to the MSK Galaxy Course

JBJS- JOPA Journal of Orthopaedics for Physician Assistants- Associate Editor

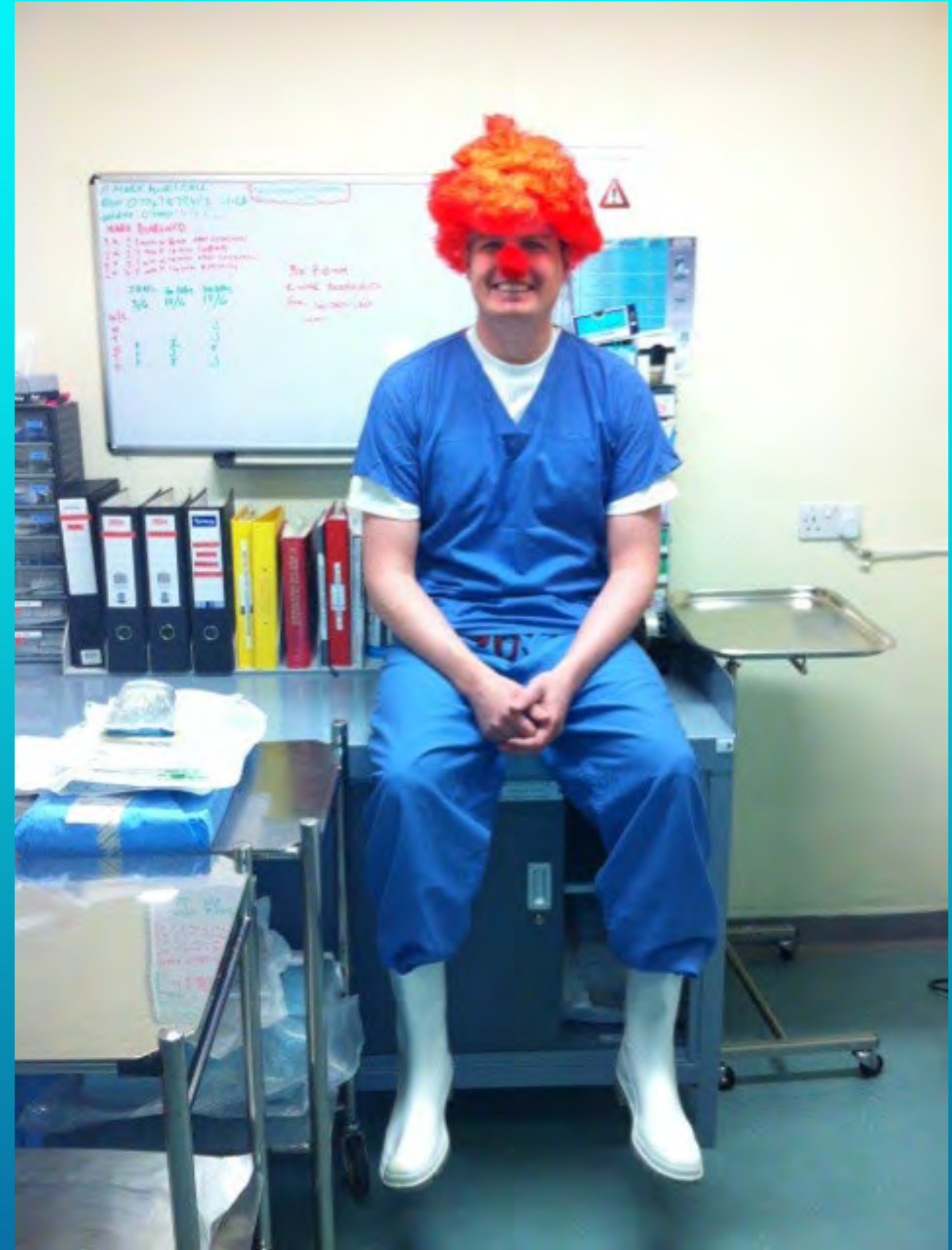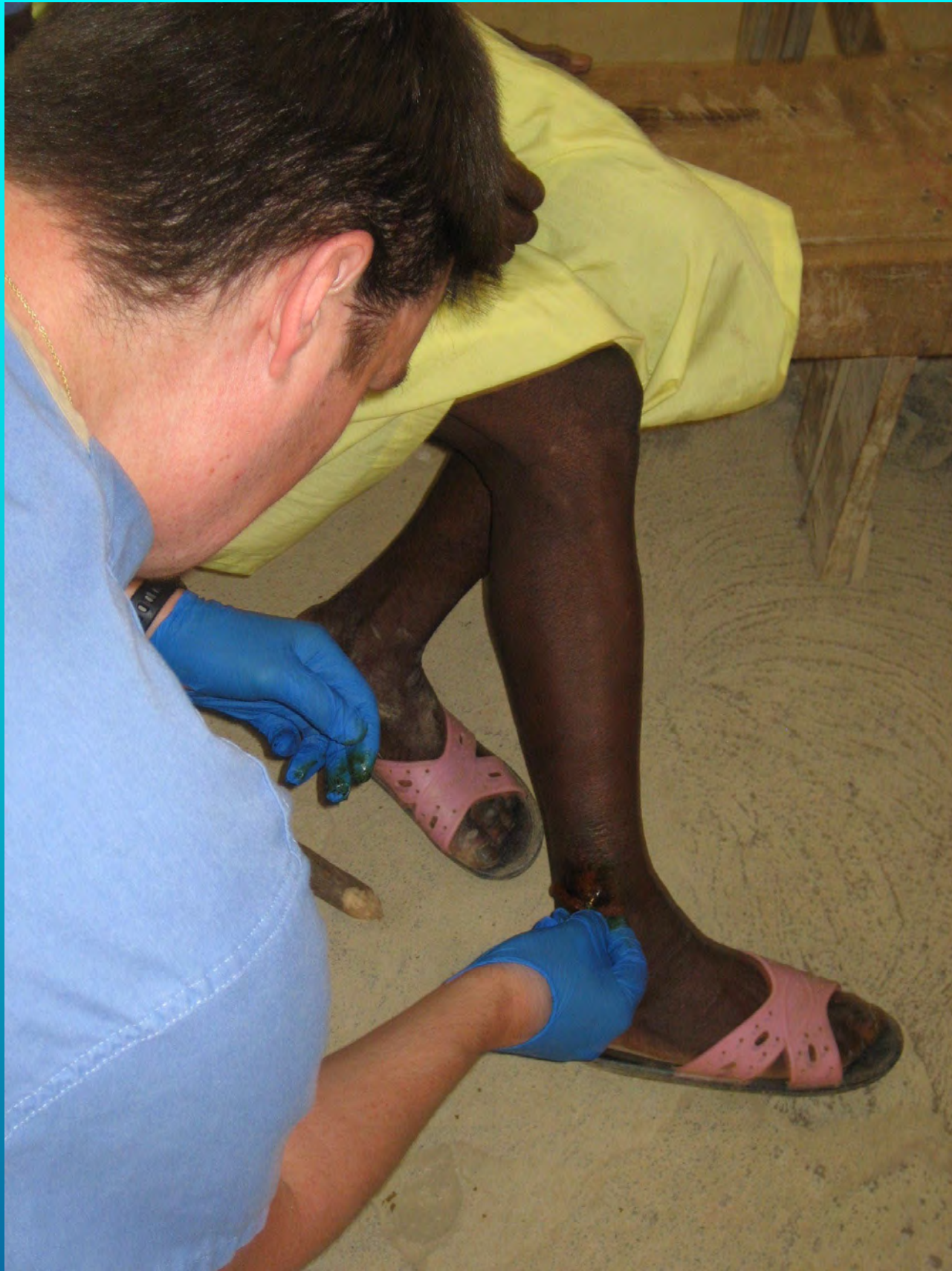American Academy of Surgical Physician Assistants – Editorial Review Board

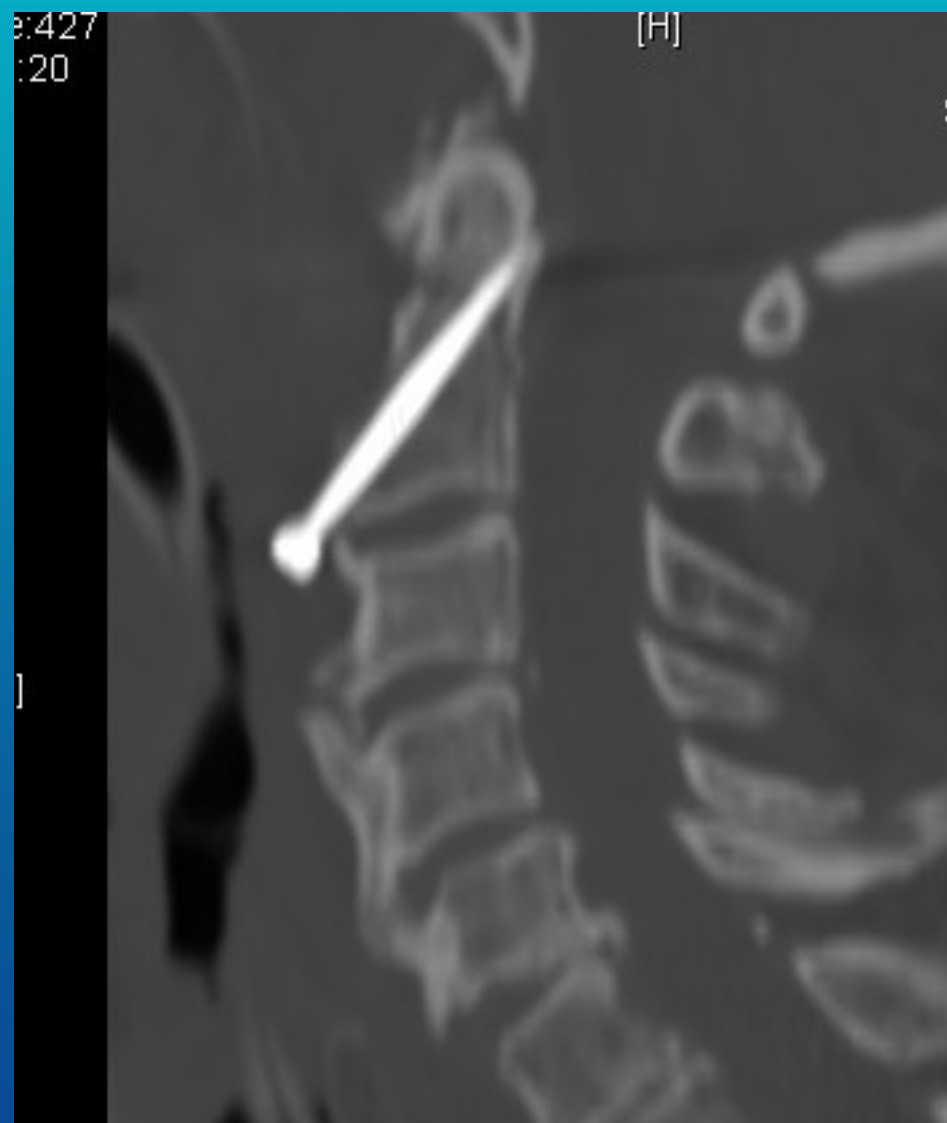
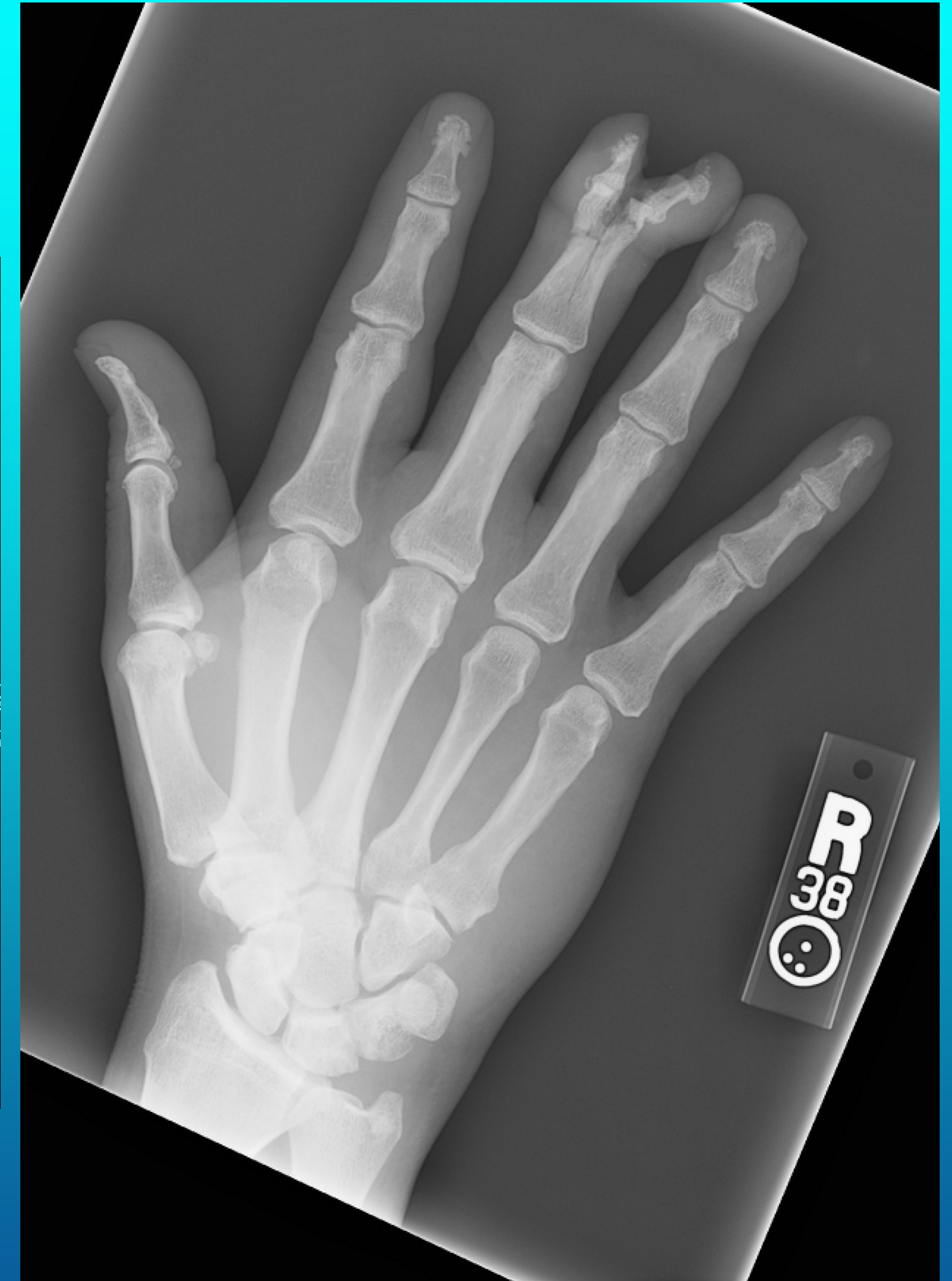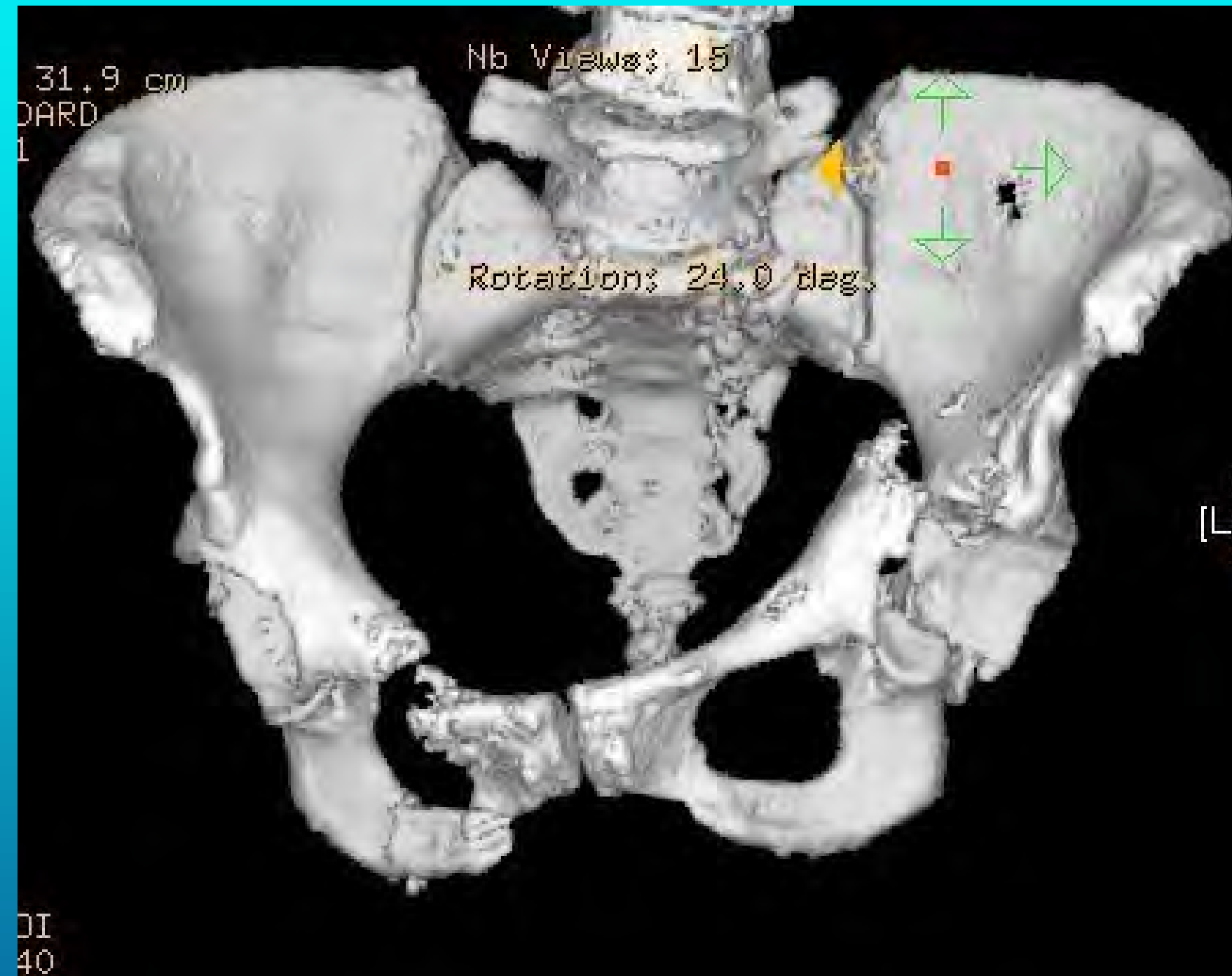
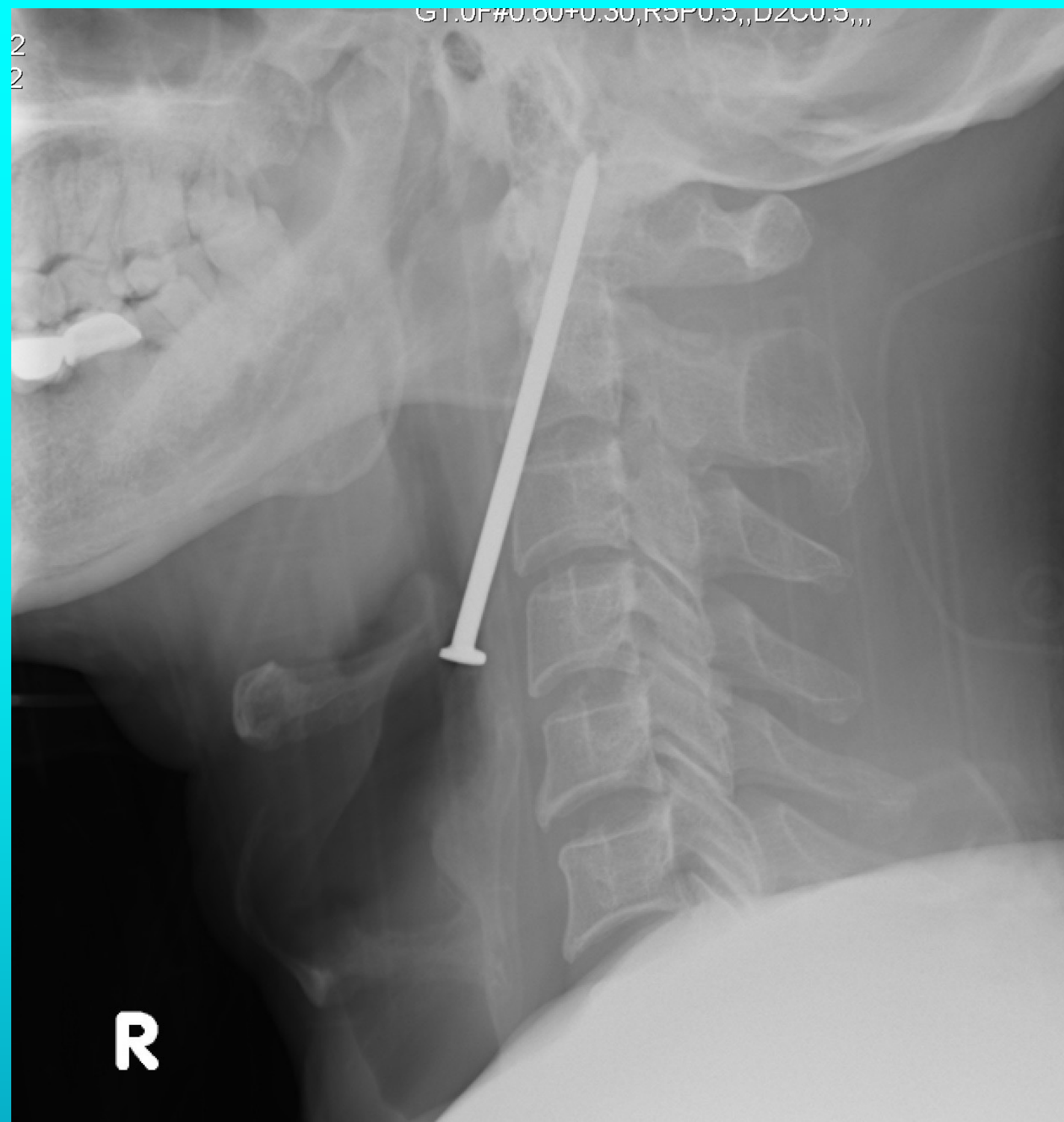
Special thanks to Tom Gocke, PA-C and OES for this presentation.

Learning Objectives

At the end of this lecture attendees will be able to :

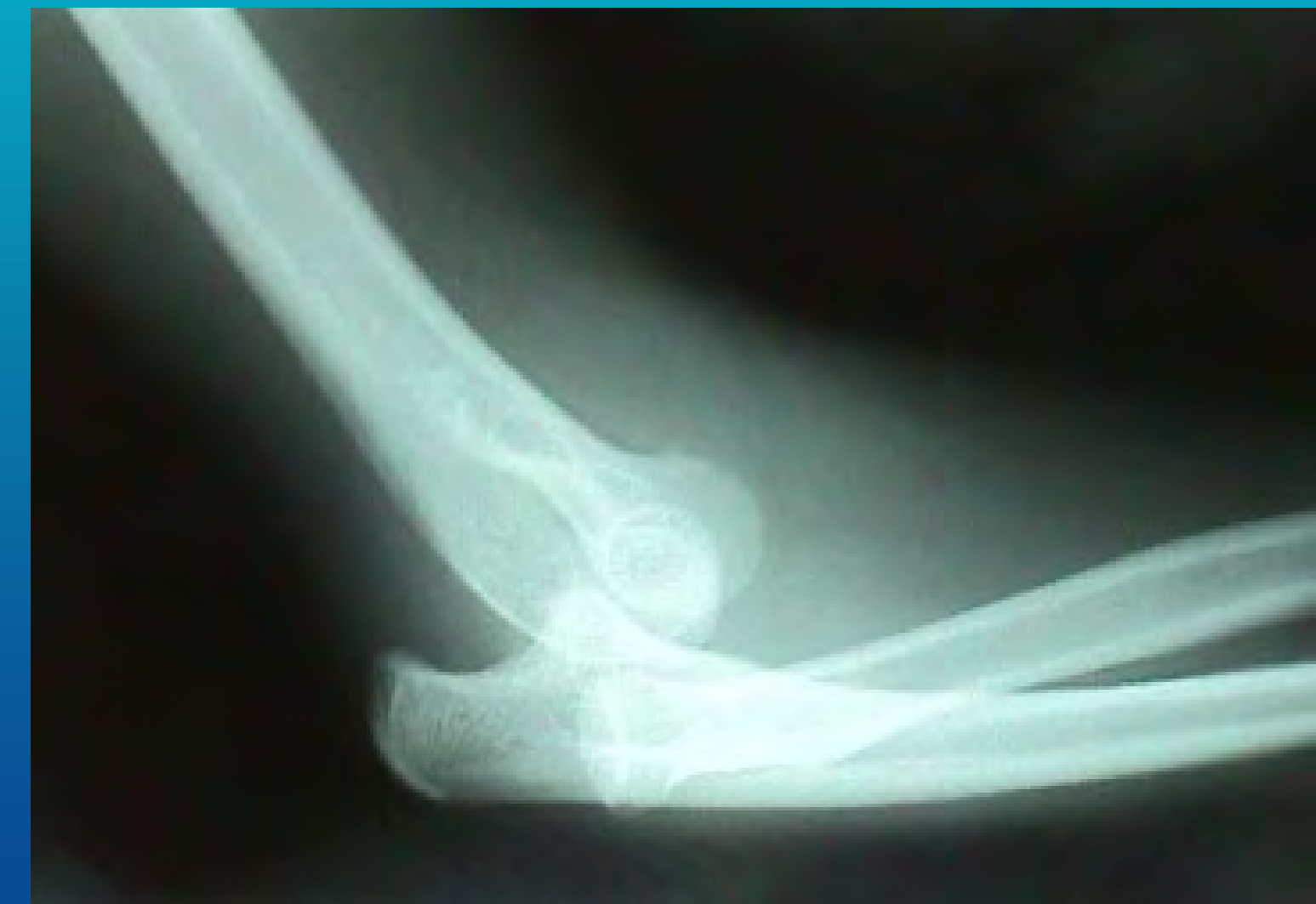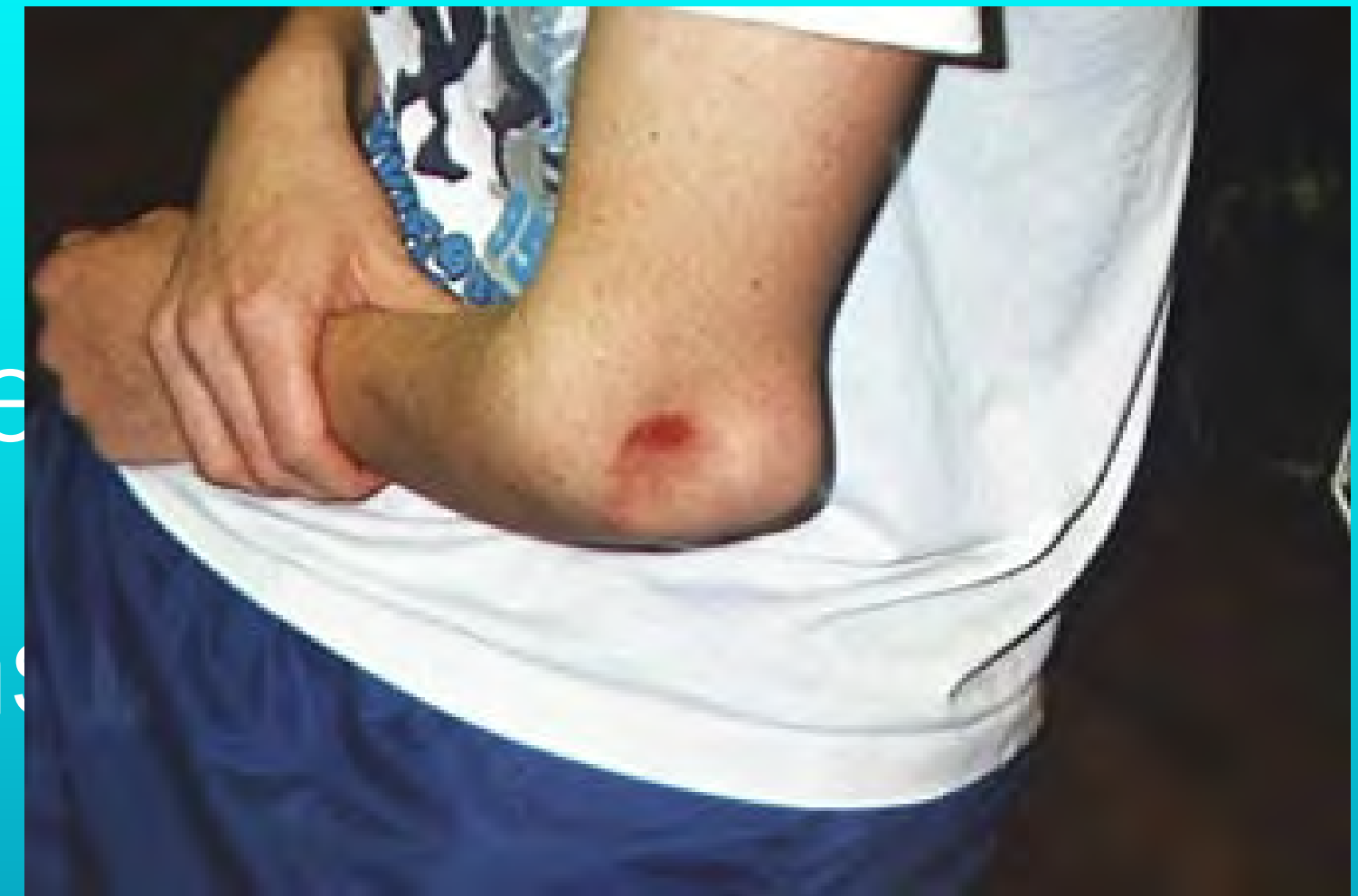- Describe fractures based on location, angulation, displacement & soft tissue injuries
- Recognize and describe factors associated with acute fractures
- Describe exam maneuvers essential for acute fractures
- Describe essential immobilization techniques for acute fractures
- Recognize and describe differences in fractures that require emergent treatment vs those that can be sent home and follow up in the office
- Recognize and treat Fractures of the Upper Extremity (UE)
- Recognize and Treat Fractures of the Lower Extremity (LE)



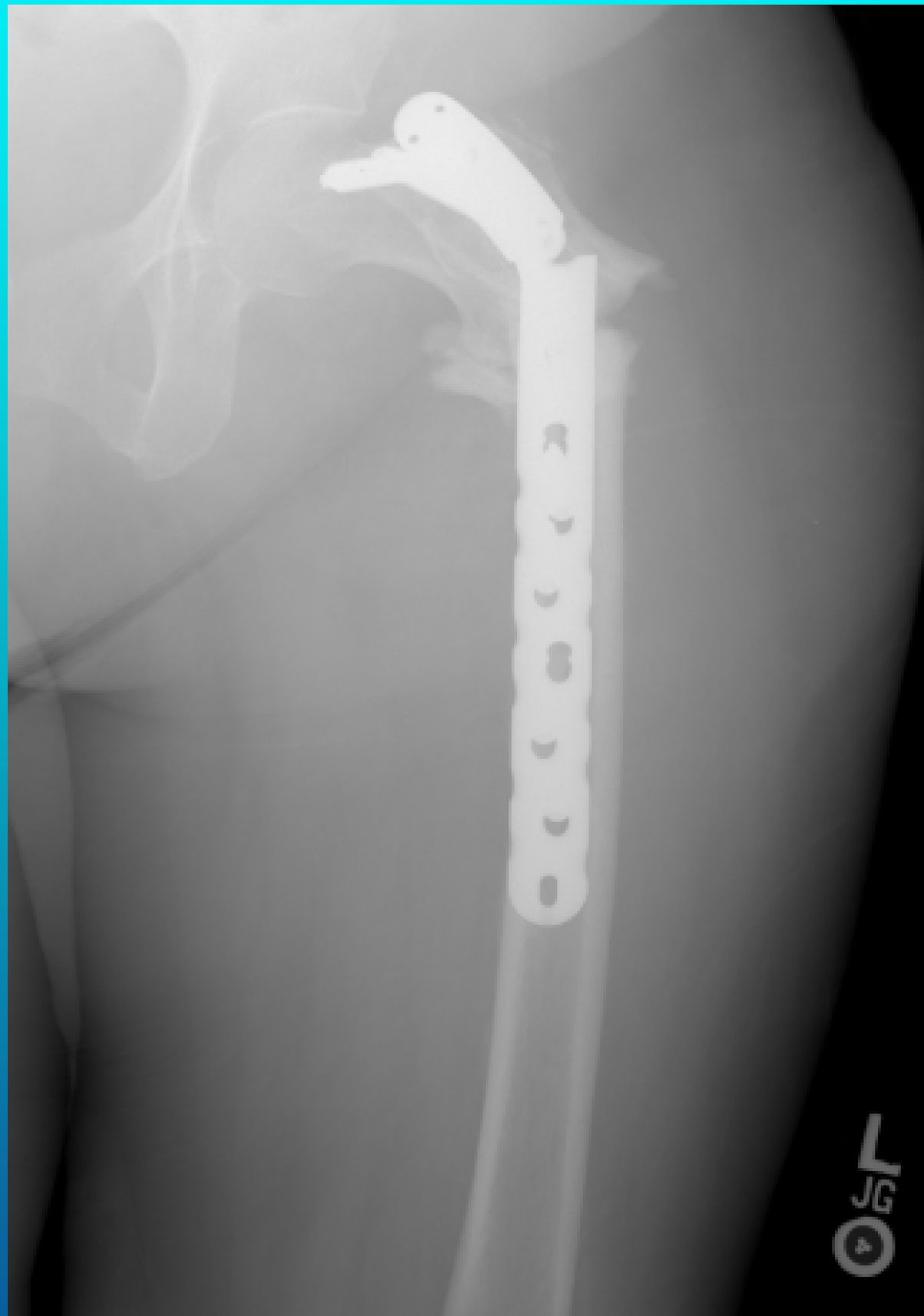

Goals of Fracture Treatment

- Restore the patient to optimal functional state
- Prevent fracture and soft-tissue complications
- Get the fracture to heal and in position which will produce optimal functional recovery
- Rehabilitate the patient as early as possible



Challenges in fracture management

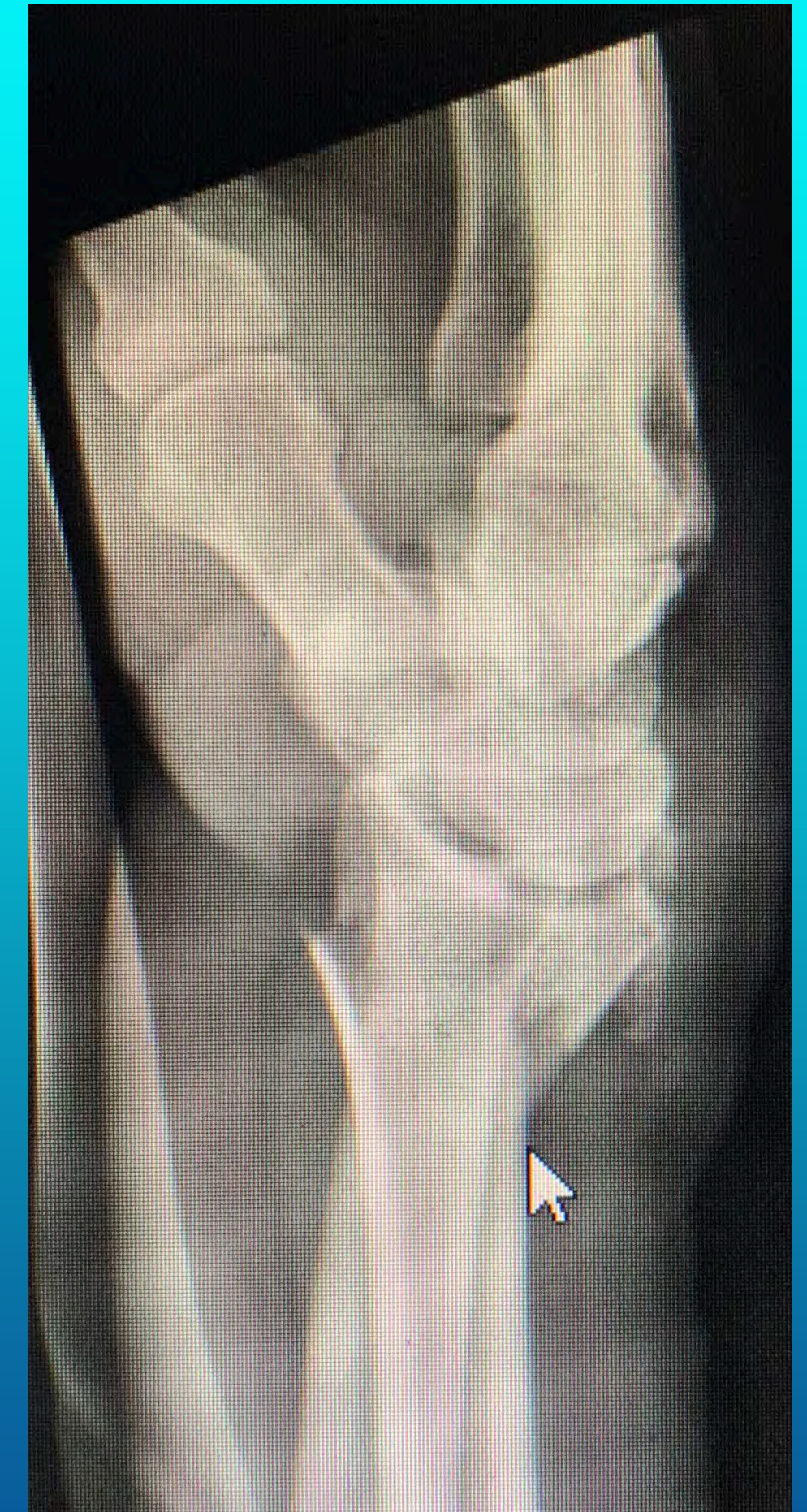
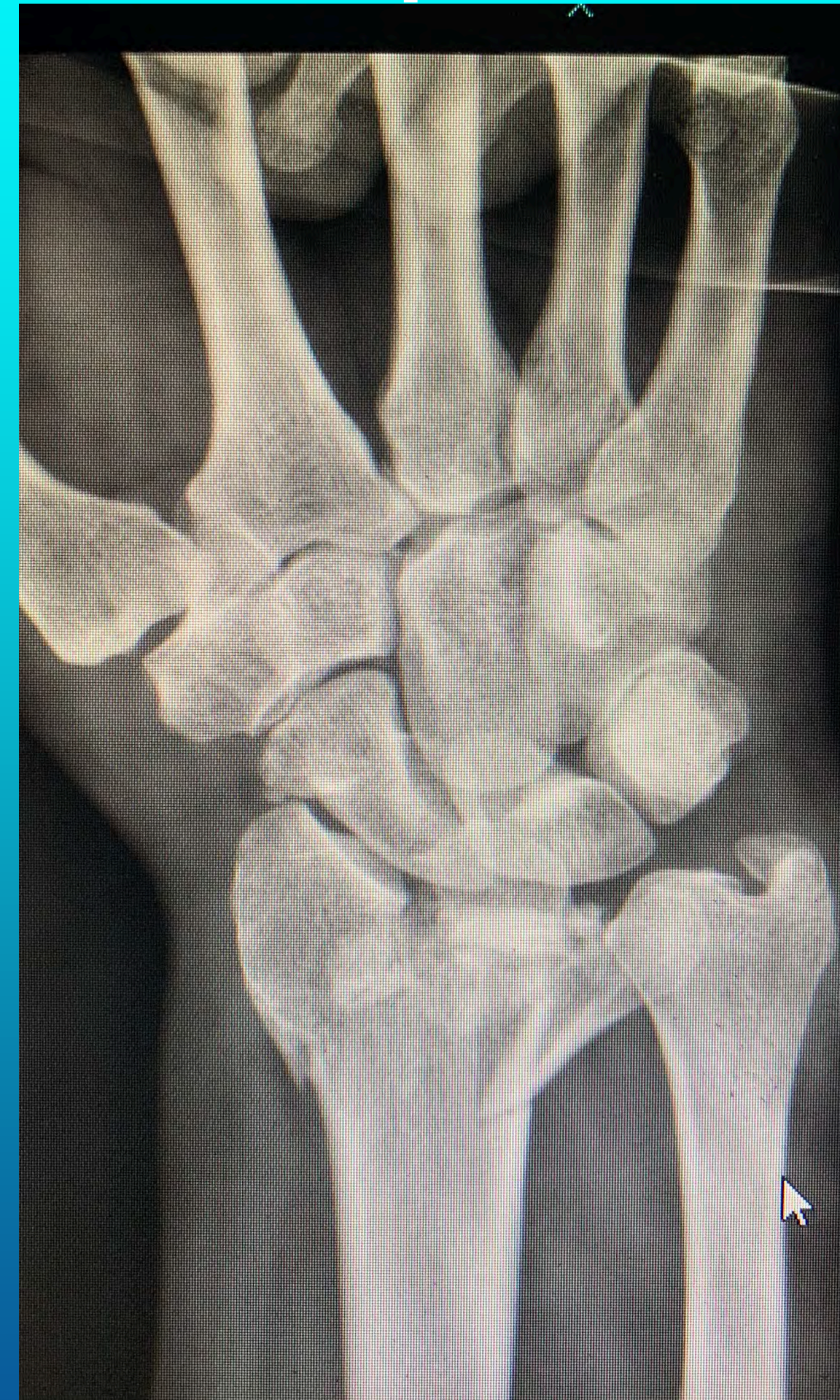
- Knowledge of anatomy
- Interpretation of x-ray
- Determining which patient needs referral for possible further treatment and which you can manage
- Timeframe for follow-up

Fracture Description

Fracture Description

- Fx location, anatomical site (bone and location on bone)
- Configuration Displacement
 - three planes of angulation
 - translation
 - shortening
- Articular involvement/epiphyseal injuries
 - fracture involving joint
 - dislocation
 - ligamentous avulsion
- Open v. Closed:
 - Gustilio-Anderson classification
- Neurovascular status



Photos courtesy TGocke PA-C

Fracture Pain

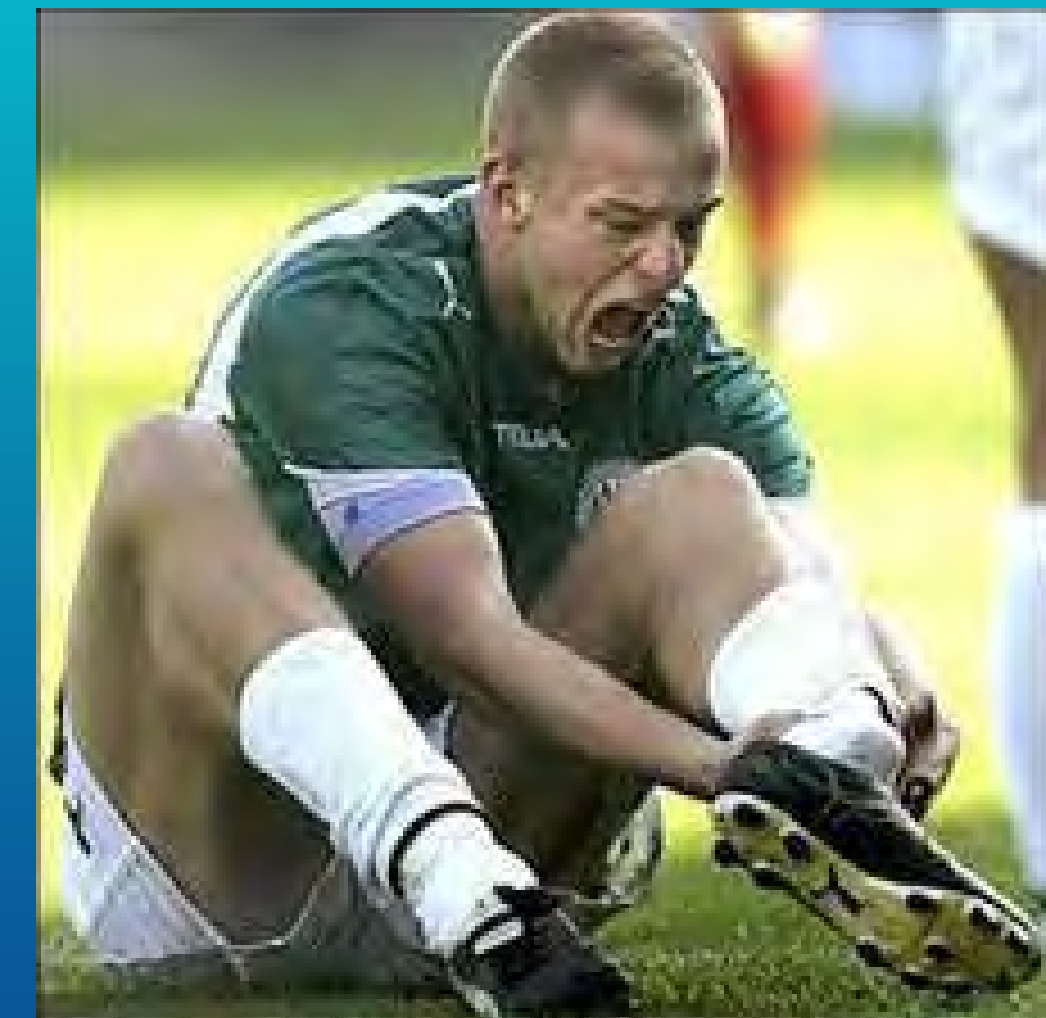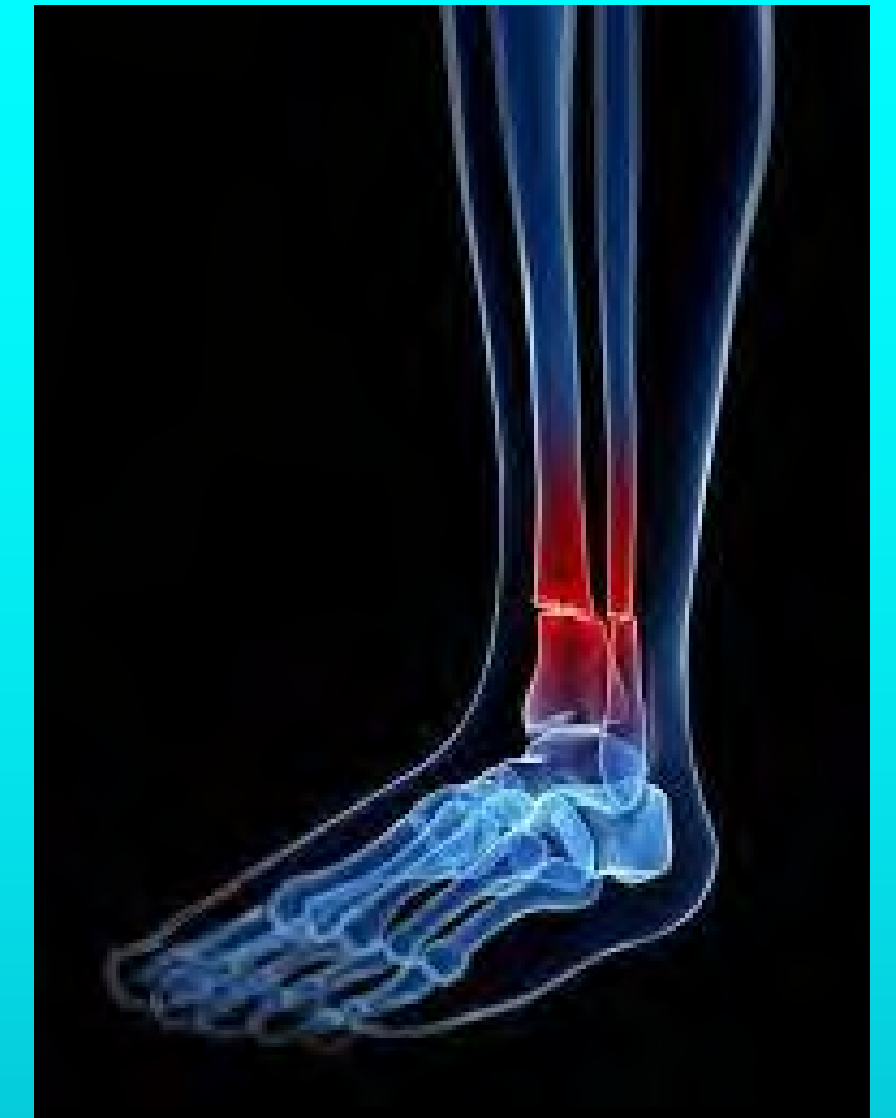Fracture Pain

There currently is a lack of effective treatment options for fracture pain that reliably relieve pain without potentially interfering with bone healing.

Current treatment options for management of fracture pain are insufficient.

Current recommendations conclude that NSAID use is warranted in fracture healing, as benefits outweigh the risk.

- The use of NSAIDs should be done at the lowest dose and may help to avoid use of narcotics
- There is a ceiling effect with Ibuprofen at 600mg, there is no difference between 600mg and 800mg regarding increased analgesic or anti-inflammatory effect.
- There is also good literature showing 600mg of Ibuprofen with 1000mg produces better analgesic effect at 2 hours than narcotic medication.



Mechanism of Injury



Mechanism of Injury

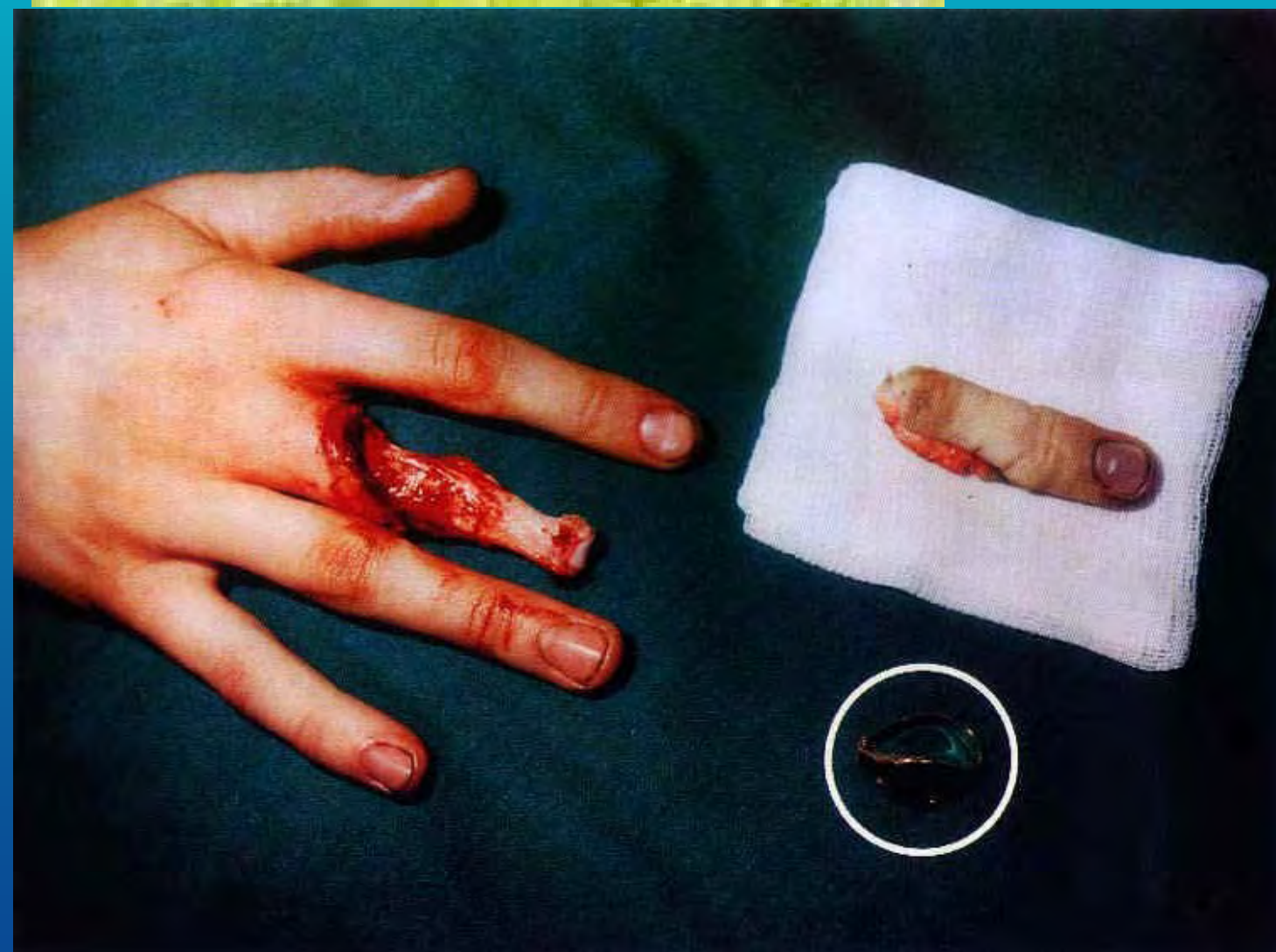Low energy vs High energy

- Stress fracture, fragility fracture, etc

Trauma starts with the transfer of energy to the body from an outside force. You must spend time to have the patient describe the specific MOI

- This should match up with the patient symptoms and area of pain

- If low energy or no injury acute fracture is unlikely



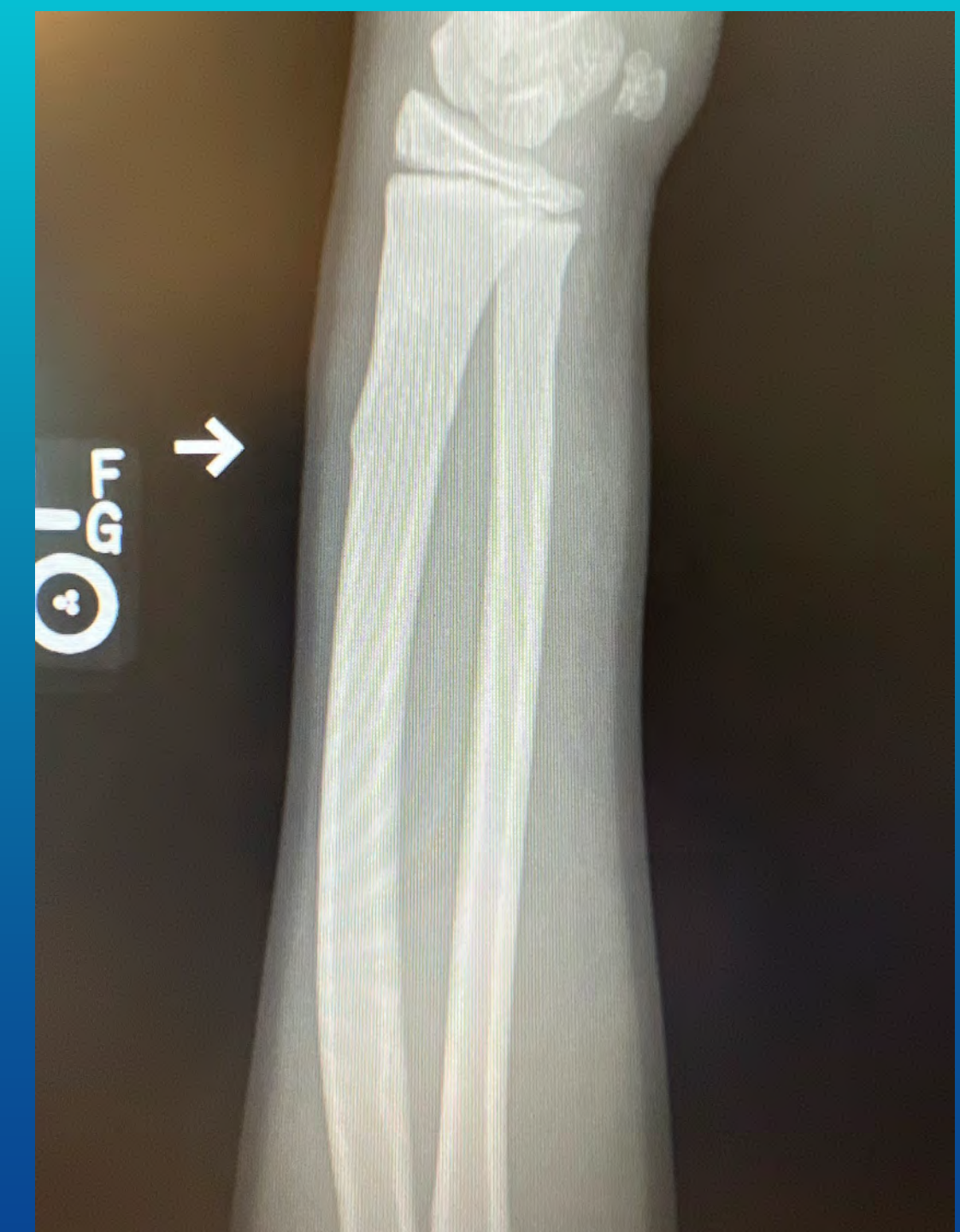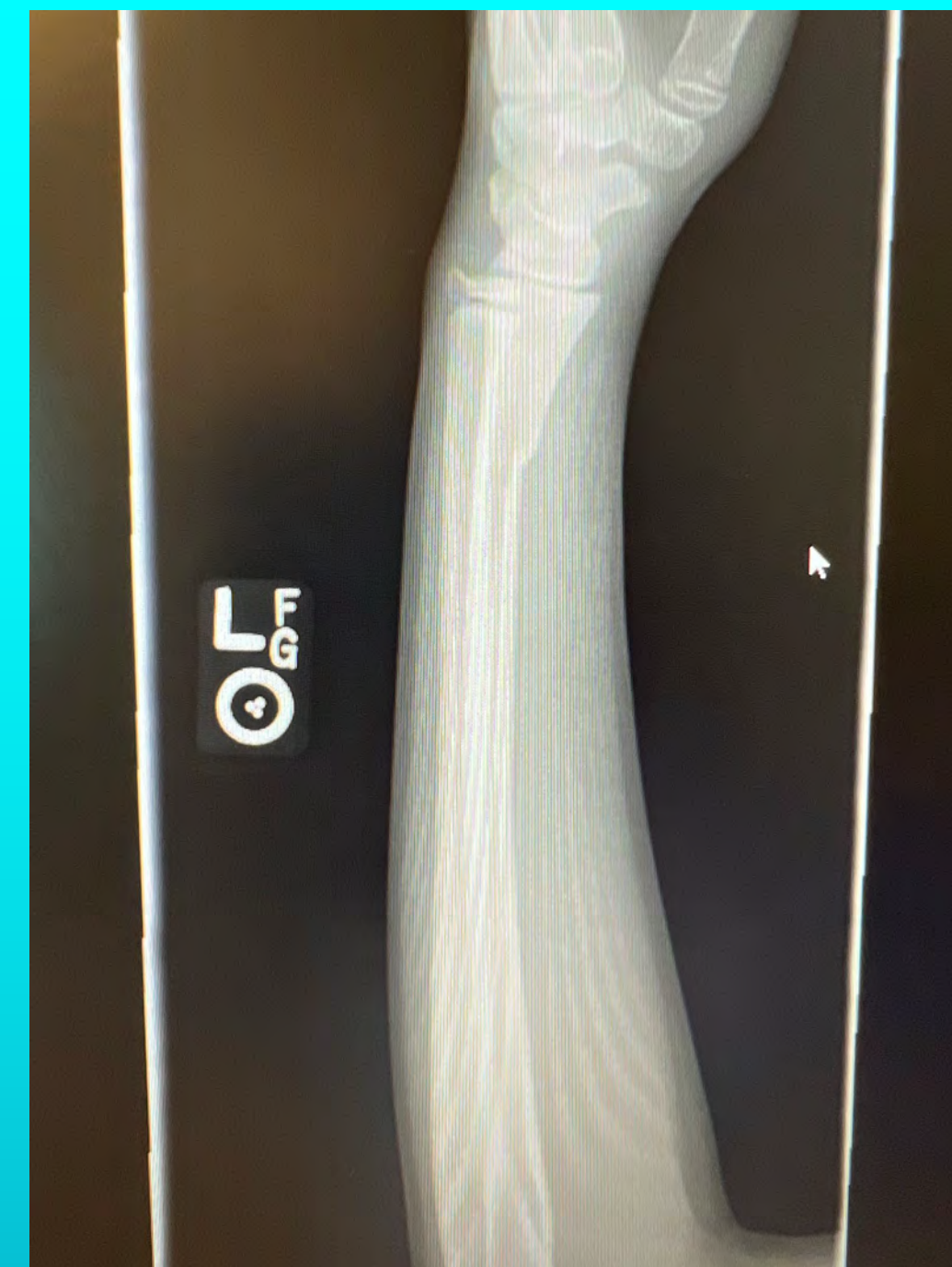Palpation

Palpation

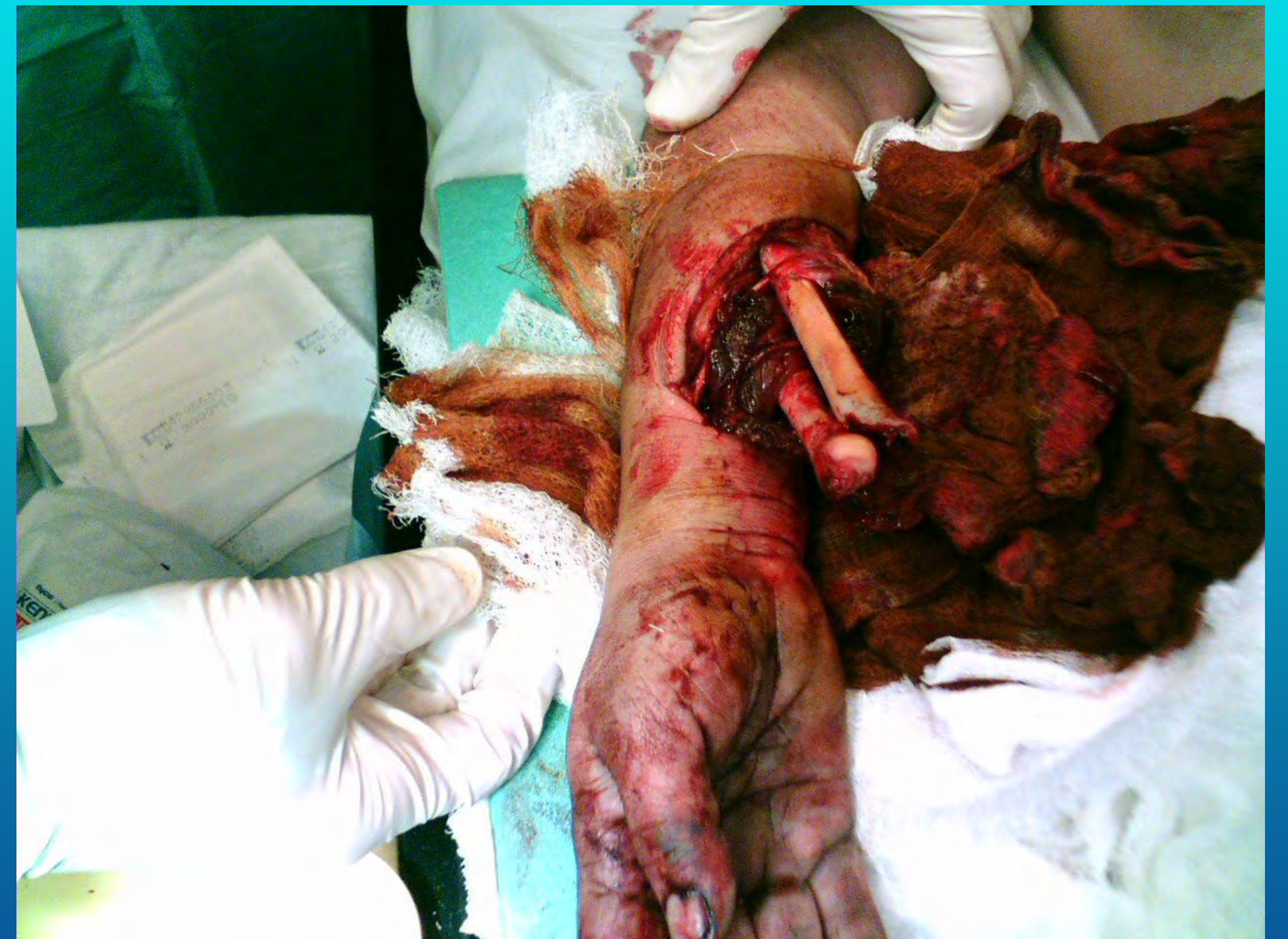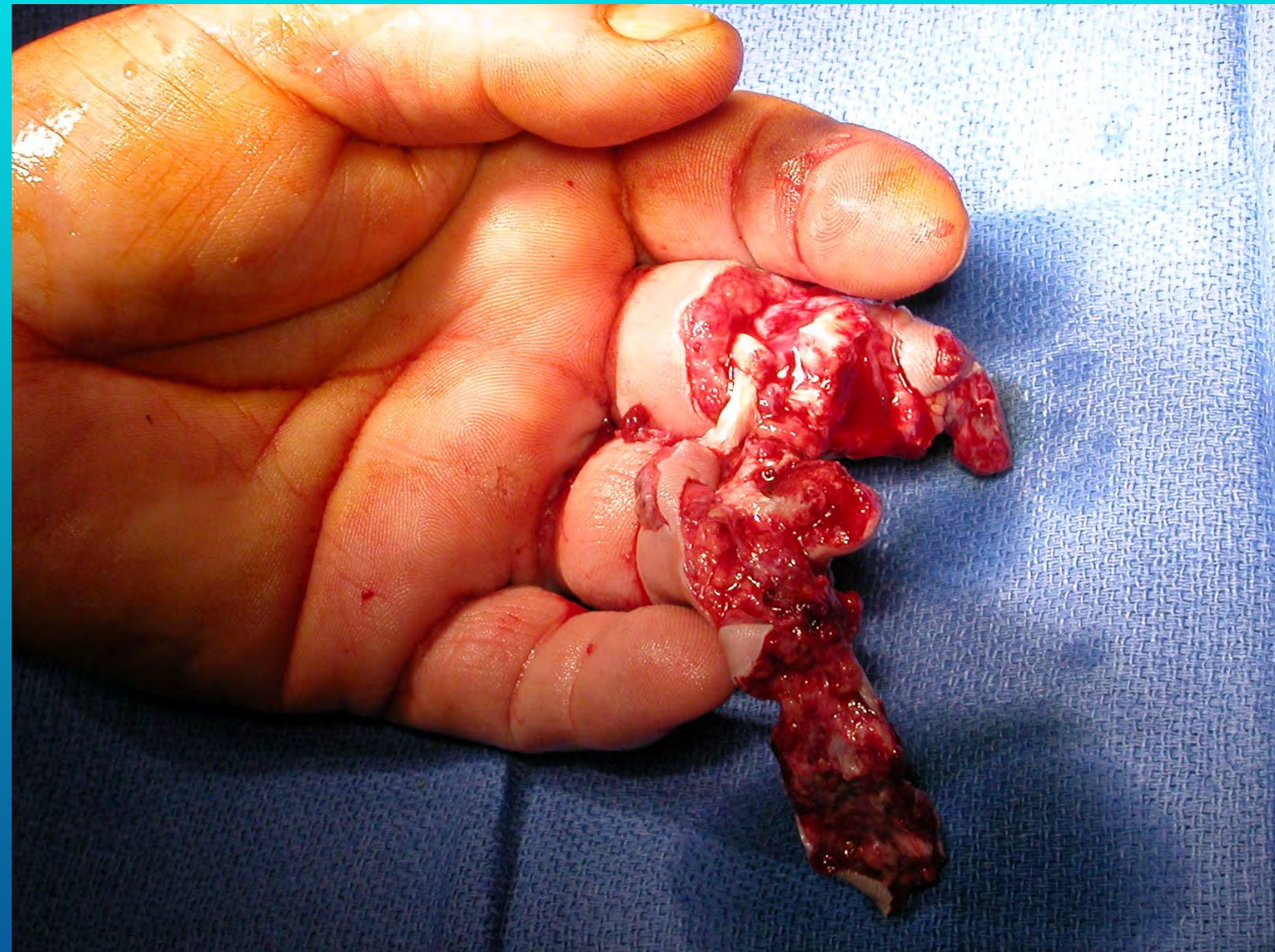Palpation is the process of using one's hands or fingers to physically examine part of the body by feel.

Fractures do not typically have referred pain, there is commonly palpable tenderness over the area of the fracture.

- Always palpate joint above and joint below to not miss anything.
- Start with palpation away from the area of pain, then palpate area of pain last
- Re-examine X-rays after palpation to look for subtle fracture findings
- If patient has change on x-ray with no palpable tenderness over this area, unlikely this is acute fracture



Soft Tissue Injury



Soft Tissue Injury

Skin

- Open fractures, degloving injuries and ischemic necrosis

Muscles

- Crush and compartment syndrome

Blood Vessels

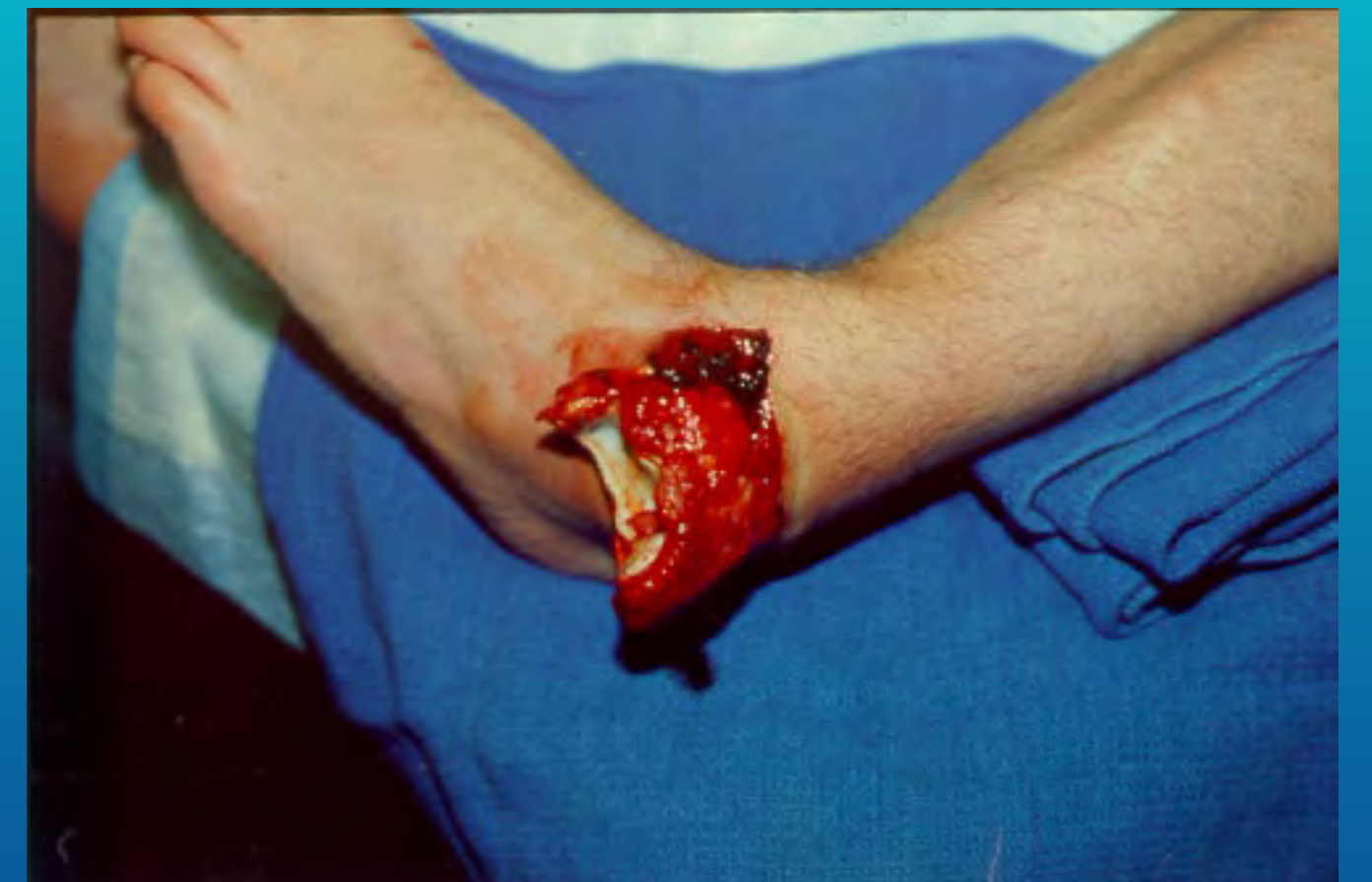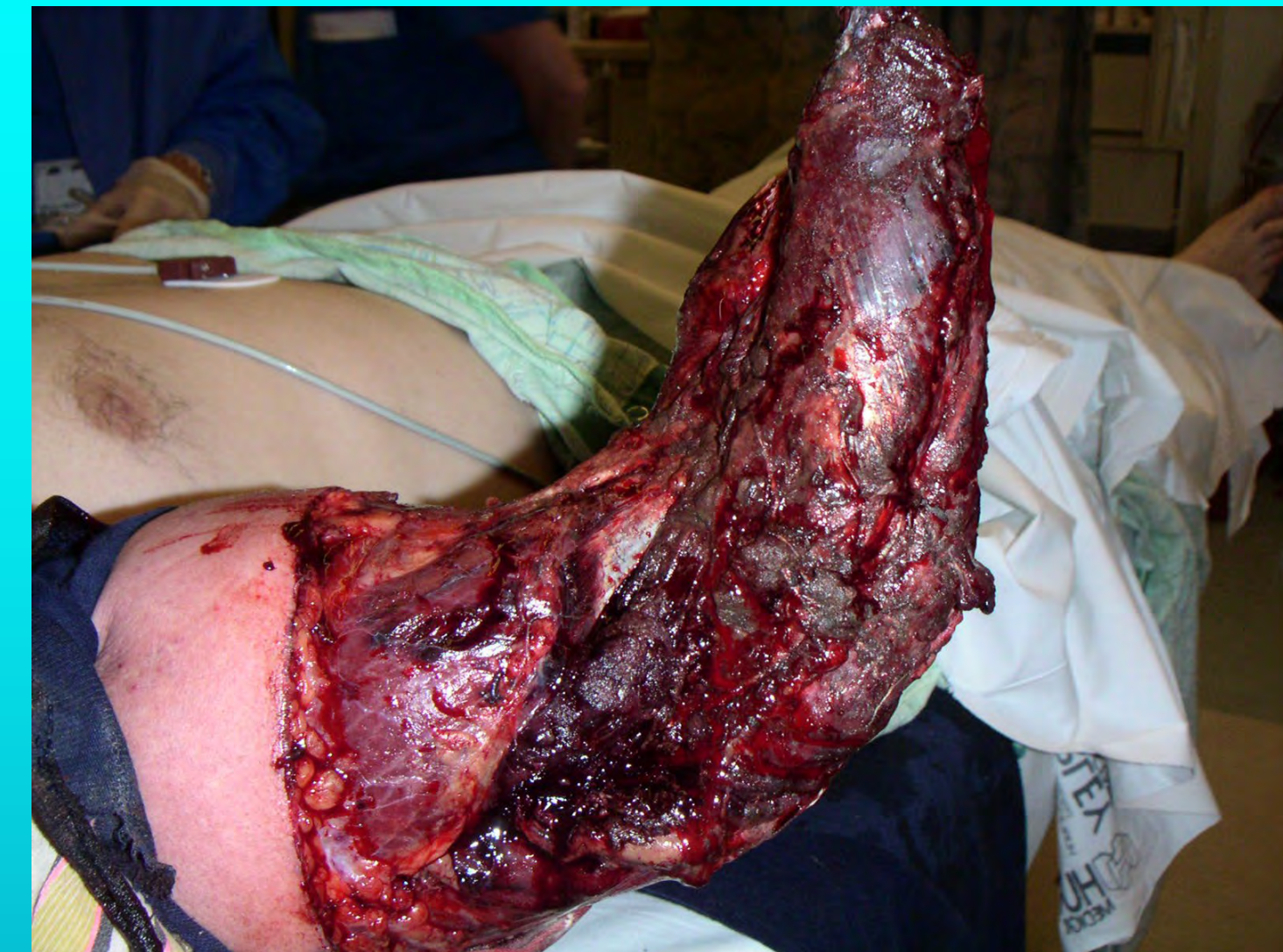- Vasospasm and arterial laceration

Nerves

- Neurapraxias, axonotmesis, neurotmesis

Ligaments

- Joint instability and dislocation

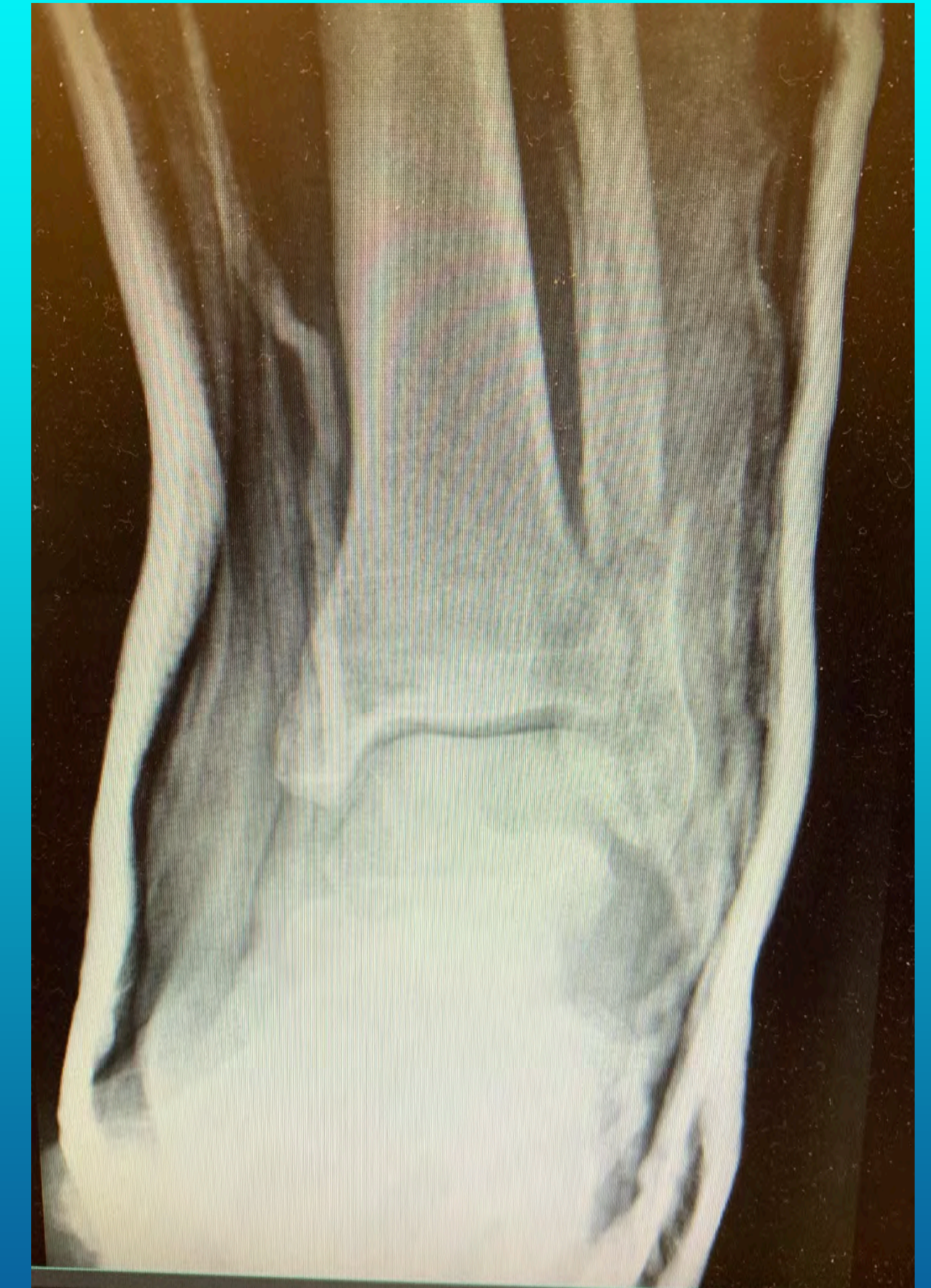
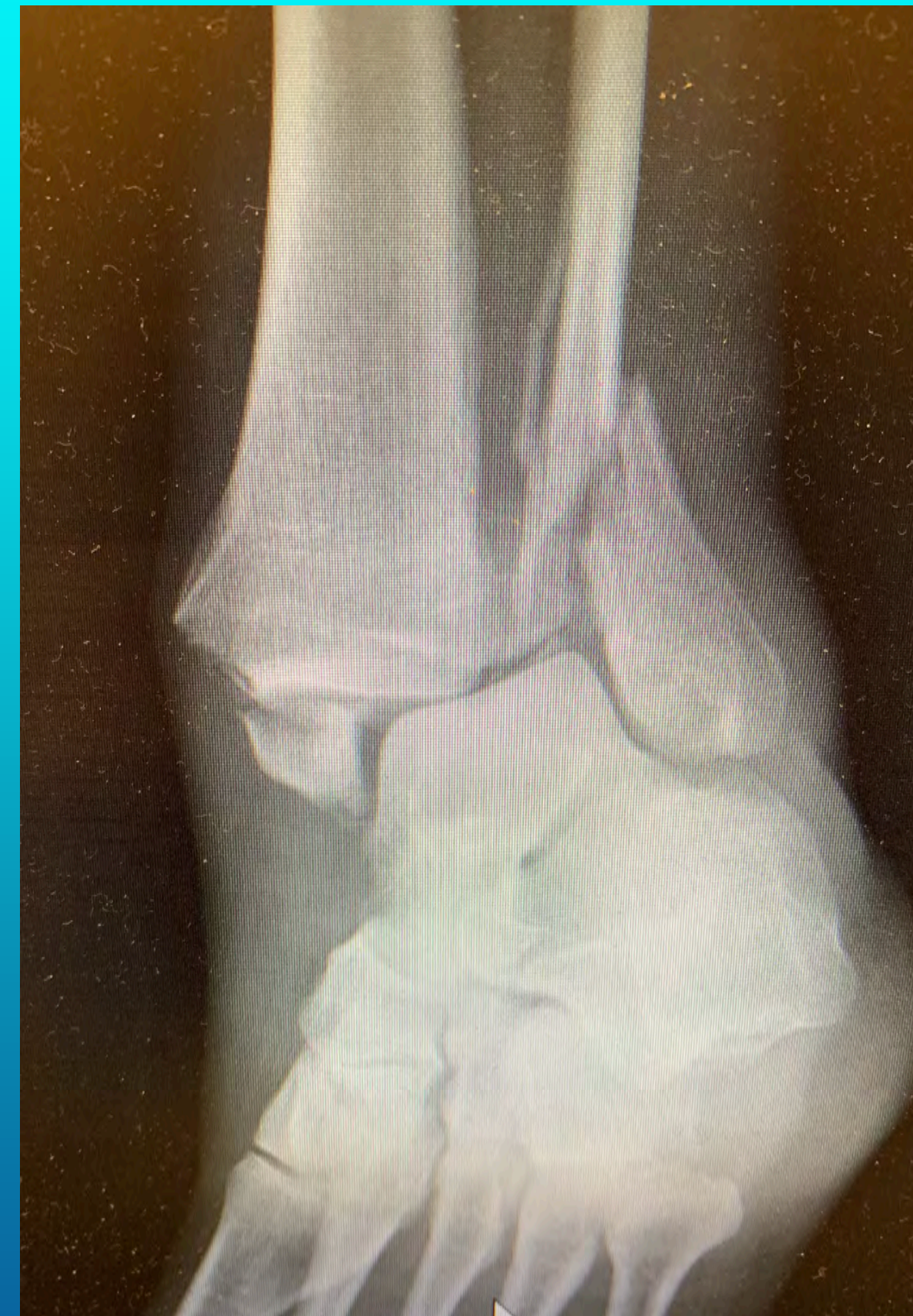
IMMOBILIZATION

IMMOBILIZATION

Importance of Immobilization

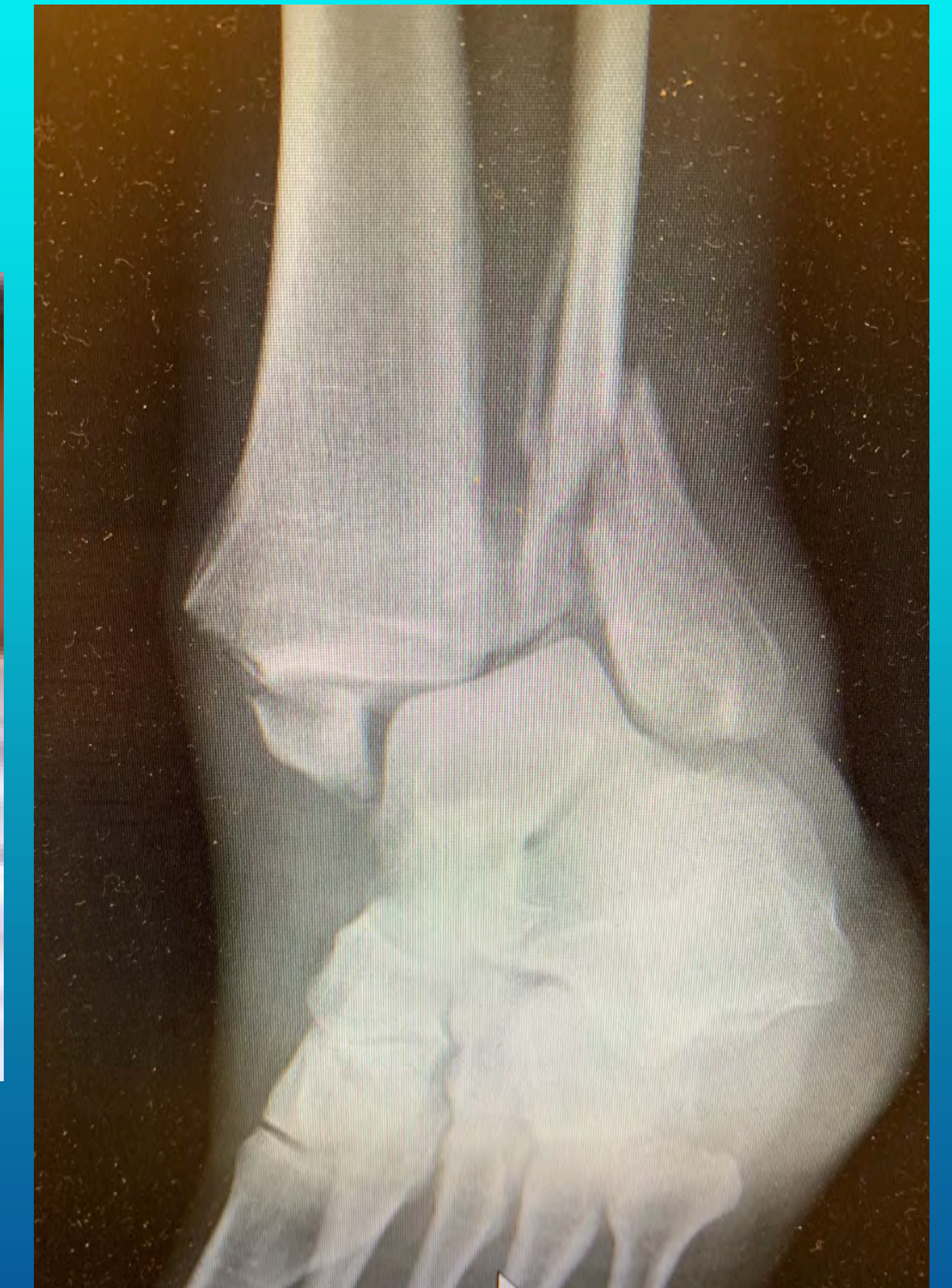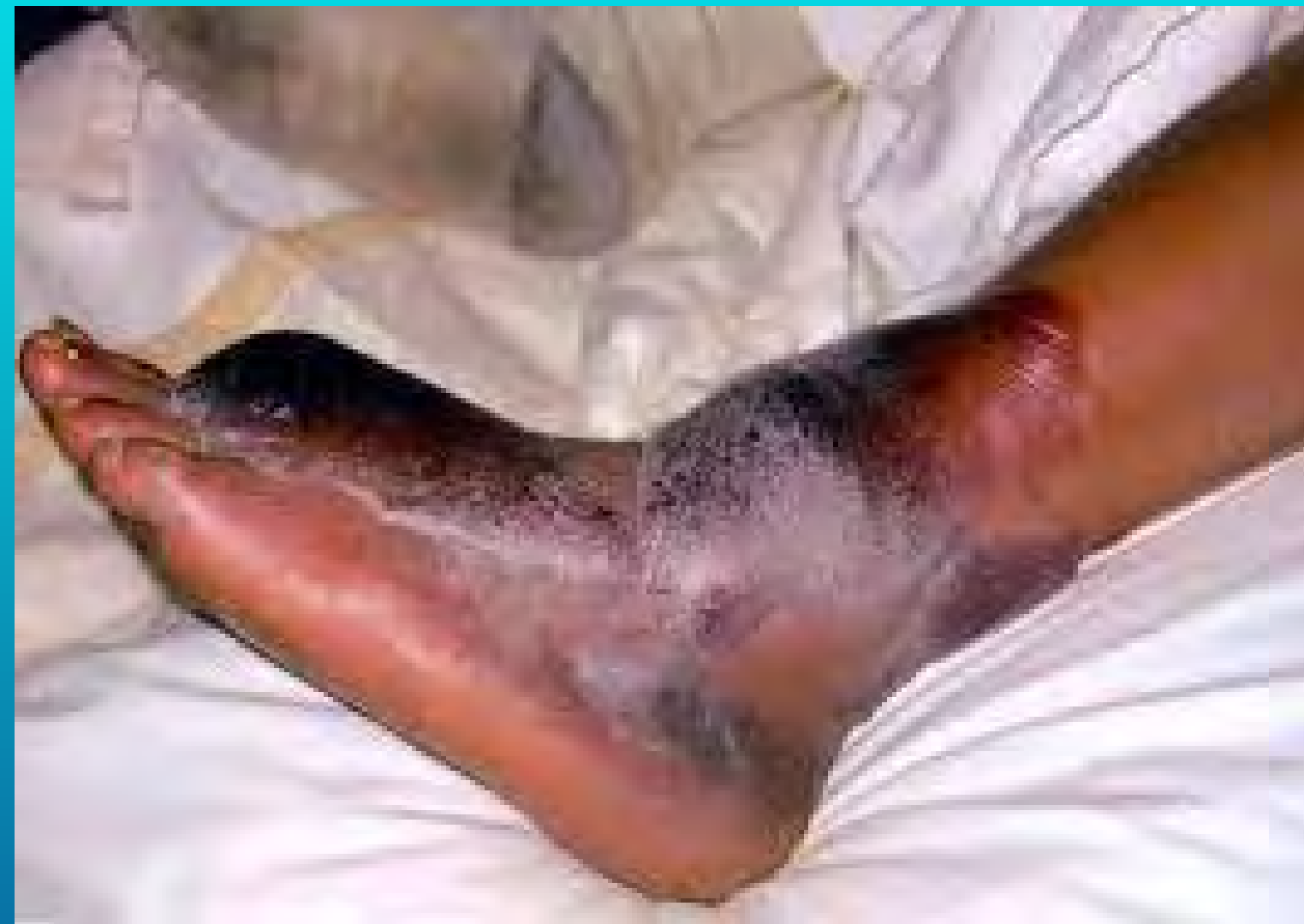- **Reduce Blood Loss**
 - Femur Fx up to 1500 ml blood loss
 - Tibial Fx up to 1000ml blood loss
- **Pain reduction**
- **Reduce damage to soft tissues**
- **Reduce or minimize compartment syndrome**
- **Reduce spread if infection**
- **Reduce Fx to minimize tissue injury**



IMMOBILIZATION

Fracture Blisters

- Occur 2nd to higher energy fx
- Skin adheres to bone and little subQ fat
- **Resembles 2^o burn (clear v. bloody)**
- Develop 6-48 hrs
- **Staph/Strep colonization**
- Impacts treatment options
- **No consensus on Treatment**
 - Dry dressing-Xeroform-Silvadene
- **Delays Surgery average 7 days**
- Infection complication



Healing

Healing

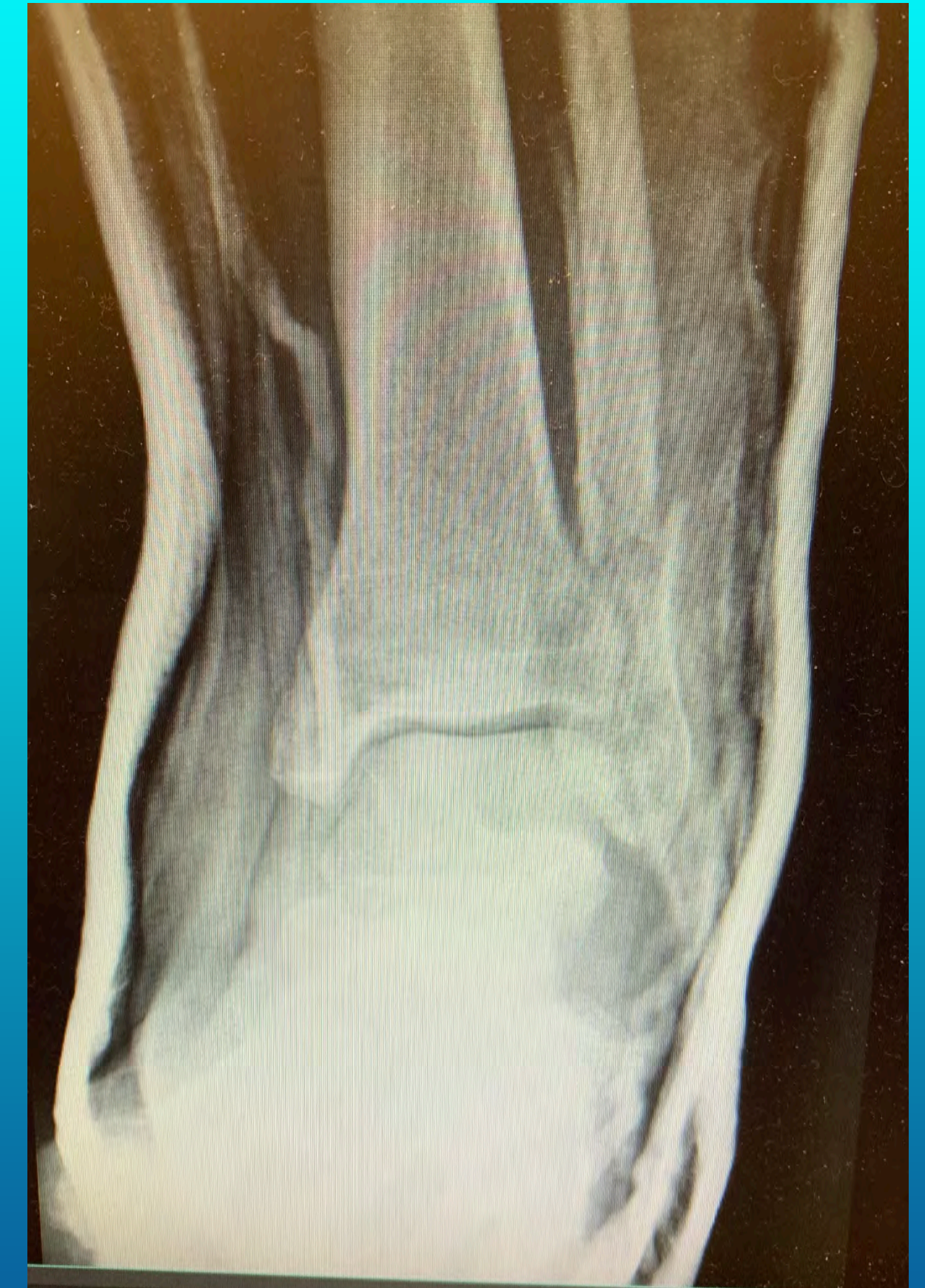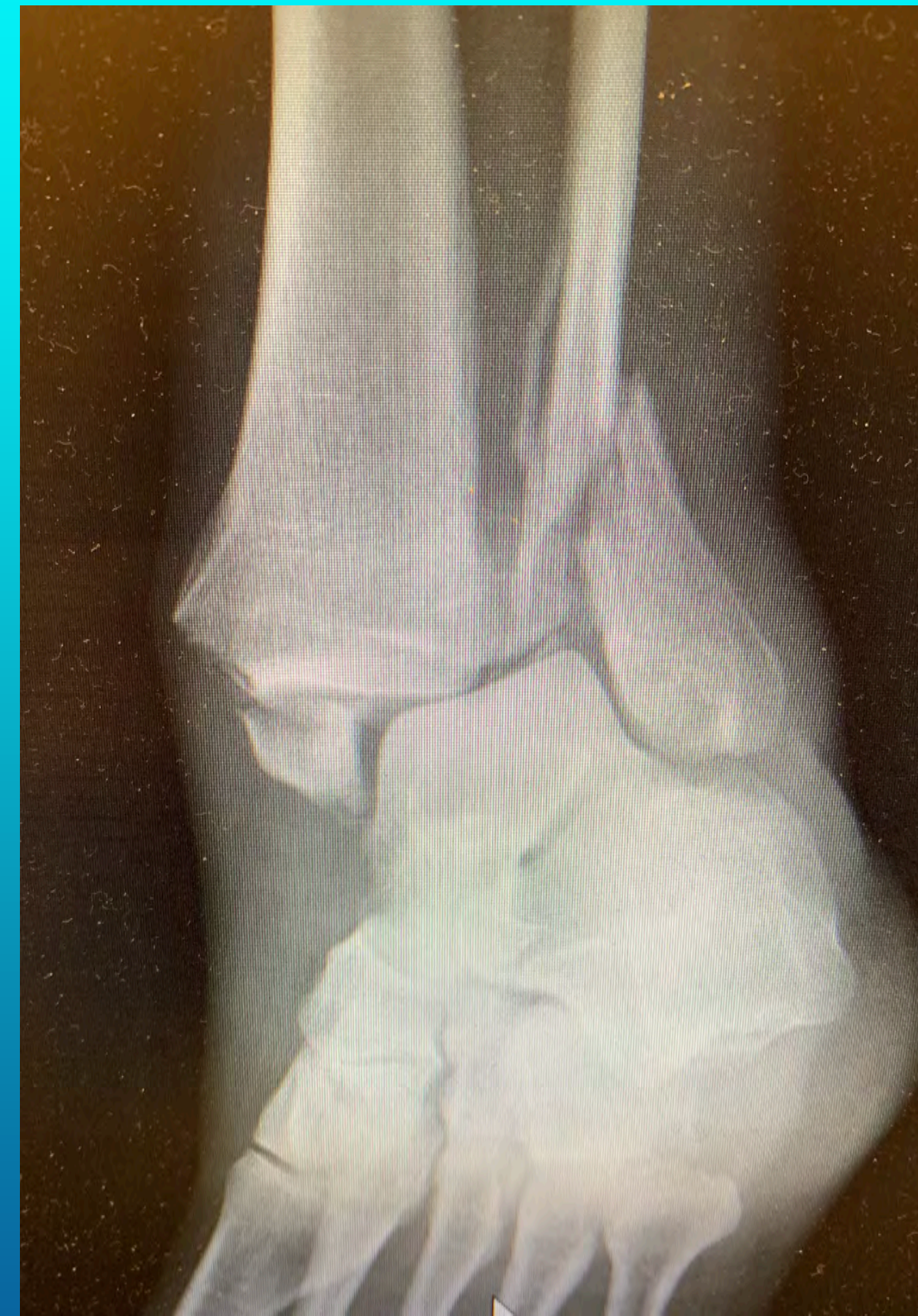When is the Fracture healed?

	Upper Limb	Lower Limb
Adult	6-8 weeks	12-16 weeks
Child	3-4 weeks	6-8 weeks

Radiologically

- Bridging callus formation
- Remodeling

Biomechanically stable



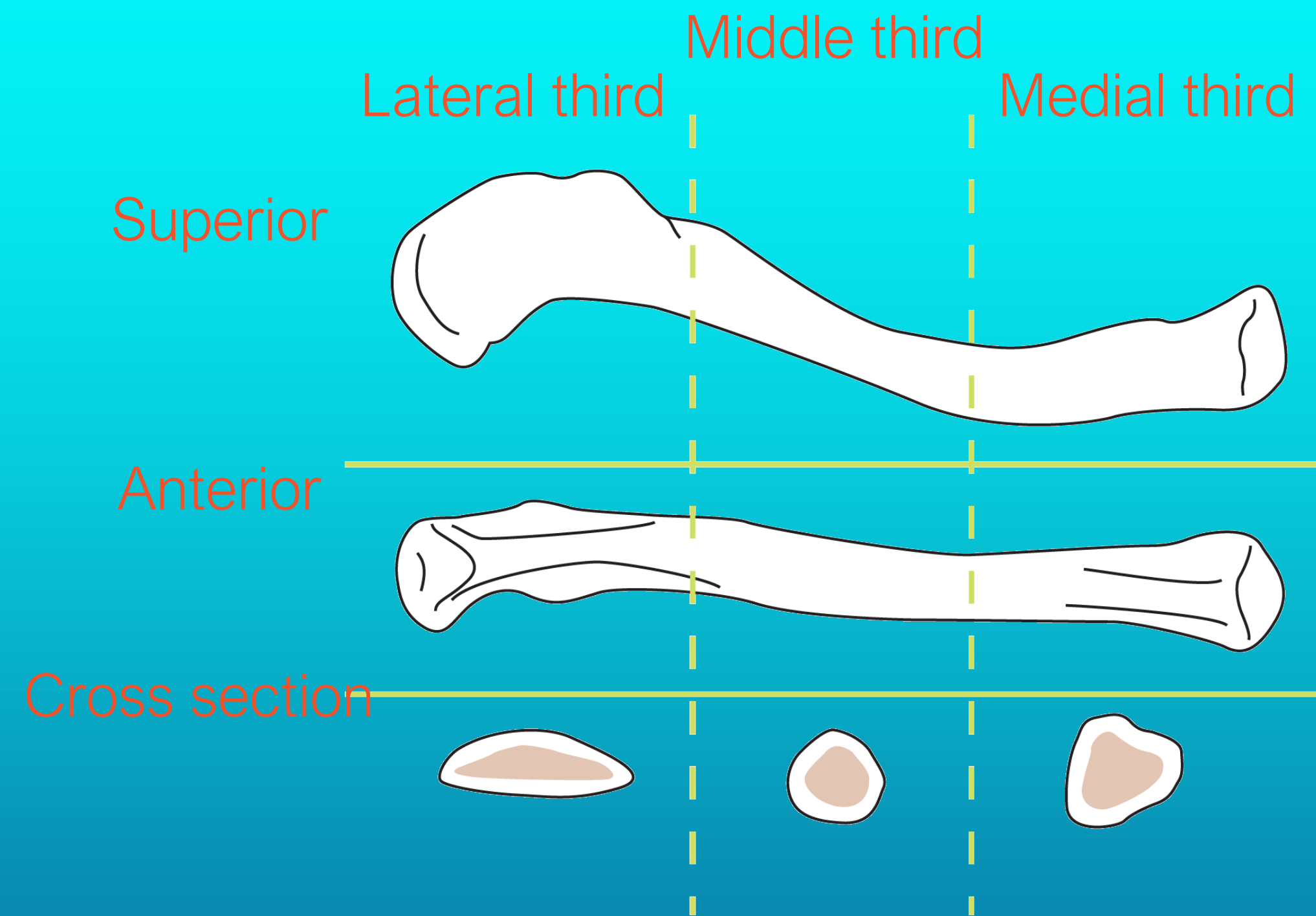
Upper Extremity Fractures

Clavicle Fx

Clavicle Fracture

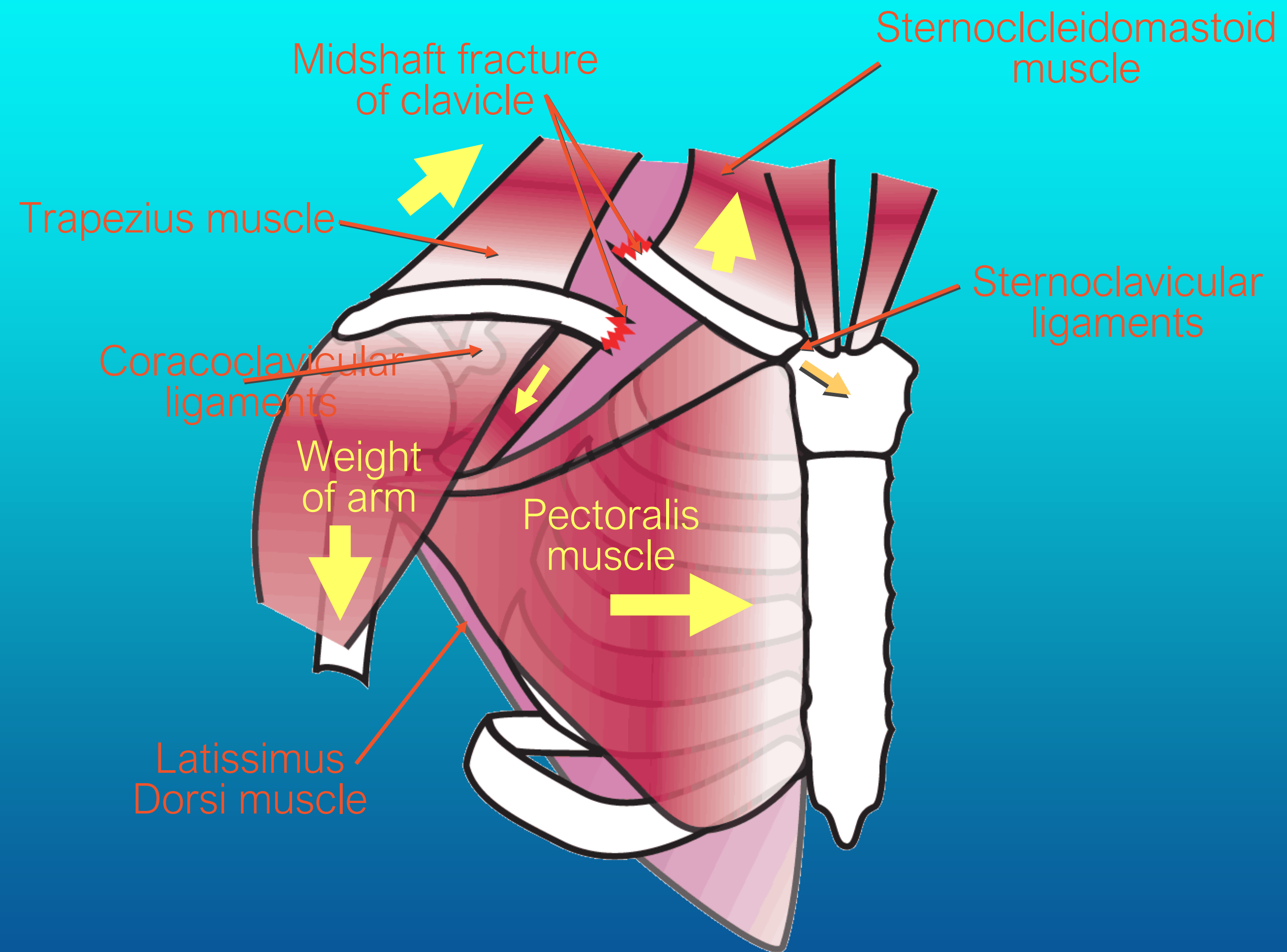
Bone –

- Triangular shaped- medial 1/3
- Tubular shaped- middle 1/3
- Flat shaped – lateral 1/3
- Most fractures occur junction of middle and distal 1/3 clavicle
- Occurs due to change in geometry of bone
- Thinnest part of bone
- No muscle and ligament coverage in this area



Craig EV: Fractures of the shoulder: Part II. Fractures of the Clavicle, in Rockwood CA, Green DP, Bucholz RW, *Rockwood and Green's Fractures in Adults*, ed 3. Philadelphia, PA: JB Lippincott, 1991, vol 1 pp 928-990

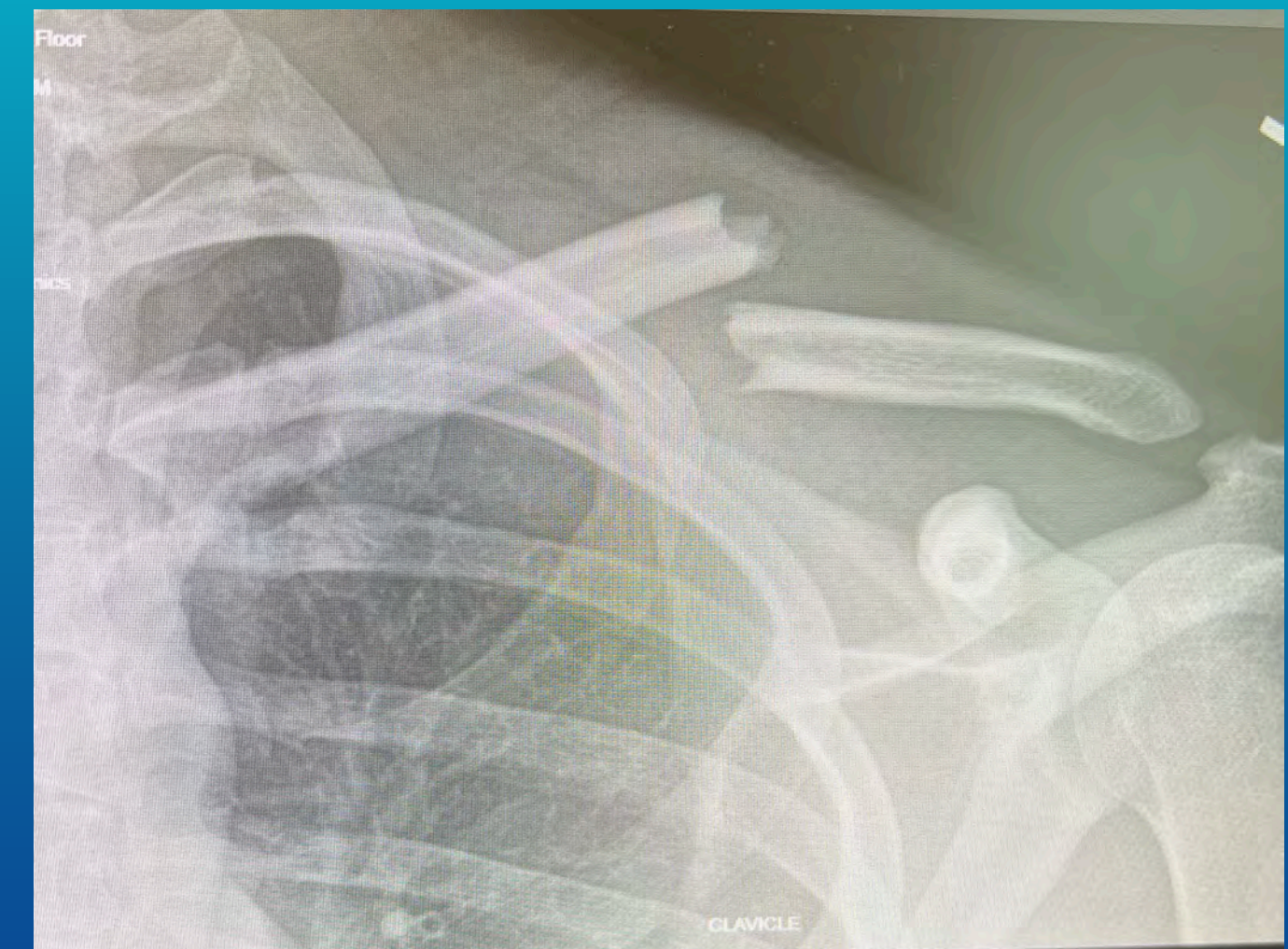
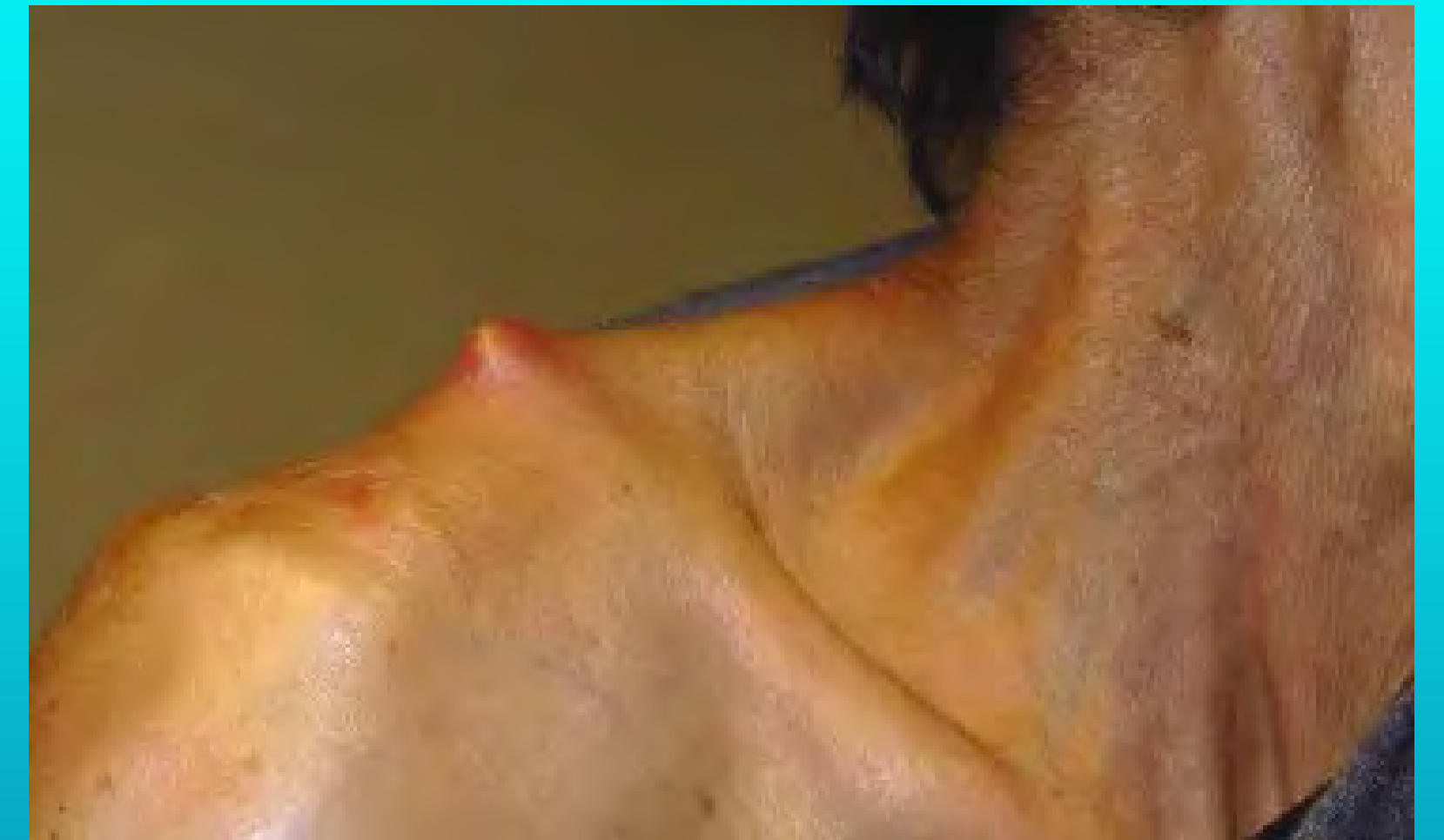Midshaft Clavicle Fracture



Mid-shaft clavicle Fracture

Factors in surgical management

- Open or closed fracture
- Pain
- Displaced fractures (>1.5 cm)/comminuted fx
- Shoulder girdle shortening (>2 cm)
- Skin impairment
- Neuro or vascular injury
- Loss Abduction strength
- Greater cosmetic deformity/failed conservative management
- Greater demand for overhead activity



Mid-shaft Clavicle Fracture

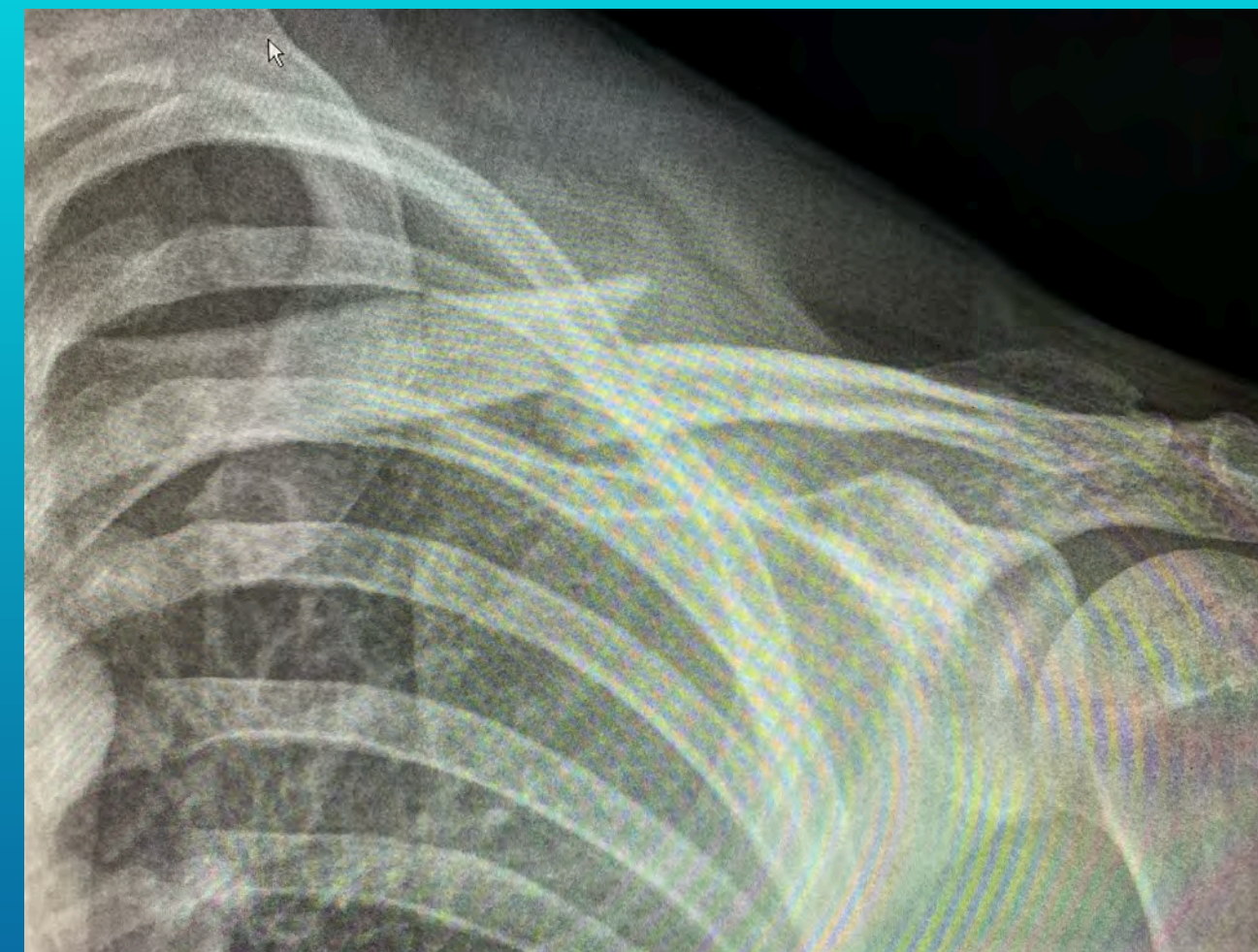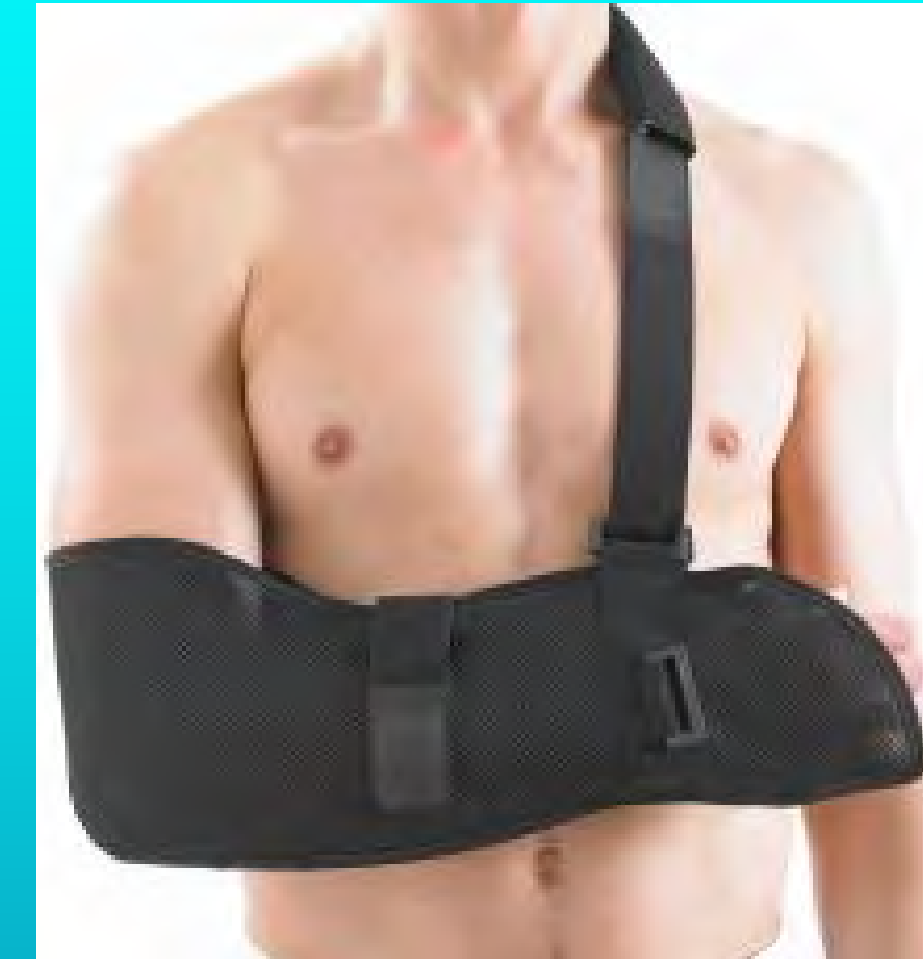Treatment Options:

- **Indications Non-op care**

- Minimally displaced, < 1.5cm shortening, medically unfit for surgery

- **Non-surgical management**

- **Sling vs. Figure 8**
 - Compliance issues
 - Less discomfort with sling
- **Pain medication**
- **Activity Limitations**
- **F/U 1-2 weeks**



Honeycutt MW, Fisher M, Riehl JT, Orthopaedic Tips: A Comprehensive Review of Midshaft Clavicle Fractures, JBJS JOPA 2019;7(3):e0053

Andersen et al: Treatment of Clavicle Fractures: Figure 8 vs. Simple Sling. Acta Orthop Scand 1987;58:71-74

Humerus Fx

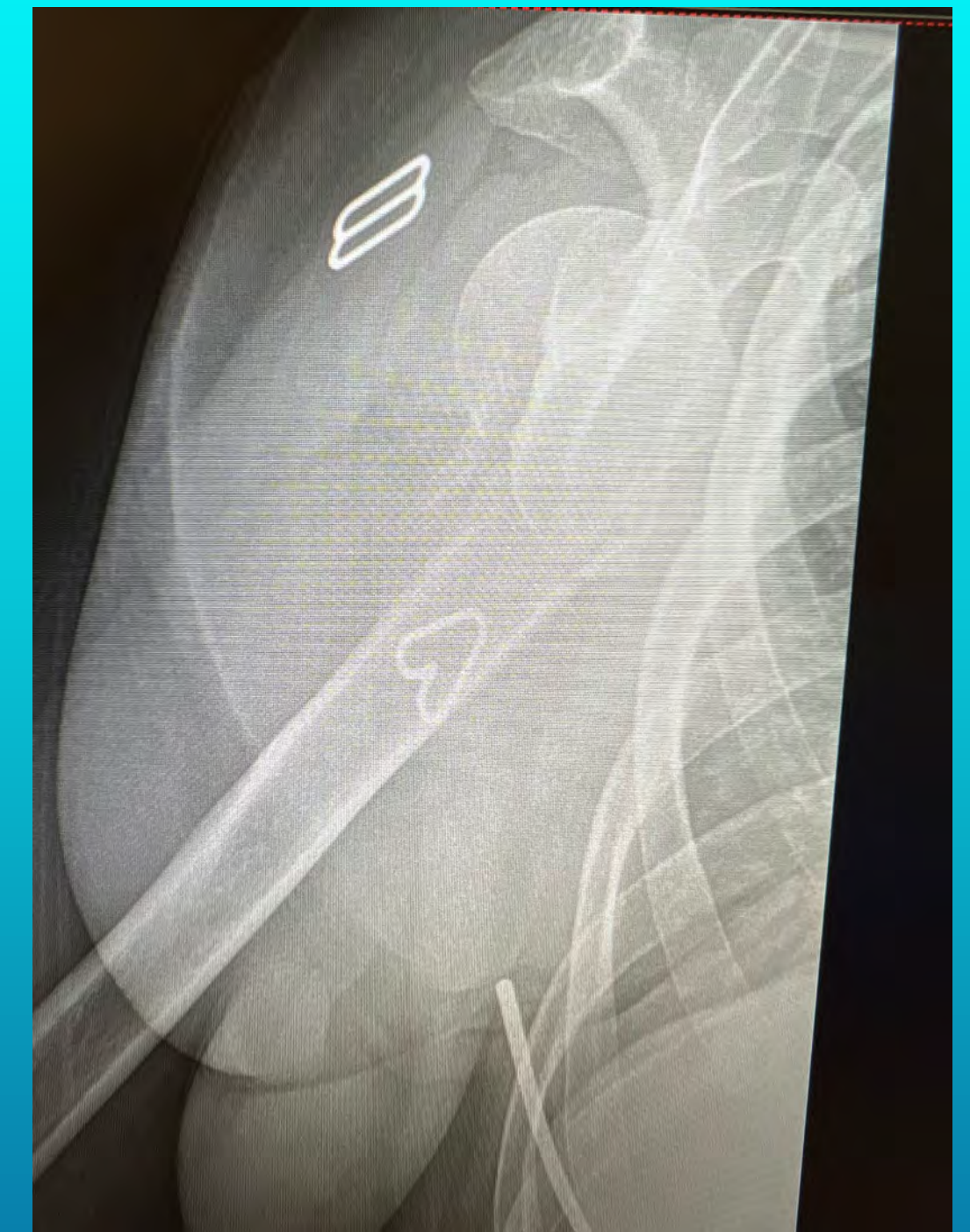Proximal Humerus Fractures

Epidemiology

- Common fx in older adults >65 yr. old
- 2-part fx most common (Surgical neck & Greater Tubercle)
- Blood supply key to overall healing process
- High-rate osteonecrosis w/ 4-part Fx
- Female > male

Factors contributing to Proximal Humerus fractures:

- Age/sex
- Bone quality - osteoporosis
- Fracture displacement
- Diabetes



Attum B, Thompson JH. Humerus Fractures Overview. [Updated 2020 Aug 10]. In: StatPearls [Internet]. Treasure Island (FL): StatPearls Publishing; 2020 Jan-. Available from: <https://www.ncbi.nlm.nih.gov/books/NBK482281/>

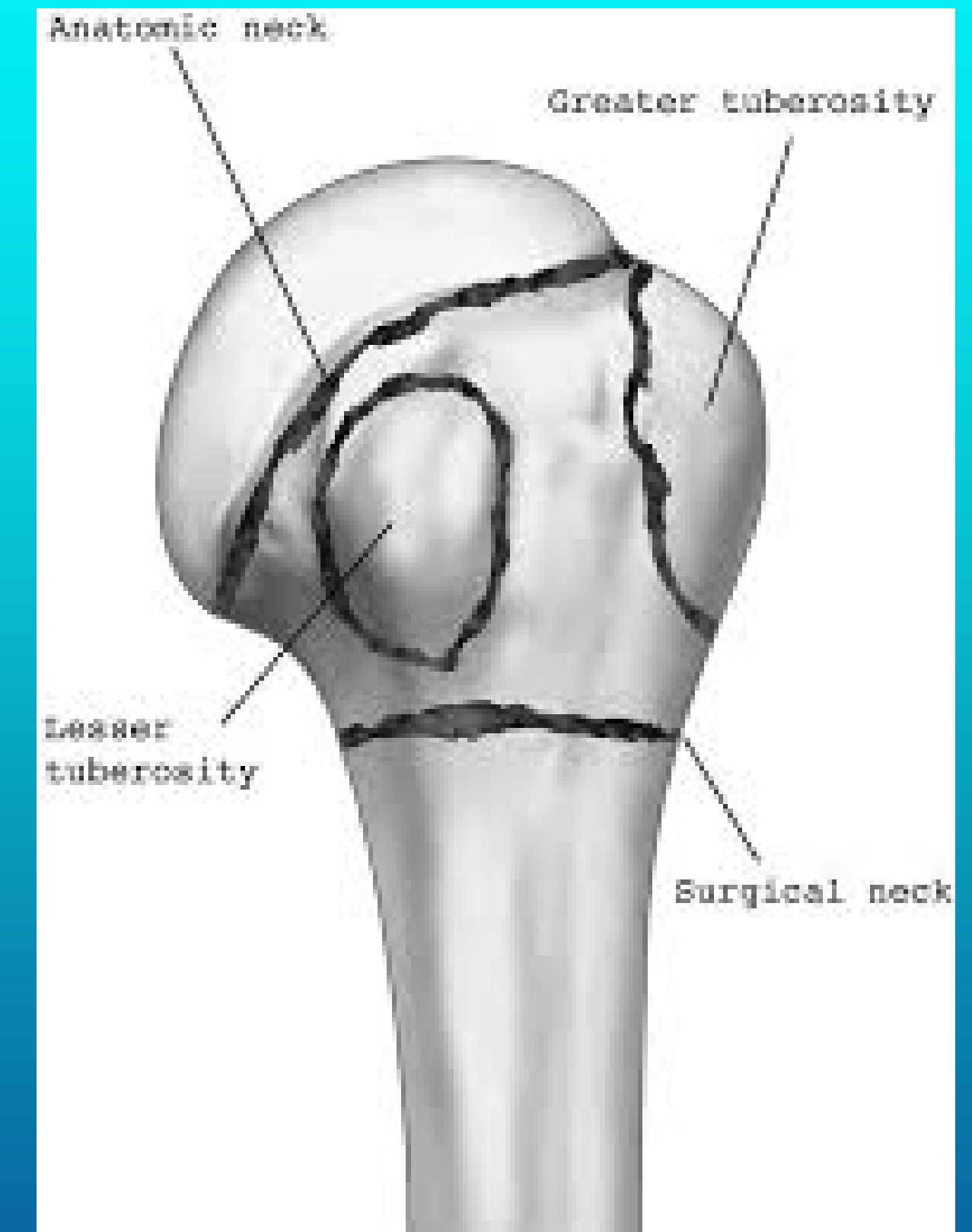
Pencle FJ, Varacallo M. Proximal Humerus Fracture. [Updated 2020 Aug 16]. In: StatPearls [Internet]. Treasure Island (FL): StatPearls Publishing; 2020 Jan Available from: <https://www.ncbi.nlm.nih.gov/books/NBK470346>

Proximal Humerus Fractures

Neer Classification

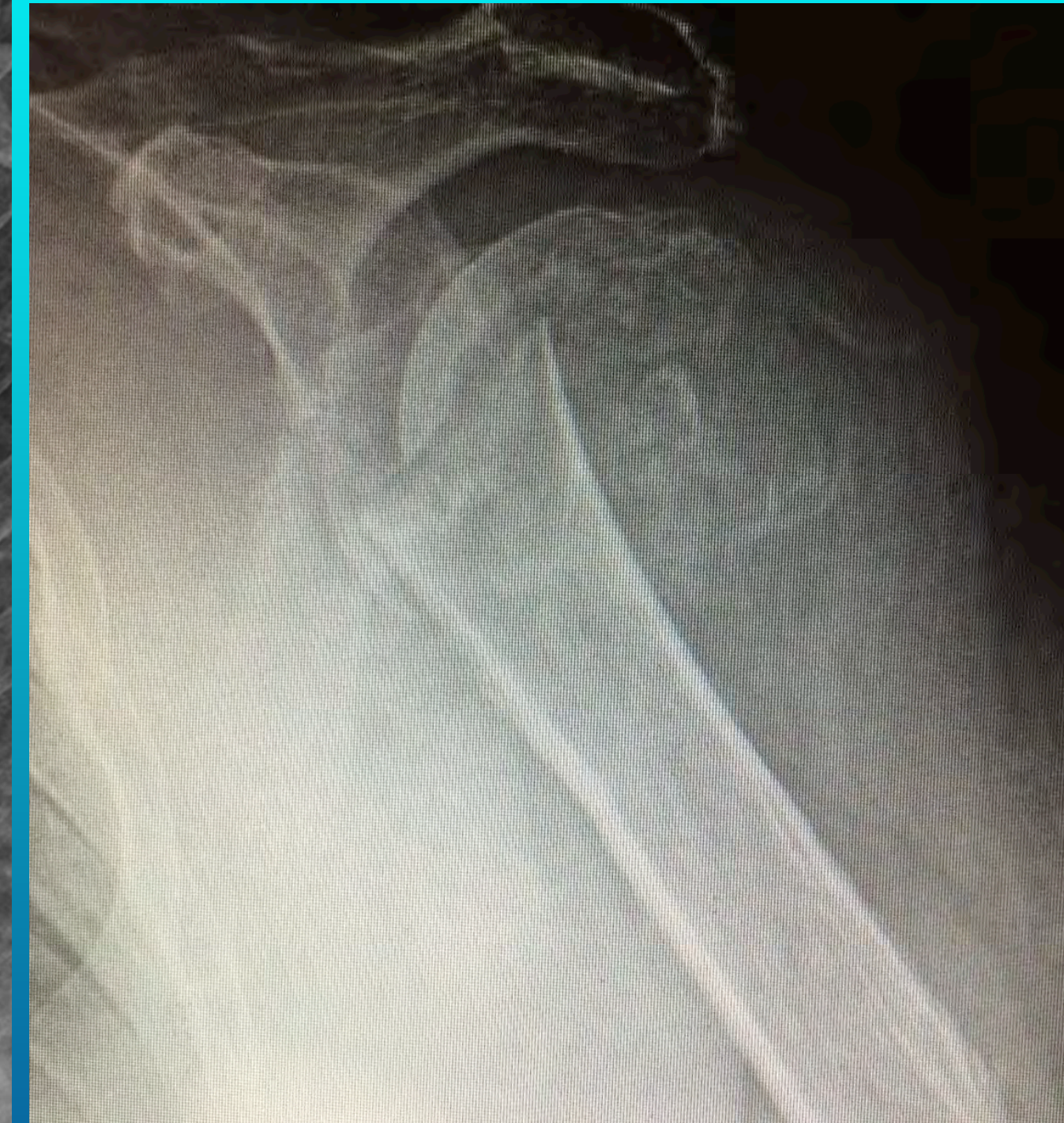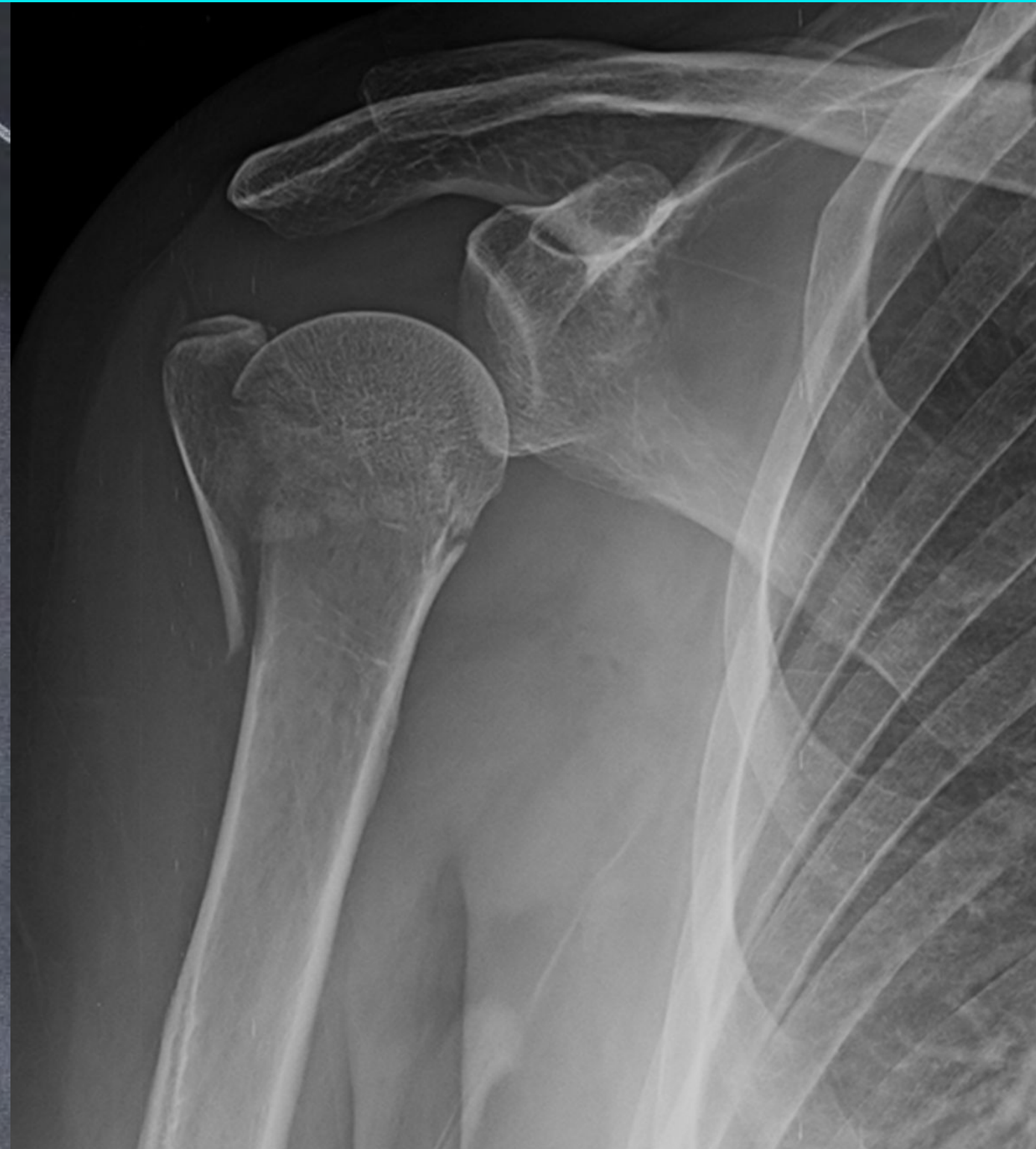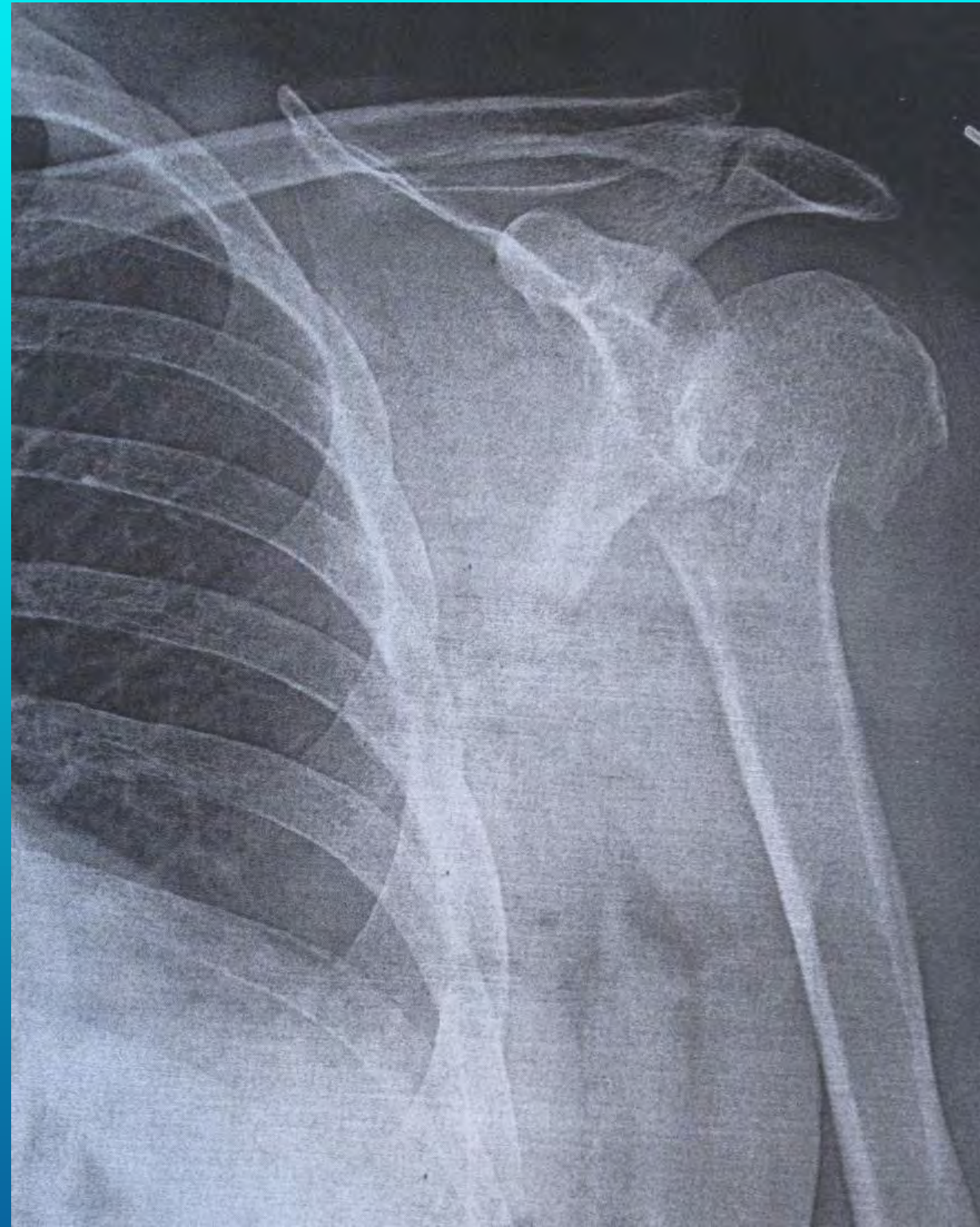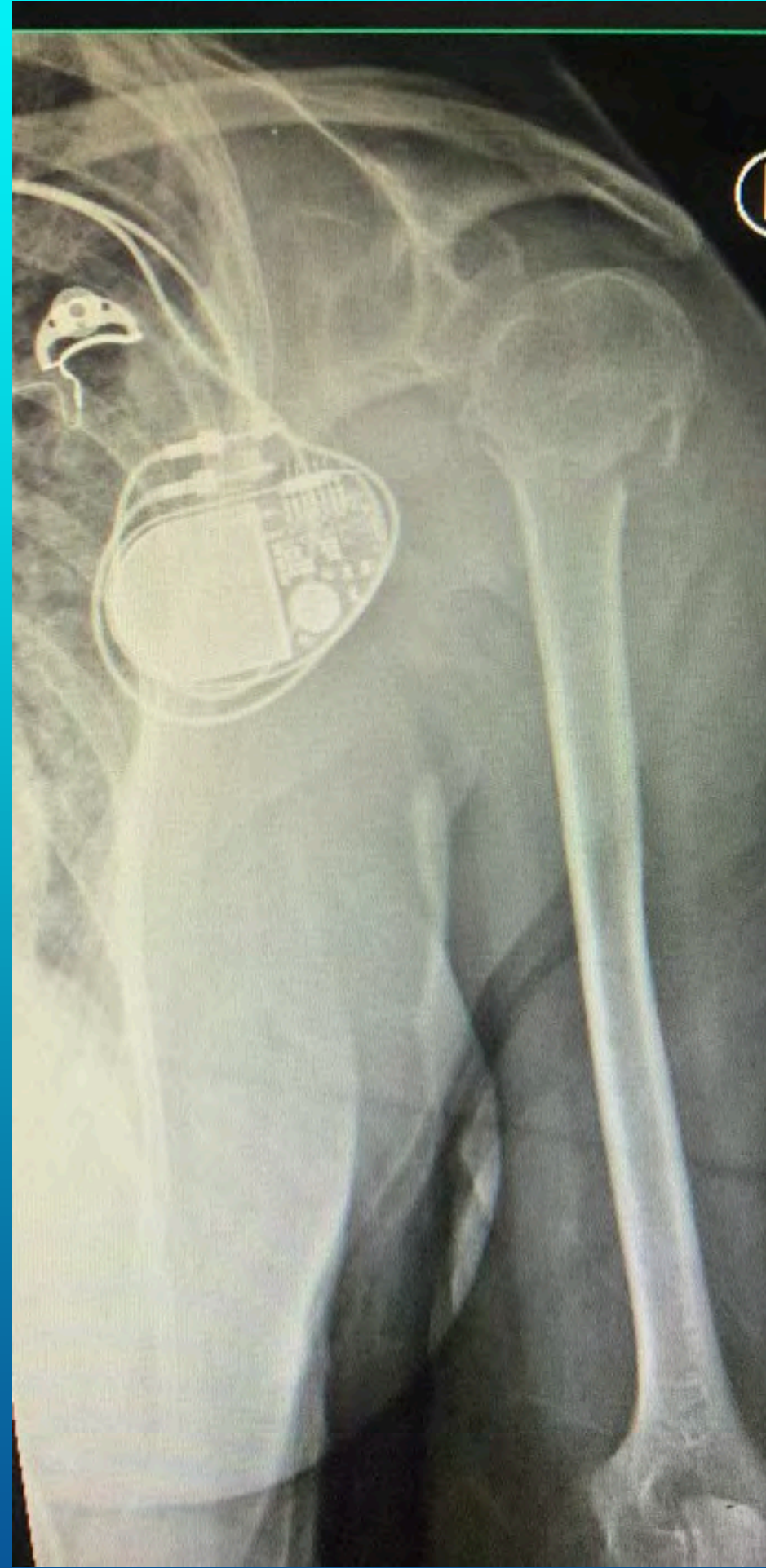
Anatomic Segments

- Shaft-Articular Head-Greater Tubercle-Lesser Tubercle
- Parts considered: **>1 cm displaced, 45 degrees angulation**
 - **2-part**
 - **Articular component**- Fx line thru anatomic neck
 - **Shaft Component** - Fx line thru surgical neck – most common
 - **3-Part**
 - Articular surface, thru anatomic neck, Humeral shaft & greater tubercle
 - Articular surface, thru anatomic neck, Humeral shaft & lesser tubercle
 - **4-Part**
 - Variation anatomic/surgical neck, great/lesser tubercle
 - Fracture / Dislocation



Triplet J, Proximal Humerus Fractures, Orthobullet.com, updated 7/19/2020 <https://www.orthobullets.com/trauma/1015/proximal-humerus-fractures>, accessed November 15, 2020

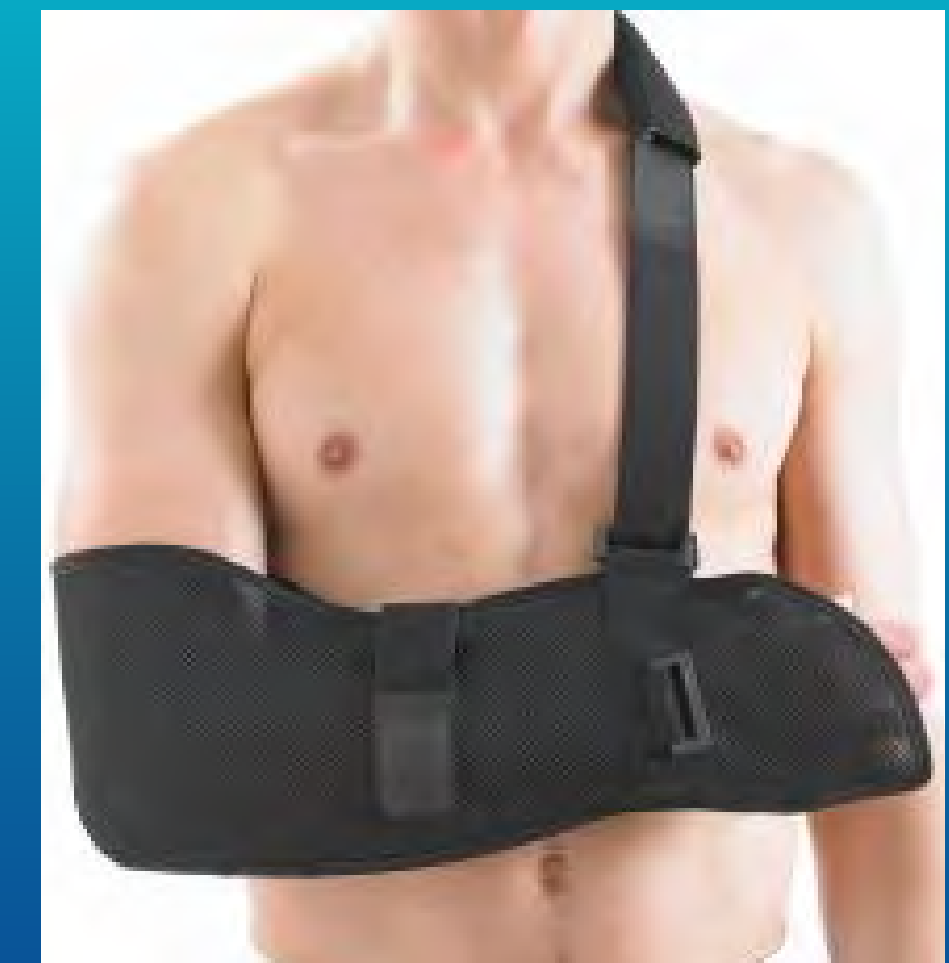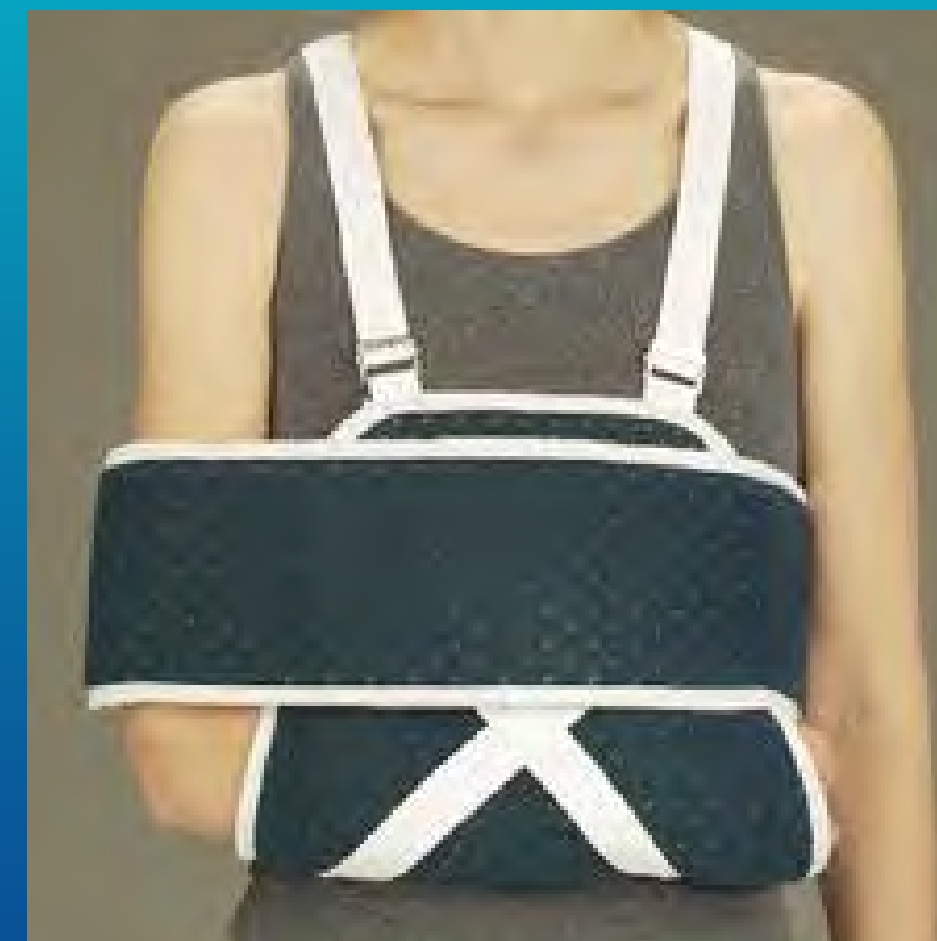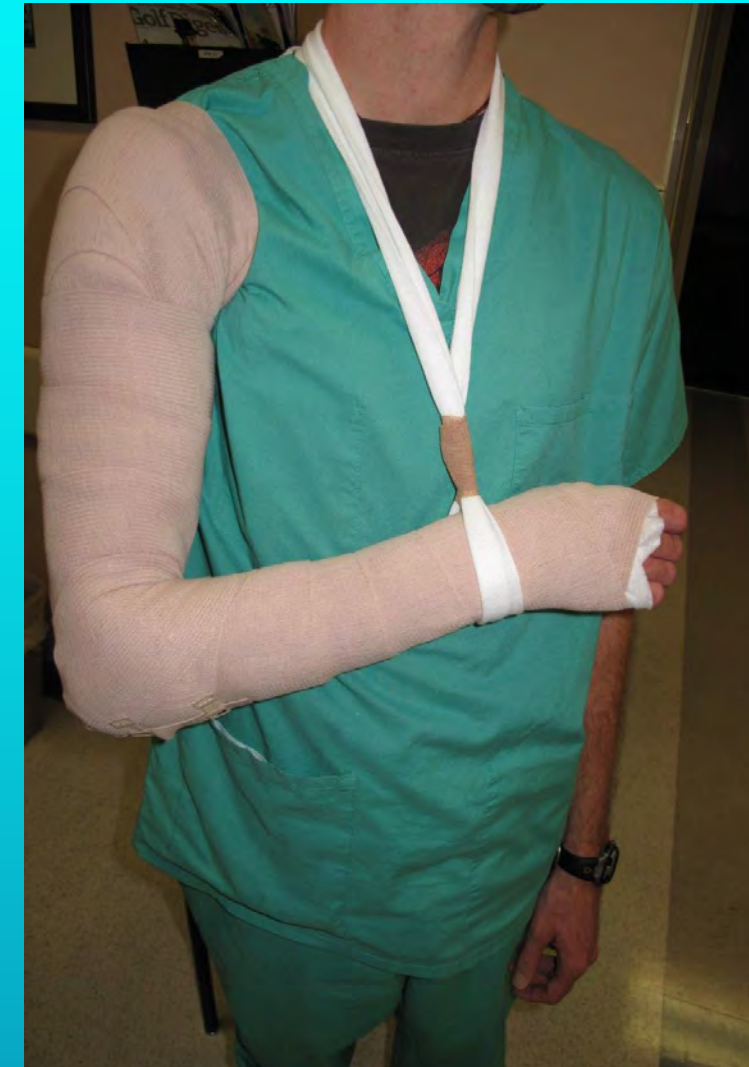Proximal Humerus fx



Proximal Humerus Fracture

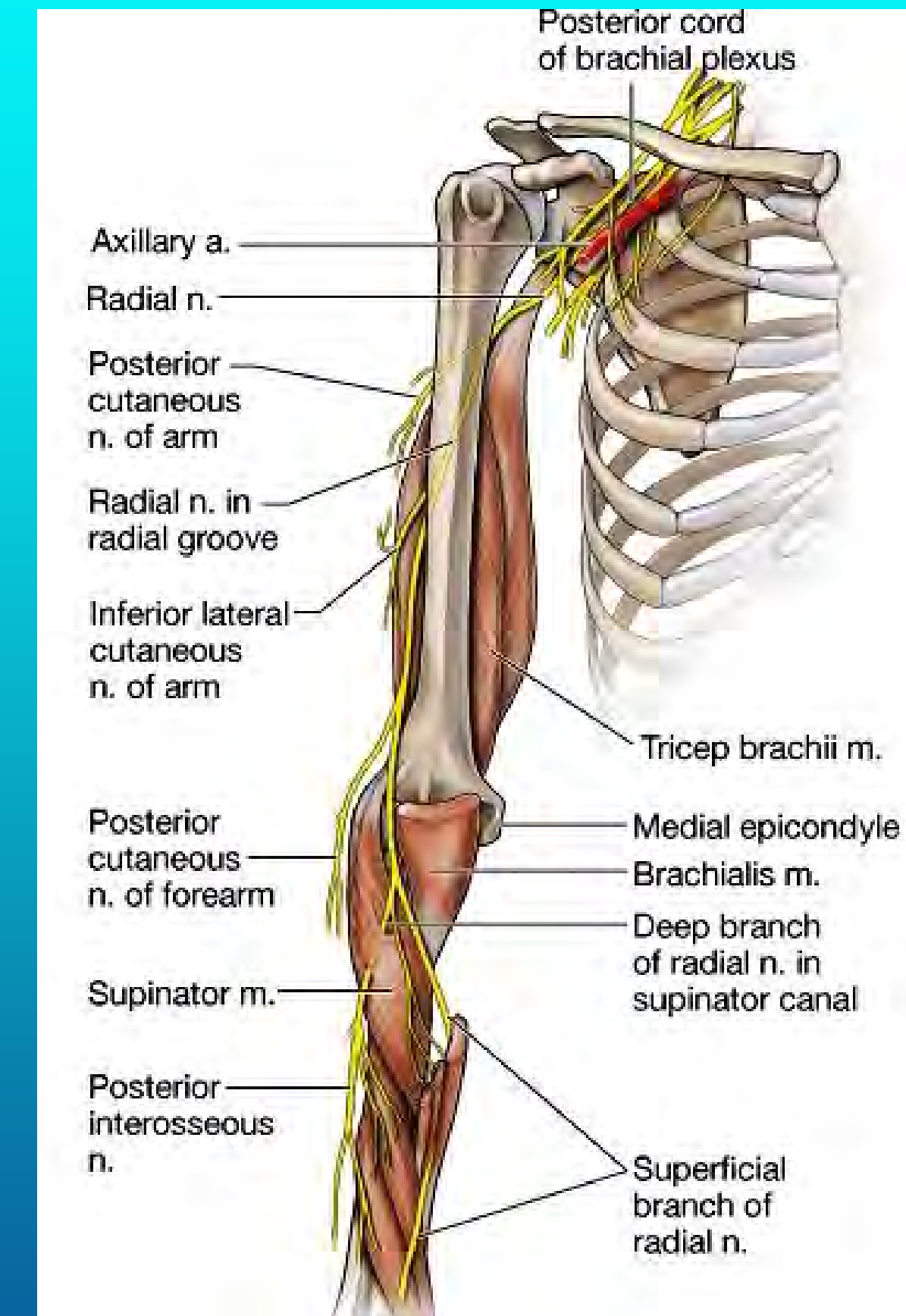
Emergent Treatment

- Majority treatment “hanging sling”
- Pain management
- Sleeping postures
- Early motion-elbow/Shoulder



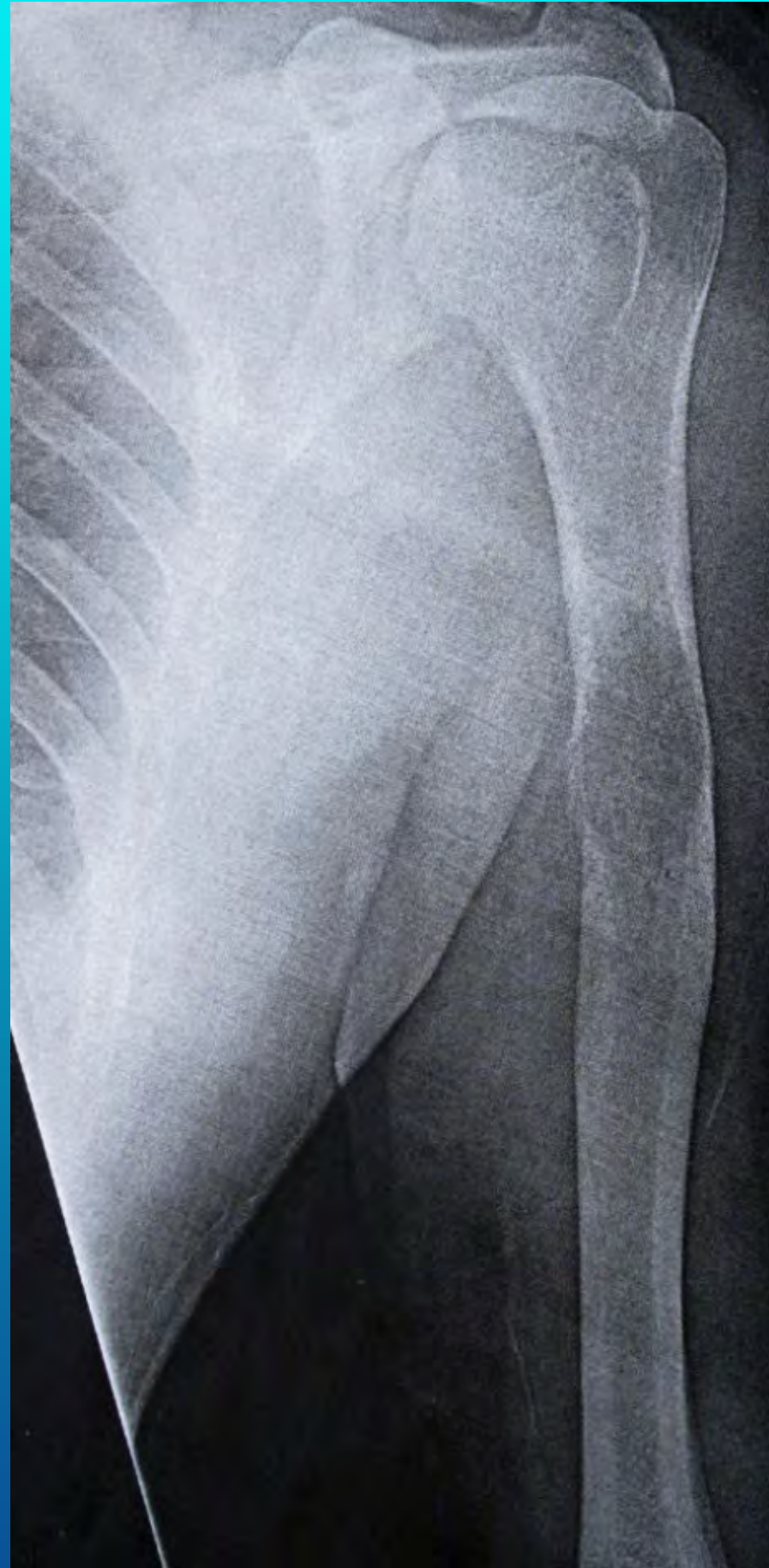Humeral Shaft Fracture

- Epidemiology
 - Usual treatment is non-operative
 - High Energy mechanism
 - Low Energy: high suspicion for pathology fx
 - Primary Mechanism of injury
 - Direct blow – transverse or comminuted fracture
 - MVA
 - Indirect blow – spiral or oblique fracture
 - Fall – elderly more common
 - Throwing motion– less common
 - Concern for Radial Nerve injury

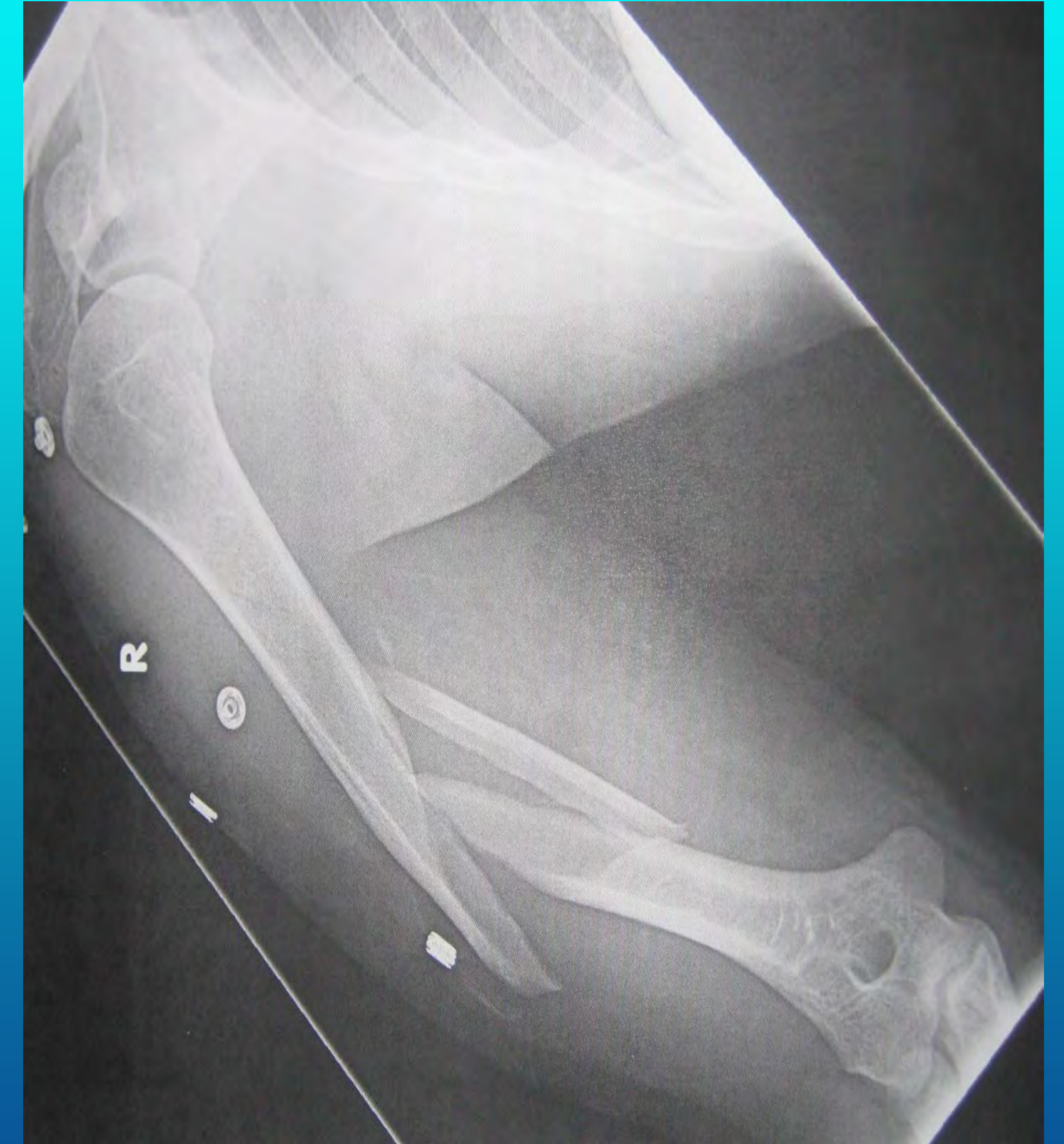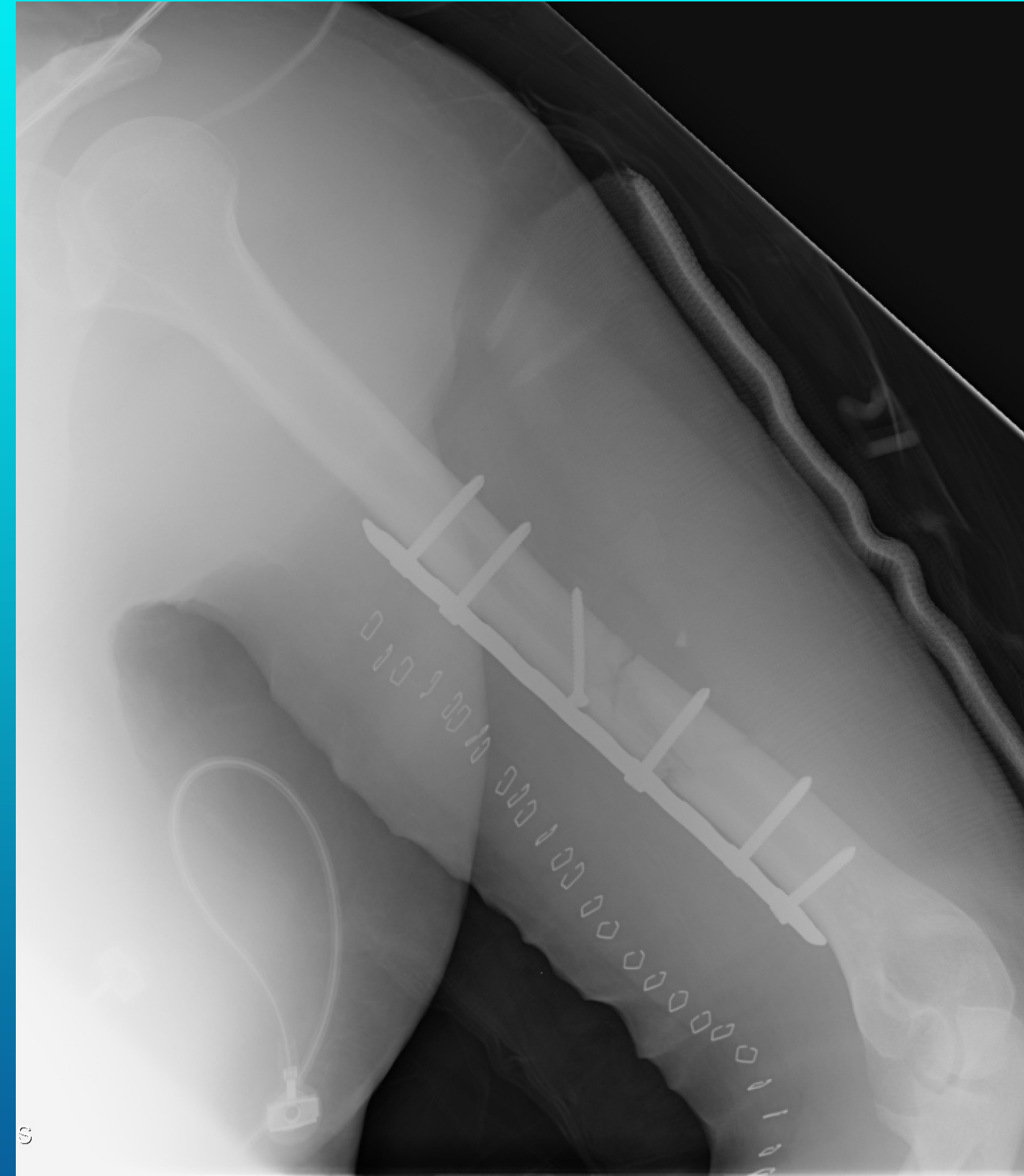


Bounds EJ, Frane N, Kok SJ. Humeral Shaft Fractures. [Updated 2020 Aug 24]. In: StatPearls [Internet]. Treasure Island (FL): StatPearls Publishing; 2020 Jan-. Available from: <https://www.ncbi.nlm.nih.gov/books/NBK448074/>

Humeral Shaft Fracture



Picture courtesy T Gocke, PA-C

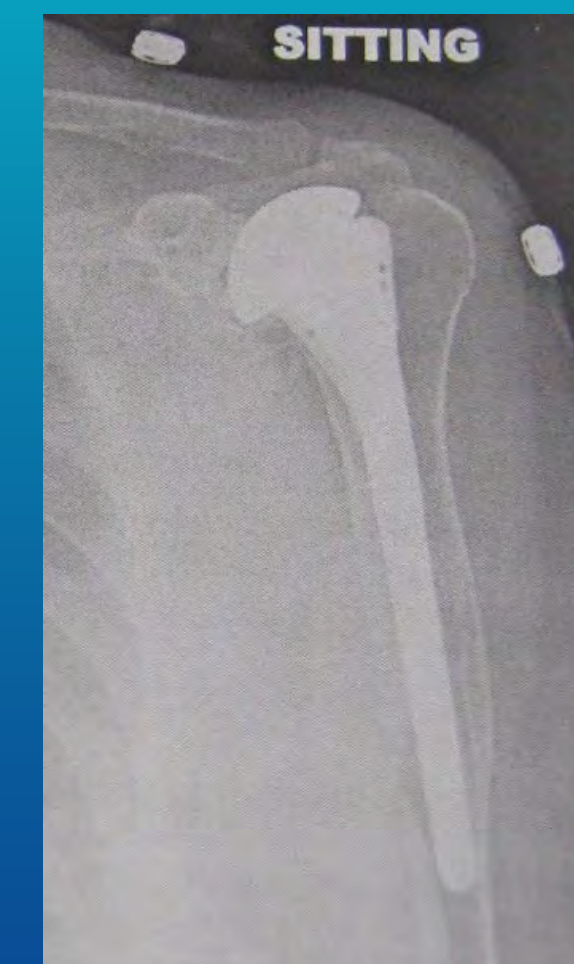
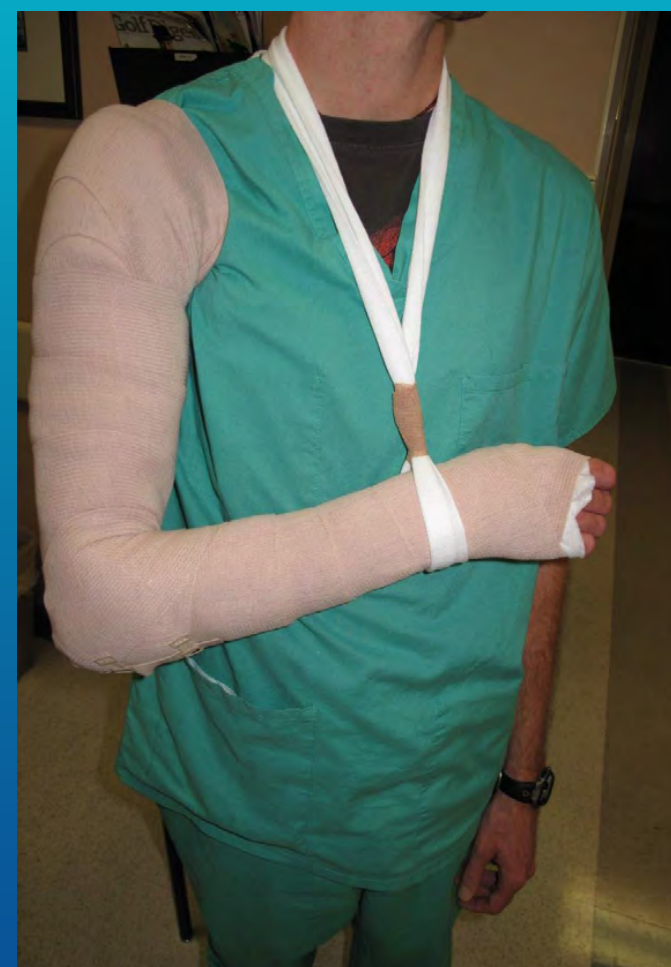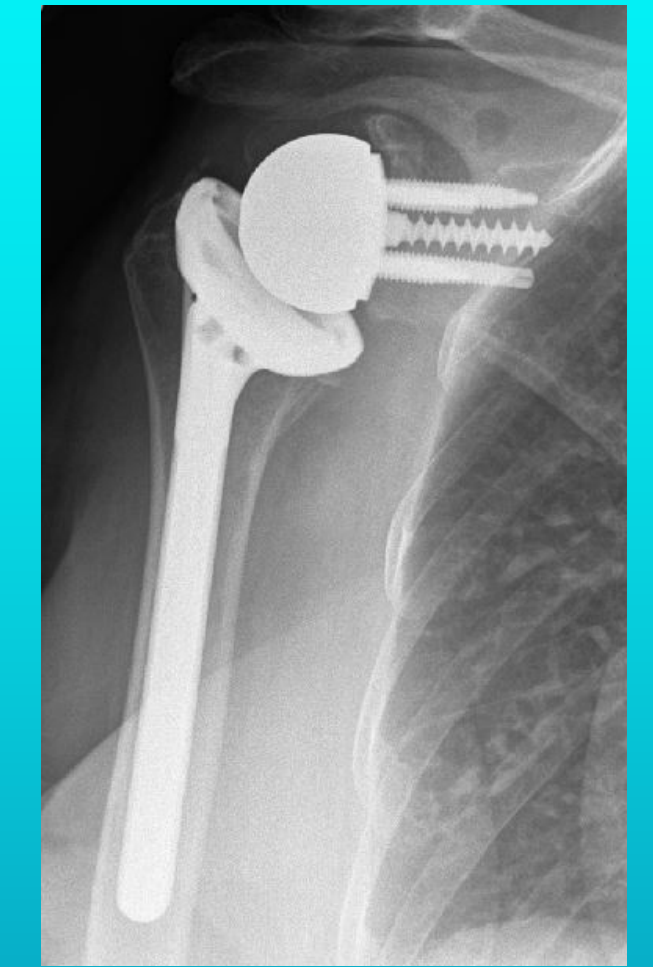
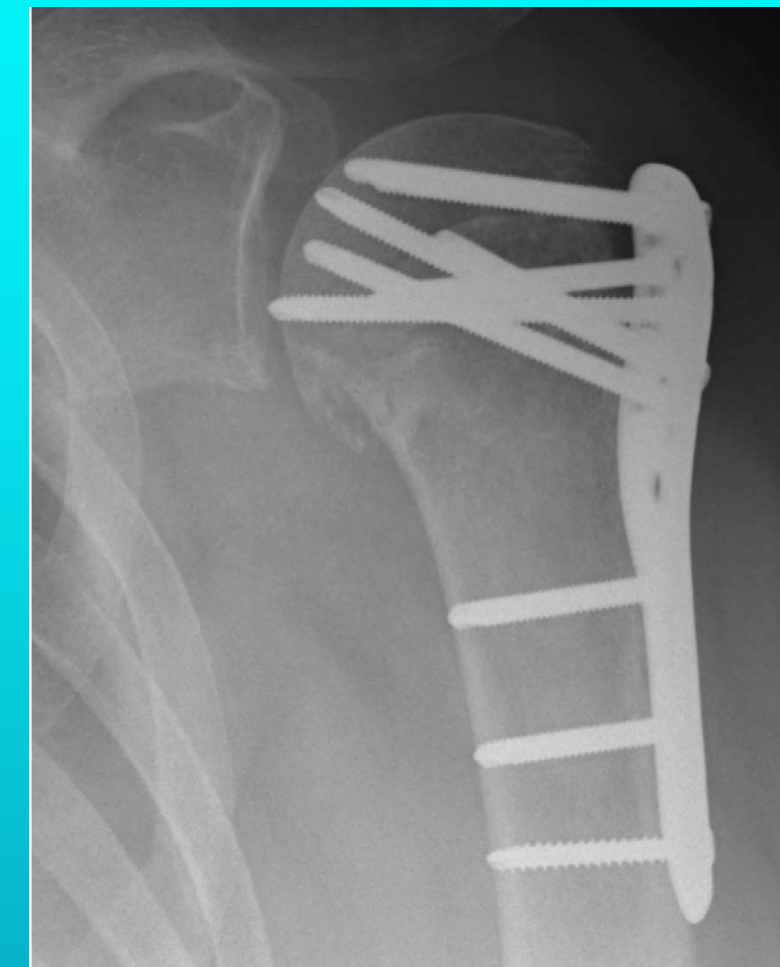


Picture courtesy T Gocke, PA-C

Humerus Fx

Proximal Humerus

- Treatment considerations-
 - Multifactorial
 - Age
 - Fracture type
 - Pt expectations
- Treatment options
 - Non-op
 - ORIF
 - Hemiarthroplasty
 - Reverse TSA



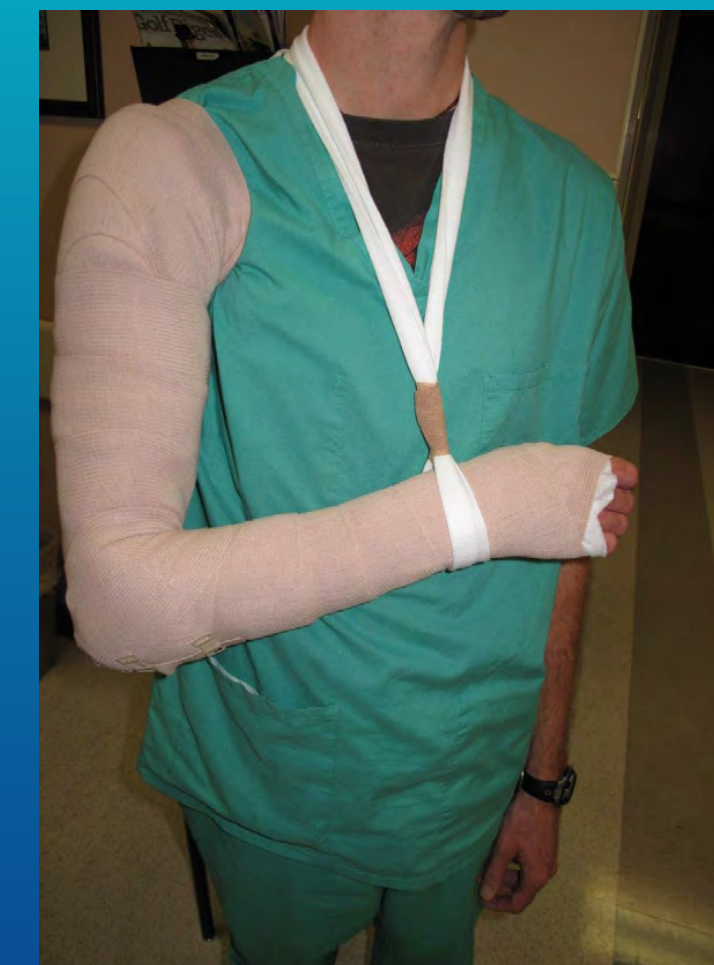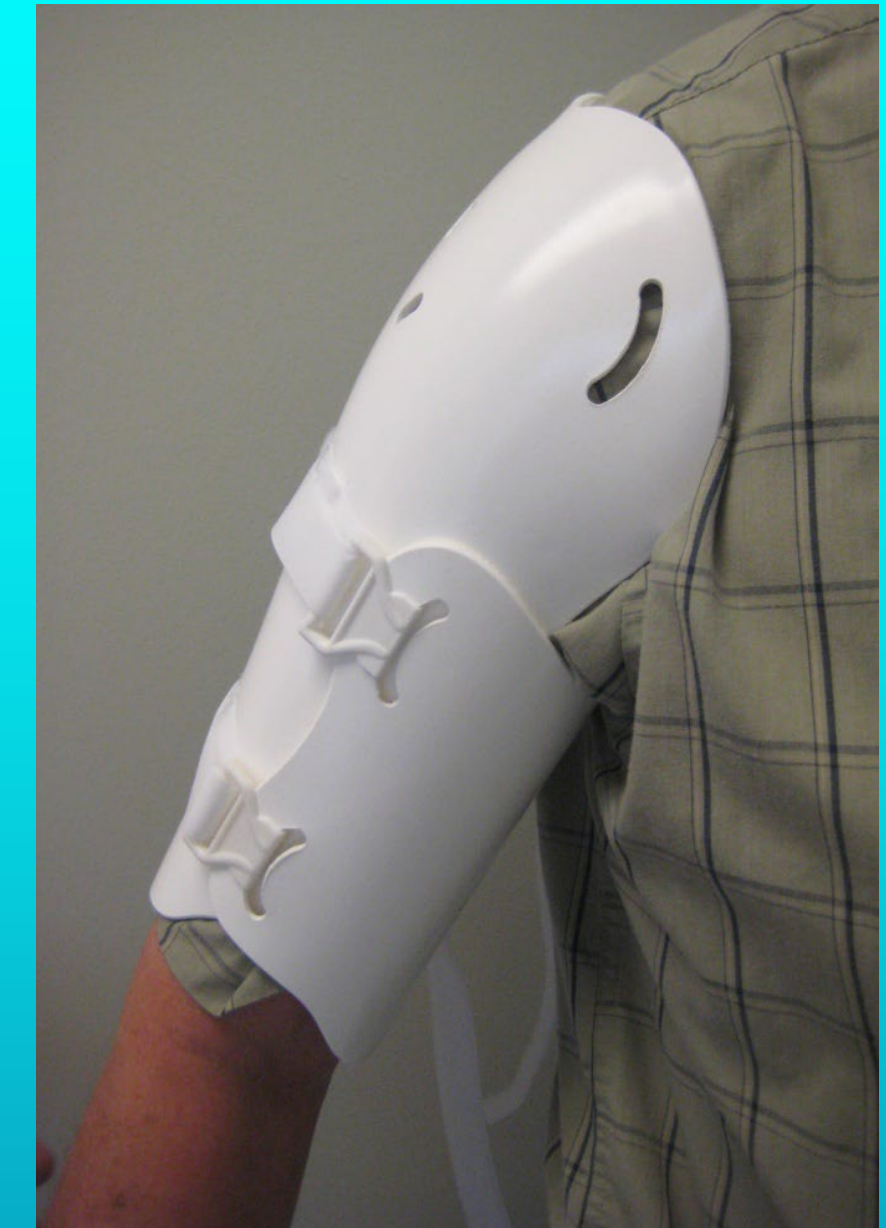Humeral Shaft Fracture

- **Treatment options- Closed Fracture**

- Frequent follow up and adjustment of hanging arm cast/brace/splint
- Xray weekly x 3 weeks
- Begin early wrist/hand ROM
- **Acceptable post reduction alignment**
 - **<20° anterior angulation**
 - **<30° varus**
 - **<15° malrotation**
 - **3cm shortening**

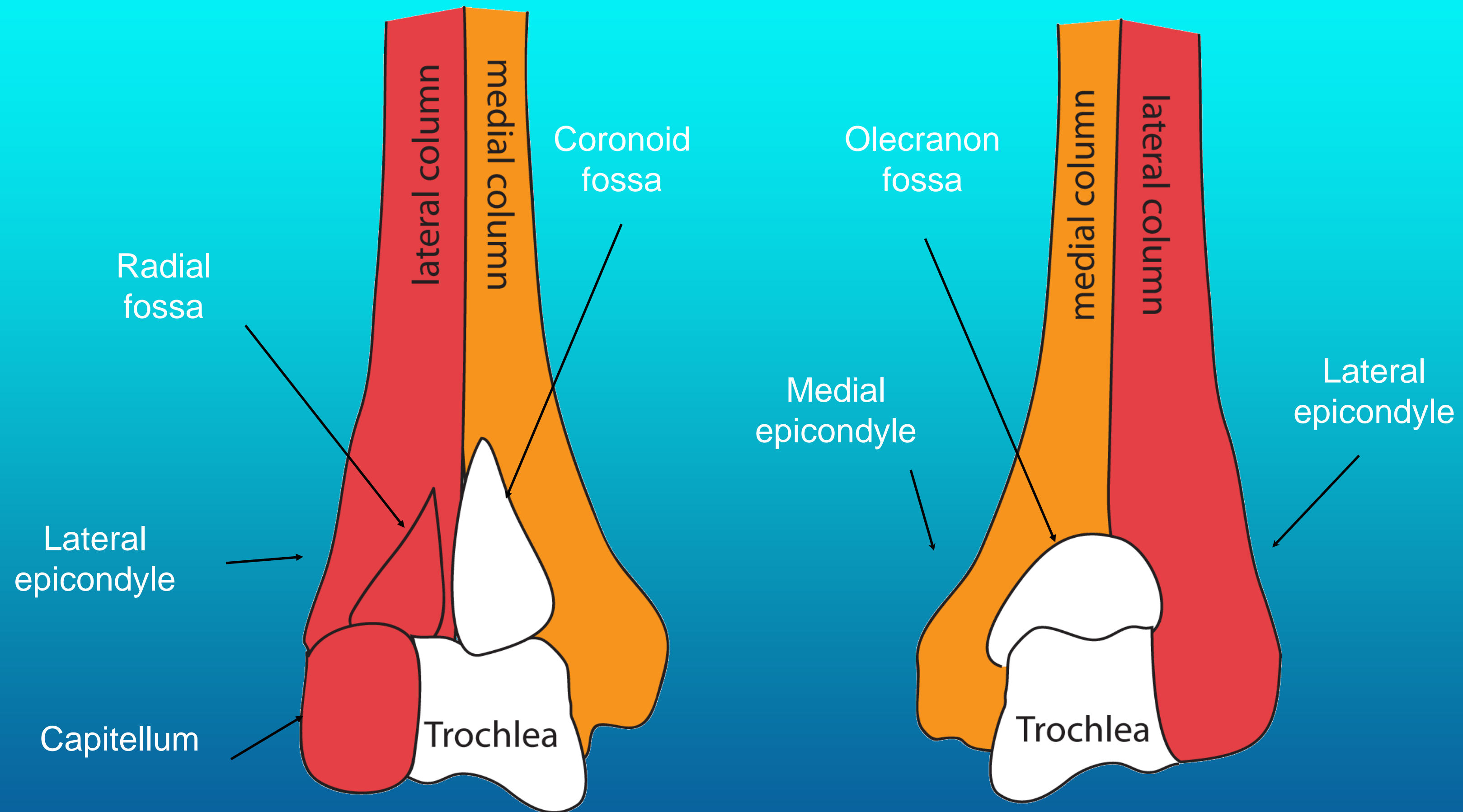
- **Surgical indications**

- Open Fx\Polytrauma
- Vascular injury
- Floating Elbow
- Obesity – immobilization difficulty



Supracondylar Humerus FX

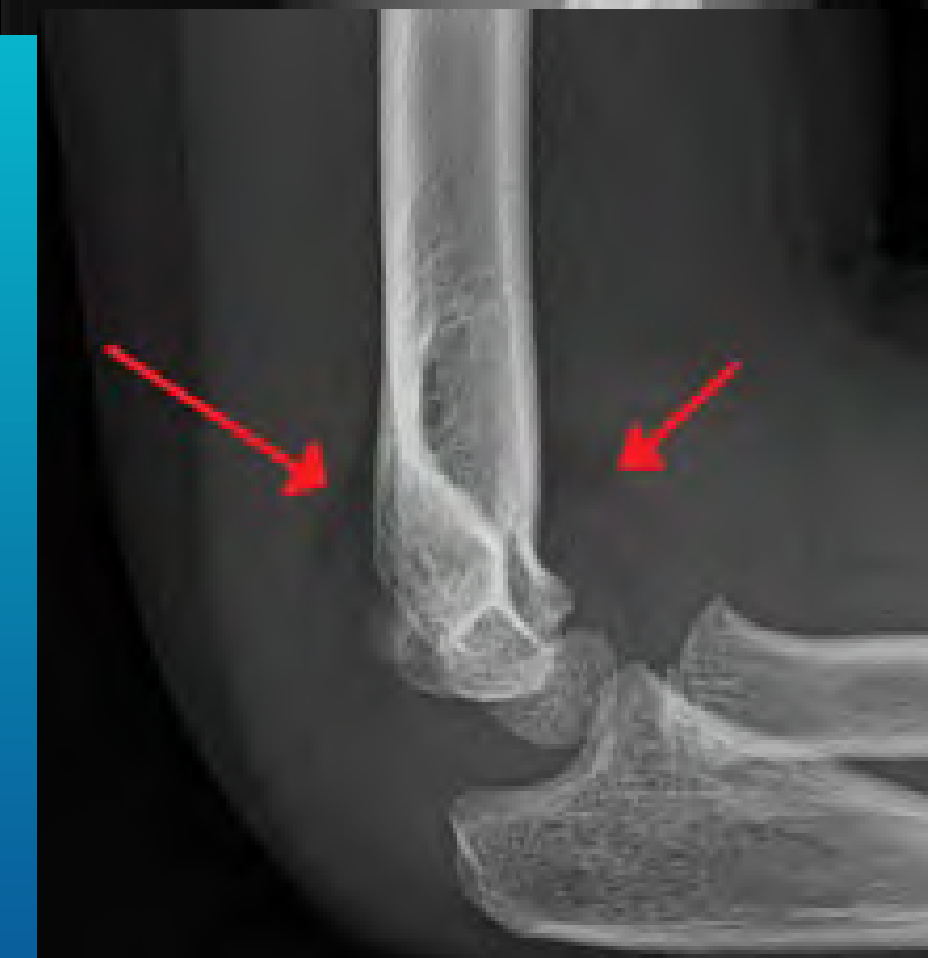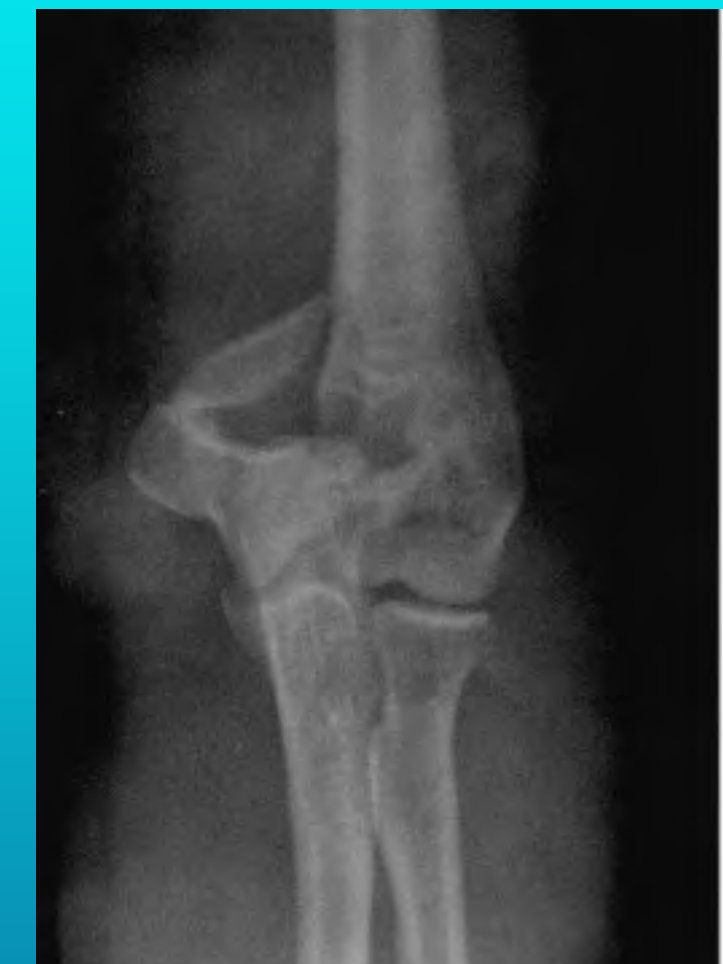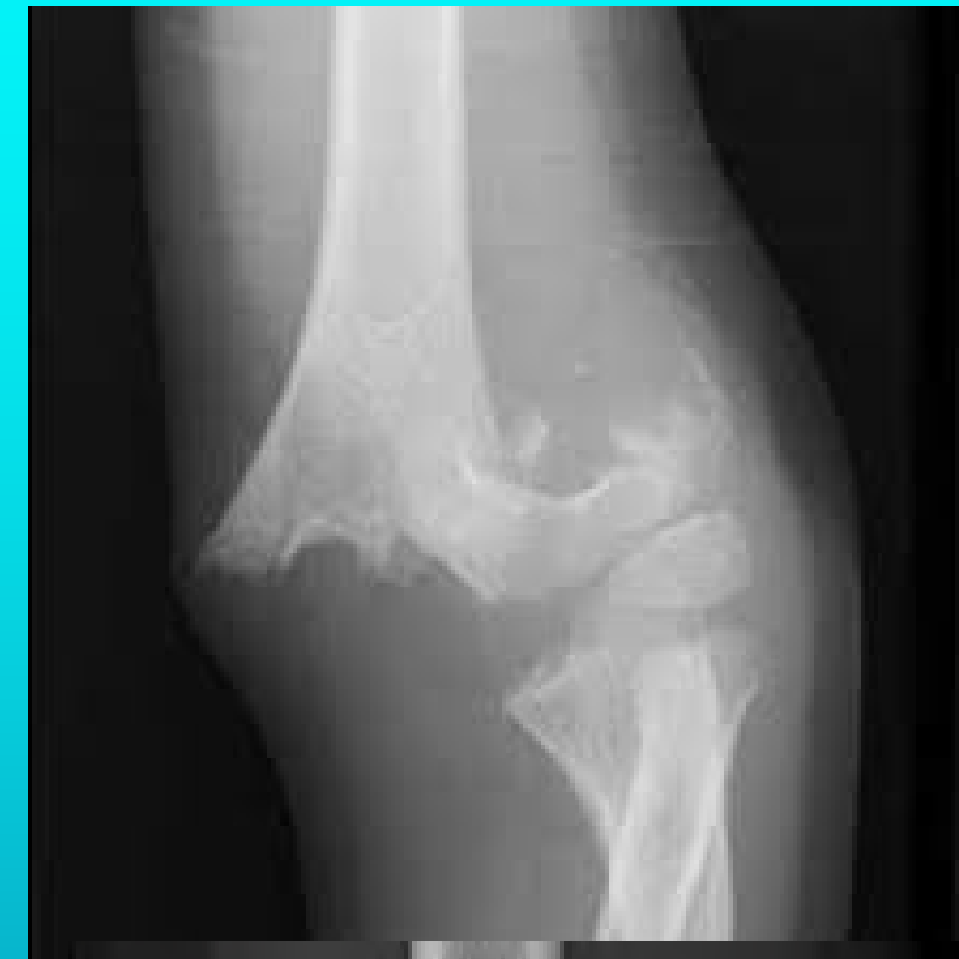Bony Landmarks



Supracondylar Humerus Fx

Epidemiology

- **30% all Elbow fx**
 - Supracondylar
 - Single Column fx- Lateral
 - Bi-column fx- heavy damage
 - Young men & older female
 - Falls from standing height/high energy
- Assoc Injuries
 - Elbow dislocation
 - Terrible Triad
 - Floating Elbow
 - Volkmann Contracture - missed forearm compartment syndrome



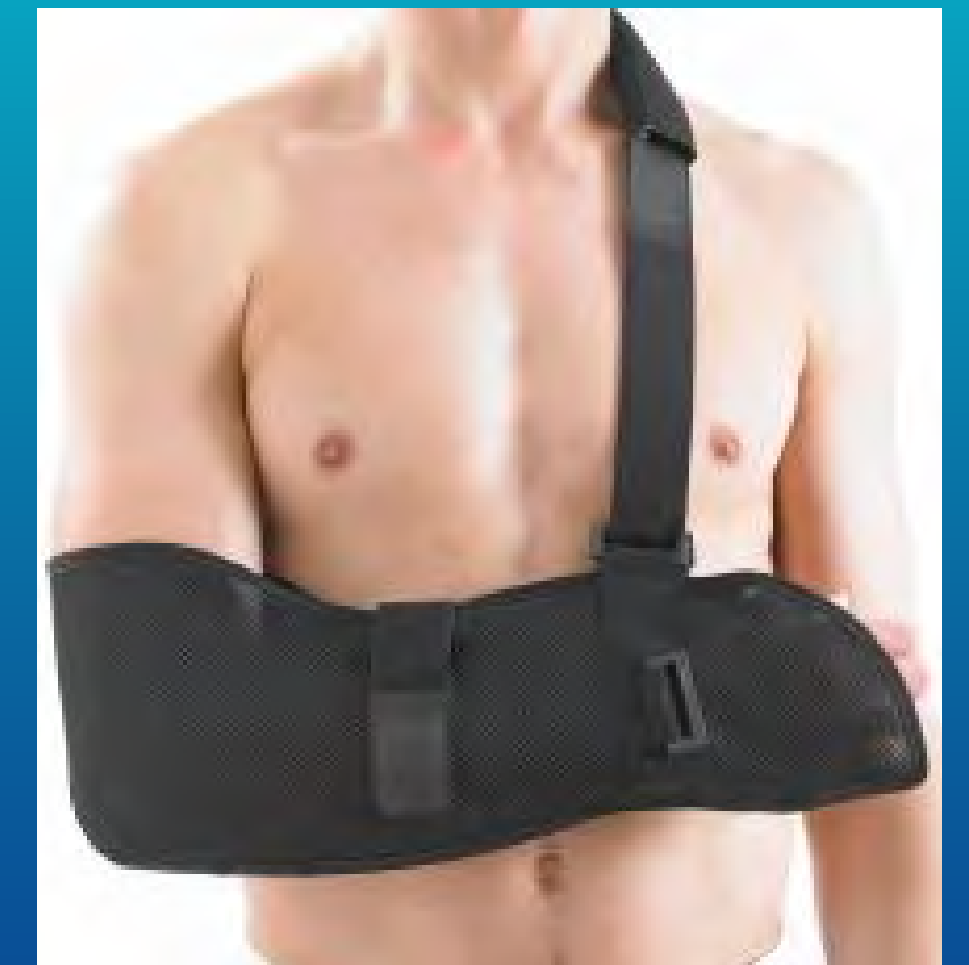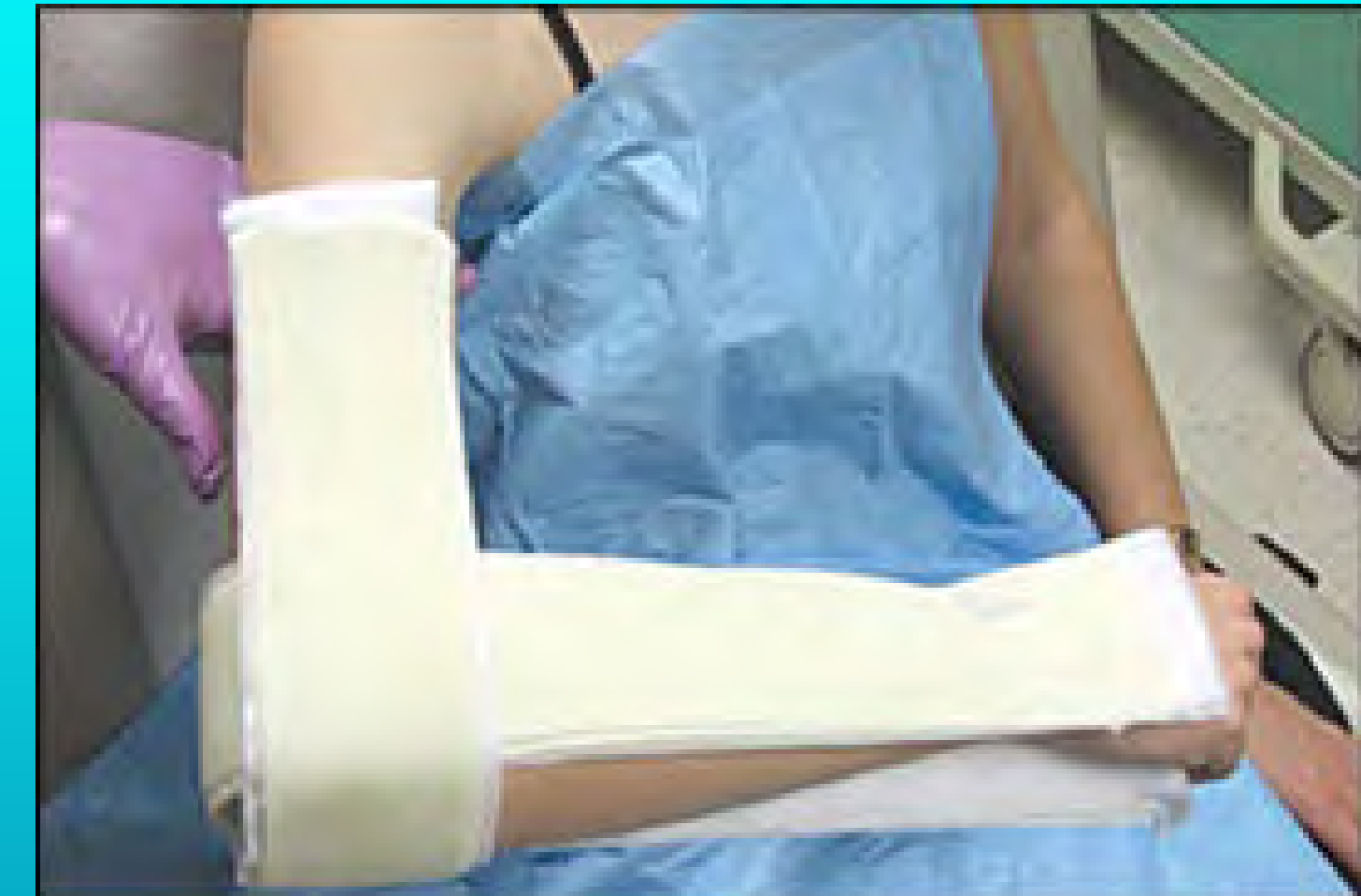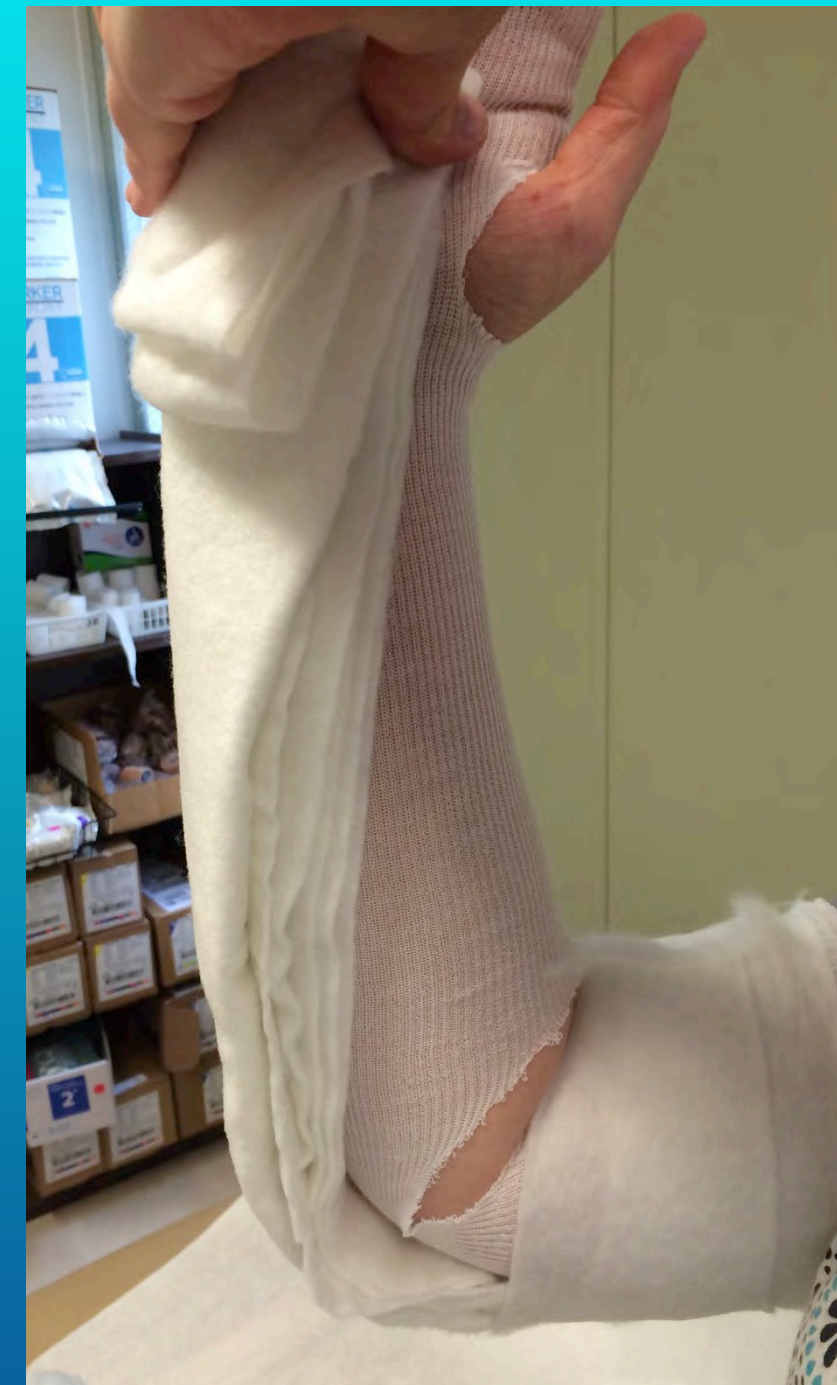Supracondylar Humerus Fx

Exam

- Neurovascular- assess frequently
 - High suspicion for vascular injury
- Grossly unstable fx – limit motion

Acute treatment

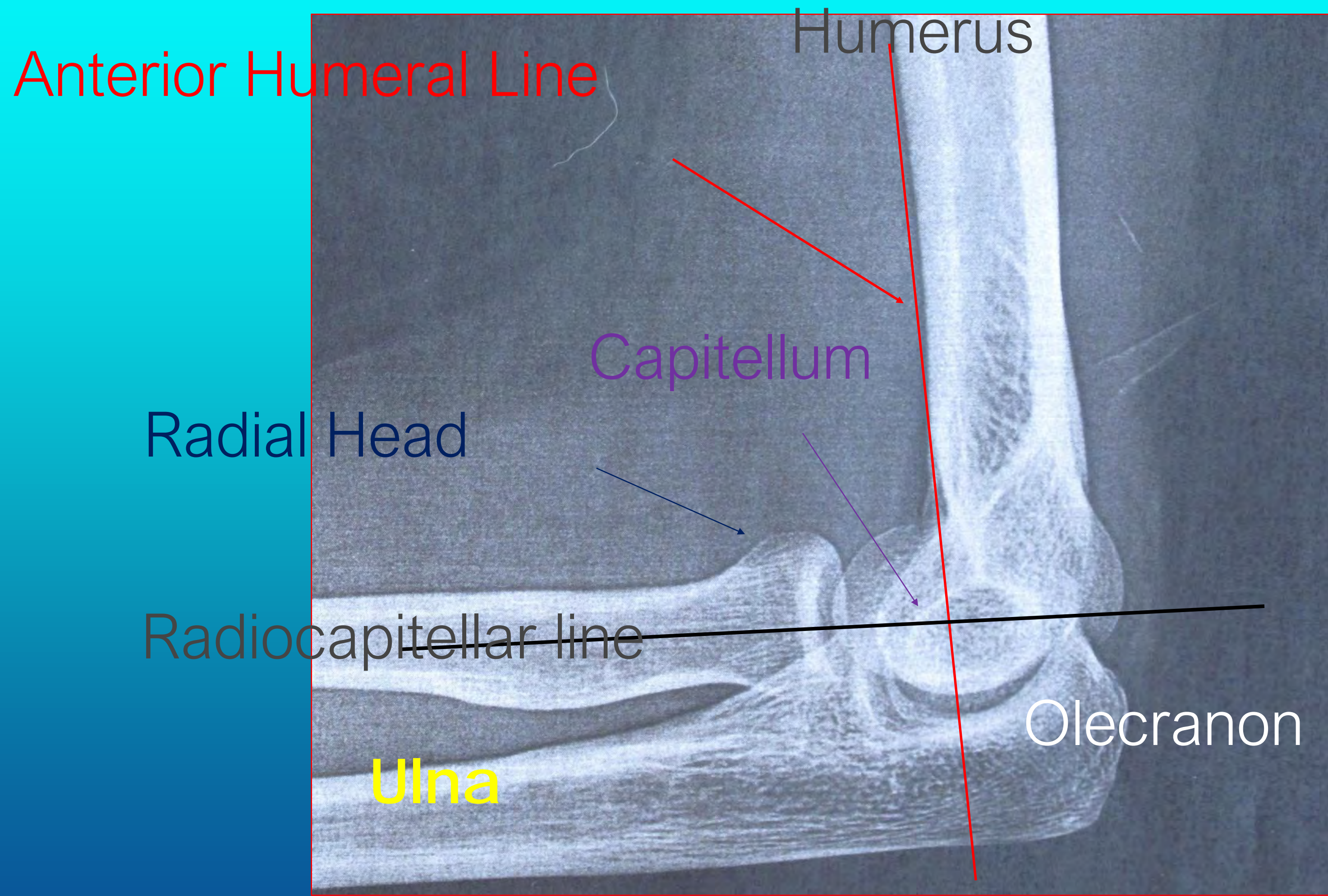
- Compromised Neurovascular
 - Emergent vascular consult/CTA
 - Concern for forearm compartment syndrome
 - Admit
- Long-arm posterior splint vs Dbl Sugar-tong
 - <90° flexion
- Sling
- Pain management
- Follow up 3-5 days
- **Most all elbow Fx require surgery**



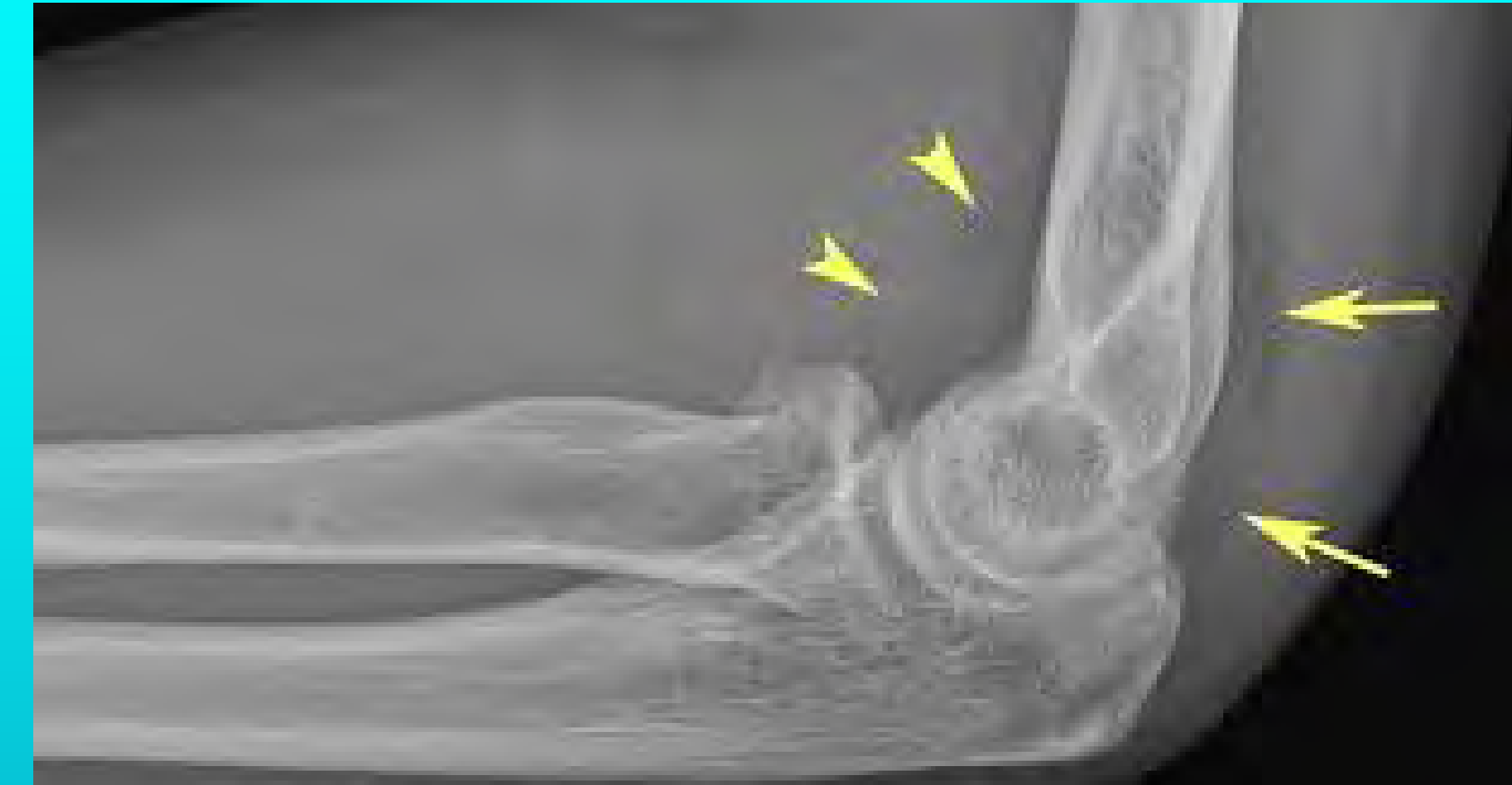Elbow Fx

--Radial head

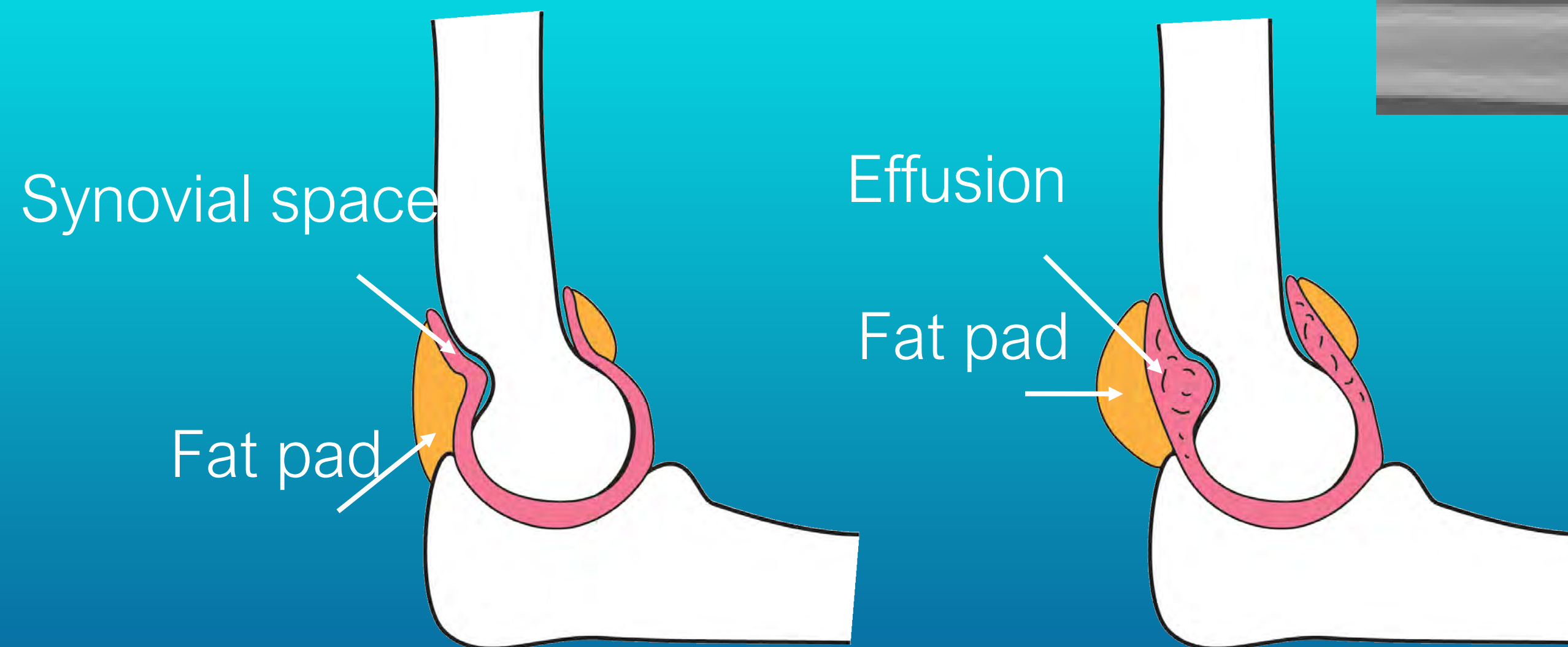
--Olecranon



Radiology



Fat Pad Sign



Radial Head Fx

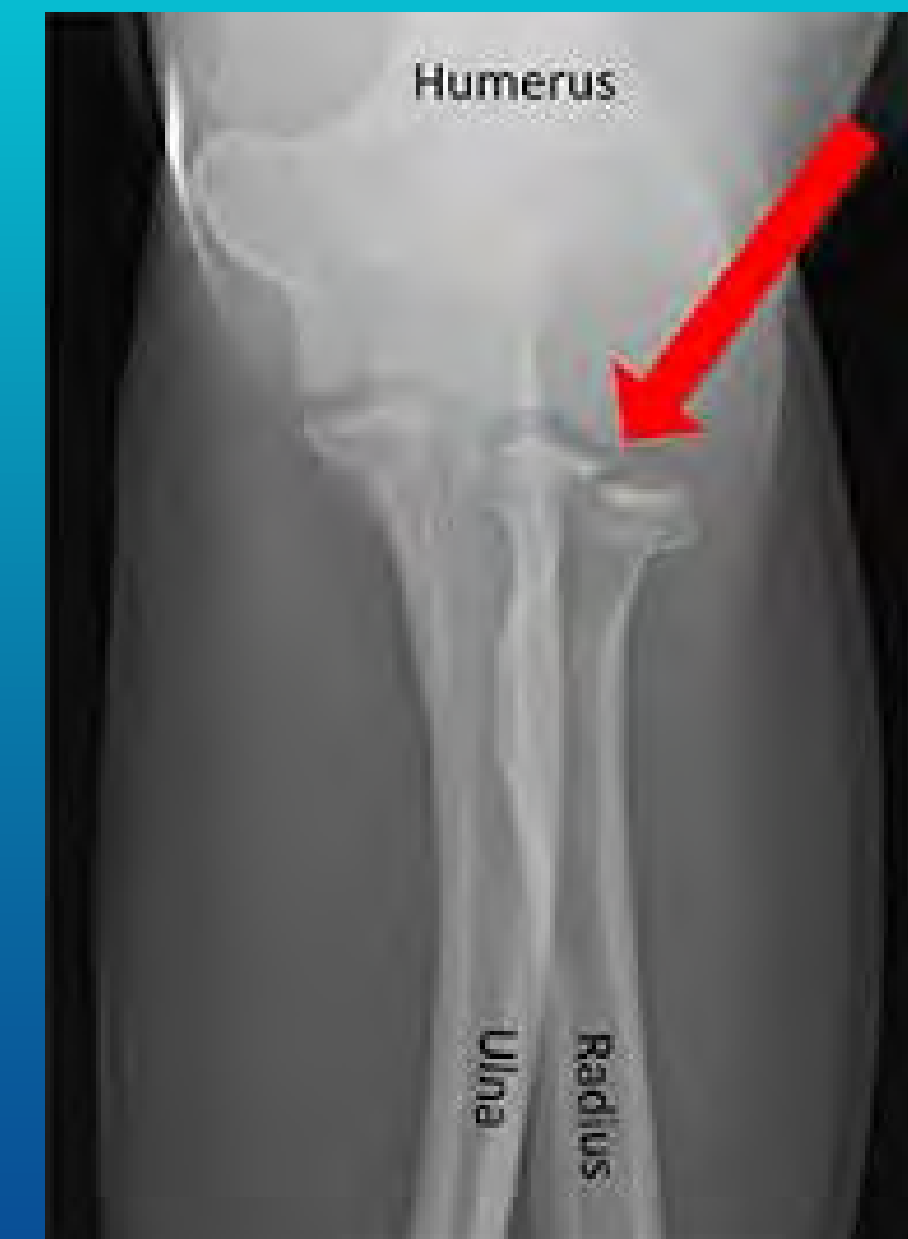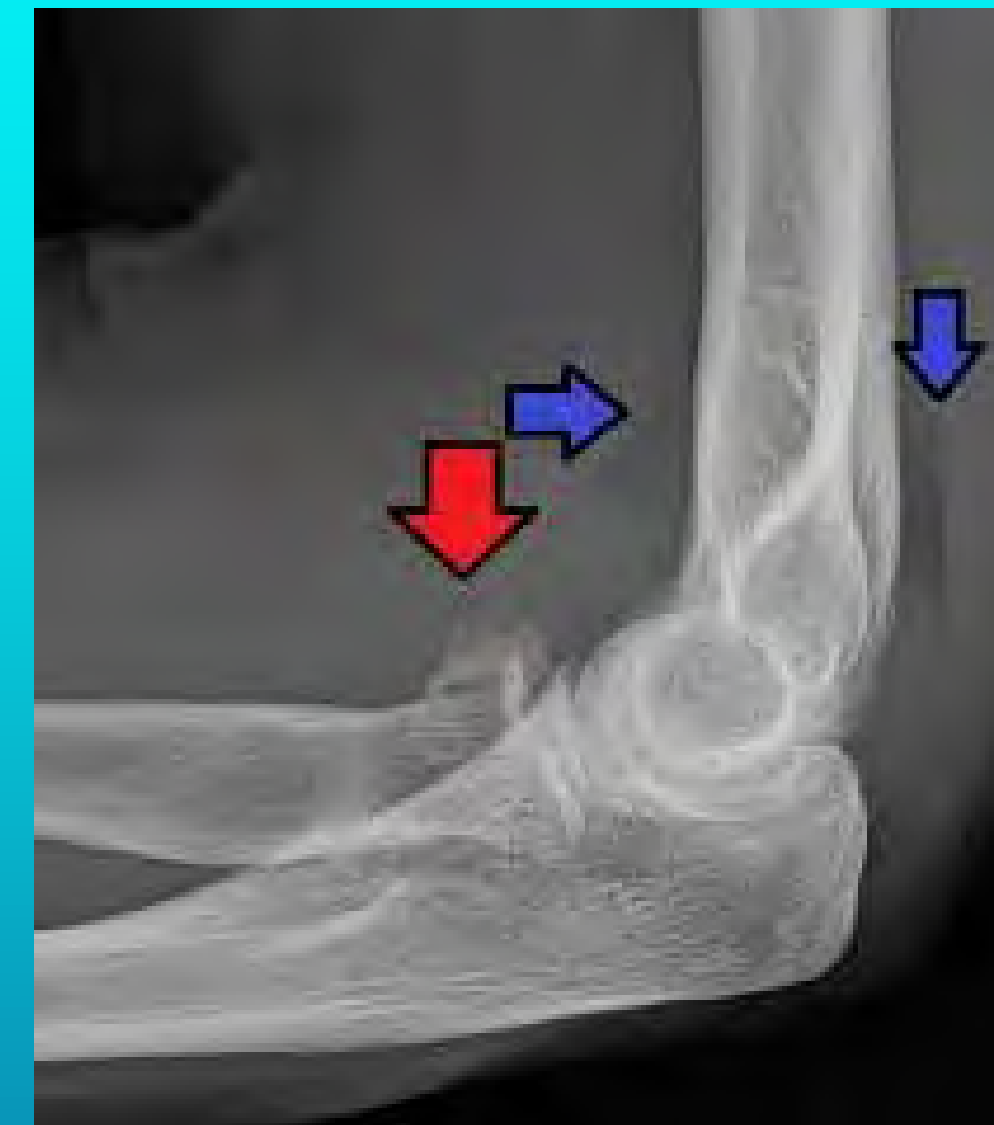Radial Head Fx

Epidemiology

- Most common elbow fx
- Injury mechanism- FOOSH, elbow extended & forearm pronated
- **35% assoc. injuries**
 - LCL sprain (80%)
 - Essex-Lopresti injury
 - Fx Coronoid/Olecranon- **ELBOW DISLOCATION**

Exam

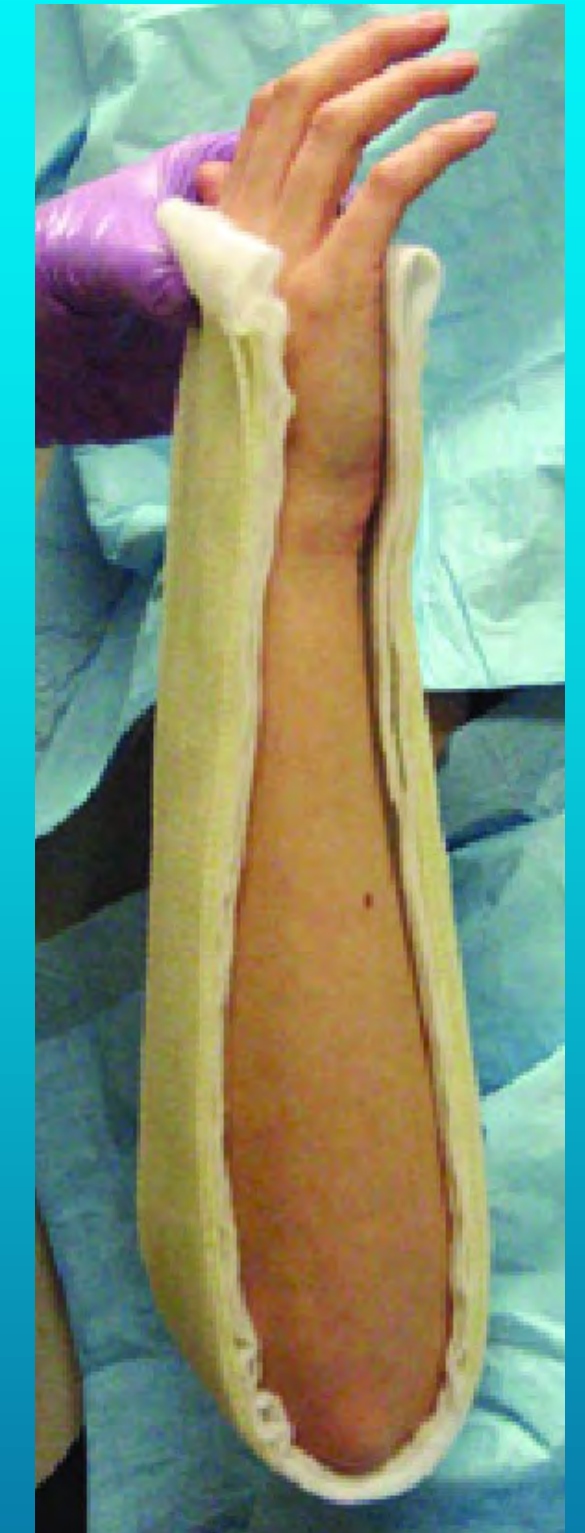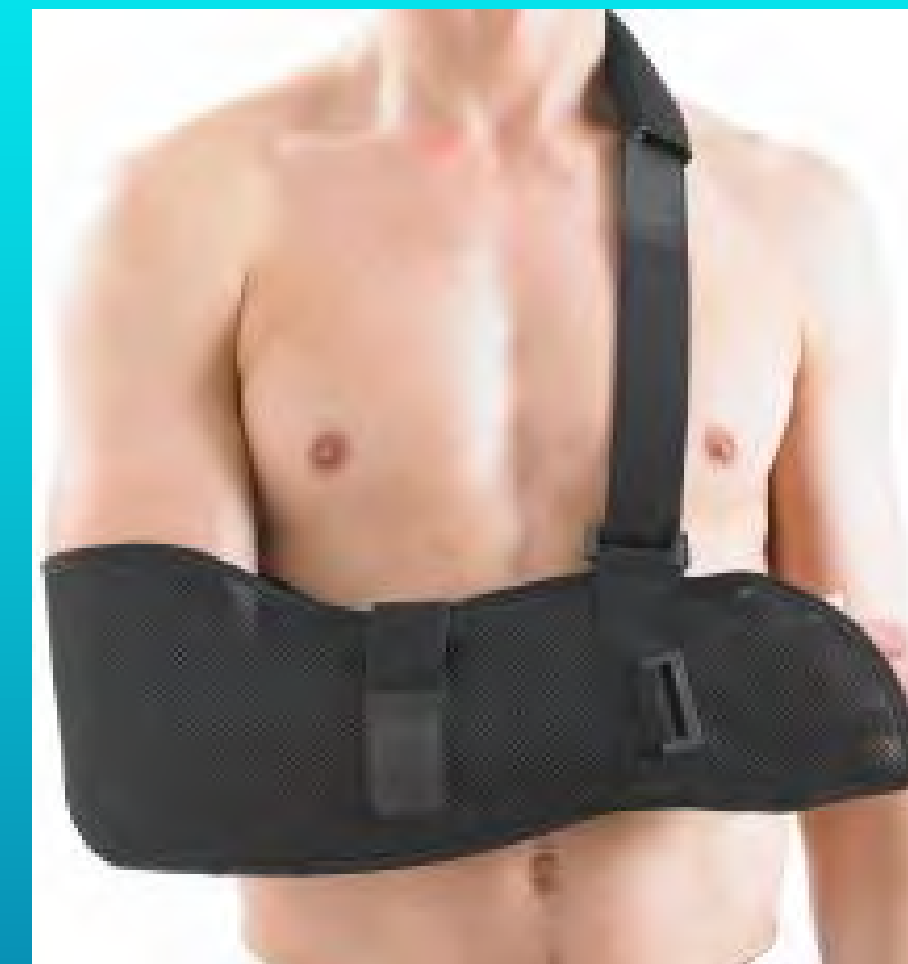- Swollen & tender lateral elbow
- Pain with Pronation/Supination



Radial Head Fracture

Treatment

- Sling vs Sugar-tong splint
 - **Sling - low demand patient/ elderly**
 - **Sugar-ting – High demand**
 - **Athletes, laborers, non-compliant, failed sling**
 - **Sugar-tong gets a sling**
 - Pain management
 - Limit Activity
 - Follow up 1 week
 - May begin ROM exercises
 - Will need serial x-rays till healed
-
- **All displaced comminuted Fx will require surgical stabilization or Radial head replacement**



Olecranon Fx

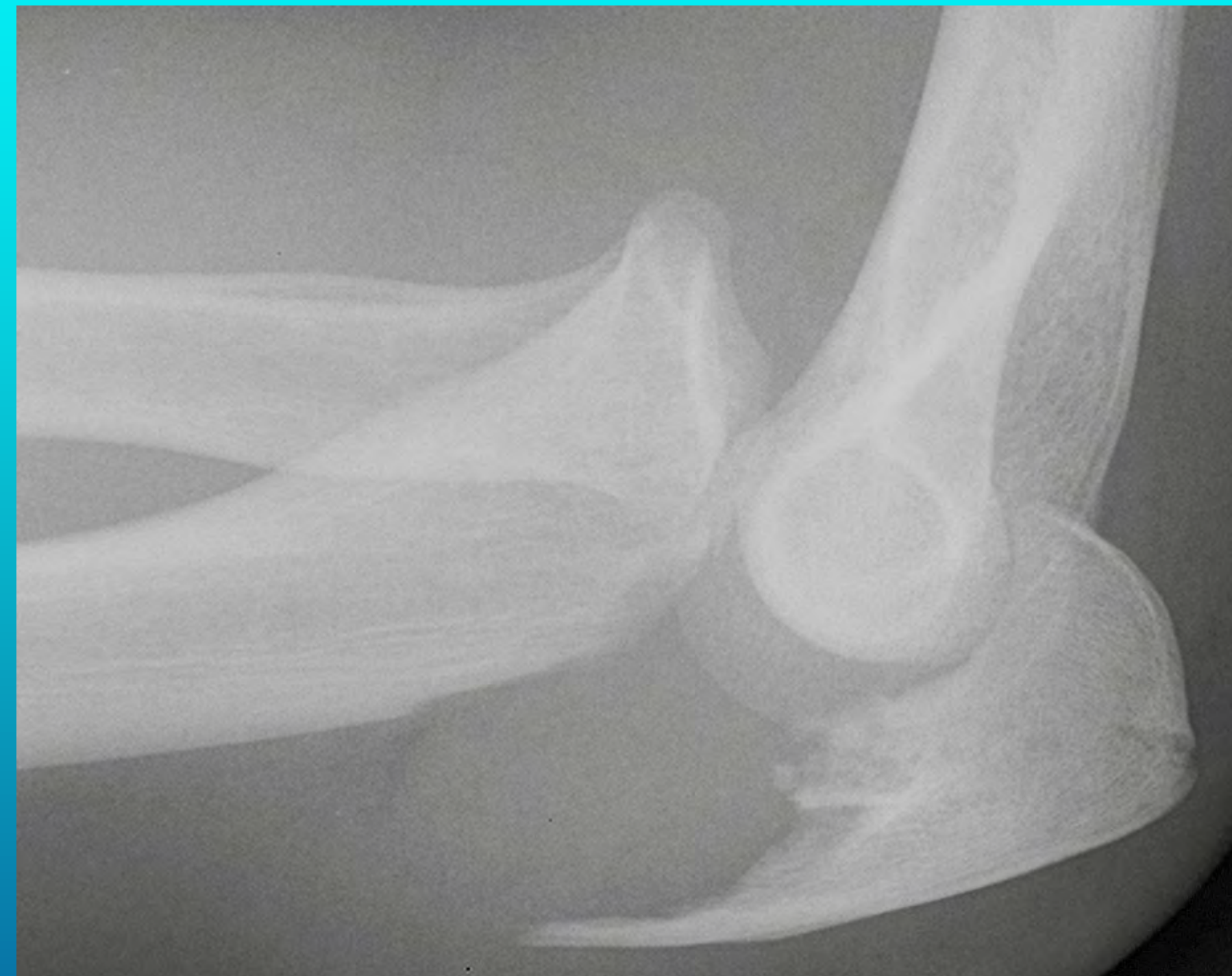Olecranon Fx

Epidemiology

- **Bimodal injury distribution**
 - Young- High energy
 - Elderly fall standing height
- Injury mechanism-
 - Direct blow leads to comminuted fx
 - FOOSHE Transverse fx
- **35% assoc. injuries**
 - LCL sprain (80%)
 - Essex-Lopresti injury
 - Fx Coronoid/Olecranon

Exam

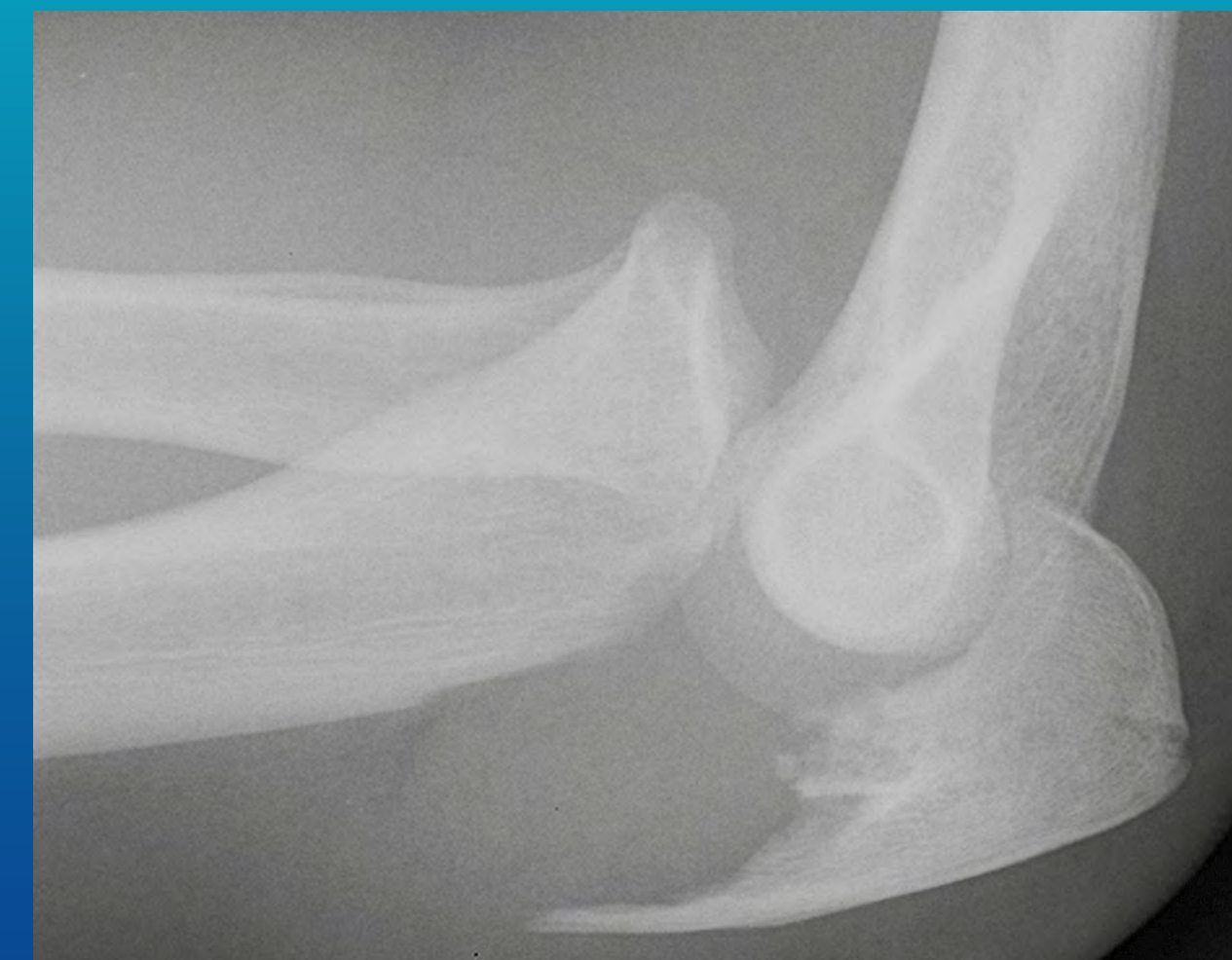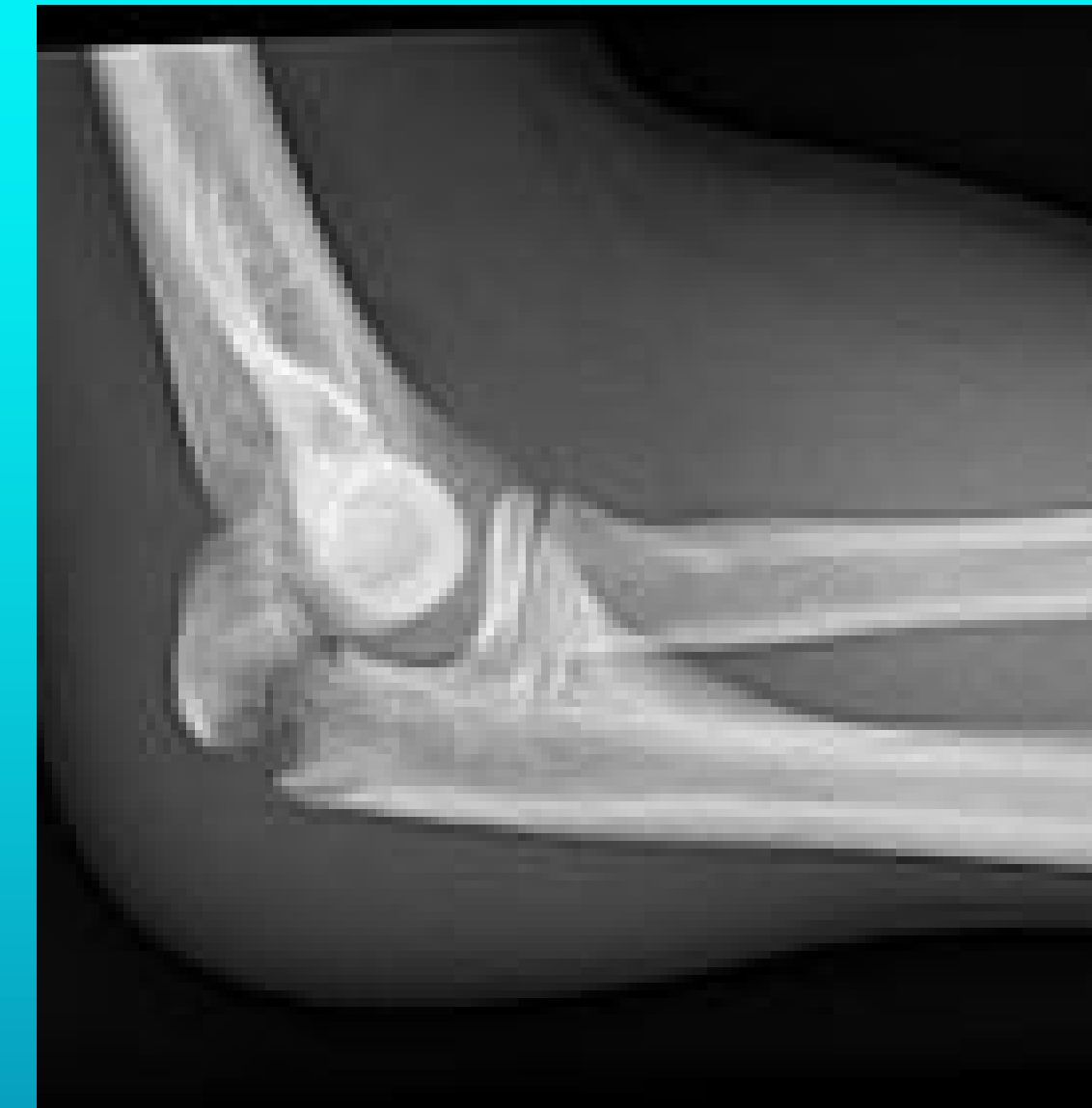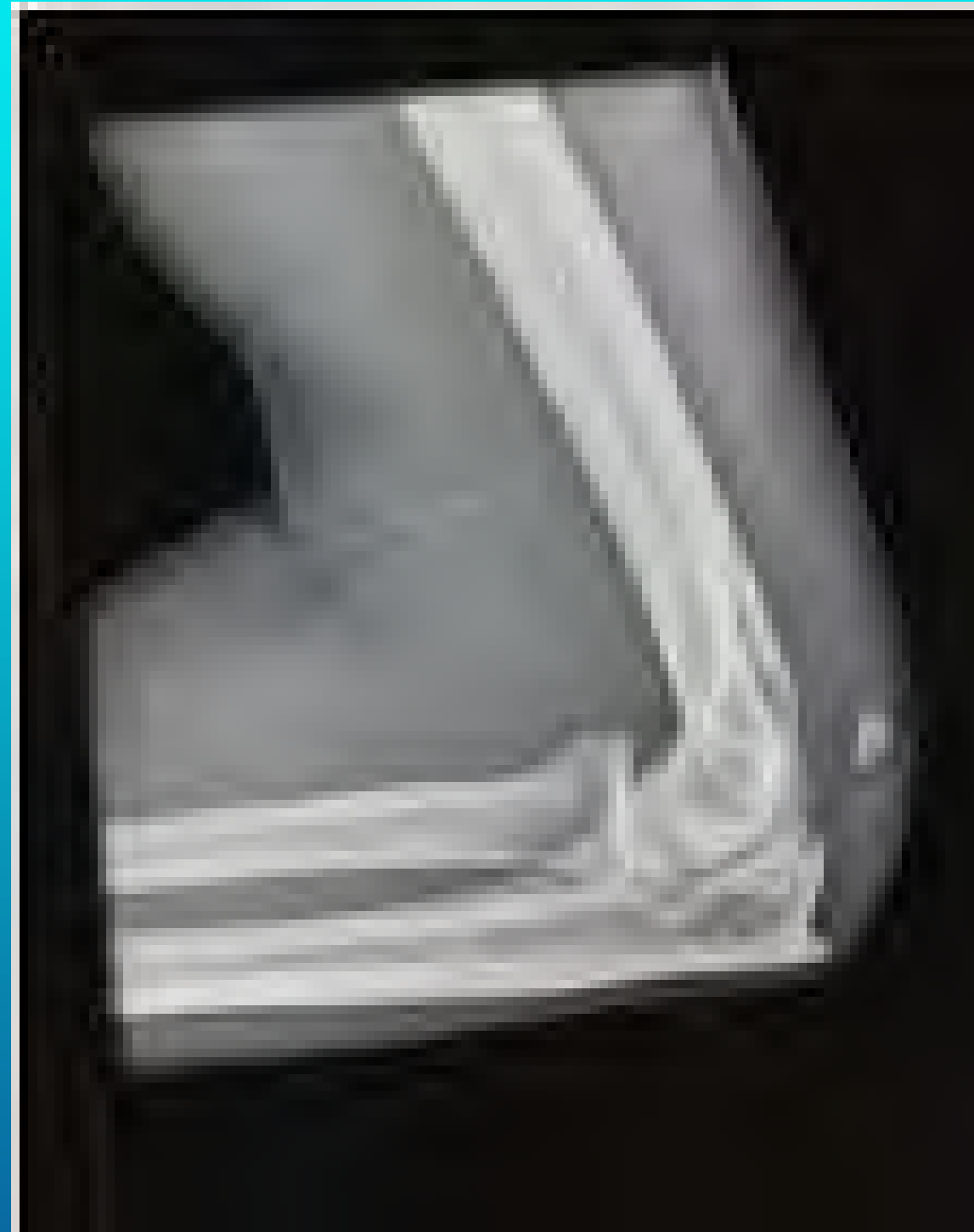- Swollen & tender lateral elbow
- Pain with Pronation/Supination



Olecranon Fx

Radiographs

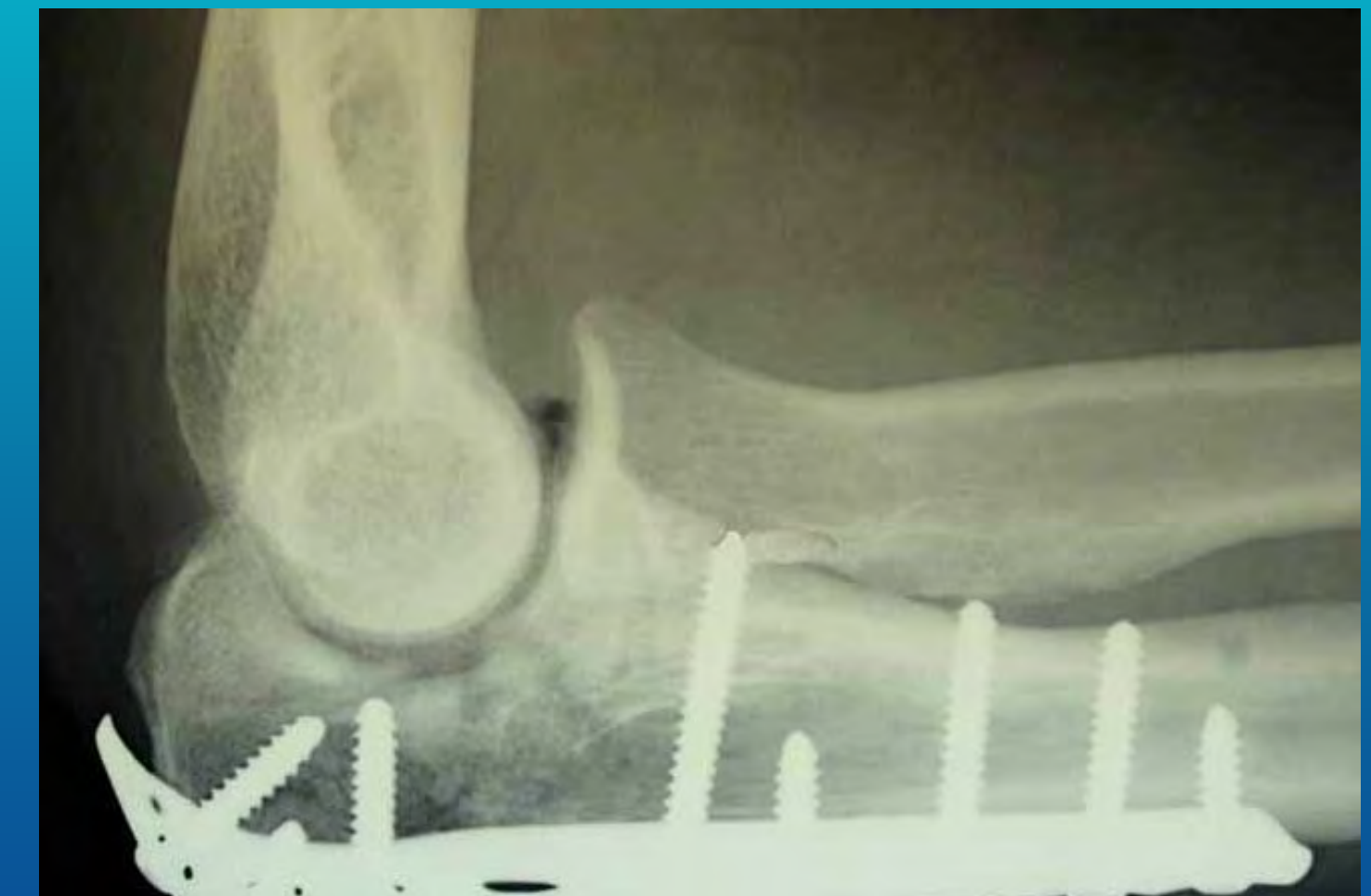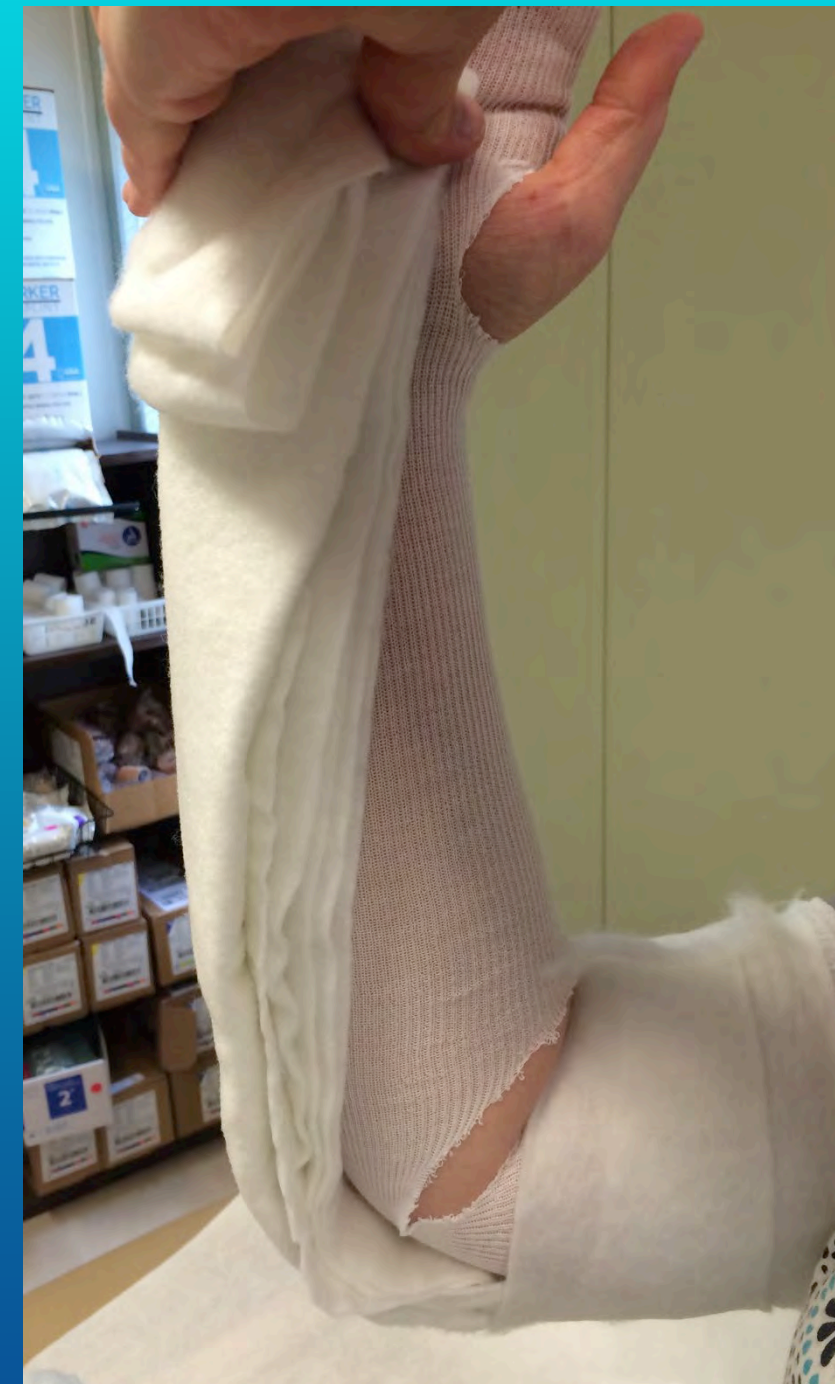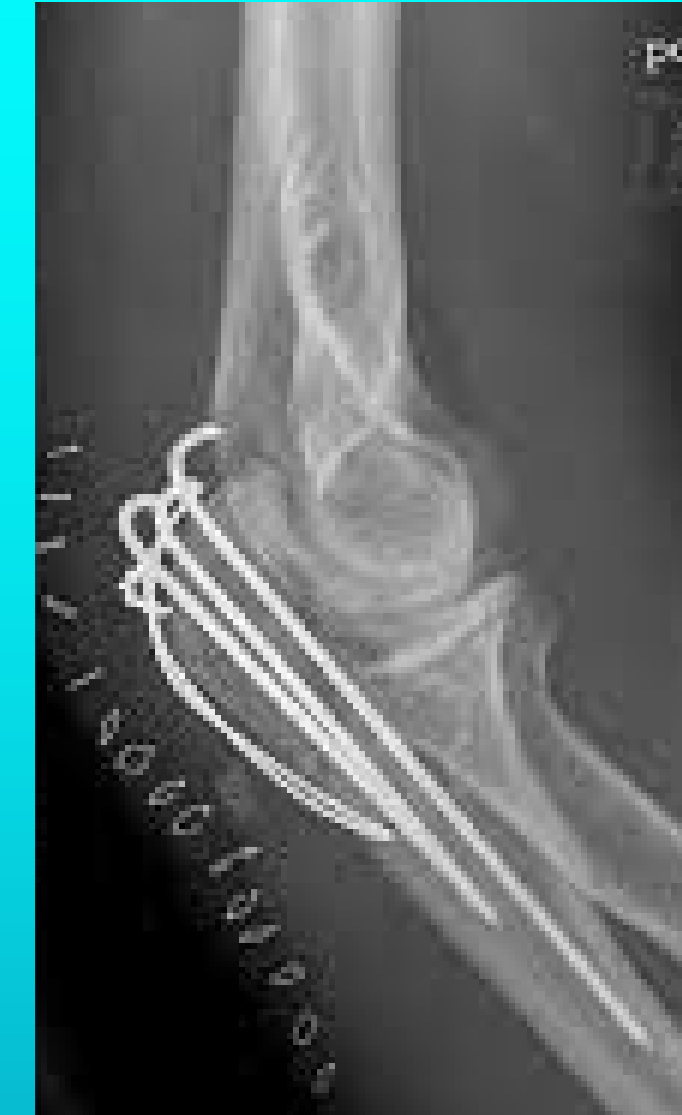- AP, & Lateral Elbow
- Fracture pattern
 - Avulsion
 - Transverse
 - Oblique
- CT Scan
- Exam
 - Limited Elbow Flex\Ext ROM
 - Palpable defect olecranon
 - Skin lesion



Olecranon Fx

Treatment

- **Most Olecranon fx will need surgical stabilization**
 - Stabilization allows for earlier ROM
- **Immobilize in Long-arm posterior splint**
 - Elbow flexed to 45-90°
- **Sling**
- Pain management
- Follow up 1 week



Forearm Fx

Forearm Fractures

Etiology

- Injury Mechanism:
 - **Direct blow**- High energy vs. ground fall
 - **FOOSH w/ pronated hand/forearm** =- axial load
 - Car accident
 - **Gunshot wounds/Farm-Industrial**
 - Significant soft-tissue injury
 - Open Fx with **nerve – vascular injury**
 - Refer to Gustilo classification (classification of open fractures)
- **Delays in surgery lead to increased risk of proximal radioulnar synostosis**

Radius and Ulna Shaft Fractures

- Symptoms
 - gross deformity, pain, swelling
 - loss of forearm and hand function
- Physical exam
 - Check forearm compartments
 - High suspicion compartment syndrome
 - Pain with passive stretch of digits
 - Pain out of proportion
 - Assess radial and ulnar pulses
 - Check Median, Radial, and Ulnar nerve function
- Neurovascular
 - Median nerve: finger flex/Make a fist
 - AIN- “OK” sign (Flexor Pollicis Longus)
 - Radial nerve: Wrist/Finger extension
 - PIN: “Thumbs up” sign (Extensor Pollicis Longus)
 - Ulnar Nerve: Finger ABD/ADD
- Assess elbow & wrist for associated injury

Forearm Fractures

Radiographic Exam

- AP/Lateral/Oblique views
 - **AP & lateral:**
 - Forearm to include wrist and elbow
 - radial head will bisect Capitellum
 - good radiocapitellar apposition on alignment
 - **Look at alignment of distal ulna - lateral**
 - Ulna should bisect base of 4th and 5th metacarpal
 - Radius & ulna should be aligned same plane

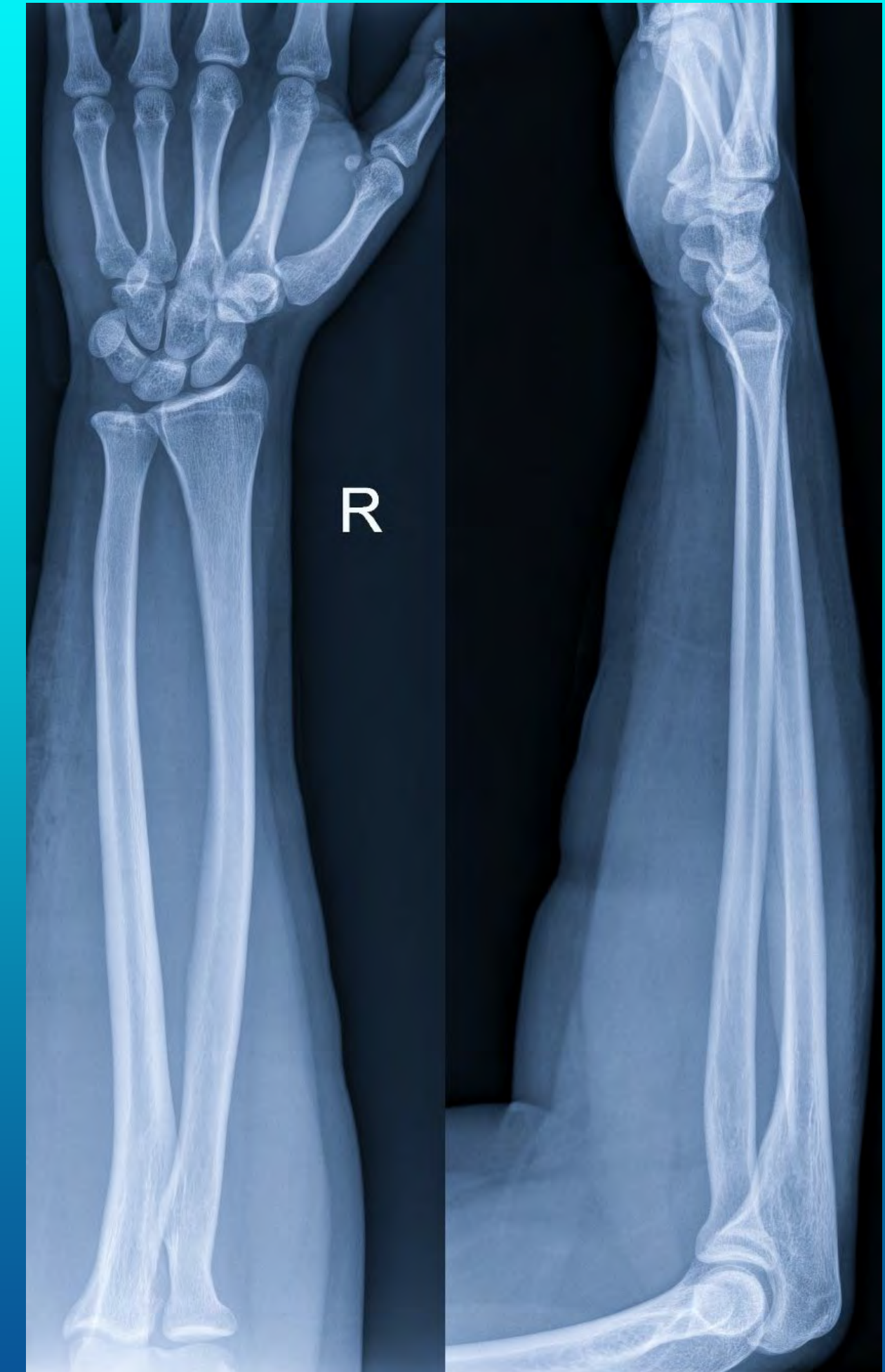
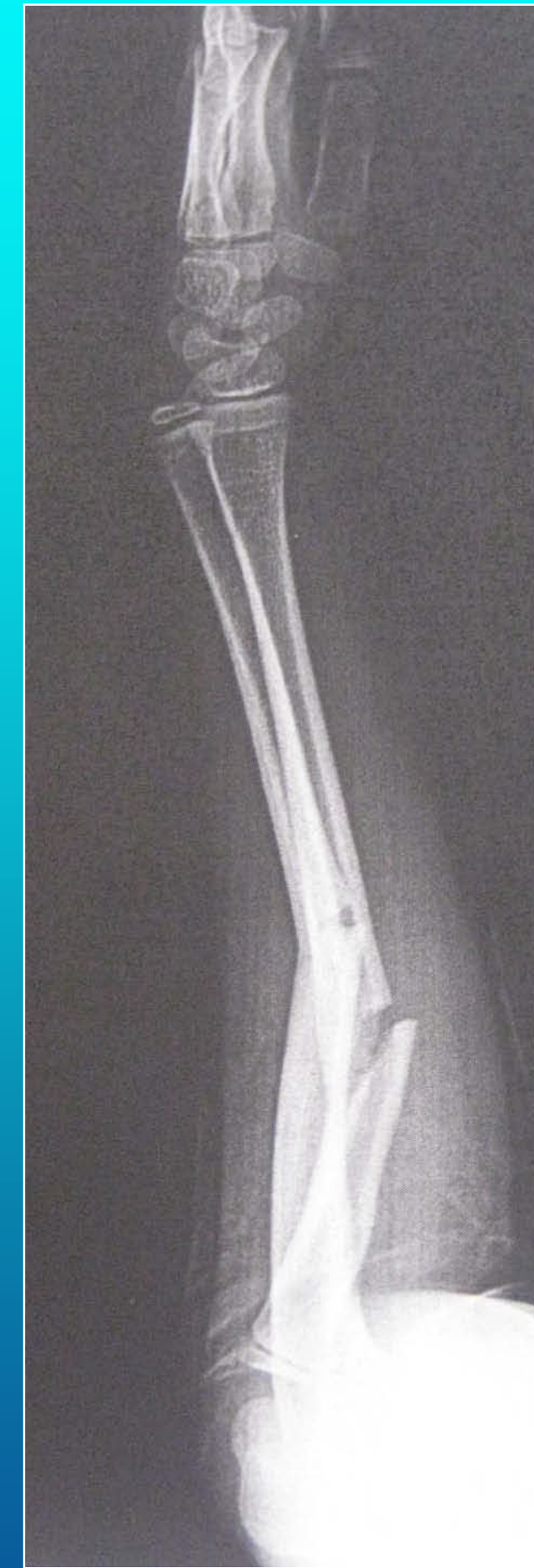
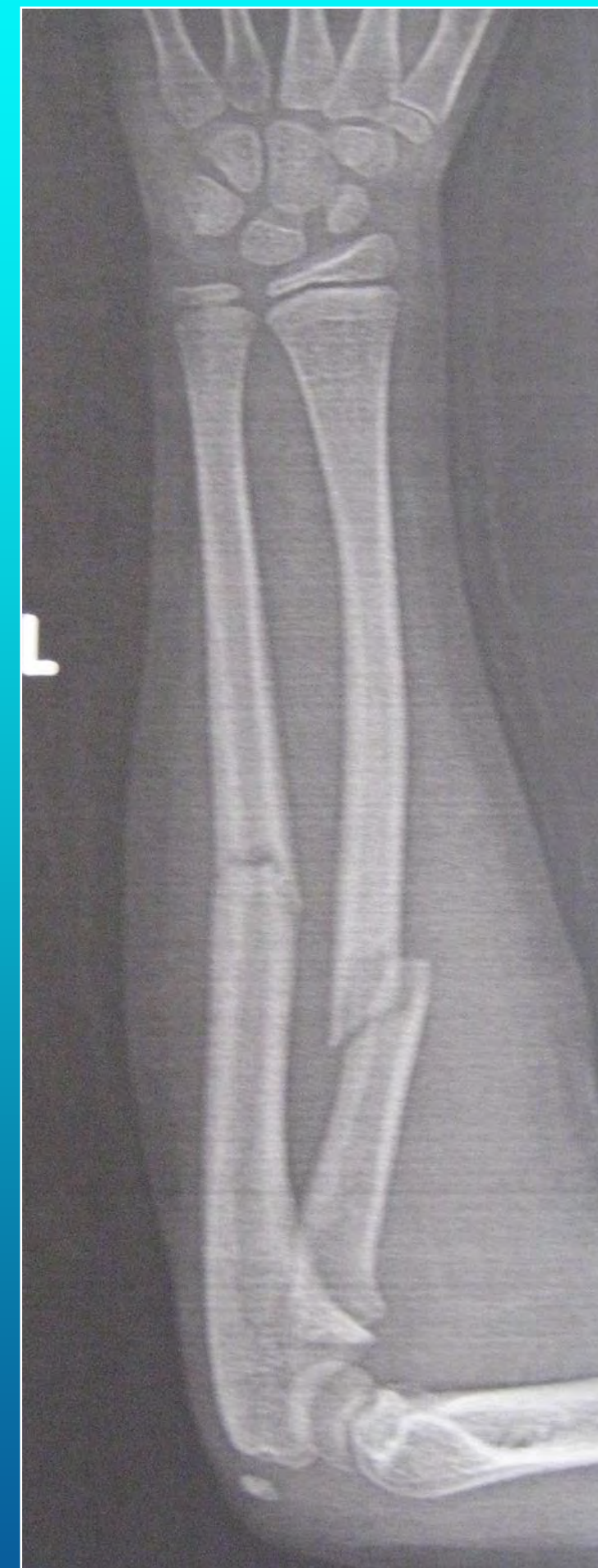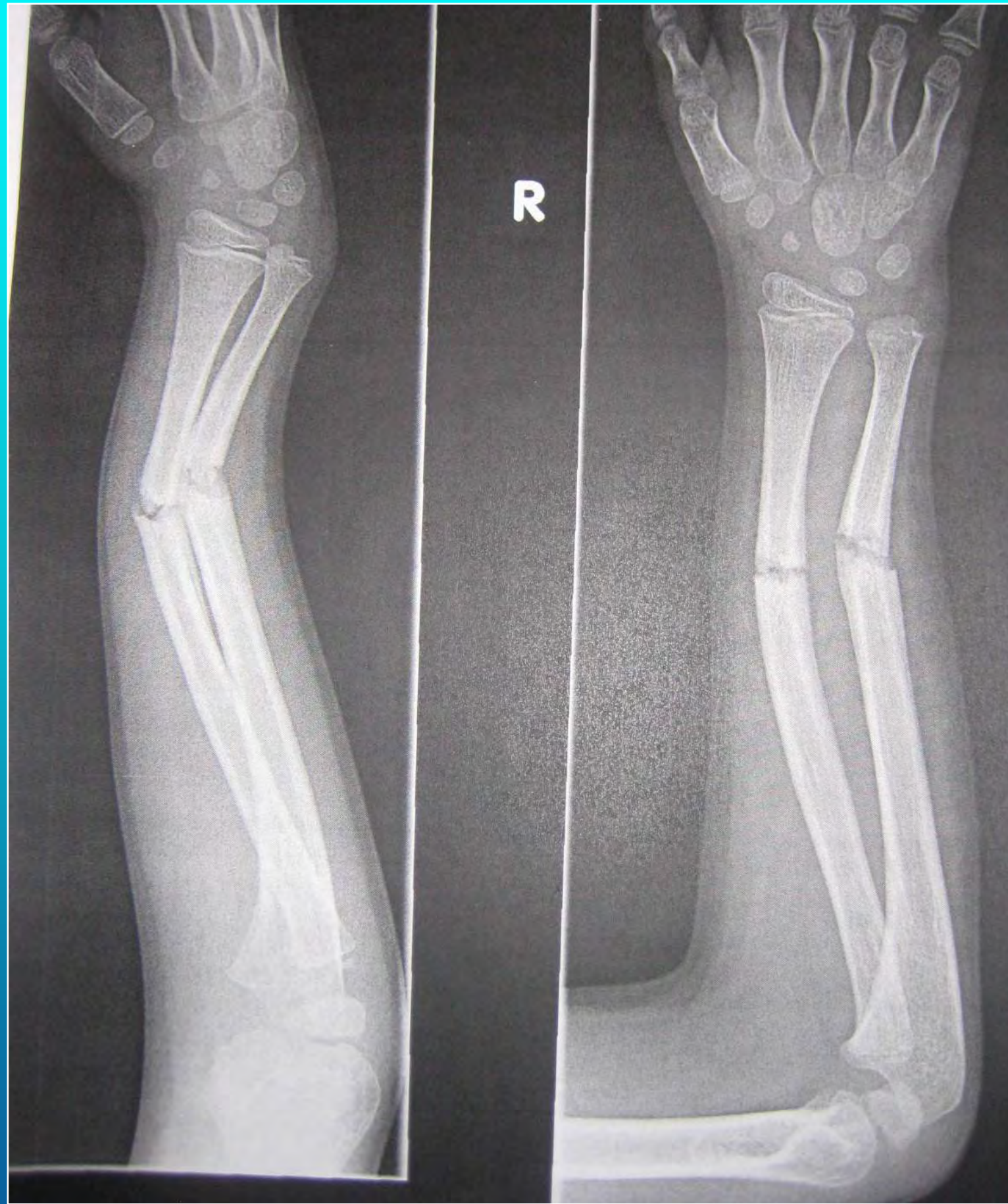Photo courtesy TGoetze, PA-C

Radius & Ulna Shaft Fx



Radius and Ulna Shaft Fractures

Treatment – **ADULTS**

- **Sugar-tong splint & Sling**
- **Pain management**
- **Follow up 1 week**
- Operative – Open Reduction Internal Fixation (ORIF)
 - Displaced distal ulna & Proximal ulna fxs
 - **ALL** radial shaft fxs
 - **ALL** both bone fxs
 - **ALL** open fractures
 - Segmental bone loss
 - Comminuted fx >1/3 length of shaft
 - Forearm nonunion
- Most important structure to restore: radial bow
- External Fixation – temporary/open wounds

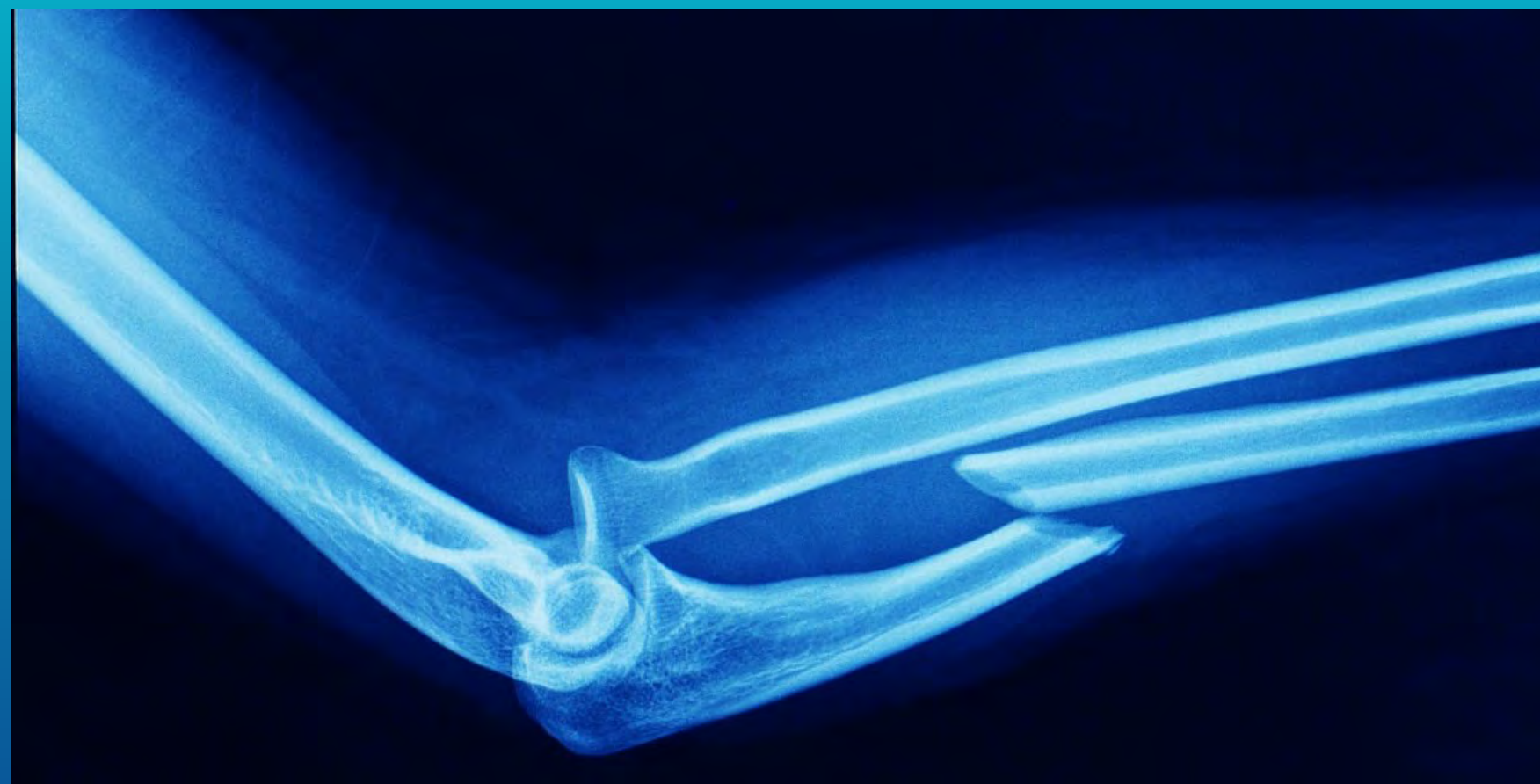Monteggia Fx & Gaeleazzi Fx

Monteggia & Galeazzi Fx – MU-GR

Monteggia FX

MU-Gr

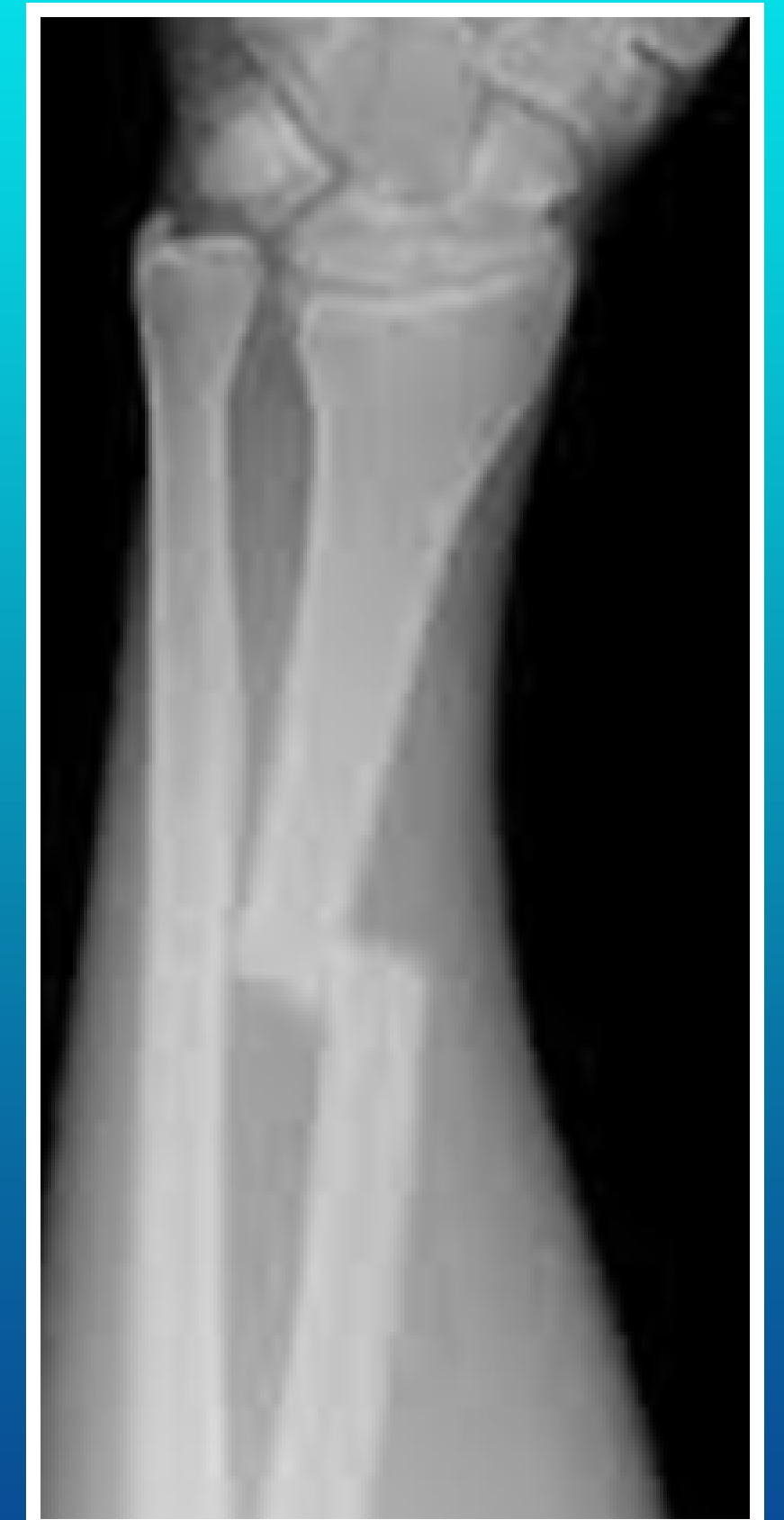- Ulna Fx with Radial head injury
 - Radial head FX
 - Radial head Dislocation



Galeazzi Fx

Mu-GR

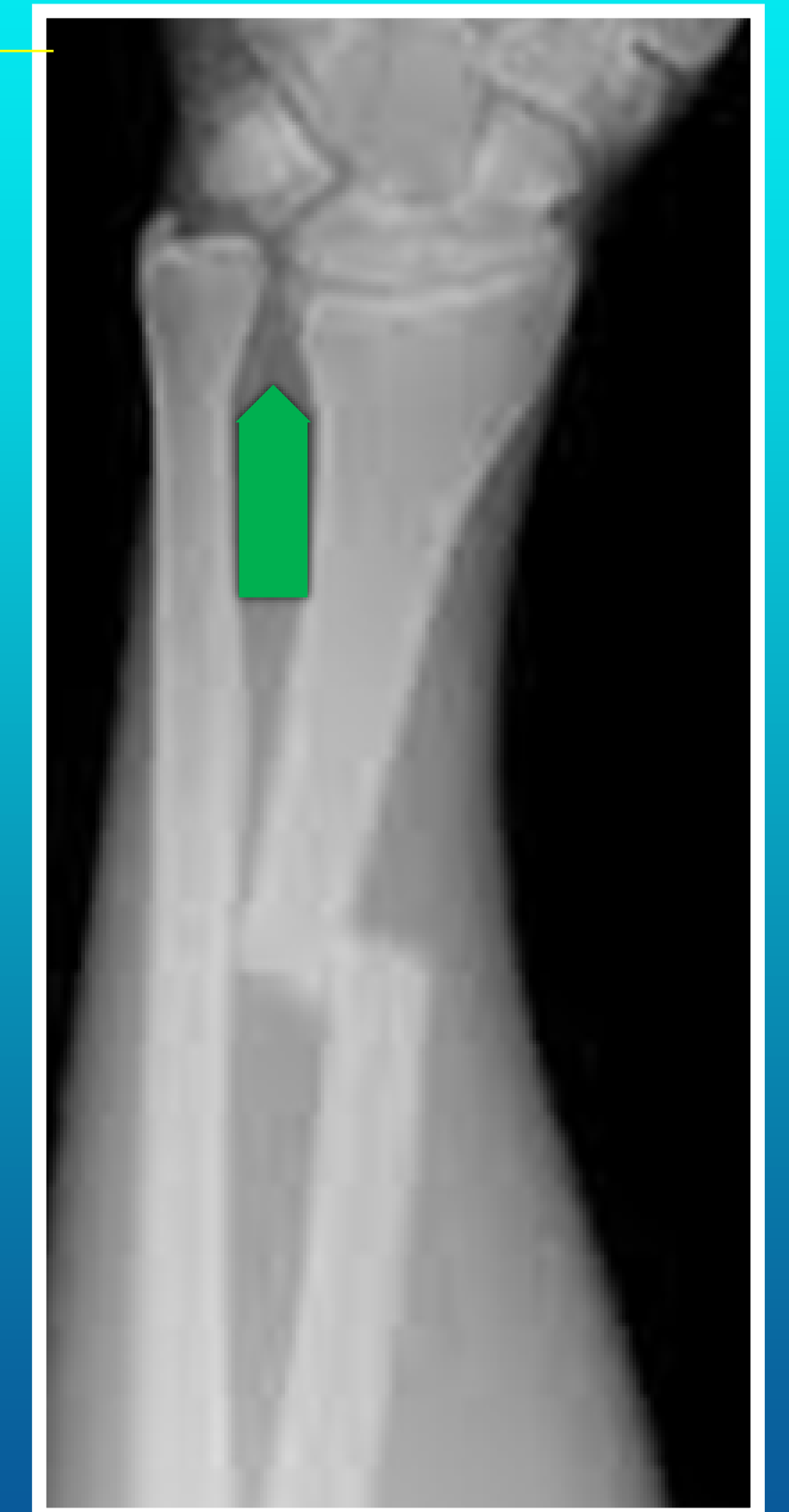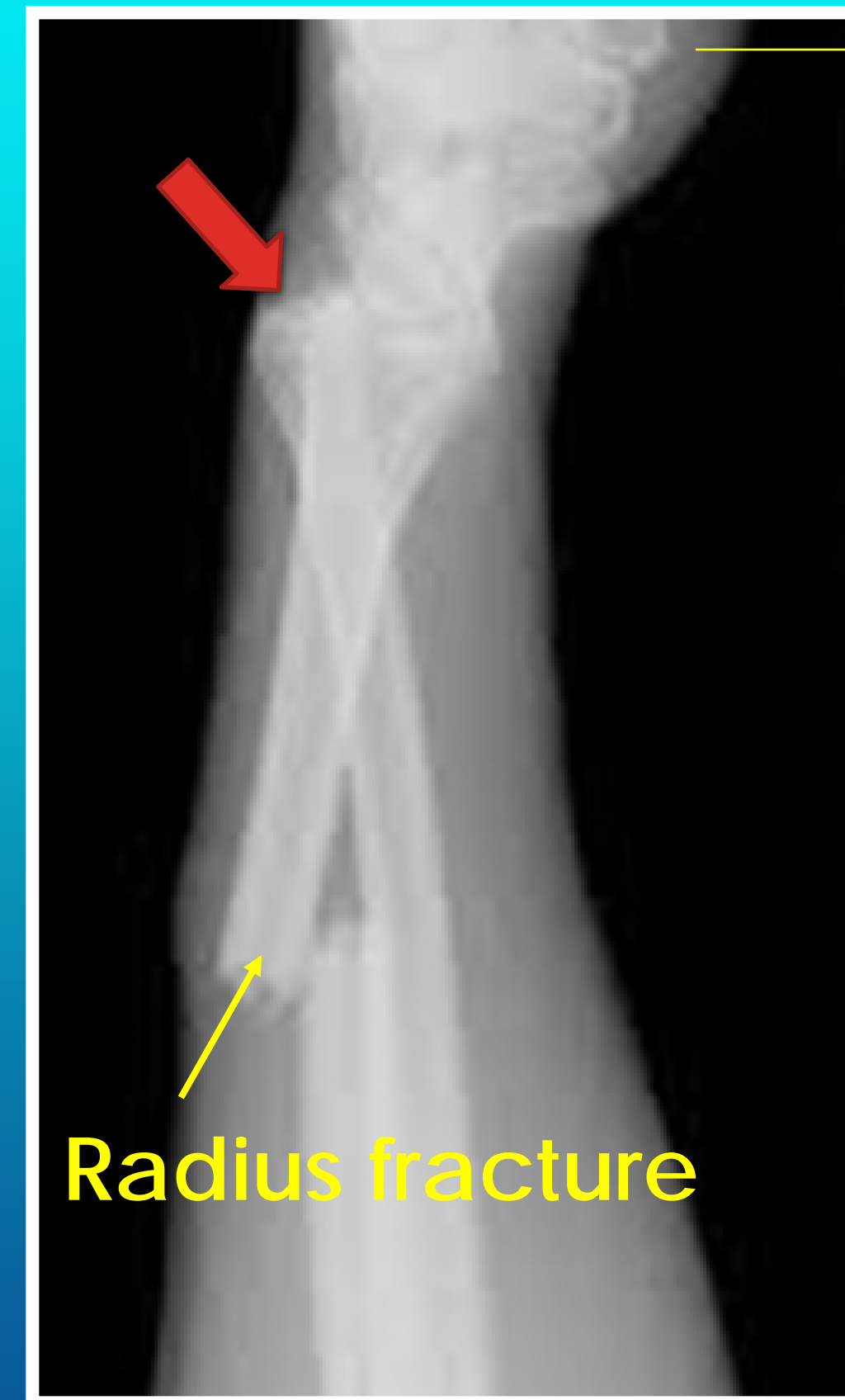- Radius Fx
- DRUJ instability/Injury



GALEAZZI FRACTURES

Dorsal displacement - ulna

- Galeazzi Fracture
 - Radius fracture and DRUJ injury
 - Ulnar styloid fx
 - widening of DRUJ on AP view
 - dorsal or volar displacement ulna
 - Best seen lateral view
 - radial shortening ($\geq 5\text{mm}$)



Monteggia Fracture

Monteggia Fracture

- Defined as: Proximal 1/3 ulnar fracture with associated radial head dislocation

Etiology

- More common in children - peak incidence 4-10yo
- Rare in adults
- Delayed diagnosis >2-3 weeks = increased risk complication

Injury Mechanism

- Fall with blow to forearm, Elbow /forearm Hyperpronated
- Energy transmitted thru Interosseous ligament
- Causes rupture of proximal Quadratus & Annular Ligament

Monteggia Fracture

Radial Head dislocation

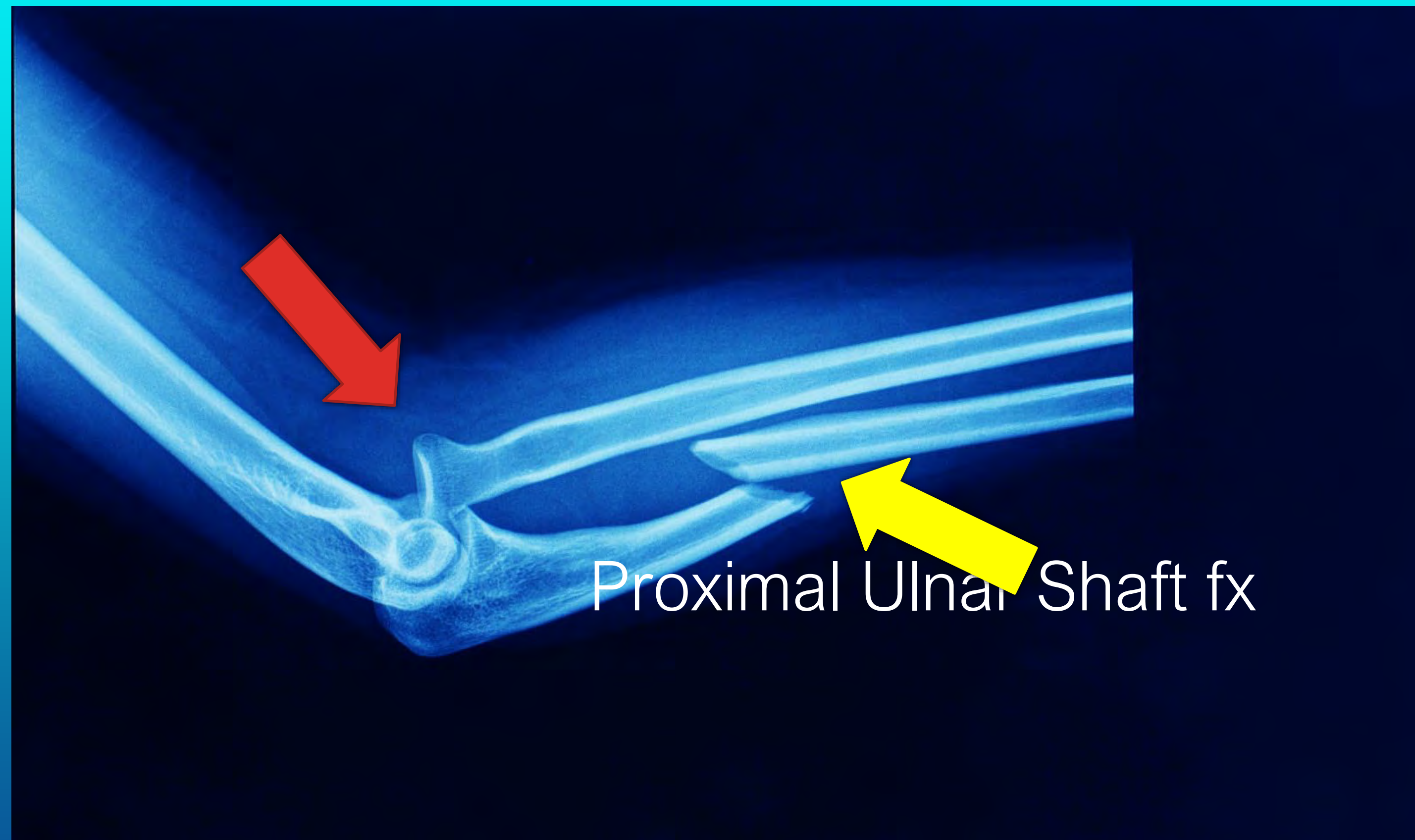


Photo courtesy TGocke, PA-C

Distal Radius Fx

Distal radius fractures

Epidemiology

- Distal Radius (DR) [& Ulna] fx account for 25% all UE fx
- Bimodal distribution: younger males and older females
 - Kids < 18: Peak 12-14 yrs boys, 10-12 old girls
 - Decreased level skeletal mineralization & density w/ puberty
 - Adults > 50: Peak Caucasians > 65 yrs old
 - Osteoporosis common risk factor
 - Prior fx > age 50
 - Steroid use
 - > 75 yrs old w/ dementia
 - Intra-articular fx more common in females w/ DM
- Contributing Factors: Obesity, osteoporosis, DM, Tobacco use

Meaike JJ, Kakar S, management of Comminuted Distal Radius Fractures: A Critical Review, JBJS Reviews 2020;8(8)e20.00010

Porrino JA, Maloney E, Scherer K, et al [Fracture of the Distal Radius: Epidemiology and Premanagement Radiographic Characterization](#), American Journal of Roentgenology 2014 203:3, 551-559

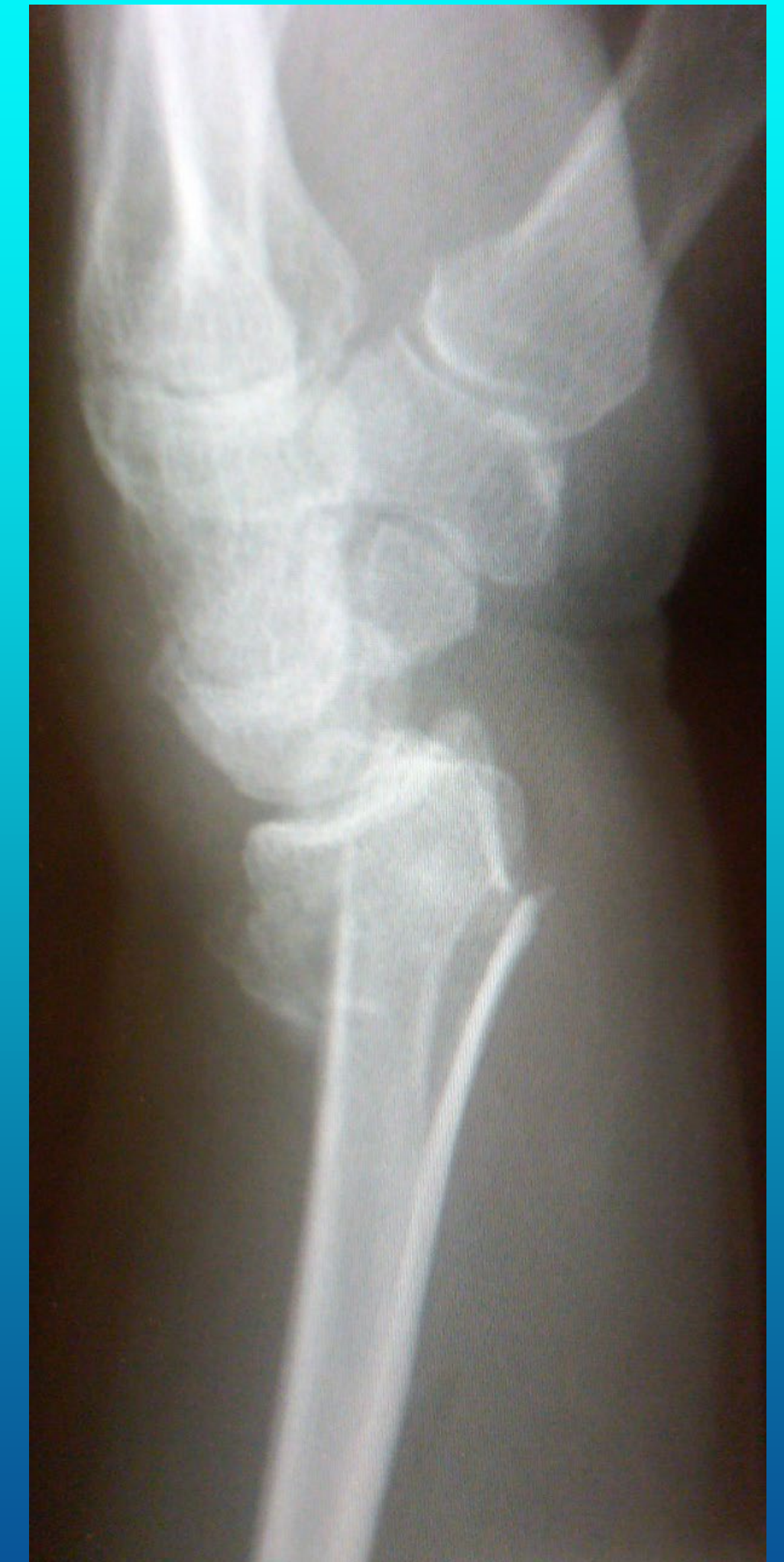Corsino CB, Reeves RA, Sieg RN, Distal Radius Fractures, StatPearls, Treasure Island, FL, StatPearls Publishing Jan 2020

Colles' Fractures

Defined as: distal radius fx, dorsal comminution-angulation-displacement, radial shortening & Ulnar styloid fx

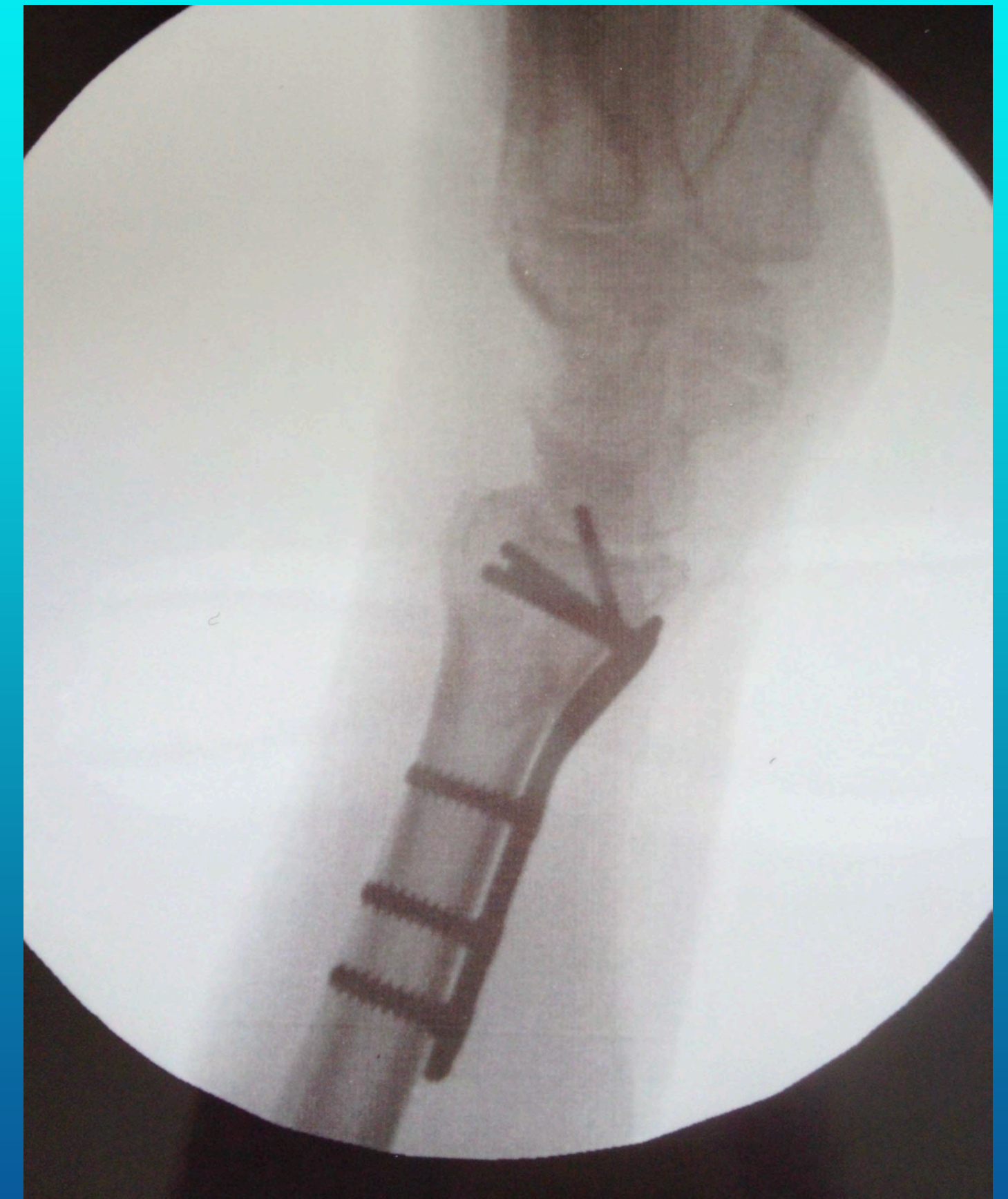
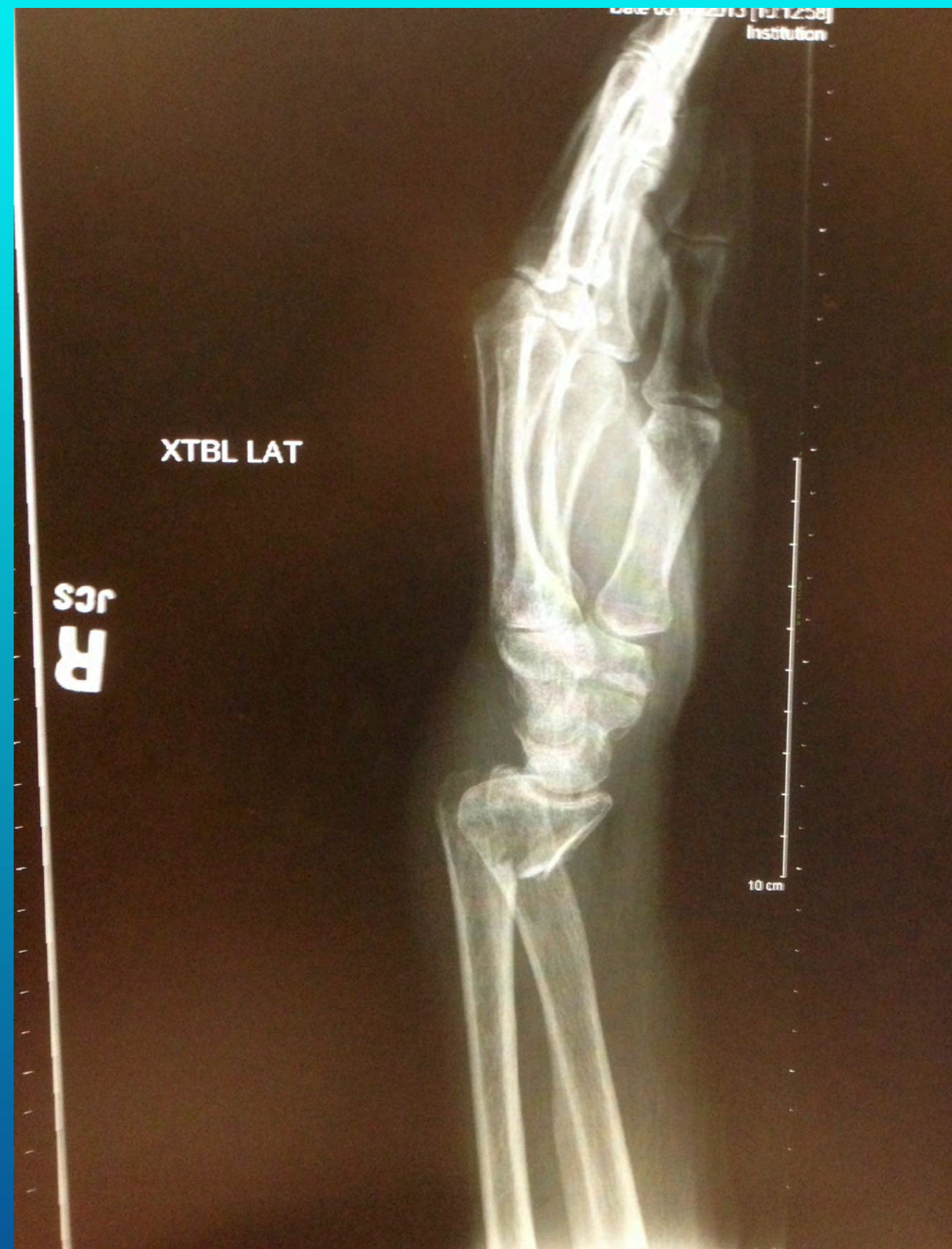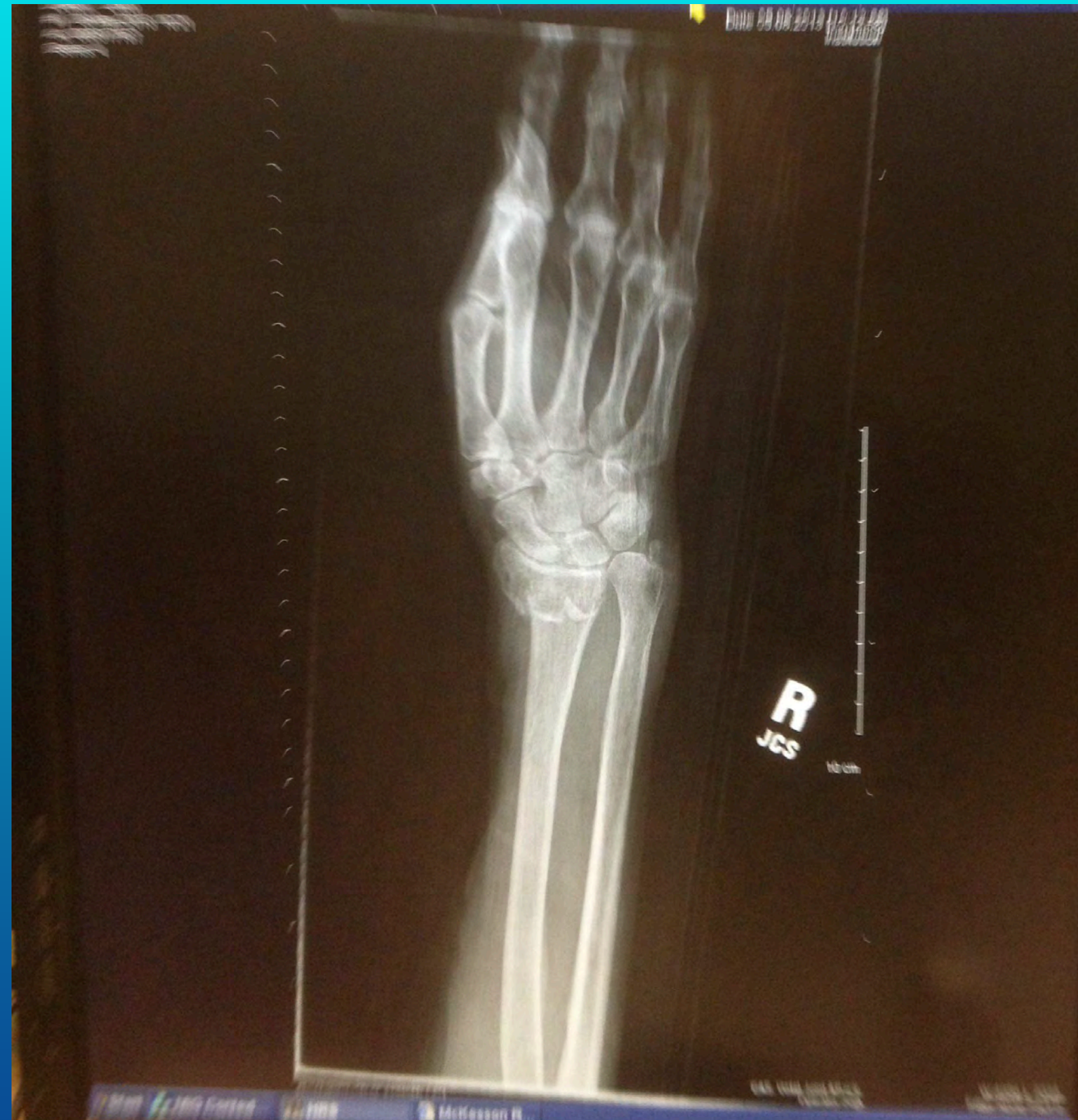- Metaphyseal fx 1.5cm proximal to Carpal articulation
- Typically - non-articular w/ dorsal displacement
 - More severe fx considered with intra-articular comminuted appearance (dorsal)
- Dorsal displacement/angulation principle distal fx fragment
- Young- time of puberty 2nd to lower bone mineralization
 - Higher energy –sports
 - Elderly- Women > men
 - Falls
 - Osteoporosis

Summers K, Fowles SM. Colles' Fracture. 2020 Aug 10. In: StatPearls Treasure Island (FL): StatPearls Publishing; 2020 Jan



X-ray courtesy Tom Gocke, PA-C Library

Colles' Fractures



X-ray courtesy Tom Gocke, PA-C Library

HEMATOMA BLOCK

- Inject Hematoma from dorsal aspect of wrist

- 5ml 1% Lidocaine & 5ml 0.5% Bupivacaine
- 10ml 1% Lidocaine
- Sterile prep & technique

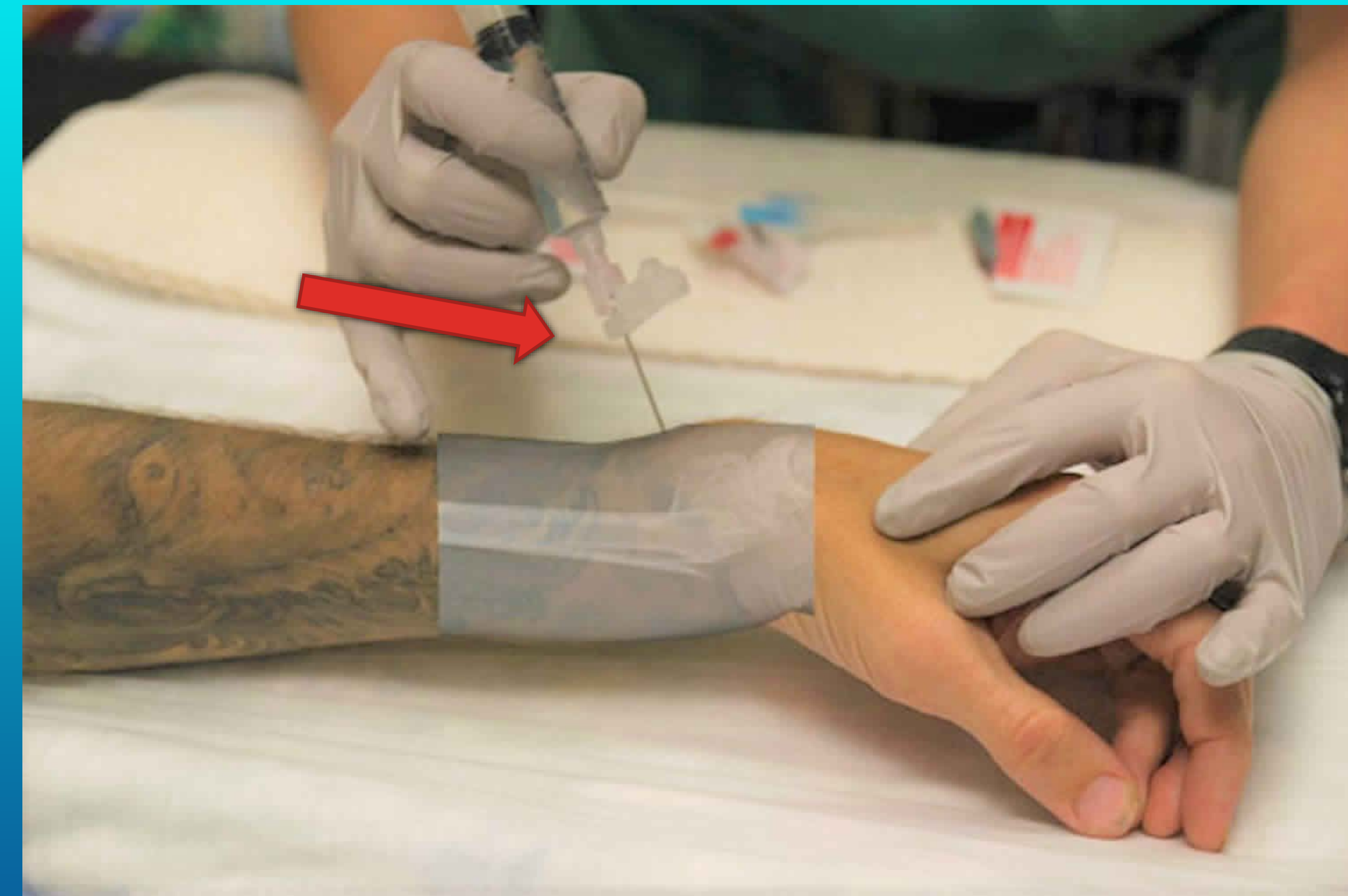- Occ. need few ml's around ulnar styloid too

- No monitoring required

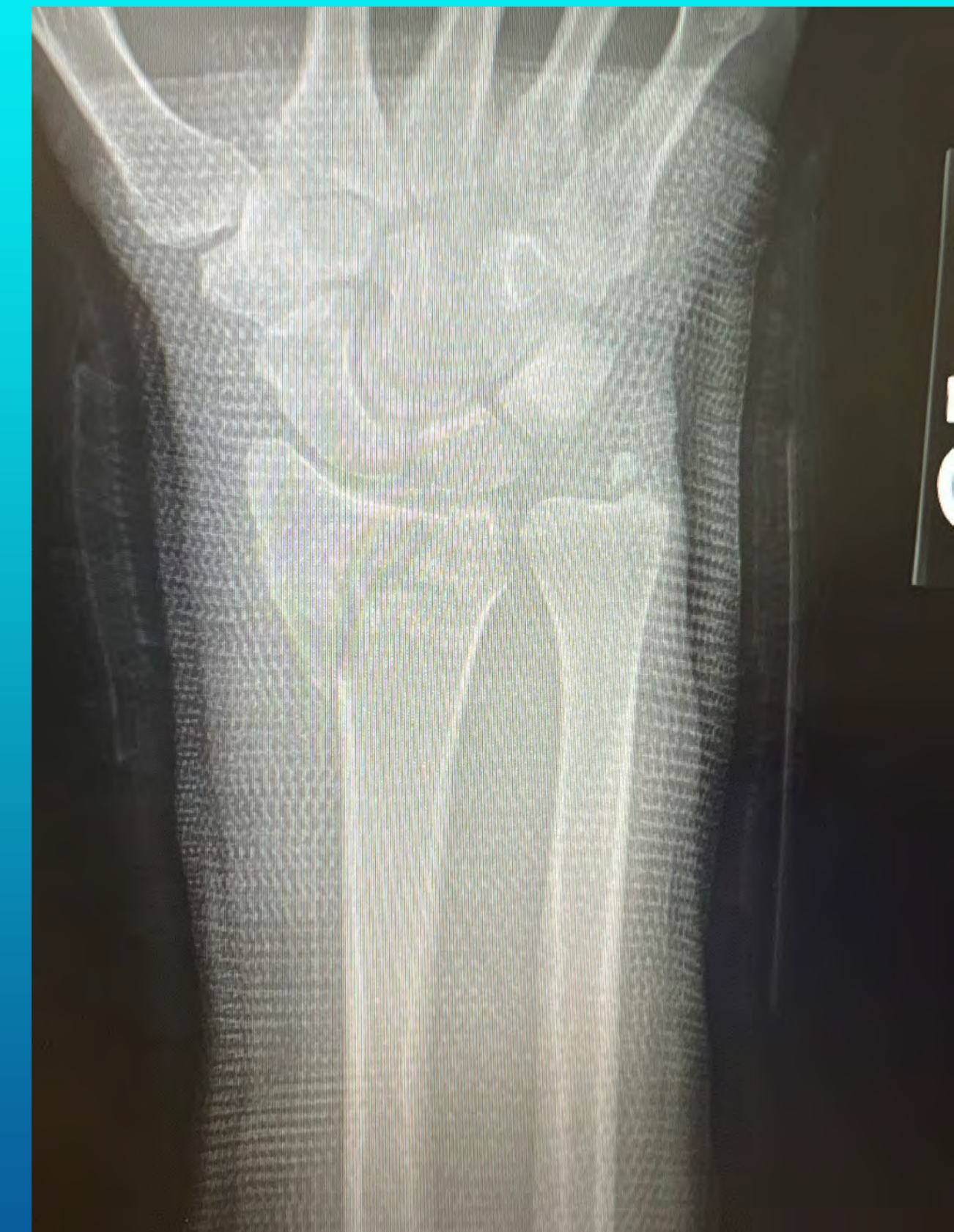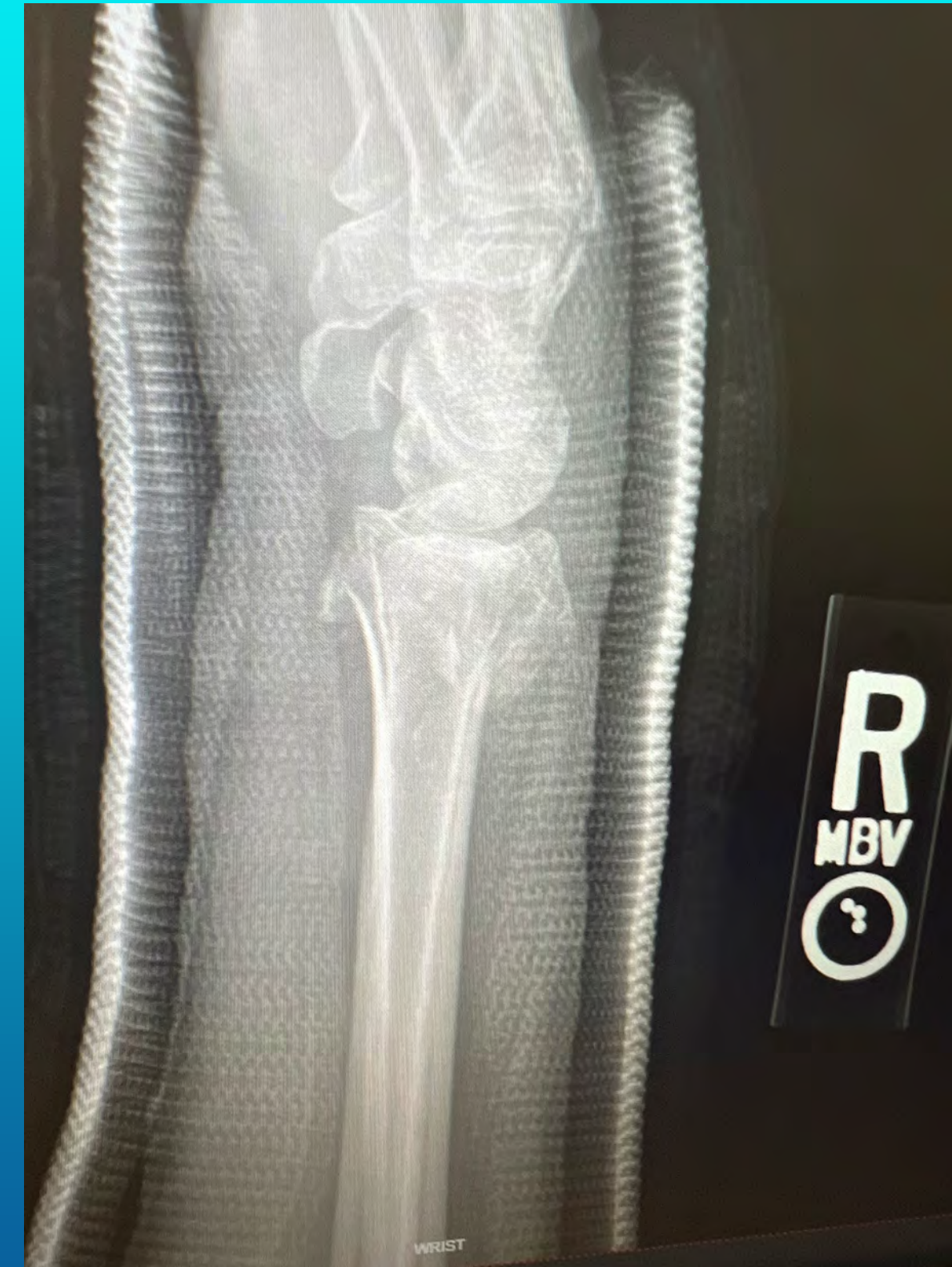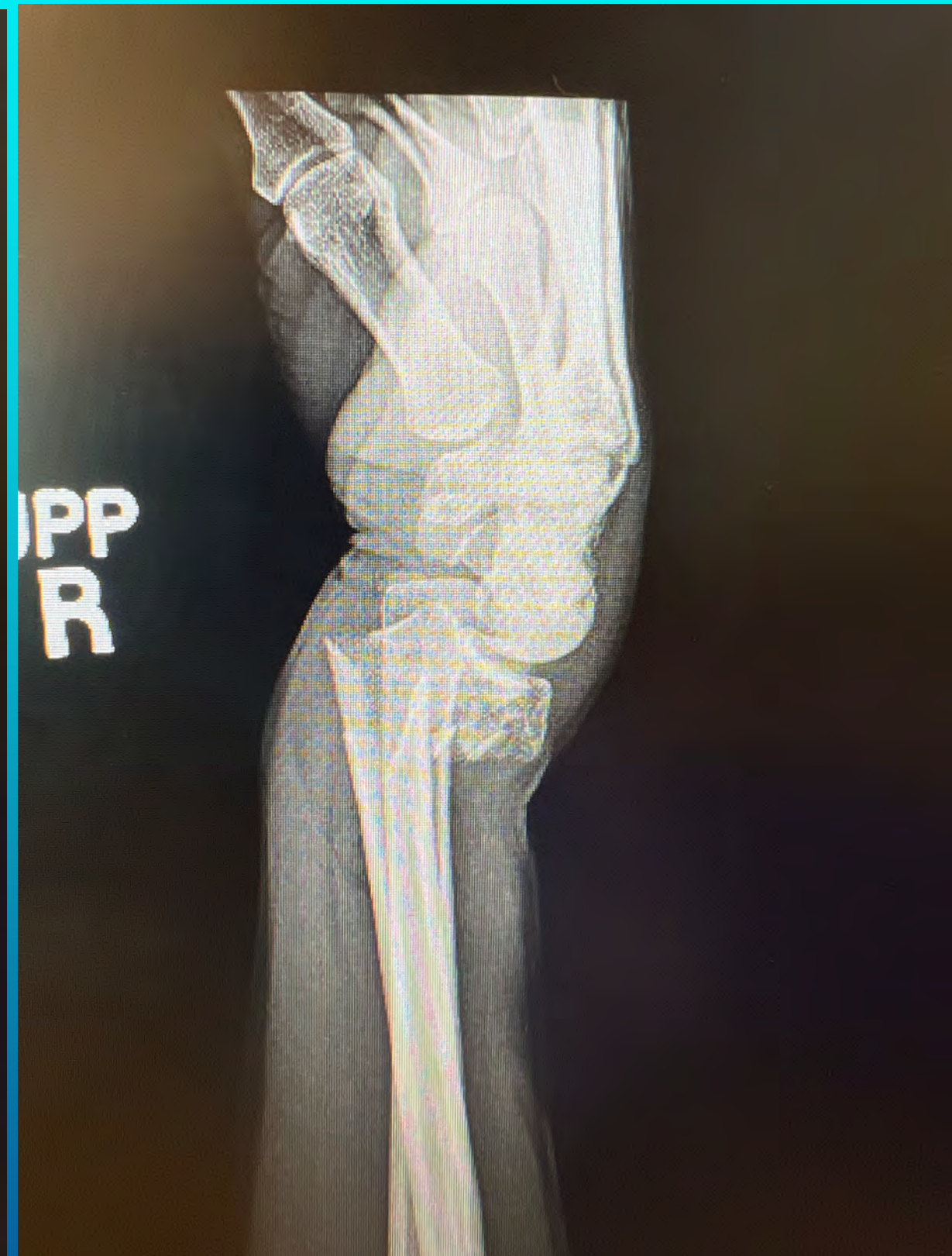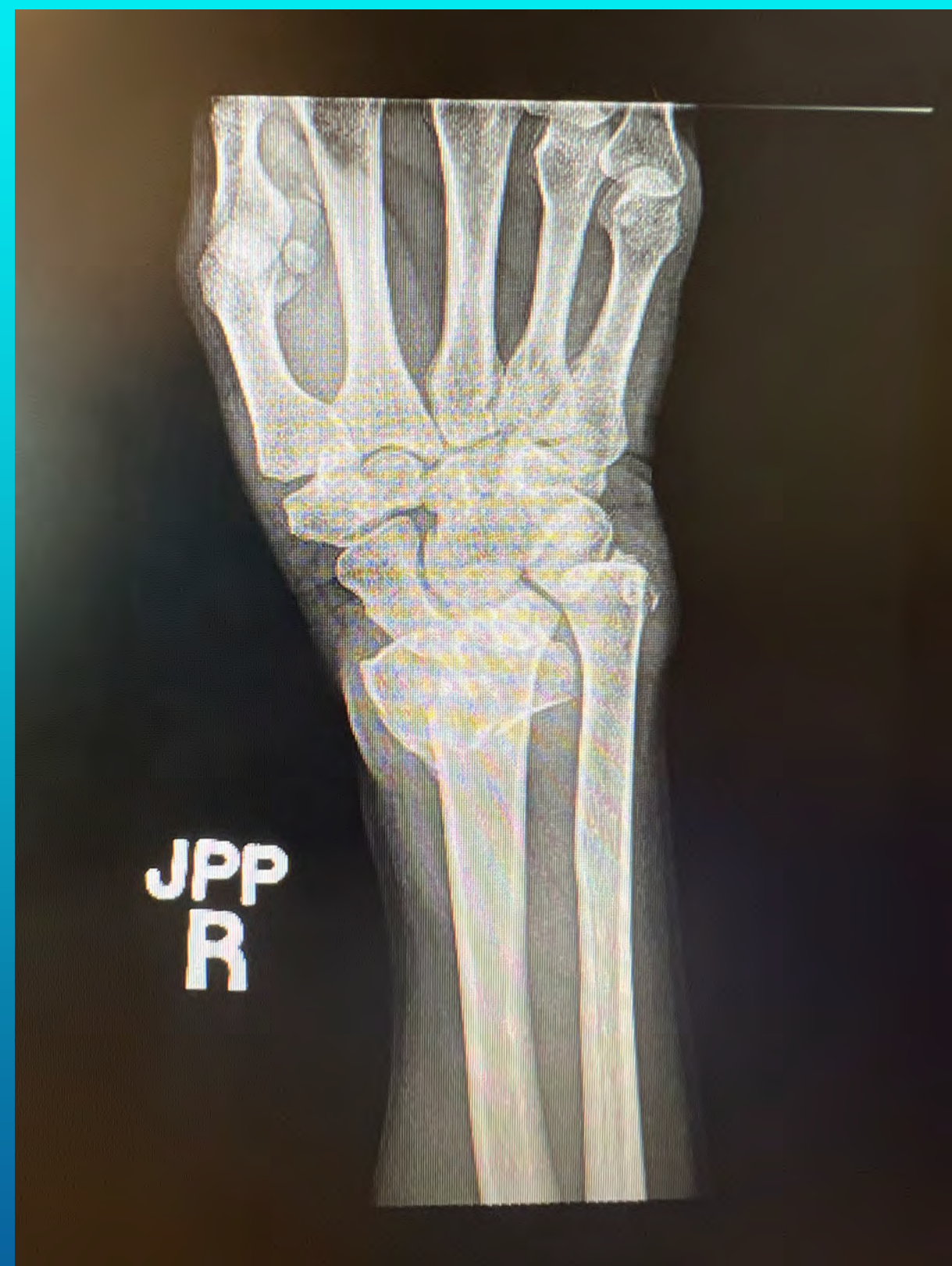- Risks:

- Infection & LA toxicity

- **Do not use once > 24hrs old as hematoma organized**



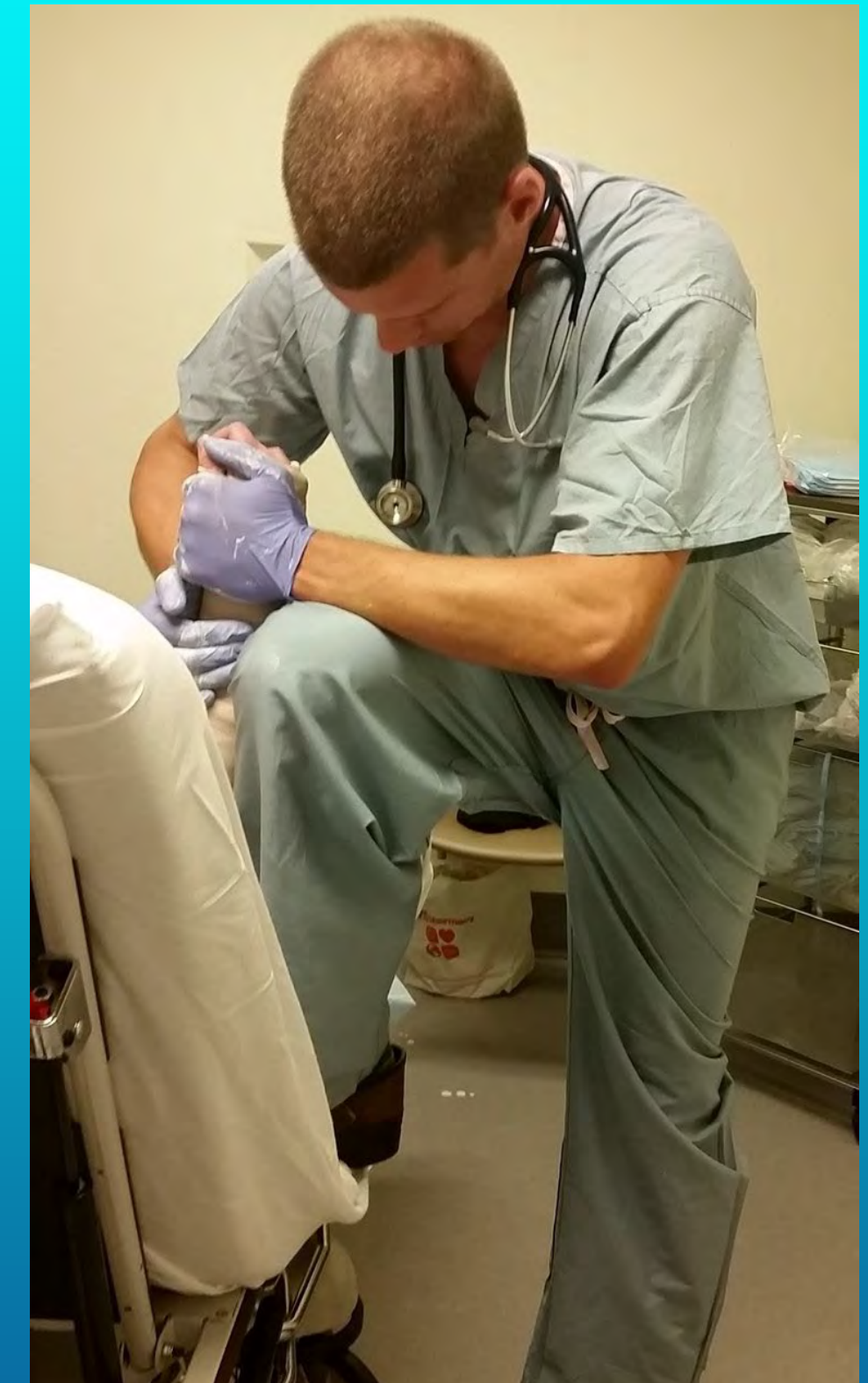HEMATOMA BLOCK



Colles' Fracture

Treatment

- **Non-op**
 - Majority of Colles- type distal radius fx do not need surgical intervention
 - **Displaced, extra-articular, non-comminuted fx are the best with Closed reduction.**
 - Reduction maneuver
 - Traction of the hand
 - Counter-traction @ the elbow
 - Re-produce deforming force – “unlock” the fracture
 - Volar-medial force applied to distal Radius fragment
 - Pronated position overcomes deforming supination force
 - Immobilize in sugar-tong splint
 - Post-reduction x-ray
 - Post-reduction exam: neurovascular intact
 - Follow up in 1 week for re-imaging

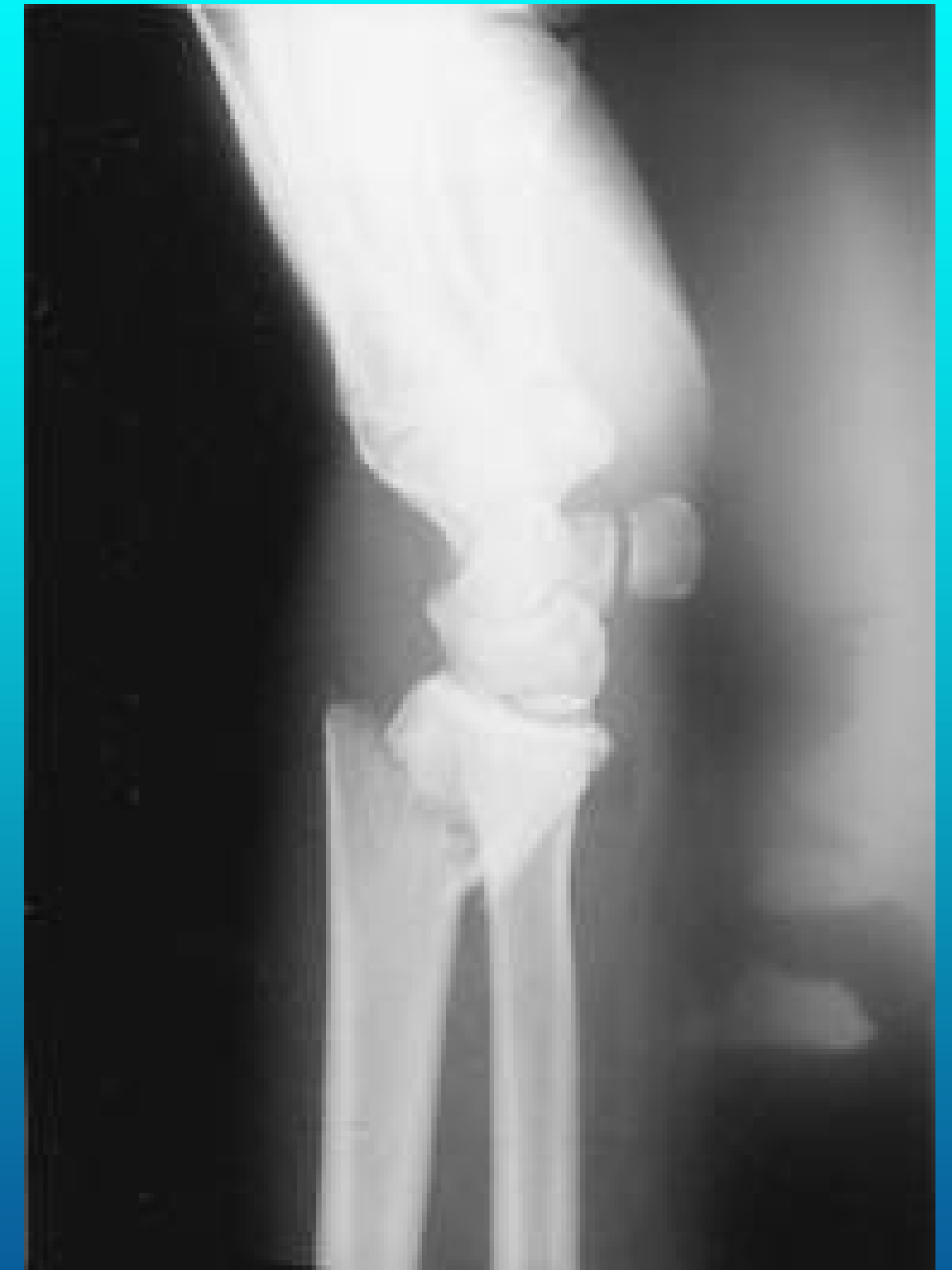

Meaike JJ, Kakar S, Management of Comminuted Distal Radius Fractures: A Critical Review, JBJS Reviews 2020;8(8)e20.00010

Distal Radius Fractures

Smith's Fracture

- Epidemiology
 - **Extra-articular distal Radius w/ volar displacement**
 - Intra-articular Smith's III = Volar Barton
 - Hand /wrist follows Radius fragment
 - 5% all distal Radius fractures
 - Garden Spade deformity
 - **Fall backward on of palmar flexed wrist or direct blow dorsal wrist**
 - Volar displacement also seen fall on palmar hand
 - Highest incident young males/older females
 - High energy falls young
 - **Osteoporotic bone elderly**



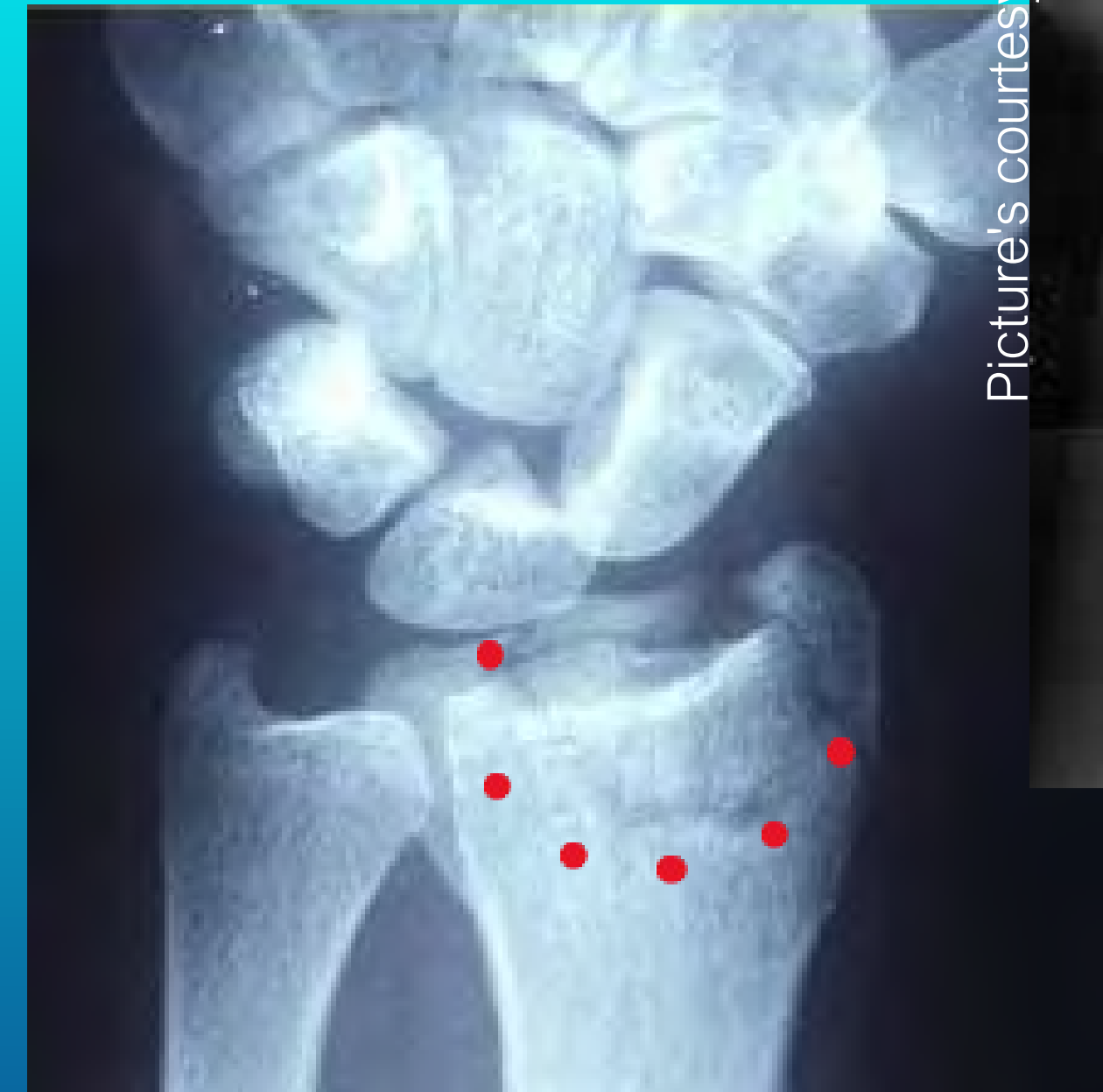Schroeder JD, Varacallo M. Smith's Fracture Review. [Updated 2020 Aug 15]. In: StatPearls [Internet]. Treasure Island (FL): StatPearls Publishing; 2020 Jan-.

Picture courtesy T Gocke, PA-C

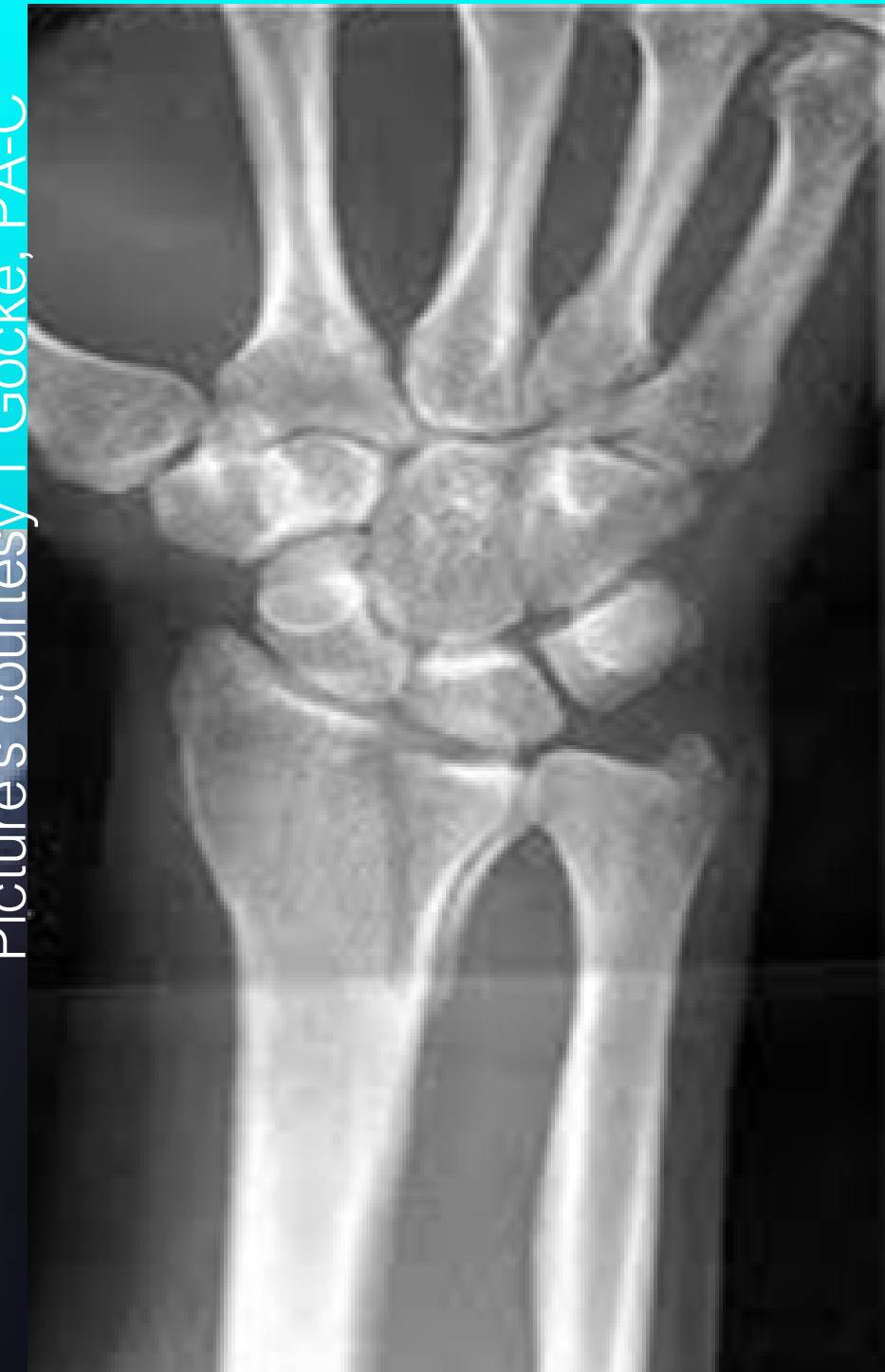Distal Radius Fractures

Die-Punch Fracture

- Defined as
 - Intra-articular distal Radius fx w/ depression into Lunate fossa
- Injury Mechanism
 - Axial load distal Radius
- Radiology
 - Traditional X-ray views
 - CT scan for comminuted fx with > 2mm displacement
- Treatment
 - Surgical intervention, no non-op options
 - Elevation of articular surface w/ stabilization distal radius fx.



Picture's courtesy T Gocke, PA-C



Ahn L, Vitale M, Franko O, Distal Radius Fractures, Orthobullets, <https://www.orthobullets.com/trauma/1027/distal-radius-fractures>, updated 1/9/2021, retrieved 2/16/2021

Carpal Fx

Carpal Bone Injuries

Scaphoid Fx – navicular

- **Epidemiology**

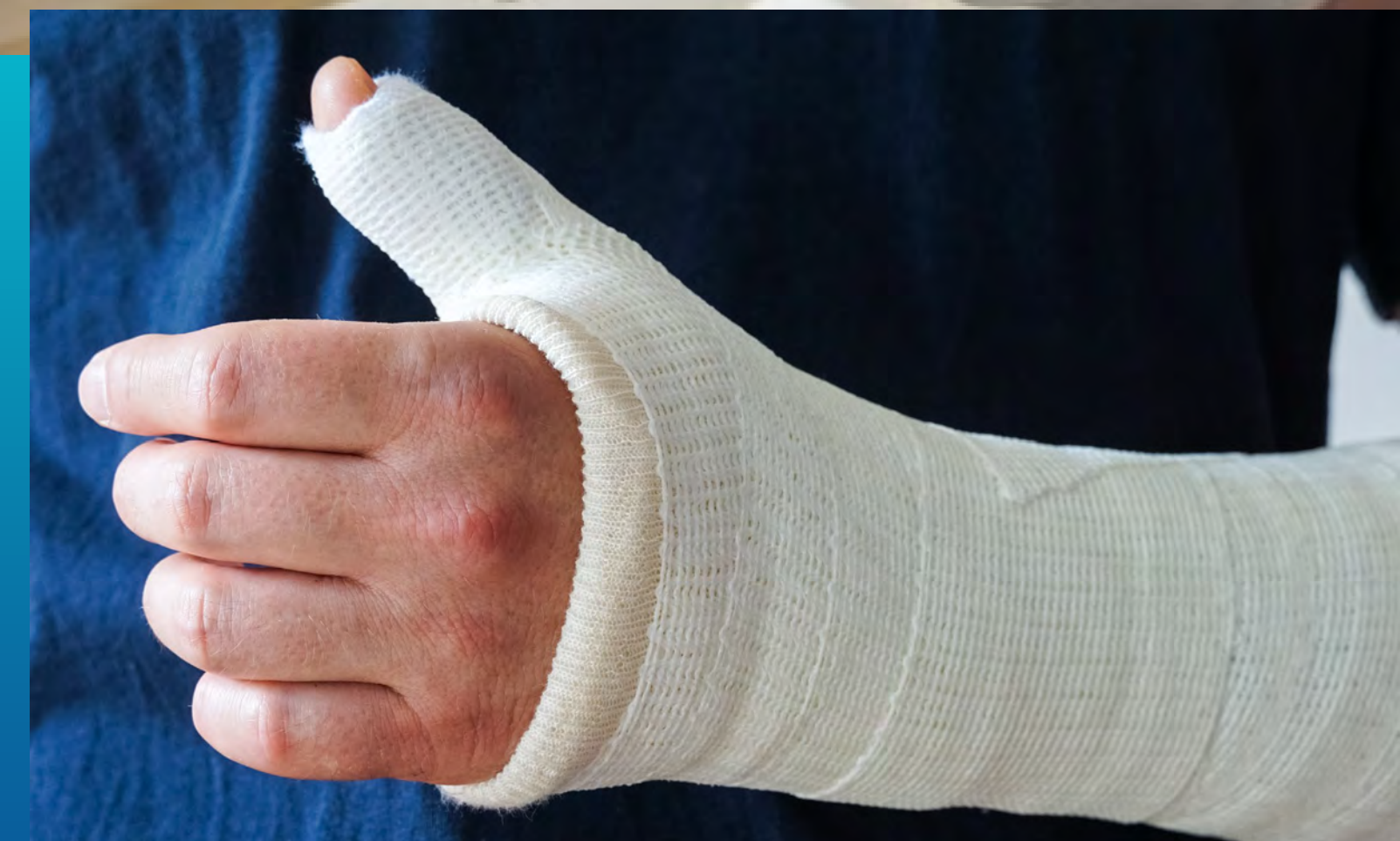
- Most frequently fractured carpal bone
 - Approximately 15% of all acute wrist injuries
 - Transverse fx pattern considered more stable & best healing prognosis
- Mechanism of Injury:
 - Fall on outstretched hand (FOOSH)
 - Axial load to wrist/carpal bones
 - Some radial deviation & Hyperpronation

Carpal Bone Fractures

Scaphoid Fx

Treatment:

- Important Initial treatment:
 - ***Suspect occult scaphoid fx***
 - Initial recognition of potential injury mechanism
 - Thorough physical examination
 - Comprehensive review of initial radiographs
 - Thumb spica splint vs. cast
 - Initial immobilization for 14-21 days
 - Repeat x-ray on follow up exam



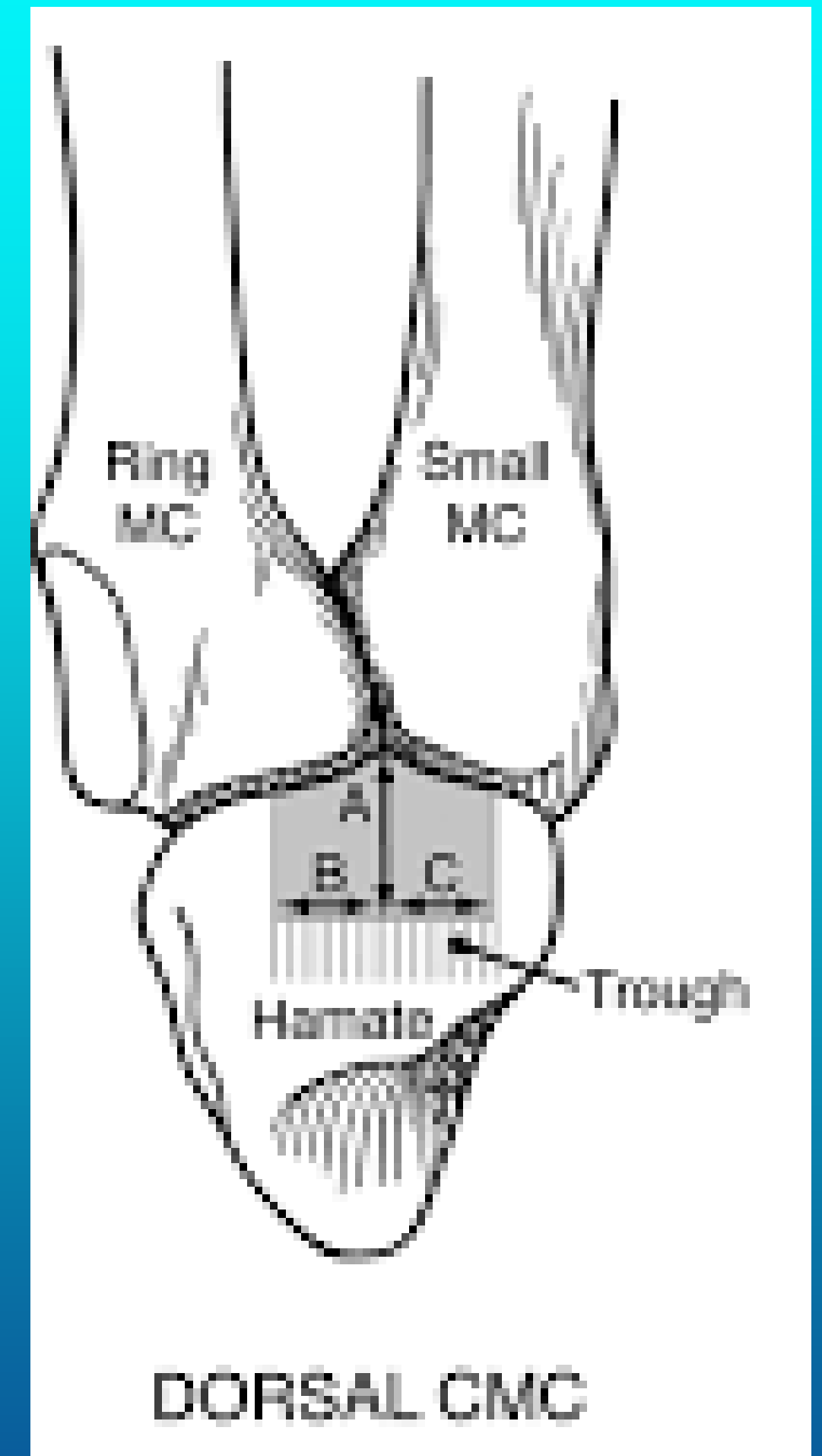
Photos courtesy TGocke, PA-C

Hand- Metacarpal Fx

Metacarpal Fractures

Anatomy Review

- Index & Long (middle) fingers least mobile
- Ring & Small fingers more mobile & articulate with Hamate
- Thumb most mobile 2nd to articulation with carpus
- Palmar & Dorsal Interossei muscles originate for MC shafts
- Intrinsic Muscles
- Extrinsic Muscles



Metacarpal Fractures

Epidemiology

- Most fractures of the hand are to the metacarpal (MC)
 - Metacarpal neck most common injured & 5th metacarpal most often injured
 - 30% of all hand Fx are to the Shaft
- Men highest incidence of metacarpal injuries
- Average age injury 10-30 yrs
- Fx located by location: Head- Neck – Shaft - Base
- Treatment metacarpal fx based on finger and fx location
- Consider other injuries
 - Lacerations – open fx – compartment injuries- Infection

Borchers JR, Best TM, Common Finger Fractures and Dislocations, *Am Fam Physician* 2012, 85;(8):805-810

Wieschhoff GG, Sheehan SE, Wortman JR, et al, Traumatic Finger Injuries: What the Orthopaedic Surgeon Wants to Know, *RNSA* 2016;36(4):1106-1128

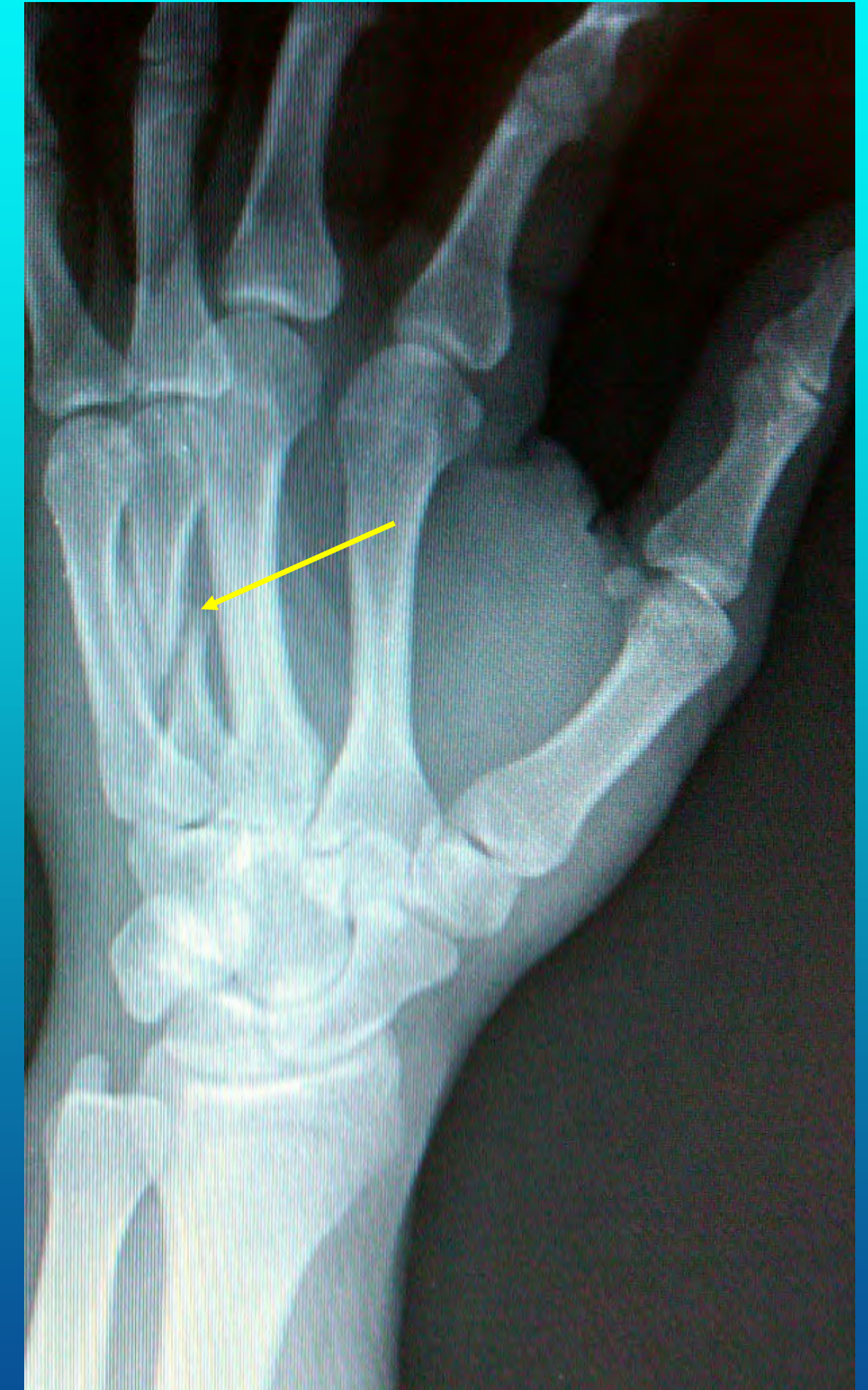Metacarpal Fractures

Metacarpal Shaft FX

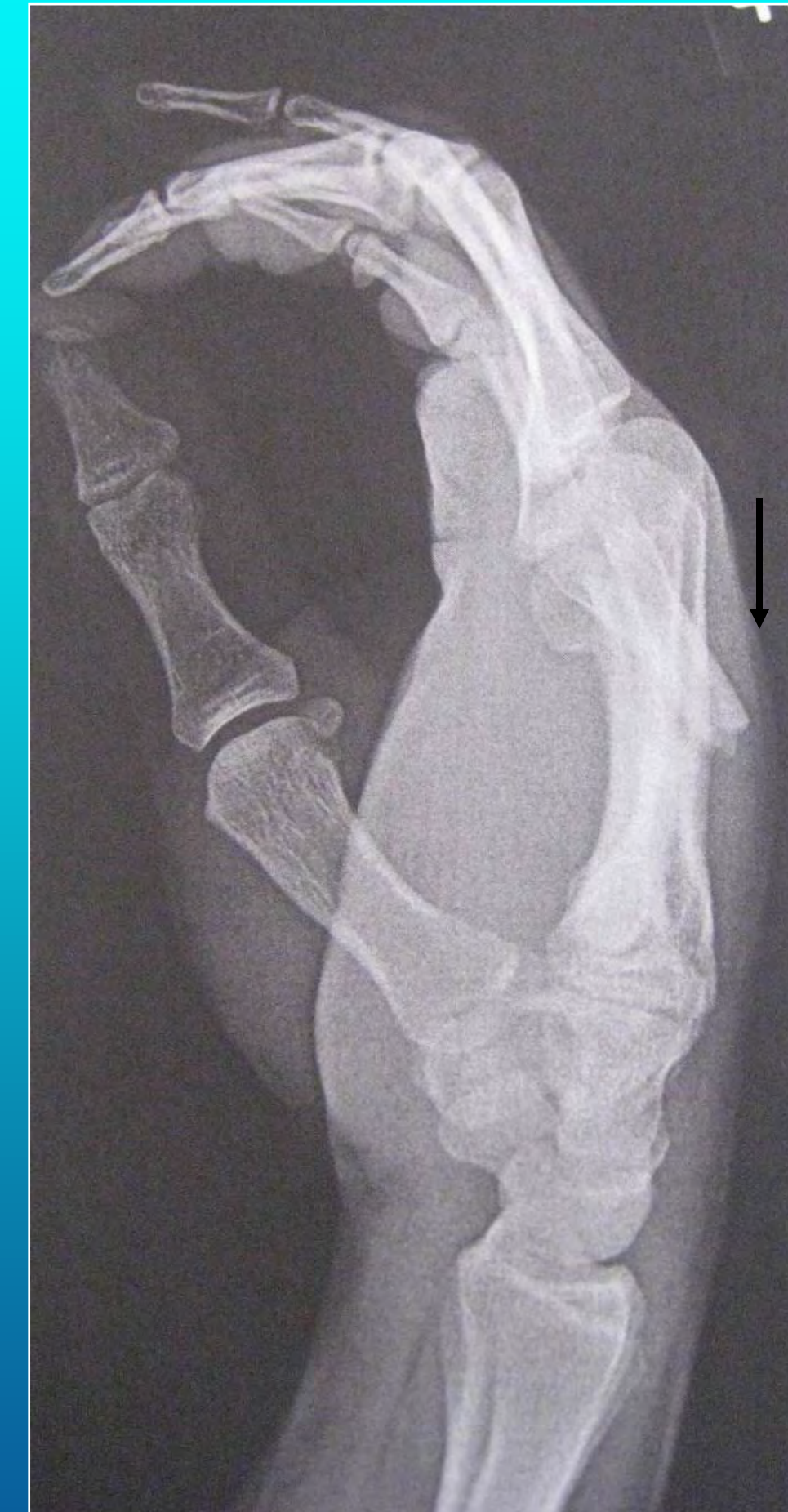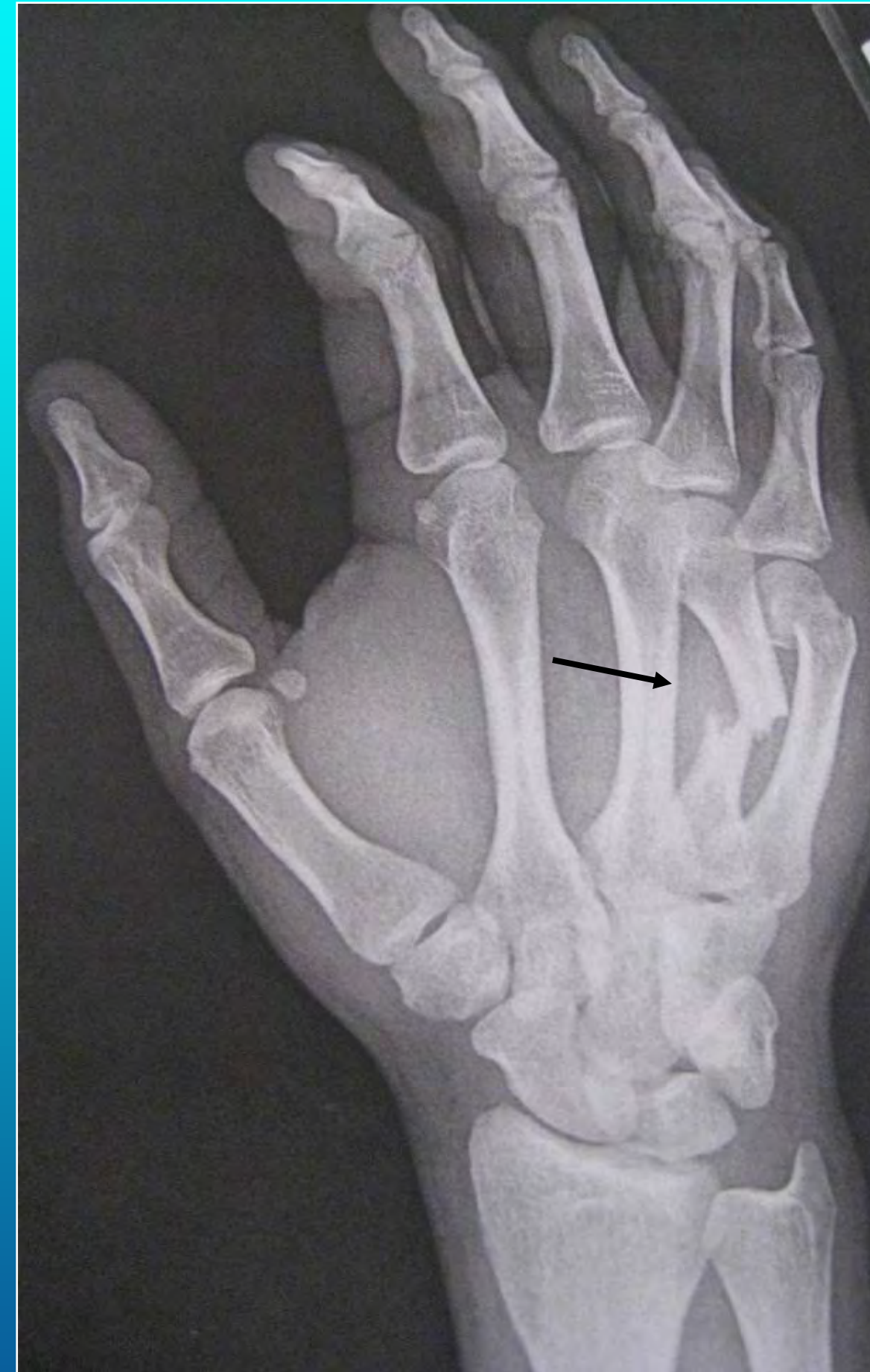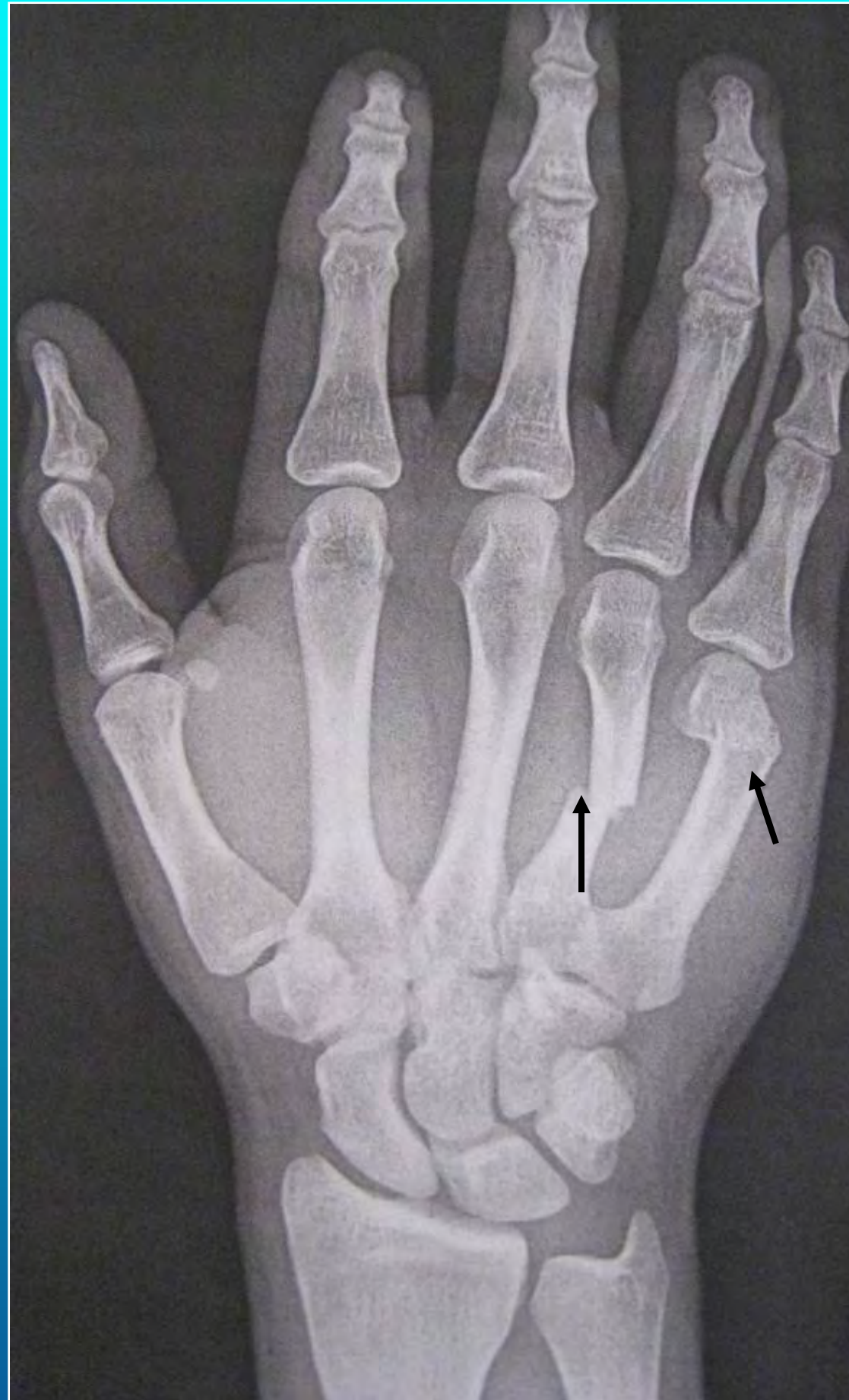- Minimal displacement
- NO malrotation
- <5mm shortening
- 10 degrees coronal angulation any MC

Nelson, Wongworawat: Tolerances, 3rd edition 2009

Wieschhoff GG, Sheehan SE, Wortman JR, et al, Traumatic Finger Injuries: What the Orthopaedic Surgeon Wants to Know, RNSA 2016;36(4):1106-1128



Metacarpal shaft Fracture



Pictures courtesy T Gocke, PA-C

Cascade sign

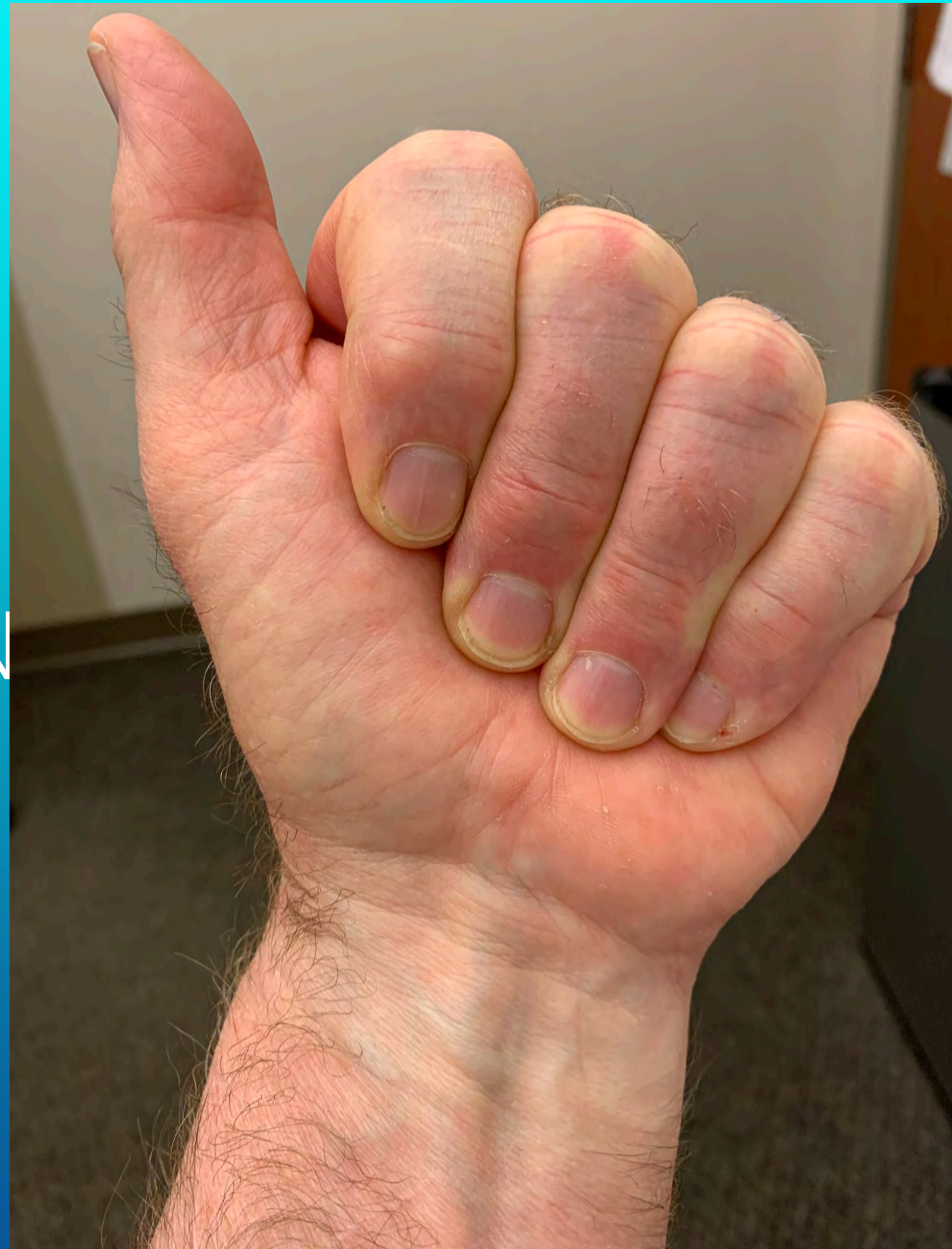


Photo courtesy TGocke, PA-C

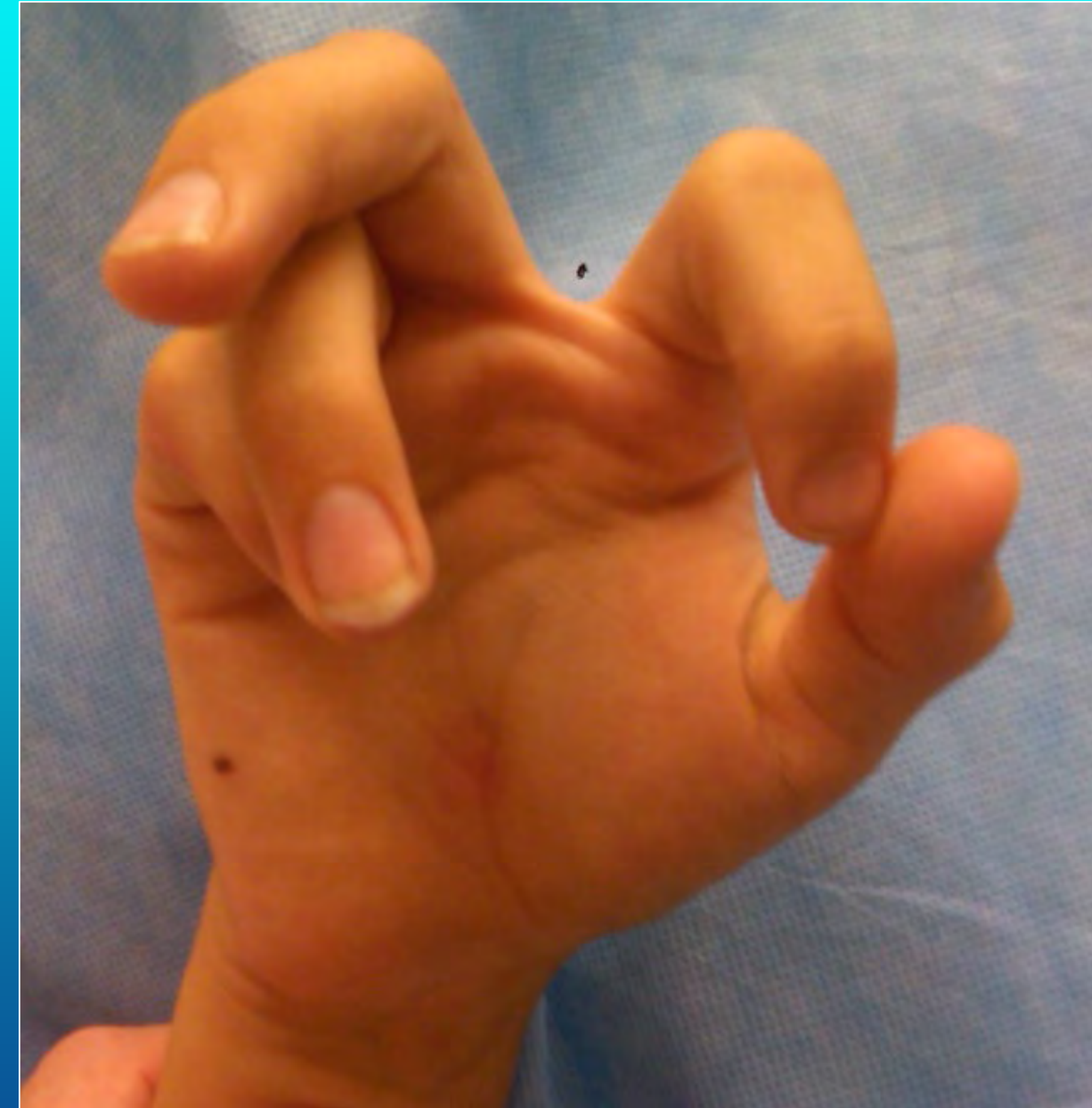
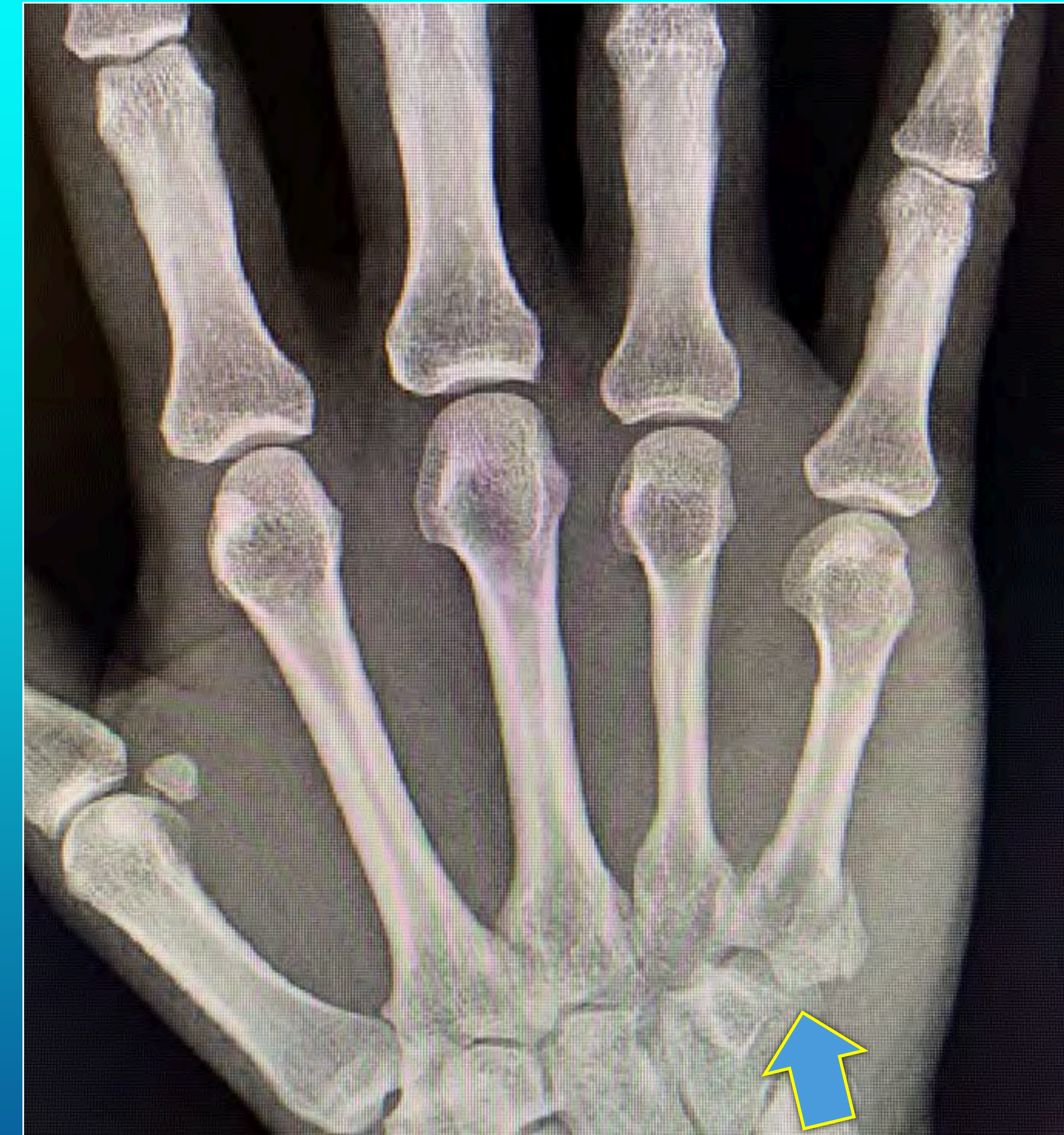

Photo courtesy TGocke, PA-C

Metacarpal base Fractures

Metacarpal Base fx –

- Extra-articular: Tx like MC Shaft
- Intra-articular: Tx based on malalignment
 - Malalignment Leads premature OA, weak grip & poor ROM
 - More Ulnar MC's allow for more ROM @ CMC jts. Leading to more noticeable malalignment
- Exam
 - Assess for Rotational deformities & weakness
 - Review X-ray studies
 - If Intra-articular or appear comminuted with ? Intra-articular extension need CT scan



X-ray Image courtesy Tom Gocke, PA-C Library

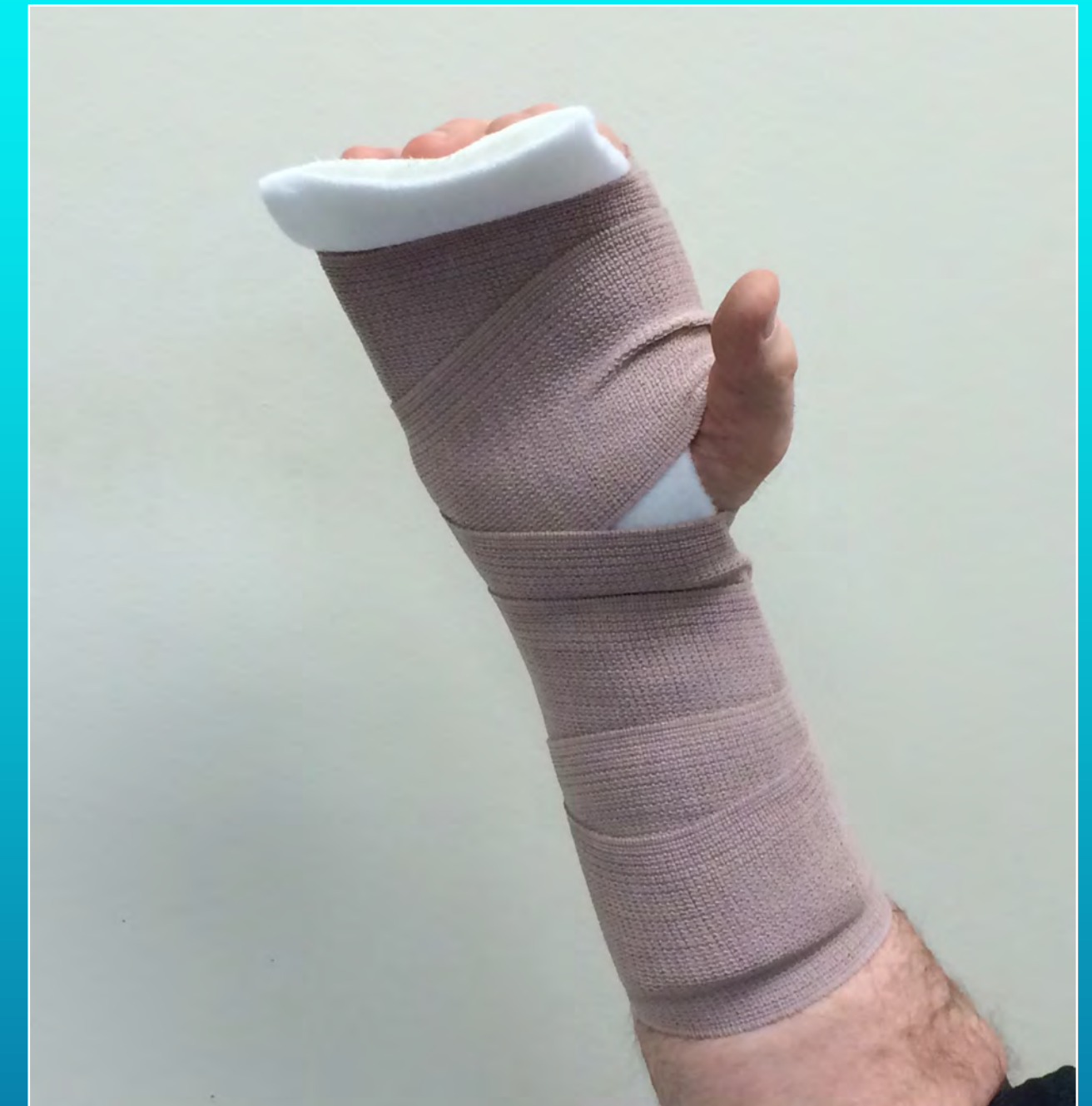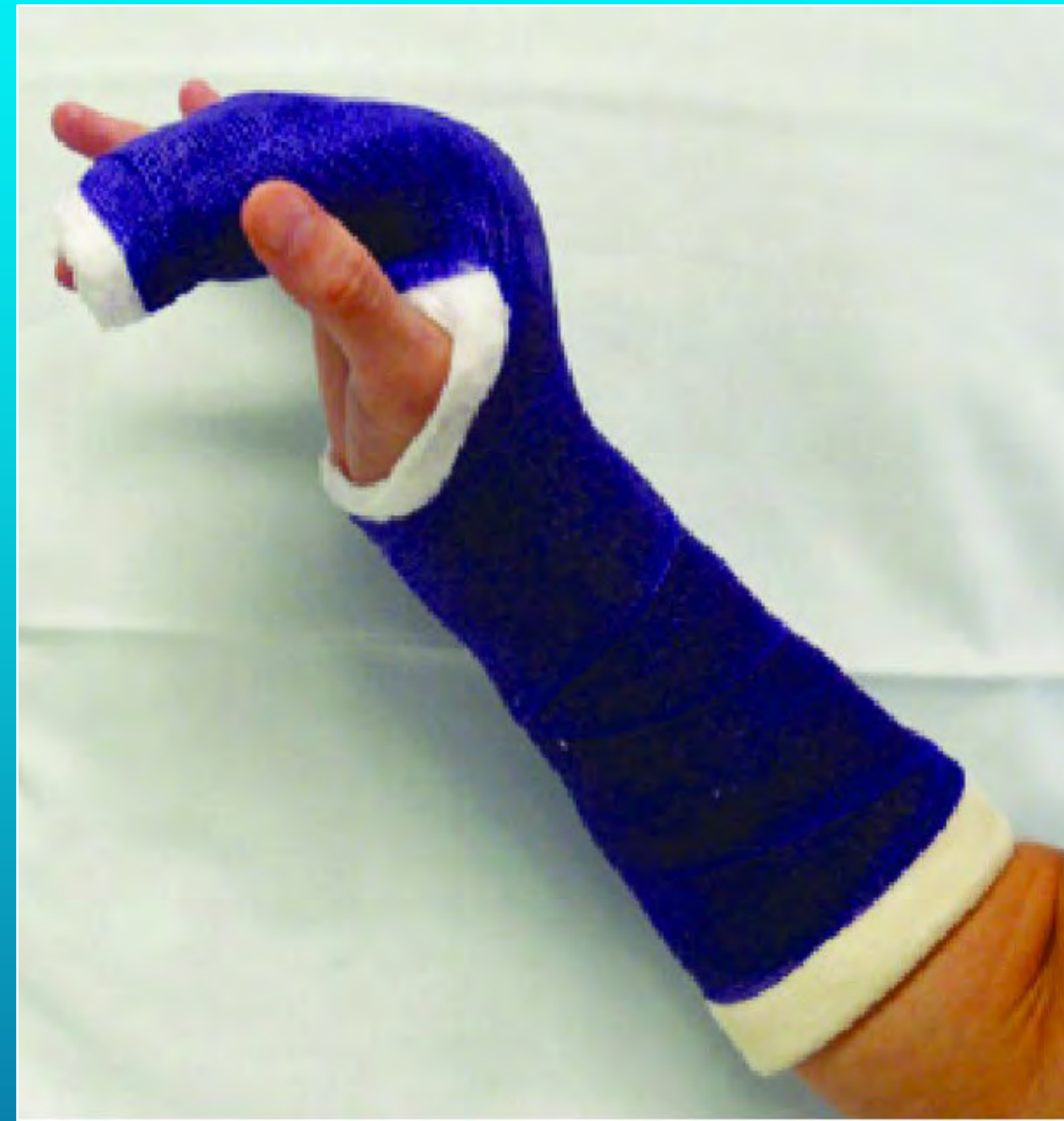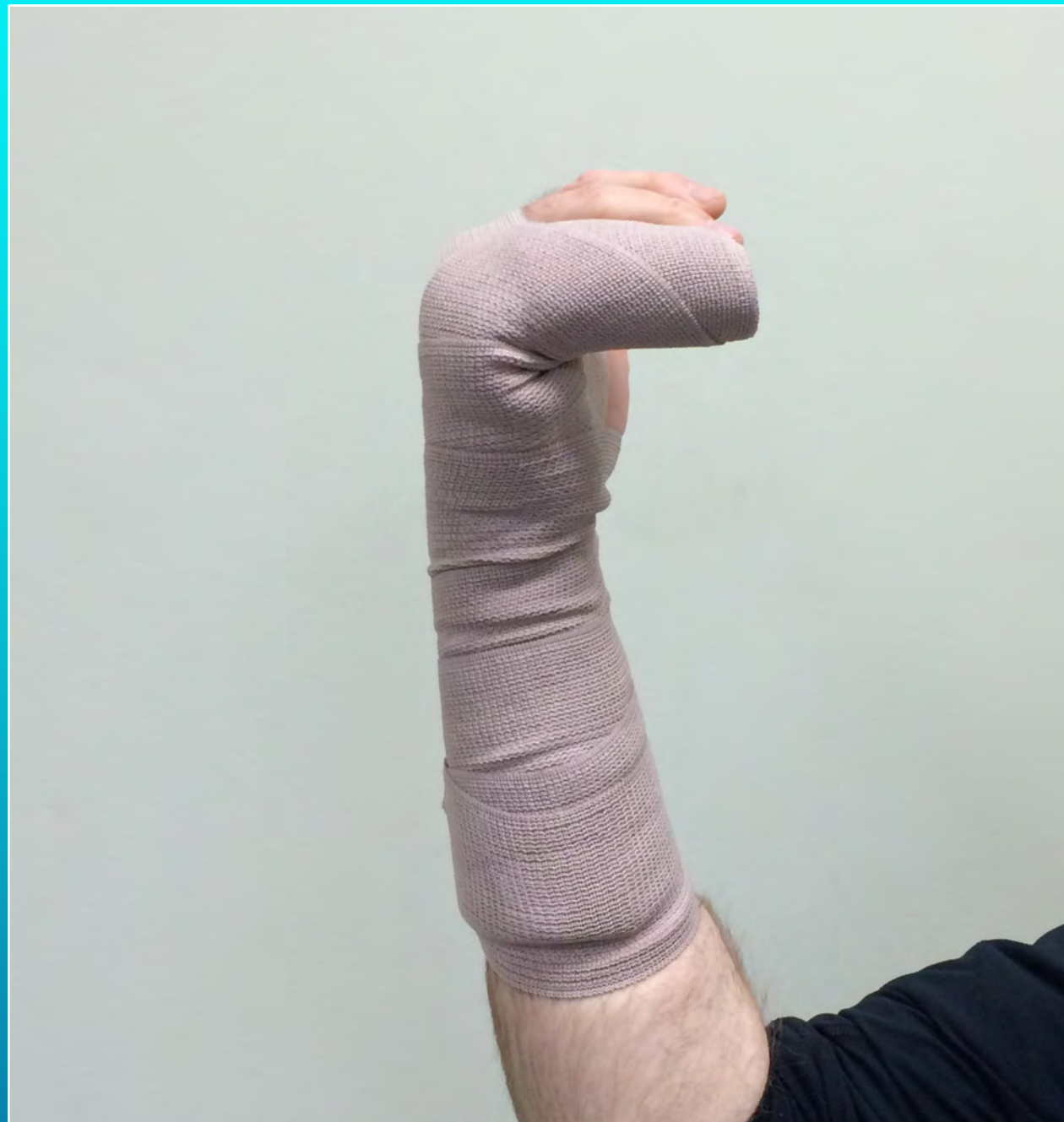Metacarpal Base Fracture

- Initial Treatment
 - Recognize injury seen on x-ray
 - **Assessment for malrotation deformities & grip strength changes (hand dynamometer)**
 - Application Ulnar/Radial gutter splint intrinsic plus position
 - Volar /dorsal blocking splint
 - **Consider CT Scan hand**
 - **Ortho Hand/Plastics Hand follow up within <1 week of CT scan being done**
 - **Surgery vs. Thermoplastic splint/Cast immobilization**
 - Needs close follow up if treated conservatively

Bernstein D, Metacarpal Base Fractures – Surgical vs. Conservative care, November 1, 2019 – Personal conversation

Oak N, Lawton JN, Intra-Articular Fractures of the Hand, Hand Clinic, 2013;29:535-549

Metacarpal Base Fracture



Finger Fx & Dislocations

Phalangeal Fractures

Epidemiology

- Most common fracture to the hand – 50%
- Finger phalanx divided into:
 - Proximal (P1) – Middle (P2) – Distal (P3)
- Common Injury Mechanism: Axial load & Crush injury
- Injury involves Tuft-Shaft-Base
- Fx pattern: Transverse or Longitudinal
- Distal Fingertip anatomy
 - Numerous septa extend from periosteum to skin
 - Overlying nail bed
 - 50% nail Bed extends beyond P3
 - Less likely to dislocate DIP jt. due to fingertip anatomy

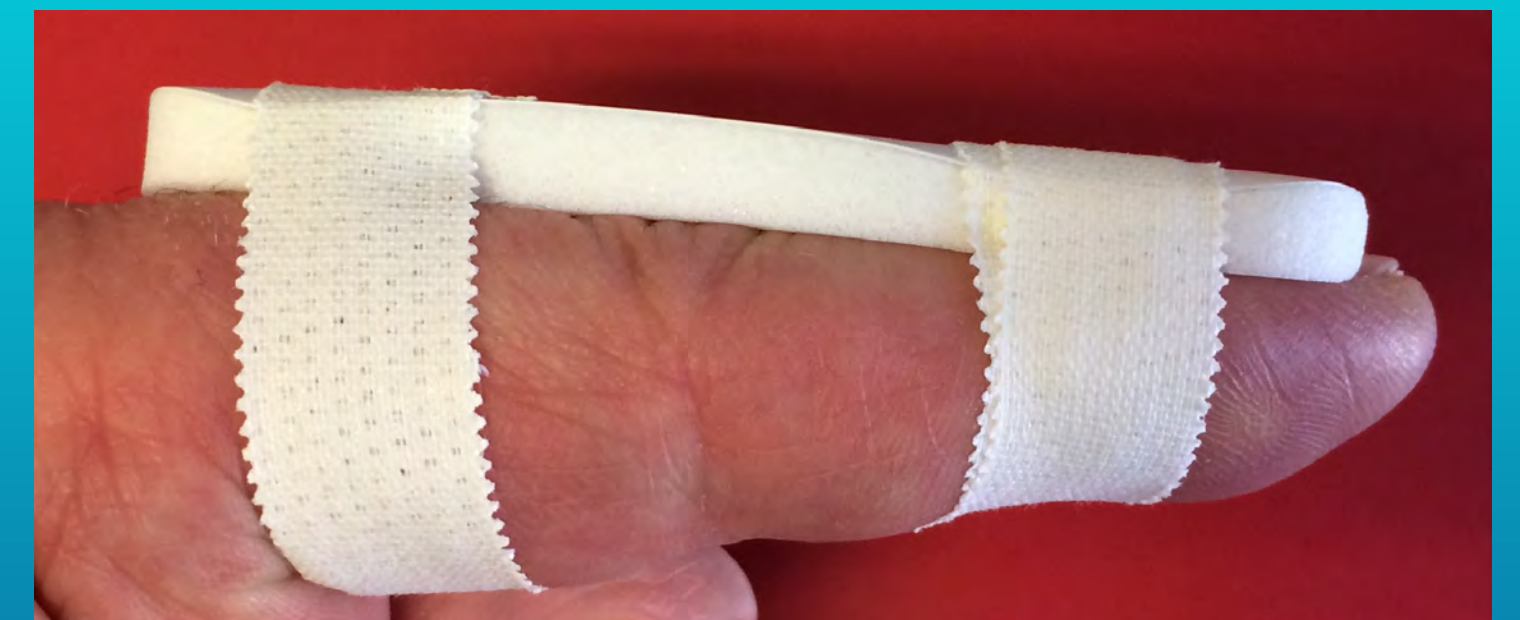
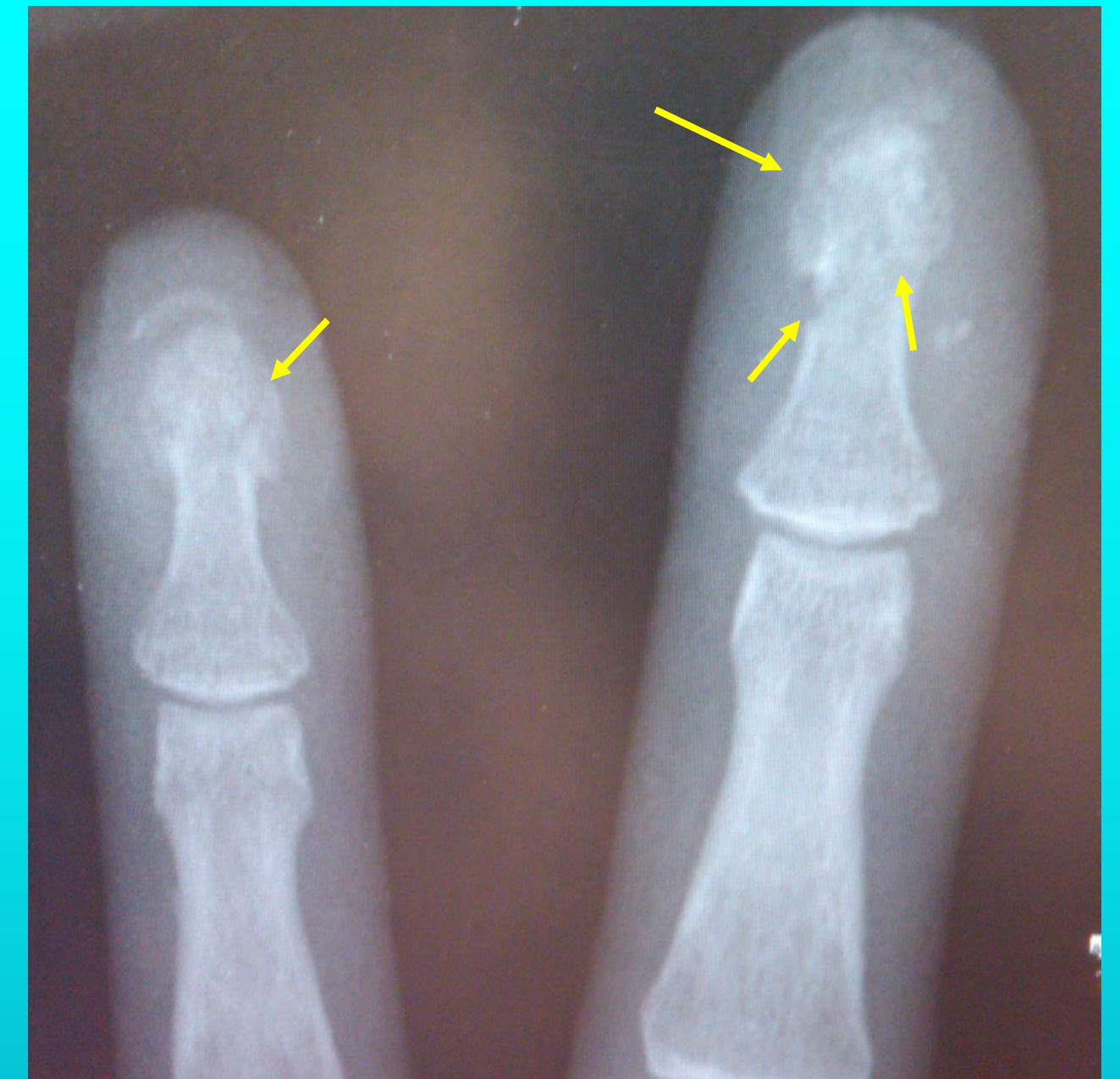Phalangeal Fractures

Treatment: Distal phalanx

- Non-operative
 - Extra-articular
 - < 10 degrees angulation
 - < 2mm shortening
 - No Rotational deformity
 - Dorsal Finger splint DIP joint vs. Stack Splint
 - Swelling may limit stack splint use initially
 - Monitor for Nail matrix & nail bed laceration

Nelson S, Wongworawat M, Tolerances: an orthopaedic reference manual, 3rd edition, Loma Linda University Press, Loma Linda, CA. 2009

Wieschhoff GG, Sheehan SE, Wortman JR, Traumatic Finger Injuries: What the Orthopaedic Surgeon Wants to Know, RNSA 2016;36(4):1106-1128



Phalanx fx

Shaft Fractures

- Transverse w/o displacement considered to be stable fx can immobilize w/a splint
- Oblique & Spiral: often unstable fx patterns and require surgery
- Intra-articular fx: most displaced & require ORIF (same as P2 injury)

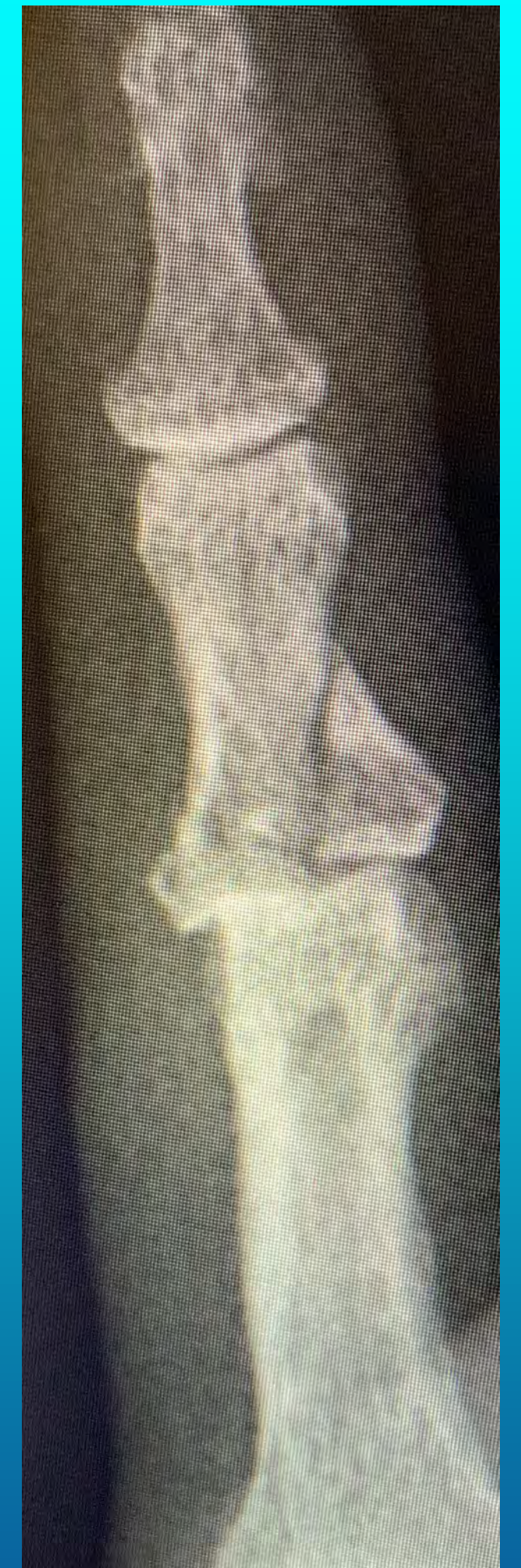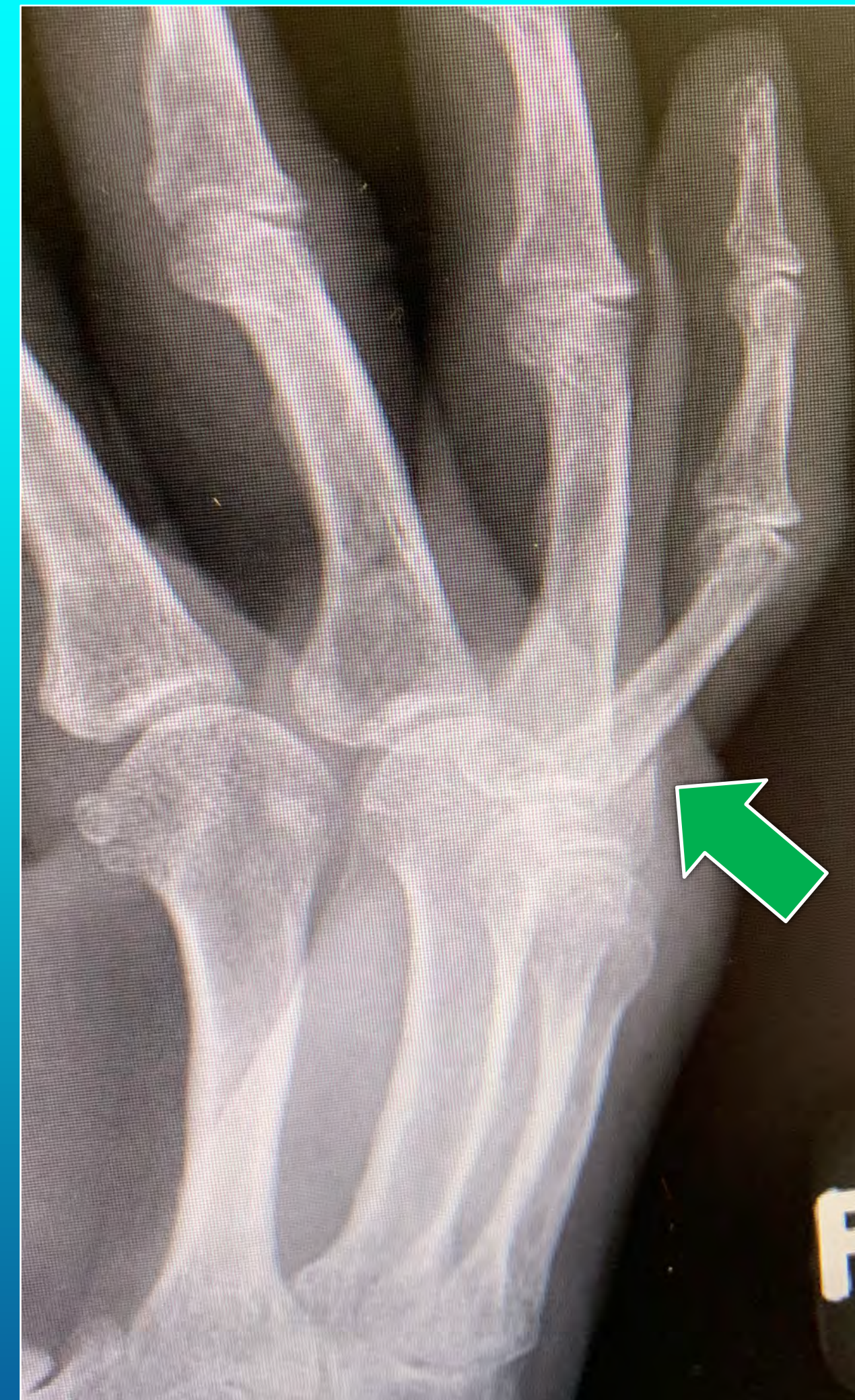Base fractures

- Often need surgery 2nd to poor ability to maintain fx reduction if displaced

Immobilize in extension

Pain meds

F/U 1 week



Lower Extremity Fractures

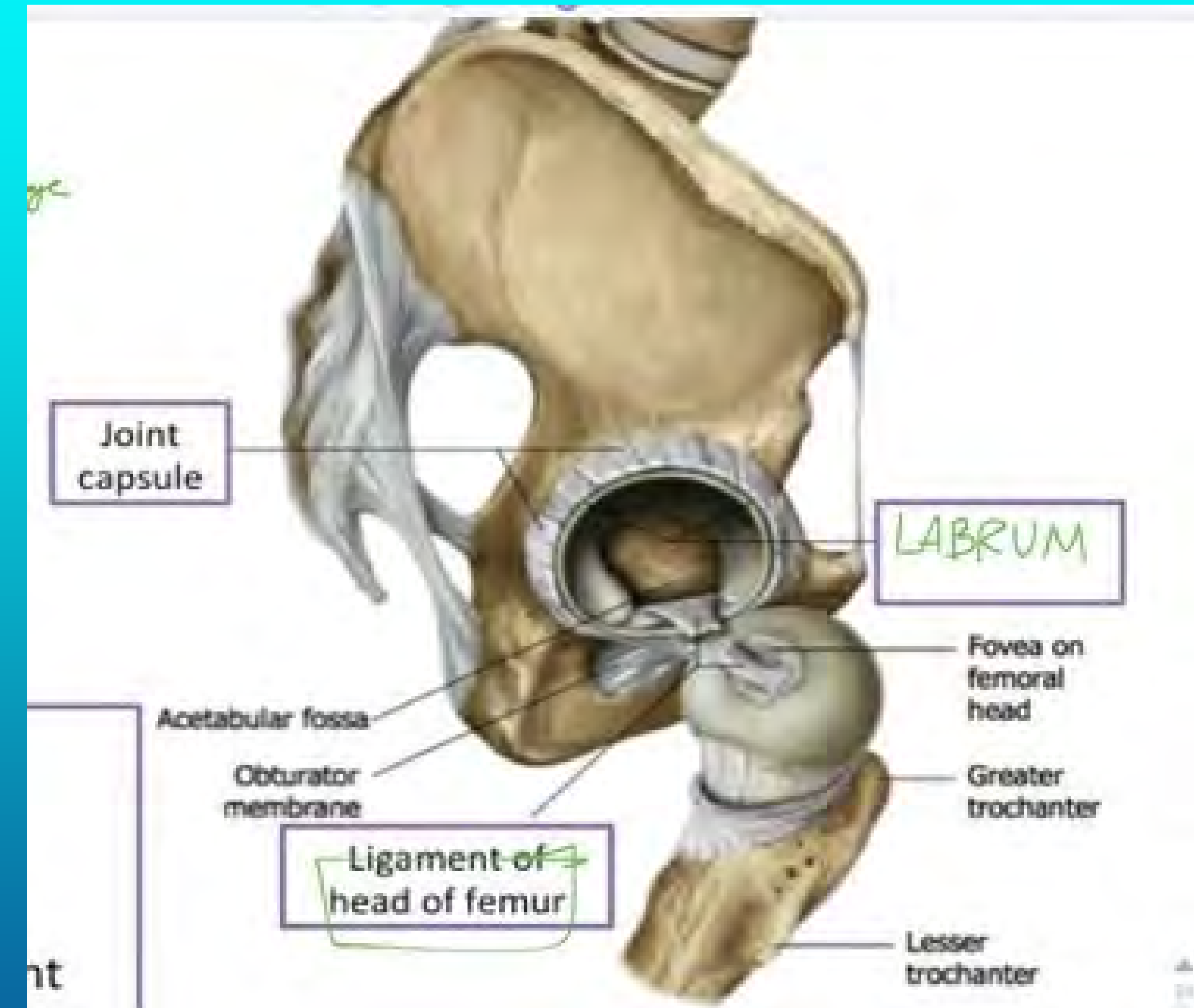
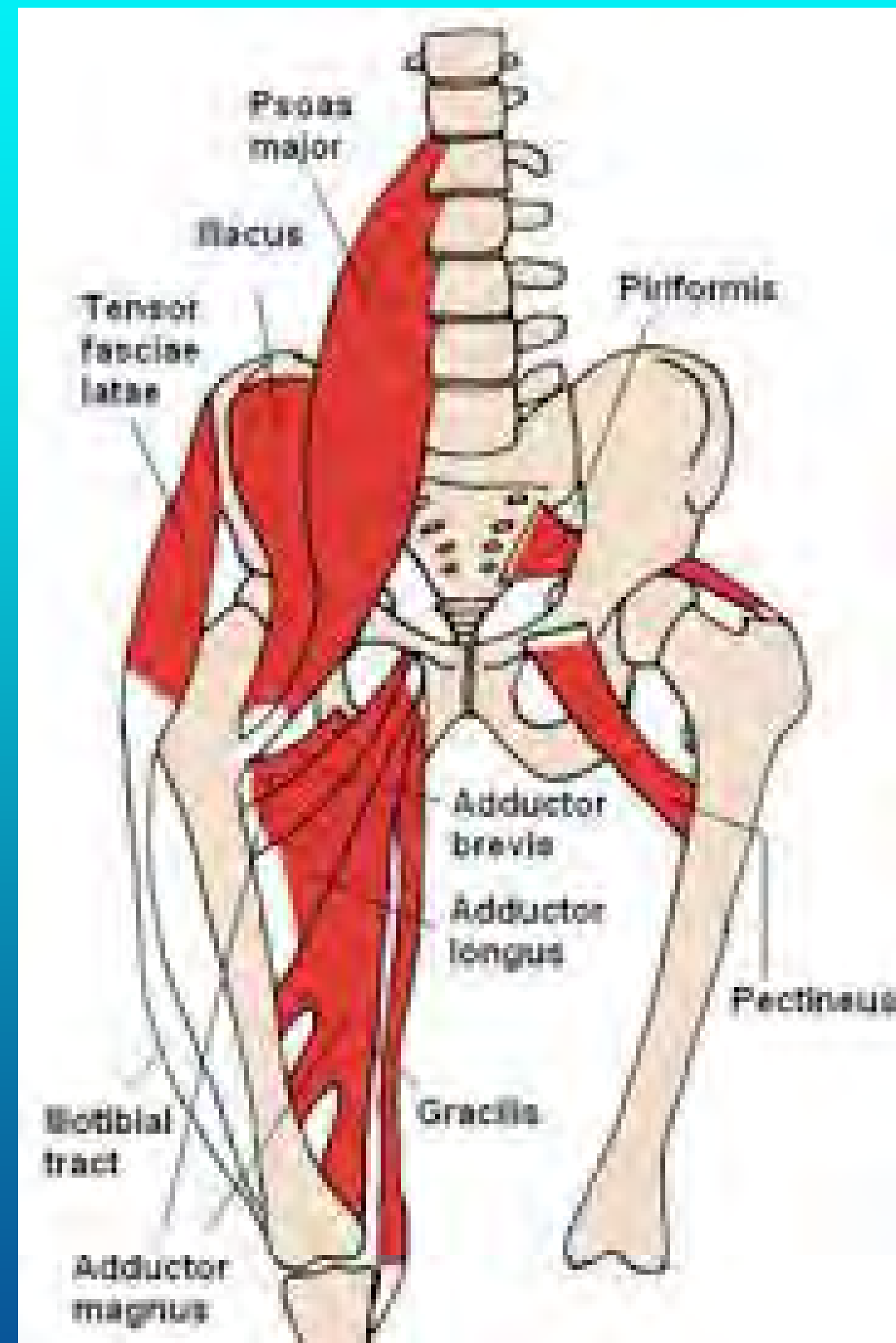
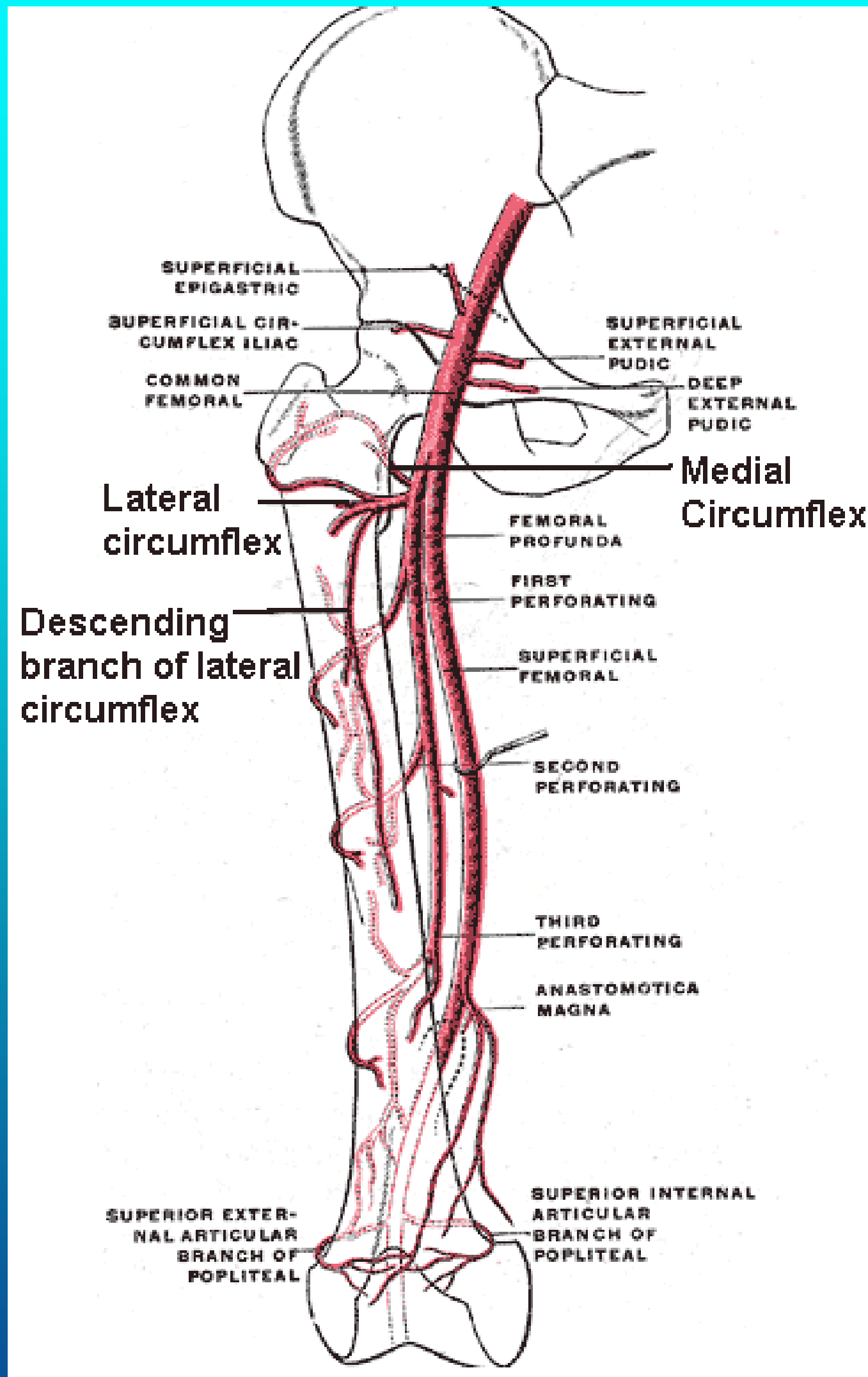
Femur fx

--Hip

--Shaft

--Distal

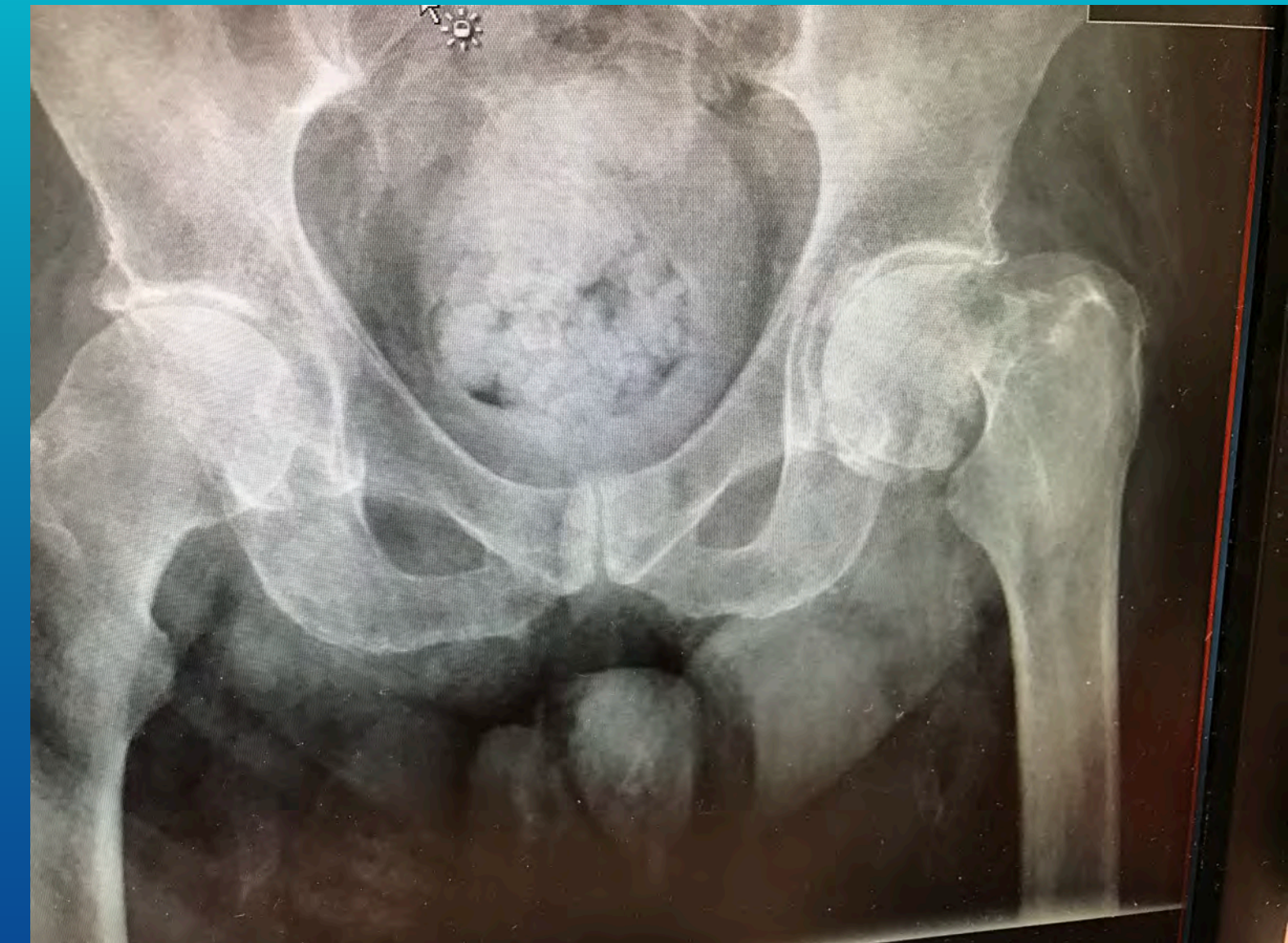
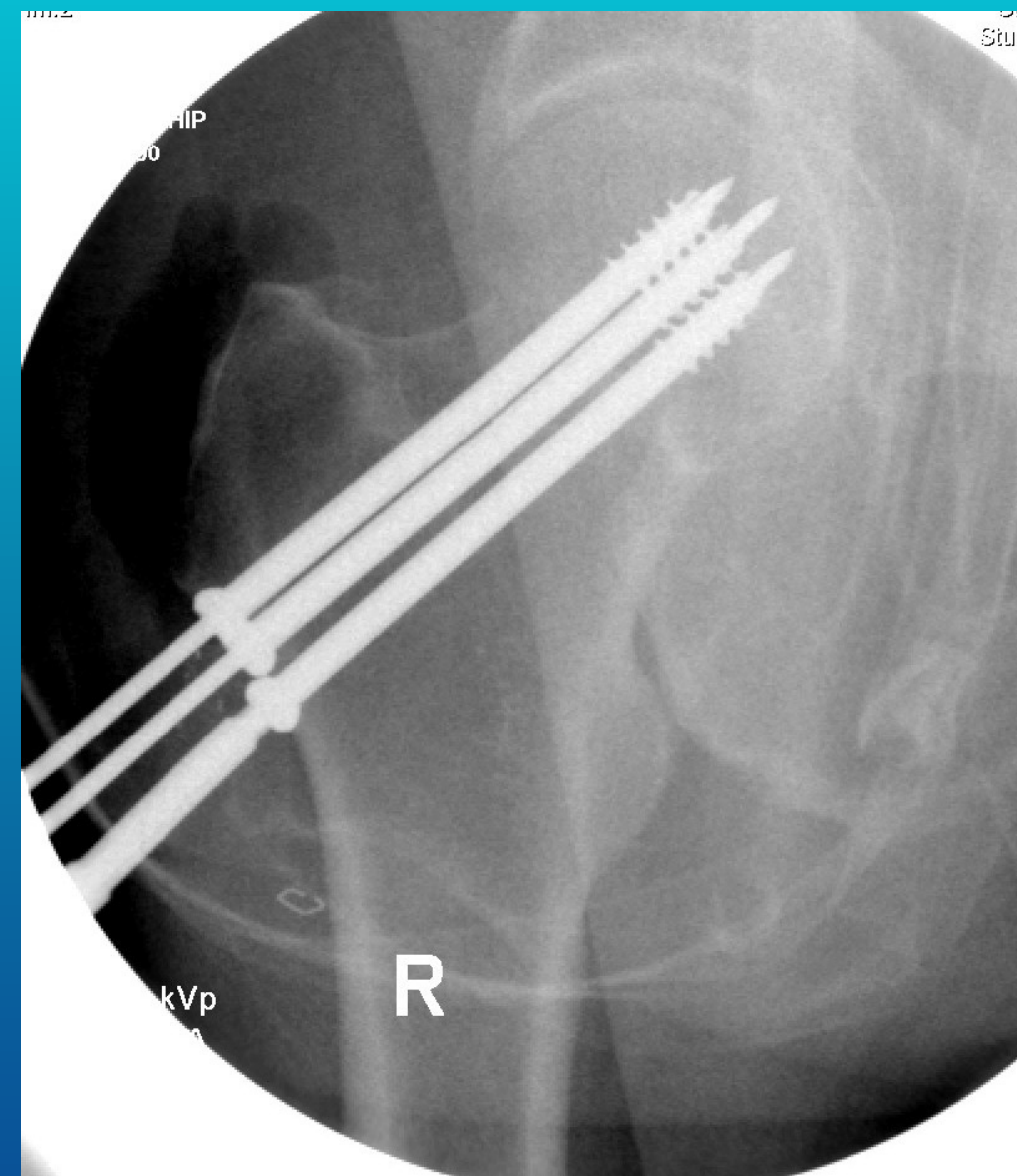
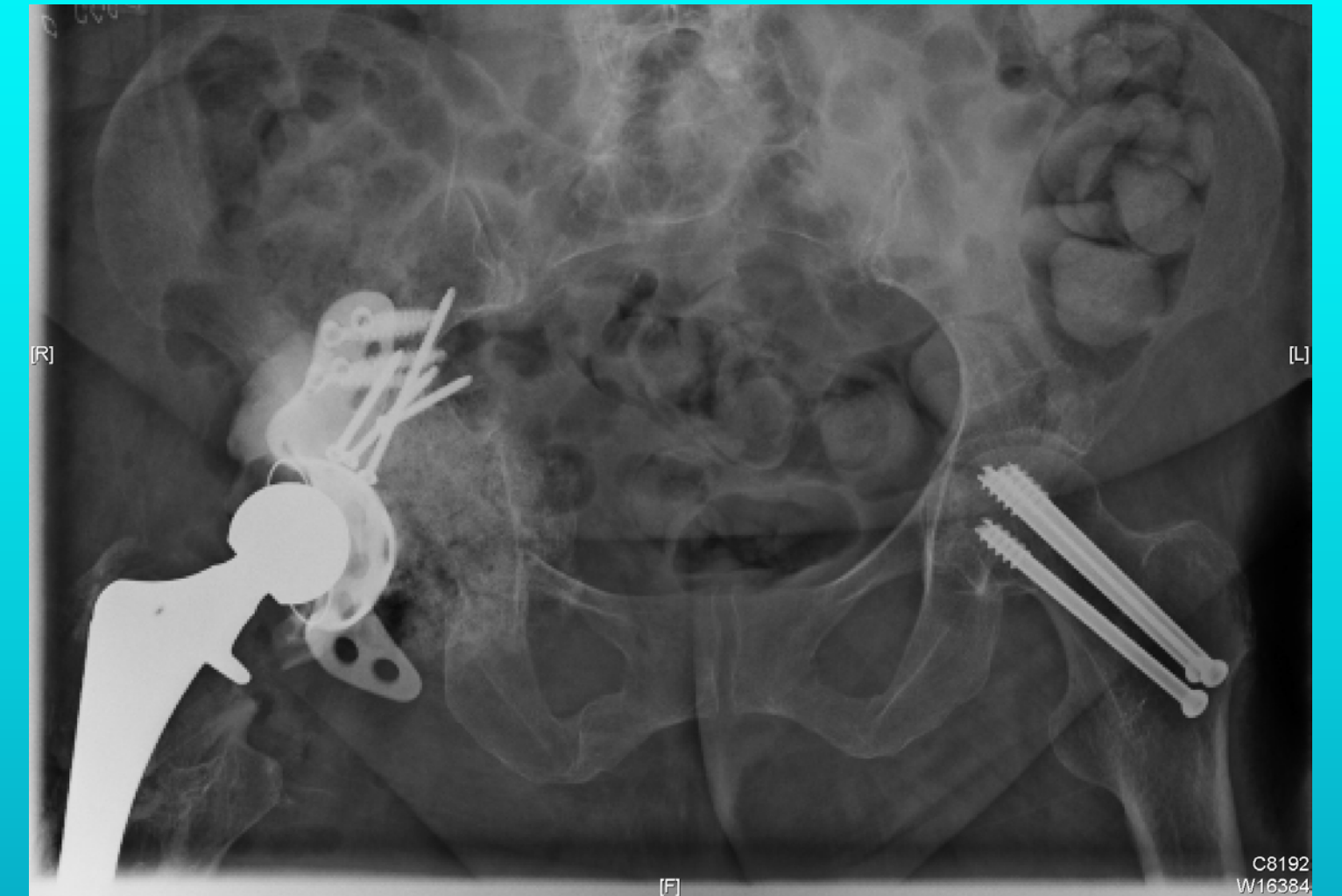Hip Anatomy



Subcapital Femoral Neck Fx

Epidemiology

- Increasingly common with aging population
- **Female-white-elderly-osteoporosis**
- High energy-young; low energy –elderly
- Neck intracapsular
 - Low blood supply
 - Poor healing potential
- **Mortality**
 - 25-30% overall
 - Chronic renal failure 45% 2 yrs
 - Decrease mortality if Surgery < 24 hrs
- **Treatment**
 - **Admit & Medical optimization**
 - **Surgery <24 hrs**
 - Mobilize



Garden Classification

Garden

Garden Classification:

Garden

Garden I: incomplete fracture, valgus impacted

Garden

Garden II: non-displaced fracture

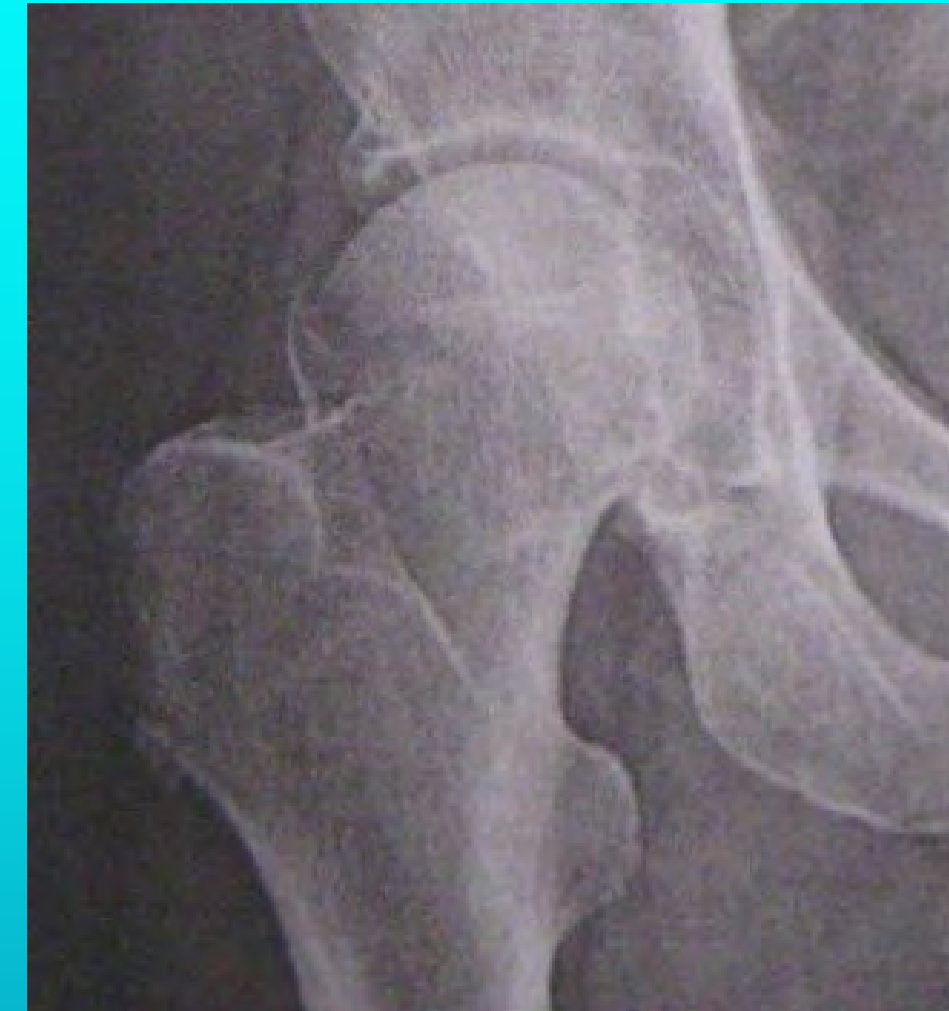Garden

Garden III: fracture with partial displacement

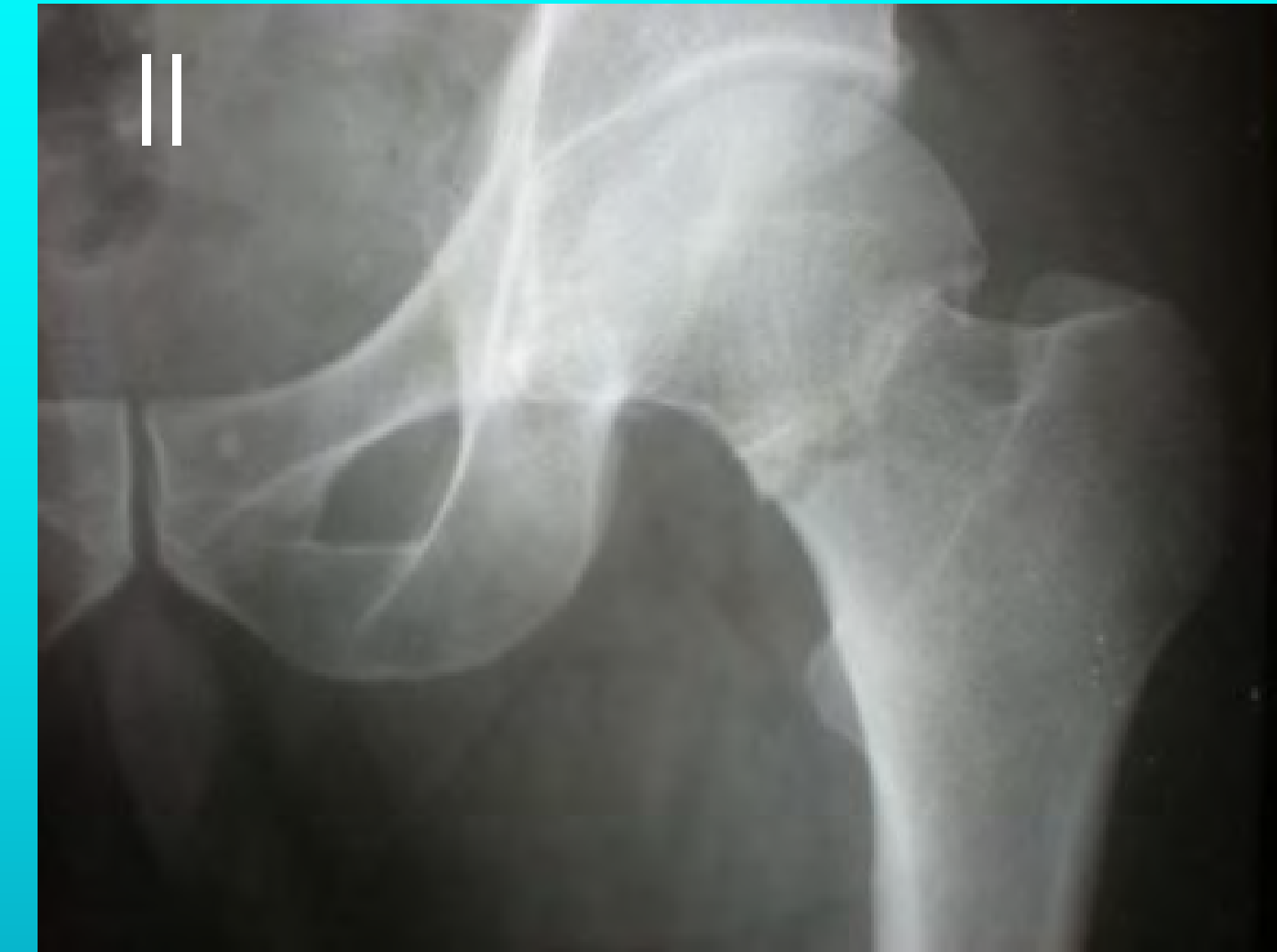
Garden

Garden IV: fracture with complete displacement

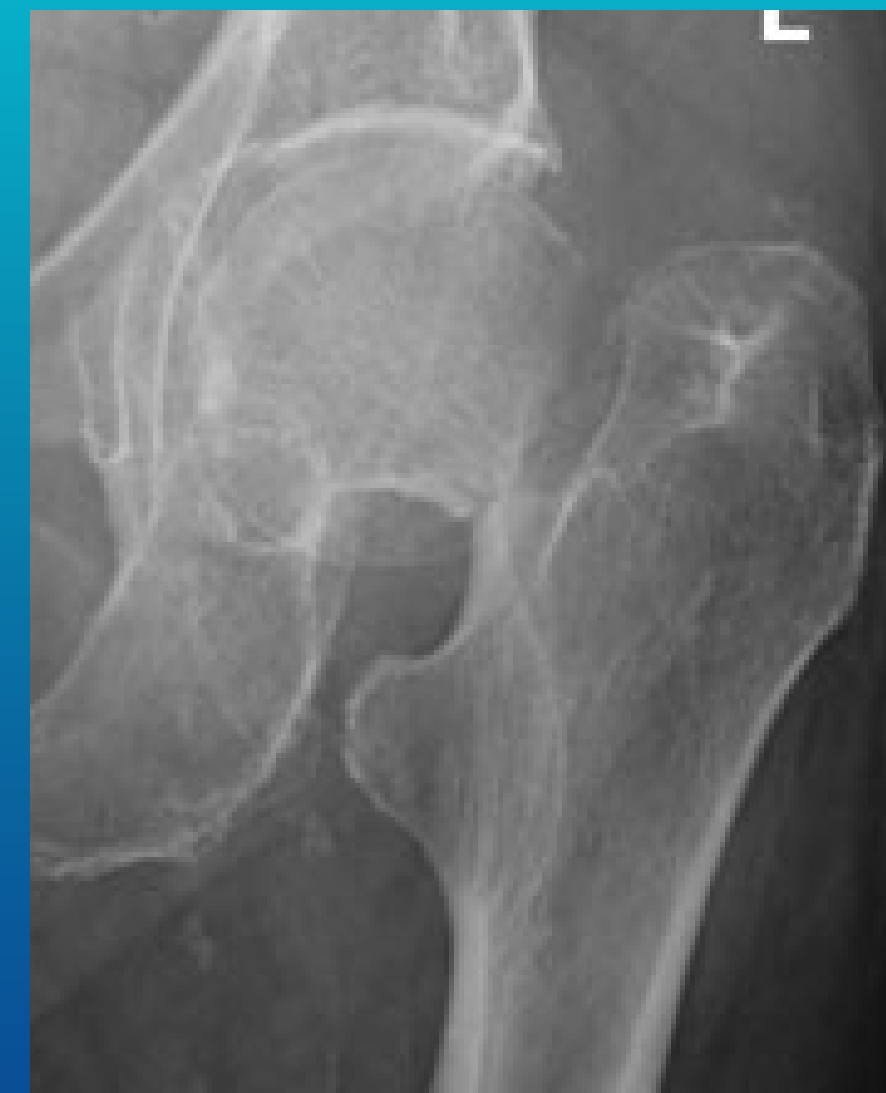I



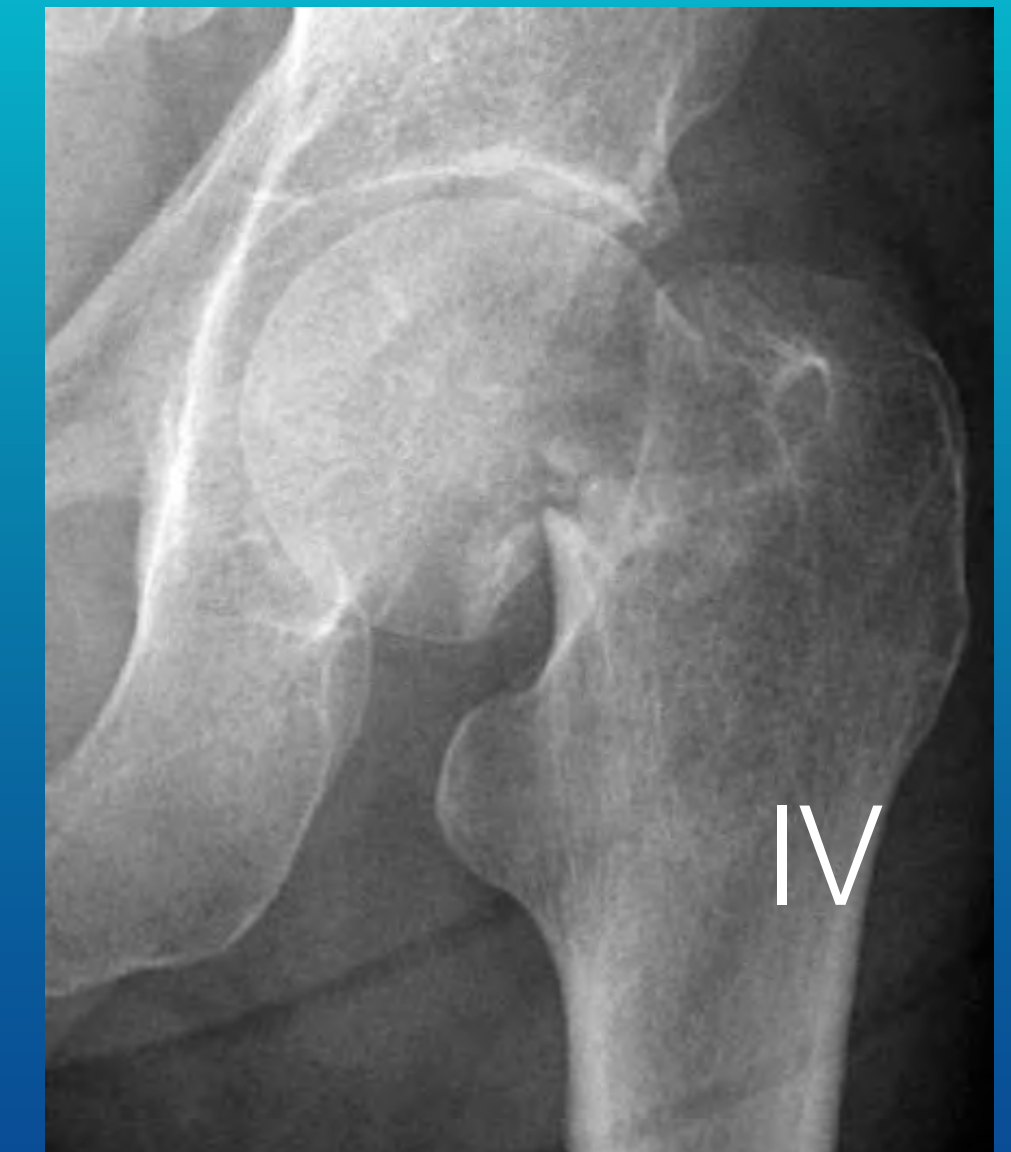II



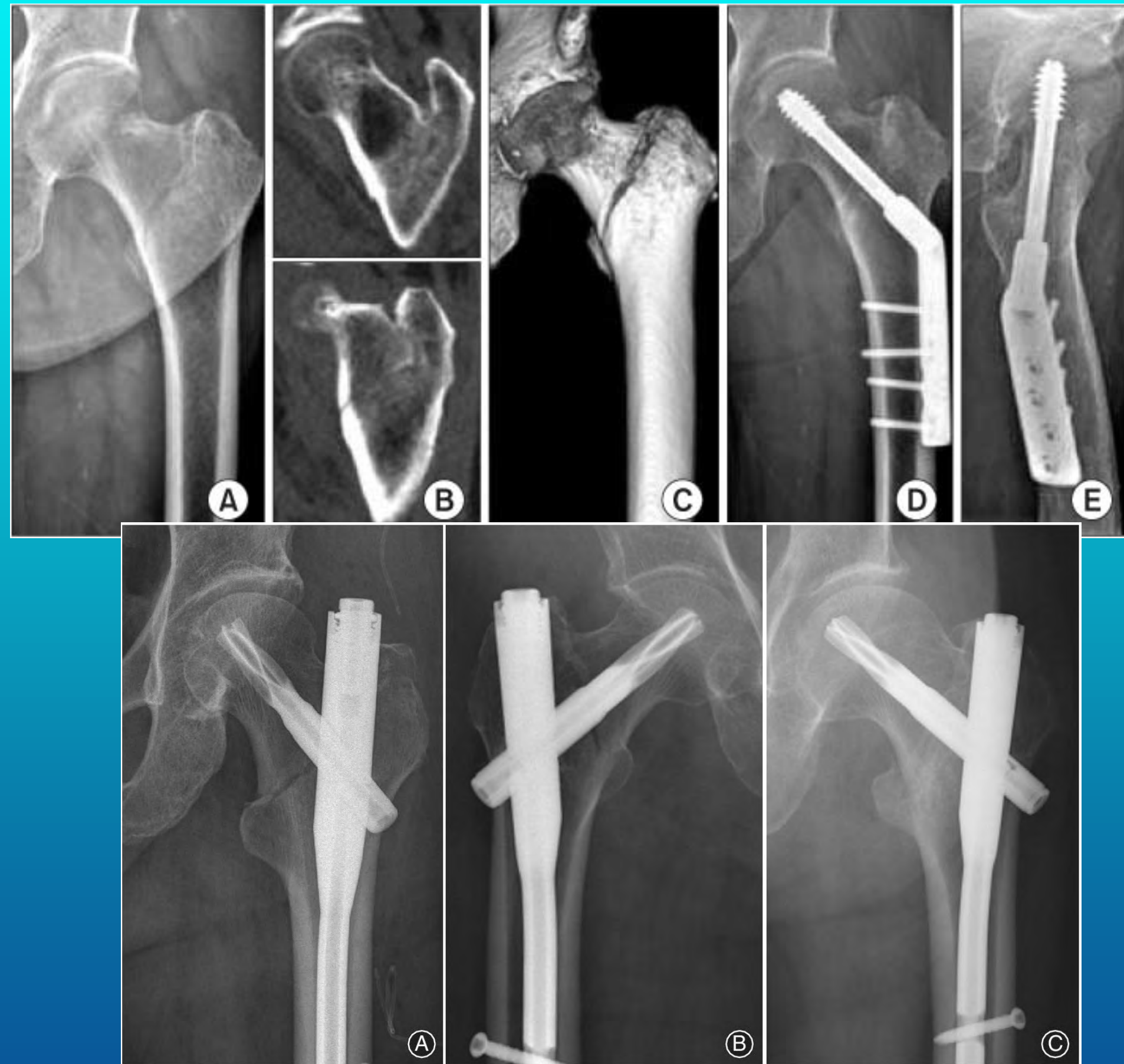
III



IV



Basicervical Femoral Neck fx



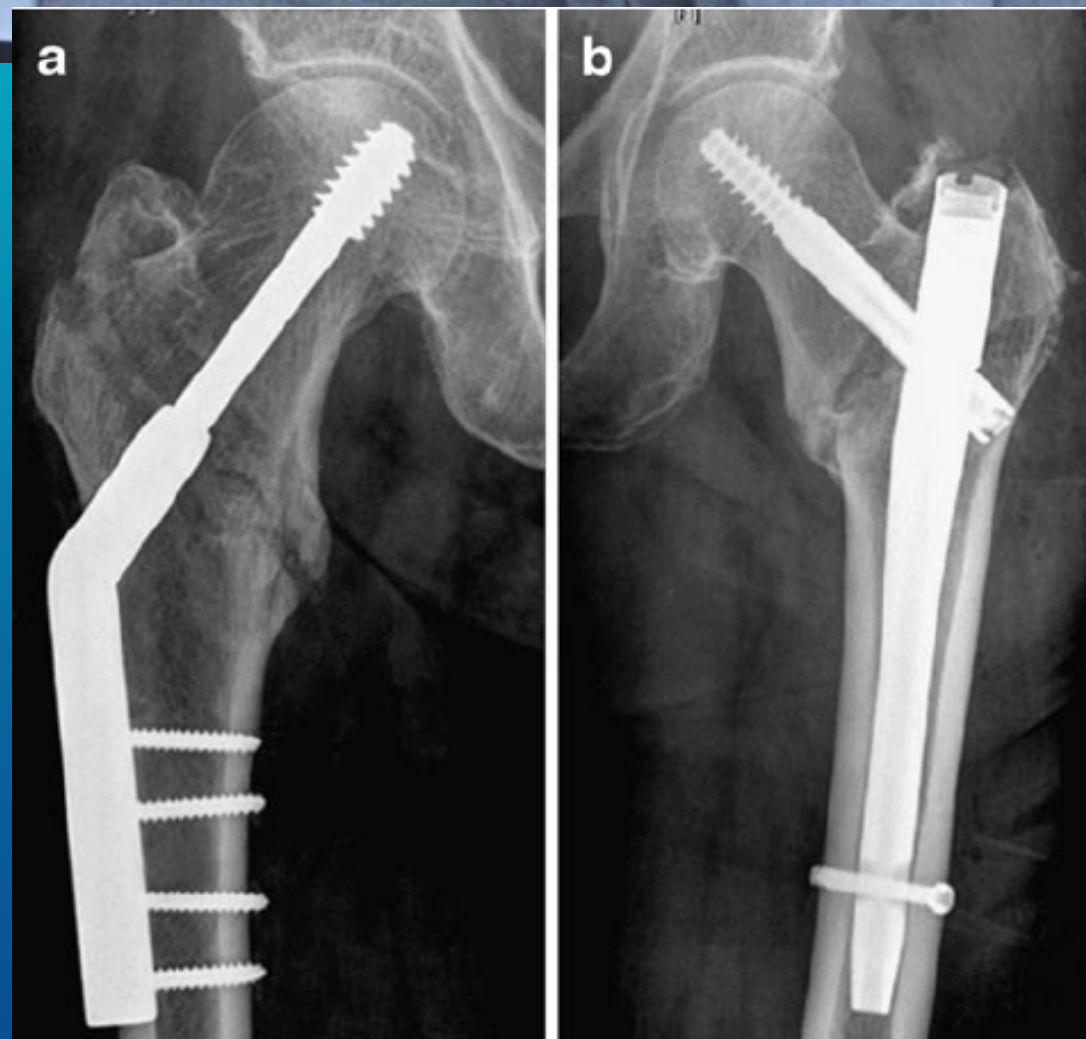
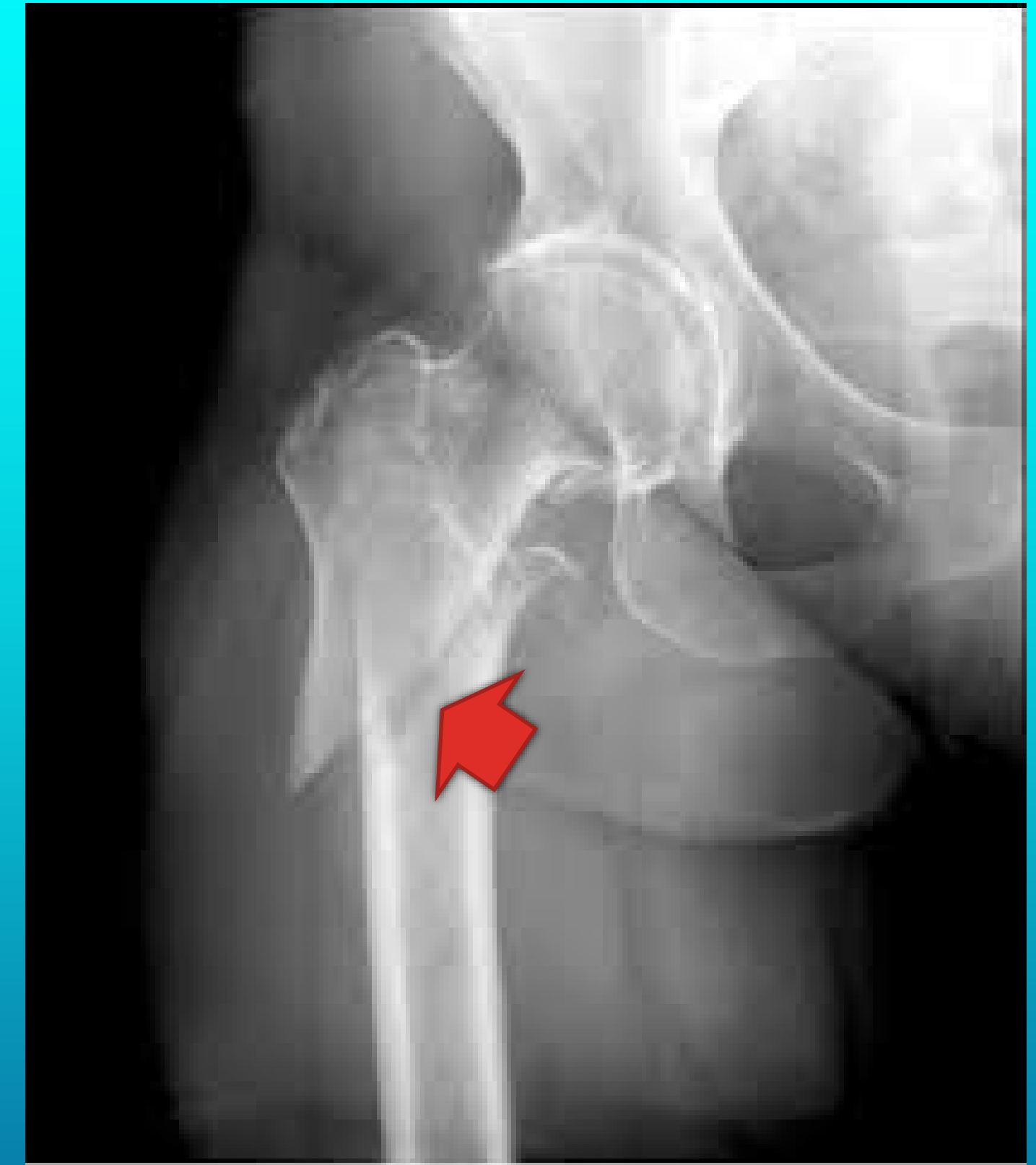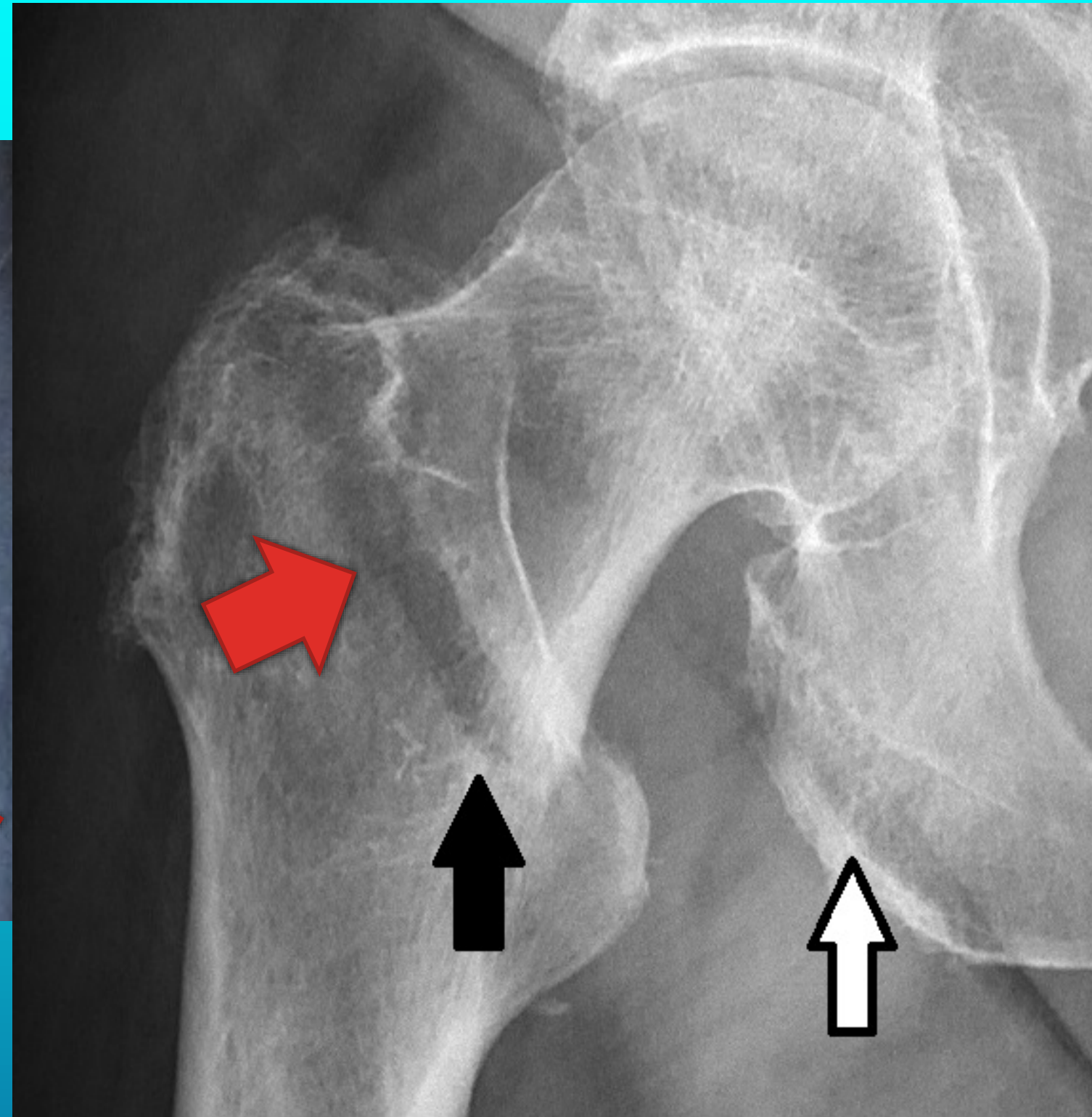
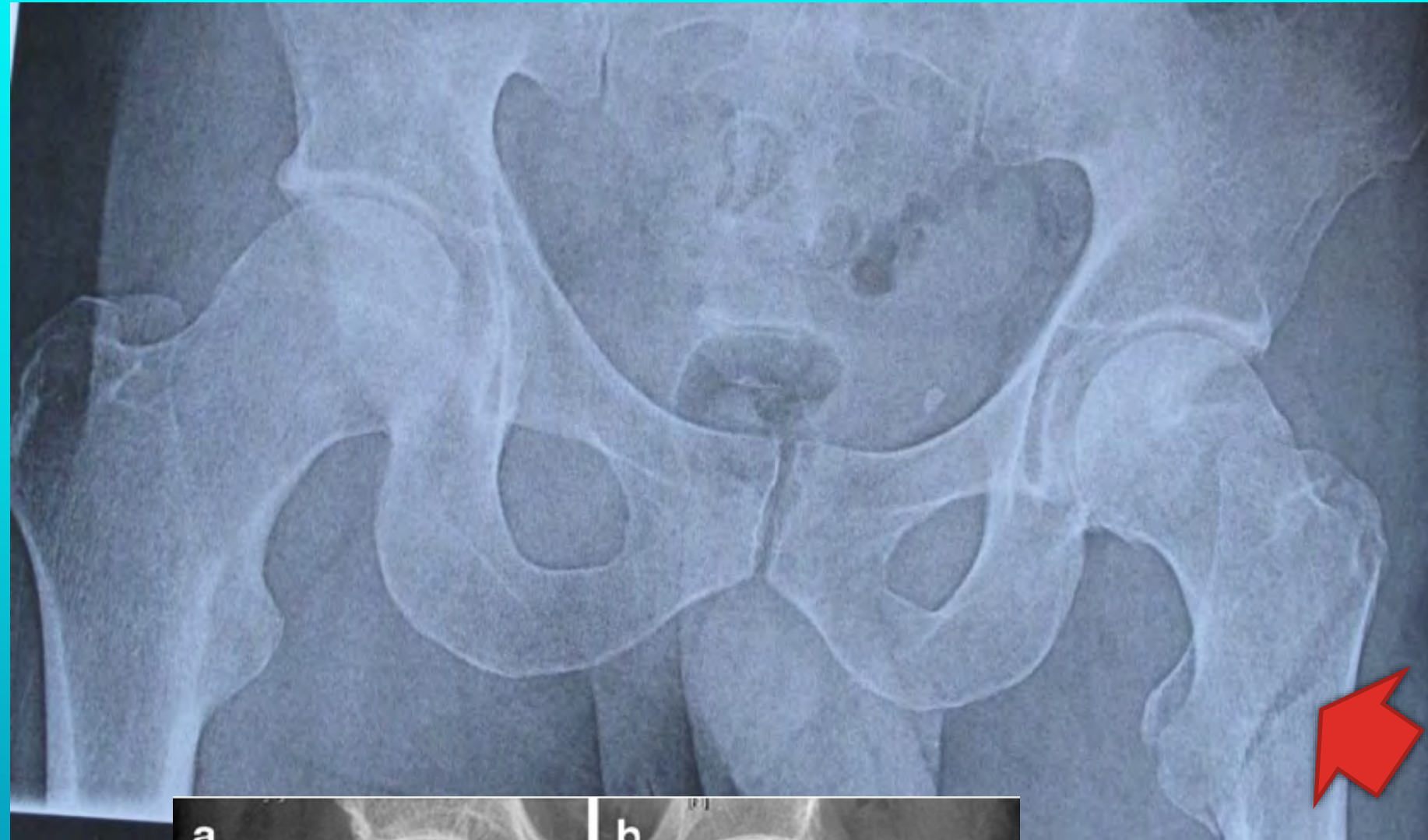
- 1.8% of proximal Femur fx
- Base of the femoral neck & Trochanteric region
- Same considerations at Subcapital Femoral Neck Fx
- Operative treatment

Intertrochanteric Femur fx

Epidemiology

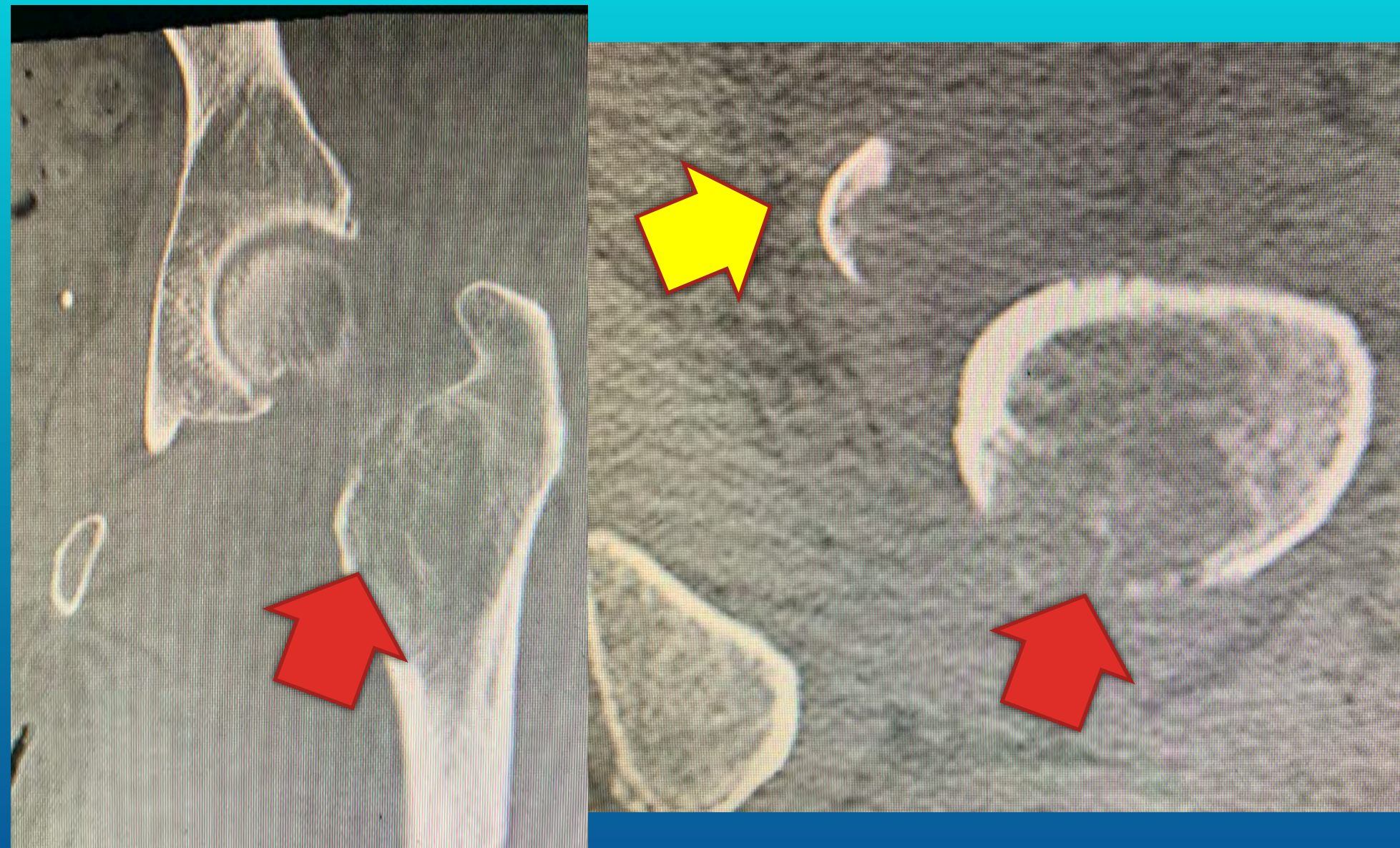- Occurs mostly in geriatric populations
- Very similar characteristics as hip fracture
- Occurs same frequency as femoral neck fractures
- Female: Male - 2:1
- Mortality & Morbidity rates similar to femoral neck fractures
- Inherently unstable fractures especially if involves posteromedial cortex
- Extracapsular:
 - Between greater and lesser trochanter
 - Area between femoral neck and trochanter

Intertrochanteric Femur Fx



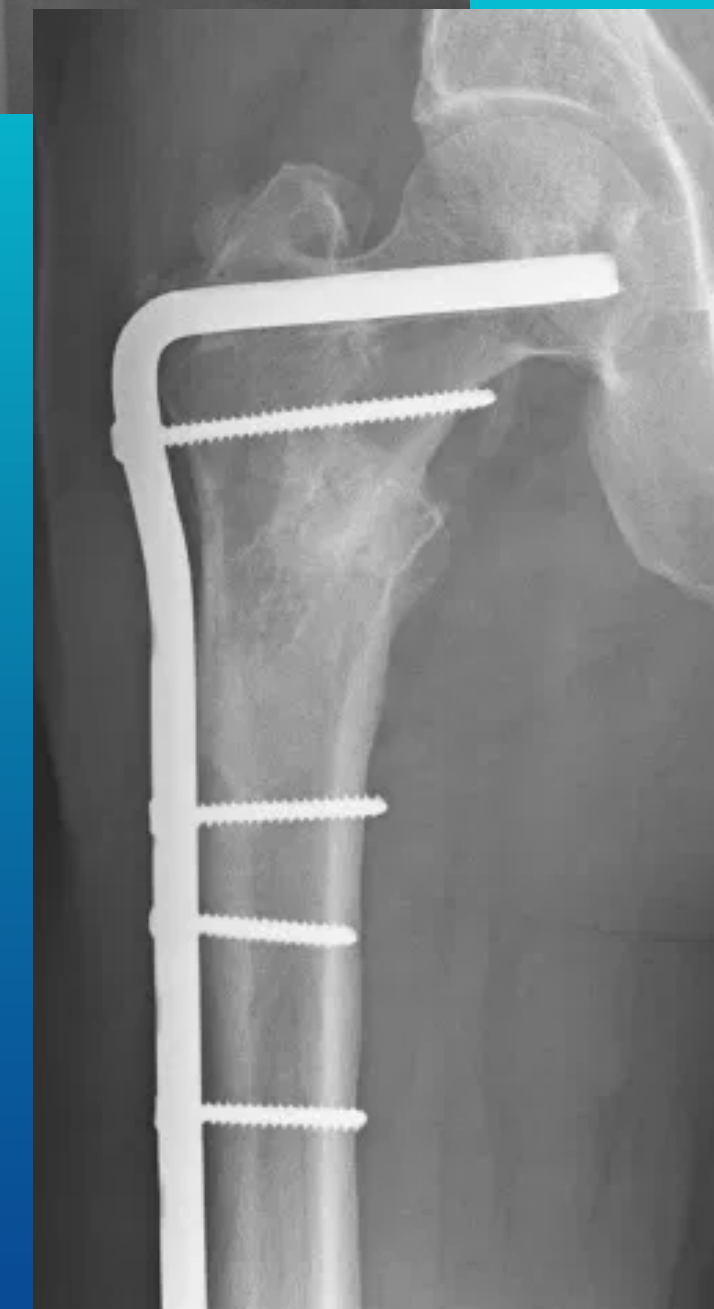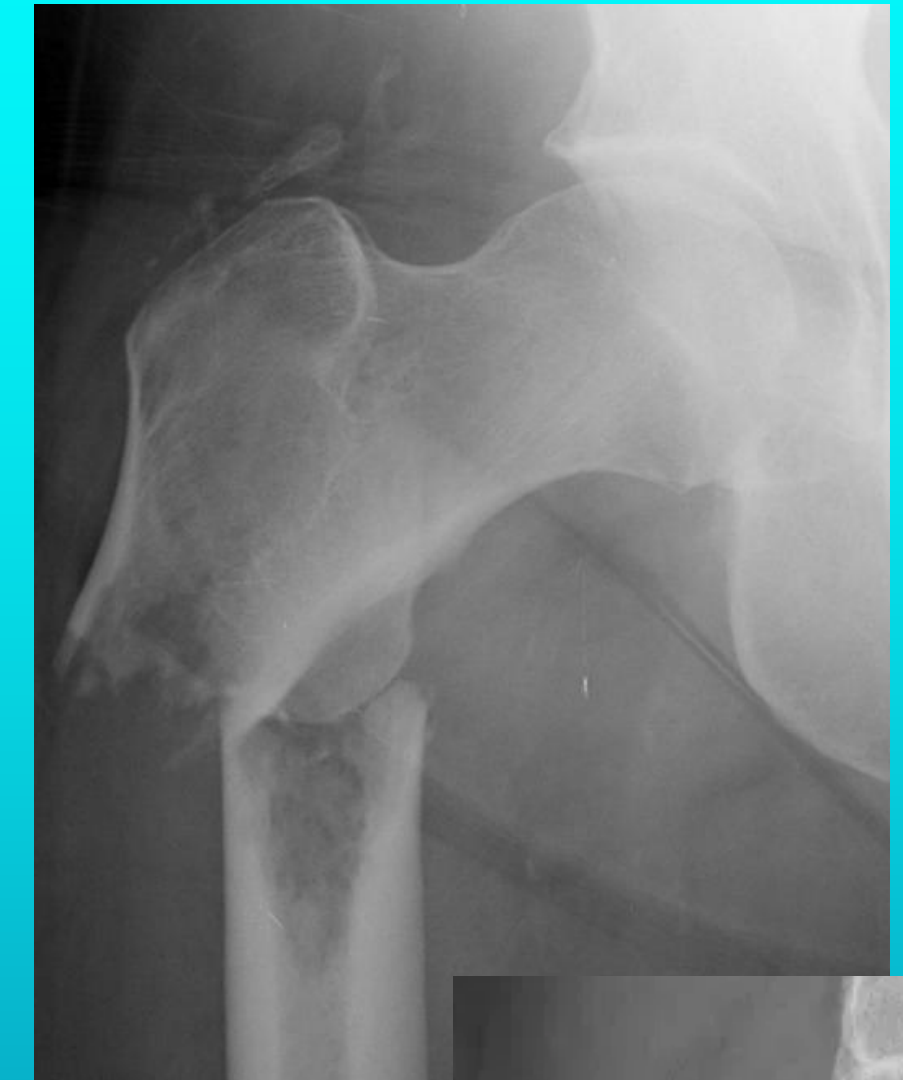Sub-Trochanteric Fx

Isolated Lesser Trochanteric Fx



Traumatic Sub Trochanteric fx

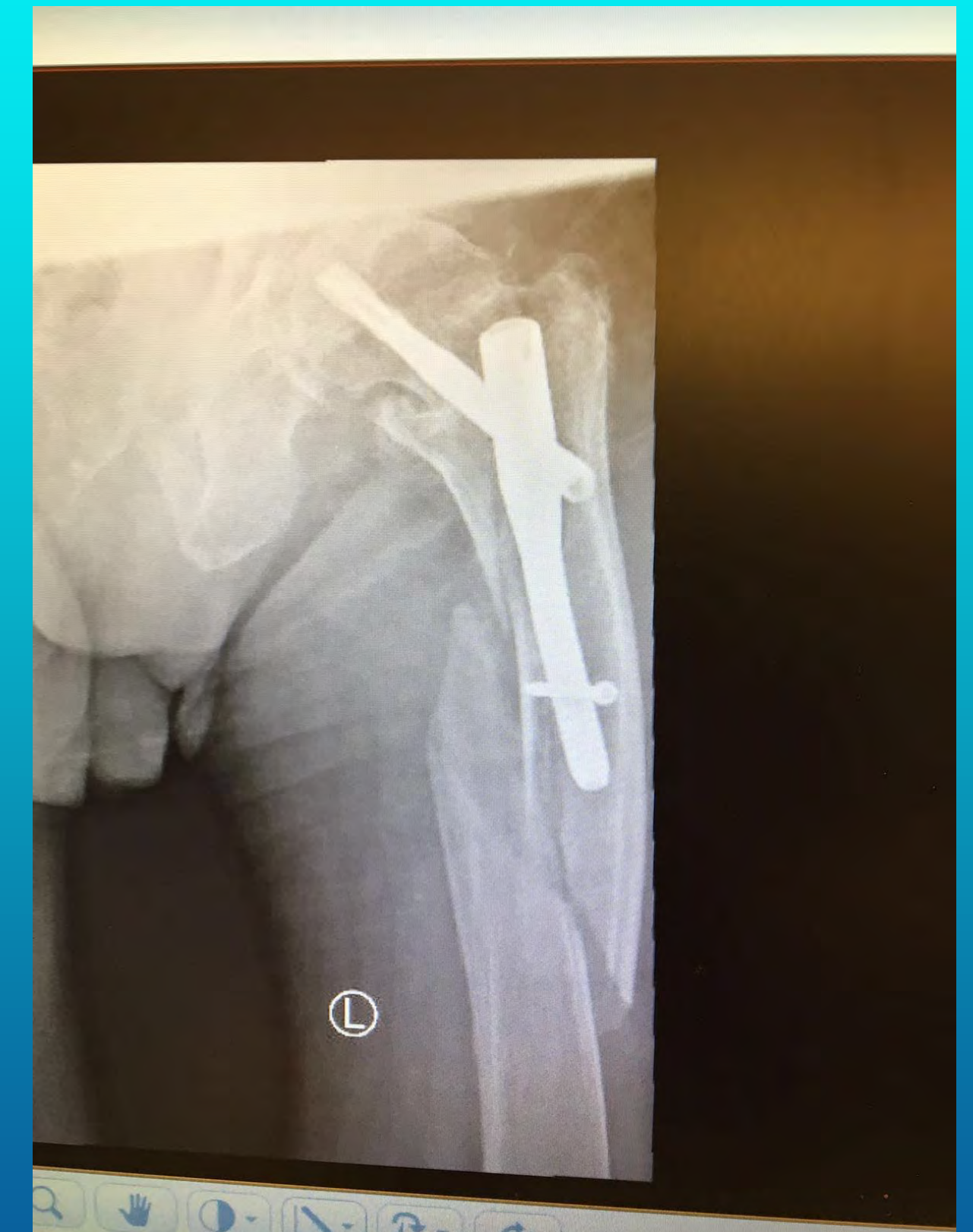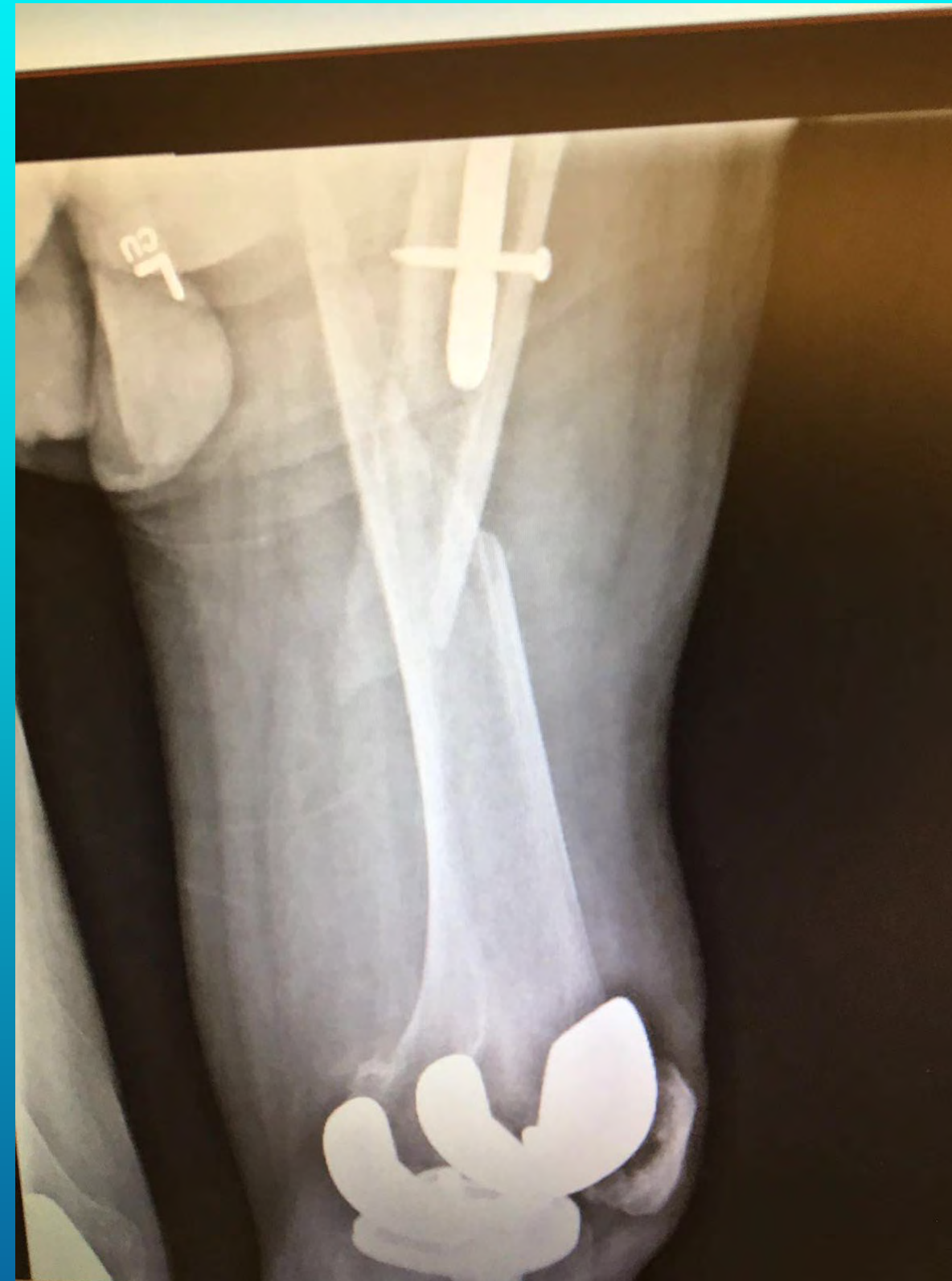- Lesser Troch to 5cm distal
- Trauma/Bisphosphonates
 - Deforming forces
 - Iliopsoas
 - ADDuctors
 - Ext. Rotators
 - X-ray
 - Traction view/pelvis
 - Femur
- Treatment- Surgery



Femur Shaft fx

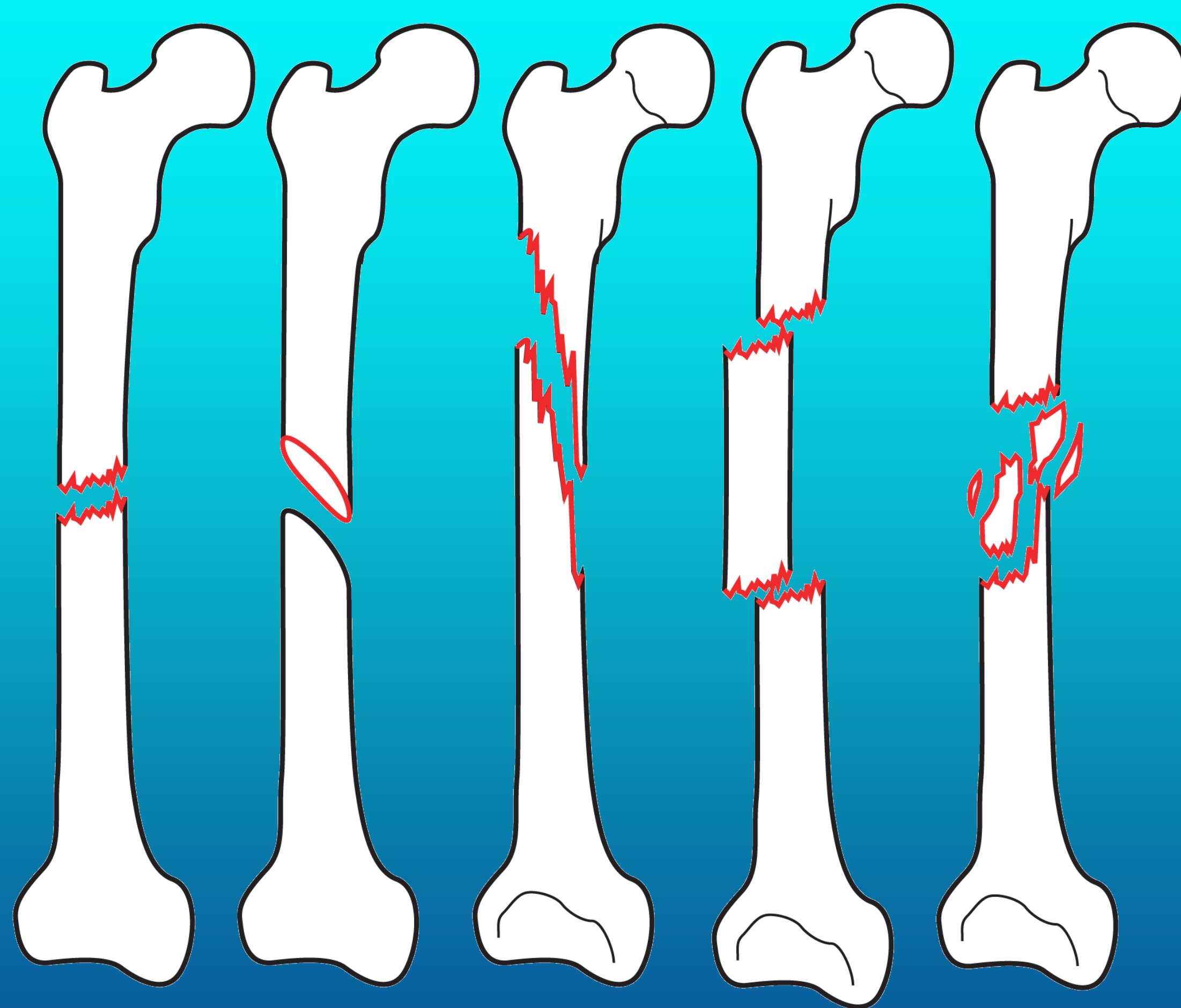
Femur Shaft Fractures

- General
 - Occurs more in young adults
 - **High energy**
 - MVA/motorcycle
 - Pedestrian vs. auto
 - Fall
 - Gunshot wound (GSW)
 - **Stress Fracture**
 - Runners or repetitive stress
 - Risk with increasing physical activity
 - Long-term Bisphosphonates use
 - **Transverse pattern:**
 - **Most common femur shaft fracture**
- Fracture may involve total hip arthroplasty (THA) components



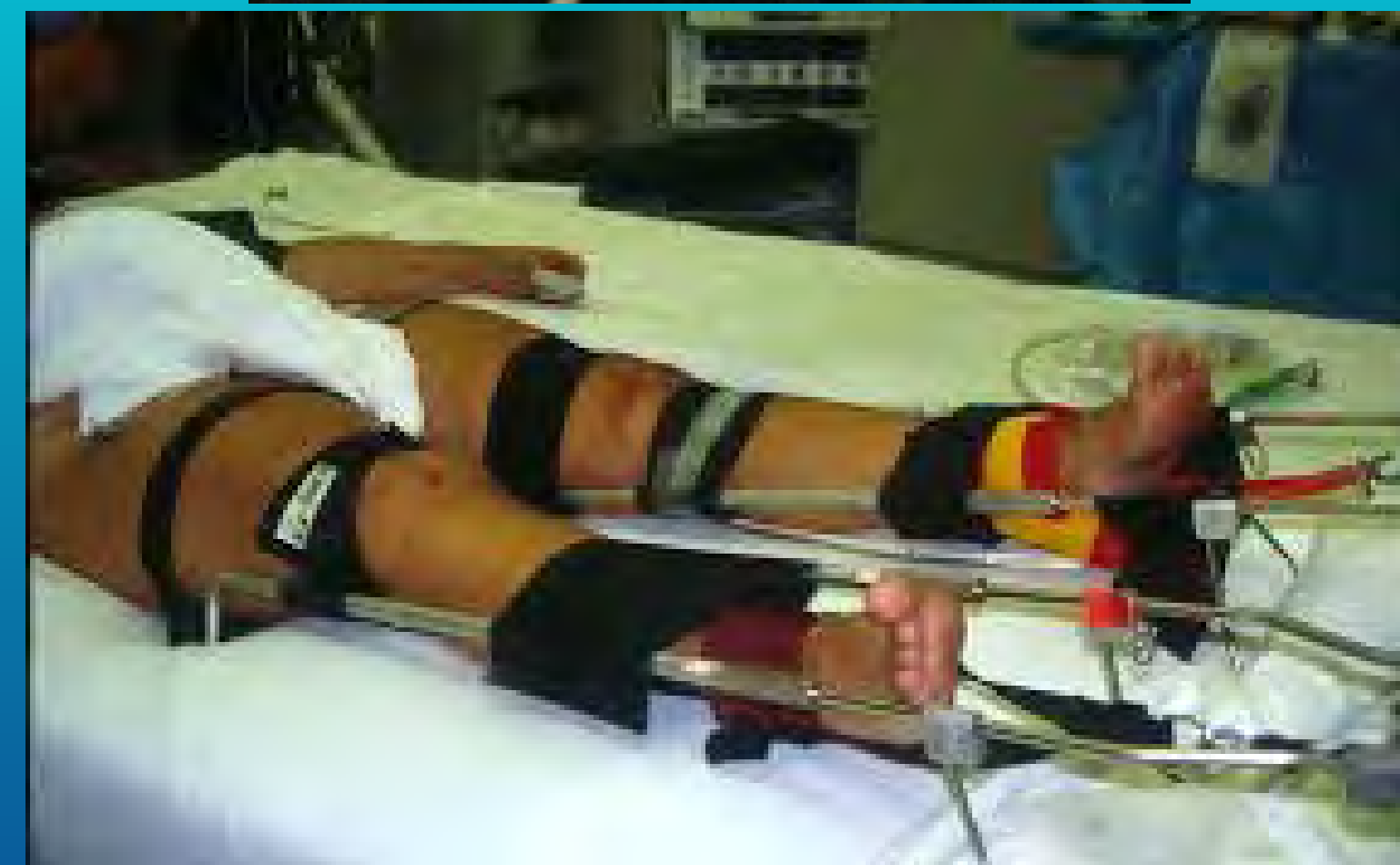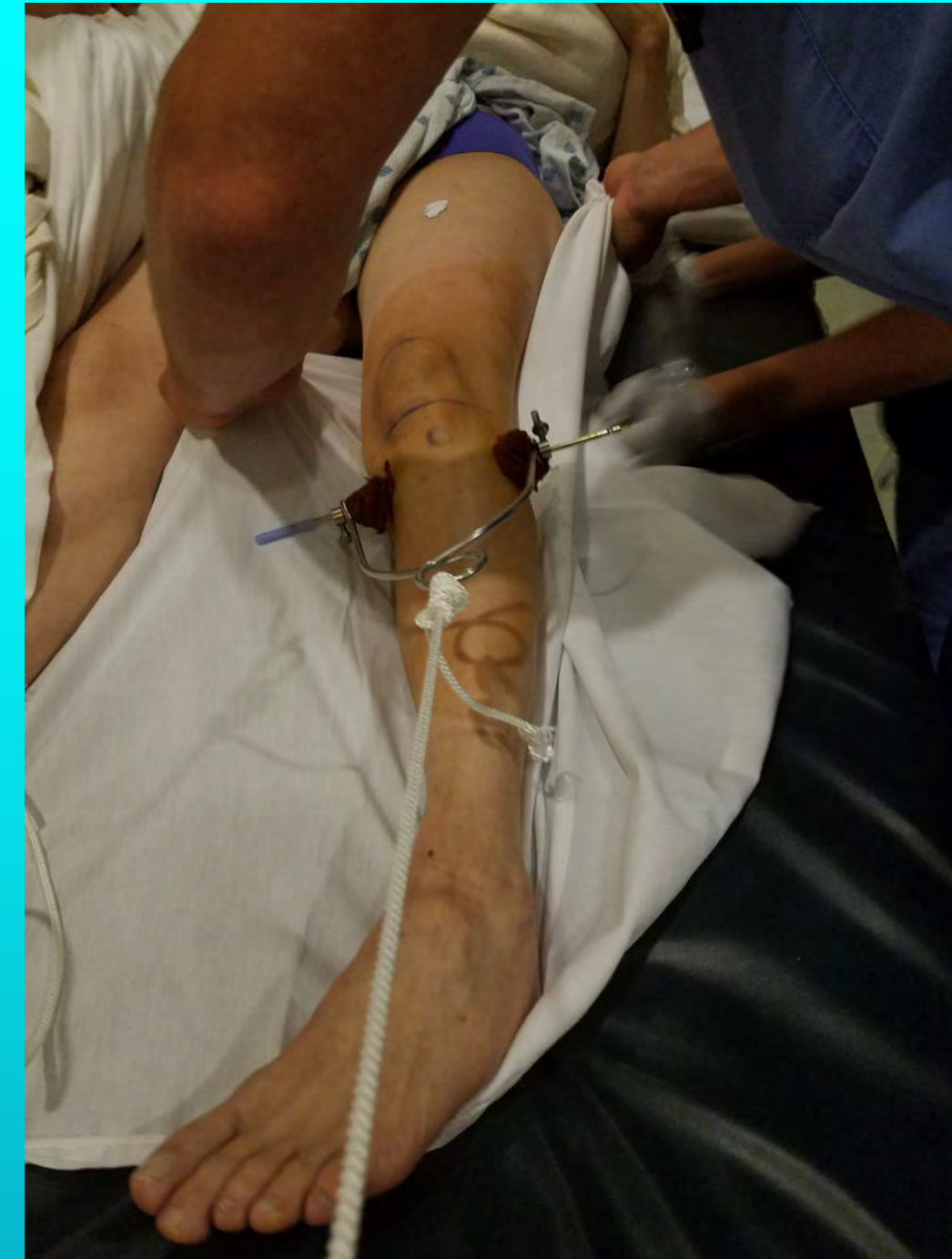Femur Shaft Fractures

- Fracture pattern
 - Transverse
 - Oblique
 - Butterfly
 - Segmental
- Comminuted
- Location
 - Proximal
 - Middle
 - Distal
- Supracondylar



Femur Shaft Fractures

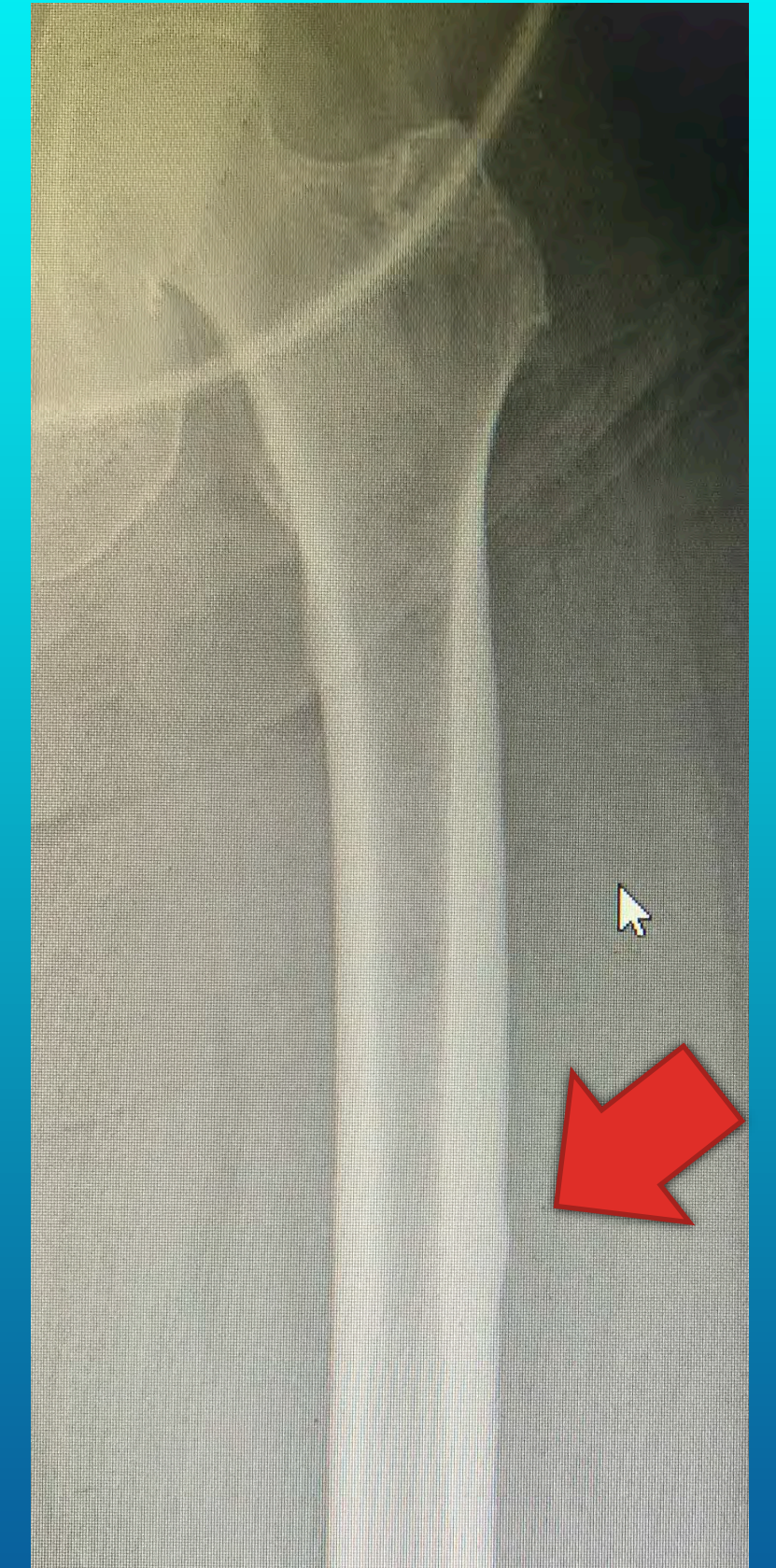
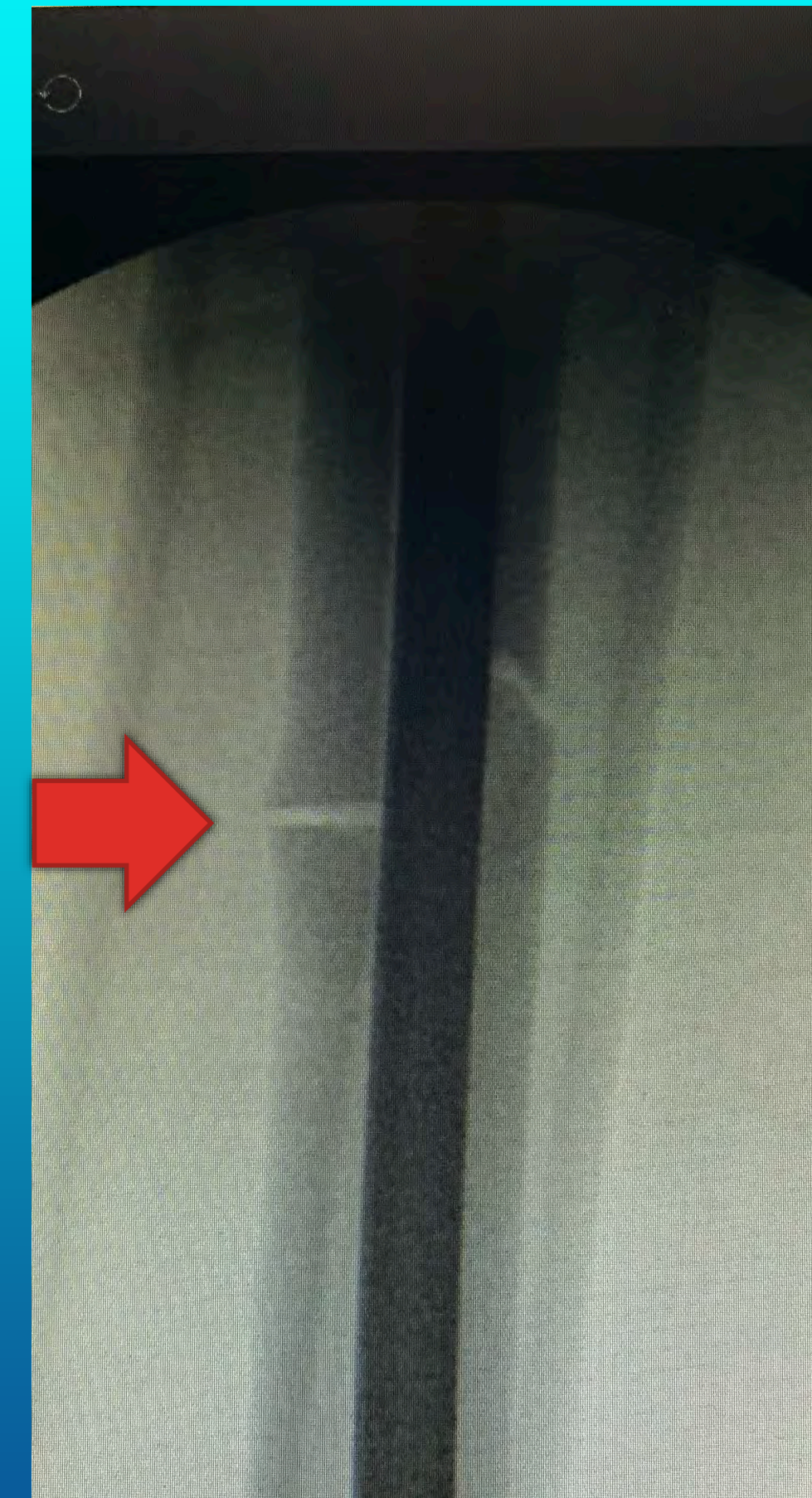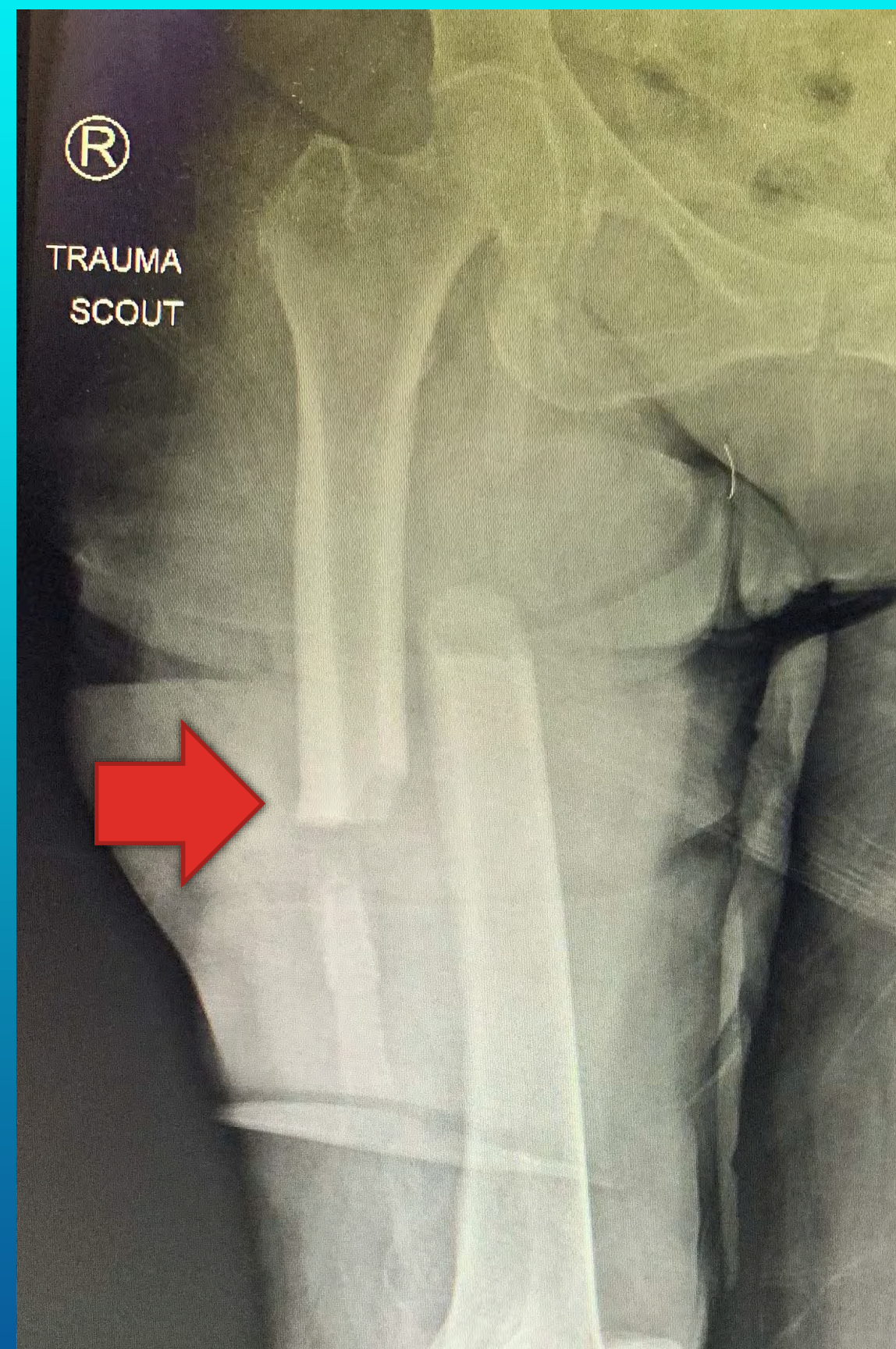
- Treatment:
 - Emergent Treatment:
 - Identify life-threatening injuries
 - Good assessment of neuro and vascular status
 - Check for associated fractures/injuries
 - Check for compartment syndrome thigh
 - Immobilize fracture until surgery
 - Immediate OR: long posterior splint (temporary measure) or traction splint
 - Prolonged OR: skeletal traction

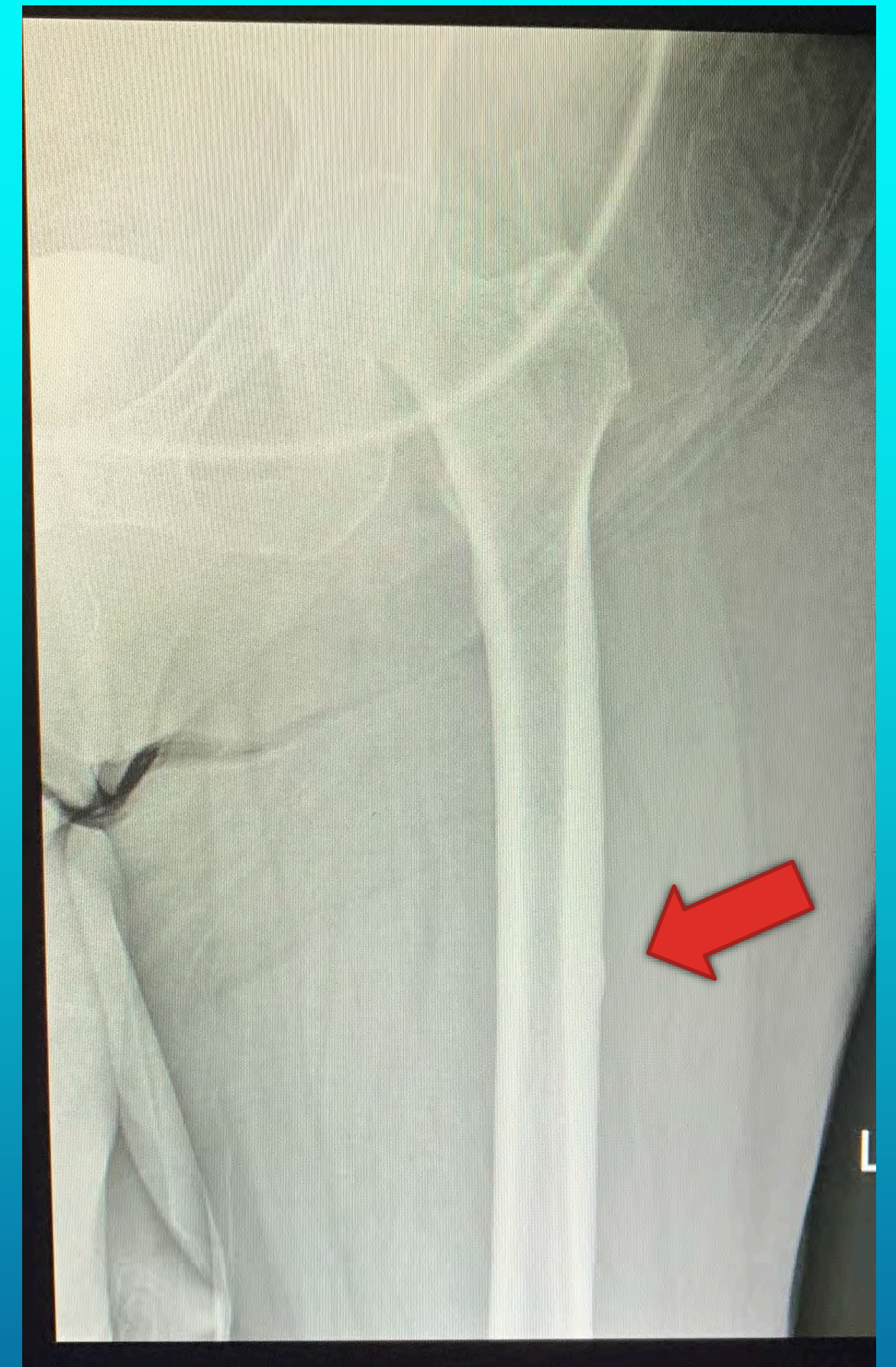
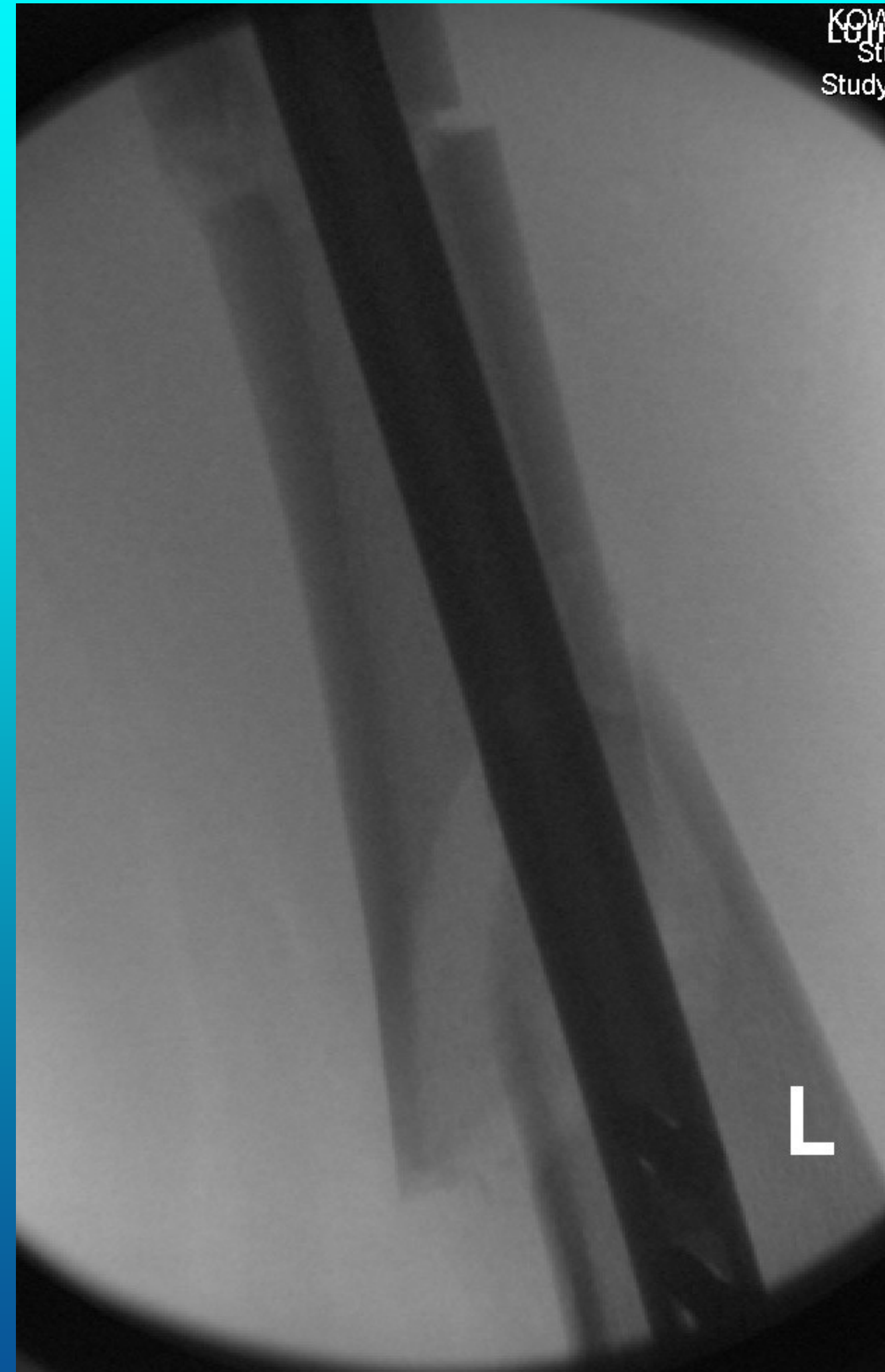
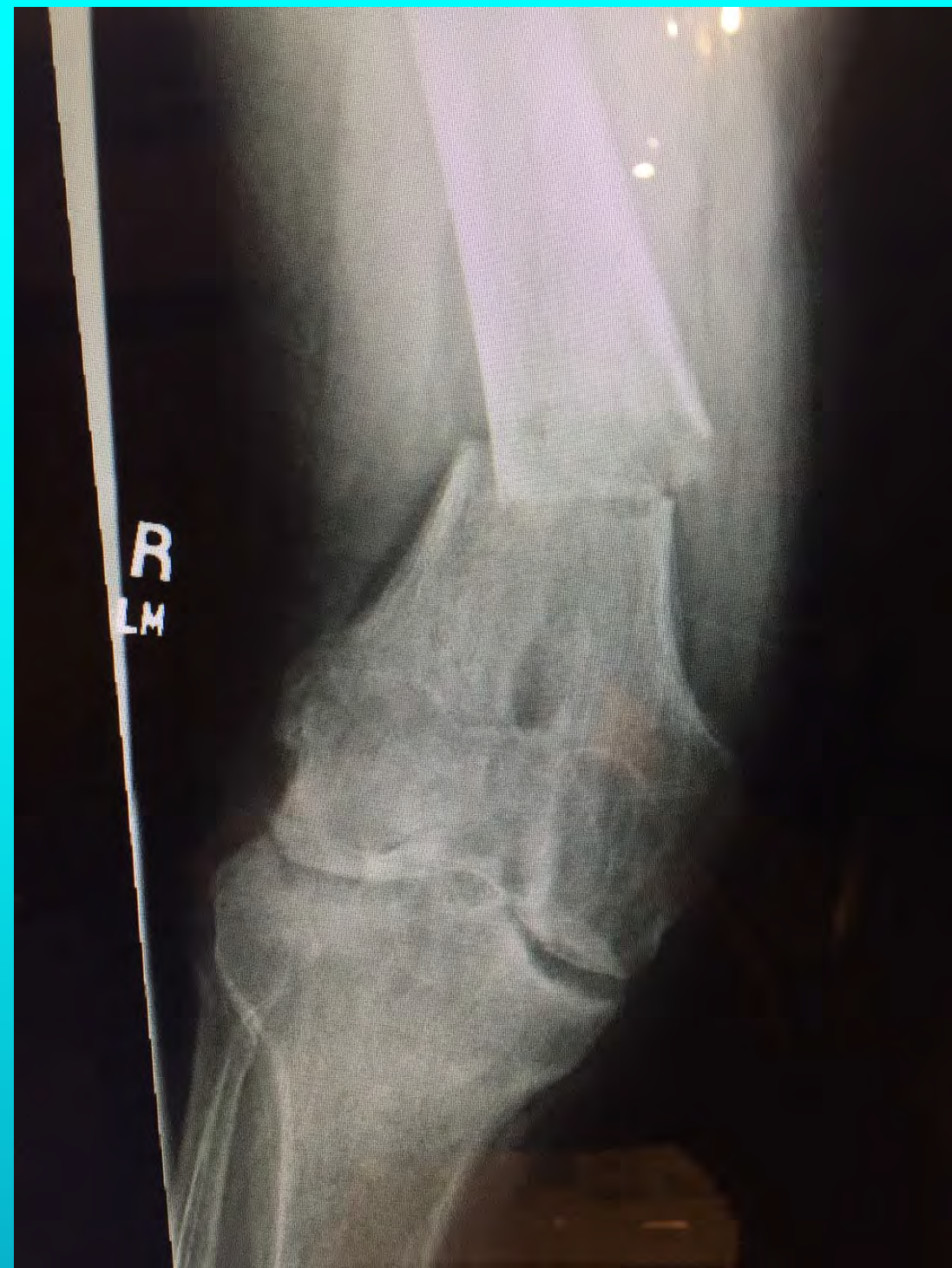
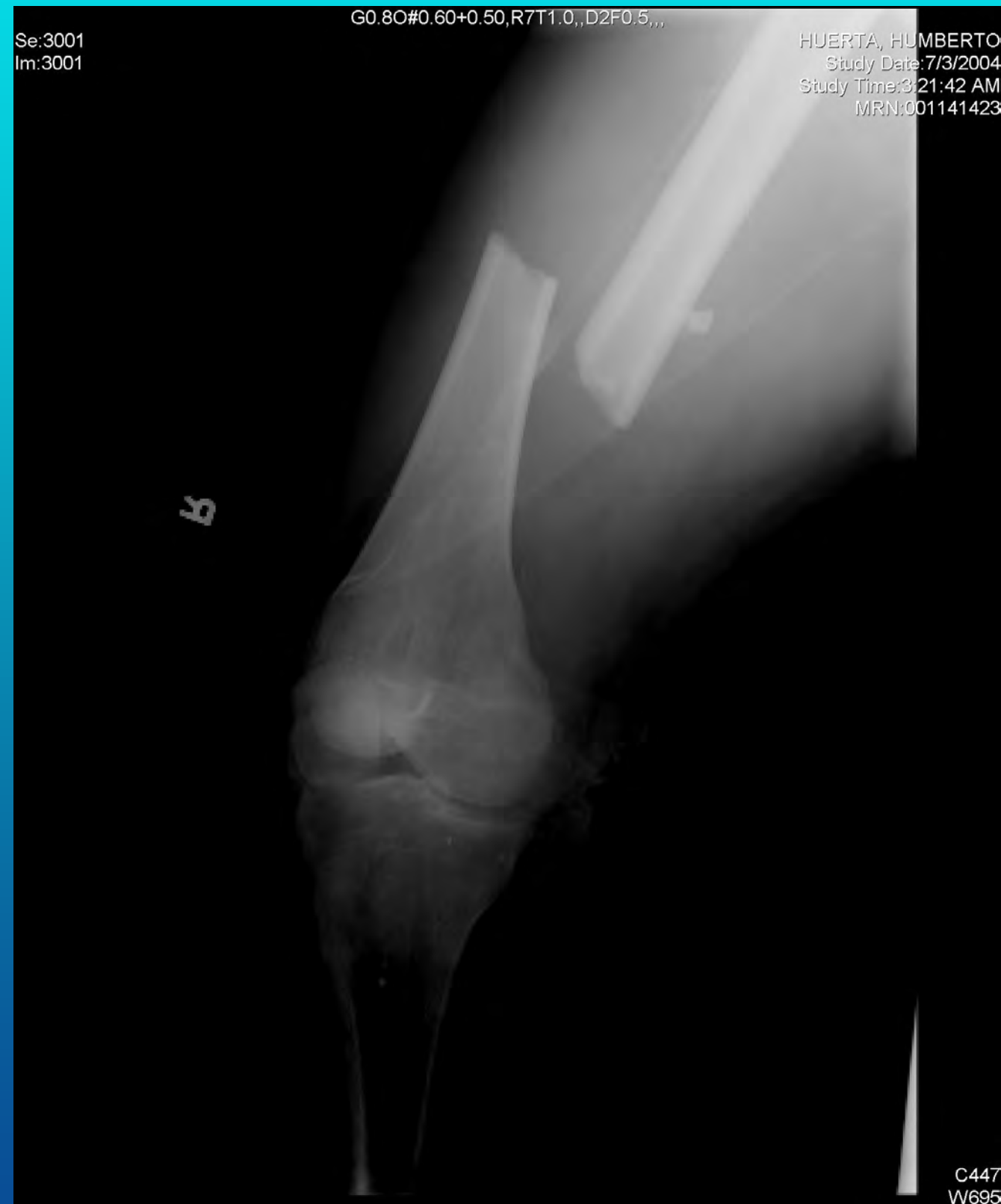Sub-Trochanteric Fx

Bisphosphonate related-Fx

- Treat osteoporosis
- Duration >5 yrs increases risk
- Asian > White
- Shorter, Heavier
- Taking DM meds >1 yr





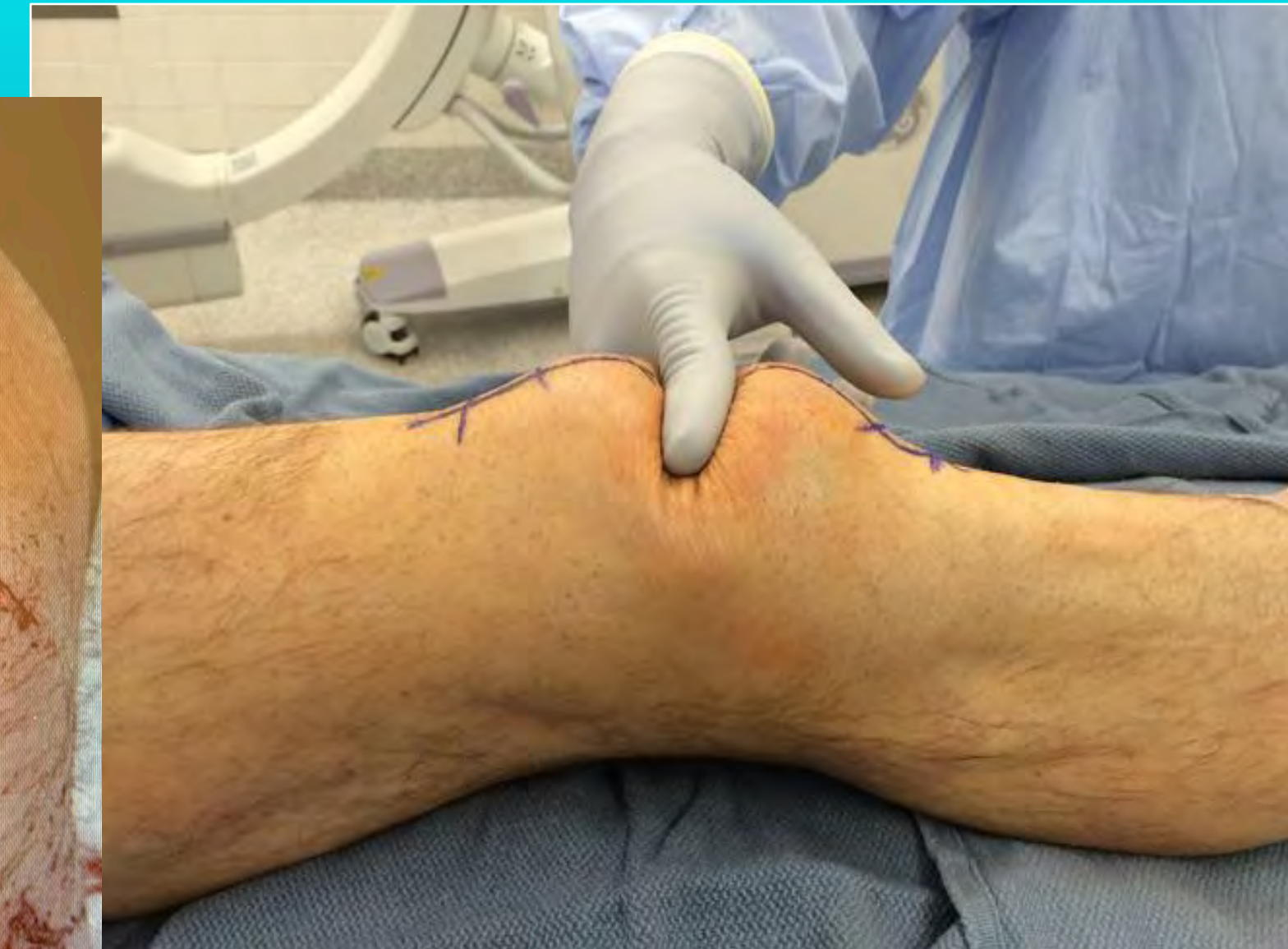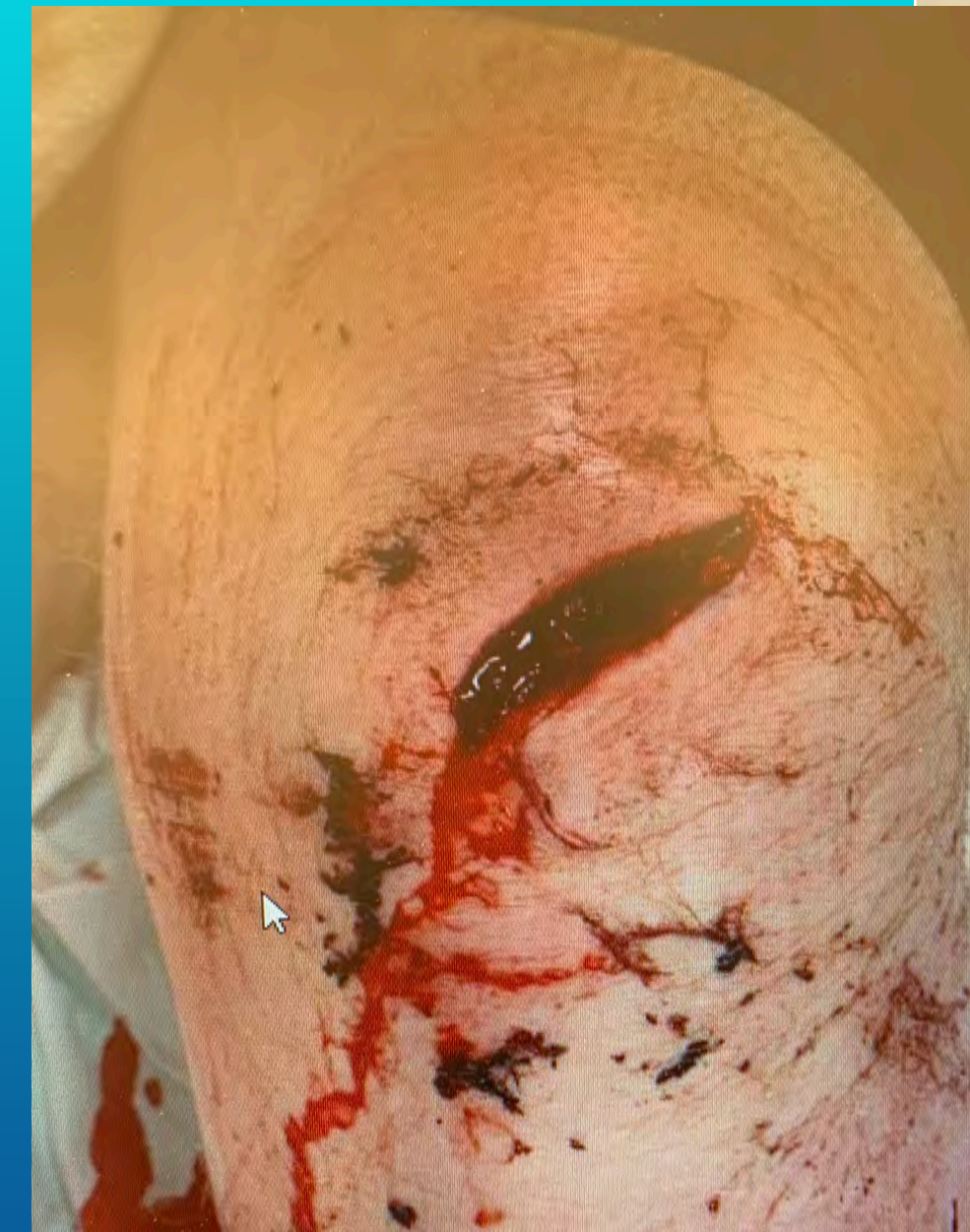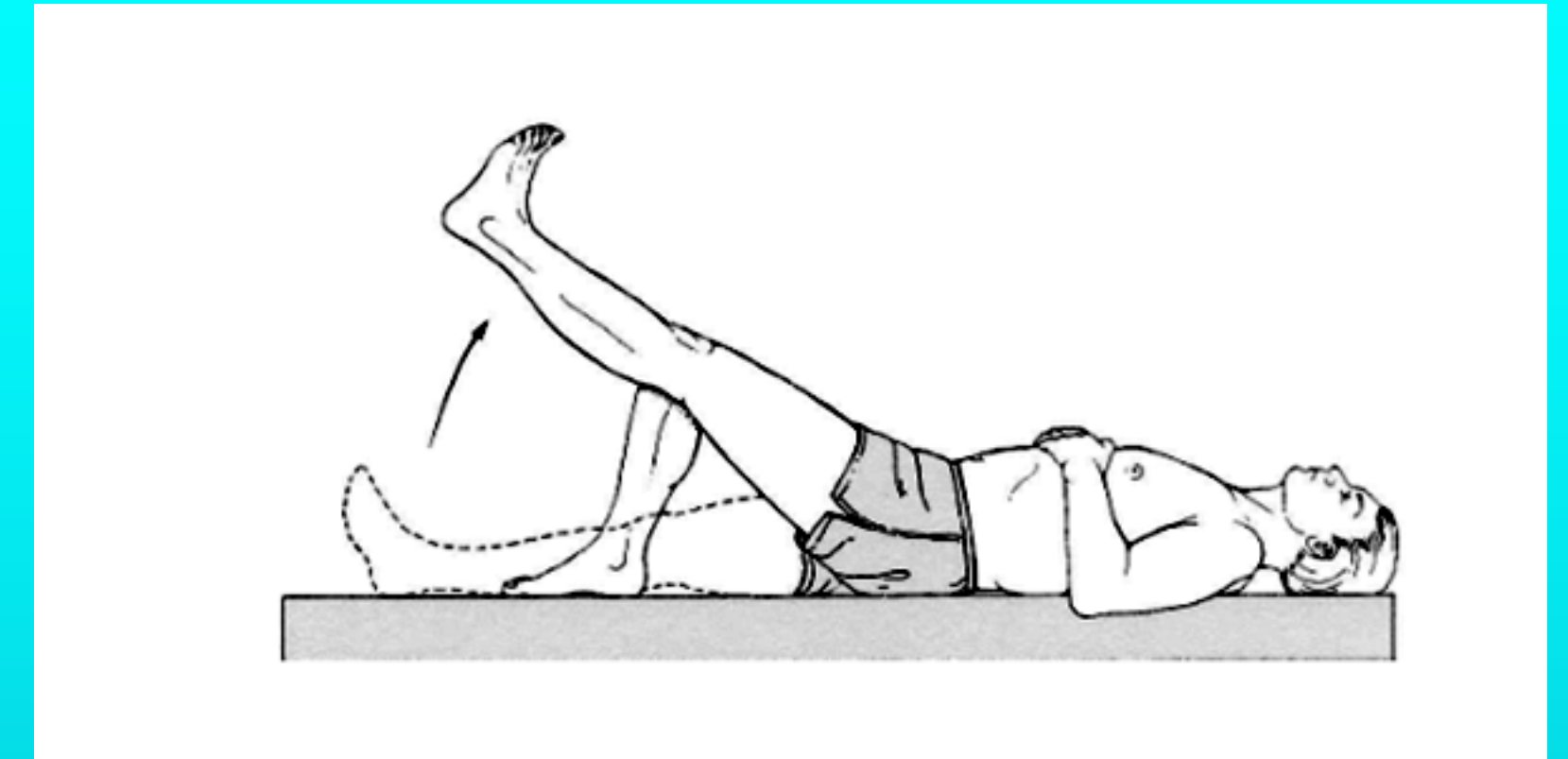
Patella fx

Patella fx

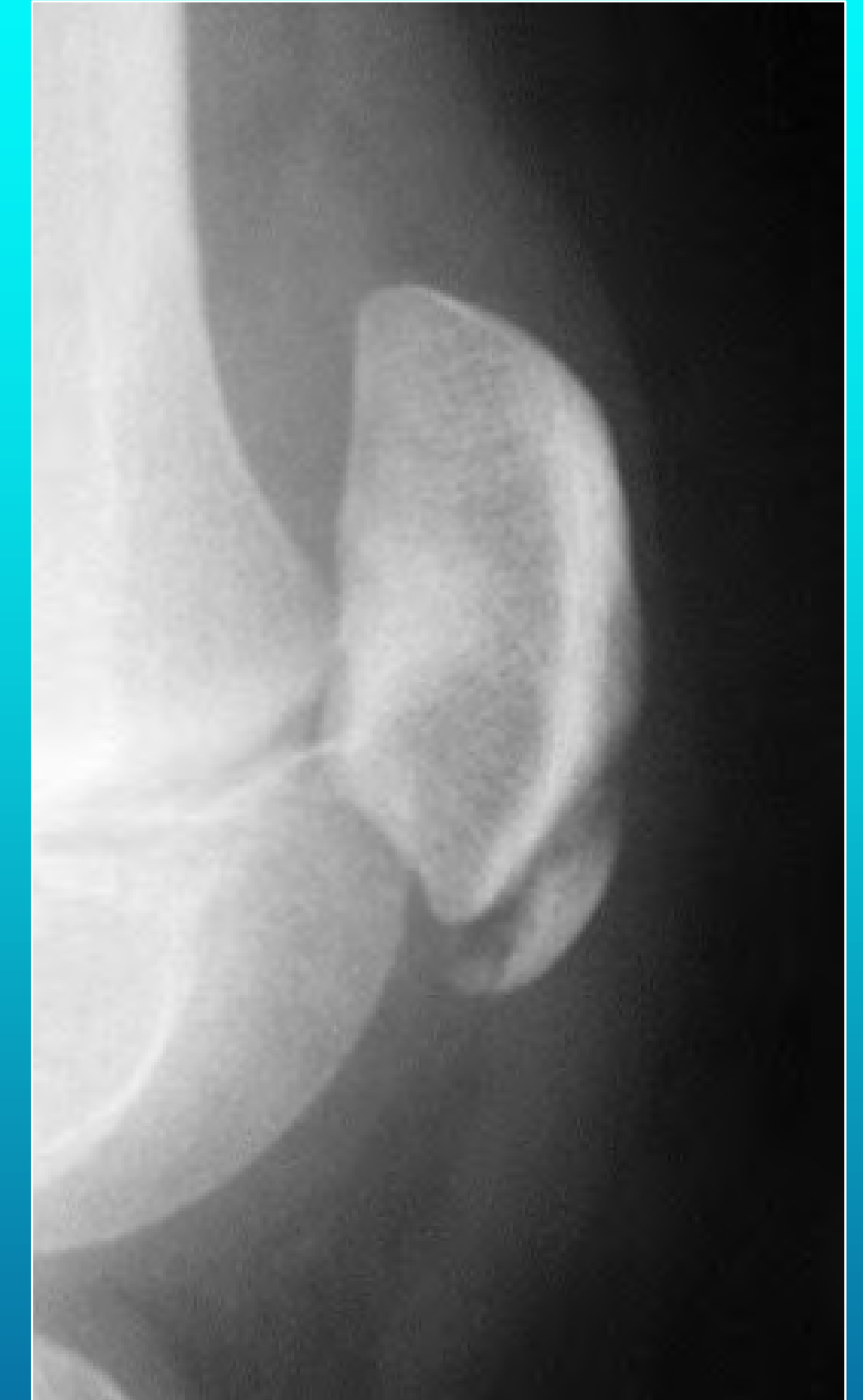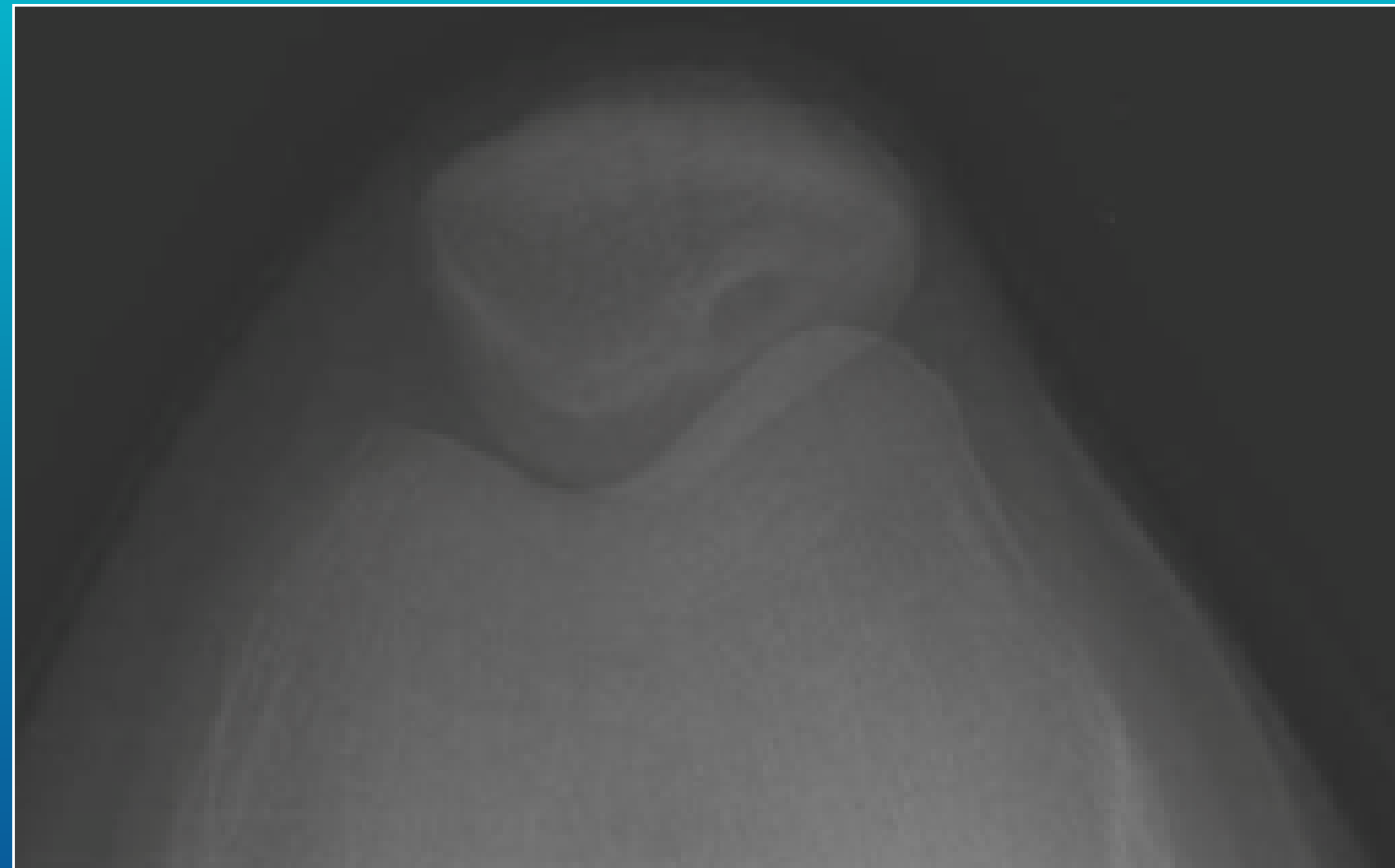
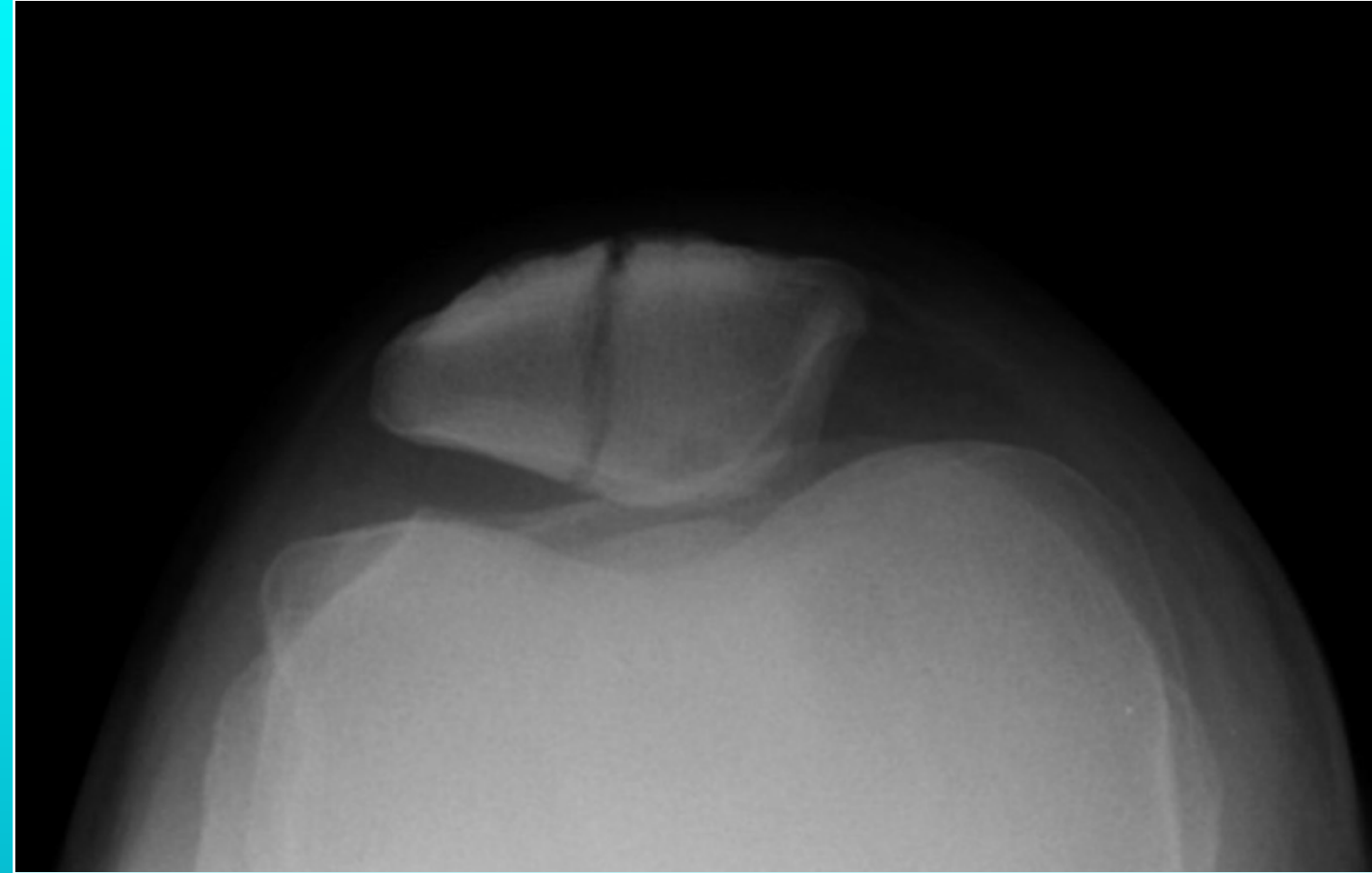
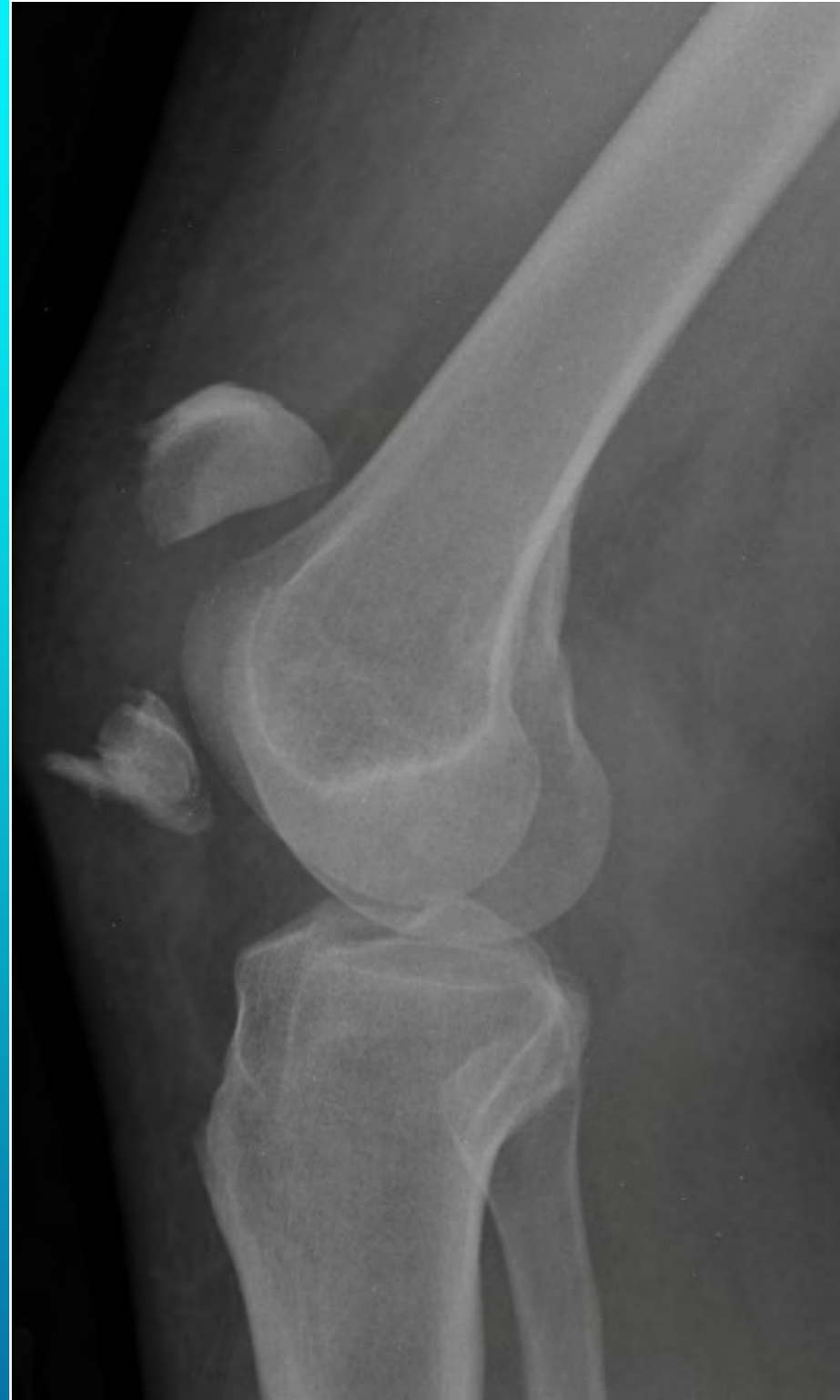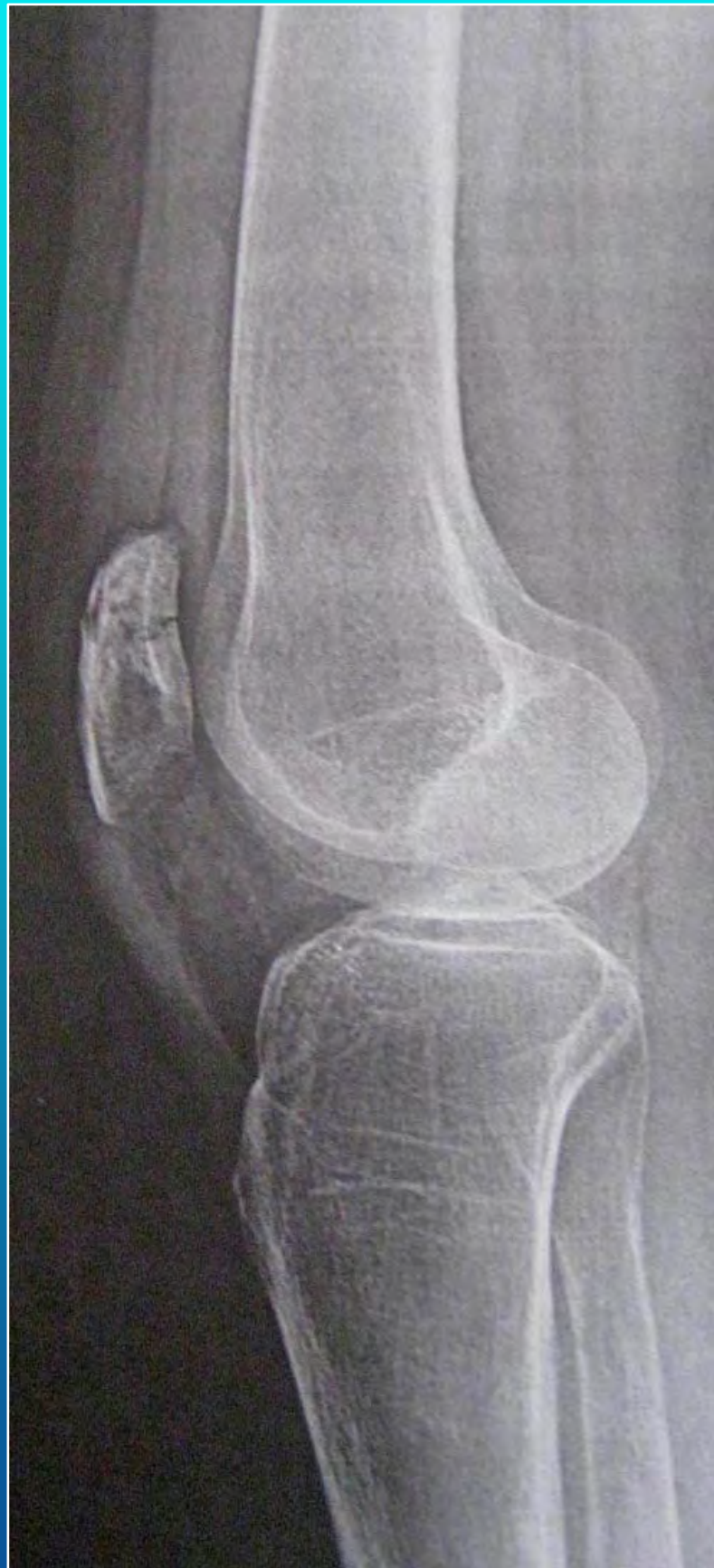- Direct blow- primary mechanism of injury
- High energy: dashboard/MVA is most frequent cause (78.3%)¹
- Indirect blow-
 - Forceful knee hyperflexion & eccentric quadriceps contraction
 - Example: Jump/fall with patient landing on their feet combined with an eccentric contraction of the quads³
 - 35% indirect blow fractures do not disrupt extensor mechanism
- Periprosthetic patella fractures after TKA⁴
 - 0.68% in non-resurfaced patella
 - 21% in resurfaced patella

Patella fx

- Visible/ palpable defect between bone fragments
- Hematoma/ hemothrosis that communicates with joint
- Complete inability to actively extend the knee (likely also correlates with tearing of the medial/ lateral retinaculum)
 - If retinaculum is intact, patient may be able to extend knee with a patella fracture



Patella fx



Patella Fractures

- Sleeve fracture
 - Seen only in pediatric age pts.
 - Osteochondral injury where articular cartilage of patella and tendon separate from patellar body
- Ossification patella begins between age 3-5 yrs
- Distal pole patella most common location (superior)
- Commonly seen kids ages 8-15yrs
 - Peak age 12-13 yrs age
 - Boys 3:1 ratio vs. girls

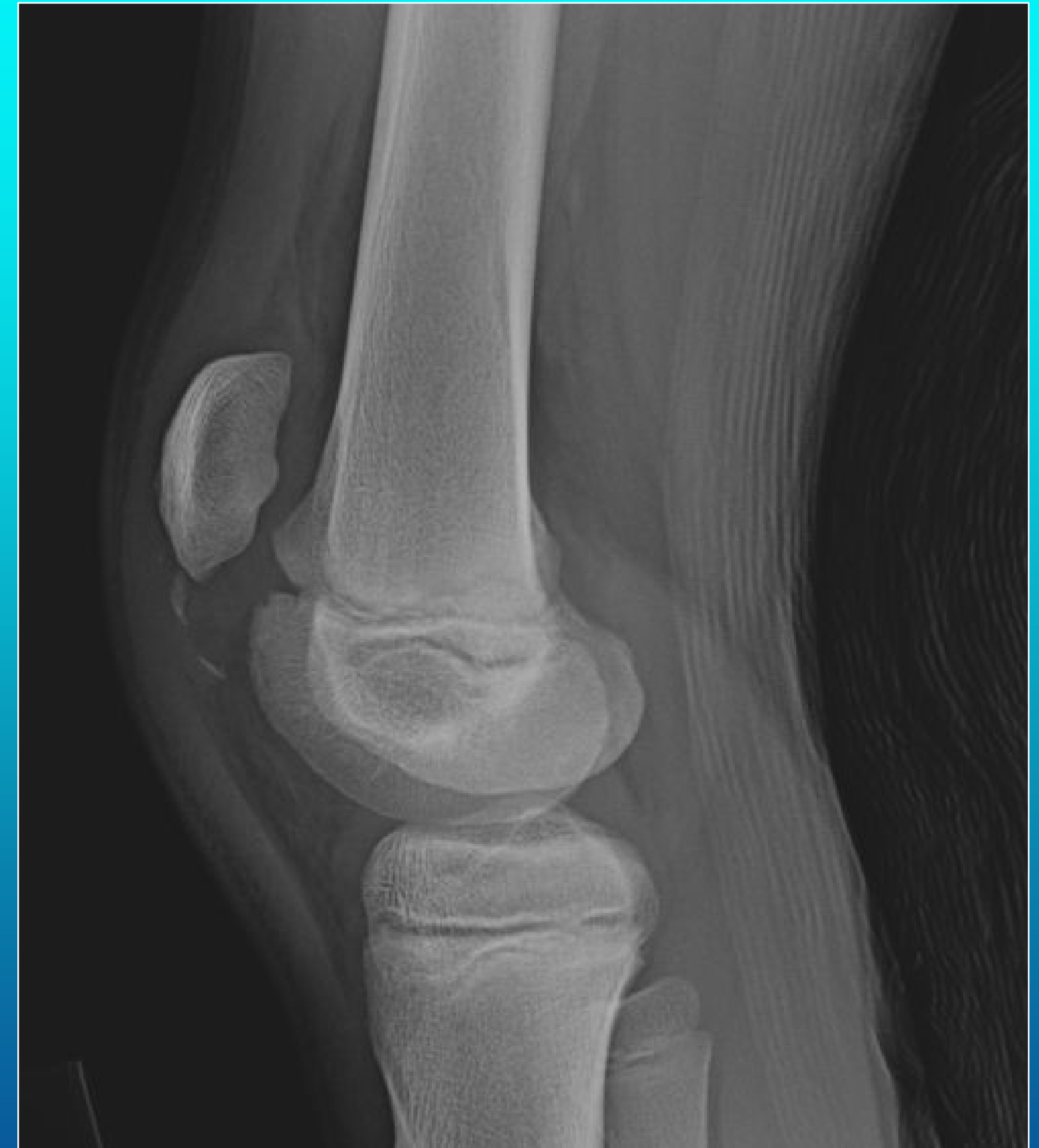
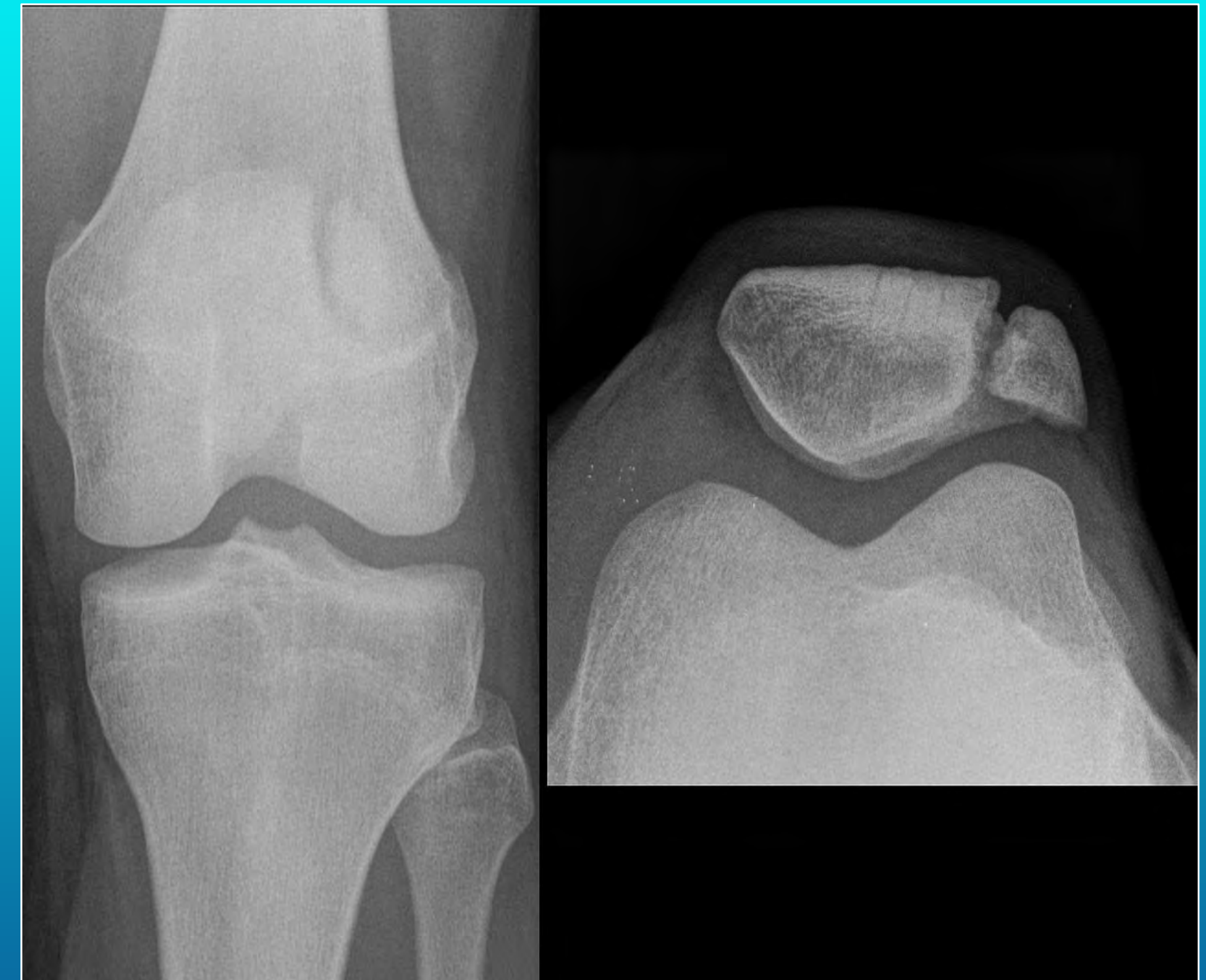
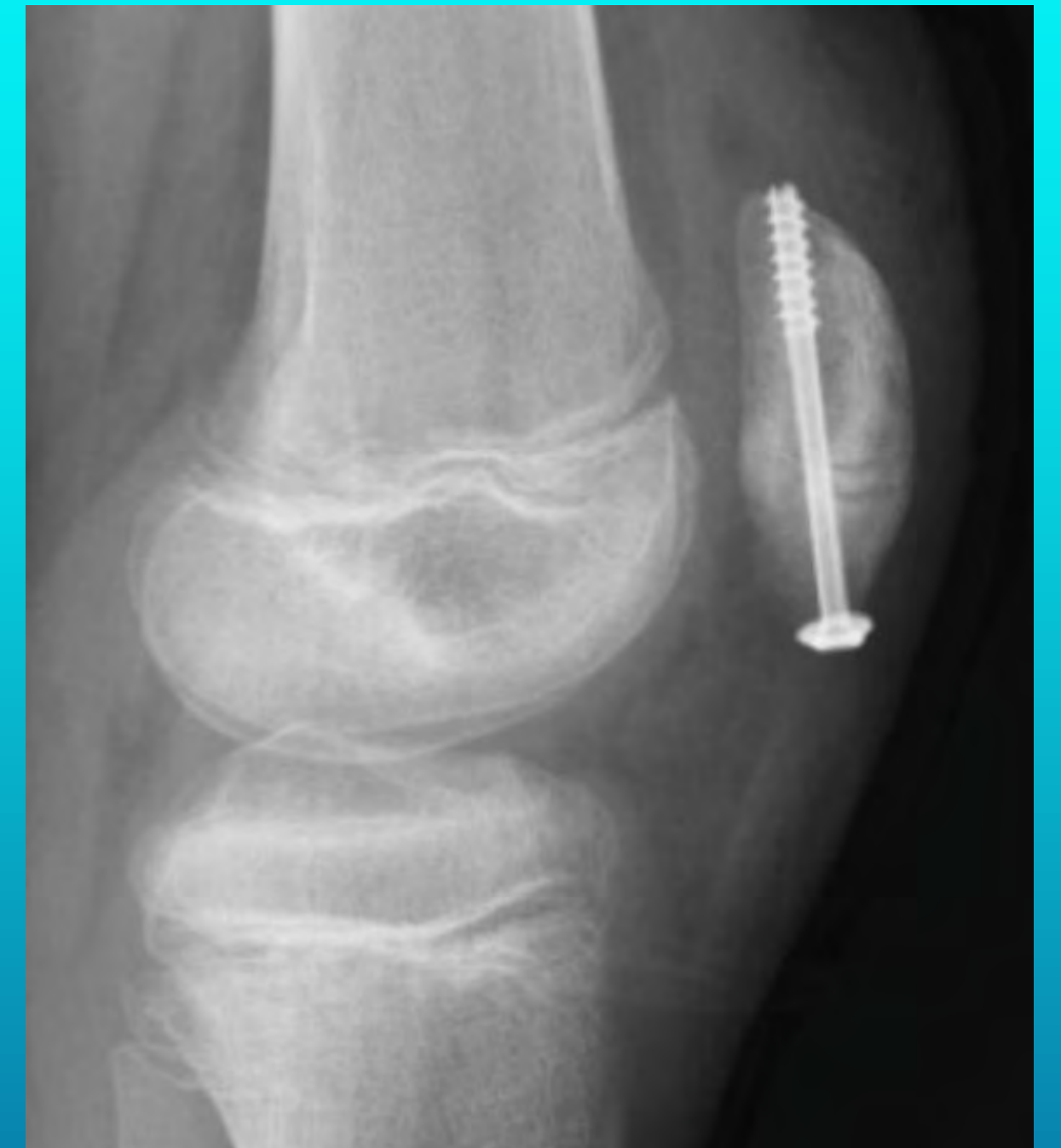
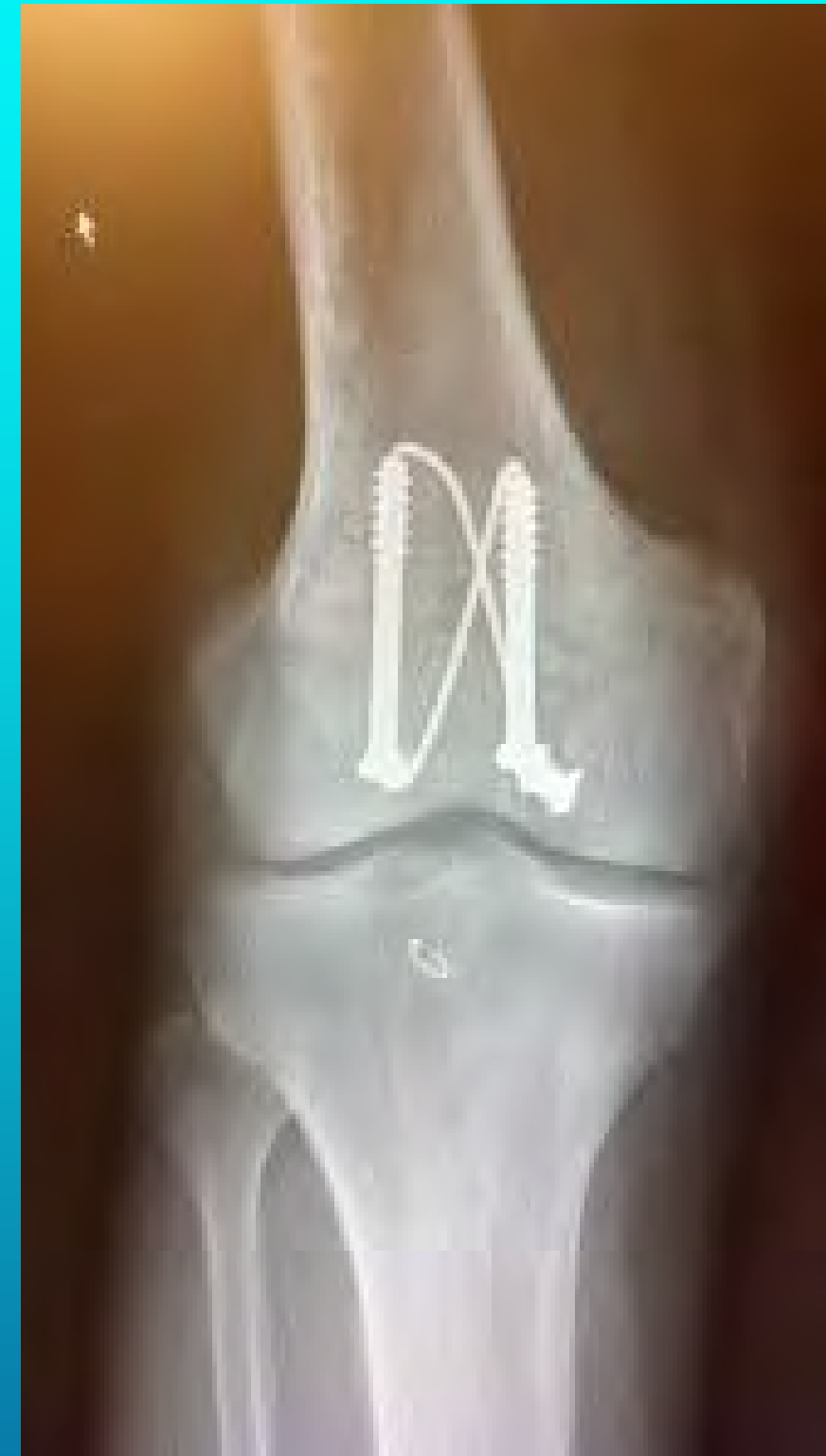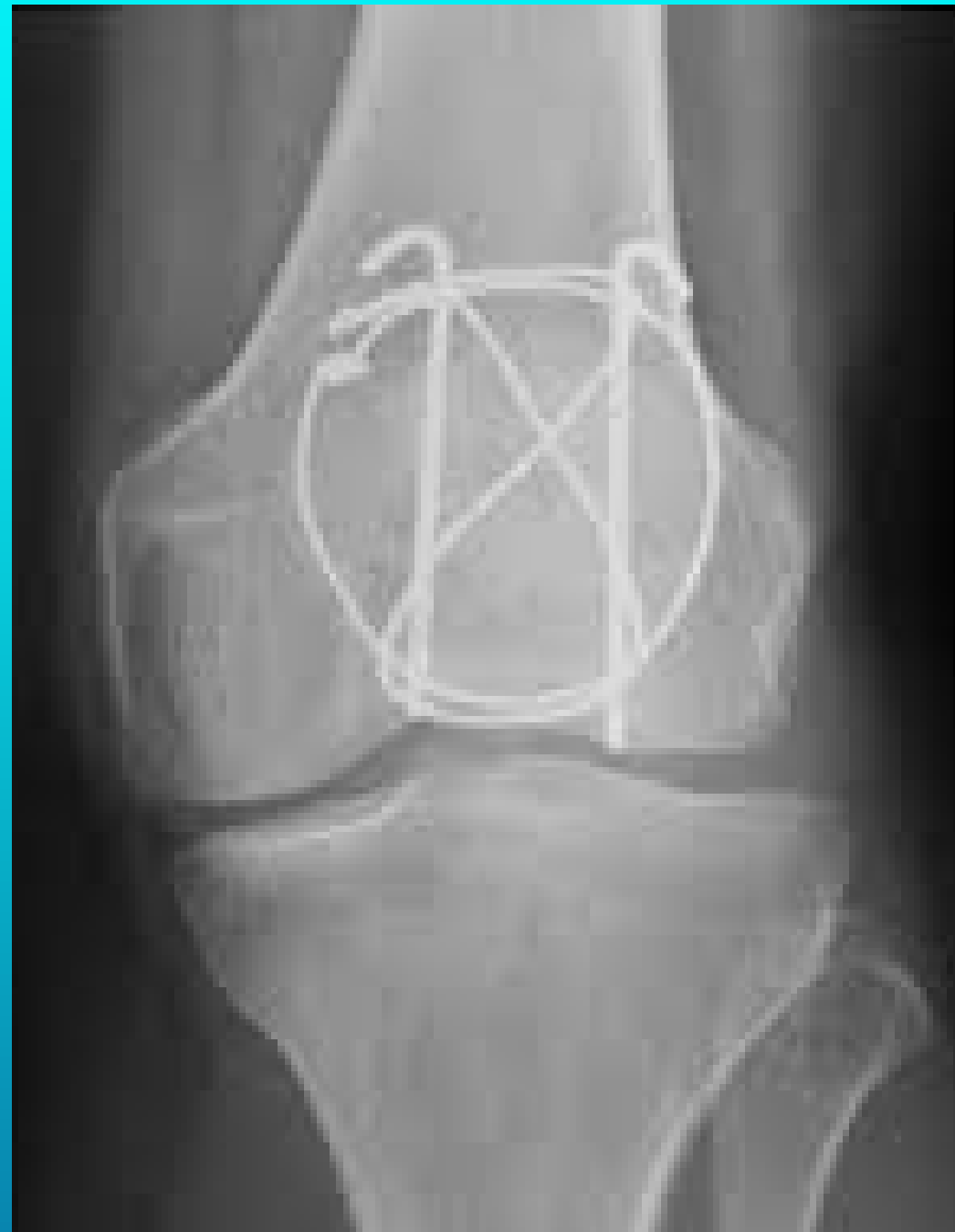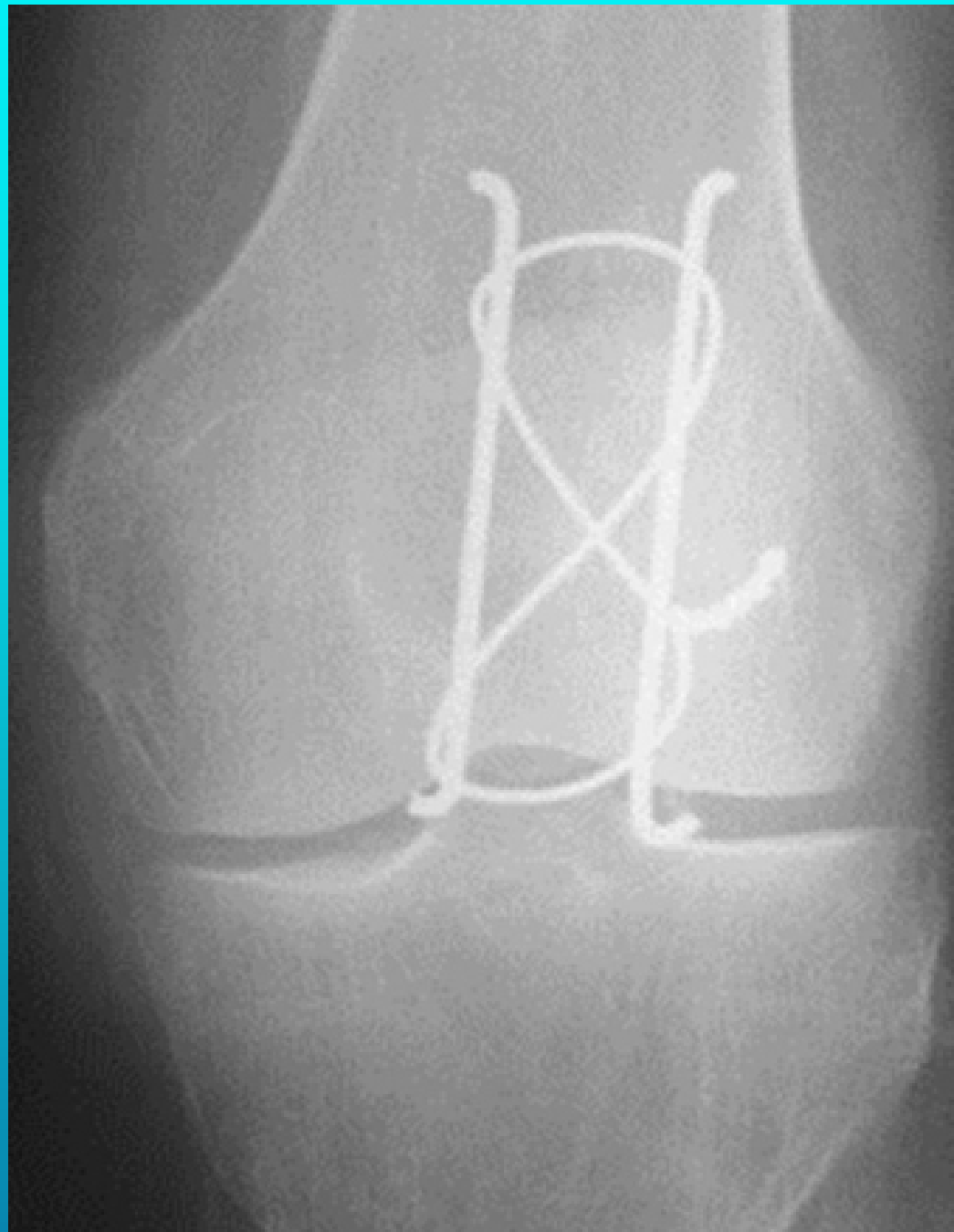
Image courtesy of pediatricimaging.wikispaces.com

Patella Fractures

- Bipartite patella
 - Asymptomatic congenital anomaly
 - 8% population
 - 50% bilateral
 - Failure of ossification center to close
 - Often confused with patella fracture
 - Most common in the Superolateral patella
 - No treatment required asymptomatic knee



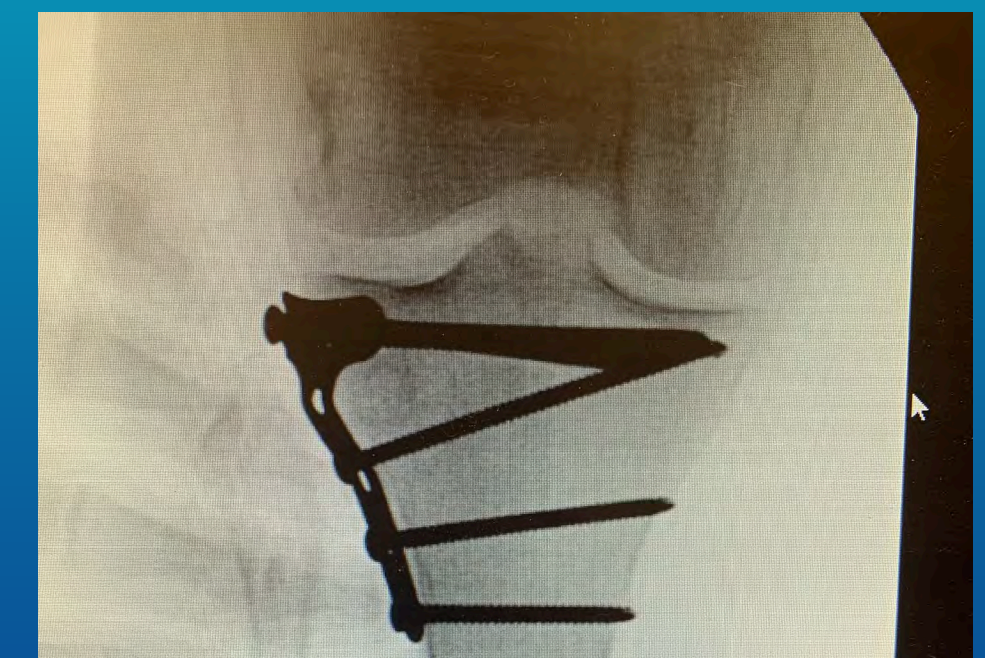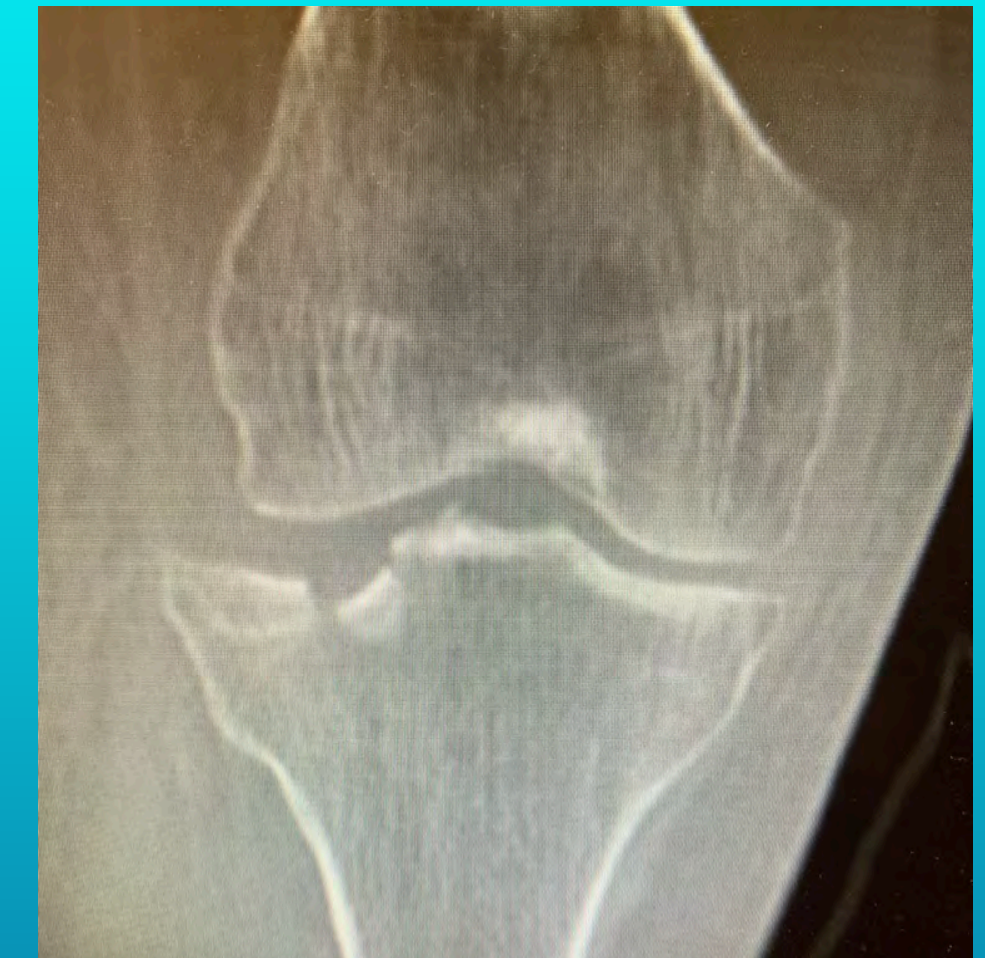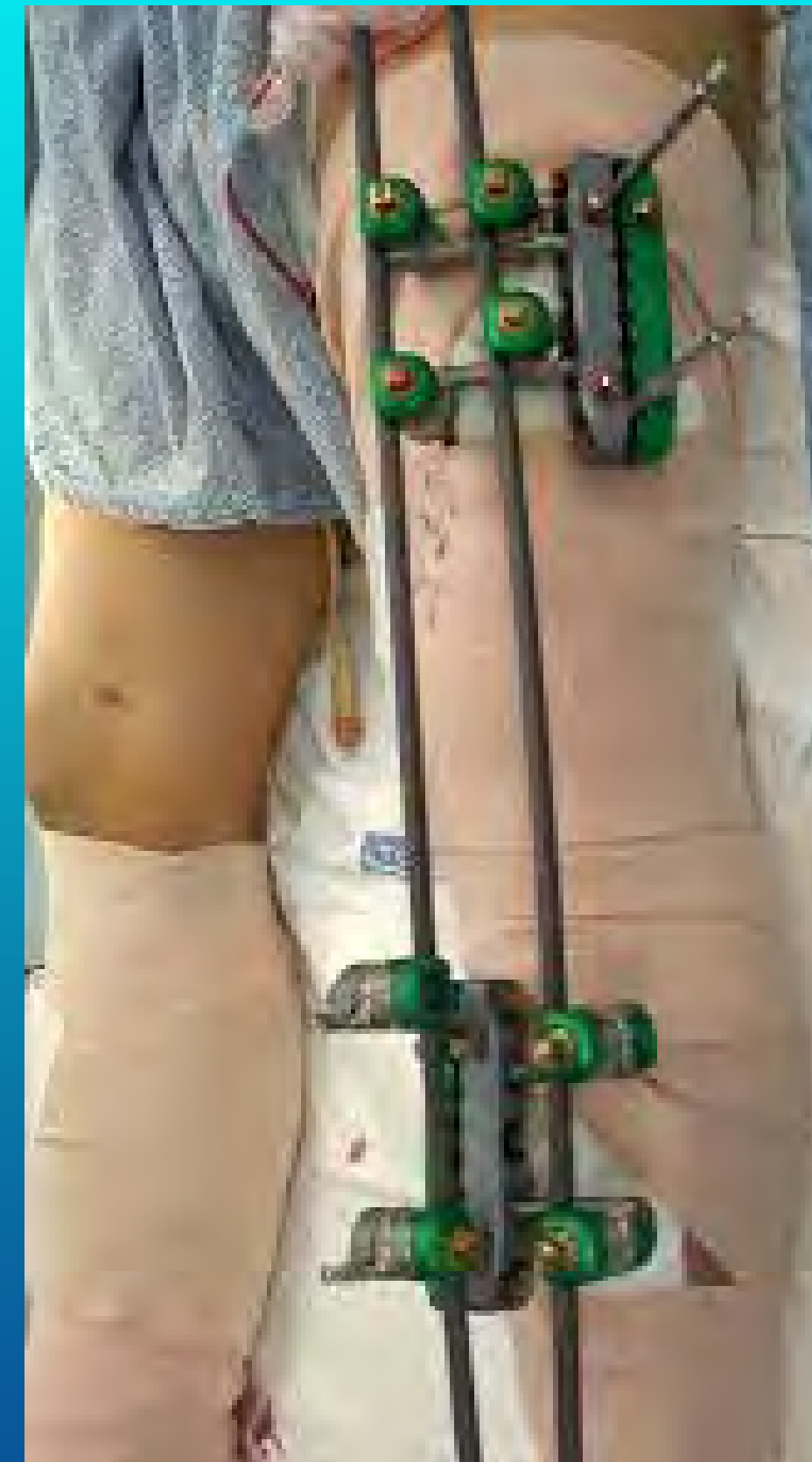Patella Fx



Tibia fx

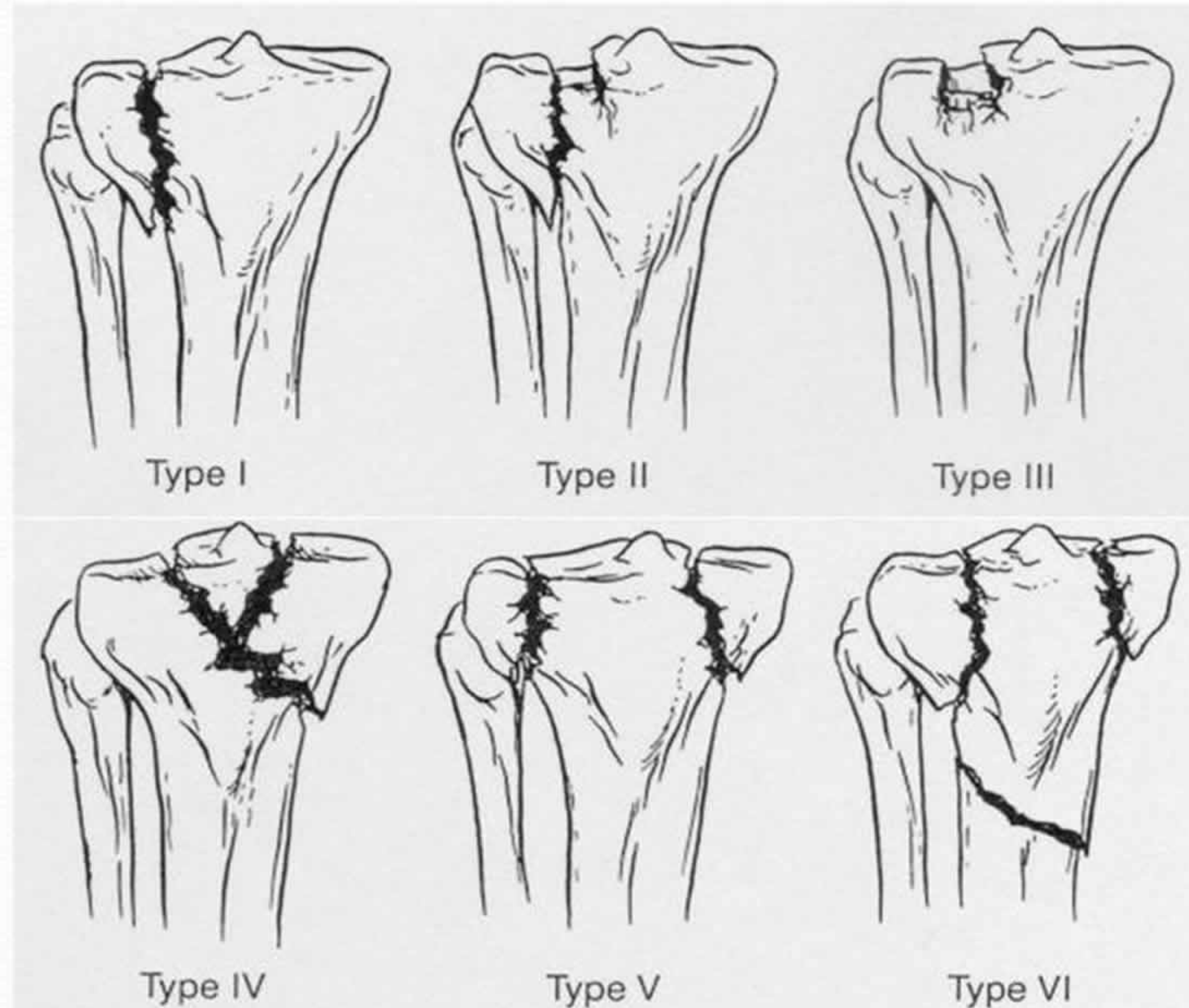
Tibial Plateau Fractures

- Compartment syndrome major concern
- Common Fracture patterns
 - **Younger age – splitting – high energy**
 - **Older age – depression (impaction) osteoporosis**
- Women > Men 2nd to osteoporosis
- Injuries to cruciate and collateral ligaments of the knee
- **Skin problems common 2nd to thin coverage at proximal tibia**
- Neurovascular injuries
- Surgical Treatment
 - Delayed – Ex-Fix
 - Definitive- ORIF



Tibial Plateau Fx

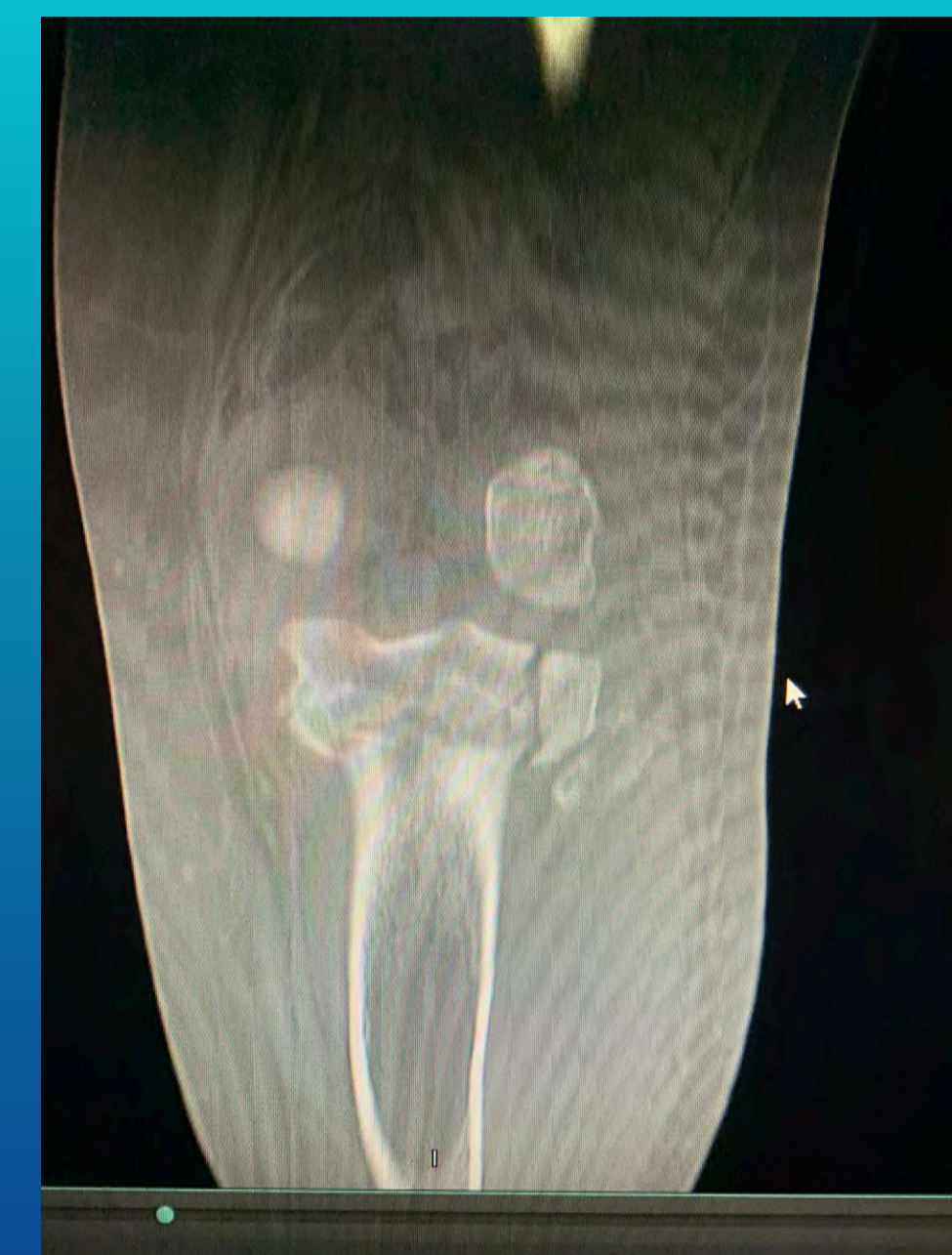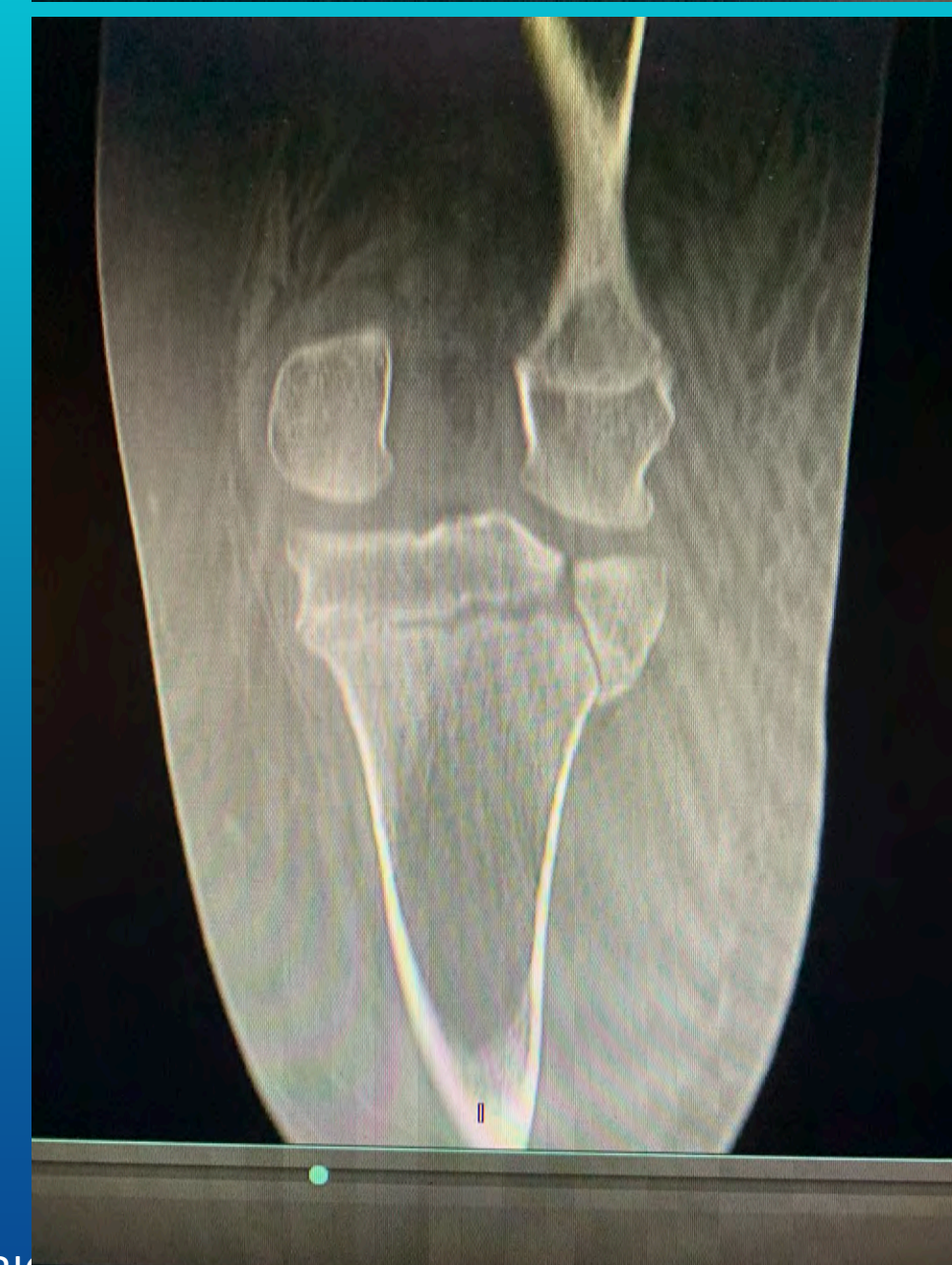
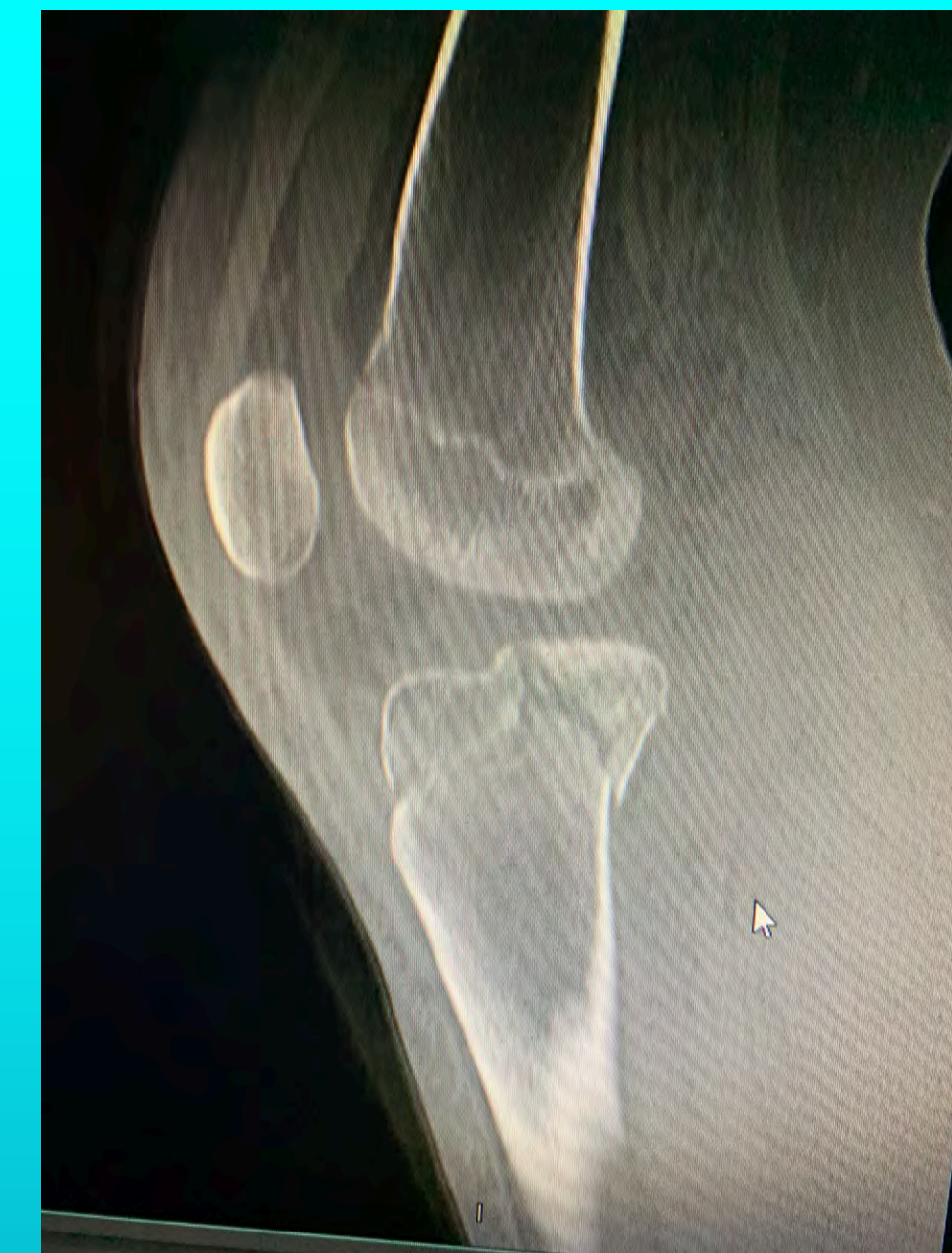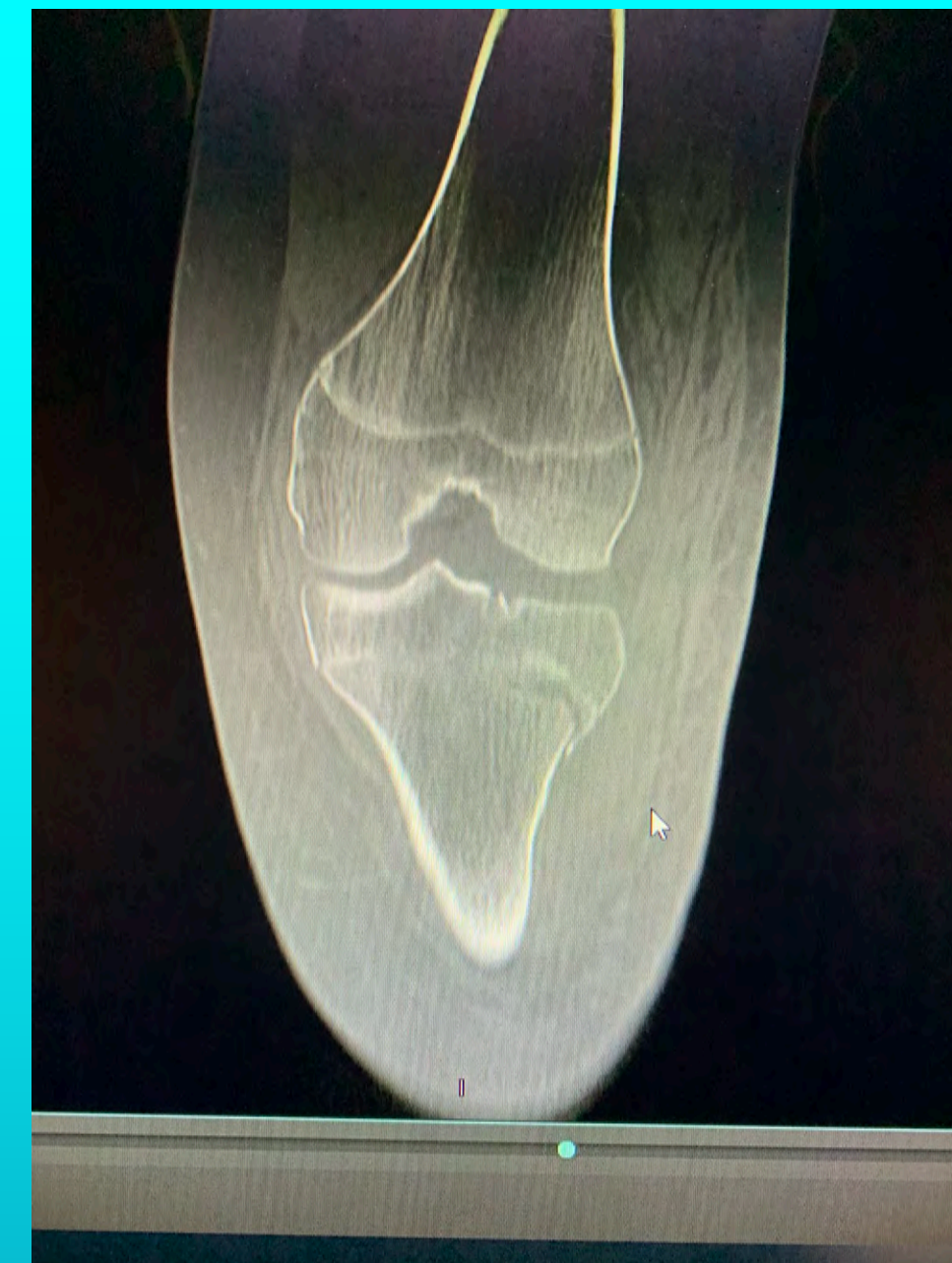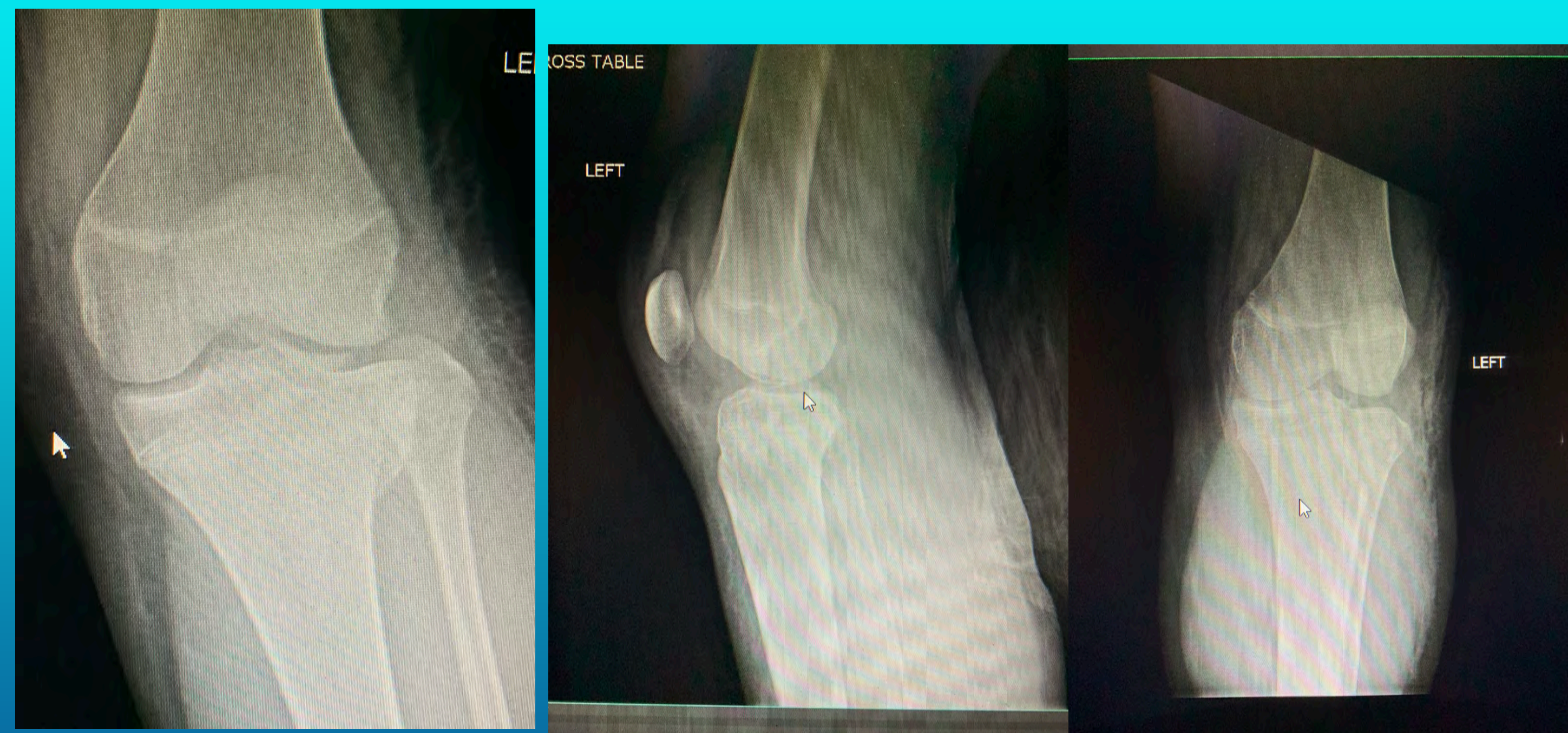Schatzker Classification of tibial plateau fracture



Lower Energy

Higher Energy

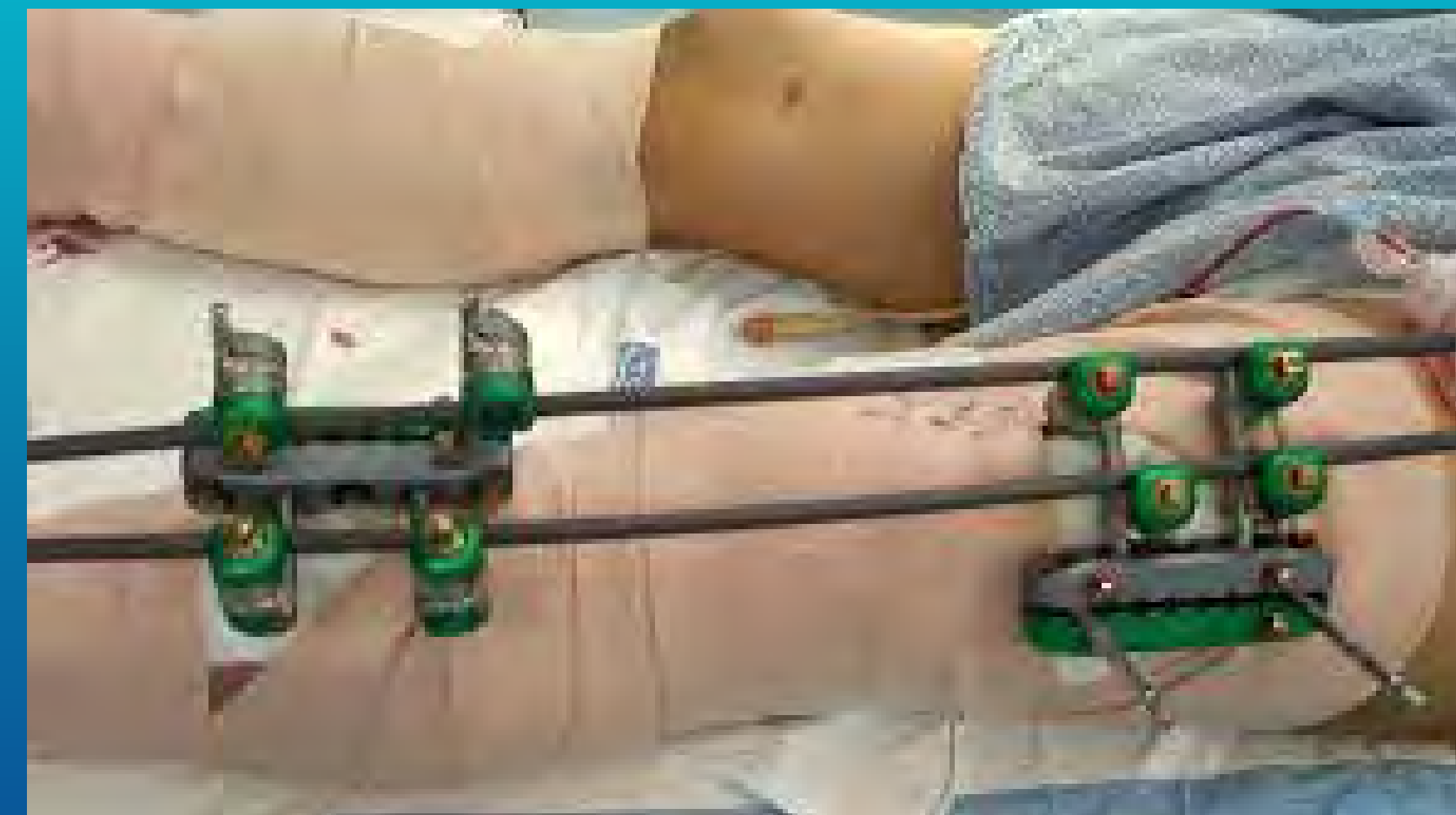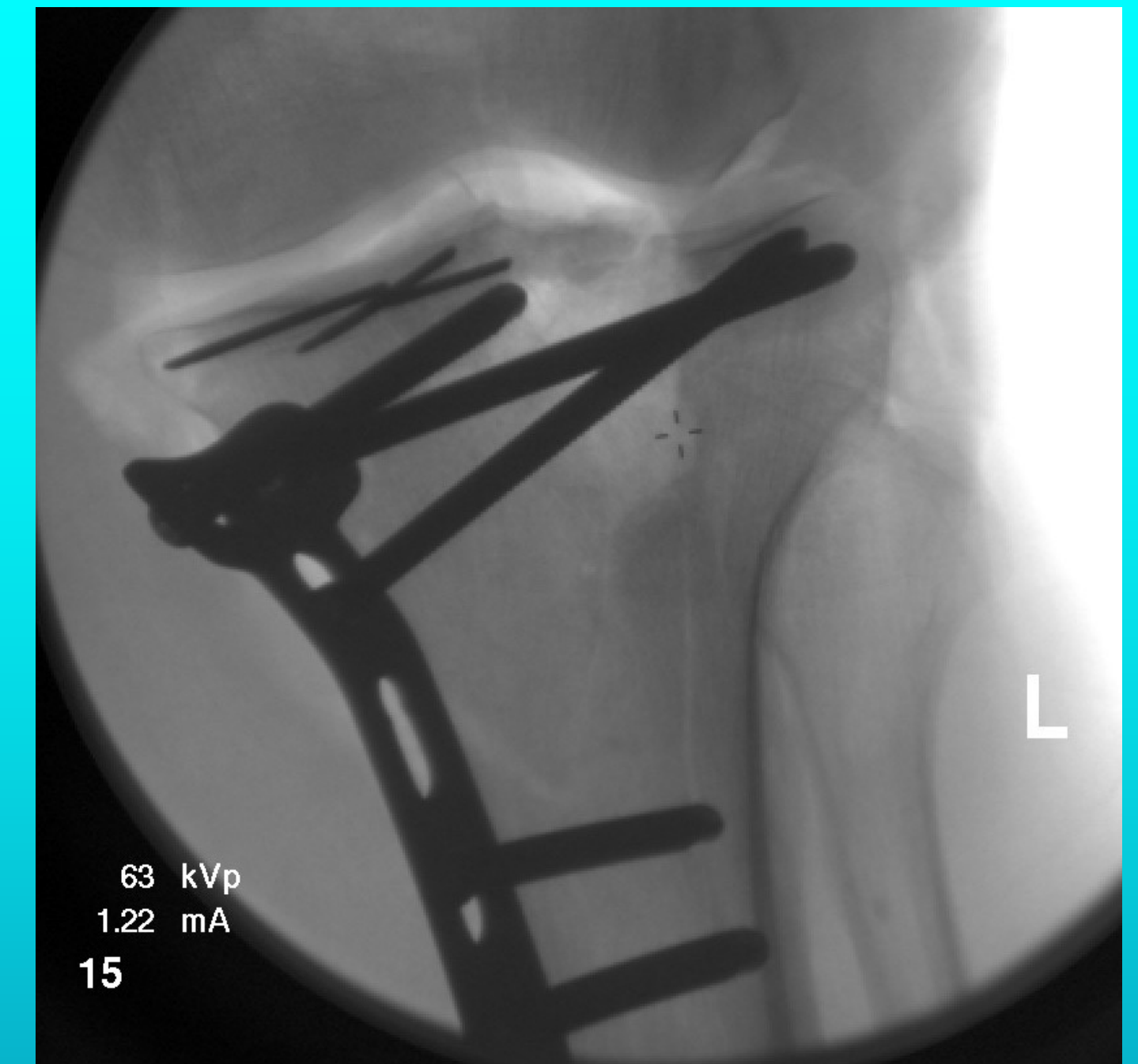
Tibial Plateau Fx



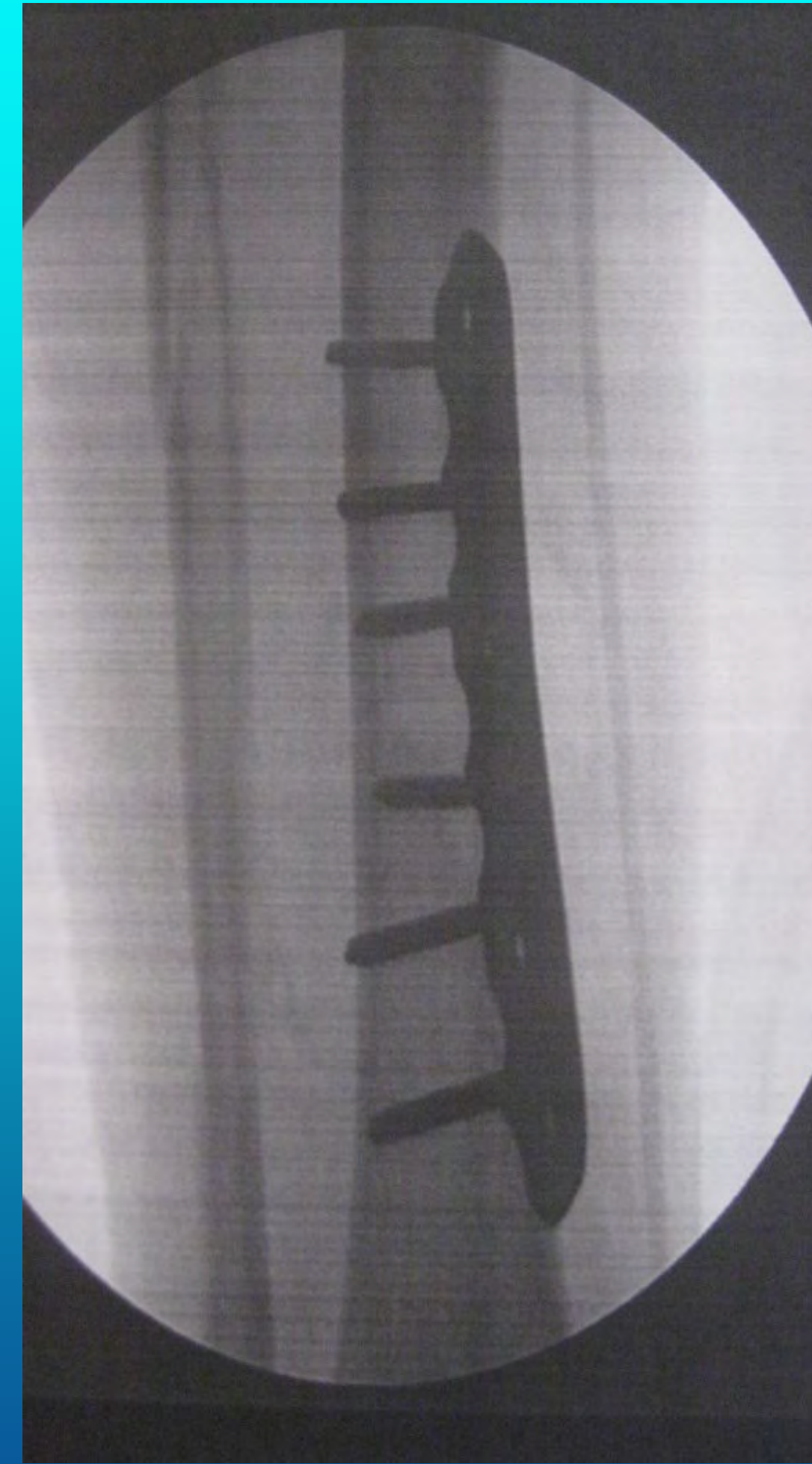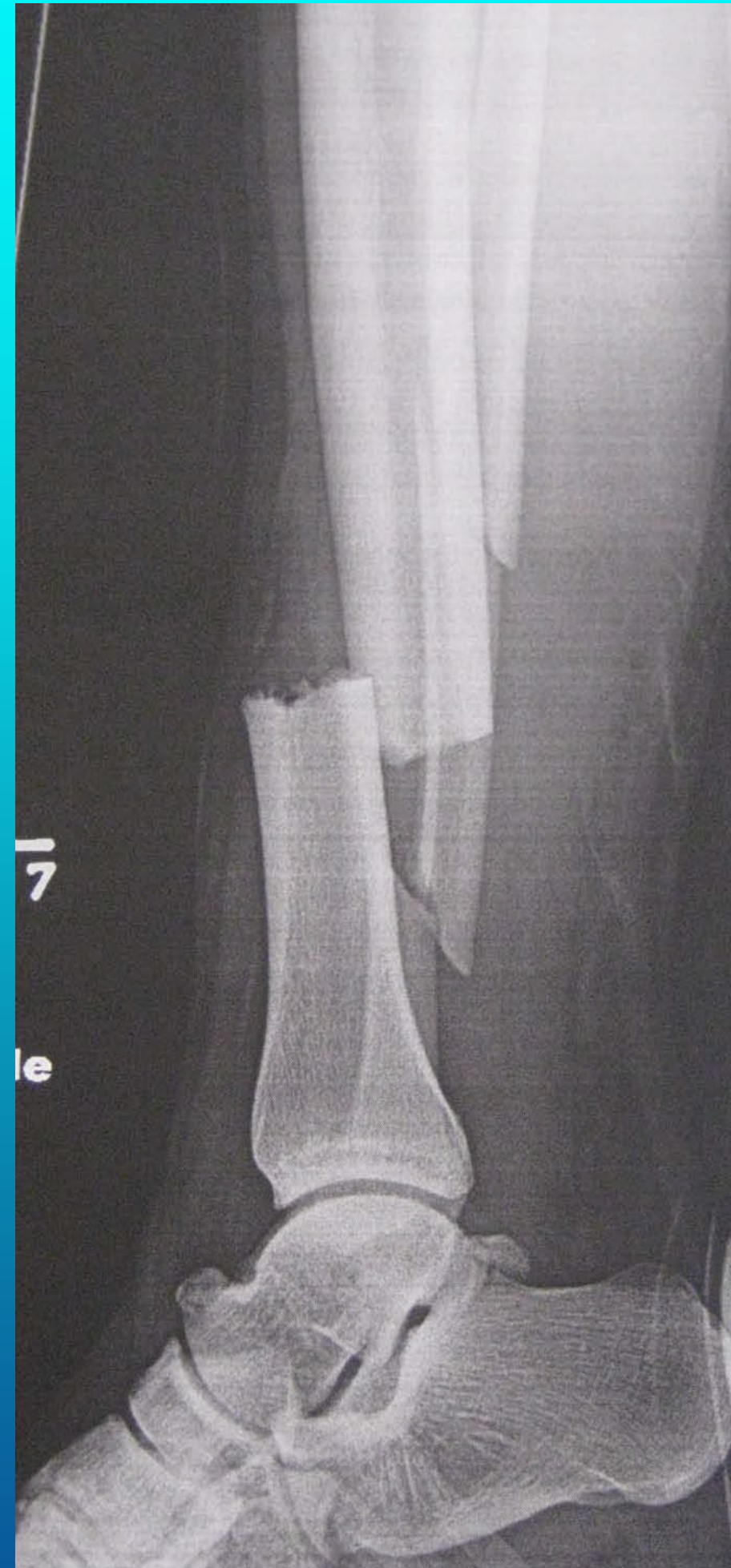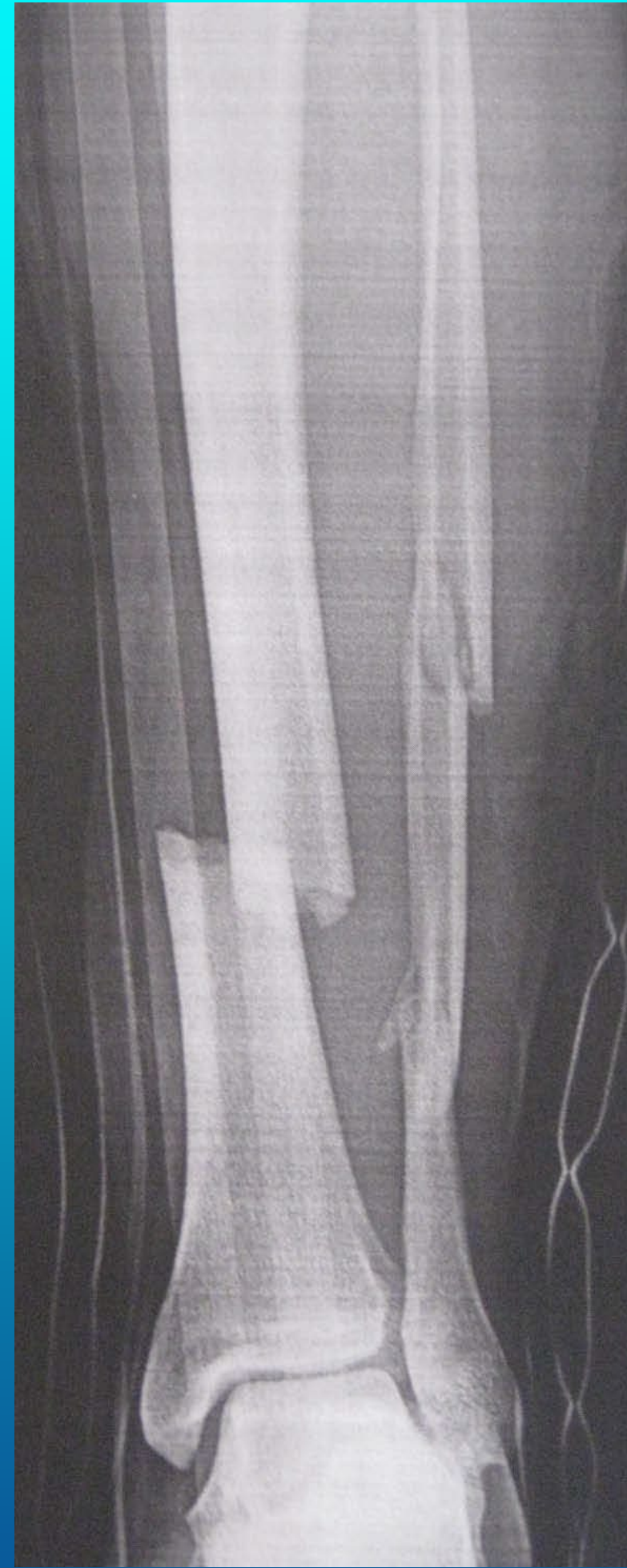
Tibial Plateau Fx

Treatment

- **High energy Tibial Plateau fx Need Ex-Fix**
 - **Restore length and protects tissue**
- Admit & Compartment checks
- Think about knee dislocation
- Vascular Assessment
 - **Ankle Brachial Index (ABI)**
Systolic BP LE
Systolic BP UE
 - **< 0.9 need CTA**
- Delay Definitive fixation 5-10 days
 - Skin



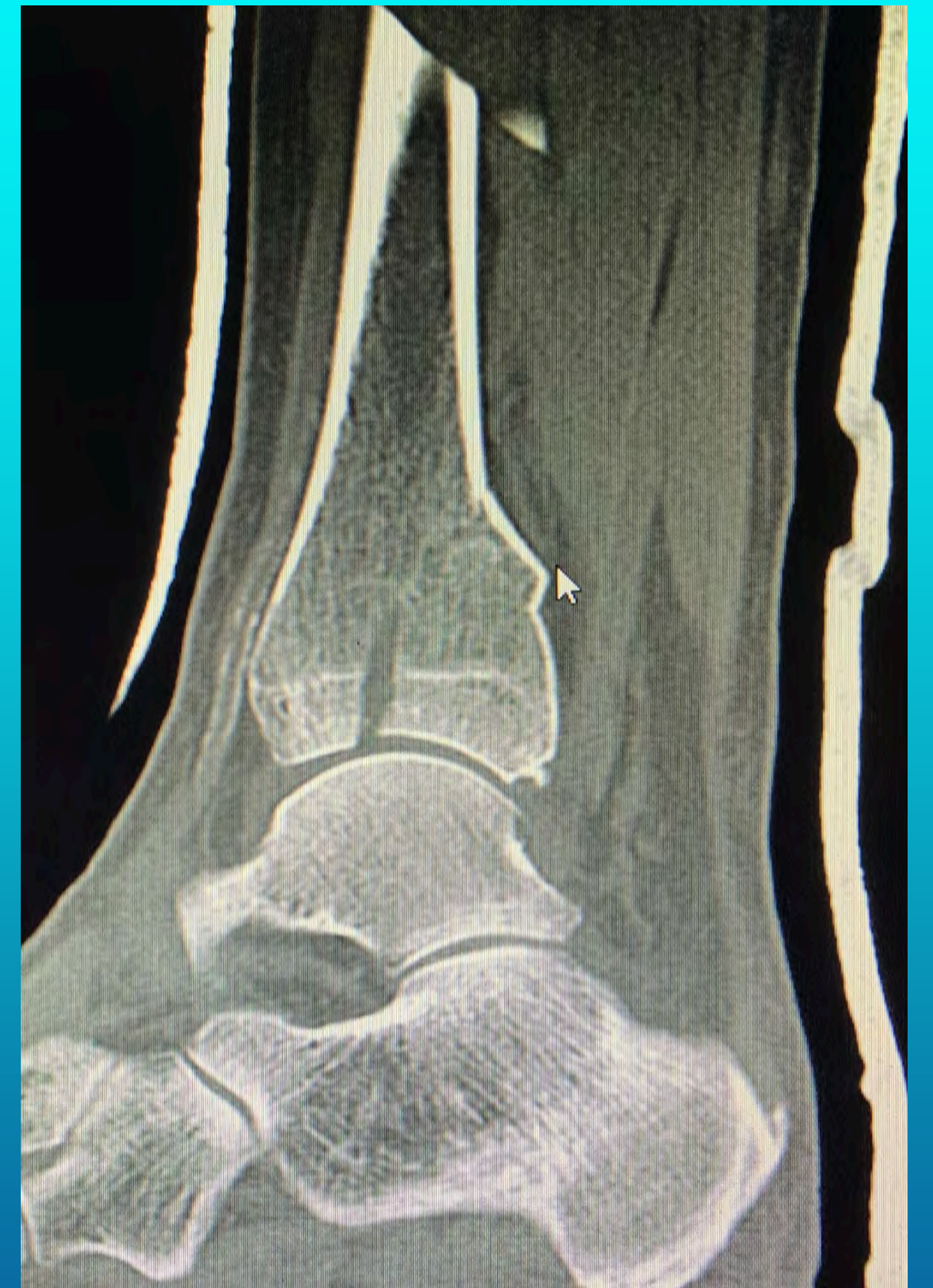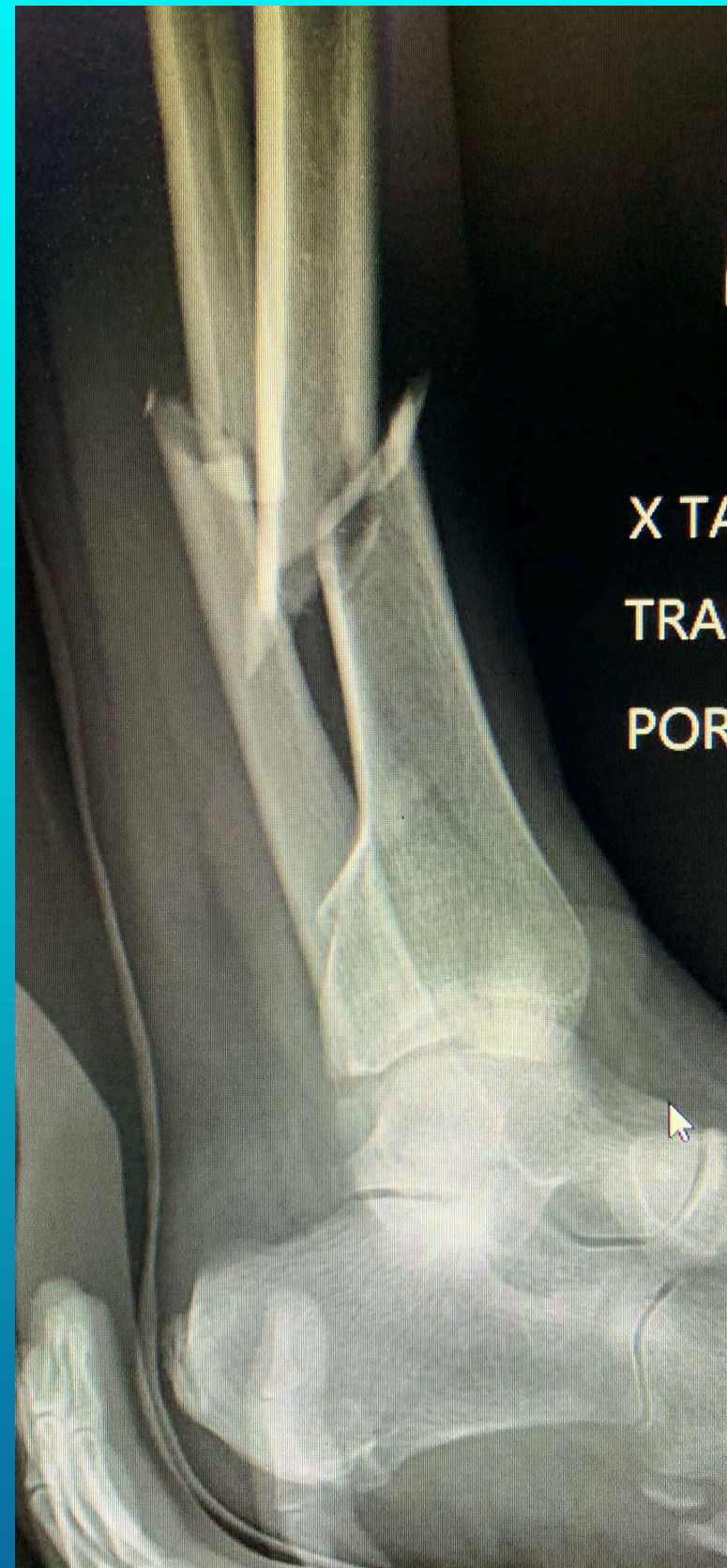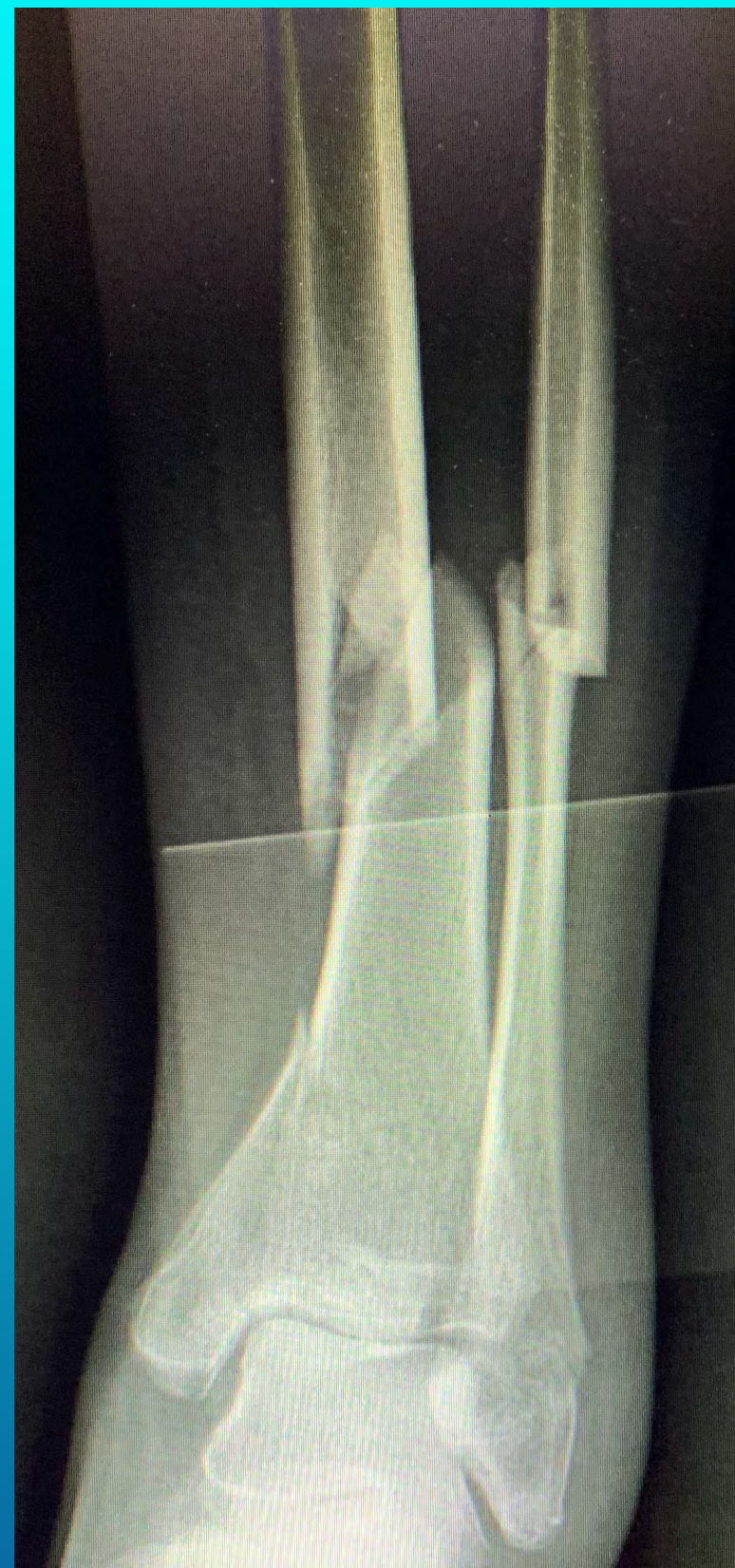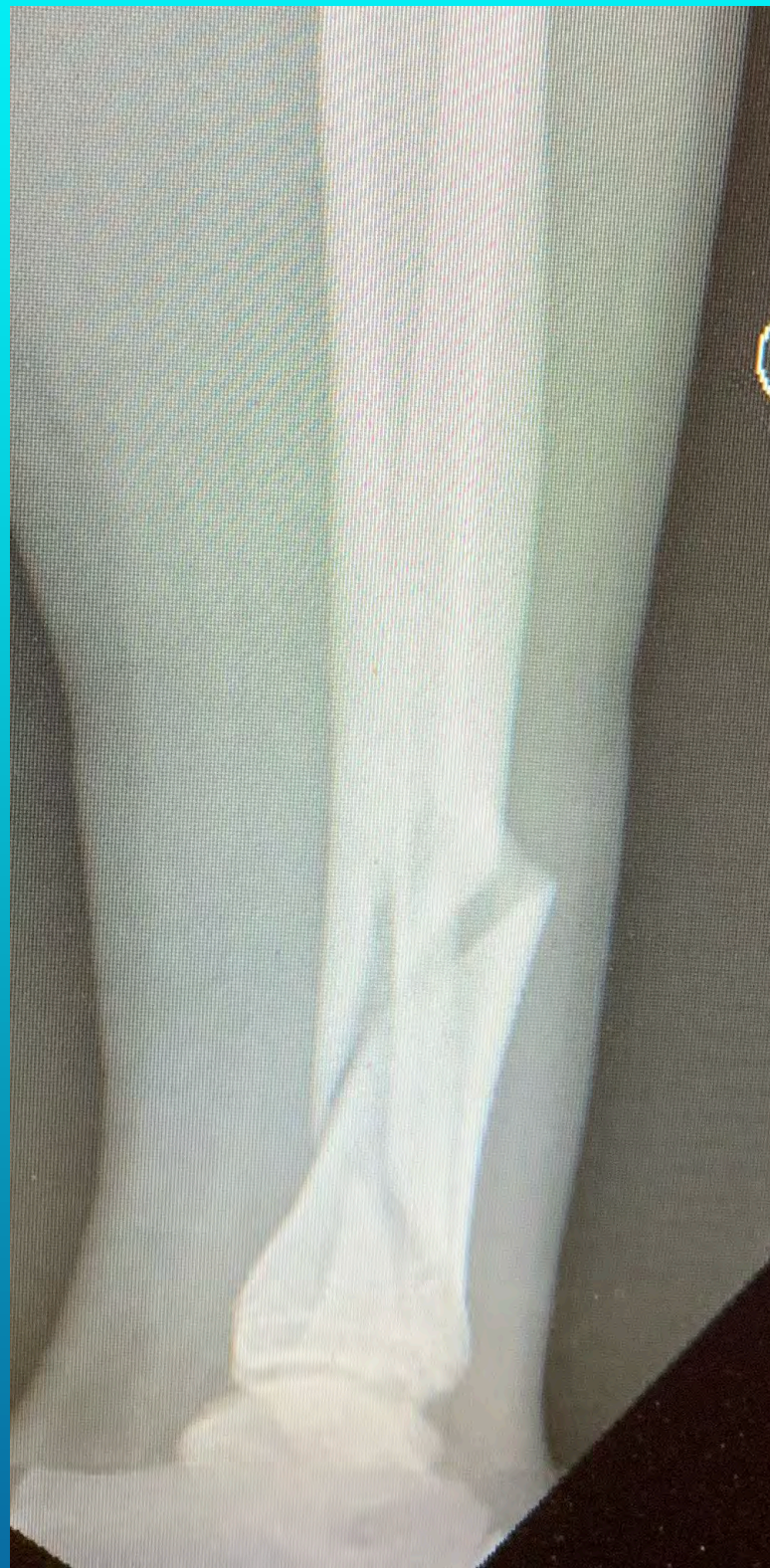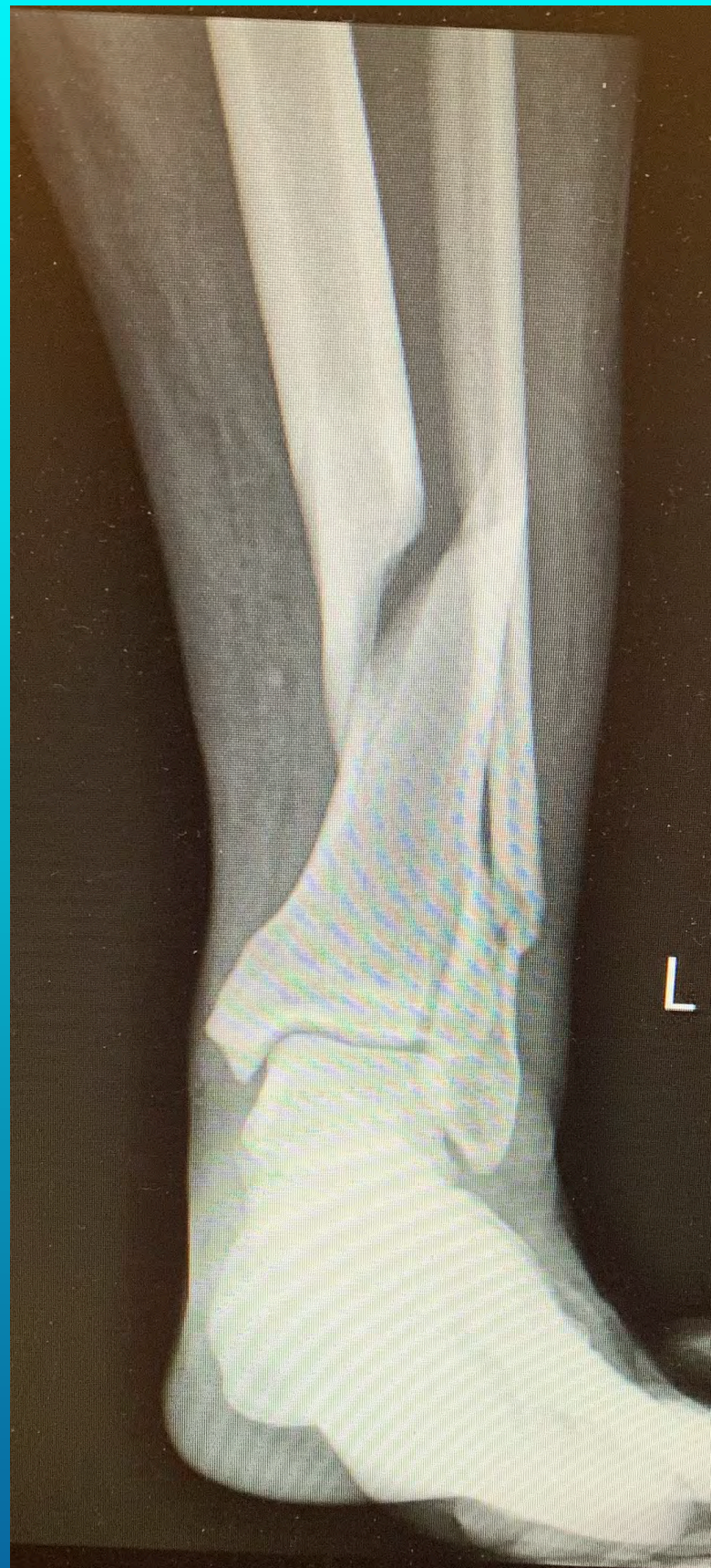Tibia Shaft Fractures



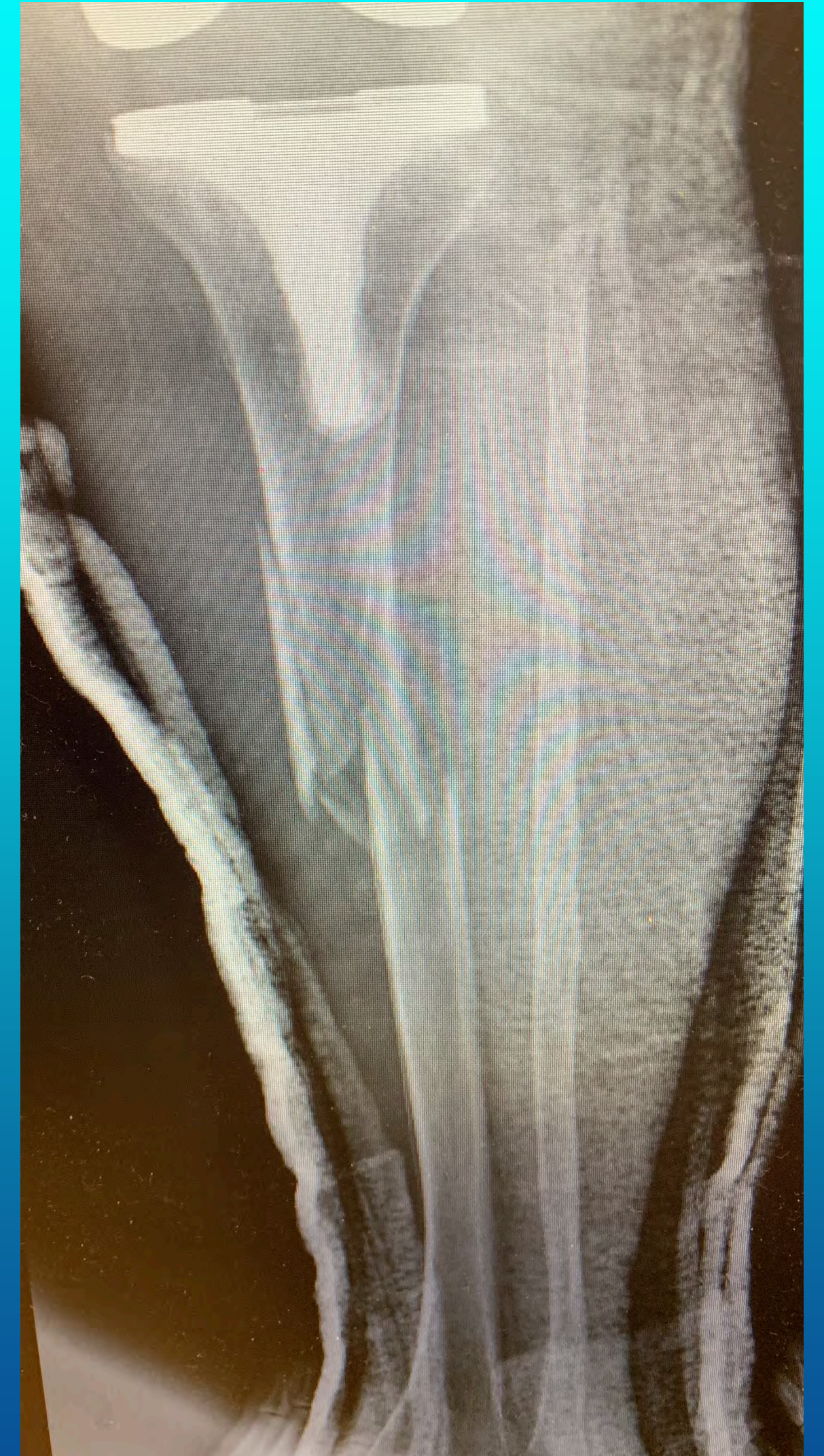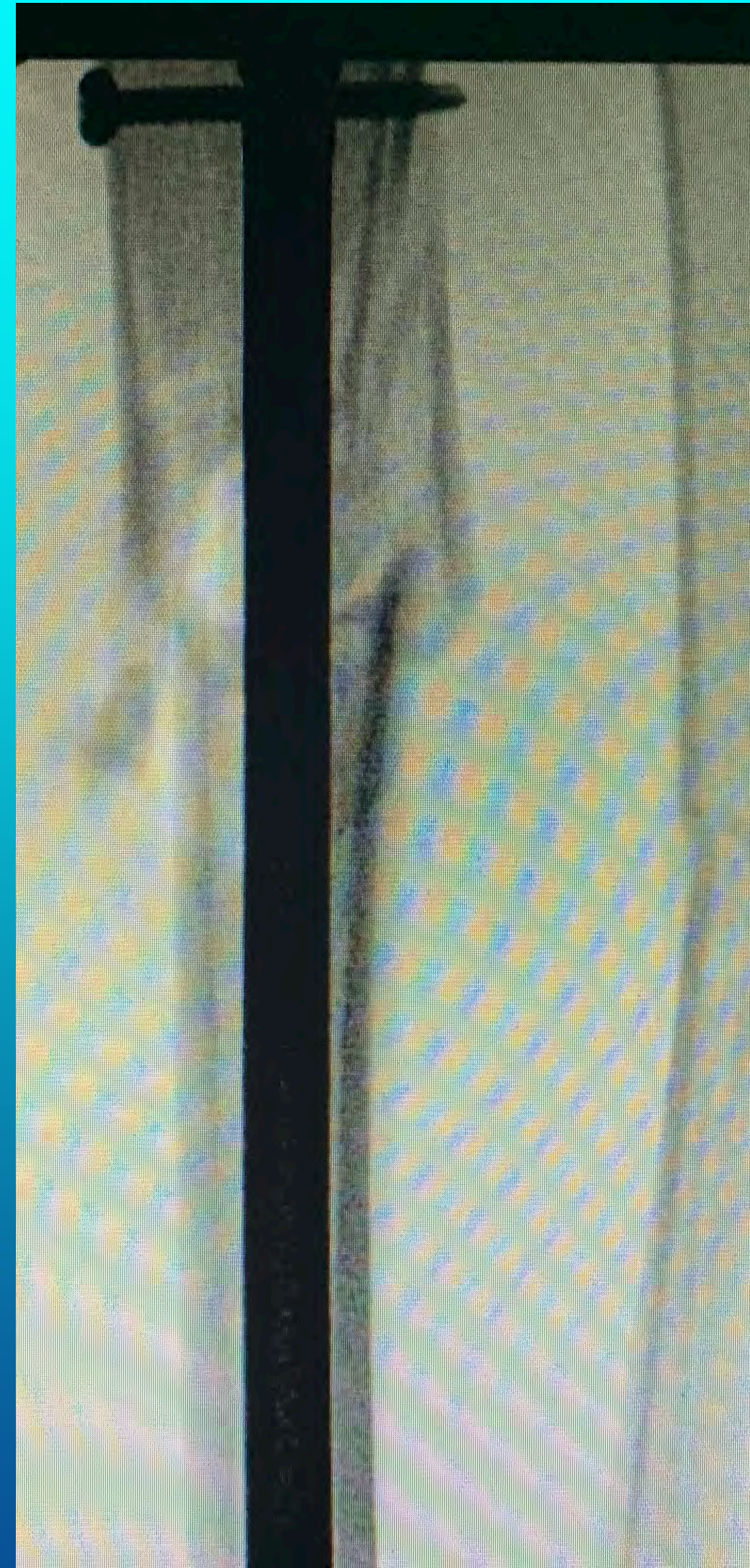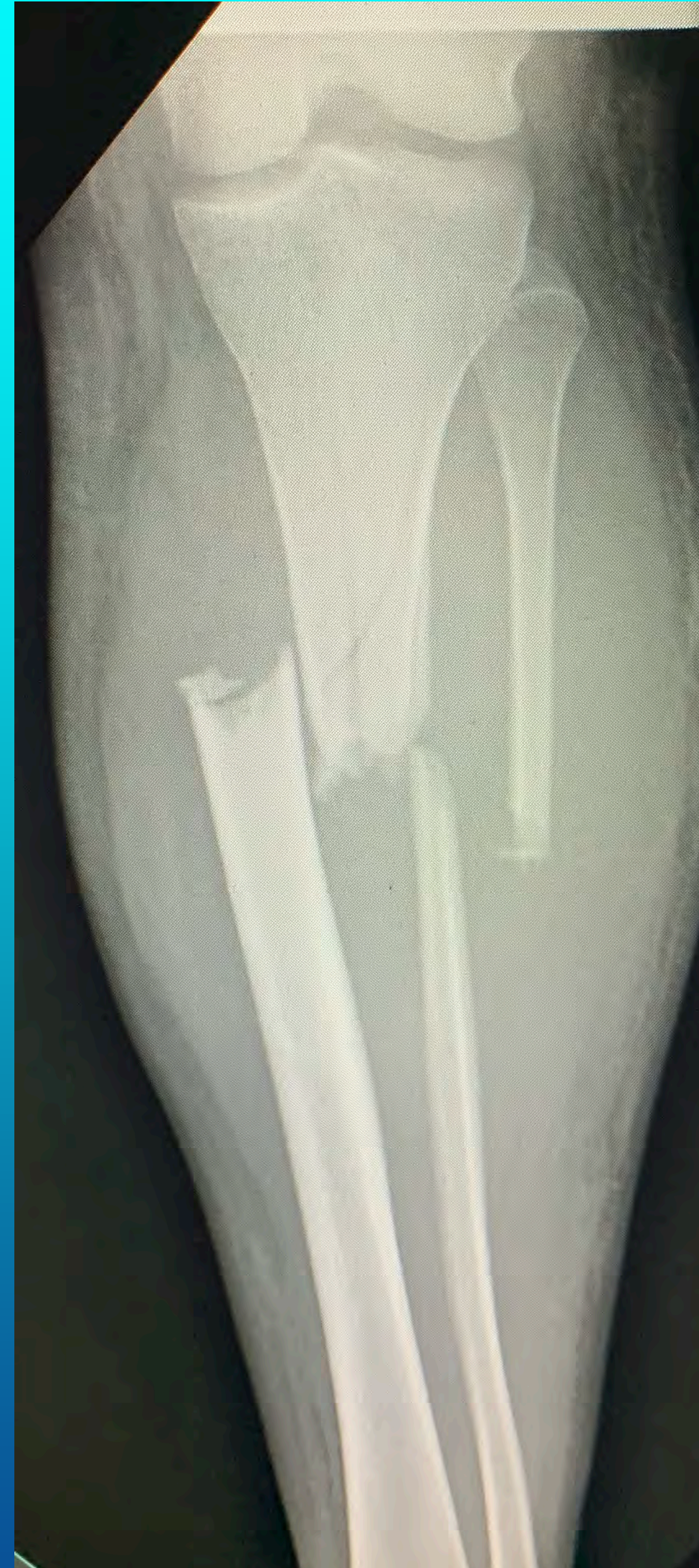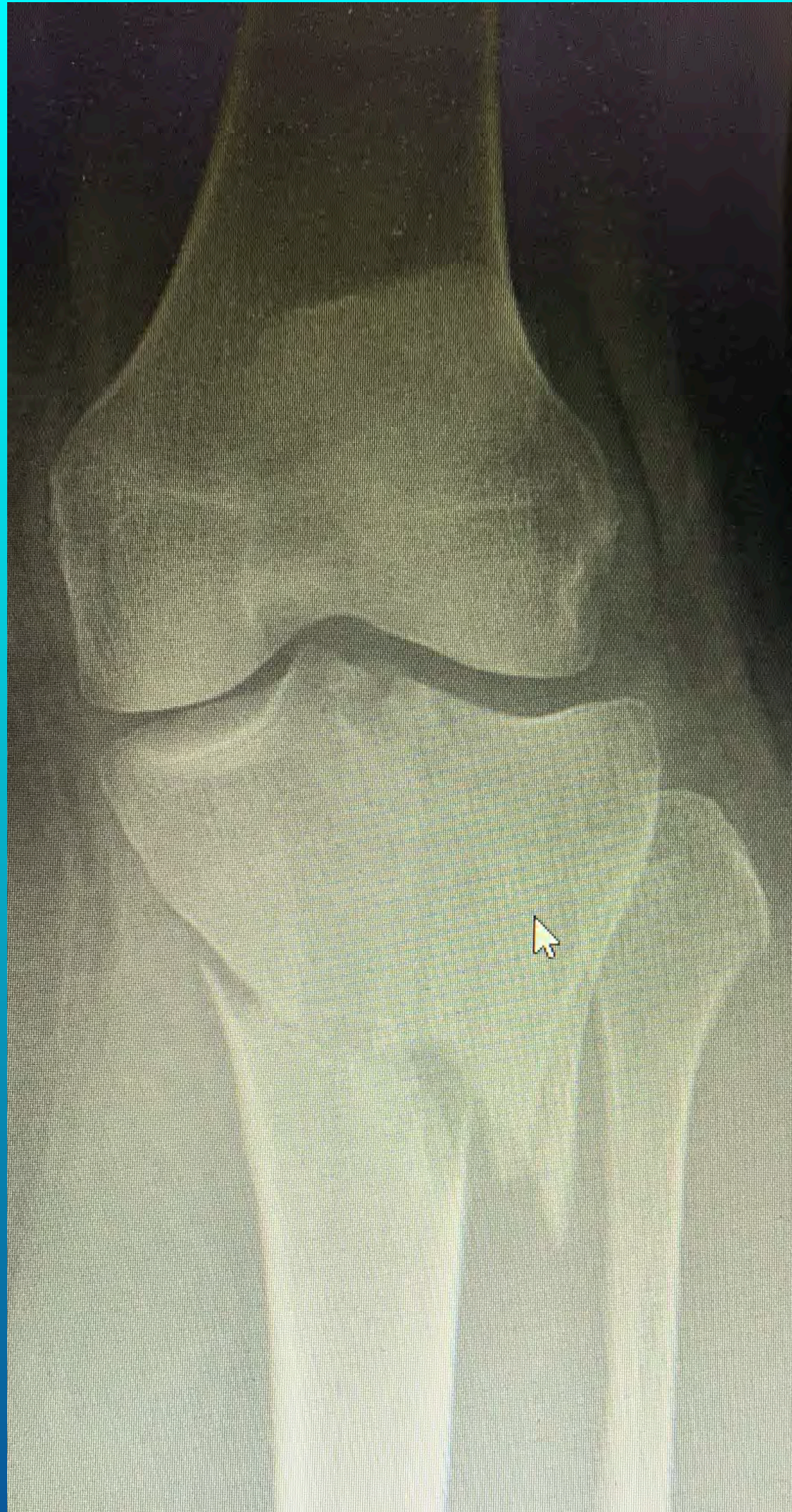Tibial Shaft FX

- Open fractures of the tibia are more common
- M>F
- 25% all Tibia shaft fractures associated with knee ligament injuries*
- Fracture of the ipsilateral fibula common
- Peroneal nerve injuries commonly assoc. W/ Tibial shaft fx
- High energy – young
 - Direct blow
 - Wedge/comminuted same level Fibula fx
 - Severe soft tissue injuries
- Low Energy- elderly
 - Torsional
 - Spiral fx Tibia w/different level Fibular fx
 - Post. Malleolar fx ankle assoc. w/ spiral Tibia fx
 - Assoc. Injuries
 - Compartment Syndrome
 - Ipsilateral FX
 - Plafond
 - Plateau
 - Femur
- Posterior Malleolus fx (distal 1/3 shaft/spiral)

Tibia Shaft fx



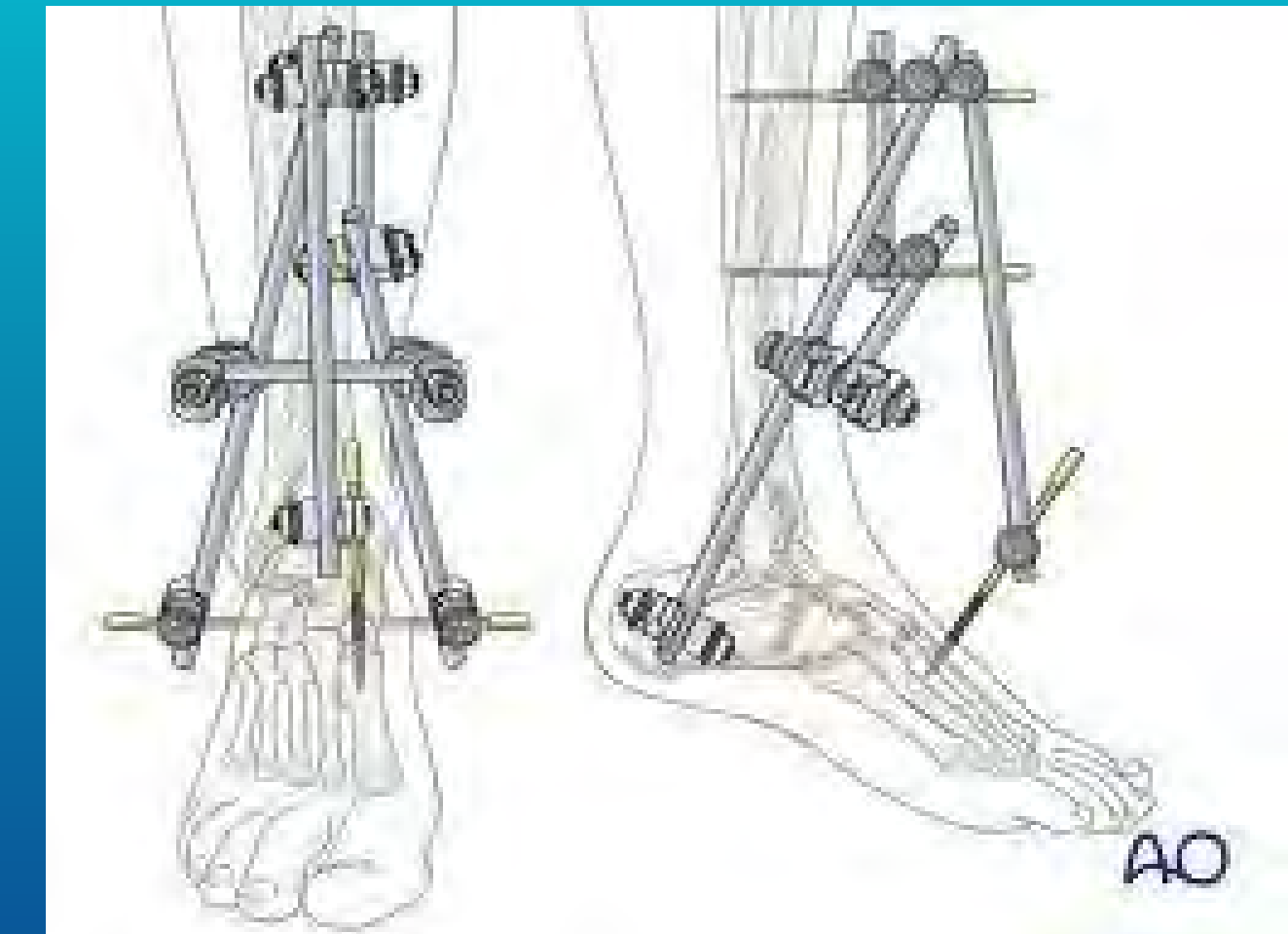
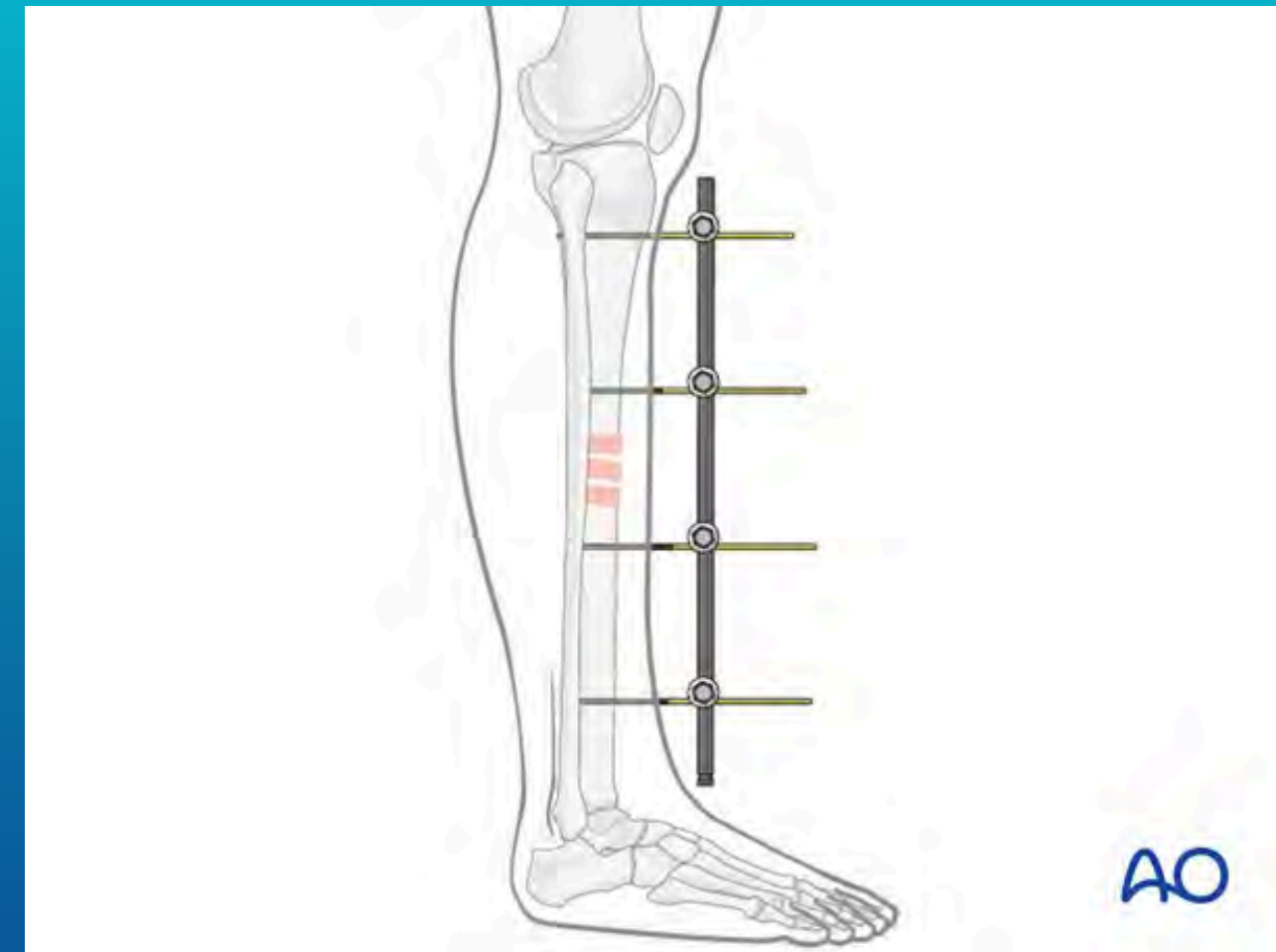
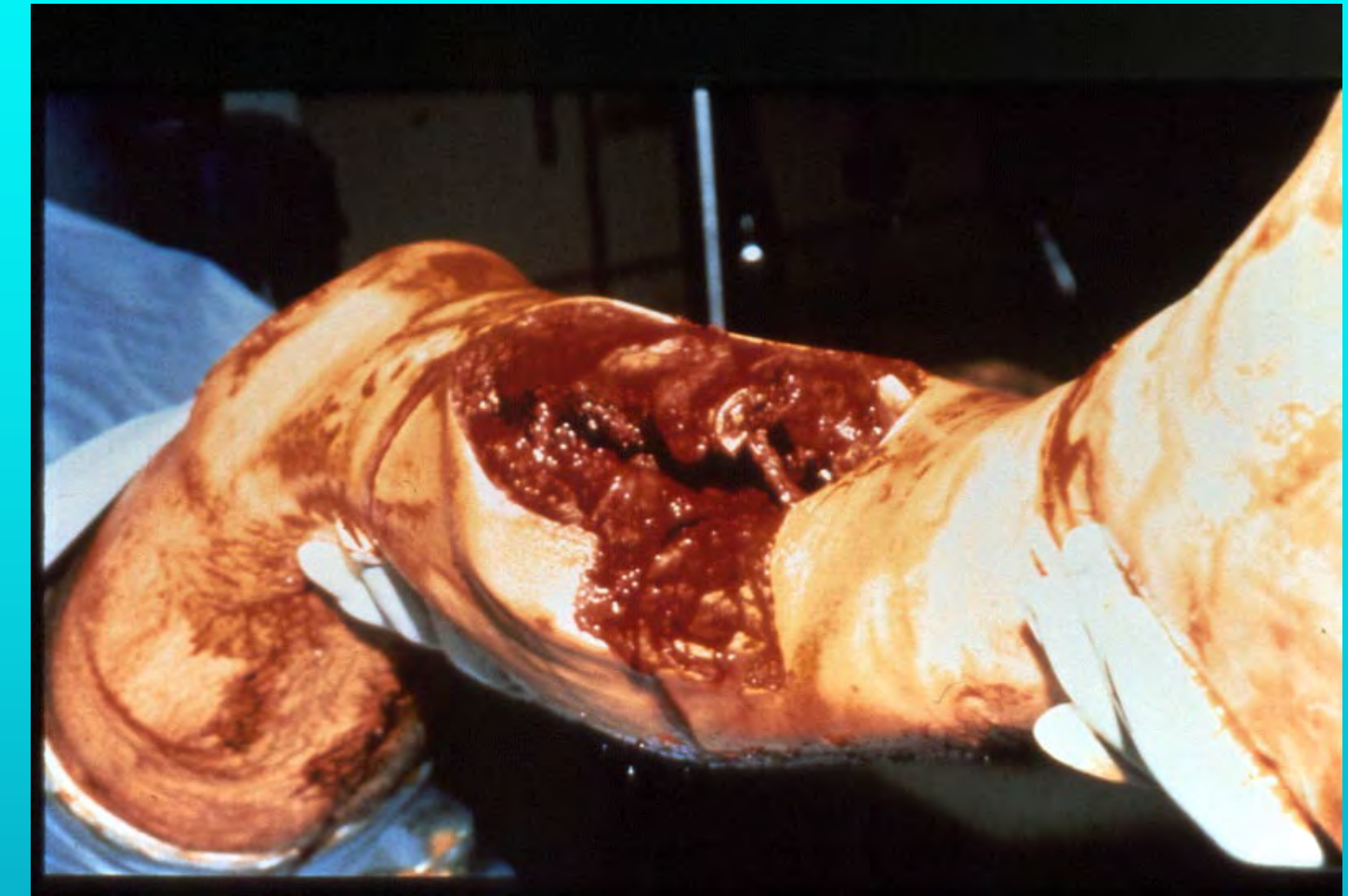Tibia Shaft Fx



Tibia Shaft Fx

Immobilization

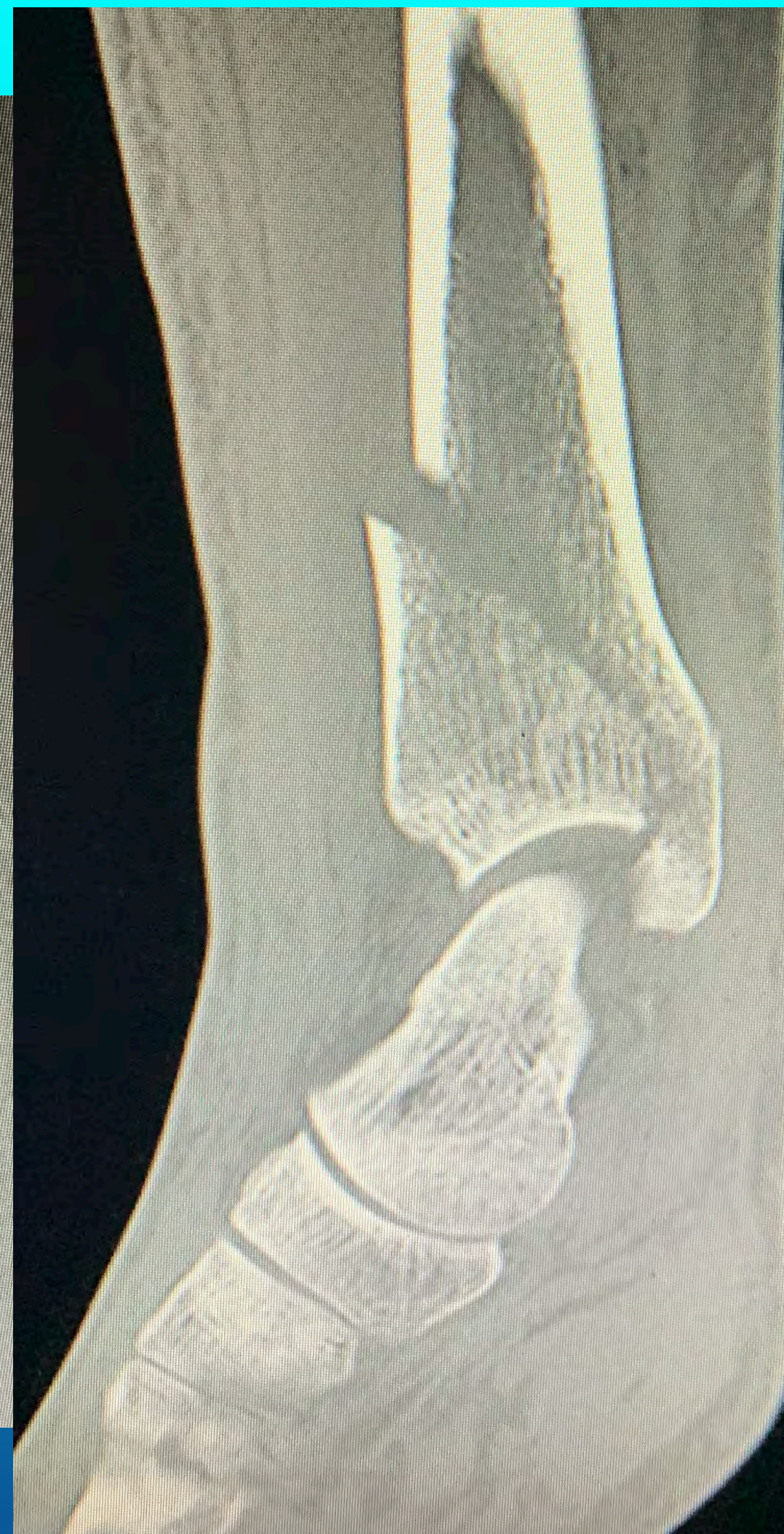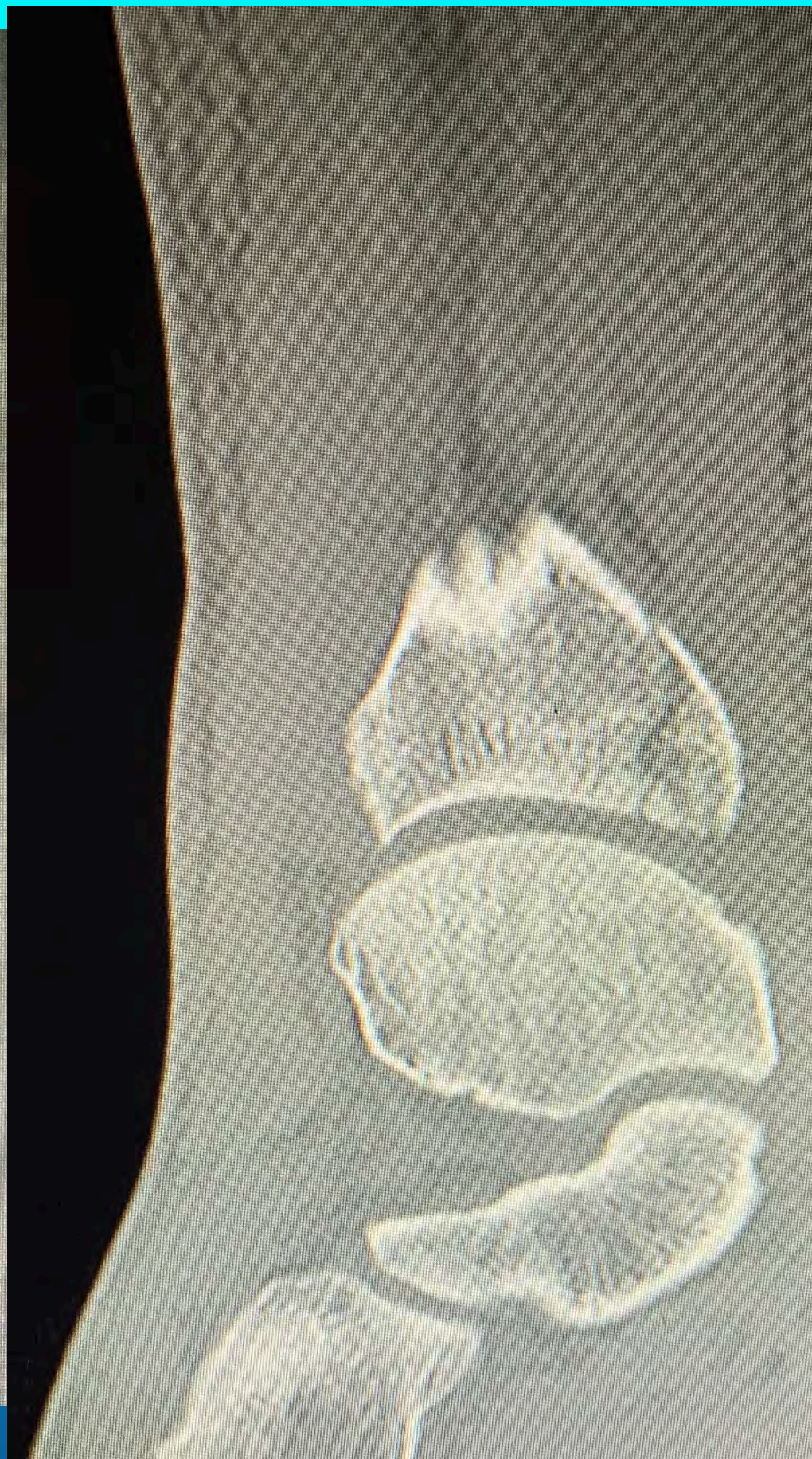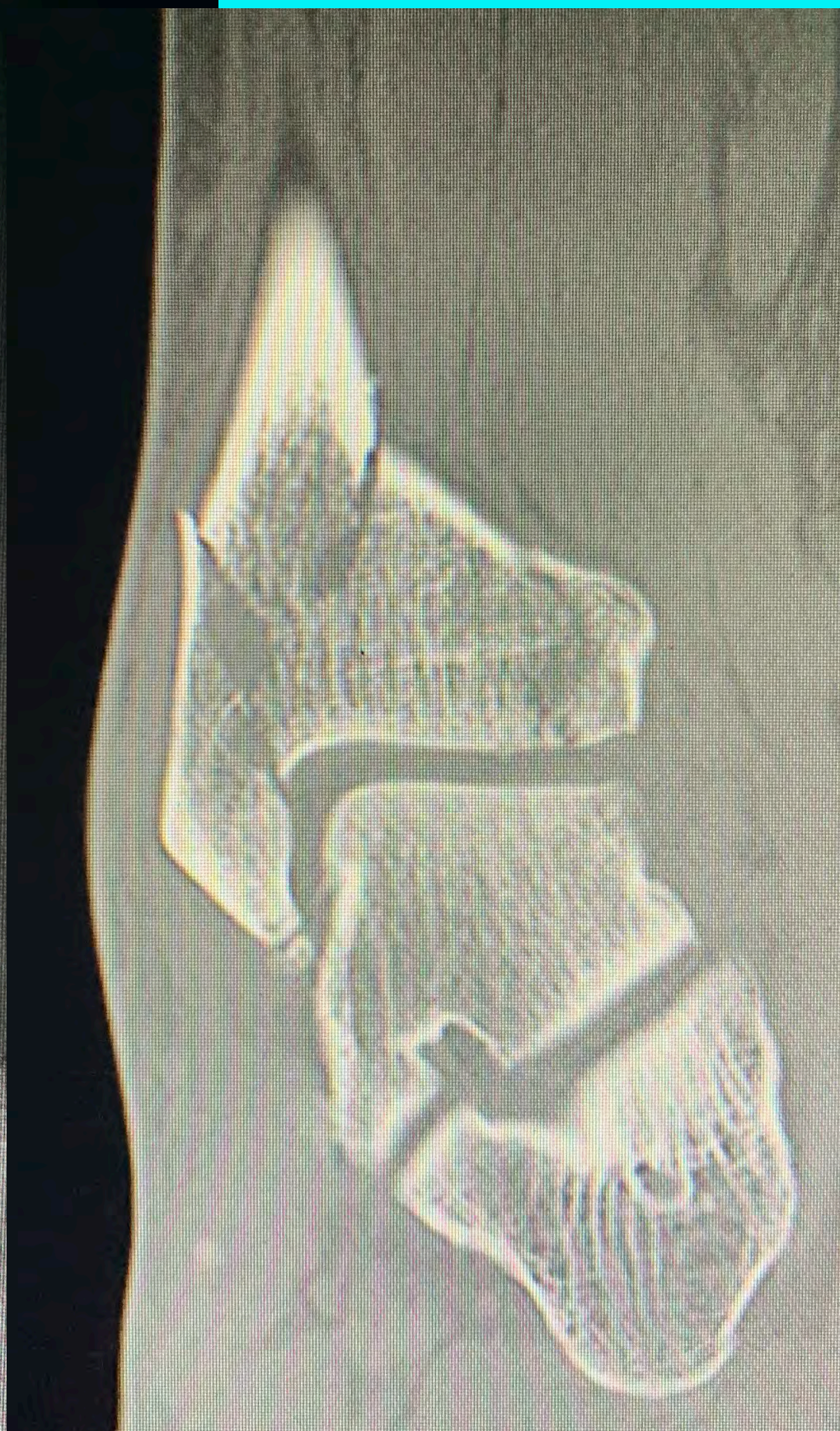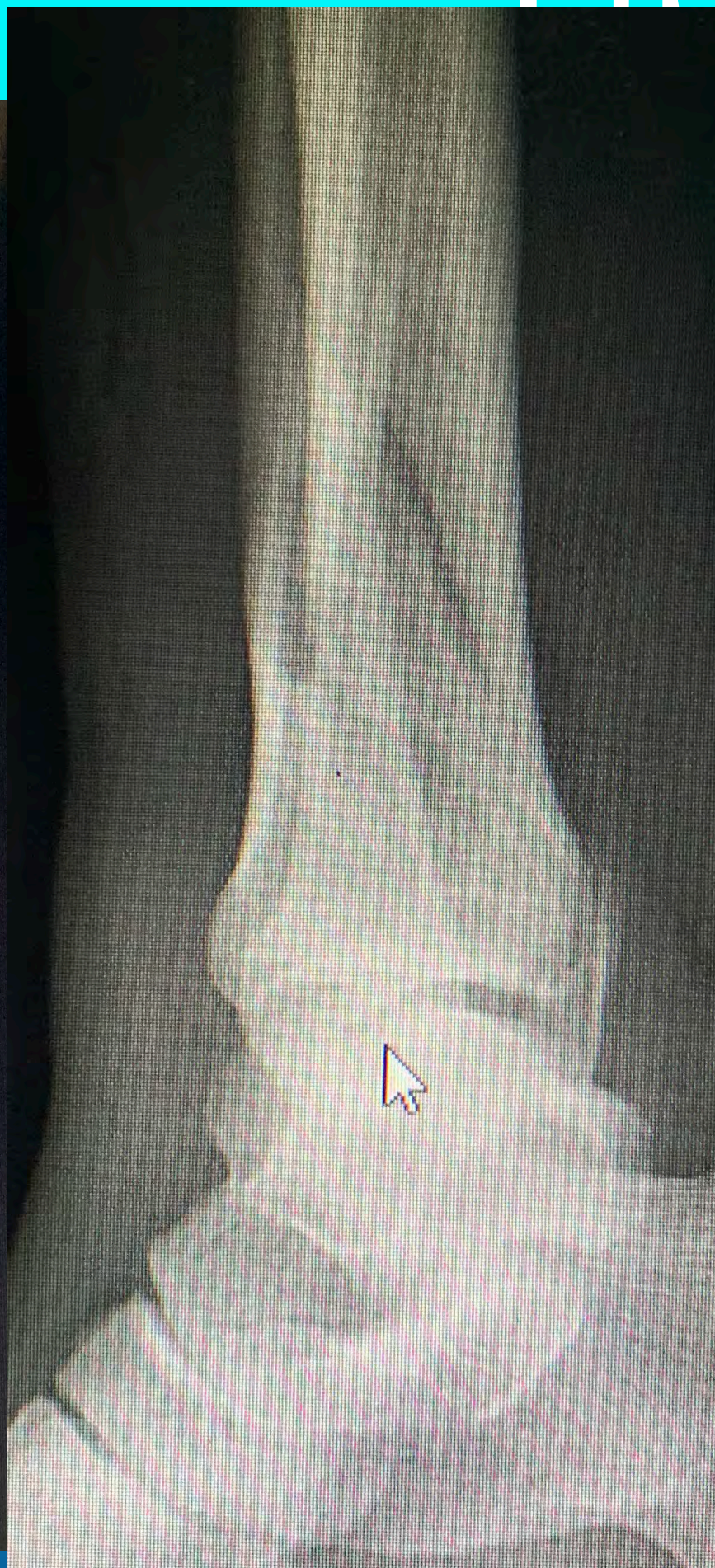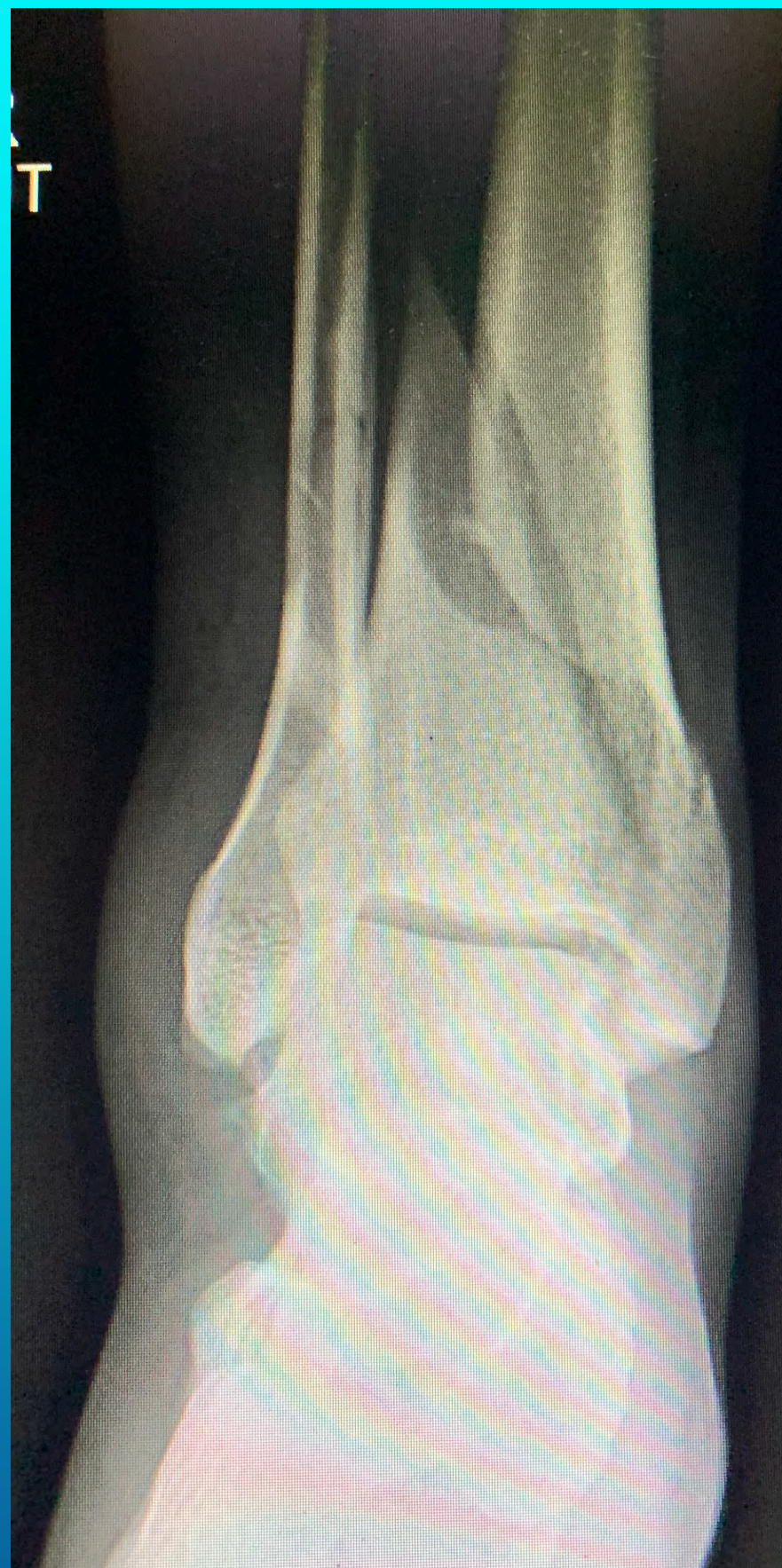- “Water Ski” position
 - Low Leg & Sugar-tong
 - Mid-shaft/Distal
 - Long leg
 - Proximal
- Compartment checks
- Soft-tissue injury
- Neurovascular checks
- Admit/Observation
- Open Fx/High Energy
 - OR for Irrigation
 - Ex Fix
 - Protect skin



Tibial Plafond Fx

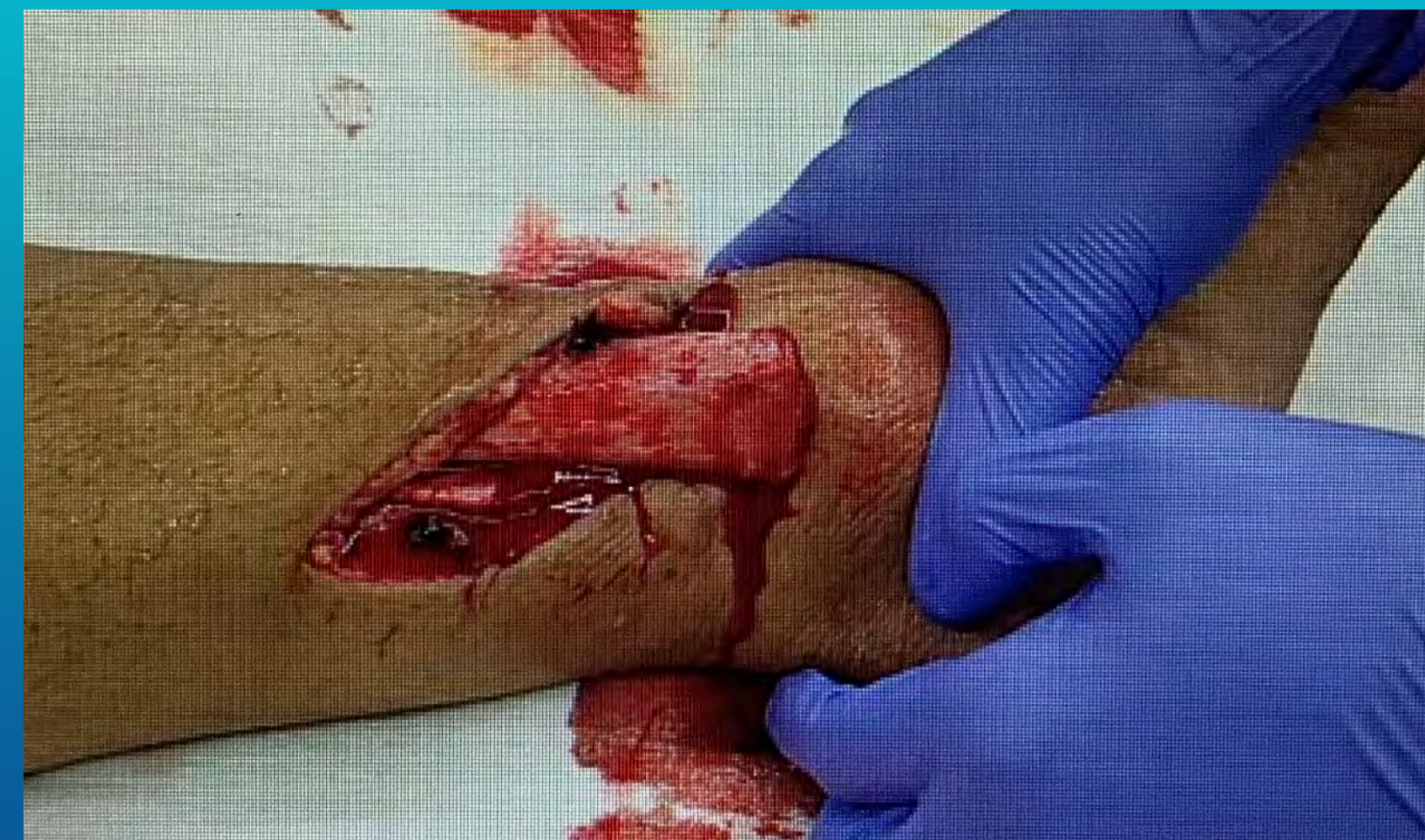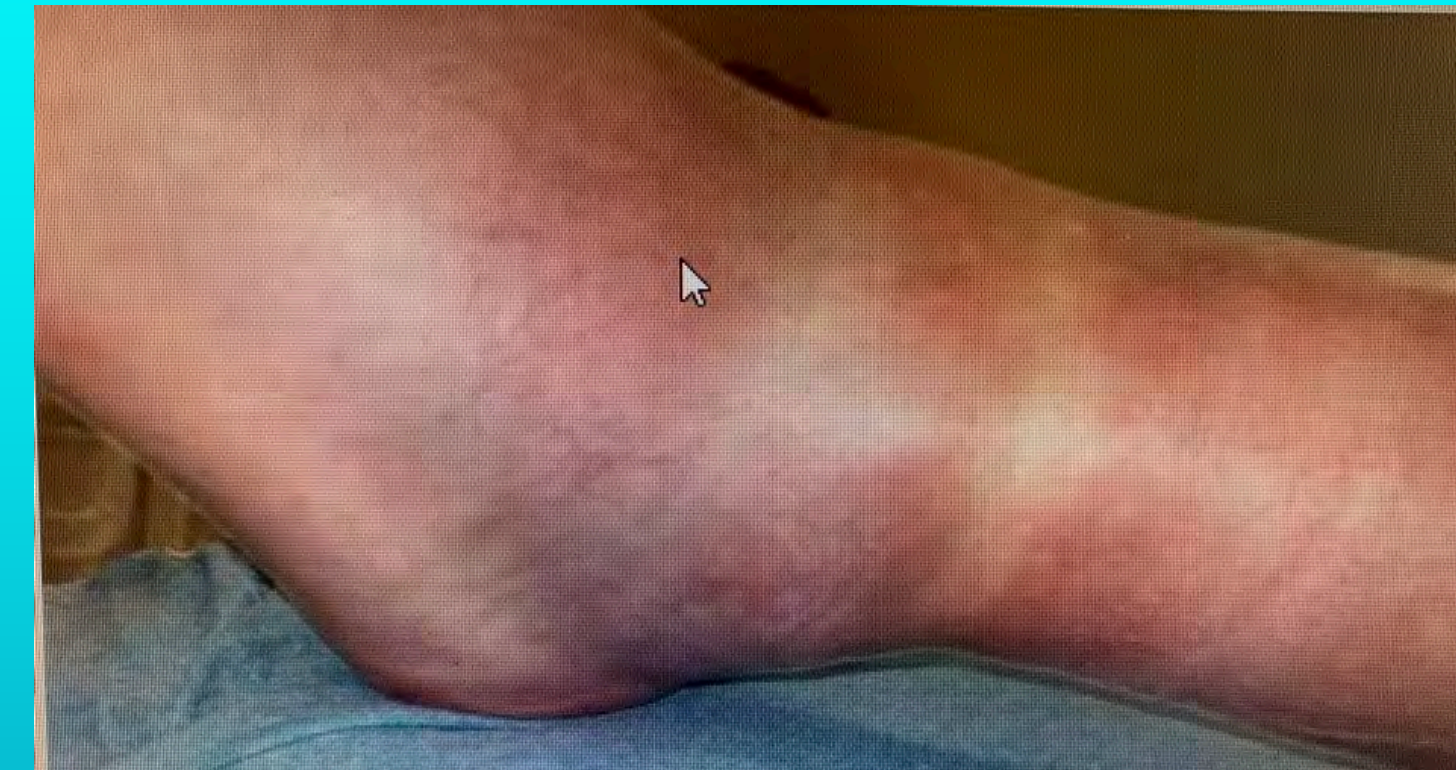- **Plafond:** anatomic location on the distal tibia
- **Pilon (Pylon):** describes force of injury
 - Most times used interchangeably
 - Described as any distal tibia fx extending into articular surface vs. comminuted fx of the tibial plafond
- Male > Female
- Increased incidence of pilon fx 2nd to higher survival rates from MVA
- ¼ all pilon fx open
- Increased soft-tissue trauma assoc. with pilon fractures
- Fracture blisters commonly associated with pilon fx
- Fibula fx commonly seen with pilon fx

Tibial Plafond Fx



Tibial Plafond Fx

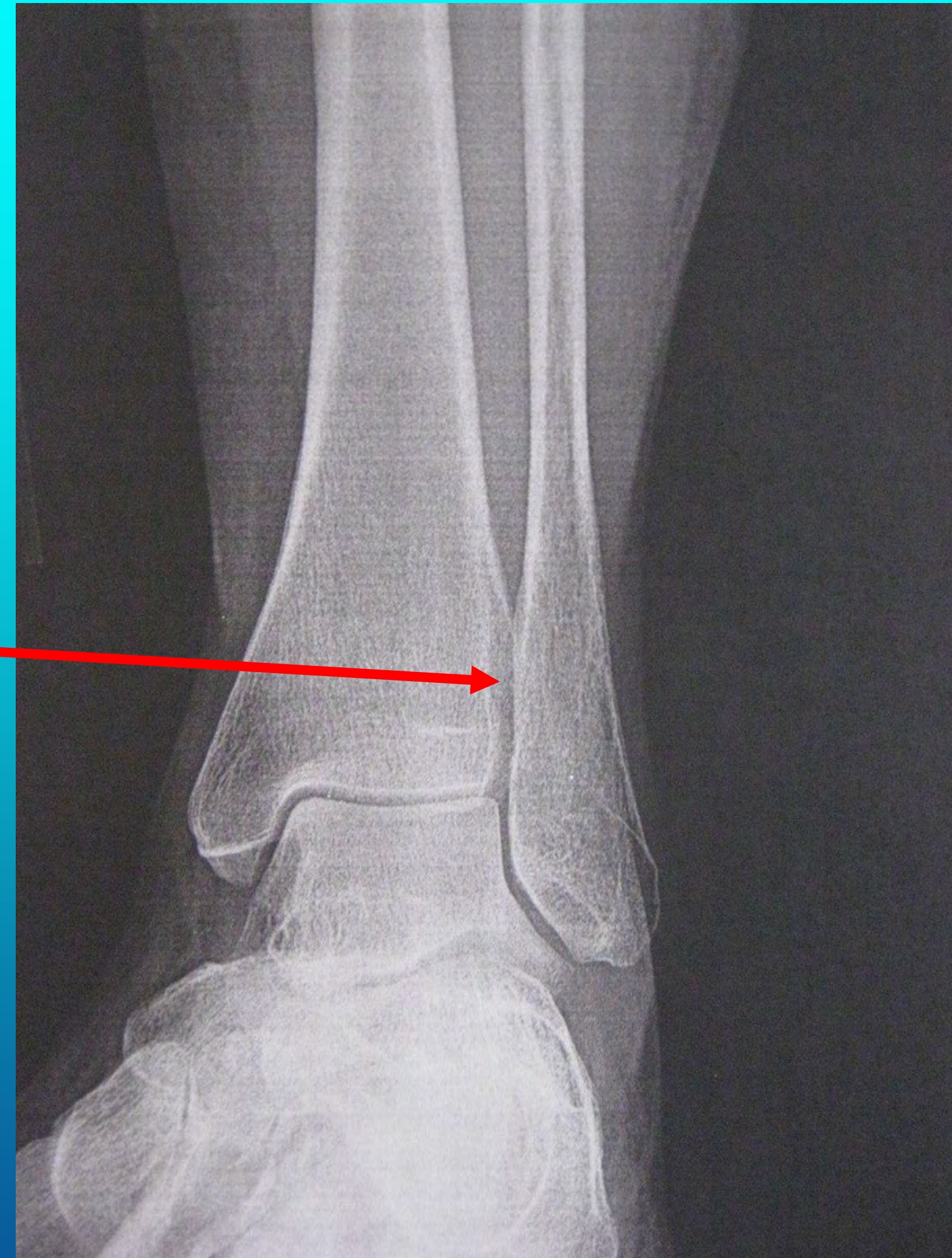
- 25% open fx
 - Gustillio- soft-tissue injury
 - “Man Scan”
- Assoc. Injuries
 - Compartment syndrome
 - L spine compression fx
 - Calcaneous- Plateau-Hip-Pelvis
- Open fx protocol
 - Admit
 - Tetanus
 - ABX coverage
 - Wound care
 - Immobilize
 - Splint
 - Ex-Fix



Ankle fx

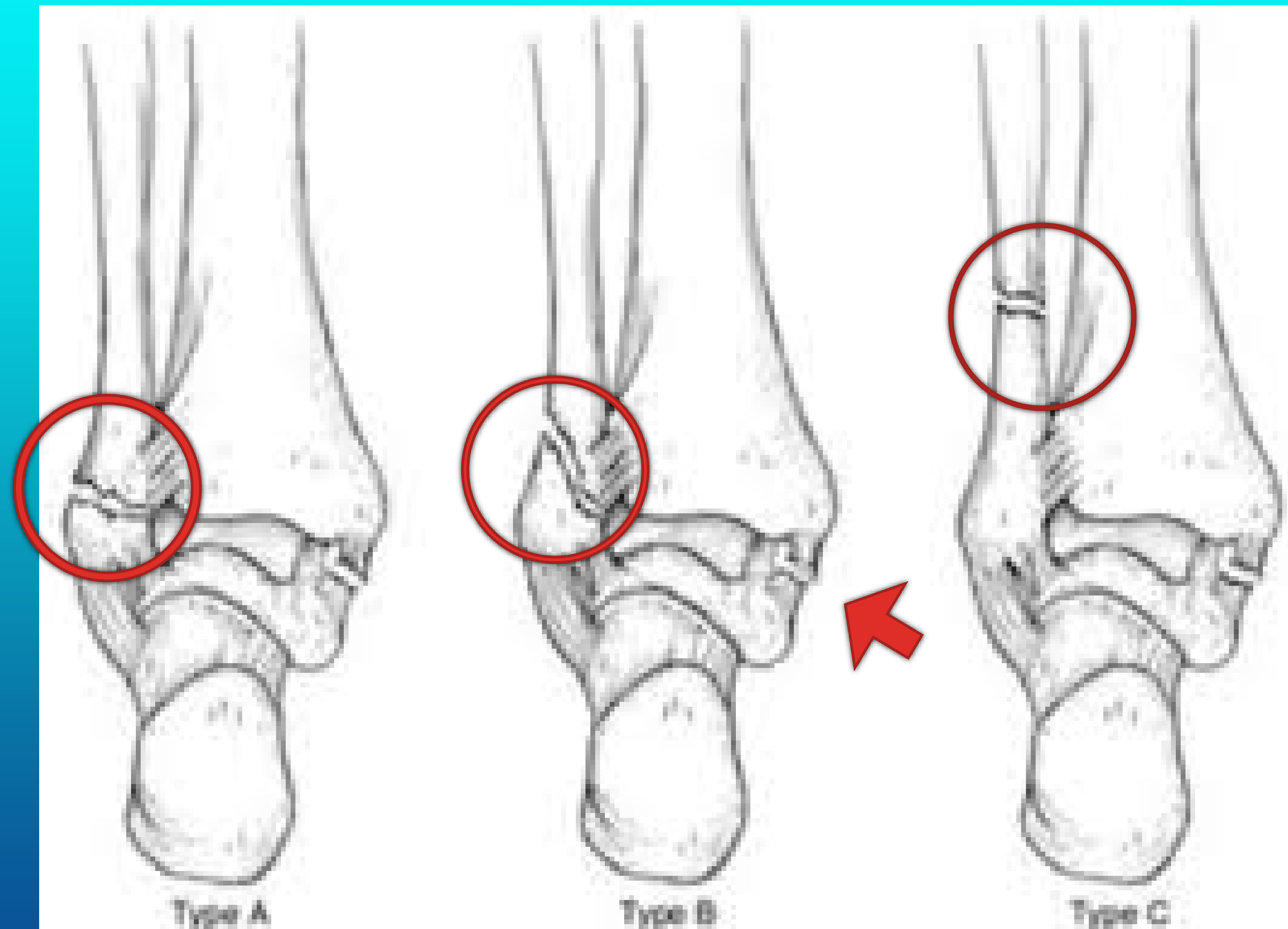
Radiographs

- Ankle (medial) clear space
 - Look for 42% overlap
- Tibiofibular clear space
 - Normal range <5 mm between tibia & fibula



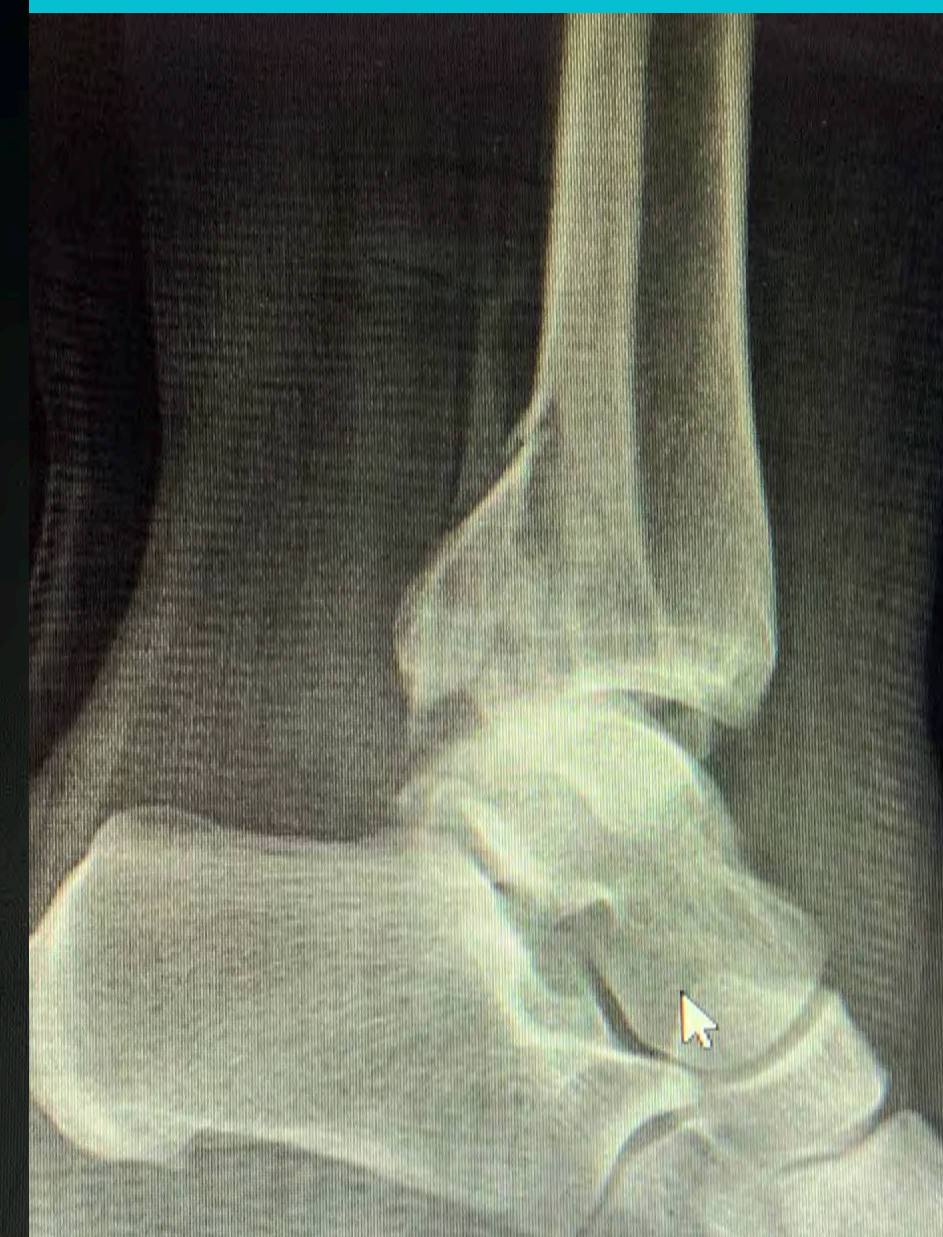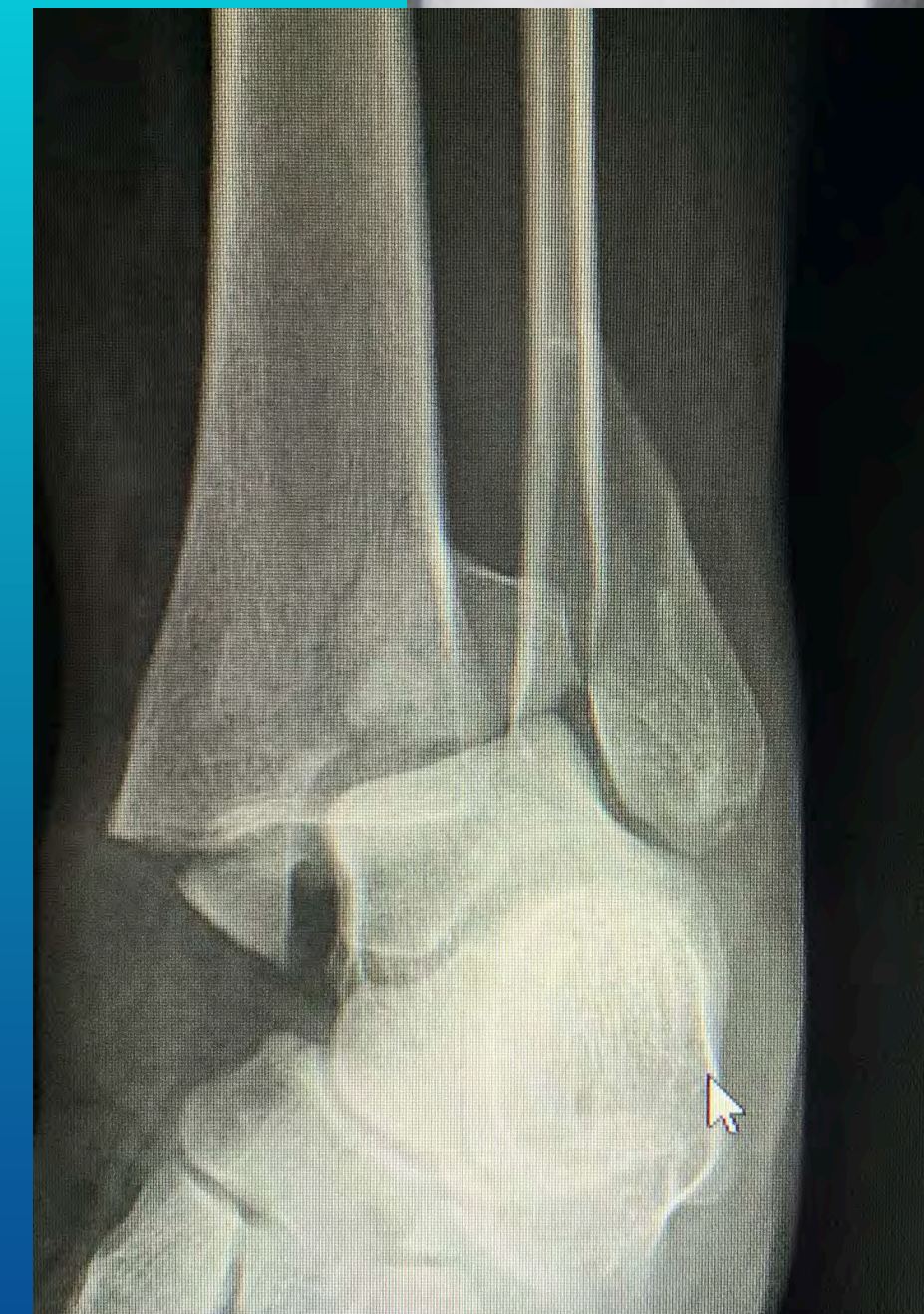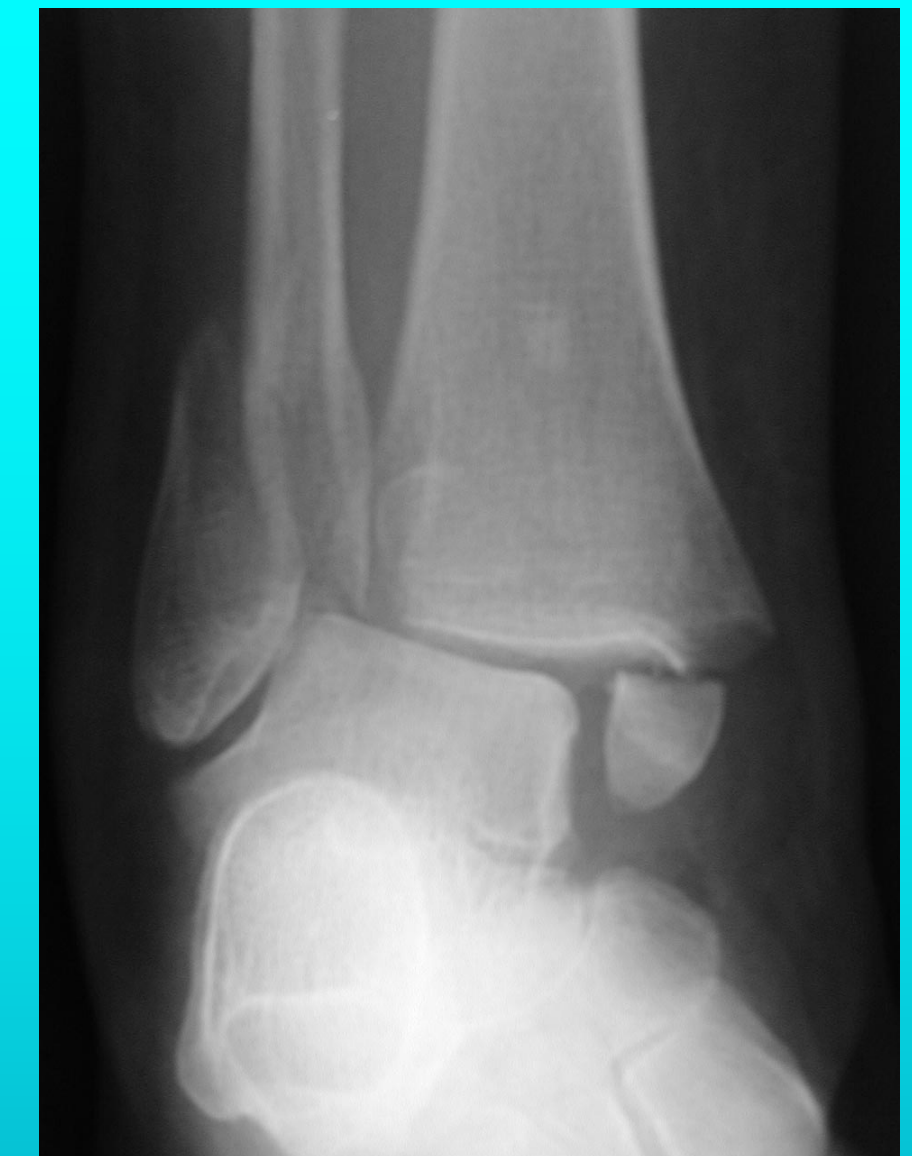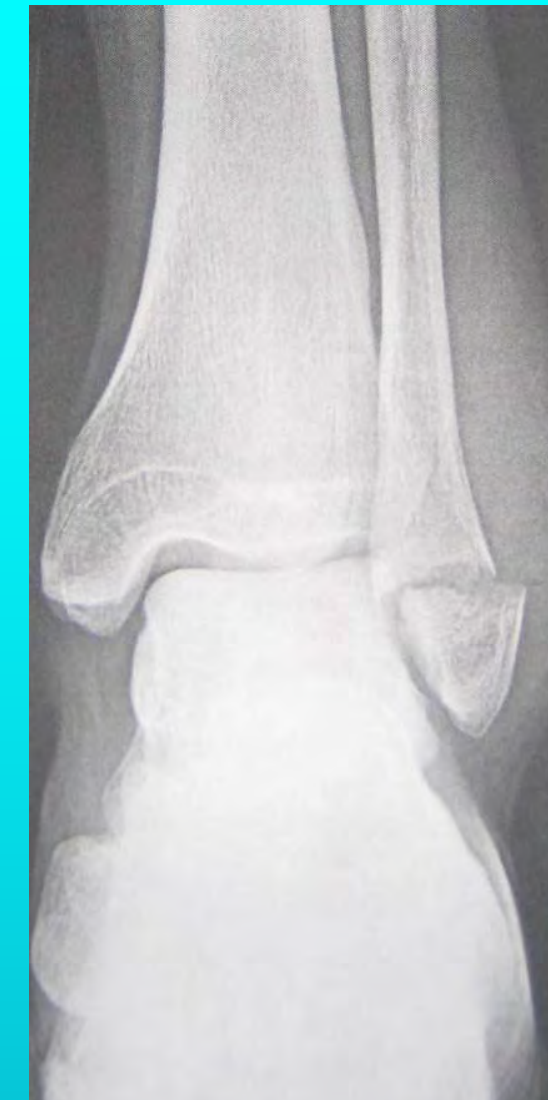Ankle Fx

WEBER Classification



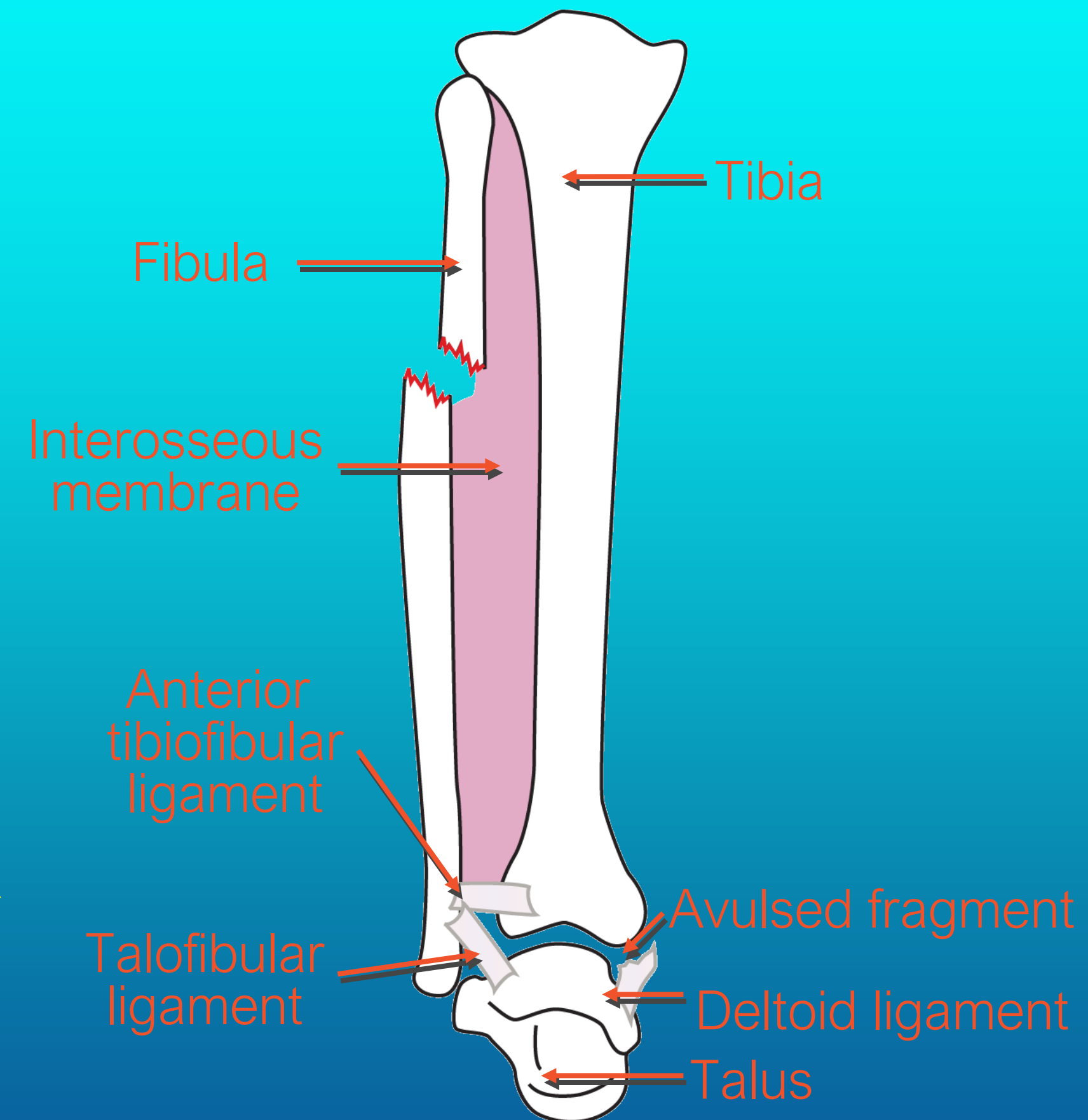
Ankle Fx

- Unimalleolar Fx – 68%
 - Isolated Fibular fx
 - Normal Mortise
- Bimalleolar Fx – 25%
 - Medial & Lateral Malleolus
 - Bimalleolar equivalent – Fibula Fx & Medial Ligament injury
 - Wide Mortise ?
- Trimalleolar Fx –
 - Medial-Lateral-Posterior
 - Wide Mortise
- Ankle Fx/Dislocation
 - Disruption Ankle Mortise
 - Talus displaces from Plafond
 - Look @ Syndesmosis



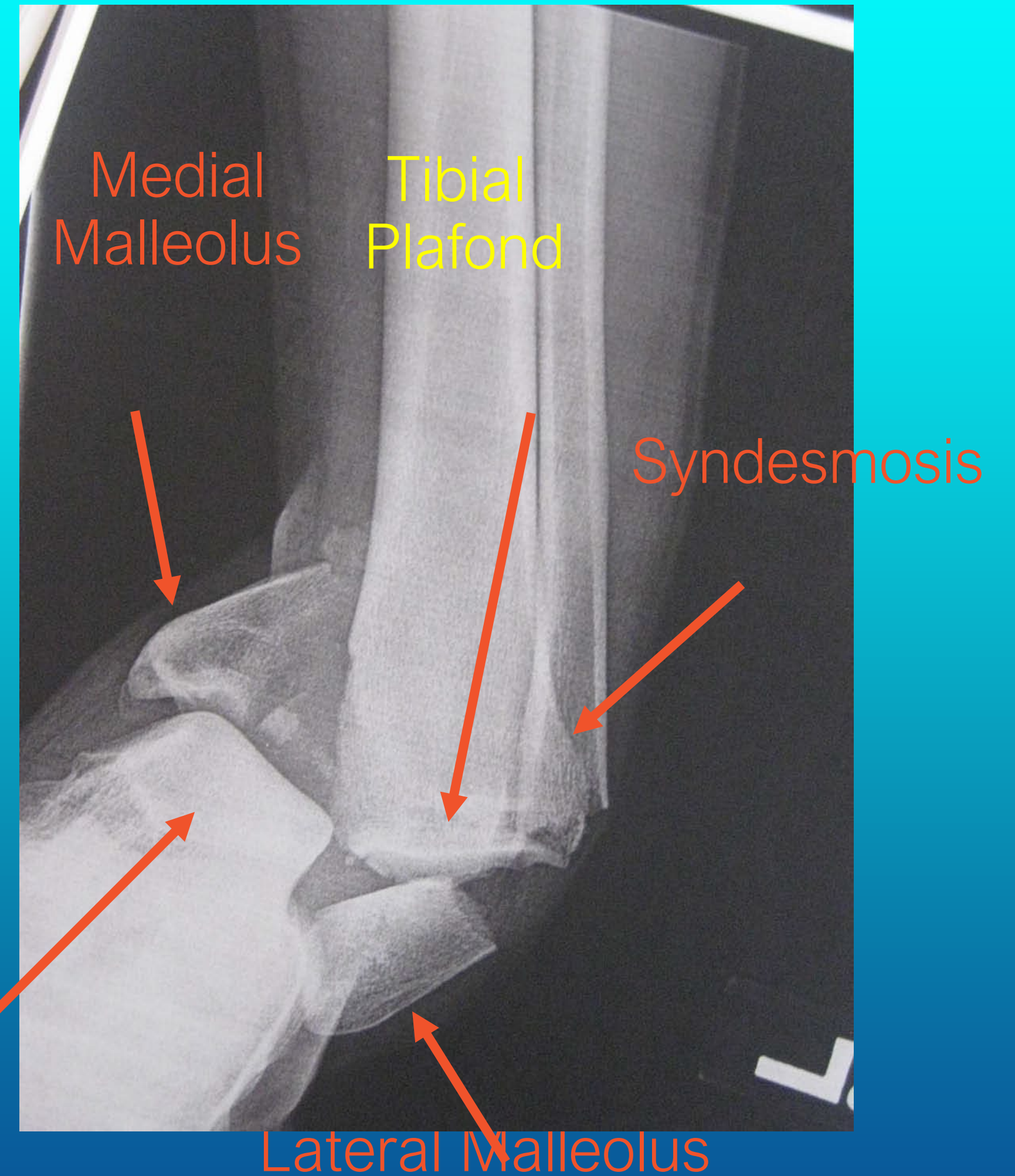
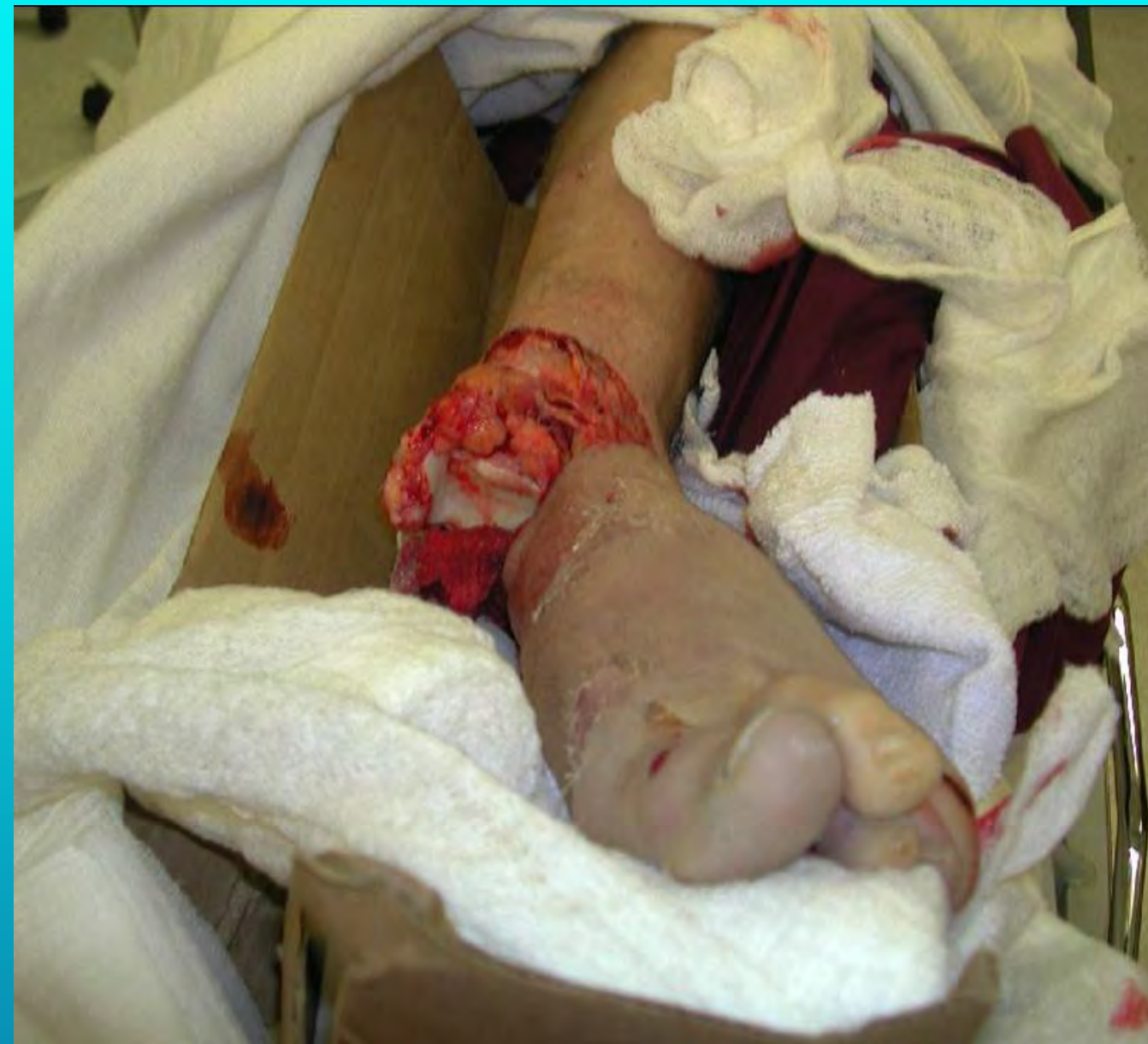Maisonneuve's Fracture

- ◆ Maisonneuve's fracture involves fracture of the proximal fibula
- ◆ Associated medial Malleolus fracture
 - ◆ Deltoid ligament injury and/or
 - ◆ Injury to the syndesmosis
- ◆ **Medial malleolus fracture & force transmitted through interosseous membrane and exits at proximal fibula**
- ◆ Do not assume medial malleolus fractures is isolated
 - ◆ **Palpate proximal Fibula**

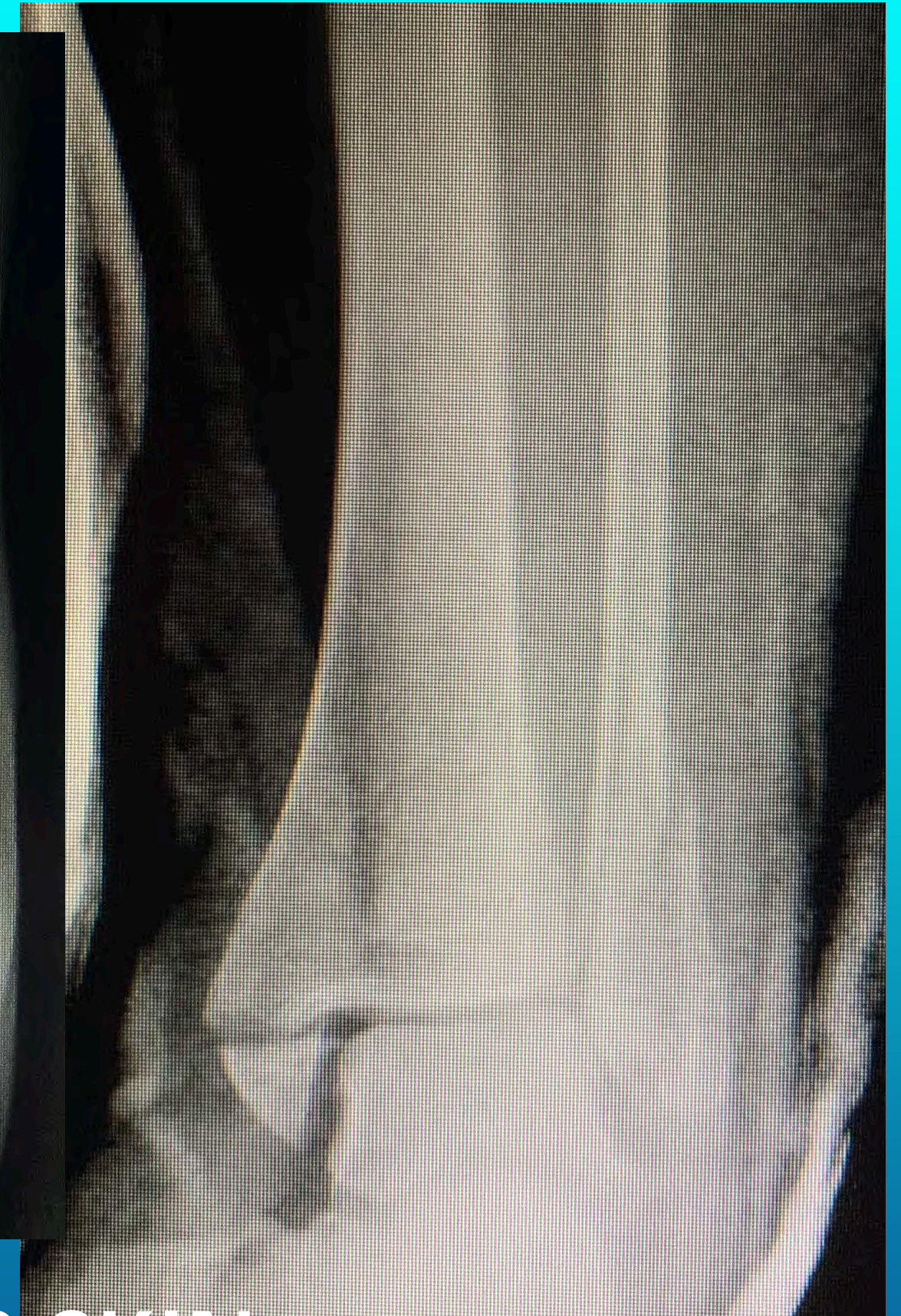
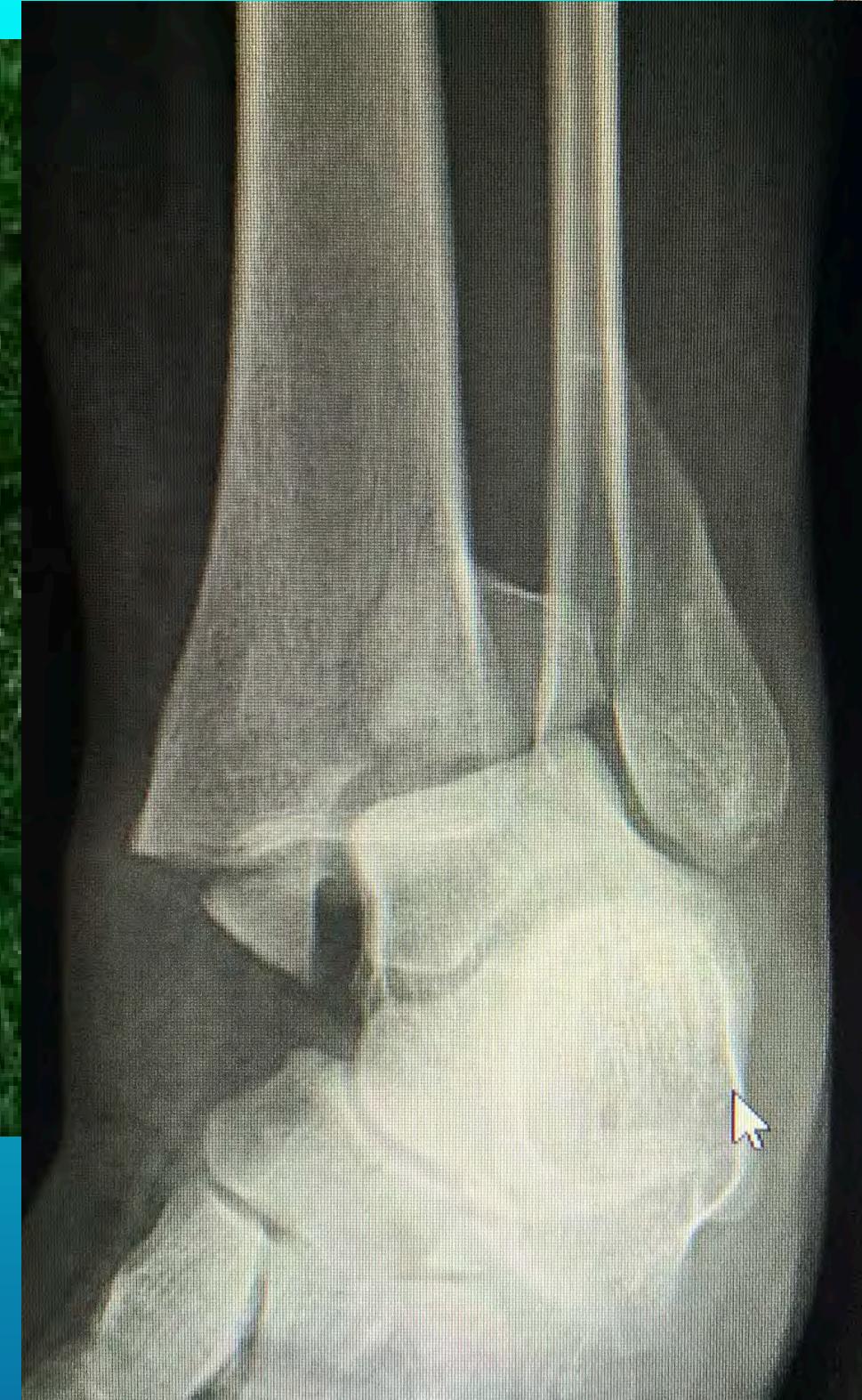
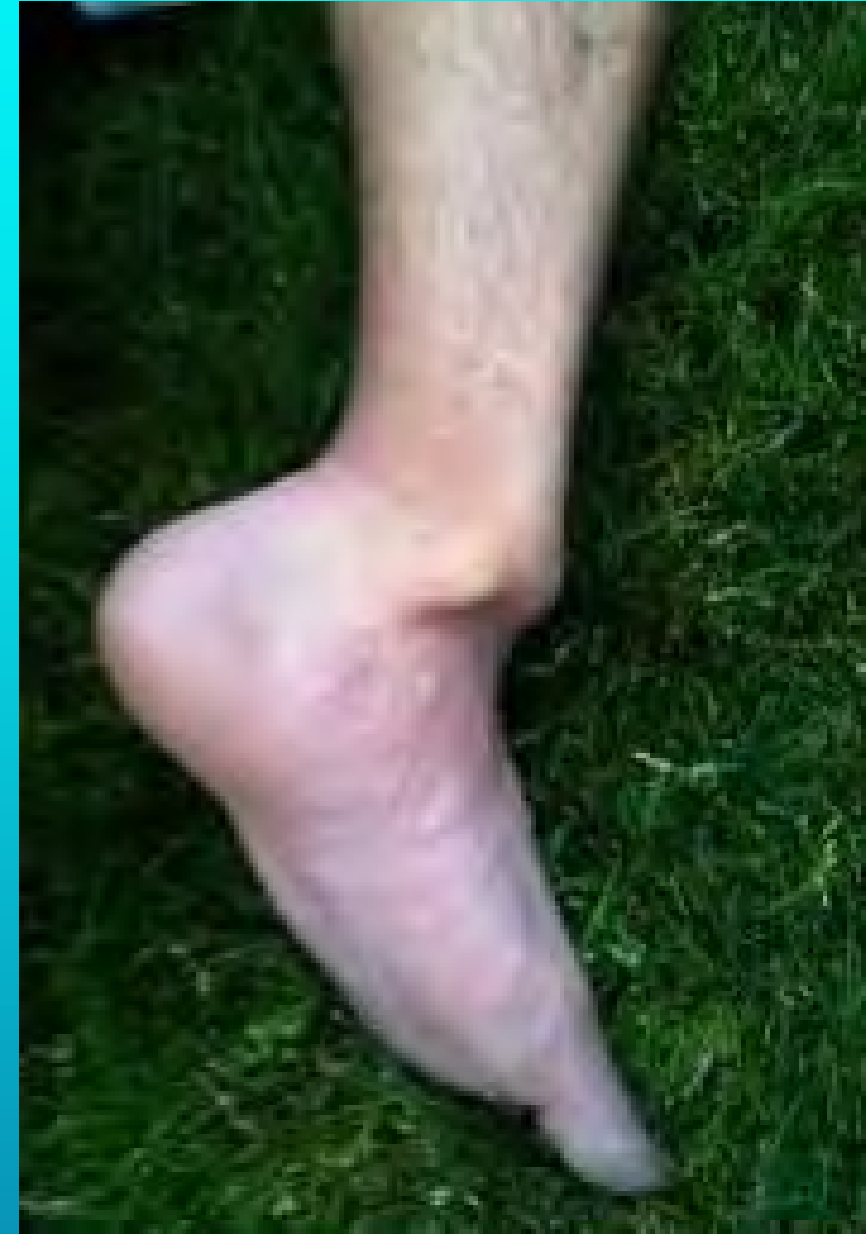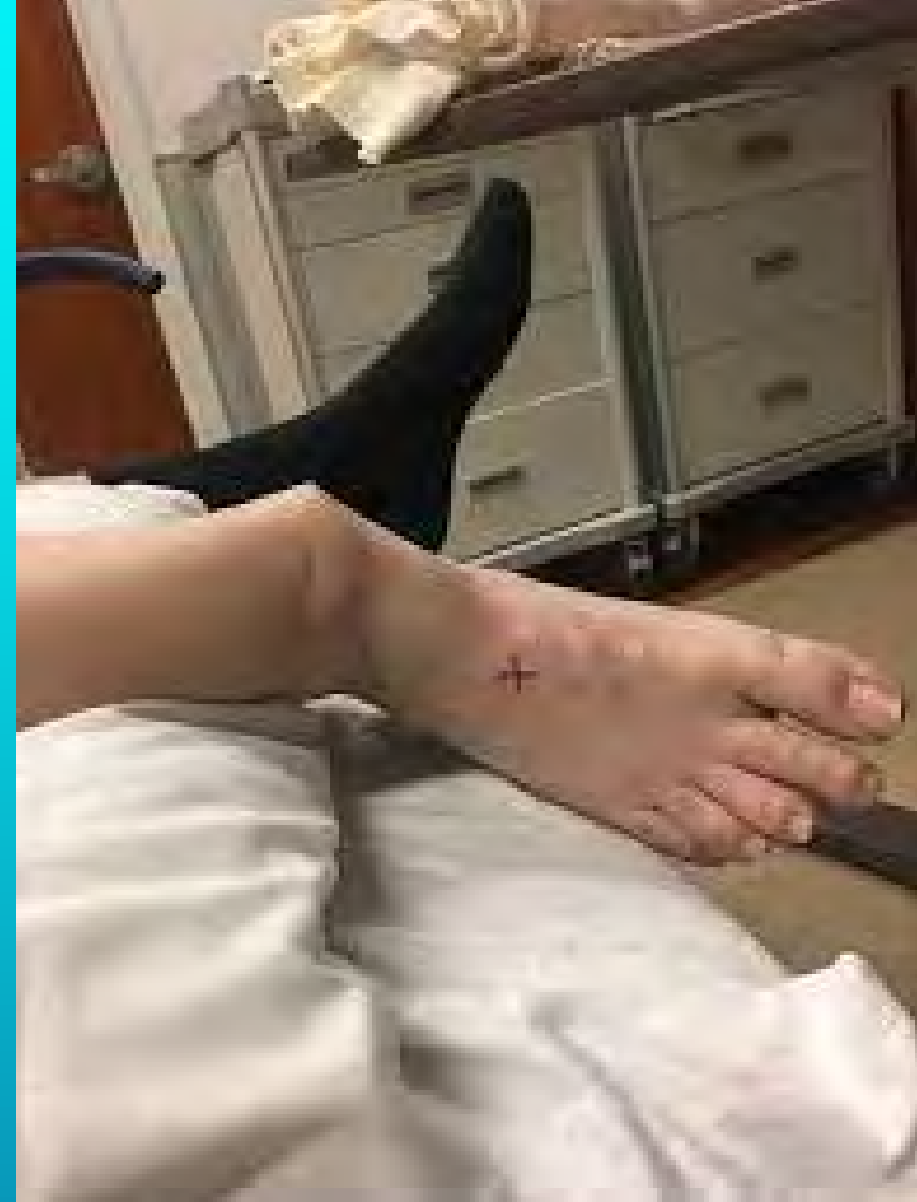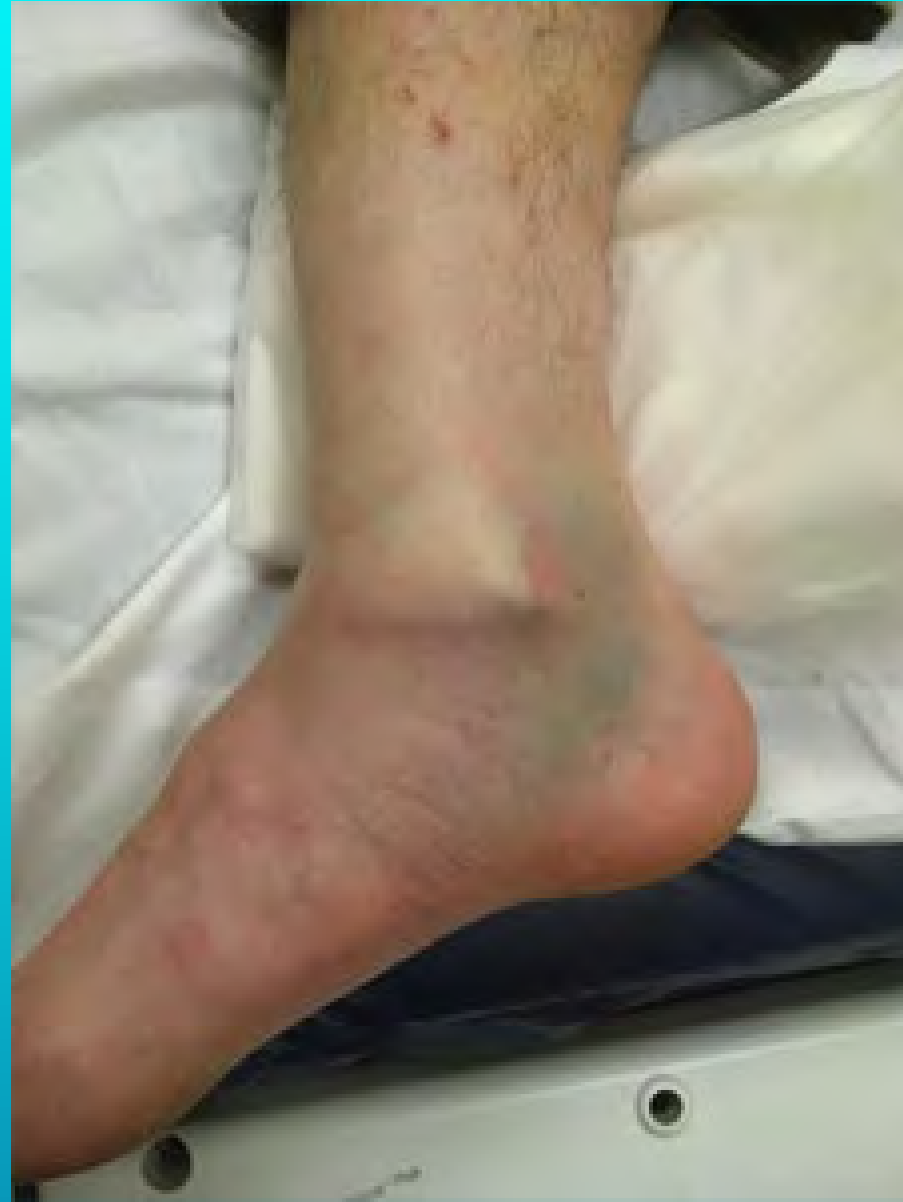Ankle Fracture-Dislocation

- Associated with Bimalleolar or Trimalleolar ankle fractures
- Talus and foot translated completely out of mortise
- Obvious deformity to ankle and foot
- Open vs. Closed
- Play close attention to pre & post reduction neuro and vascular exams



Ankle Fx/Dislocation



REDUCTION AS SOON AS POSSIBLE PROTECTS SKIN

Ankle Fx/Dislocation

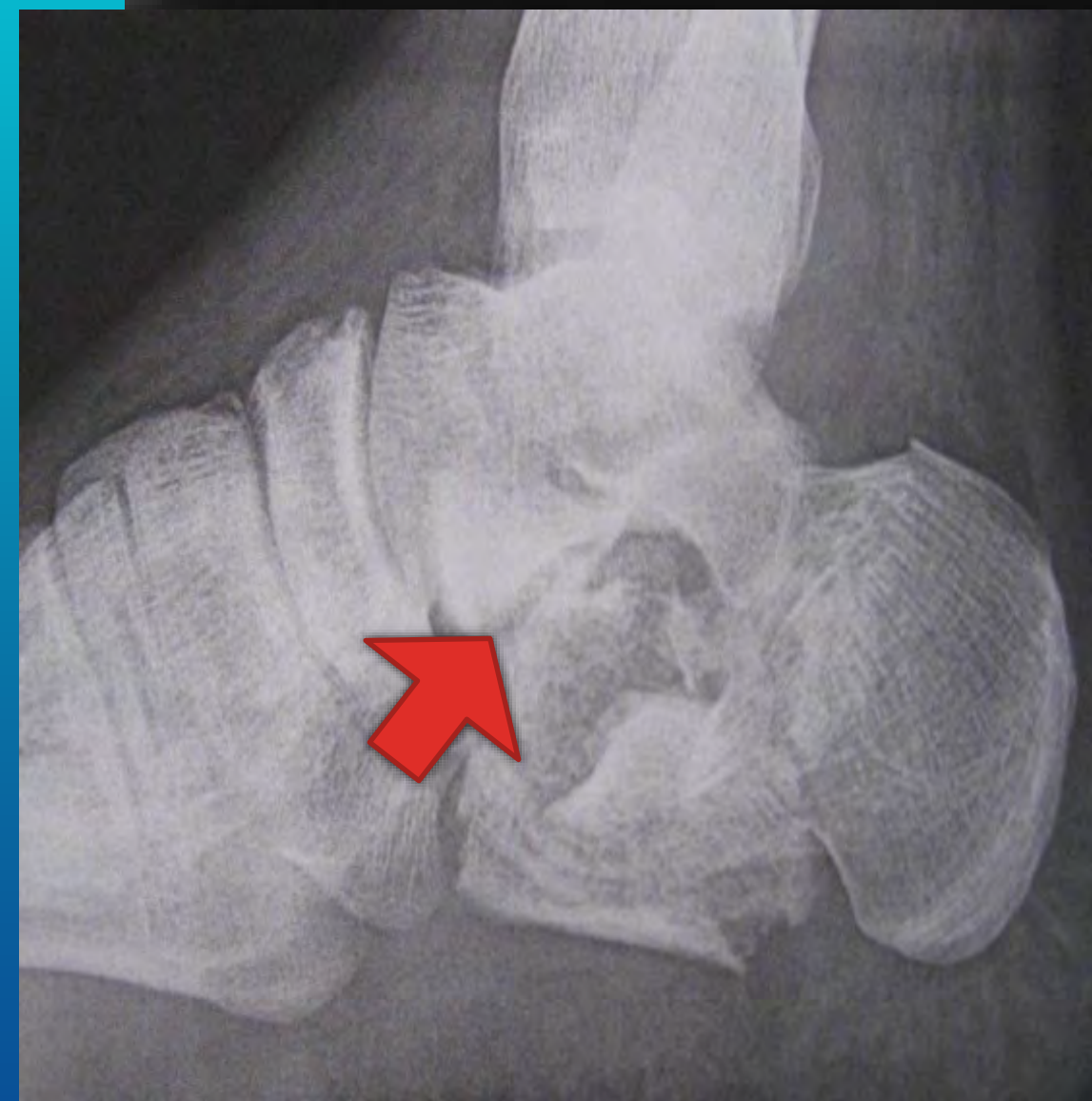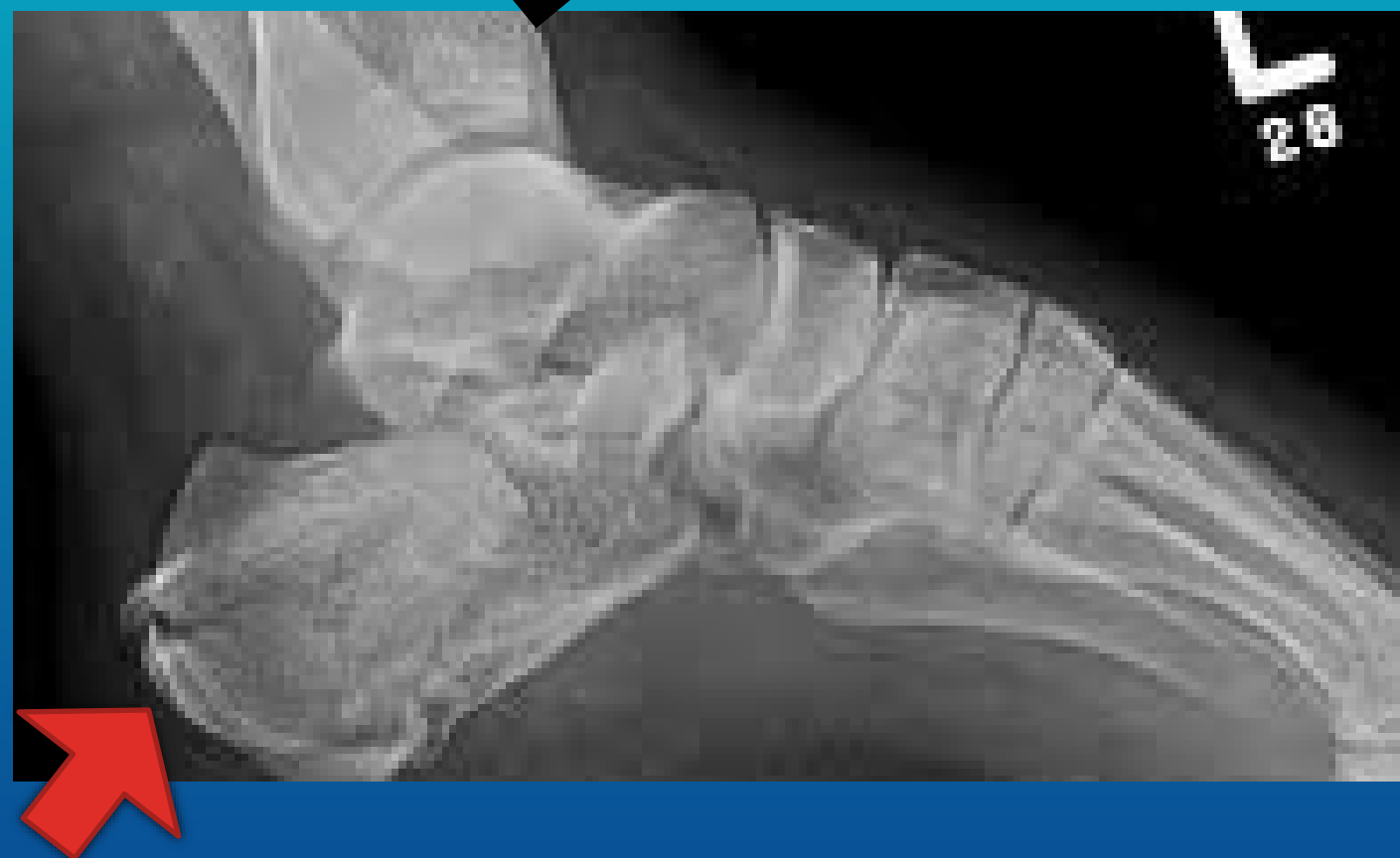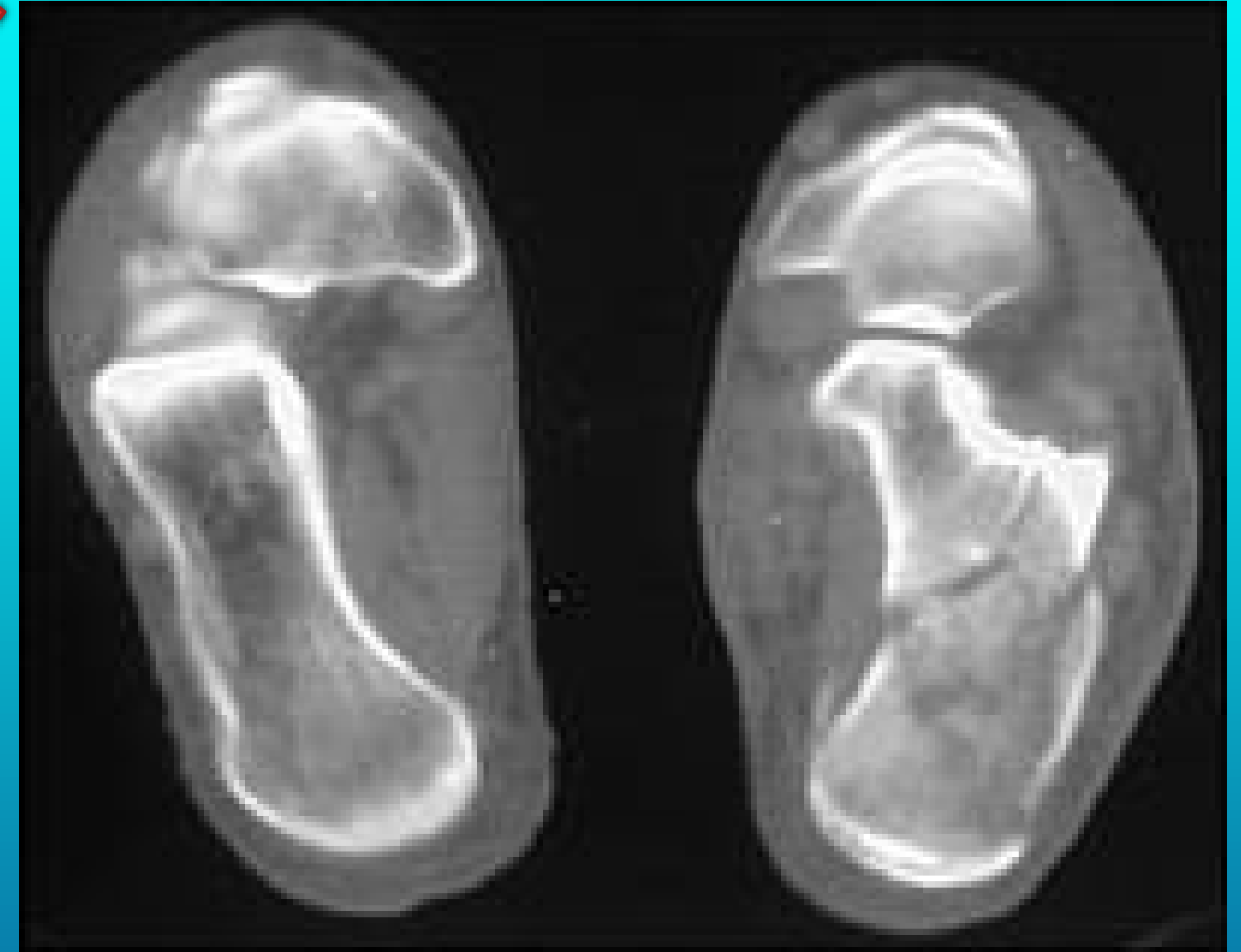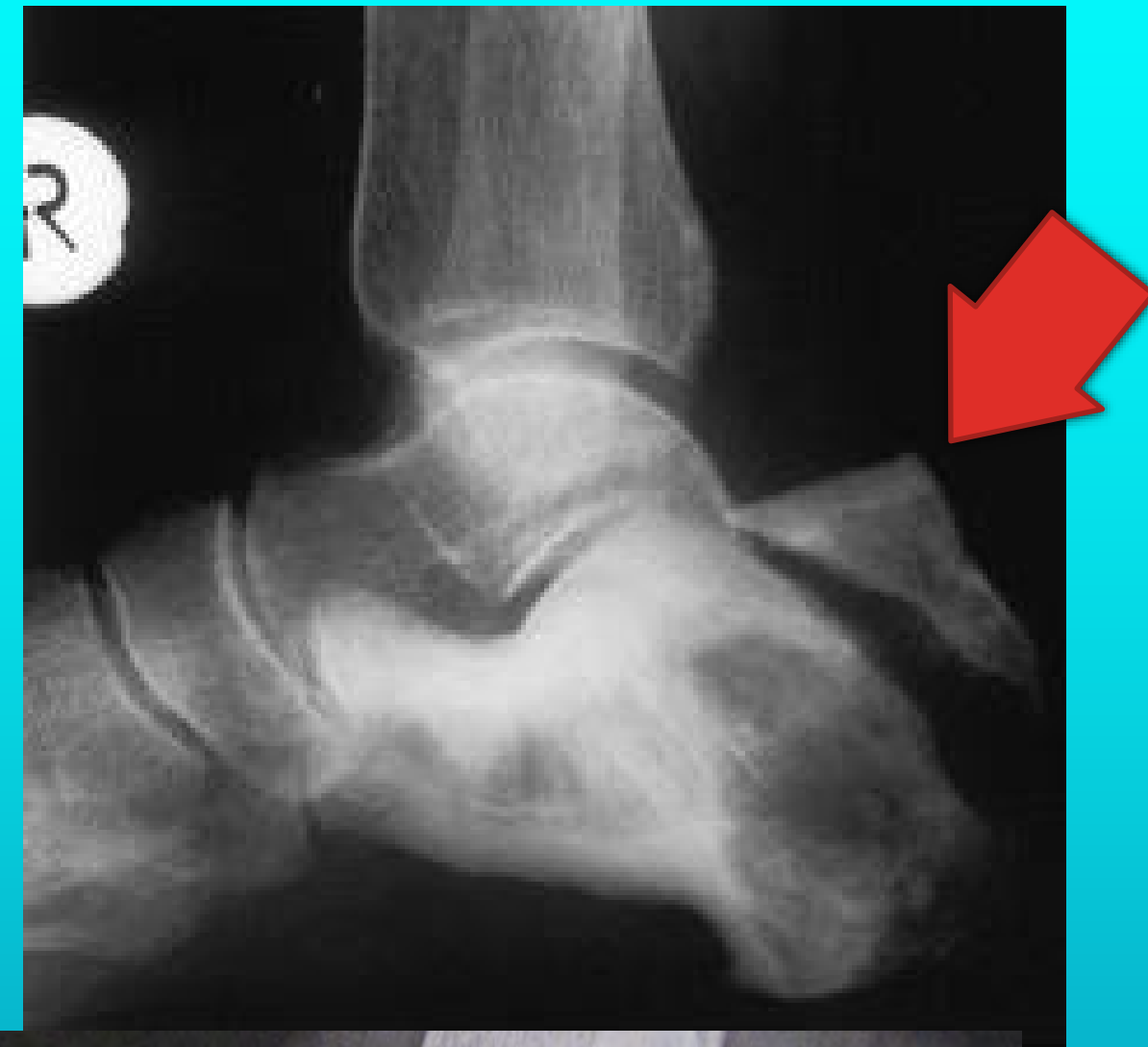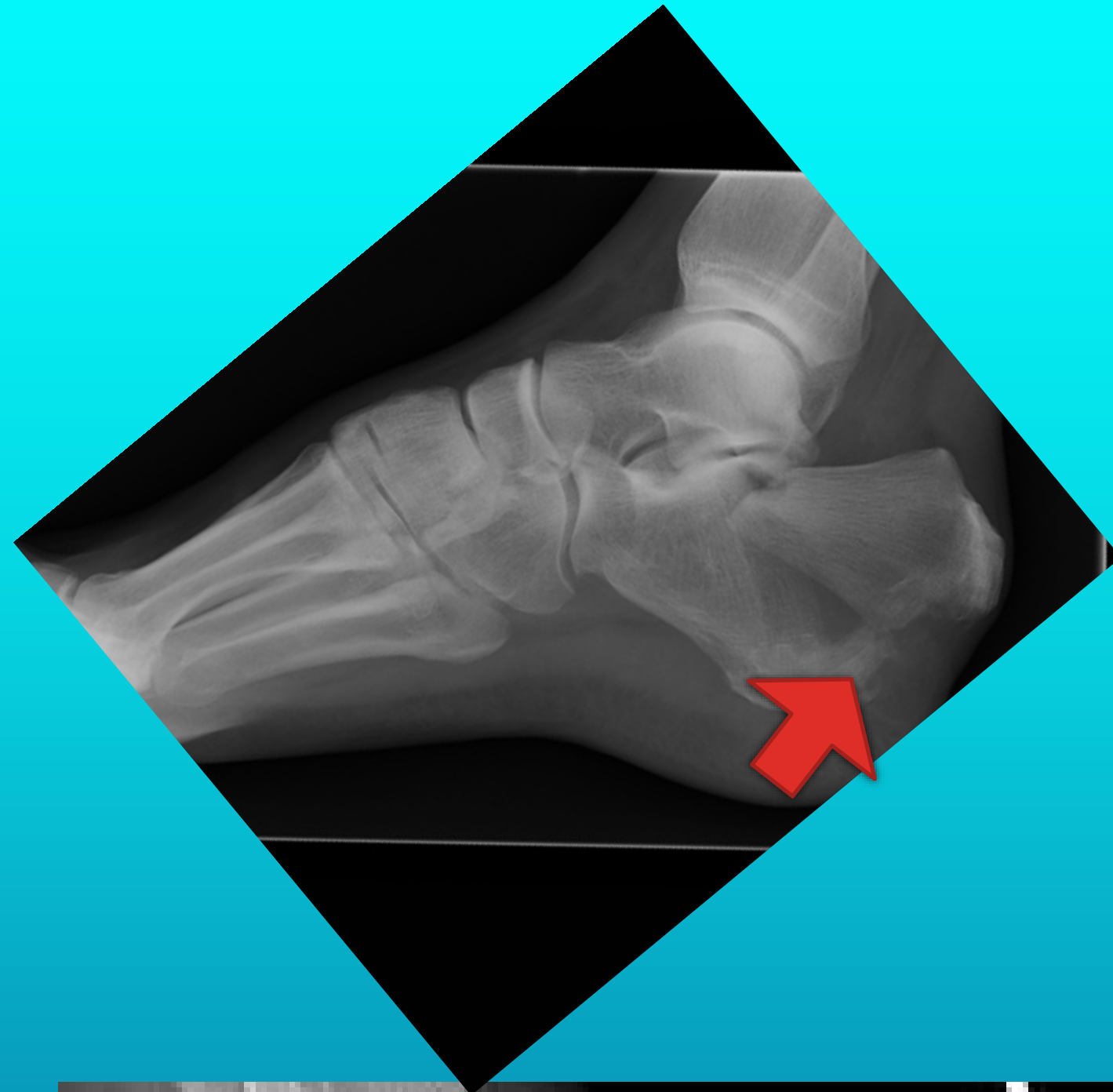- Knee flexion – relaxes effects of Gastroc
 - Water ski traction
 - Reduction
 - Dangle ankle over the edge of the table
- Hold reduction while splint applied and Dries
 - Hold Big Toe and Internal rotation
 - Posterior & Sugar-tong/stirrup splint
- Check Neurovascular frequently
- Post reduction x-ray

Calcaneous fx

Calcaneous Fractures

- Common tarsal bone fracture
- 65-75% fx intra-articular
- 17% open fx
- High energy mechanism
 - tends to have poor outcomes
- Men > Women
- Associated injuries
 - Lumbar Spine fractures
 - Femur/Pelvis fractures
 - Contralateral Calcaneous fx
- Watch for Tarsal Tunnel syndrome
- Watch for foot compartment syndrome
- Mondor sign- plantar bruising

Calcaneal Fracture



Calcaneous Fracture

- Initial Treatment:
 - Assess for associated Injuries
 - RICE
 - Bulky padded dressing and splint
 - helps decrease swelling
 - Reduces soft tissue injury
 - Fx Blisters common occurrence – (“bacterial cesspools”)
 - NWB
 - Compliance Issues
 - Poor: Bulky padded splint, admit– RICE – Skin checks – Surgery at appropriate time
 - Reliable: Bulky padded splint, D/C- RICE- skin check office one week – Surgery at appropriate time
 - Encourage smoking cessation, blood sugar control, good nutrition

Lisfranc Injury

Lisfranc Fracture

- Defined: *disruption in articulation 2nd (medial) cuneiform & base second metatarsal leading to disruption TMT joint complex*
- Age- 30”s
- Males>females
- MVAs, falls from height, and athletic injuries
- Injury mechanism :
 - *caused by rotational forces & axial load, forefoot Hyperplantar flexed*

Lisfranc Fractures

Picture courtesy T Gocke, PA-C

Physical Examination:

- **History**

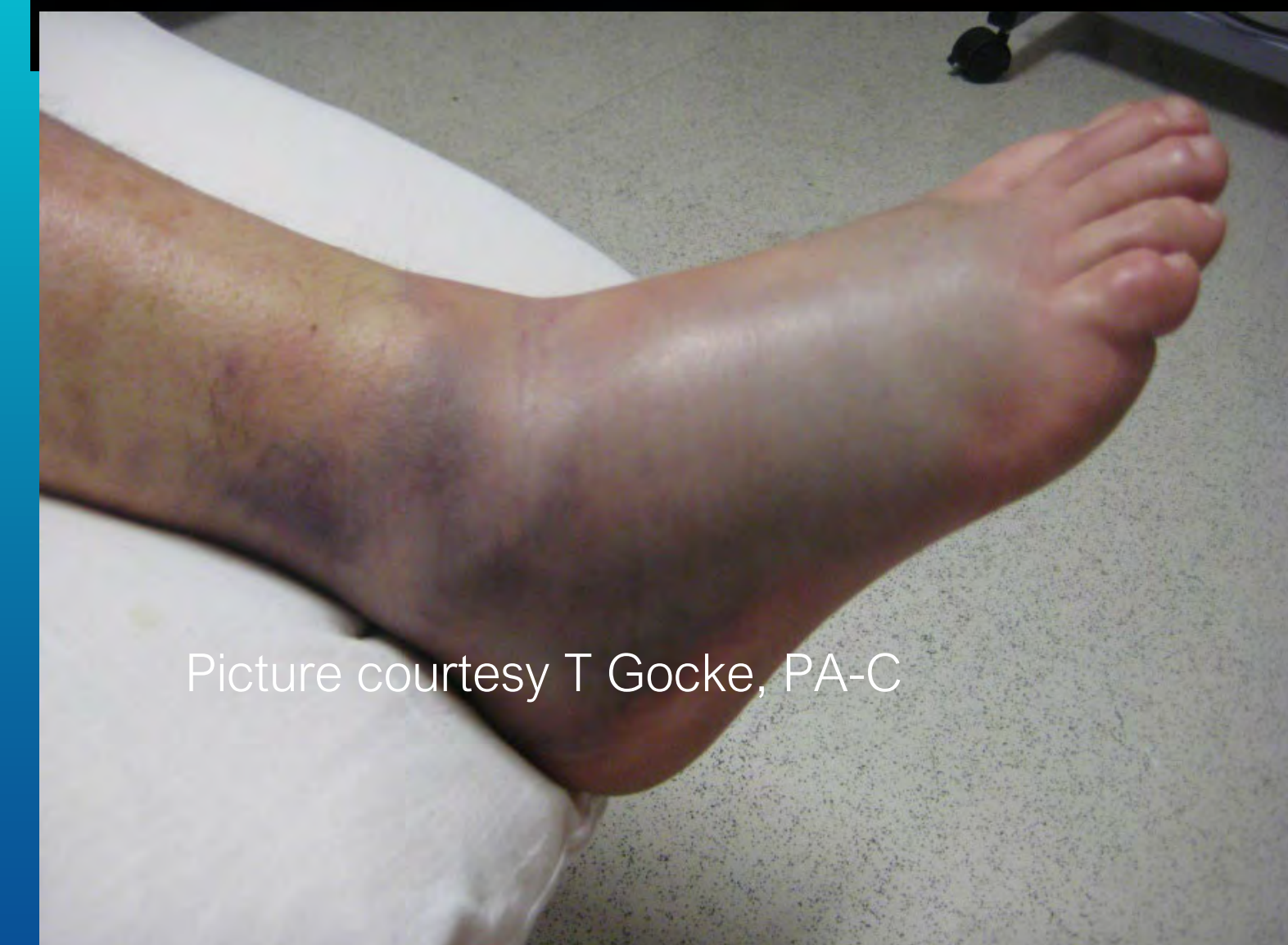- Severe pain
- Unable to wt bear
- “told they had a sprained foot”
- “negative x-rays”

- **Exam**

- plantar bruising --Mondor sign
- swelling throughout midfoot
- tenderness over tarsometatarsal joint
- Loss of motion & stability

- **Treatment**

- Similar to Calcaneous/Talus Fx
- Most require surgical intervention



Picture courtesy T Gocke, PA-C

Metatarsal Fx

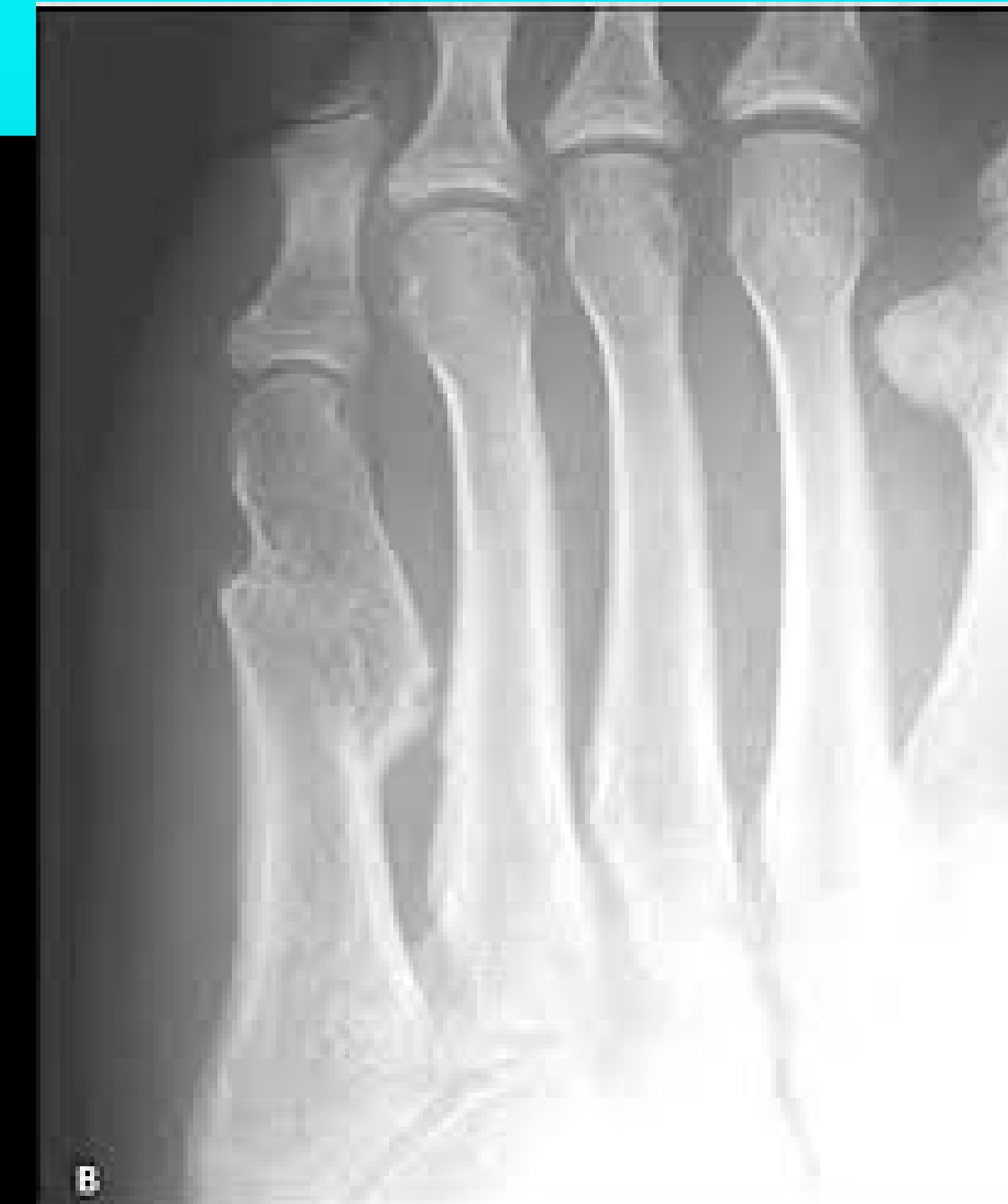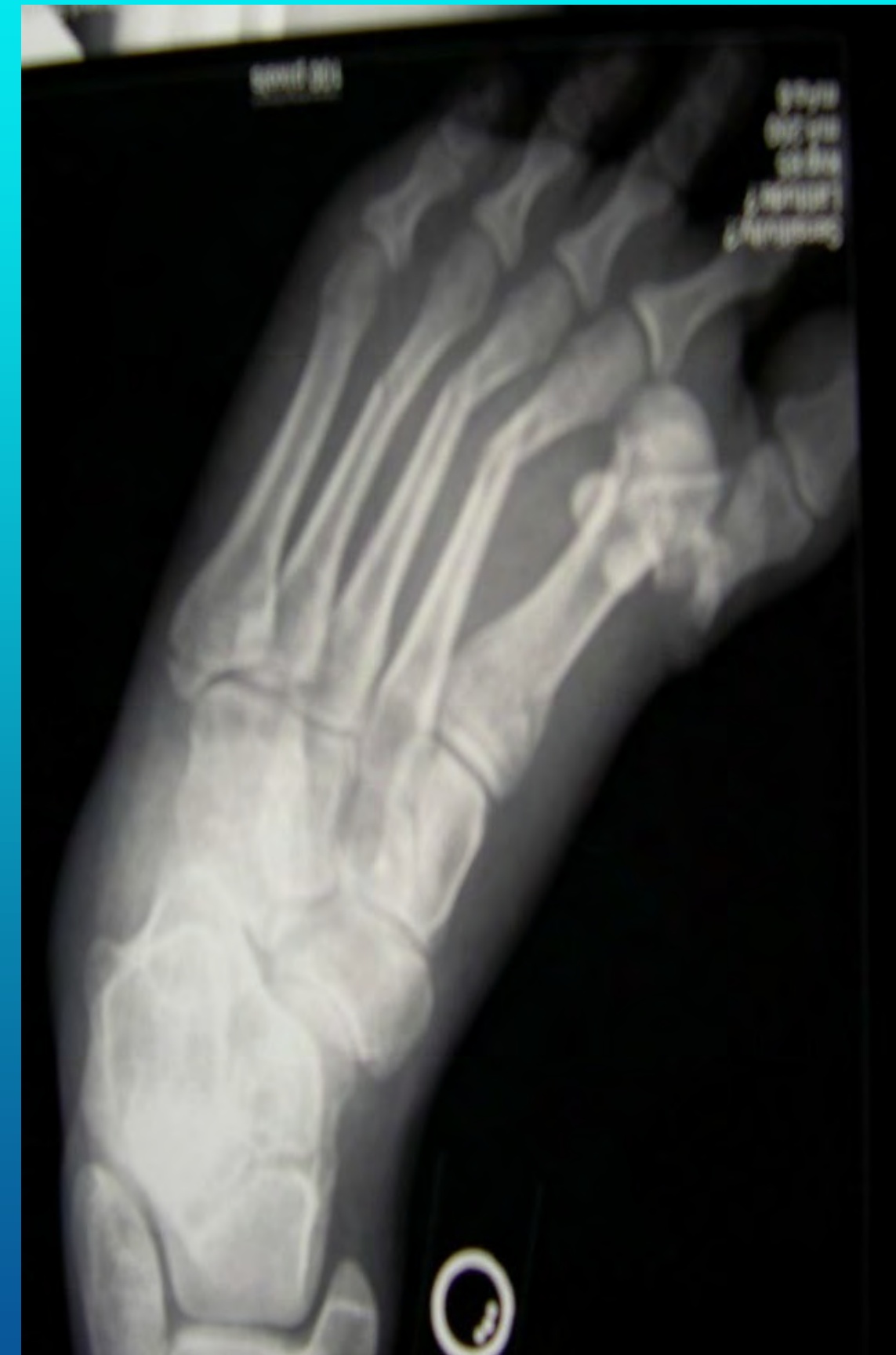Metatarsal Fractures

- Metatarsal fractures common injuries of the foot
- 5th metatarsal most commonly fractured
- 2nd and 5th decade of life
- 3rd metatarsal fractures rarely occur in isolation
 - fracture of 2nd or 4th metatarsal
- Most trauma related to crush injury or direct blow
- Most are non or minimally displaced/angulated
- Intact Great toe & 5th Metatarsal leads to stability of fx central 3 Metatarsals
- When fx displace-plantar direction
 - 2nd to pull by toe flexors & intrinsic muscles

Metatarsal Fractures

Radiographs

- Most oblique or transverse fx pattern
- More displacement at neck 2nd to flexor & intrinsic muscle
- > displacement & angulation if 1st MT fx
- <20 degrees varus/valgus angulation acceptable
- > 4mm plantar/dorsal displacement - reduce
- > 10 degrees dorsal angulation - reduce



Metatarsal Fractures

- Treatment
 - Monitor foot compartment syndrome
 - Well padded Jones dressing & splint/ fx boot/ post op shoe
 - Neuro/vascular checks
 - NWB – WBAT depending on fx and swelling
 - **FX beyond acceptable limits**
 - Finger/toe traps for closed reduction and splint
 - Repeat x-ray – good alignment then can D/C
 - Make NWB till follow up exam

Metatarsal Fractures

- **Unable to improve alignment**
 - Manipulate under anesthesia/ankle block
 - Closed reduction and reassess
 - CRPP and reassess
 - Padded dressing and splint/fx boot
- Healing time all FX
 - 4-6 weeks
 - Associated factors can slow or impede healing

Toe Fx

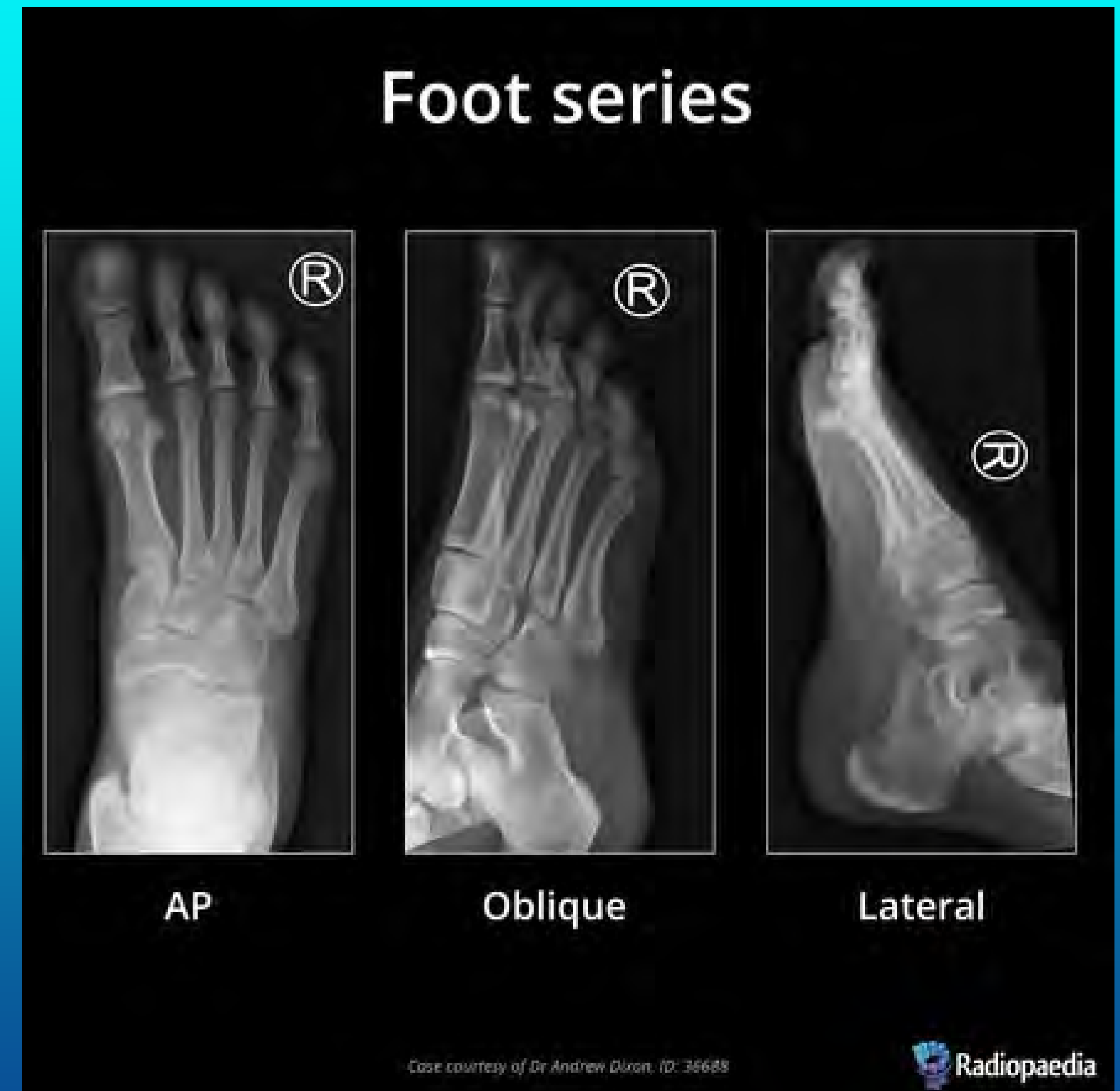Toe Fractures

- Toe Fx Account for < 7% all fx seen in Primary care setting
- Lesser Toe fx 4x more likely vs Great toe fx
- Most Lesser Toe fx are non-displaced
- Great toes Fx
 - involves >25% articular surface need close F/U & ? Surgery
 - Comminuted
 - Displaced
- Injury Mechanism:
 - Axial load – Jammed toe
 - Crush injury
 - Jt. Hyperextension

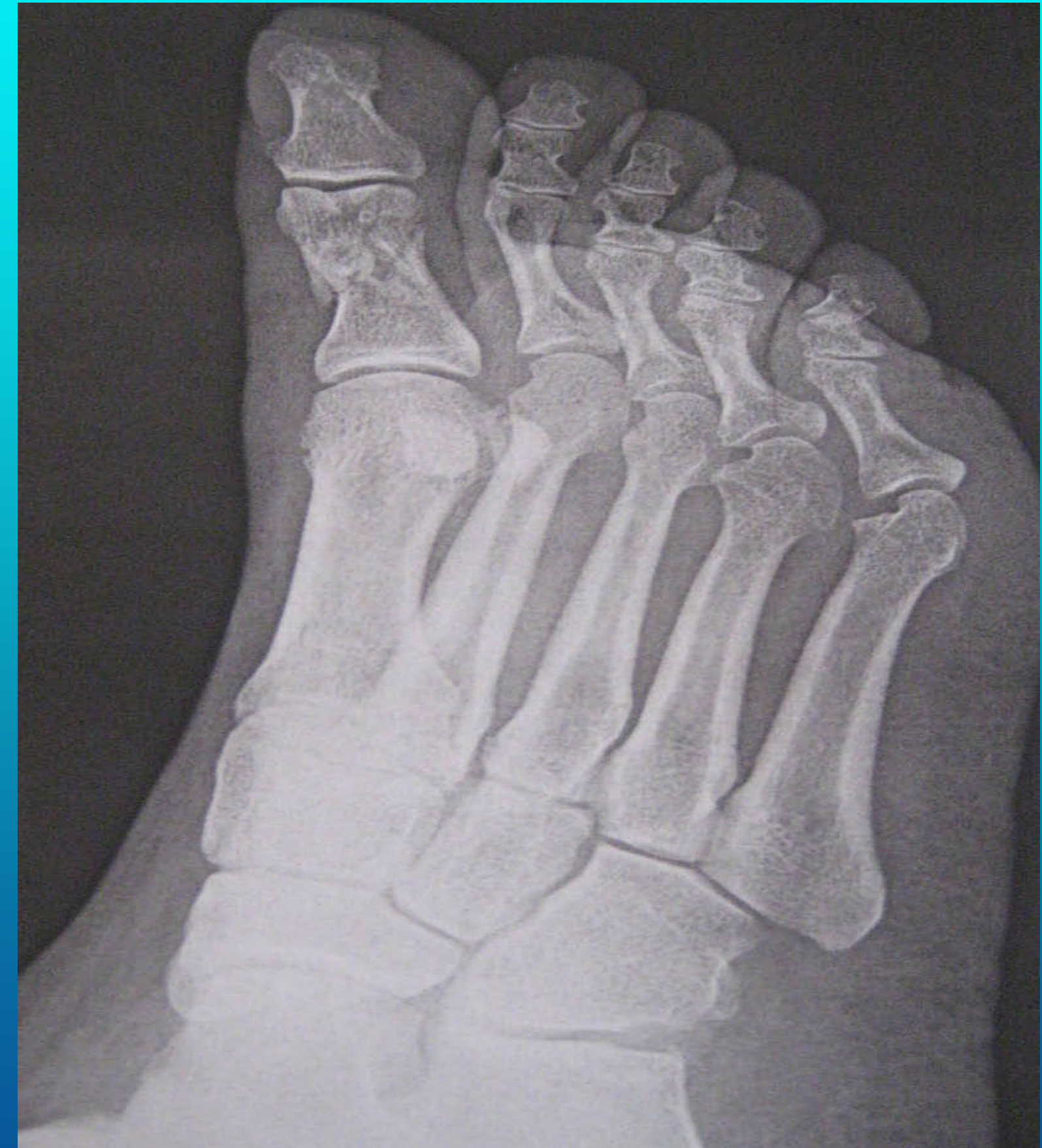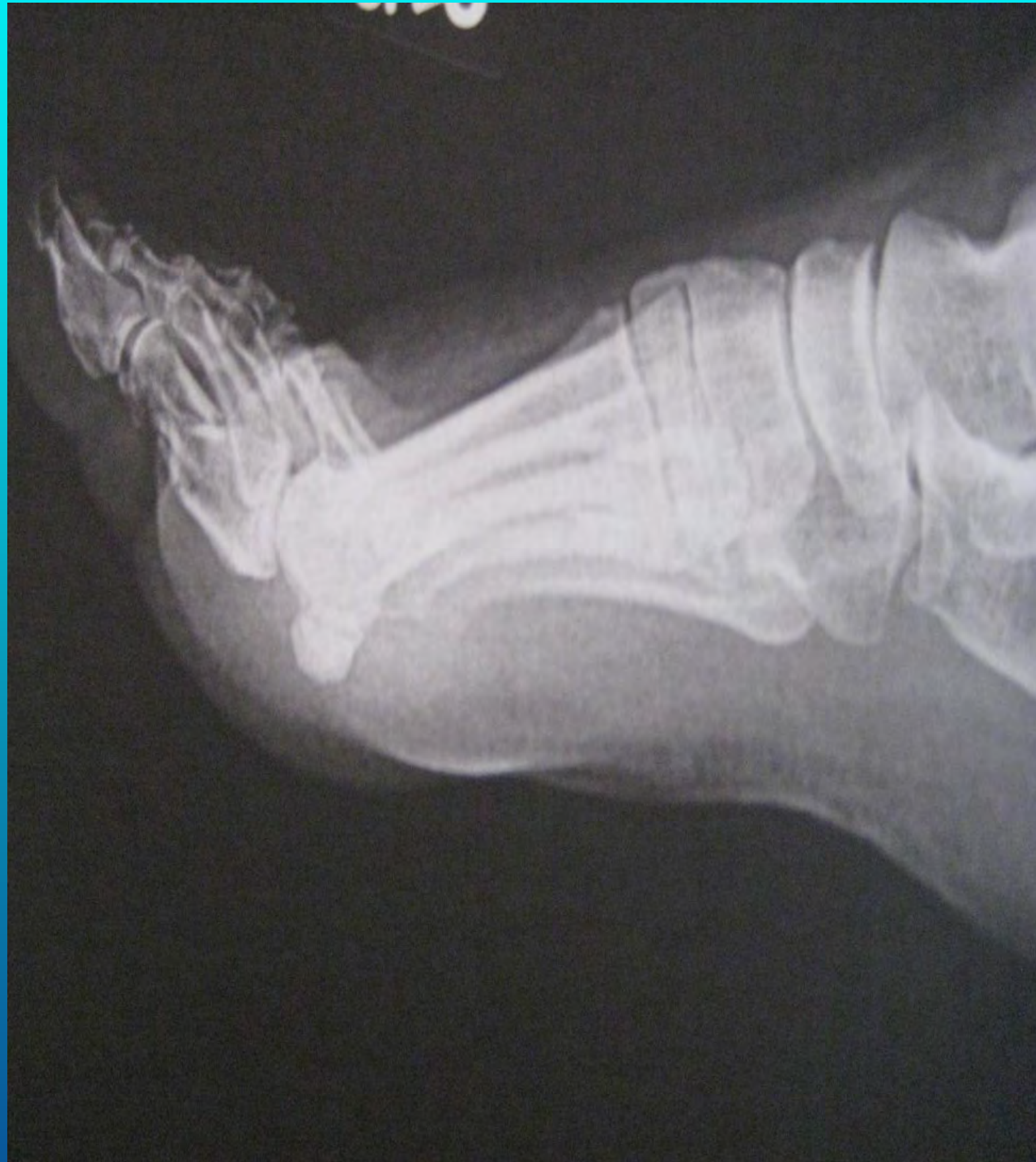Toe Fracture

Radiology

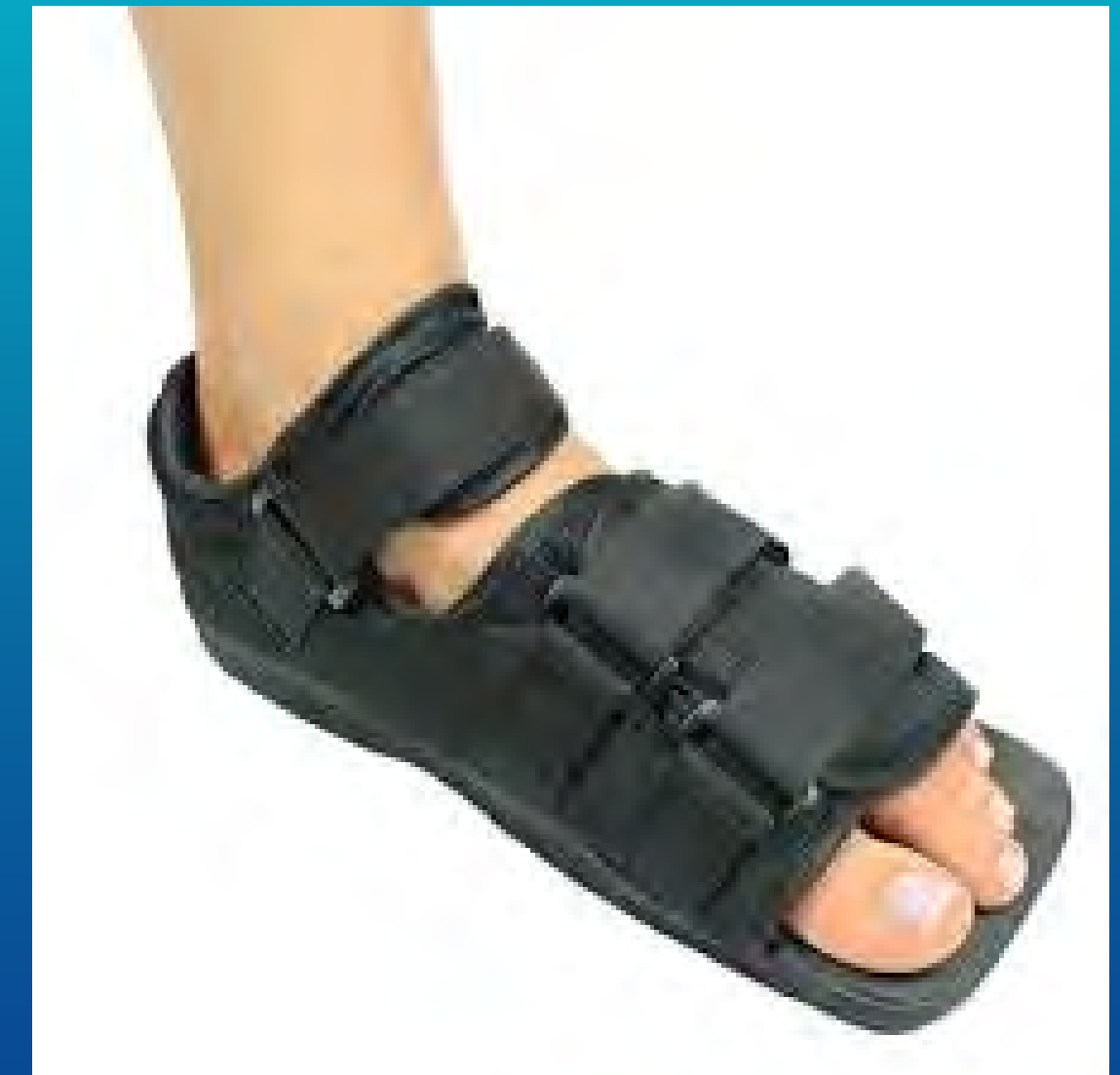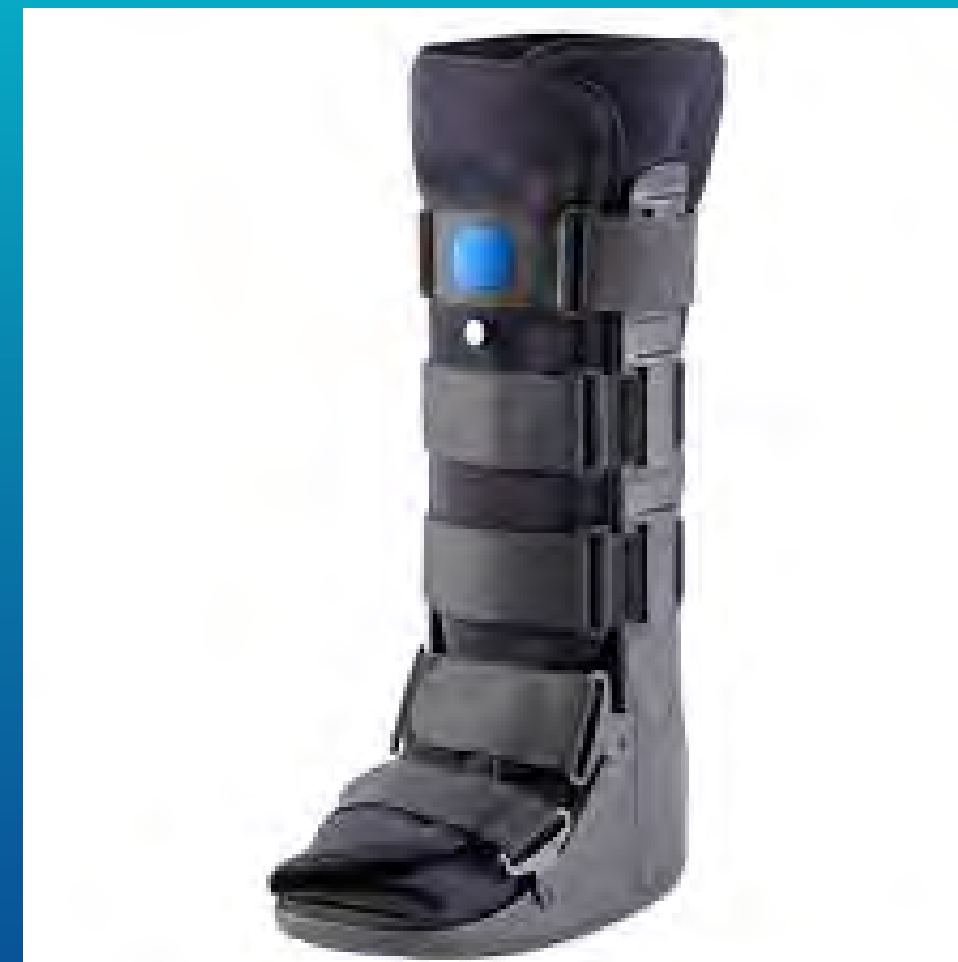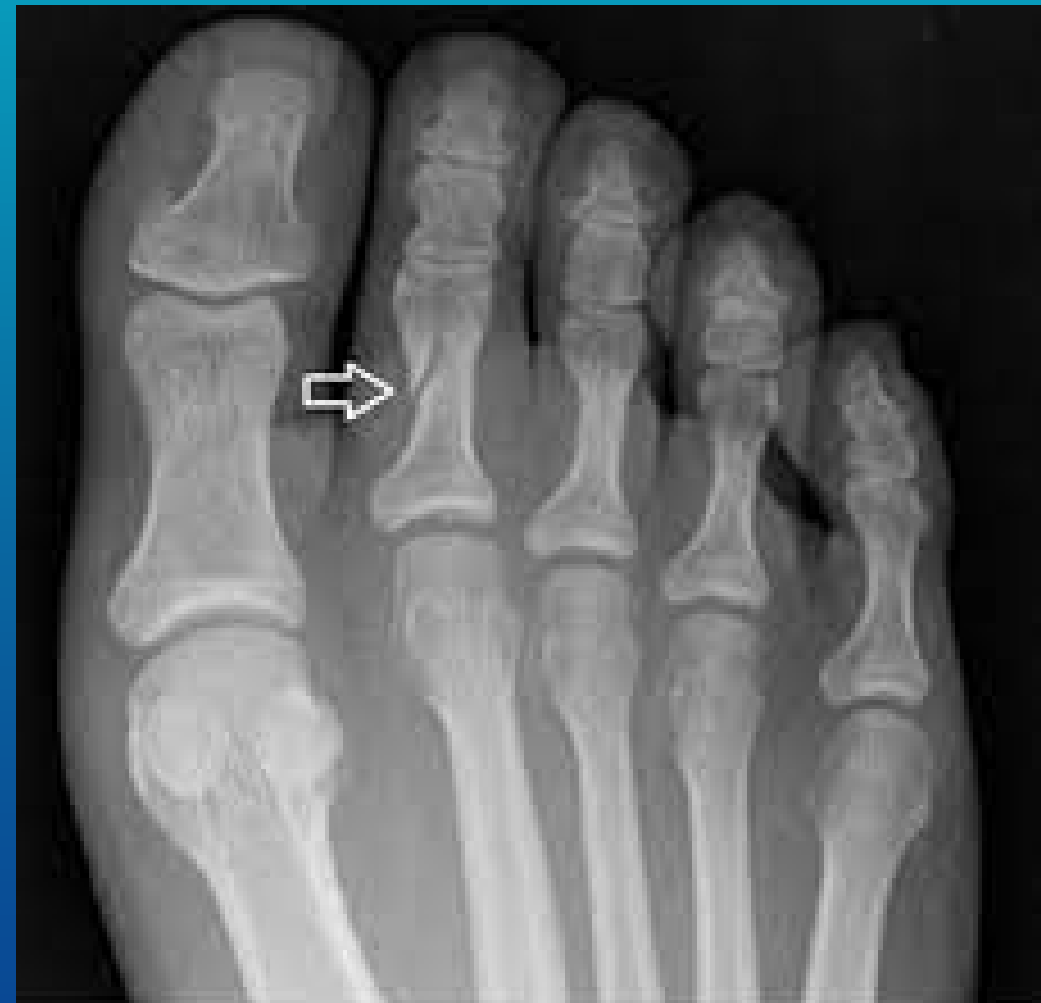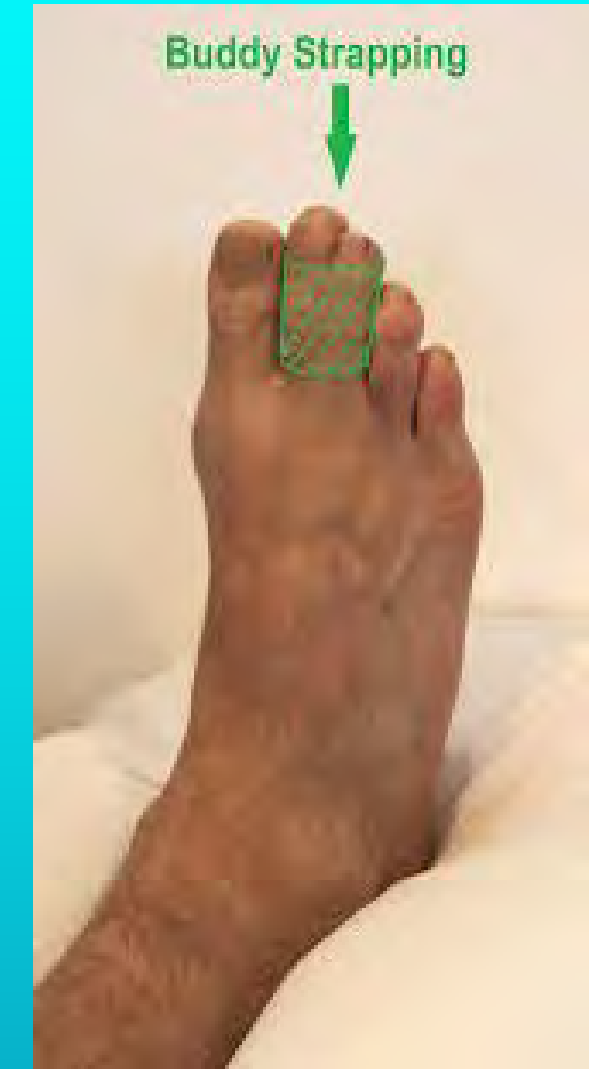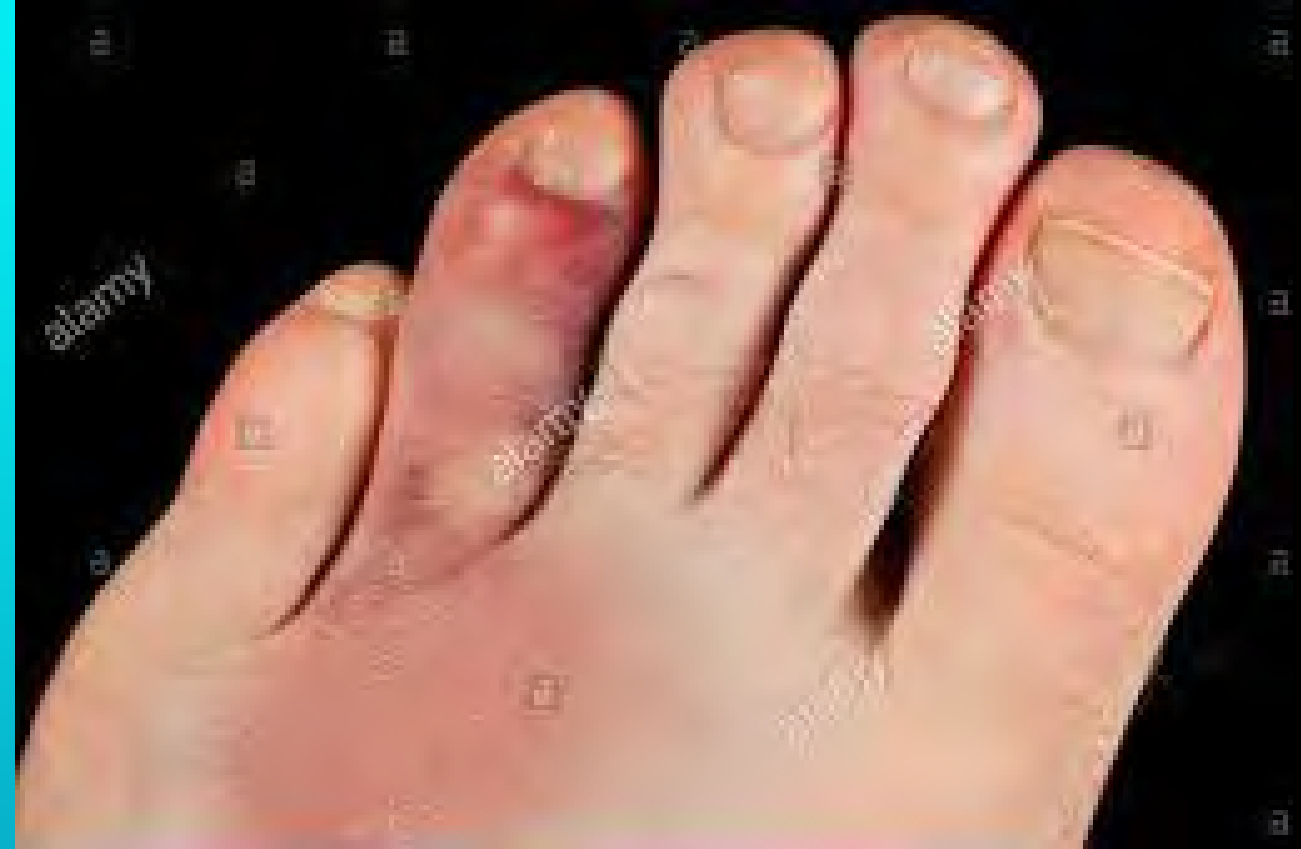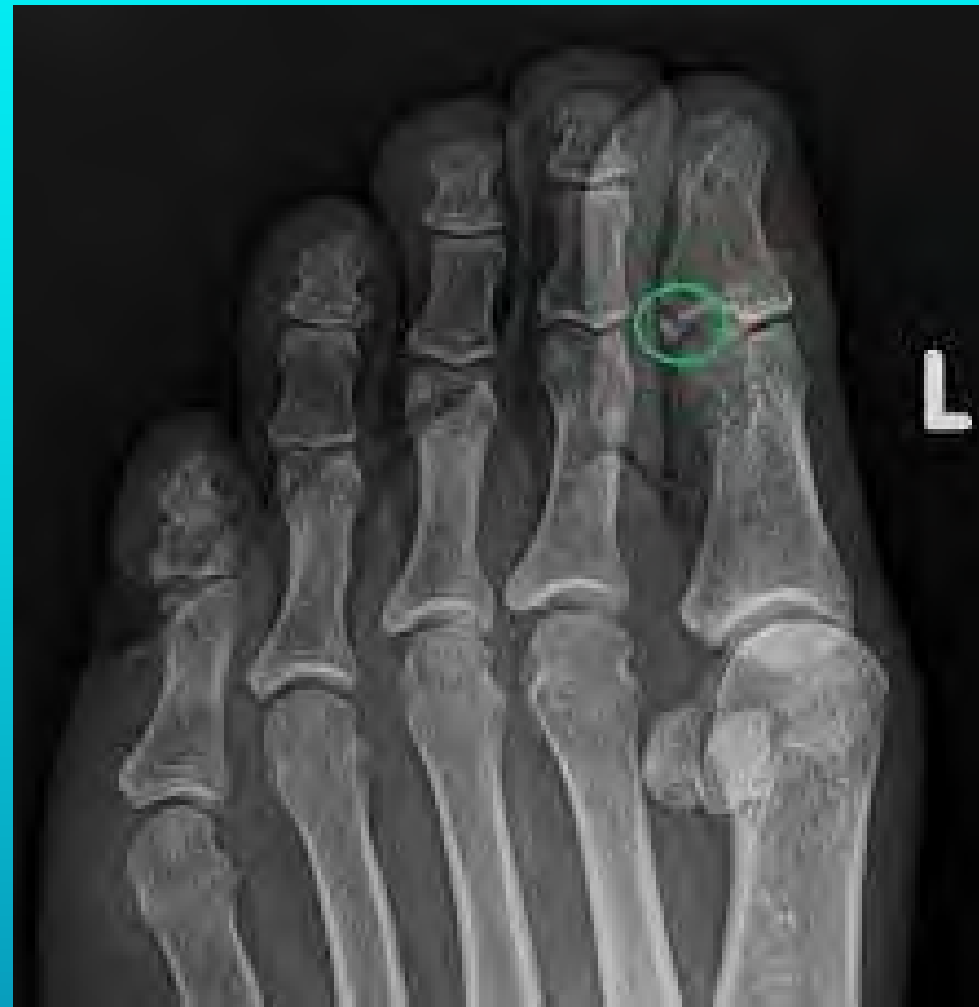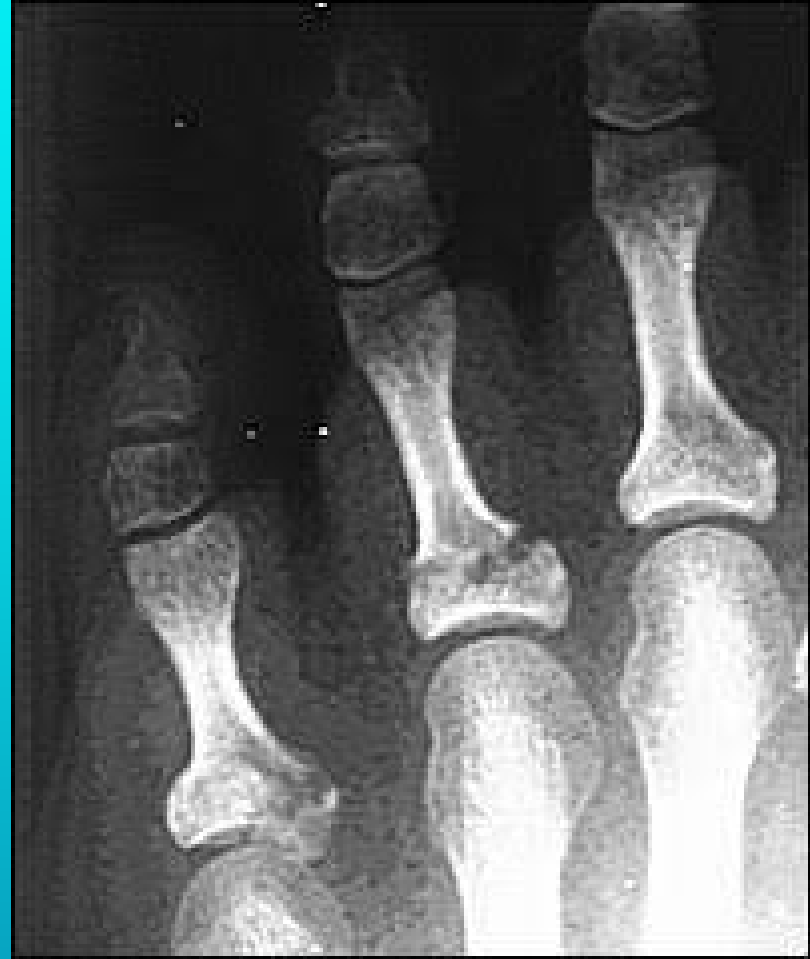- 3 views: AP, Lateral, Oblique
- Clear views of injured toes
 - Spiral & Transverse fx – angular deformity
 - Oblique fx – shortening
 - Avulsion fx
- Post –reduction images as needed
- Treatment
 - Open fx go to the OR/ABX/Tetanus
 - Reduce angulated/deformed toes
 - Digital/hematoma block as needed
 - Buddy Tape
 - Post op Shoe
 - Follow up 1 Week



Fracture Great Toe Proximal Phalanx



Toe Fx



The END

QUESTIONS ?

Thank you!!!!!!

orthopac2@gmail.com

773-630-1378



References

- Uebbing CM, Walsh M, Miller JB, Abraham M, Arnold C. Fracture blisters. West J Emerg Med. 2011;12(1):131–133. <https://www.ncbi.nlm.nih.gov/pmc/articles/PMC3088393>
- Ahn L, Sheth U, Mid-Shaft Clavicle Fractures, Orthobullets.com, 10/28/2020, <https://www.orthobullets.com/trauma/1011/midshaft-clavicle-fractures>, accessed November 17, 2020
- Honeycutt MW, Fisher M, Riehl JT, Orthopaedic Tips: A Comprehensive Review of Midshaft Clavicle Fractures, JBJS JOPA 2019;7(3):e0053
- Andersen et al: Treatment of Clavicle Fractures: Figure 8 vs. Simple Sling. Acta Orthop Scand 1987;58:71-74
- Triplet J, Proximal Humerus Fractures, Orthobullet.com, updated 7/19/2020 <https://www.orthobullets.com/trauma/1015/proximal-humerus-fractures>, accessed November 15, 2020
- Bounds EJ, Frane N, Kok SJ. Humeral Shaft Fractures. [Updated 2020 Aug 24]. In: StatPearls [Internet]. Treasure Island (FL): StatPearls Publishing; 2020 Jan-. Available from: <https://www.ncbi.nlm.nih.gov/books/NBK448074/>
- Ekholm R, Ponzer S, Törnkvist H, Adami J, Tidermark J. The Holstein-Lewis Humeral Shaft Fracture: Aspects of Radial nerve injury, Primary treatment, and Outcome. J Orthop Trauma. 2008 Nov-Dec;22(10):693-7.

References

- Bounds EJ, Frane N, Kok SJ. Humeral Shaft Fractures. [Updated 2020 Aug 24]. In: StatPearls [Internet]. Treasure Island (FL): StatPearls Publishing; 2020 Jan-. Available from: <https://www.ncbi.nlm.nih.gov/books/NBK448074/>
- Liman MNP, Avva U, Ashurst JV, et al. Elbow Trauma. [Updated 2019 Jun 23]. In: StatPearls [Internet]. Treasure Island (FL): StatPearls Publishing; 2020 Jan-. Available from: <https://www.ncbi.nlm.nih.gov/books/NBK542228/>
- Sullivan CW, Hayat Z. Olecranon Fracture. [Updated 2020 Jan 17]. In: StatPearls [Internet]. Treasure Island (FL): StatPearls Publishing; 2020 Jan-. Available from: <https://www.ncbi.nlm.nih.gov/books/NBK537295/>
- Layson J, Best BJ. Elbow Dislocation. [Updated 2019 Nov 11]. In: StatPearls [Internet]. Treasure Island (FL): StatPearls Publishing; 2020 Jan-. Available from: <https://www.ncbi.nlm.nih.gov/books/NBK549817/>
- Schulte, LM, Meals CG, Neviasser RJ, Management of Adult Diaphyseal Both-bone Forearm Fractures, J AM Acad Orthop, Surg 2014;22:437-446
- Allen, D, Galeazzi Fracture, OrthoBullets, updated 1/19/20109, <https://www.orthobullets.com/trauma/1029/galeazzi-fractures>, retrieved April 10, 2020

References

- Johnson NP, Silberman M. Monteggia Fractures. [Updated 2019 Jul 30]. In: StatPearls [Internet]. Treasure Island (FL): StatPearls Publishing; 2020 Jan-. Available from: <https://www.ncbi.nlm.nih.gov/books/NBK470575/>
- Meaike JJ, Kakar S, management of Comminuted Distal Radius Fractures: A Critical Review, JBJS Reviews 2020;8(8)e20.00010
- Porrino JA, Maloney E, Scherer K, et al [Fracture of the Distal Radius: Epidemiology and Premanagement Radiographic Characterization](#), American Journal of Roentgenology 2014 203:3, 551-559
- Corsino CB, Reeves RA, Sieg RN, Distal Radius Fractures, StatPearls, Treasure Island, FL, StatPearls Publishing Jan 2020
- Miller D, Sarwark J. (2019, April 1). Visual Guide to Splinting [NUEM Blog. Expert Commentary by Pirotte M]. Retrieved from <http://www.nuemblog.com/blog/splinting>
- Buijze G, Goslings JC, Rhemrev JS, et al. Cast immobilization with and without immobilization of the thumb for non-displaced scaphoid waist fractures: a multicenter, randomized, controlled trial. J Hand Surg Am. 2014;39:621

References

- Wieschhoff GG, Sheehan SE, Wortman JR, et al, Traumatic Finger Injuries: What the Orthopaedic Surgeon Wants to Know, *RNSA* 2016;36(4):1106-1128
- Bloom J, Overview of Metacarpal Fractures, UpToDate, updated May 10, 2021, <https://www.uptodate.com/contents/overview-of-metacarpal-fractures#H48141897> retrieved Feb 21, 2021
- Guo J, Dong W, Jin L, et al. Treatment of basicervical femoral neck fractures with proximal femoral nail antirotation. *J Int Med Res*. 2019;47(9):4333-4343. doi:10.1177/0300060519862957
- Yoo JI, Cha Y, Kwak J, Kim HY, Choy WS. Review on Basicervical Femoral Neck Fracture: Definition, Treatments, and Failures. *Hip Pelvis*. 2020;32(4):170-181. doi:10.5371/hp.2020.32.4.170
- Black DM, Geiger EJ, Eastelli R, et al, Atypical Femur Fracture Risk versus Fragility Fracture Prevention with Bisphosphonates, *N Engl J Med* 2020; 383:743-753
DOI: 10.1056/NEJMoa191652, retrieved on May 2, 2021 www.nejm.org/doi/full/10.1056/NEJMoa1916525

REferences

- Ahn L, Patella Fracture, Orthobullets, updated 5/25/2021 <https://www.orthobullets.com/trauma/1042/patella-fracture>, retrieved 6/2/2021
- van Leeuwen, C., Haak, T., Kop, M. *et al.* The additional value of gravity stress radiographs in predicting deep deltoid ligament integrity in supination external rotation ankle fractures. *Eur J Trauma Emerg Surg* **45**, 727–735 (2019).
- Ehrlichman LK, Gonzalez TA, Macaulay AA, Ghorbanhoseini M, Kwon JY. Gravity Reduction View: A Radiographic Technique for the Evaluation and Management of Weber B Fibula Fractures. *Arch Bone Jt Surg*. 2017;5(2):89-95.
- Karadsheh M, Taylor BC, Forsthoefel C, Femoral Shaft Fractures, OrthoBullets, updated May 27, 2021, <https://www.orthobullets.com/trauma/1040/femoral-shaft-fractures>, retrieved June 2, 2021
- Blomberg J, Femoral Neck Fractures, OrthoBullets, updated June 1, 2021, <https://www.orthobullets.com/trauma/1037/femoral-neck-fractures>, retrieved June 4, 2021

References

- Kojima KE, Ferreira RV. TIBIAL SHAFT FRACTURES. *Rev Bras Ortop*. 2015;46(2):130-135. Published 2015 Dec 6. doi:10.1016/S2255-4971(15)30227-5
- Torlincasi AM, Lopez RA, Waseem M. Acute Compartment Syndrome. [Updated 2021 Feb 10]. In: StatPearls [Internet]. Treasure Island (FL): StatPearls Publishing; 2021 Jan-. Available from: <https://www.ncbi.nlm.nih.gov/books/NBK448124/>
- Macey, Lance R. MD; Benirschke, Stephen K. MD; Sangeorzan, Bruce J. MD; Hansen, Sigvard T. Jr MD Acute Calcaneal Fractures: Treatment Options and Results, *Journal of the American Academy of Orthopaedic Surgeons*: 1994;2 (1);36-43
- Whitaker C, Turvey B, Illical EM. Current Concepts in Talar Neck Fracture Management. *Curr Rev Musculoskelet Med*. 2018;11(3):456-474. doi:10.1007/s12178-018-9509-9
- Lee C, Brodke D, Perdue PW Jr, Patel T. Talus Fractures: Evaluation and Treatment. *J Am Acad Orthop Surg*. 2020 Oct 15;28(20):e878-e887. doi: 10.5435/JAAOS-D-20-00116. PMID: 33030854.
- Moracia-Ochagavía I, Rodríguez-Merchán EC. Lisfranc fracture-dislocations: current management. *EFORT Open Rev*. 2019;4(7):430-444. Published 2019 Jul 2. doi:10.1302/2058-5241.4.180076

References,

- Smidt KP, Massey P. 5th Metatarsal Fracture. [Updated 2021 Apr 12]. In: StatPearls [Internet]. Treasure Island (FL): StatPearls Publishing; 2021, <https://www.ncbi.nlm.nih.gov/books/NBK544369/>
- Sarpong NO, Swindell HW, Trupia EP, Vosseller JT, Metatarsal Fractures, Foot and Ankle Orthopaedics, AOFAS, 2018:1-8
- Gravlee JR, Hatch RL, Toe Fractures in Adults, UpToDate 2020; <https://www.uptodate.com/contents/toe-fractures-in-adults>, Retrieved 6/2/2021