

The Use of Clozaril and Electroconvulsive Therapy to Treat Olanzapine Resistant Rabbit Syndrome

Introduction

- Rabbit syndrome is an antipsychotic induced extrapyramidal syndrome characterized by perioral tremors
- The pathophysiology is debated. The most accepted theory is that a hypercholinergic state arises due to the dopamine blockade, leading to the development of rabbit syndrome¹
- Affects only 2.3% individuals on antipsychotics²
- Most commonly caused by typical antipsychotics such as haloperidol due to the high incidence of extrapyramidal symptoms³
- Increasing use of atypical antipsychotics is leading to an increasing incidence of atypical antipsychotic induced rabbit syndrome. The most common causative atypical antipsychotic is risperidone.³
- Clinical manifestations include rapid, repetitive, rhythmic movements of the mouth, not including the tongue
- Usually presents during the use or following discontinuation of chronic treatment with antipsychotic medications

Image 1: Clinical Manifestations⁴

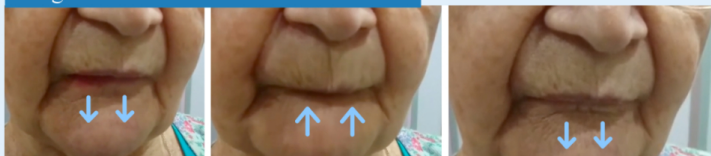


Figure 1: Differential Diagnosis

- Tardive dyskinesia
- Sydenham's chorea
- Multiple Sclerosis
- Parkinson's Disease
- Huntington's Disease

Case Description

History

- 49 year old Caucasian male
- Chief complaint: "A demon/[former staff member] is controlling my mouth and speech"
- Presents to a psychiatric hospital after failing psychiatric treatment at another inpatient facility
- Reports worsening symptoms despite treatment with olanzapine 15 mg IM
- Delusions and hallucinations- hyper fixated on "black magic," believes he is god, he can hear others through "air waves," that demons and former staff members control his mouth, forcing him to say things
- Denies loss of sleep, feelings of agitation or aggression, no thoughts of self harm or harm to others
- Past psychiatric history- schizophrenia and pervasive personality disorder, including multiple intermittent psychiatric hospitalizations at various facilities since age 29
- Past medical history- schizophrenia, pervasive personality disorder, immune thrombocytopenia, gastroesophageal reflux disease
- Medications- olanzapine 15 mg IM twice daily, pantoprazole 40 mg daily
- Granted medications against will by probate court judge
- Reports past use of PCP
- Denies alcohol and tobacco use
- History of legal charges regarding stalking women on college campuses and assaulting a police officer upon arrest

Physical Exam

- General- No acute distress, appropriate dress, flat affect, appears disheveled, hair unkempt
- Musculoskeletal- abnormal but constant motor activity, fidgeting, rapid vertical movements of the mouth even when not speaking; no atrophy, erythema, edema, non tender to palpation in bilateral upper and lower extremities
- Neurologic/Psychiatric
 - Speech and language- adequate volume of speech, fast rate, abnormal cadence
 - Mood and behavior- feels "okay"; pleasant attitude
 - Thought content- somatic preoccupation, persecutory; believes the physician is trying to kill him, believes a staff member from his previous facility is Satan and is controlling his mouth
 - Thought process- comprehensible, pressured, tangential
 - Insight and judgment- Poor; disagrees with schizophrenia diagnosis and believes he is hospitalized for urinary incontinence; acknowledges auditory hallucinations
 - Memory- immediate and 5 minute delayed recall intact; recent memory intact
 - Attention- appropriate attention and concentration
 - Fund of knowledge- appropriate; knowledge of current and recent past events intact
 - Calculating ability- intact
 - Abstract thinking- intact

Outcome

- Added benztropine to regimen to treat extrapyramidal symptoms/rabbit syndrome with no success
- Added cariprazine 3 mg twice daily to augment antipsychotic effects of olanzapine with no success
- Olanzapine, cariprazine, and benztropine discontinued
- First initiated clozaril 500 mg
 - 3 months after initiation → no longer complaining of others taking control of his mouth, no signs and symptoms of rabbit syndrome
 - 6 months after initiation → significant decrease in all positive symptoms (delusions, hallucinations)
- Next, initiated electroconvulsive therapy (about 12-14 sessions)
 - 2 weeks after initiation → significant decrease in all positive symptoms, conversations with staff and family became reality based and goal oriented

Discussion

- Very little is known about rabbit syndrome- its causative agents and recommended treatment agents are still being debated.
- There is currently no standard of care besides a change in antipsychotic treatment regimen
- Some cases have been successfully treated with ...
 - Anticholinergics such as benztropine or procyclidine, but symptoms can return when anticholinergics are stopped, requiring the addition of another medication to an already burdensome treatment regimen³
 - Simply discontinuing the causative drug, although this is not a feasible option for many patients⁵
 - The substitution of the causative antipsychotic with another antipsychotic that has stronger anticholinergic properties such as olanzapine or quetiapine⁵
- More neuropsychiatric and pharmacological research on the basal ganglia will likely reveal the true treatment of rabbit syndrome⁶

Conclusions

- Although extrapyramidal symptoms are more commonly associated with typical antipsychotics, atypical antipsychotics may also cause them. Thus, clinicians prescribing any antipsychotics must monitor their patients for the development of all extrapyramidal symptoms, including rabbit syndrome.
- Early recognition and treatment of rabbit syndrome can decrease stressors on the patient.

References

1. Nataraj J, Jabbar R. Antipsychotic-induced Rabbit Syndrome in a pediatric patient. *CJHP*. 2015;68(6). doi:10.4212/cjhp.v68i6.1506
2. Yassa R, Lal S. Prevalence of the Rabbit Syndrome. *Am. J. Psychiatry*. 1986;143(5):656-657. doi:10.1176/ajp.143.5.656
3. Catena Dell'Osso M, Fagioli A, Ducci F, Masalehdan A, Ciapparelli A, Frank E. Newer antipsychotics and the Rabbit Syndrome. *Clin. Pract. Epidemiology Ment. Health*. 2007;3(1):6. doi:10.1186/1745-0179-3-6
4. Dos Santos Souza F, Furlan Chavez M, Dos Santos Moraes Nunes N, et al. Risperidone-induced Rabbit Syndrome: video clinical report. *Annals of Clinical Case Studies*. 2021;3(1037).
5. Gundogmus I, Tekin S, Tasdelen Kul A, Uzun O, Ozmenler KN. Amisulpride-induced late-onset Rabbit Syndrome: Case report and literature review. *European Psychiatry*. 2022;65(S1). doi:10.1192/j.eurpsy.2022.1835
6. Hocaoglu C. Clozapine-induced Rabbit Syndrome: A case report. *Mental Illness*. 2009;1(1):1-3. doi:10.4081/mi.2009.e1

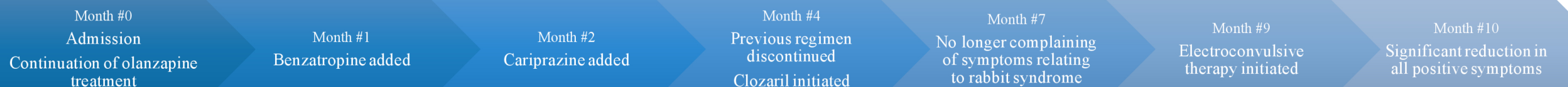

Figure 1: Hospital Course