



Atraumatic Hip Pain in the Pediatric Patient

Sarah Bolander, DMSc, PA-C, DFAA
Midwestern University
Cactus Pediatric Orthopaedics

Learning Objectives

- Recognize the critical components of a focused history and physical for hip pain in a pediatric patient
 - Identify red flags in a child with a limp or hip pain
 - Identify and interpret applicable diagnostics for specified hip conditions discussed
 - Determine the urgency and plan for management with the most common pediatric conditions associated with hip pain
-

Pediatric Limp

History

- History of trauma? Timing important
- Pain description and location
- Age of onset and duration
- Birth history
- Fever, systemic, or constitutional sx
 - Current or recent
- Additional musculoskeletal history or associated symptoms



Trauma is the most common cause

Pediatric Limp

Hip Pain:

Presents in the groin but often refers to thigh or knee in pediatric patients

Physical Exam

- Observation with gait evaluation
- Inspection
- Limb length discrepancy
- Tenderness with palpation
- Range of motion
- Neurovascular exam
- Specialized tests
- Abdominal, genitalia, or spine exam may be indicated

GLAP

G: Gait

L: Location

A: Age

P: Pain

DDX

TRAUMA

Congenital

- Hip Dysplasia

Infectious

- Septic Arthritis
- Osteomyelitis
- Psoas Abscess

Inflammatory

- Transient Synovitis
- Rheumatologic
- Traction apophysitis

Musculoskeletal

- Legg-Calve-Perthes
- SCFE
- Stress Fx
- Osteochondrosis

Other

- Intra-abdominal or genitourinary
 - Sickle cell
 - Malignancy
 - Muscular dystrophy
 - Limb length discrepancy
-

Hip pain in children

< 4 years old

- Transient synovitis
- Osteomyelitis/septic arthritis
- Juvenile idiopathic arthritis
- Non-accidental injury
- Referred pain from limb

- *uncommon:*
 - *Leukemia*
 - *Eosinophilic granuloma*
 - *Metastases neuroblastoma*

4 - 10 years

- Transient synovitis
- Perthes disease
- Osteomyelitis /
septic arthritis

- *uncommon:*
 - *Leukemia*
 - *Ewing*

10 - 16 years

- Slipped femoral epiphysis
- Avulsion fractures
- Osteomyelitis /
septic arthritis

- *uncommon:*
 - *Leukemia*
 - *Osteoid osteoma*
 - *Ewing*
 - *Osteosarcoma*

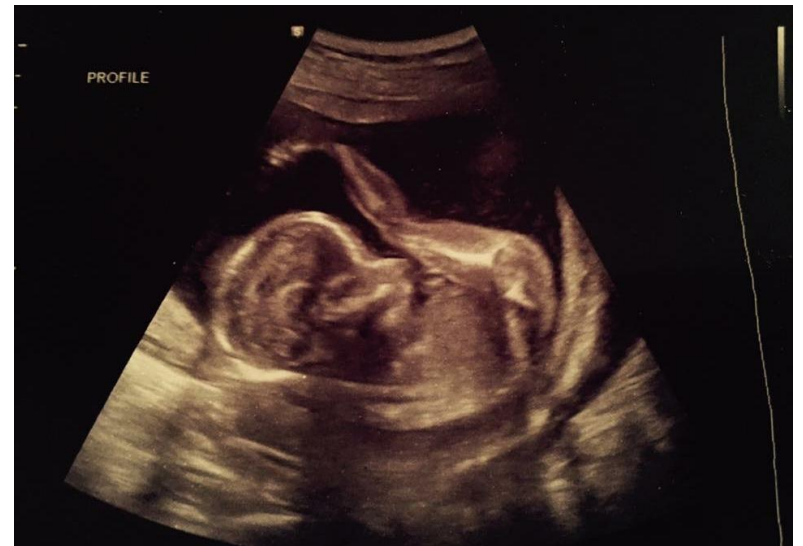Developmental Dysplasia of the Hip



DDH

Most common orthopaedic disorder in newborns

Pathophysiology: maternal/fetal laxity, genetic laxity, and intrauterine malpositioning



DDH



[International Hip Dysplasia Institute](#)

Epidemiology:

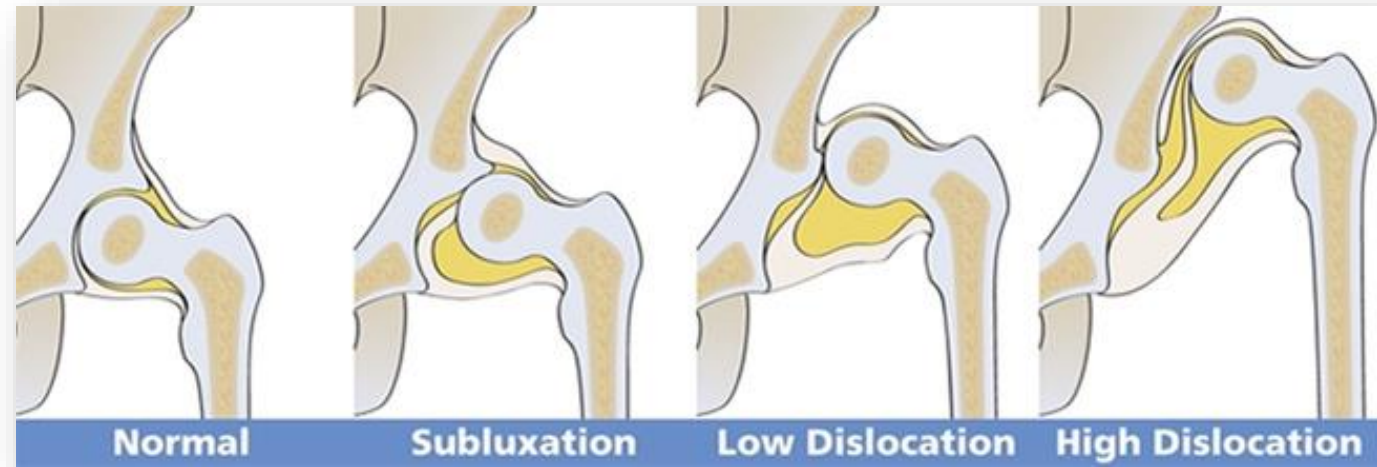
- Left hip most commonly affected (bilateral >20%)
- Risk factors are key:
 - Female > male 8:1
 - 1st born, breech position and family history
 - Swaddling is also strongly associated

* CP/Neuromuscular disorders

DDH

Disease spectrum:

- Dysplasia
- Subluxation
- Dislocation



[International Hip Dysplasia Institute](#)

Associated conditions:

- Congenital muscular torticollis
- Metatarsus adductus

DDH: Physical Exam

Galeazzi:

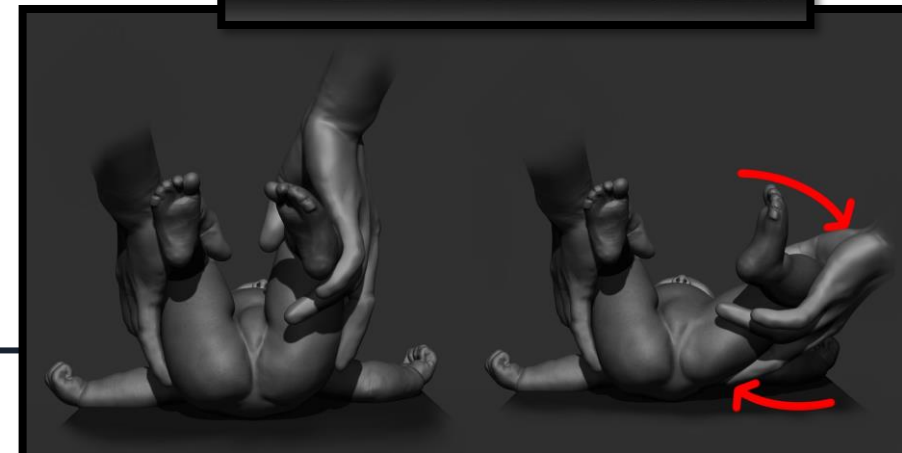
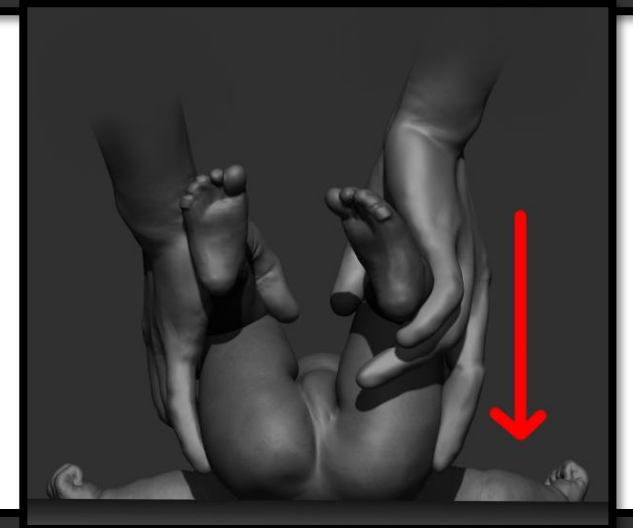
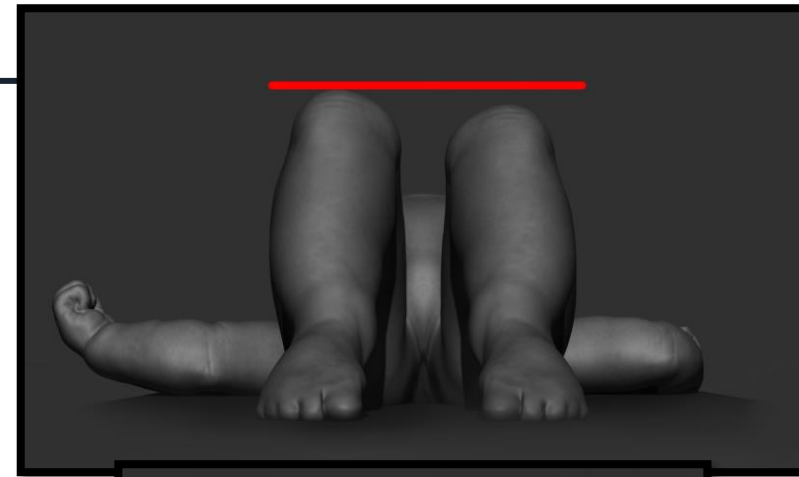
- Apparent limb length discrepancy while supine and knees flexed at 90 degrees
- May be consistent with unilateral dislocated hip

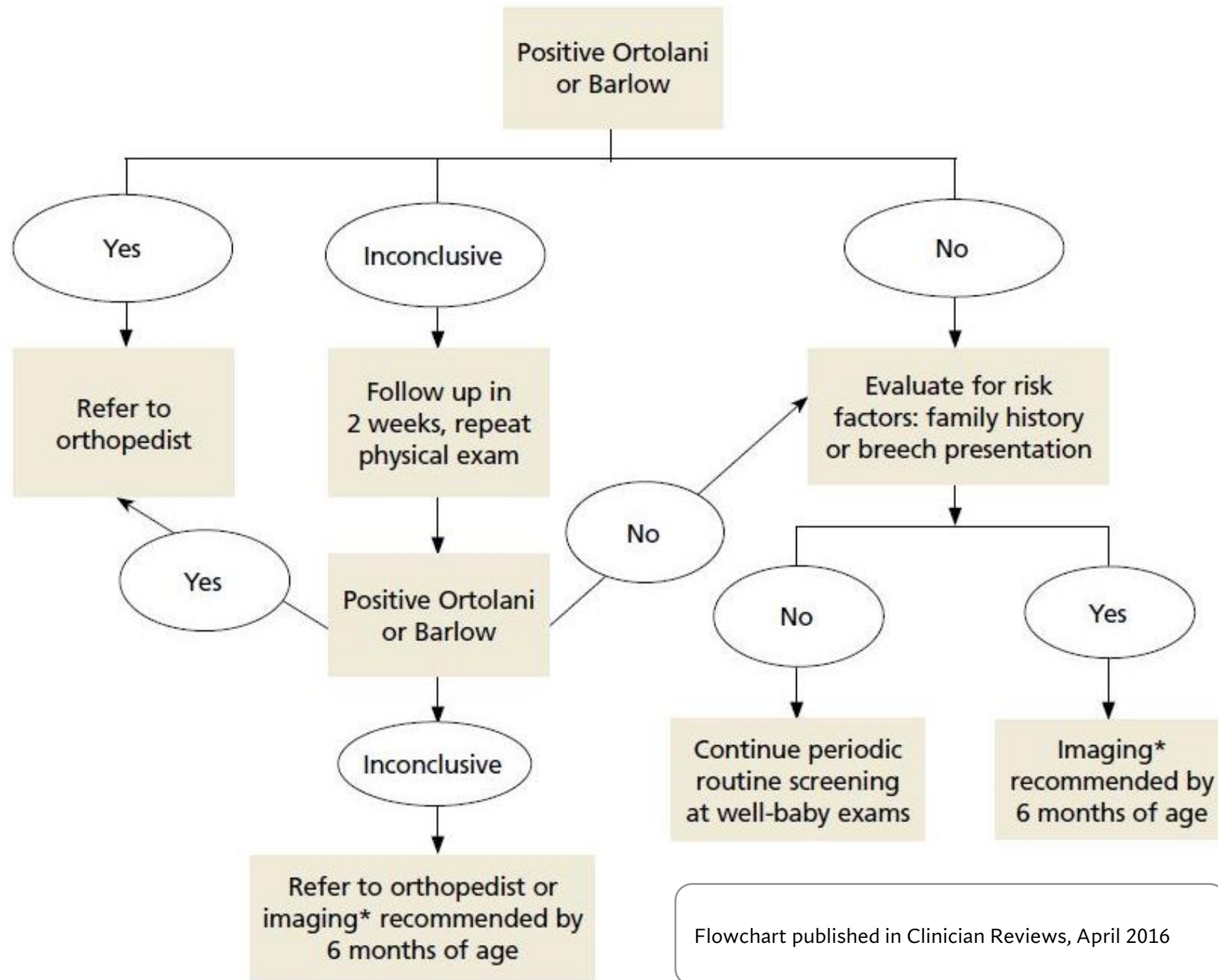
Barlow:

- Provocative maneuver
- Flexion, adduction, and provide posterior pressure to the joint

Ortolani:

- Reductive maneuver
- Flexion, abduction, and place posterior pressure to lift the greater trochanter





DDH: Imaging

Ultrasound is diagnostic test of choice for infants

- Requires dynamic stress testing by skilled provider
- Recommended **after 3-4 weeks**
- Utilized to confirm suspected diagnosis or with significant risk factors
- Universal ultrasound screening is not recommended

DDH: Radiographs

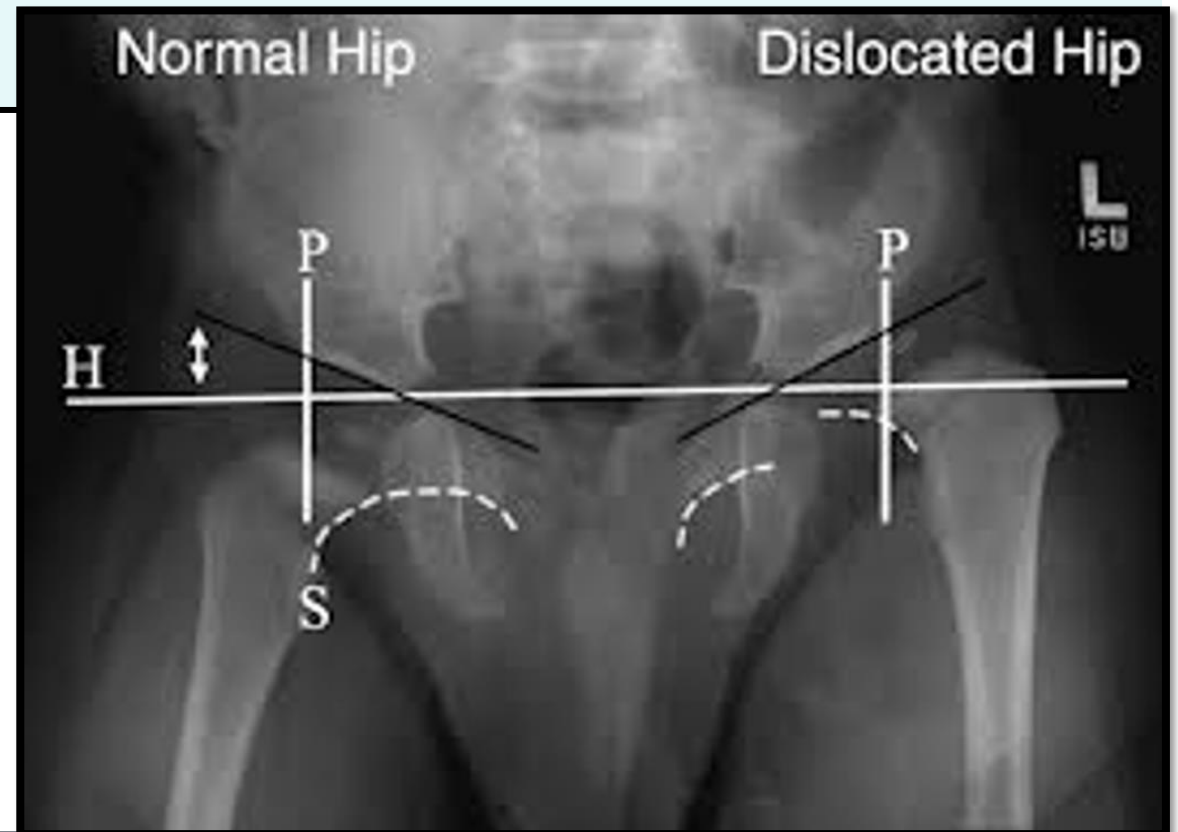
> 4-6 months

P: Perkin line

H: Hilgenreiner line

S: Shenton line

Acetabular angle: angle from acetabular roof to Hilgenreiner line



DDH: Management

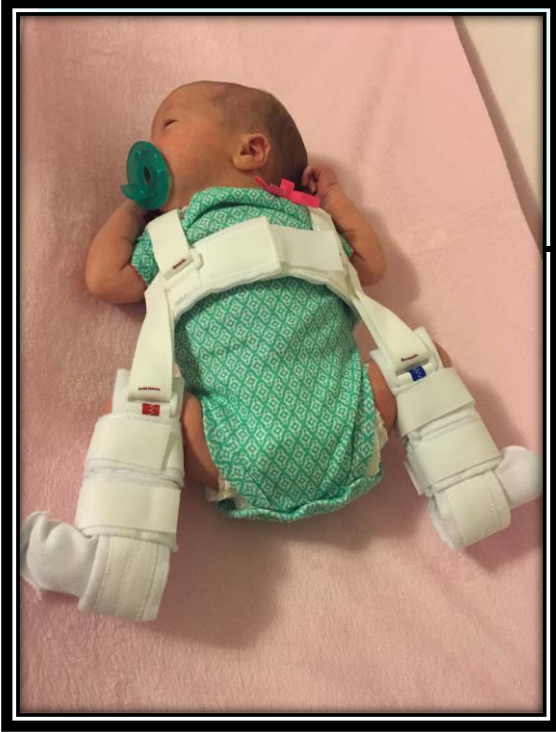
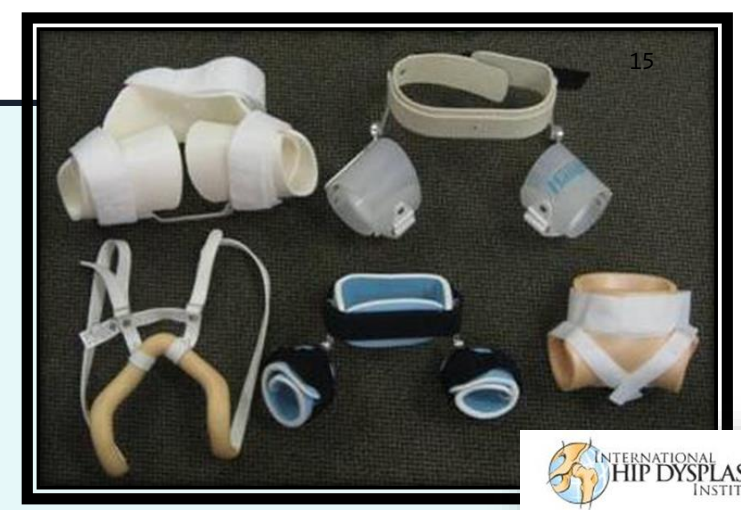
Photo Courtesy of Trent Tipton, PA-C



- Clinical suspicion is adequate to initiate treatment
- Mainstay initial treatment is Pavlik harness for the majority of pts
- Treatment in harness should be implemented before 6 weeks of age
- Surgery indications > 18 months
- Syndromic or neuromuscular disorders may have more advanced dysplasia that will not respond to harness.



DDH: Parent Education

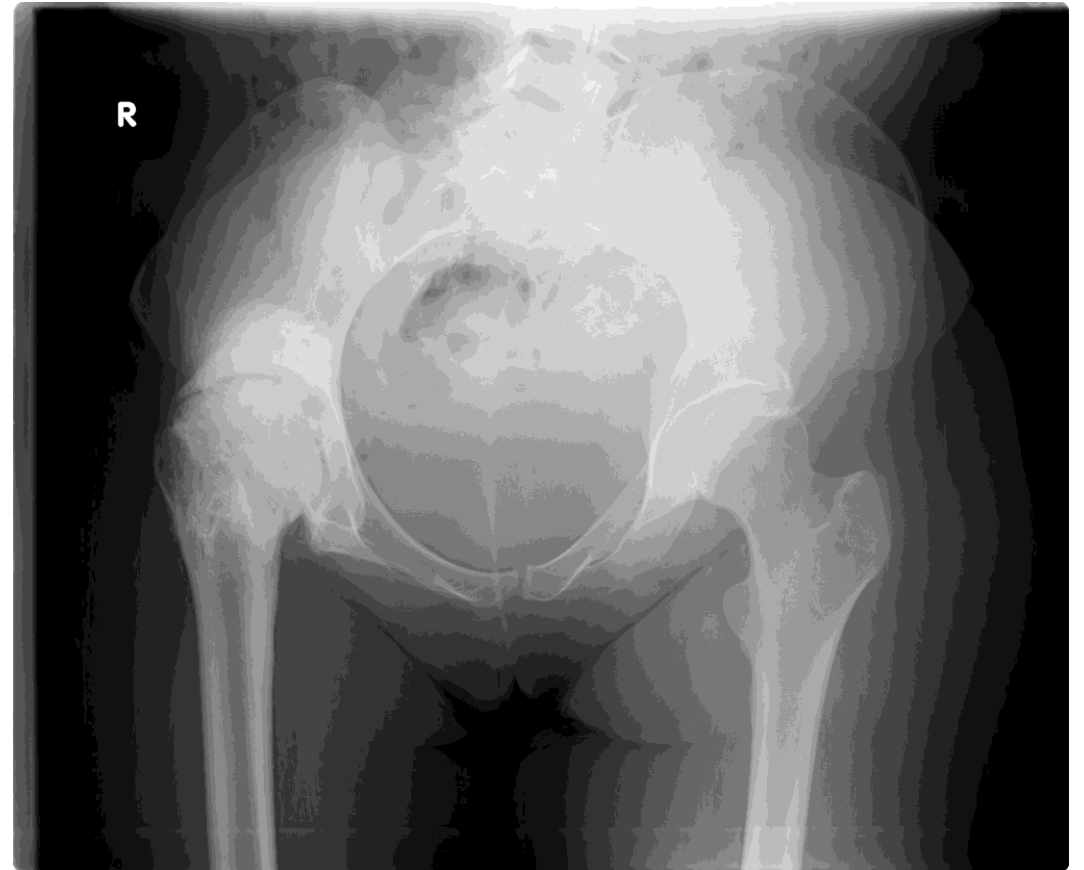
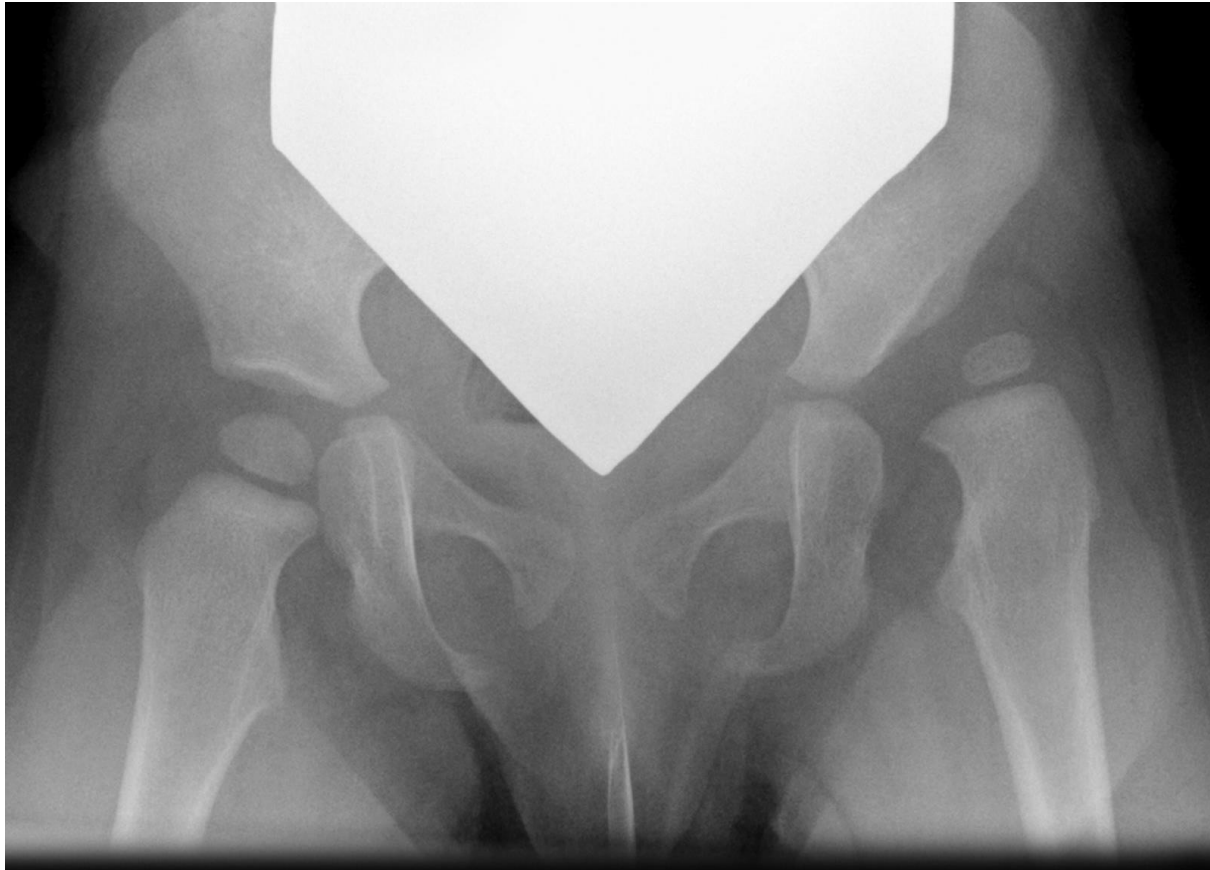
Patient compliance is essential

- Frequent appointments with pediatric orthopaedics to assure harness fit and evaluate femoral nerve function

No need to remove harness for well child checks and perform specialized tests once DDH is diagnosed

Parents will be asked to avoid tight fitting clothes and provided recommendations for safe swaddling and hip healthy products

Untreated DDH



Legg-Calve-Perthes Disease



Legg-Calve-Perthes Disease

Juvenile idiopathic osteonecrosis of the femoral head

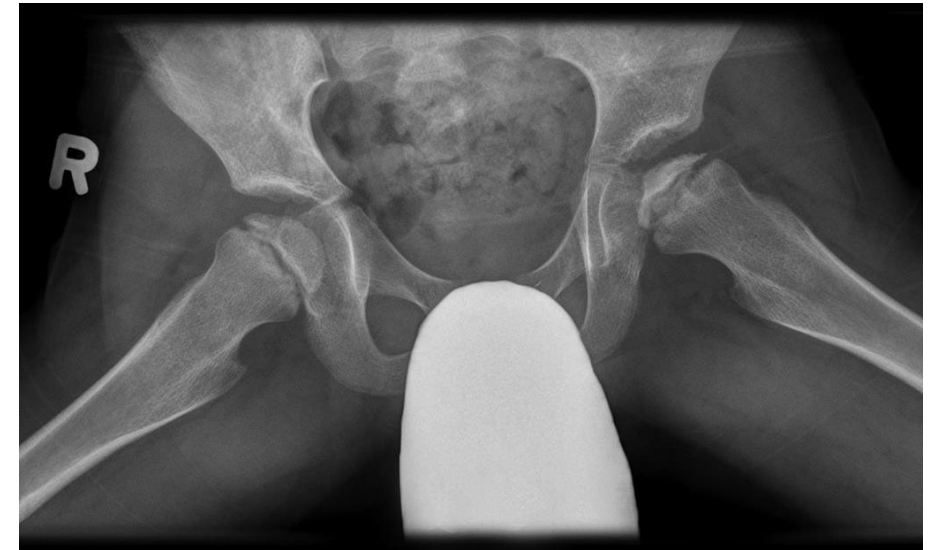
Peak incidence 4-8 years of age, M>F 5:1

Bilateral in 10-20%

Risk Factors:

- Family History
- Maternal smoking/secondhand smoke

Associated with hyperactivity (ADHD)



Case courtesy of A.Prof Frank Gaillard, Radiopaedia.org, rID: 7983

Perthes: Clinical Presentation

Painless limp or insidious onset of pain: hip, groin, thigh, or knee

- Limp or pain is often activity related and worsens by the end of the day
- Pain relieved with rest

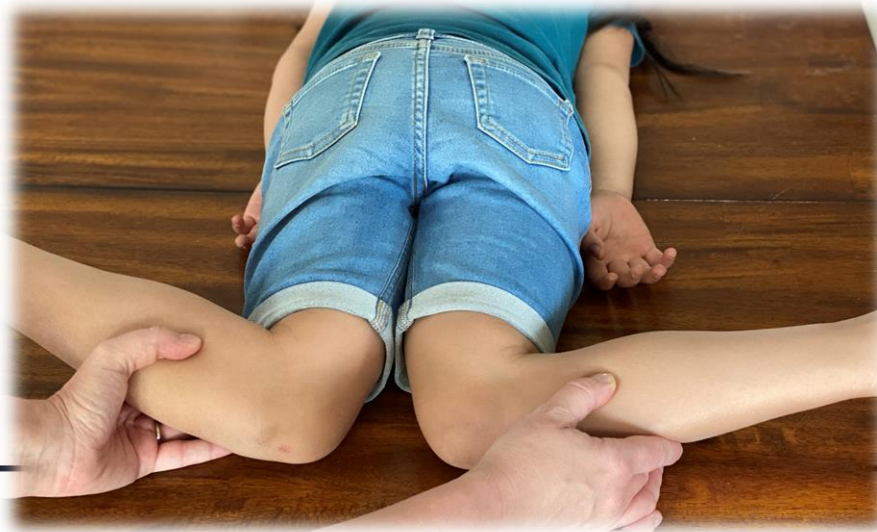Muscle spasticity may be present

May have history of minor trauma

Perthes: Physical Exam

- Gait disturbance: Antalgic limp / Trendelenburg gait
- Limited internal rotation or abduction of hip
- Limb length discrepancy presents later in the course of the disease

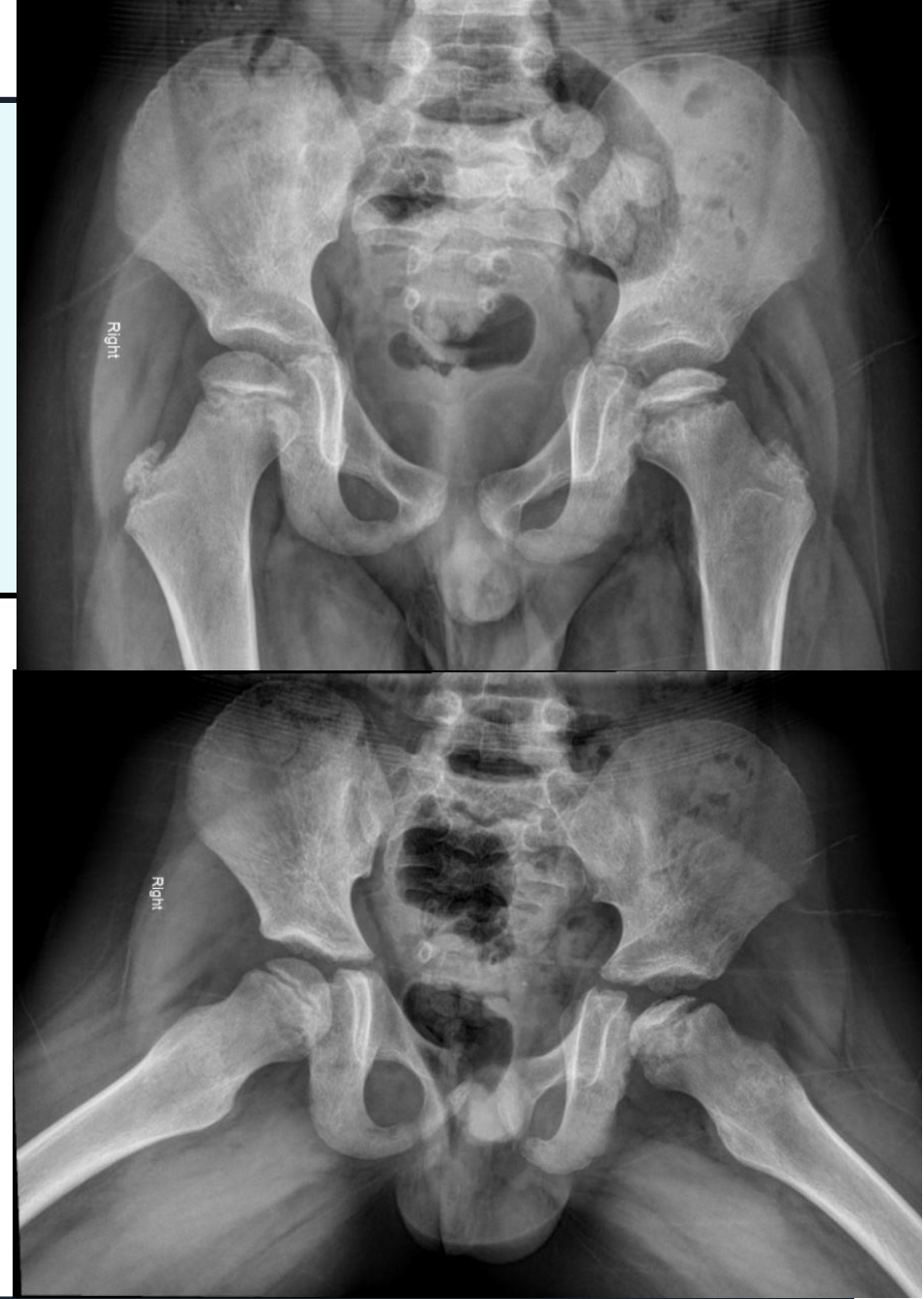(+) Galeazzi



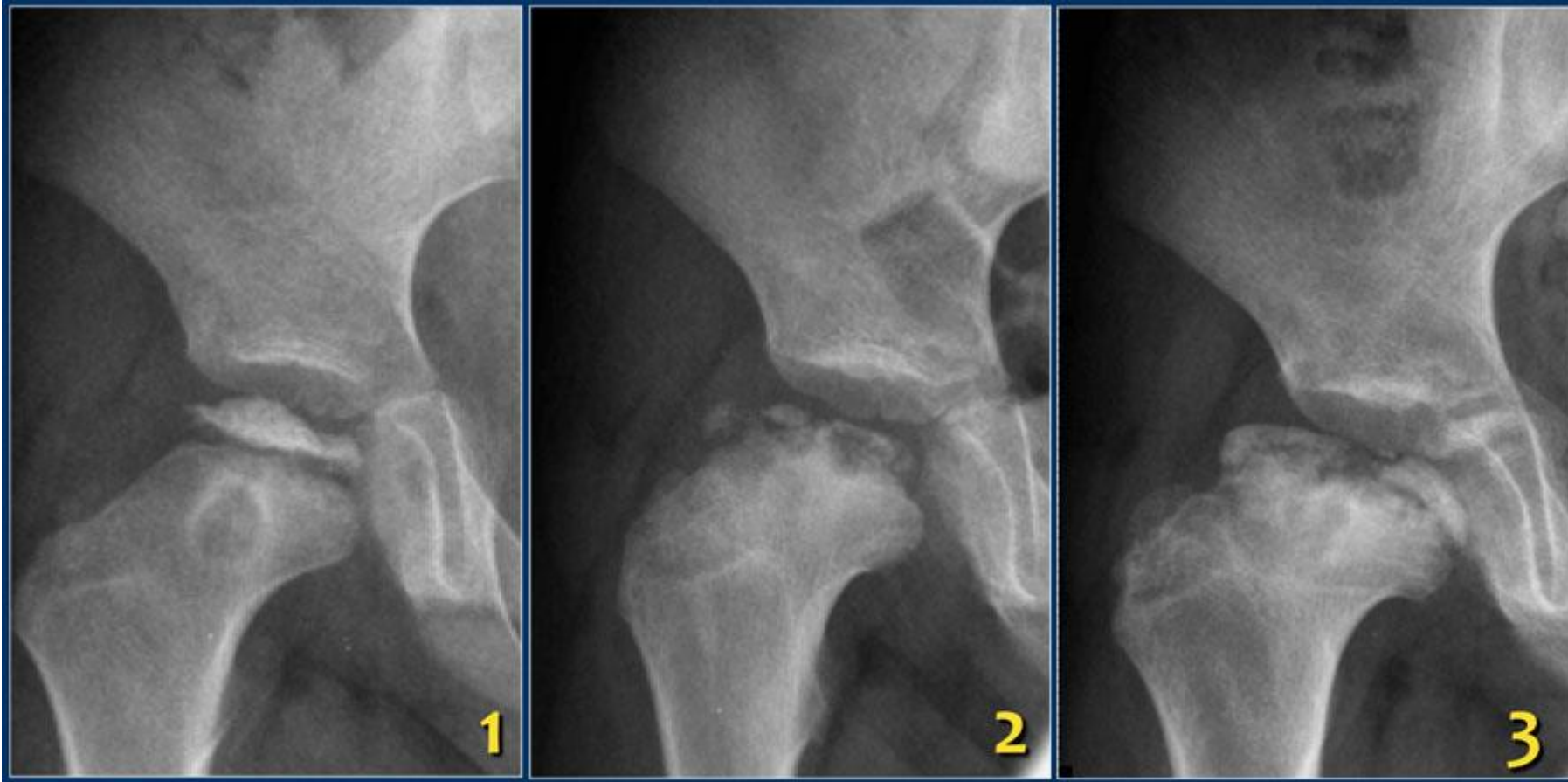
Perthes: Imaging

Radiographs (AP pelvis and frog laterals) are mainstay for diagnosis and monitoring condition

- Plain radiographs are often initially normal
- Bone scan or MRI if needed



Gradual Course of Perthes



Stages

Initial Phase (necrosis)
Fragmentation
Re-ossification
Healed (remodeling)

Perthes: Treatment

Age of onset best prognostic factor

- Younger age at presentation = better outcome

Goal: Symptomatic control and preserve hip function

Treatment recommendations are controversial

- Nonsurgical Options: Observation, activity restrictions, PT
 - Hip needs to be contained in acetabulum
 - Surgical early vs late as needed (> 6 yo)
-

Slipped Capital Femoral Epiphysis (SCFE)



SCFE

Slipping along the femoral physis

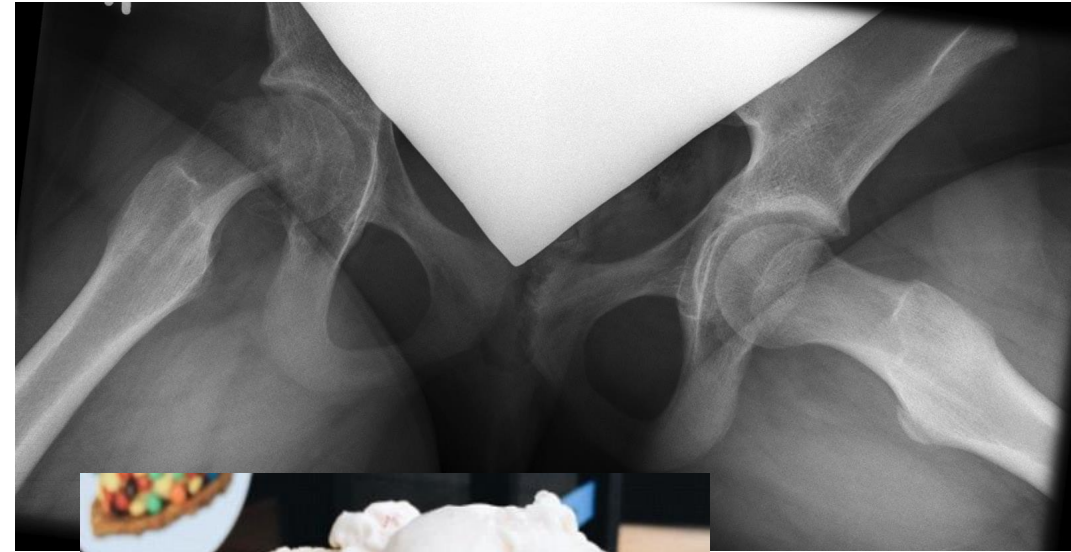
- “Ice cream slipping off the cone”

Peak incidence is 10-16 years old, M>F

Bilateral in 20-40% of patients

Obesity is significant risk factor

Etiology unknown: mechanical, genetic, trauma, inflammatory, endocrine



SCFE: Clinical Presentation

Typical presentation: obese adolescent with dull, achy hip pain and difficulty with ambulation

- May be associated with history of minor trauma
 - Isolated knee or thigh pain in 15% of cases
-

SCFE: Physical Exam

Decreased hip ROM

- Limited internal rotation, abduction, and flexion
- Pain may be present

Positive Trendelenburg may be seen in chronic presentation

Clinical Stability:

- Stable slip: patient able to walk or weight bear
 - Unstable slip: unable to bear weight even with crutches due to pain and displacement, pain severe
-

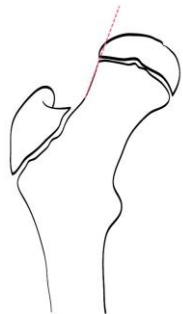
SCFE: Imaging

MRI is better to detect pre-slips

Radiographs are typically sufficient for diagnosis

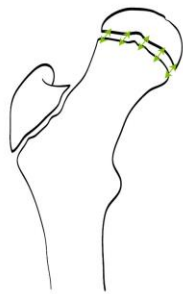AP and lateral views of **both** hips

- Line of Klein: line drawn along lateral edge of femoral neck on AP view should intersect the epiphysis



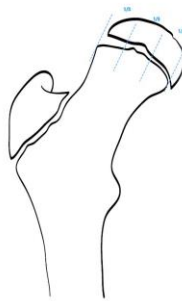Normal

F. Gaillard
2010
Radiopaedia.org (CC BY)



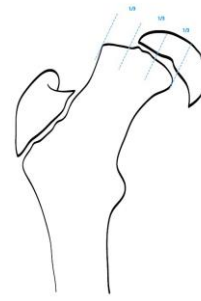Pre-slip

F. Gaillard
2010
Radiopaedia.org (CC BY)



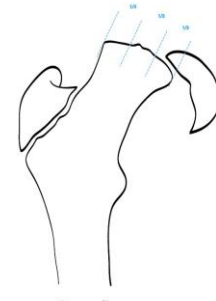Mild slip

F. Gaillard
2010
Radiopaedia.org (CC BY)



Moderate slip

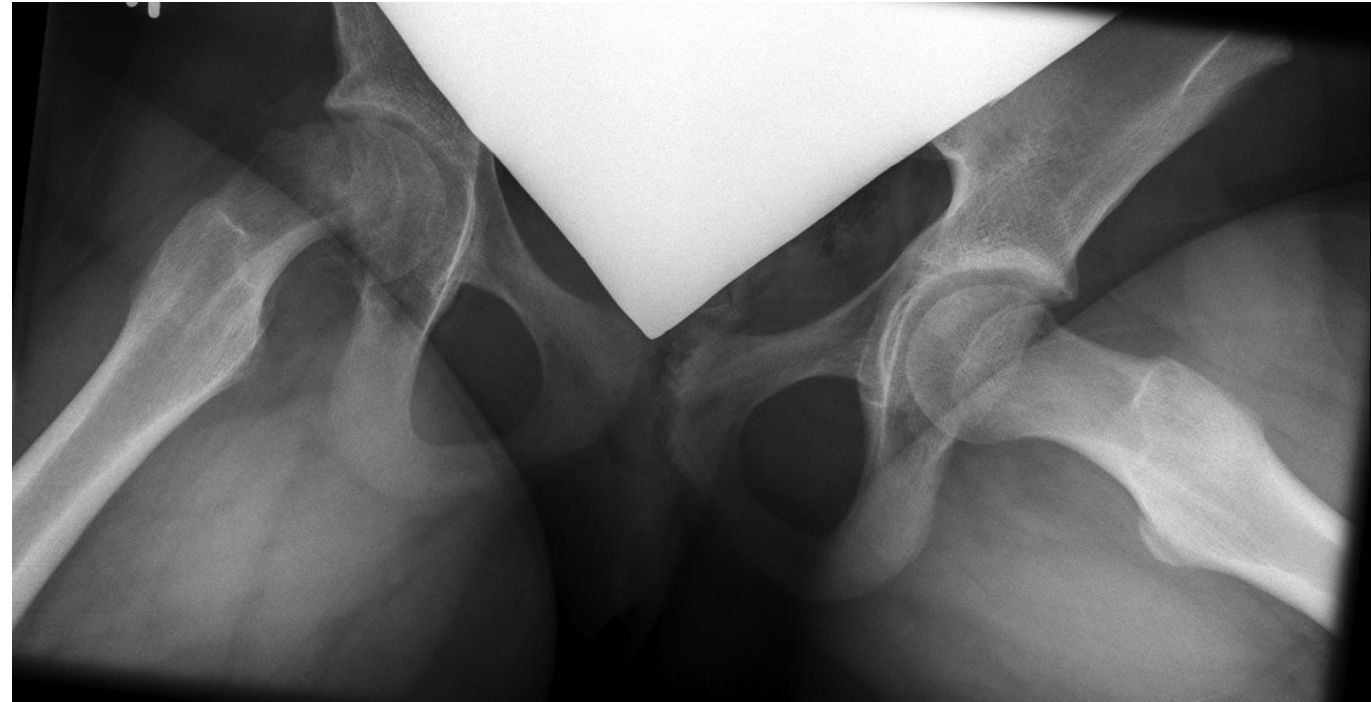
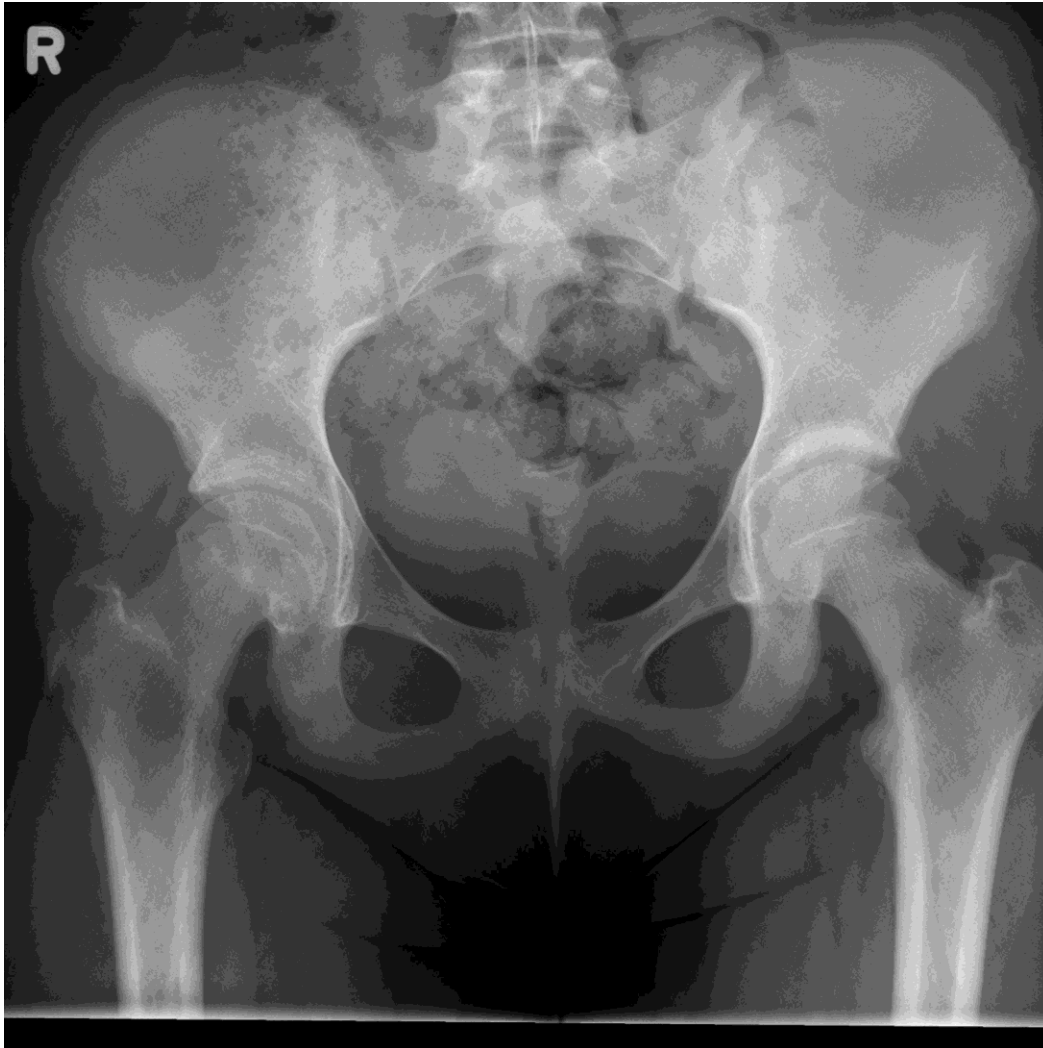
F. Gaillard
2010
Radiopaedia.org (CC BY)



Severe slip

F. Gaillard
2010
Radiopaedia.org (CC BY)

SCFE: Imaging



Classification Patterns	Symptoms	Imaging
Pre-slip	Pain present	Physeal widening (-) Displacement
Acute	Sx < 3 weeks Severe pain Limited ROM	(+) Joint effusion (-) Metaphyseal remodeling
Acute-on-chronic	Sx ≥ 3 weeks Acute increase in pain Decreased ROM	(+) Joint effusion (+) Metaphyseal remodeling
Chronic	Sx ≥ 3 weeks Vague, intermittent pain	(-) Joint effusion (+) Metaphyseal remodeling

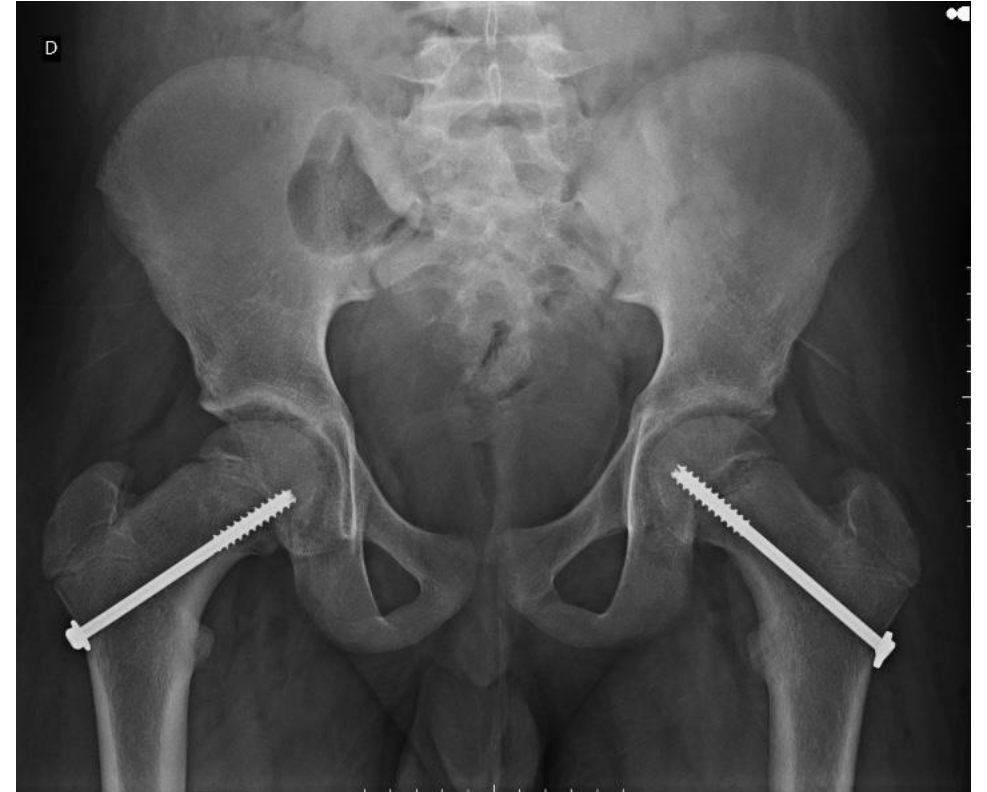SCFE: Treatment

Non-weight bearing

Admit to hospital on bed rest

Emergent operative stabilization

- Goal: prevent further slippage and avoid potential complications



Case courtesy of Dr Hemilianna Hadassa Silva Matozinho, Radiopaedia.org, rID: 81469

Septic Arthritis & Transient Synovitis of the Hip



Septic Hip

Epidemiology:

- Peak occurrence in first few months of life and again between ages 3-6 years old, M>F

Pathophysiology:

- Direct inoculation from trauma or surgery
 - Hematogenous seeding
 - Spreading of osteomyelitis from adjacent bone
-

Septic Hip: Clinical Presentation

Febrile and often acutely toxic appearing

Monoarticular pain: severely exacerbated with passive ROM

+ Roll test

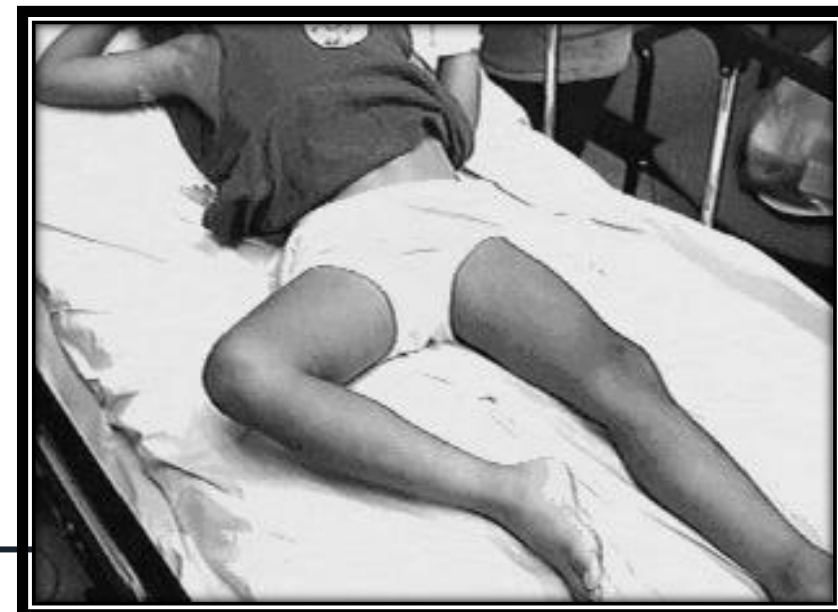Limited or refusal to weight bear

Differential Diagnosis:

Psoas abscess

Transient synovitis

Septic
Hip



DDX: Transient Synovitis of the Hip

Most common cause of pediatric hip pain

Appears well, typically afebrile (Temp <101)

Pain typically more mild, worse in am and improves during day

Recent URI

Etiology unclear, 3-8 years-old, M>F

Management: NSAIDs

- Improves in 24-48 hours with resolution within 1 week
 - Must rule out septic arthritis, hospitalize if suspicious
-

Septic Hip vs Transient Synovitis

Kocher Criteria

1. WBC > 12,000
2. ESR > 40
3. Fever > 101.3
4. Non-weight bearing on the affected side

CRP independent risk factor

- CRP > 2.0

Probability based on # of Kocher Criteria Met:

None: 0.2%

1/4: 3%

2/4: 40%

3/4: 93%

4/4: 99.6%

Septic Arthritis: Diagnostics

Prompt arthrocentesis: Gold standard

Labs: WBC with diff, ESR, CRP, blood culture

- Continue to monitor CRP and ESR

Other considerations:

- Gonococcal arthritis: culture
 - Group A strep: throat culture, ASO titer
 - Serology for coccidioidomycosis
-

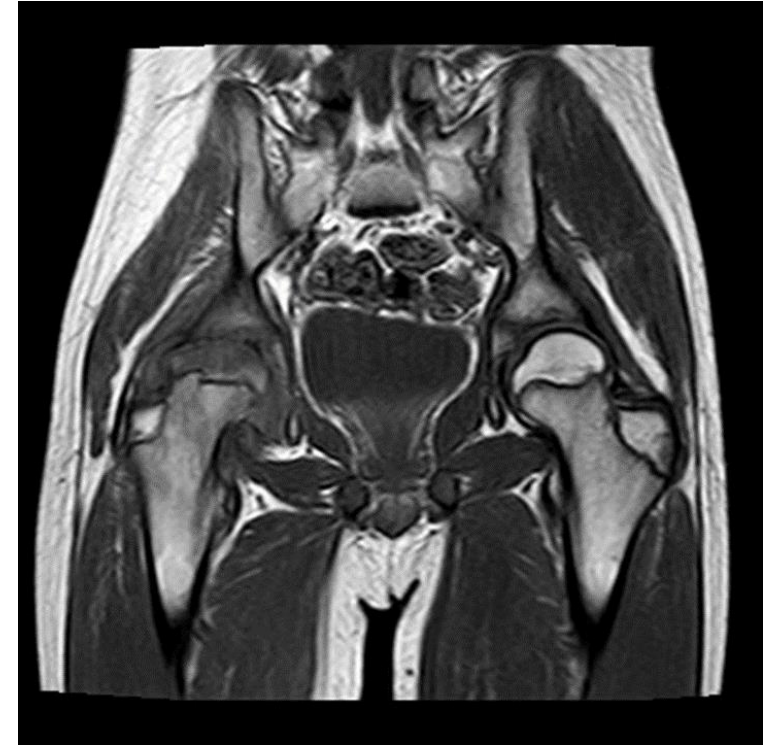Septic Arthritis: Diagnostics

Radiographs: AP/Lat may show increased joint space (effusion) or narrowing (destruction)

Ultrasound: detect effusion and guides aspiration

MRI : detects effusion, bone involvement, or associated concerns

- Pediatric patients require sedation



Case courtesy of Dr Ahmed Abd Rabou, Radiopaedia.org, rID: 2774

Septic Hip

Operative management: surgical I&D

- Joint aspiration or surgical identification is diagnostic

Antibiotic Need: Empiric treatment with modifications based on gram stain and culture

- *S. aureus*, *S. pneumo*, group A strep, *H. influenza*

❖ *N. gonorrhoeae* in adolescents

- Non operative management consideration: : High dose penicillin
-

Atraumatic Hip Diagnostics to Consider

Infectious or Inflammatory Causes:

- Basic Labs: CBC, ESR/CRP, blood culture
- Rheumatologic: RF, ANA
- Septic Arthritis: arthrocentesis urgently
 - Gram staining, cell count, and culture
- Additional considerations: Lyme and/or Cocci

Night Pain or Pain at Rest

- Red Flag
- Warrants further work-up

Imaging

- Plain radiographs are first line
 - Consider AP pelvis and Frog Laterals of both hips
 - Ultrasound: effusion, infant hips
 - MRI: high suspicion or early presentation
-

Take Home Points

1. Consider imaging for breech newborns or with positive family history of hip dysplasia regardless of physical exam findings
 2. Always fully evaluate the hip with all atraumatic knee complaints!
 3. Patients need to be made non-weightbearing immediately following suspicion for slipped capital femoral epiphysis
 4. Labs and NSAIDs can initially help differentiate infectious versus inflammatory process of the hip
 5. SCFE and Septic arthritis of the hip require emergent identification and management
 6. Avoid crutches < 8-10 yo
-

Resources

AAOS: <http://www.aaos.org/>

POSNA: <https://posna.org/>

AAFP: <http://www.aafp.org/>

International Hip Dysplasia Institute: <http://hipdysplasia.org/>

Radiopaedia: <http://radiopaedia.org/>

Radiology Assistant: <http://www.radiologyassistant.nl>

OrthoBullets: <https://www.orthobullets.com>

References

1. Committee on Quality Improvement, Subcommittee on Developmental Dysplasia of the Hip. American Academy of Pediatrics. Clinical practice guideline: early detection of developmental dysplasia of the hip. *Pediatrics*. 2000; 105: 896-905.
 2. Thomas SRYW. Specialty Update: Children's Orthopaedics. A review of long-term outcomes for late presenting developmental hip dysplasia. *Bone Joint J*. 2015; 97-B: 729-733.
 3. Ibrahim T, Little DG. The pathogenesis and treatment of Legg-Calve-Perthes disease. *JBJS Reviews*. 2016; 4(7): e4. <http://dx.doi.org/10.2106/JBJS.RVW.15.00063>
 3. Sawyer JR, Kapoor M. The limping child: a systemic approach to diagnosis. *Am Fam Physician*. 2009; 79(3):215-24.
 4. Peck D. Slipped capital femoral epiphysis: diagnosis and management. *Am Fam Physician*. 2010; 82(3):258-62.
 5. Schur MD, Andras LM, Broom AM, et al. Continuing delay in the diagnosis of slipped capital femoral epiphysis. *Pediatrics*. 2016. doi:10.1016/j.jpeds.2016.06.029
 6. Kocher MS, Zurakowski D, Kasser JR. Differentiating between septic arthritis and transient synovitis of the hip in children: an evidence-based clinical predication algorithm. *J Bone Joint Surg. Am*. 1999;81:1662-70.
 7. Gottlieb M, Holladay D, Rice M. Current approach to the evaluation and management of septic arthritis. *Pediatr Emerg Care*. 2019;35(7):509-513.
- ❖ Guidelines and recommendations from organizations including American Academy of Orthopaedic Surgery (AAOS), Pediatric Orthopaedic Society of North America (POSNA), American Academy of Pediatrics (AAP), and American Academy of Family Physicians (AAFP) were also discussed.
-

Contact Information

Sarah Bolander, DMSc, PA-C, DFAAPA

sbolan@midwestern.edu

Cactus Pediatric Orthopaedics: 480-551-0300
