

ECG Breakout Session

September 16th/17th, 2022

Danielle M Sparenga, DNP, ACNP-BC

Mayo Clinic Phoenix, Arizona

- No disclosures
- No off label uses
- Copyright permissions obtained from Dan Sorajja, MD, Mayo Clinic Electrophysiology



Learning Objectives

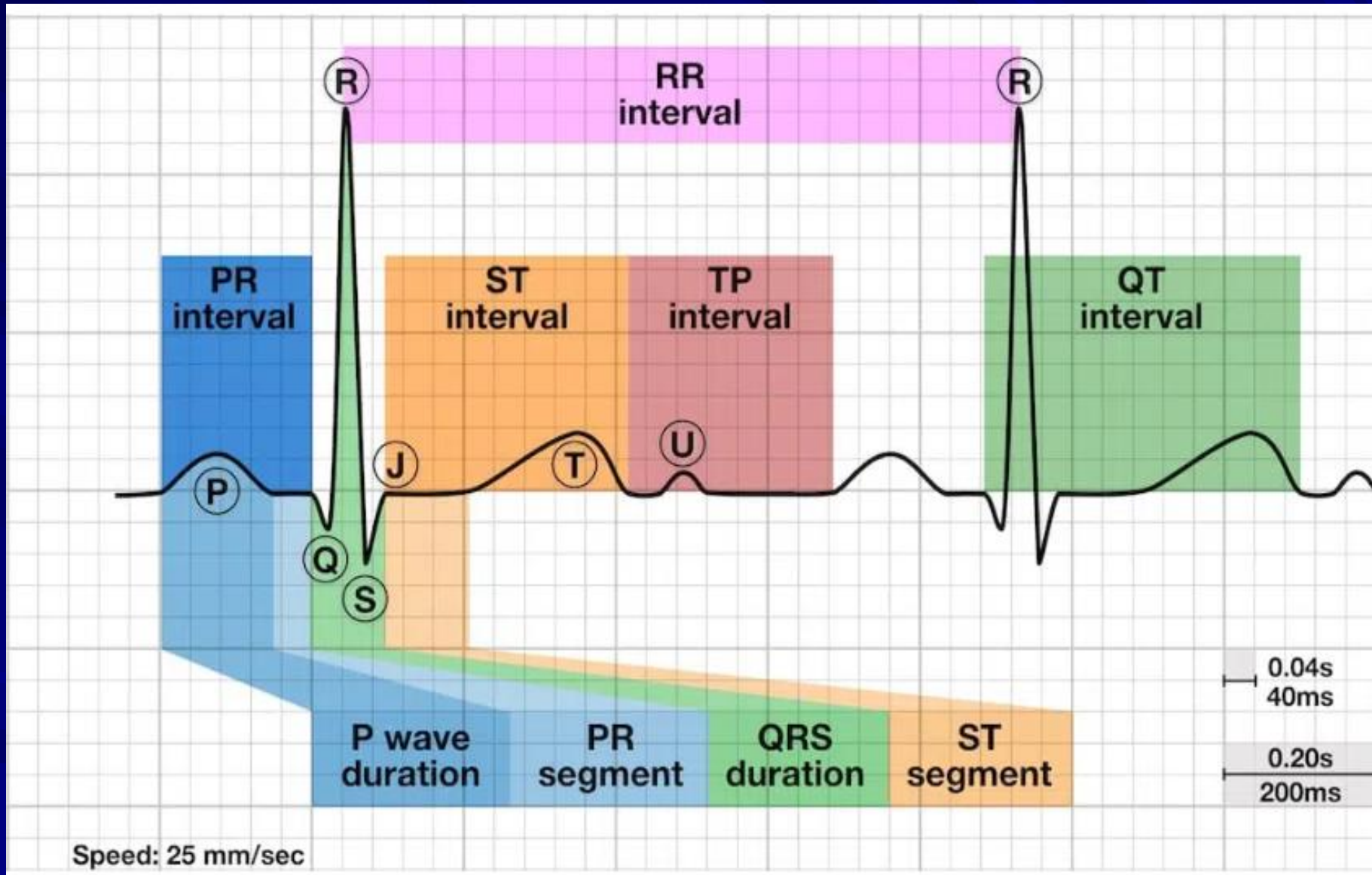
- Review 6 step approach to 12 lead interpretation
 - Name the rhythm
 - Name the abnormality
- Recognize common clinical ECG findings including ECG changes associated with myocardial ischemia & infarction
- Clinical ECG applications/findings in an acute setting
- Practice

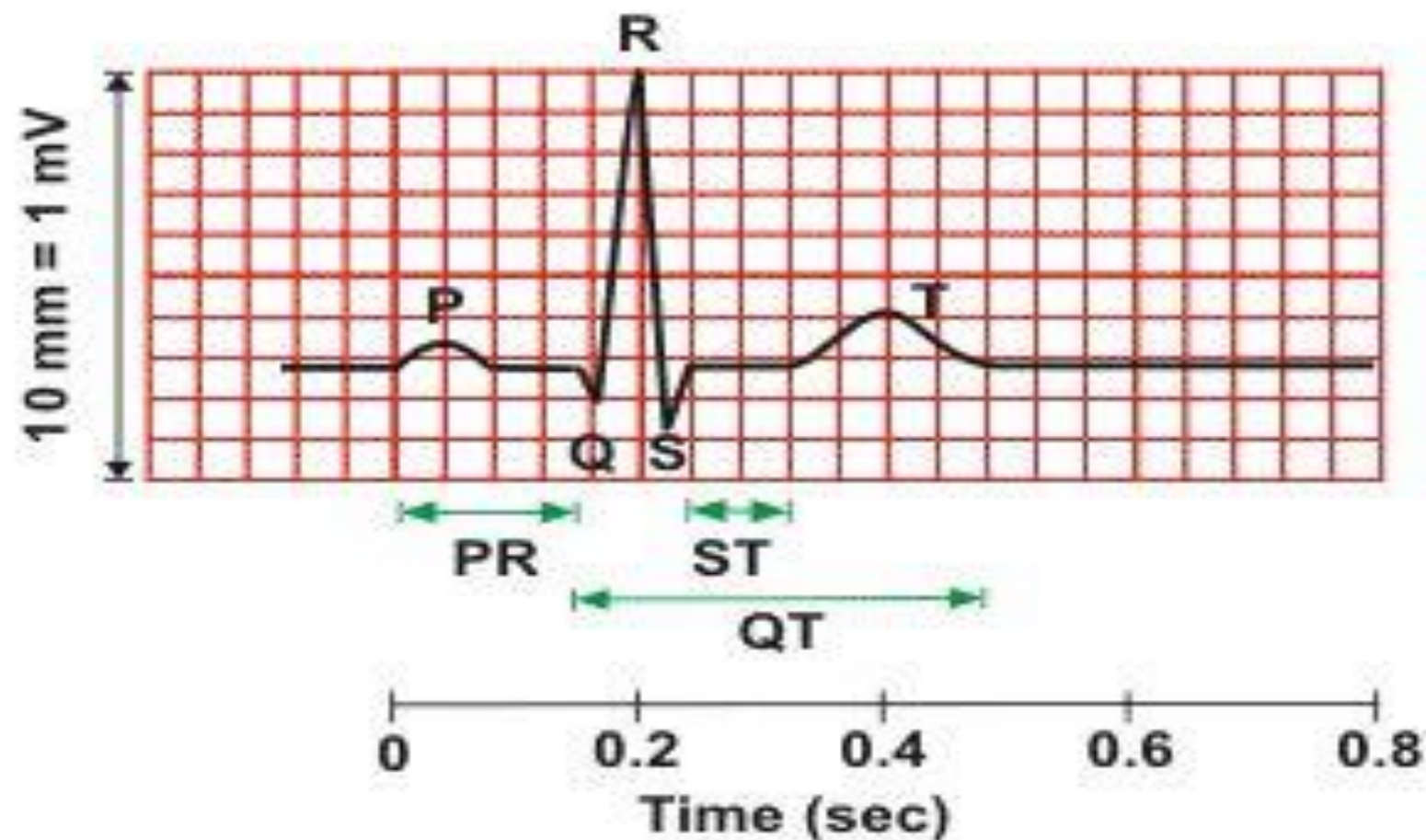
Key To 12 Lead Interpretation

6 step method

- Rate & Rhythm
- Axis determination
- Intervals (PR, QRS, QT)
- Morphology (BBB)
- Ischemia, Injury, Infarct
- Bonus step: Correlate to history and clinical presentation

• Intervals (PR, QRS, QT)





P wave (0.08 - 0.10 s)

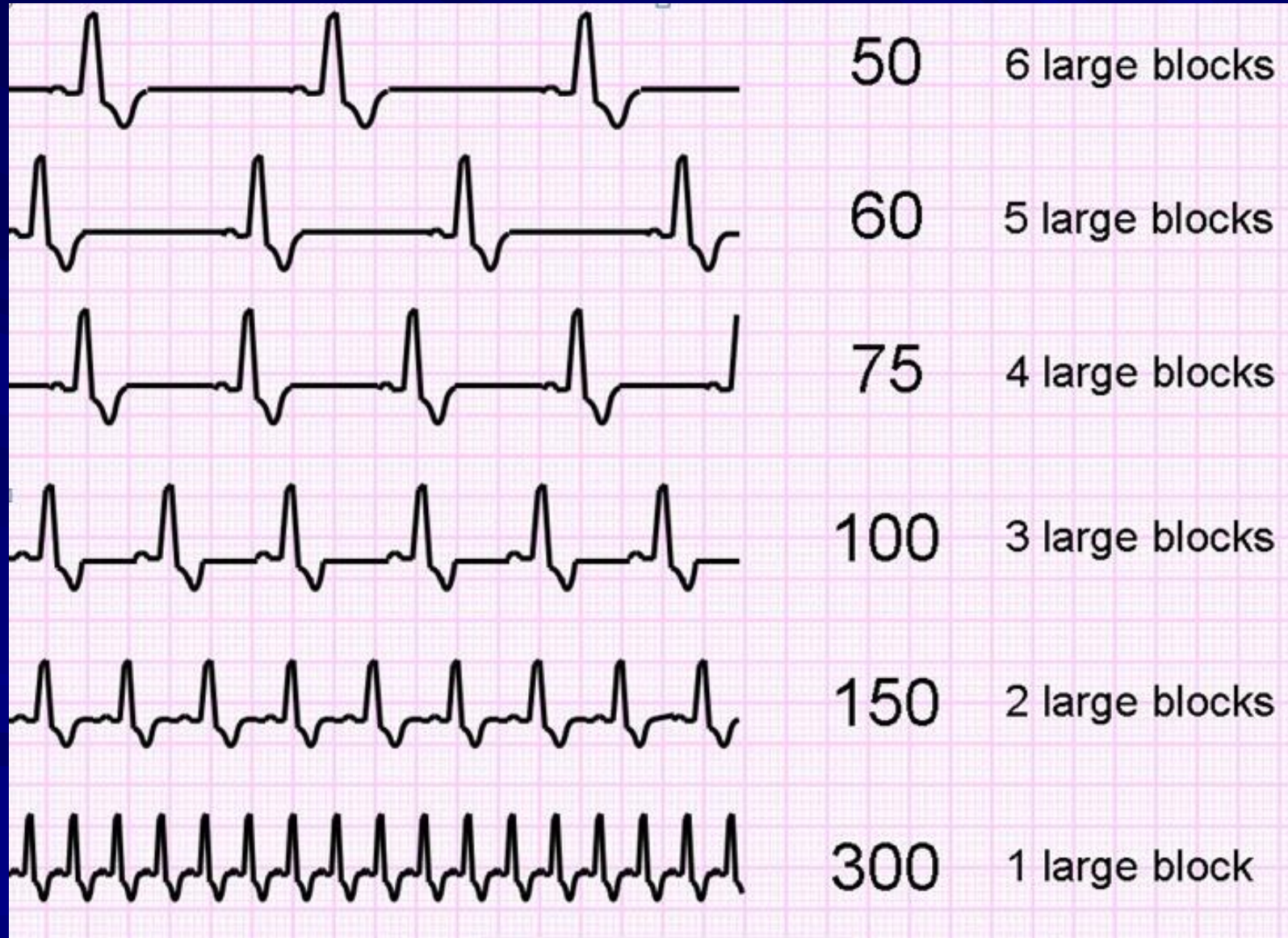
QRS (0.06 - 0.10 s)

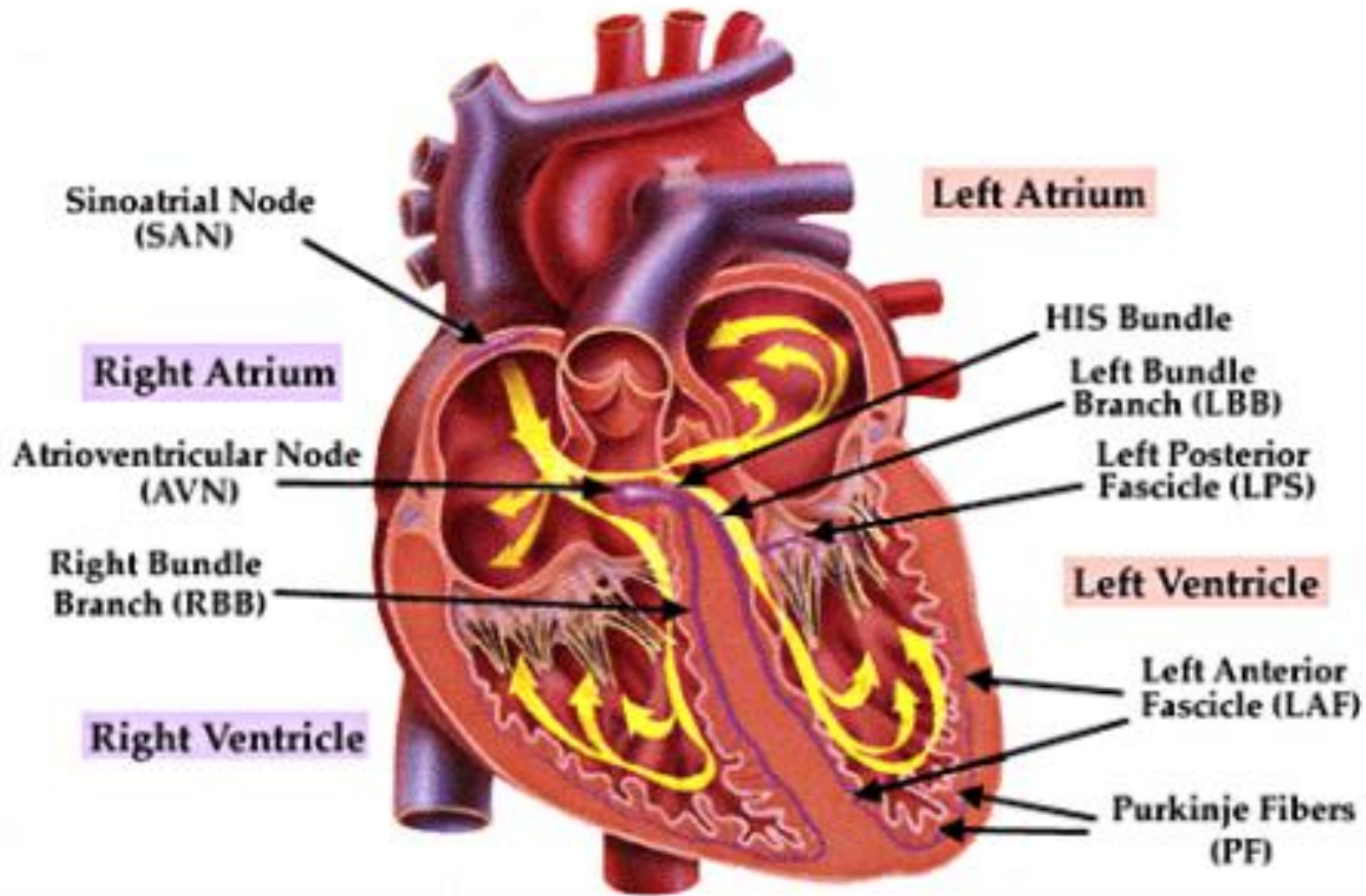
P-R interval (0.12 - 0.20 s)

Q-T_c interval (≤ 0.44 s)*

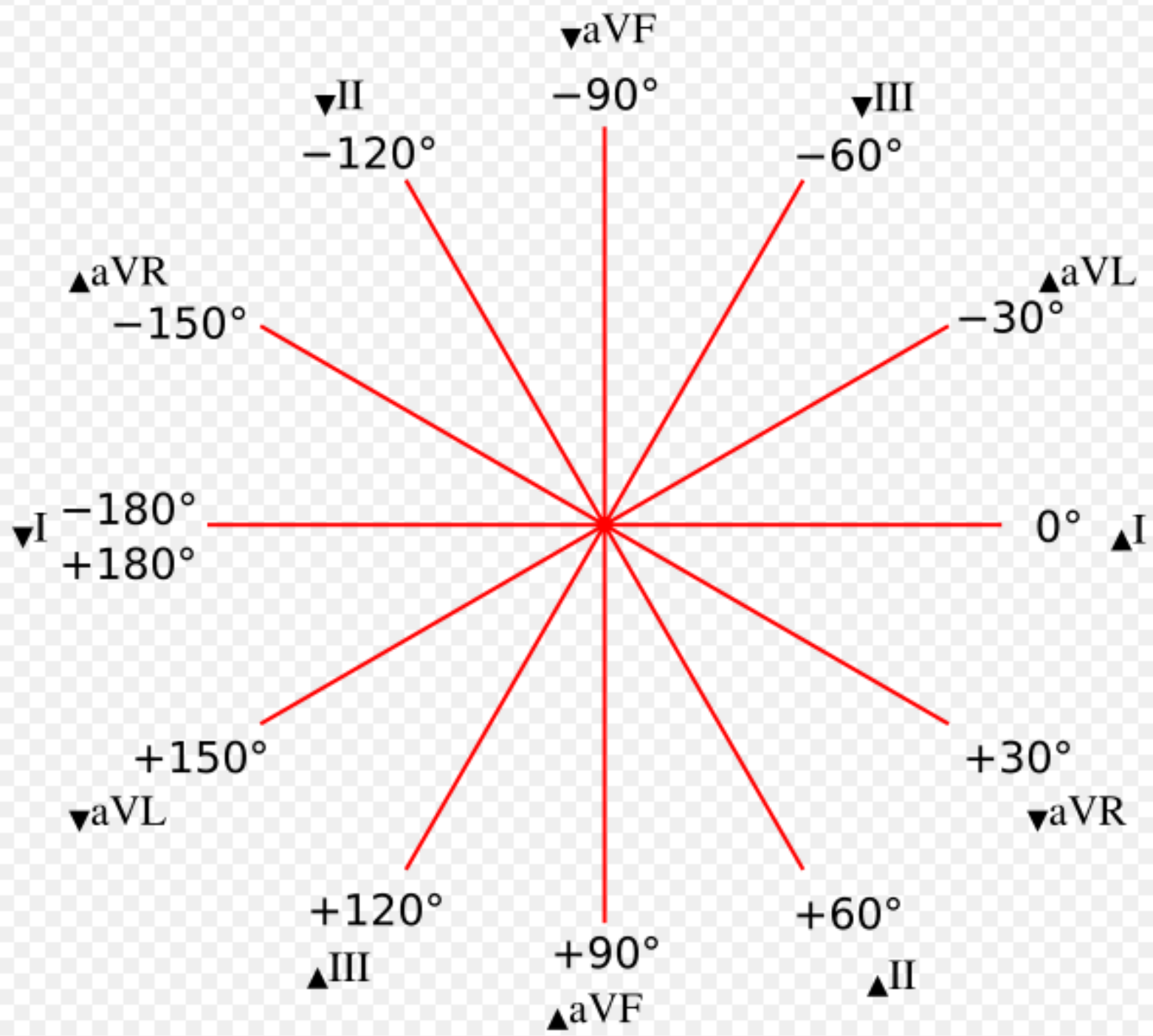
$$*QT_c = \frac{QT}{\sqrt{RR}}$$

Determining Heart Rate



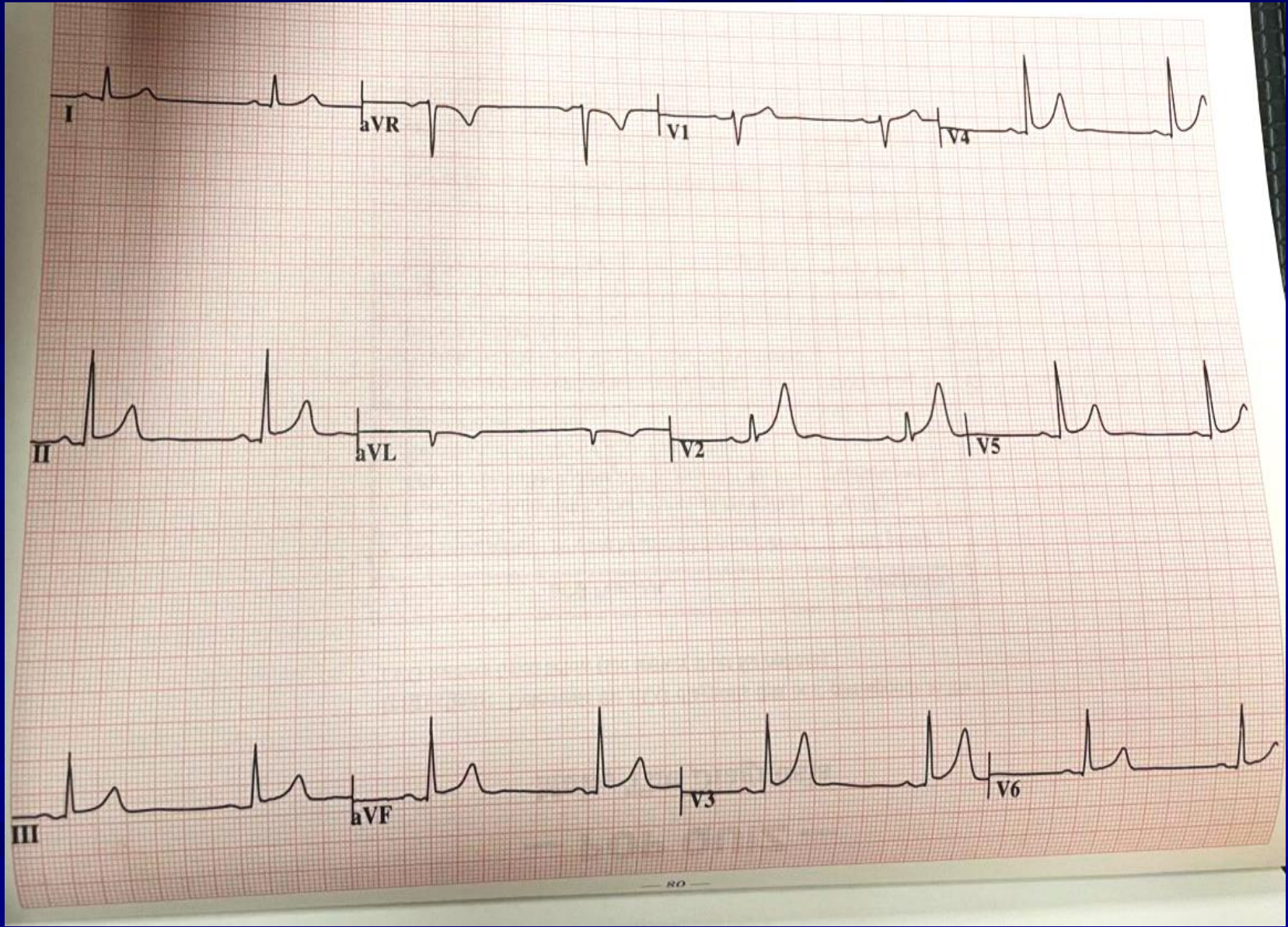


Cardiac Conduction System



Axis

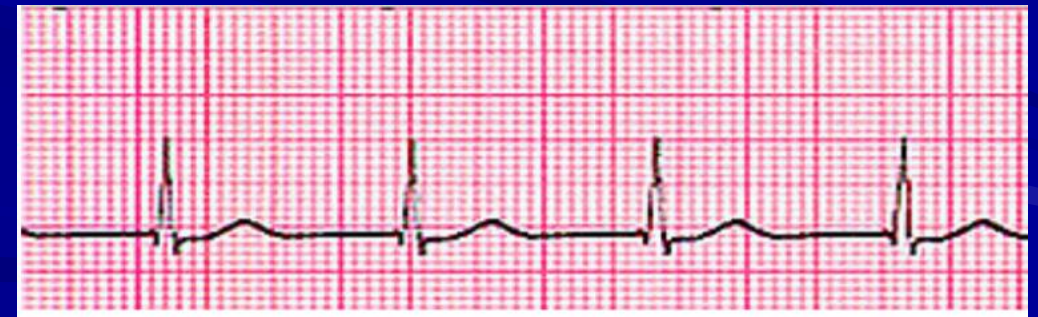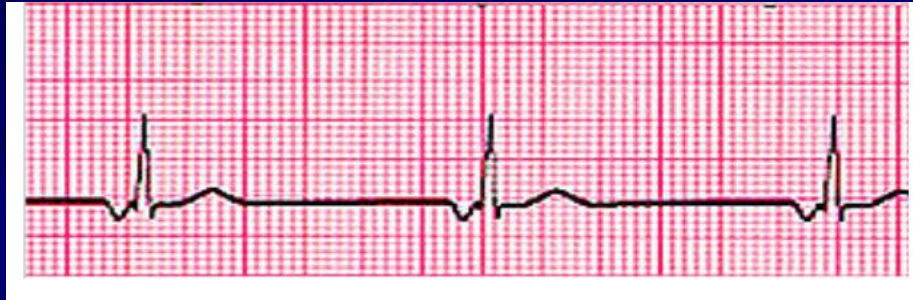Axis	Lead I	aVF	Lead II
Normal Axis (0° to 90°)	+	+	
Normal variant (0° to -30°)	+	-	+
Left axis deviation (-30° to -90°)	+	-	-
Right axis deviation ($>100^{\circ}$)	-	+	
Right superior axis (-90° to $+180^{\circ}$)	-	-	



Bradycardia

- Sinus Bradycardia
- Junctional Rhythm
- Heart blocks
- Atrial fibrillation with SVR
- ** Where are the P waves?
- ** Is the Patient symptomatic?

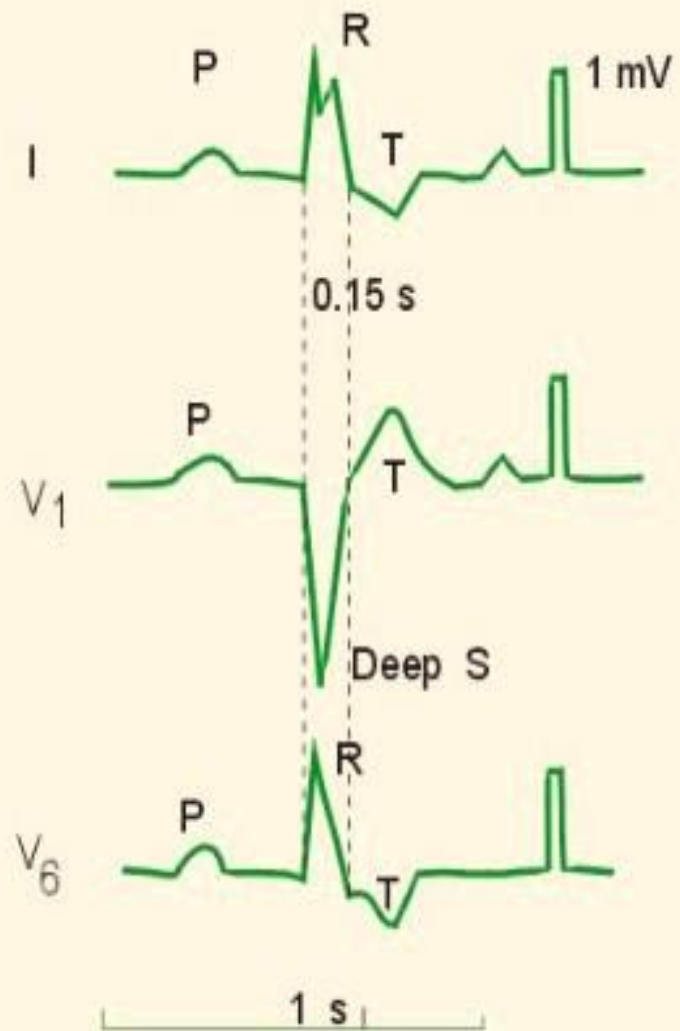
Junctional Rhythm



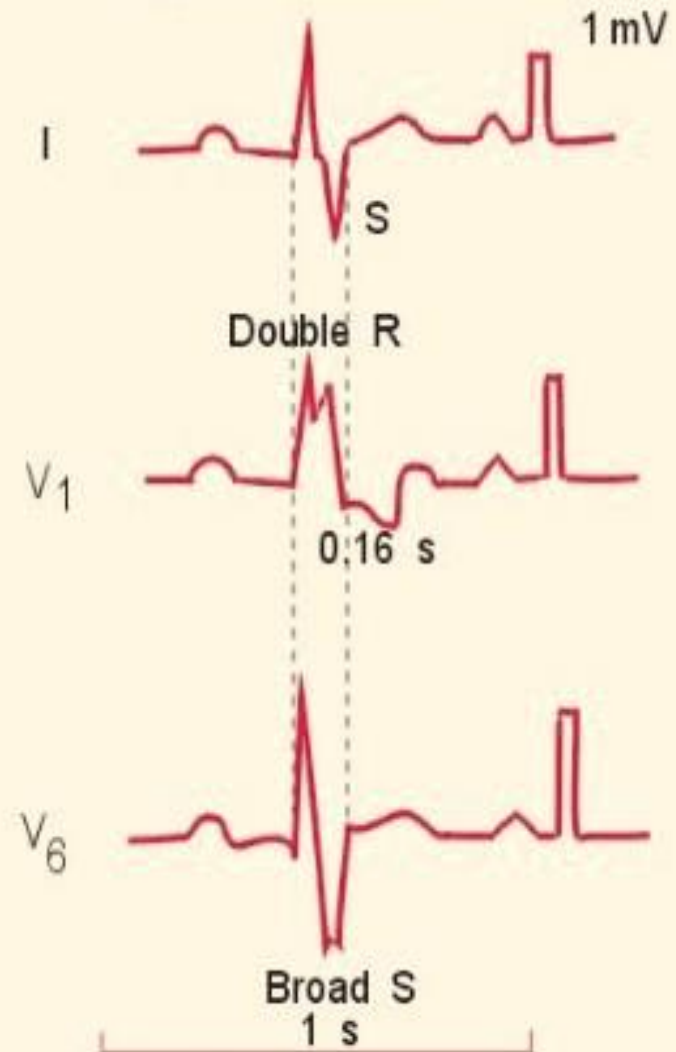
Narrow or Wide?

Bundle Branch Block

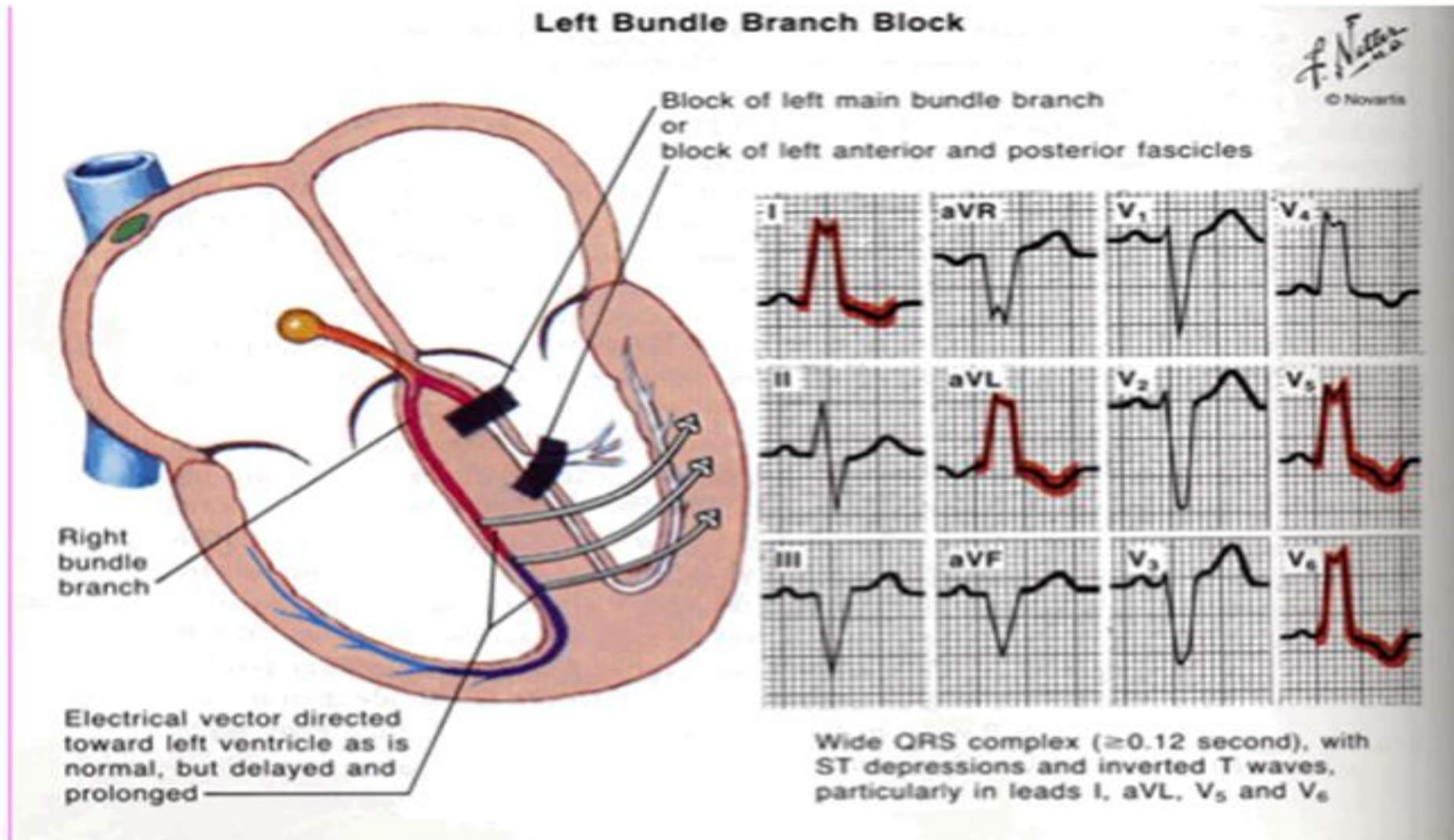
Left bundle branch block



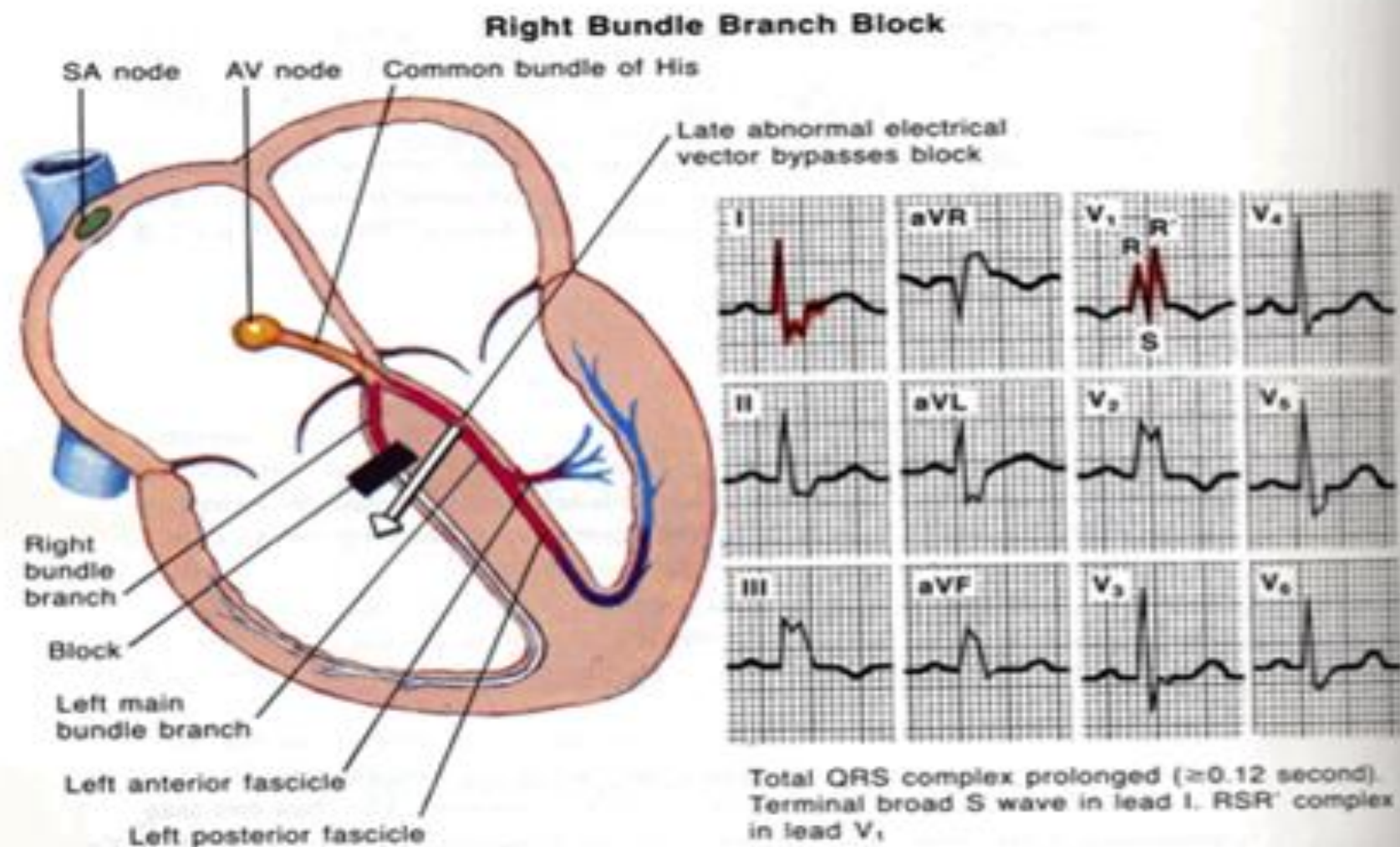
Right bundle branch block



Left bundle branch block



Right bundle branch block



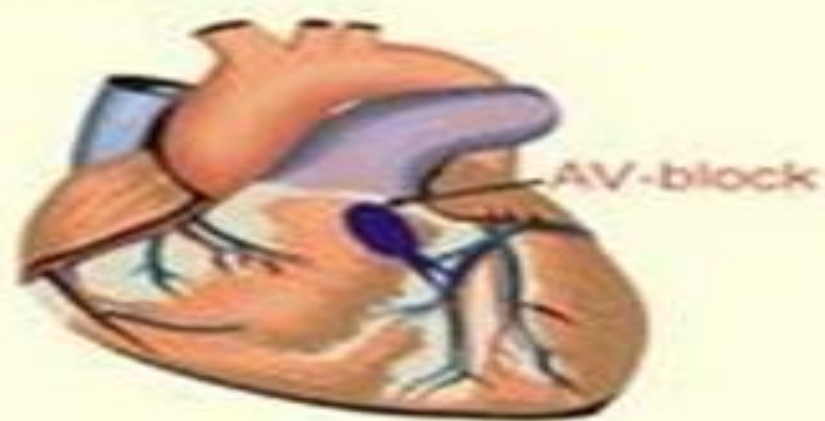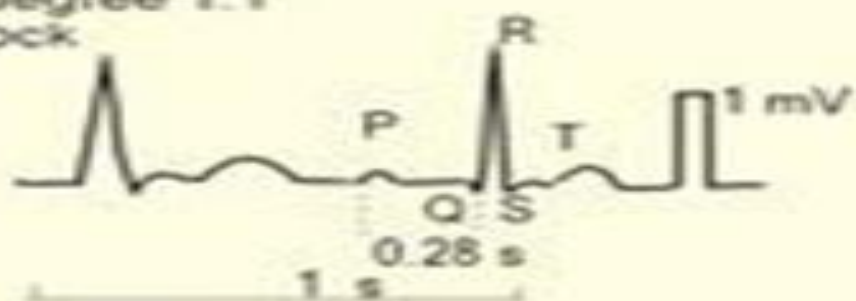
Blocks

- 1st Degree
- 2nd Degree
 - Type I (Mobitz I) Wenchebach
 - Type II (Mobitz II)
 - 2:1 AV block
- 3rd Degree (Complete Heart Block)

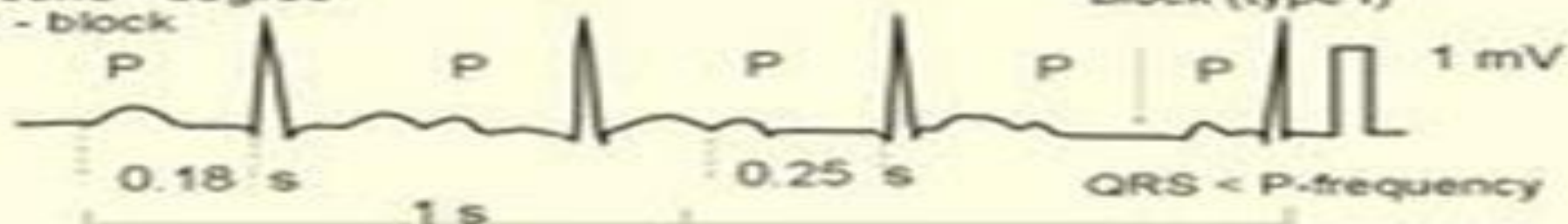
Heart Block Poem

- If the “R” is far from “P,” then you have a **FIRST DEGREE**
- Longer, longer, longer, drop! Then you have a Wenkebach
- If some “P”s just don’t get through, then you have **MOBITZ II**
- If “P”s and “Q”s just don’t agree, then you have a **THIRD DEGREE**

First - degree 1:1
AV - block



Second - degree
AV - block



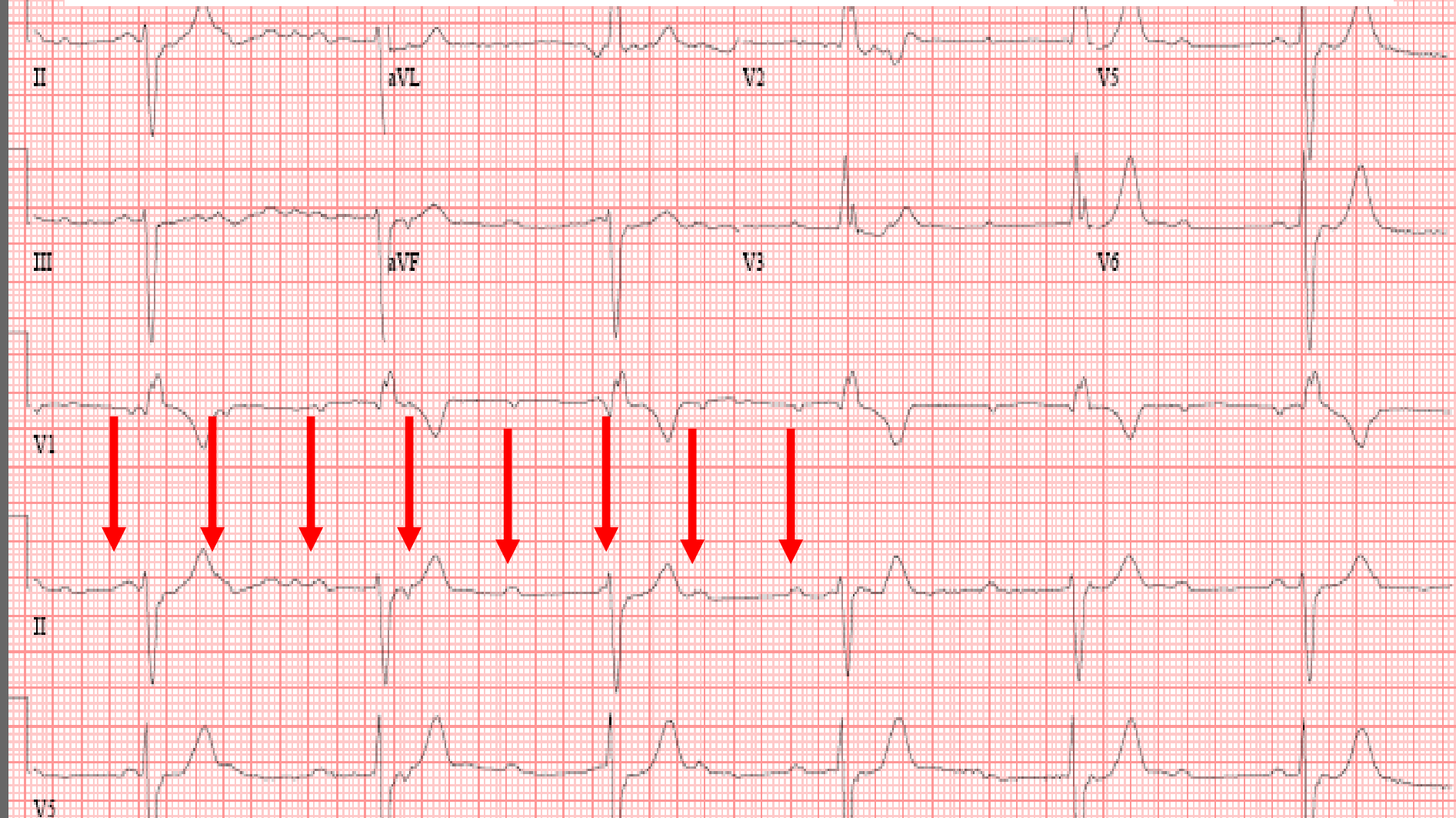
Second - degree
AV - block

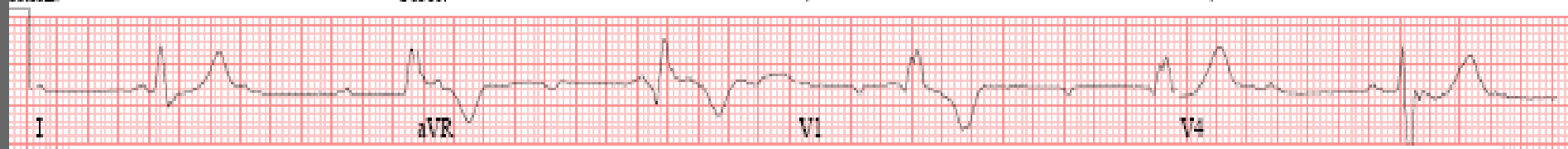


Third - degree
AV - block

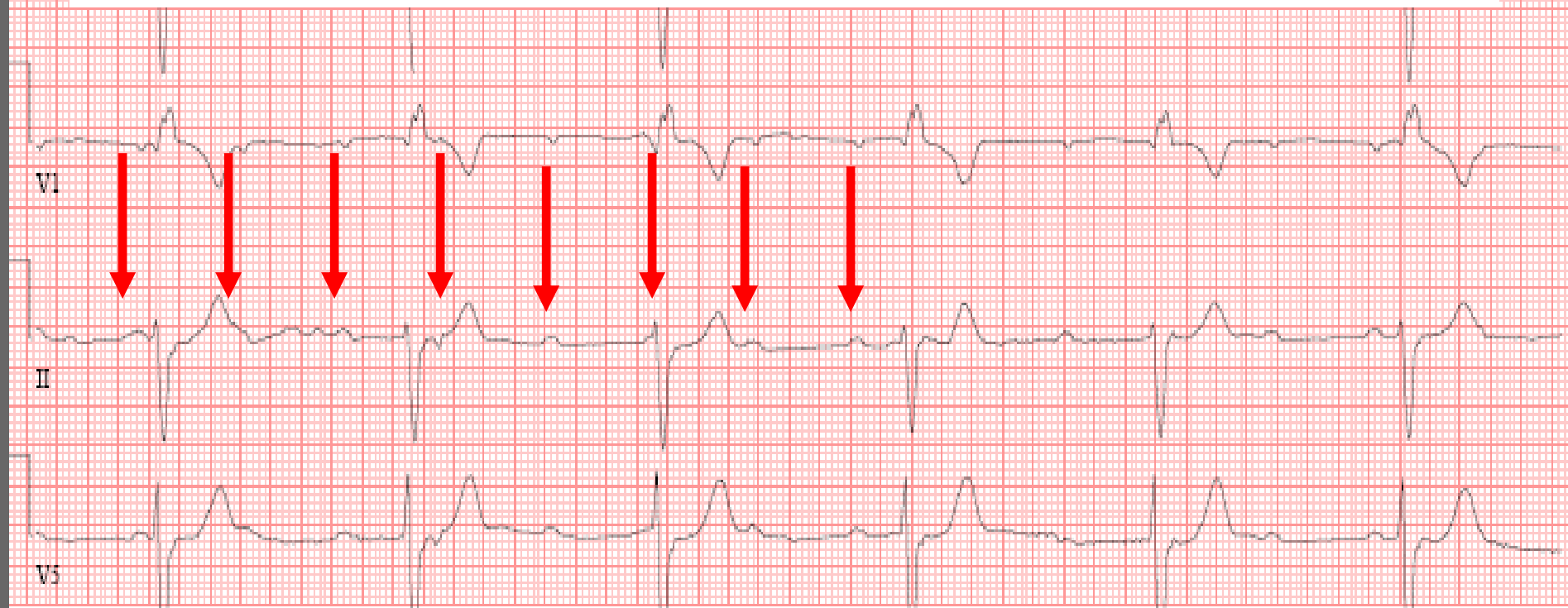


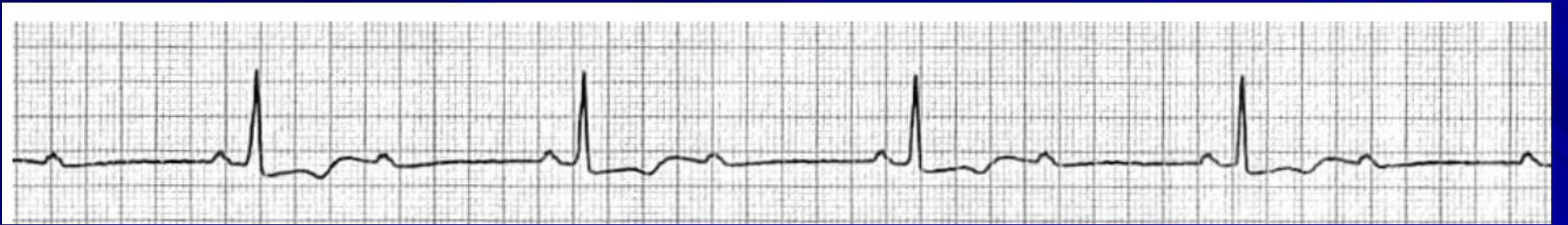Where are the P waves?





P waves number more than
QRS complexes meaning . . .
This is complete heart block





2:1

Feature	Mobitz Type I	Mobitz Type II
QRS Duration	Narrow	Wide
Response to maneuvers that increase heart rate & AV conduction (ie Atropine, Exercise)	Block Improves	Block worsens
Response to maneuvers that reduce heart rate & AV conduction (ie carotid massage)	Block worsens	Block improves
Develops during acute MI	Inferior MI	Anterior MI
Other	Grouped beating	History of Syncope

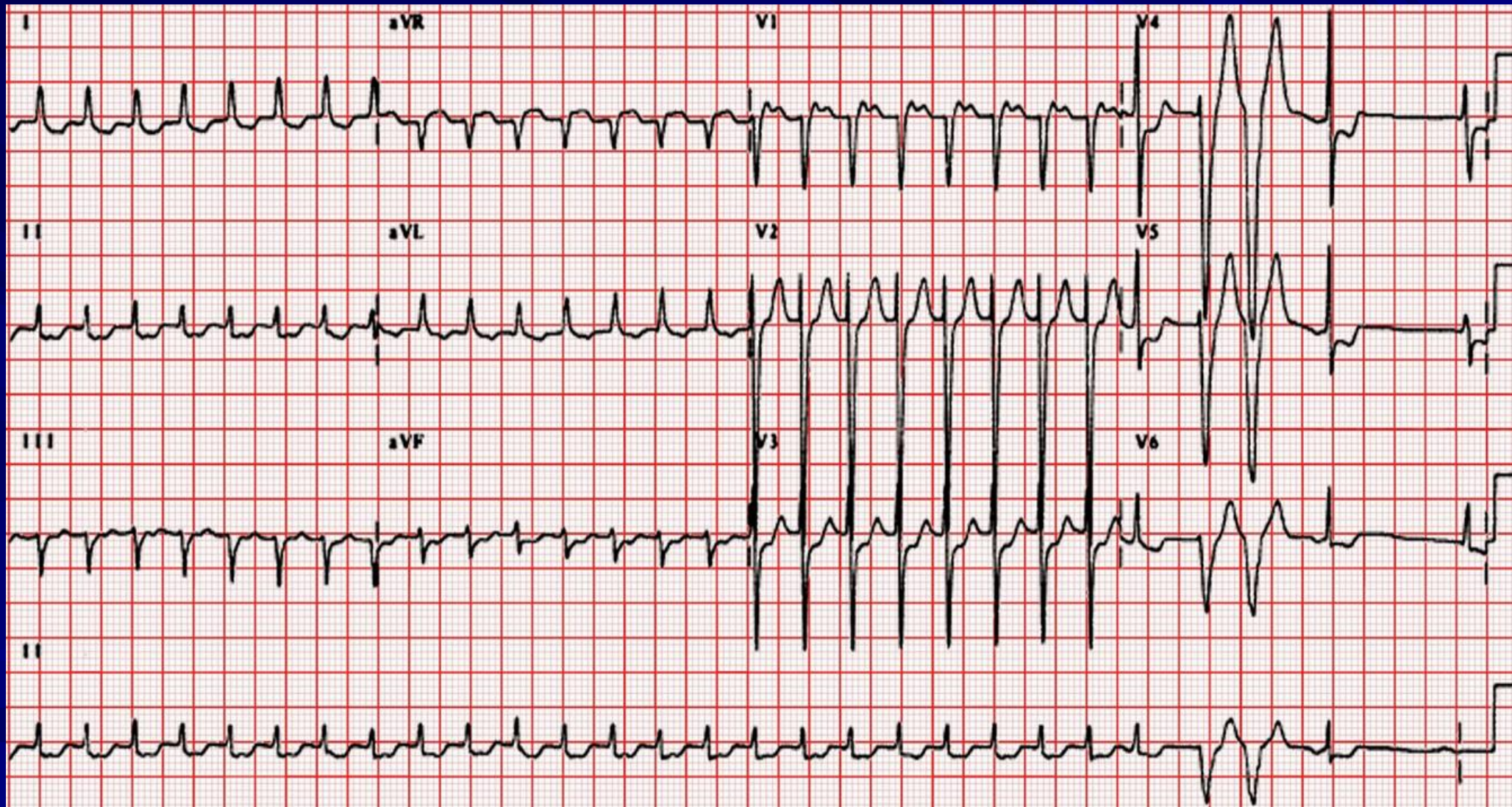
Tachyarrhythmia

Tachyarrhythmia	Rate	QRS	Rhythm	P waves
Sinus tachycardia	Fast	Narrow	Regular	Yes
Supraventricular tachycardia or SVT (AVNRT)	Fast	Narrow	Regular	No
Atrial Fibrillation	Fast	Narrow	Irregular	No
Atrial Flutter	Fast	Narrow	Regular	Sawtooth
Ventricular tachycardia	Fast	Wide	Regular	No
Ventricular fibrillation	Fast	Wide	Irregular	No

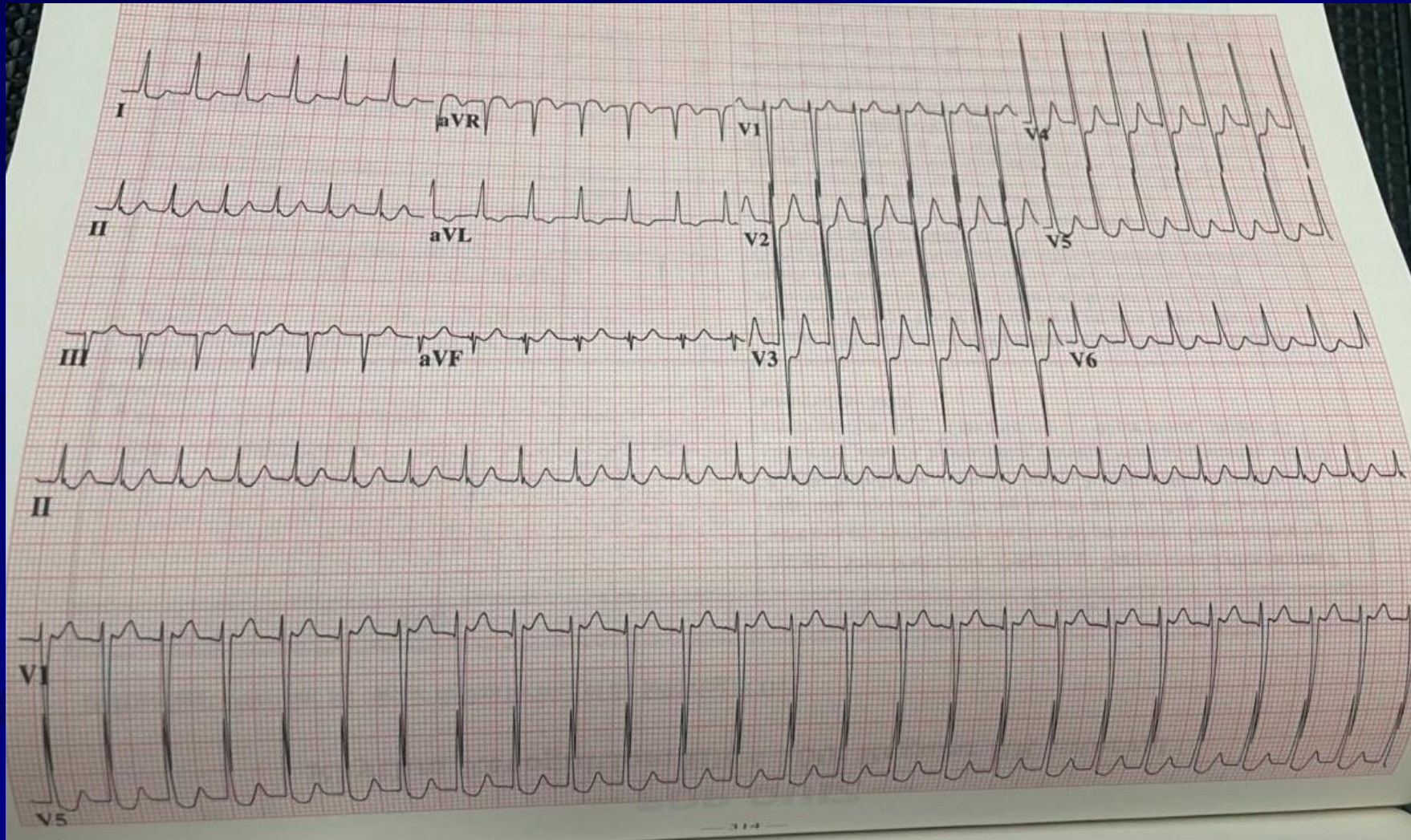
SVT

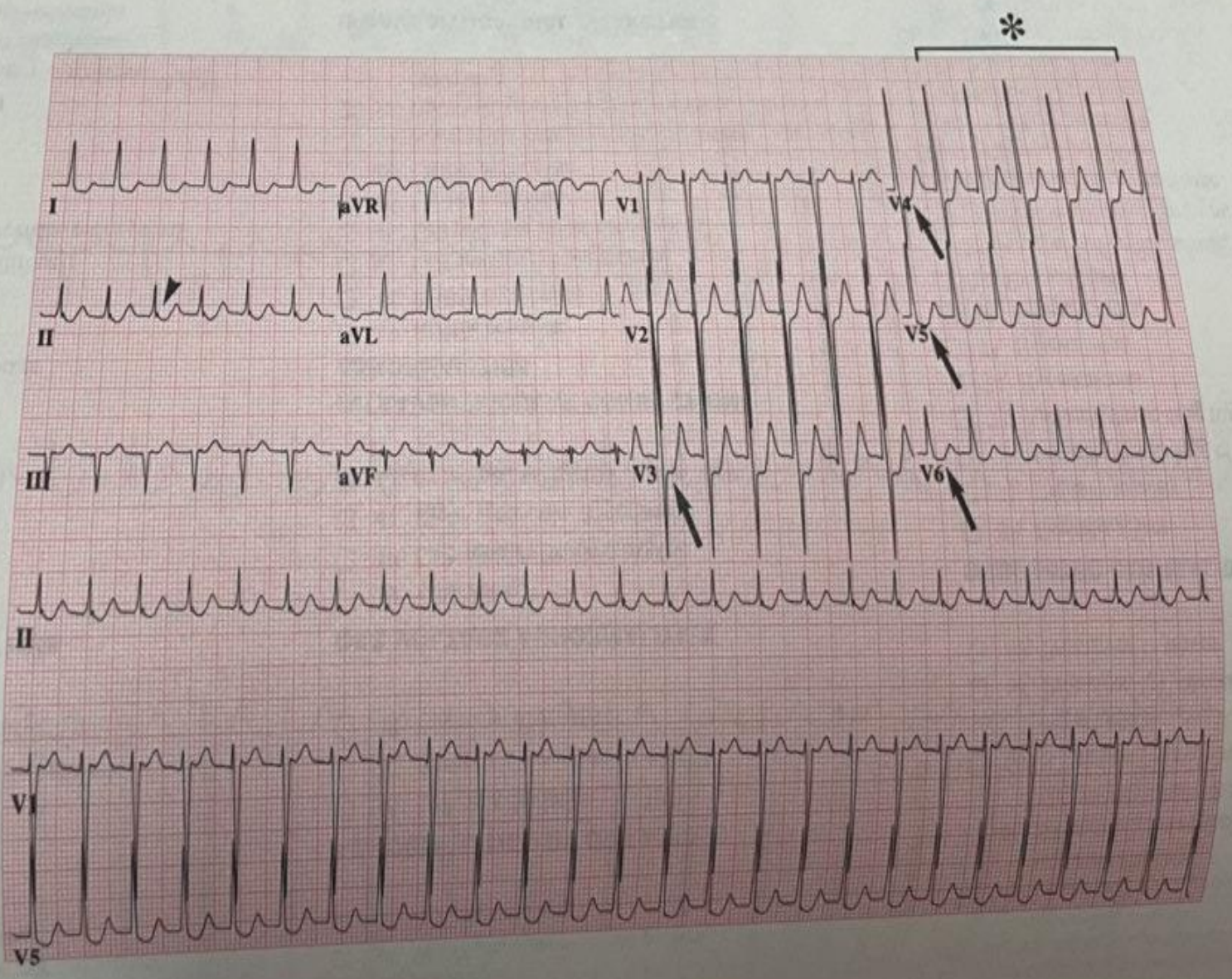
Abnormally fast rhythm that starts in the atria

- Atrial tachycardia
- AV node re-entrant tachycardia
- Atrial Fibrillation
- Atrial Flutter
- Paroxysmal SVT



71 yr old M presenting with palpitations



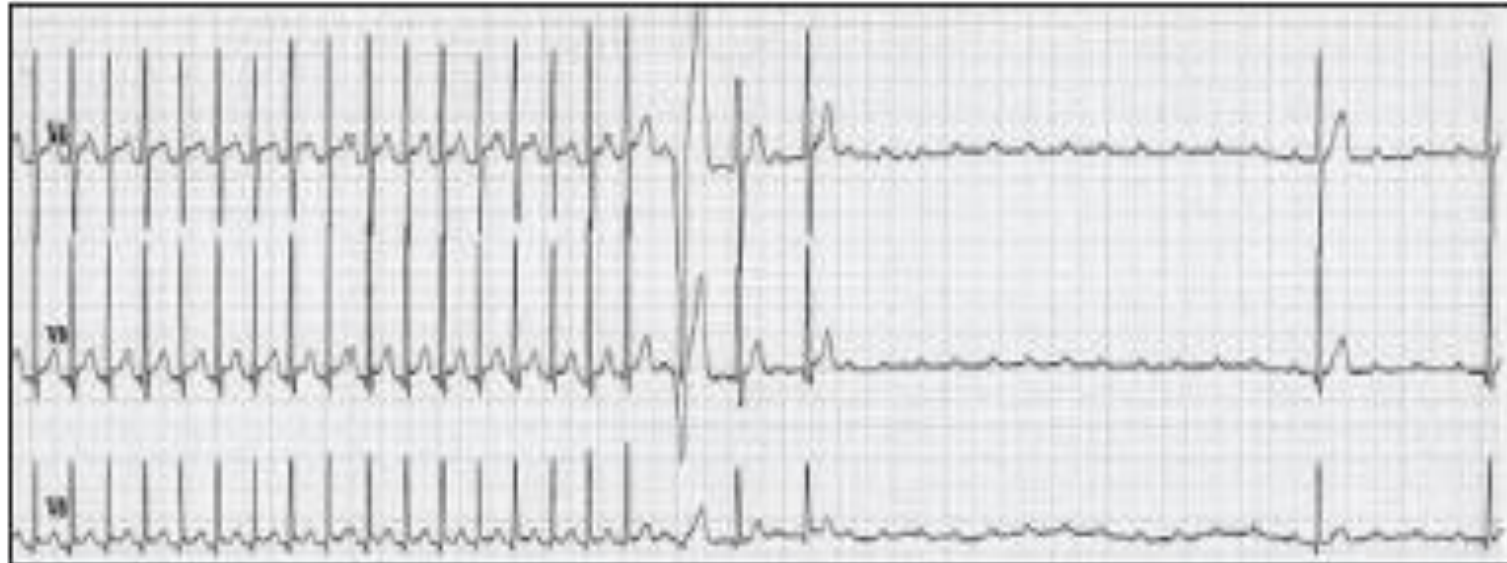

SVT

Medscape®

www.medscape.com

Adenosine (6 mg)

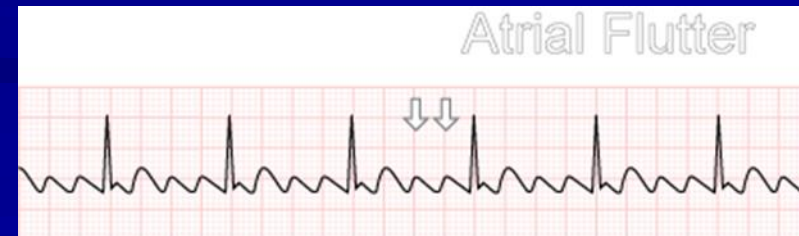
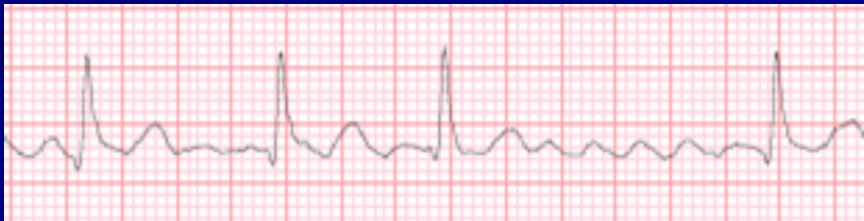
Source: Br J Cardiol © 2004 Sherbourne Gibbs, Ltd.

Regular or Irregular?

Afib vs. Aflutter

- Afib is regularly irregular meaning: Variation in R-R intervals that are not multiples of the P-P interval
- Atrial flutter has undulations (“F waves”) that are regular
- Coarse AF vs Atrial Flutter
- Typical Atrial Flutter vs Atypical Atrial Flutter

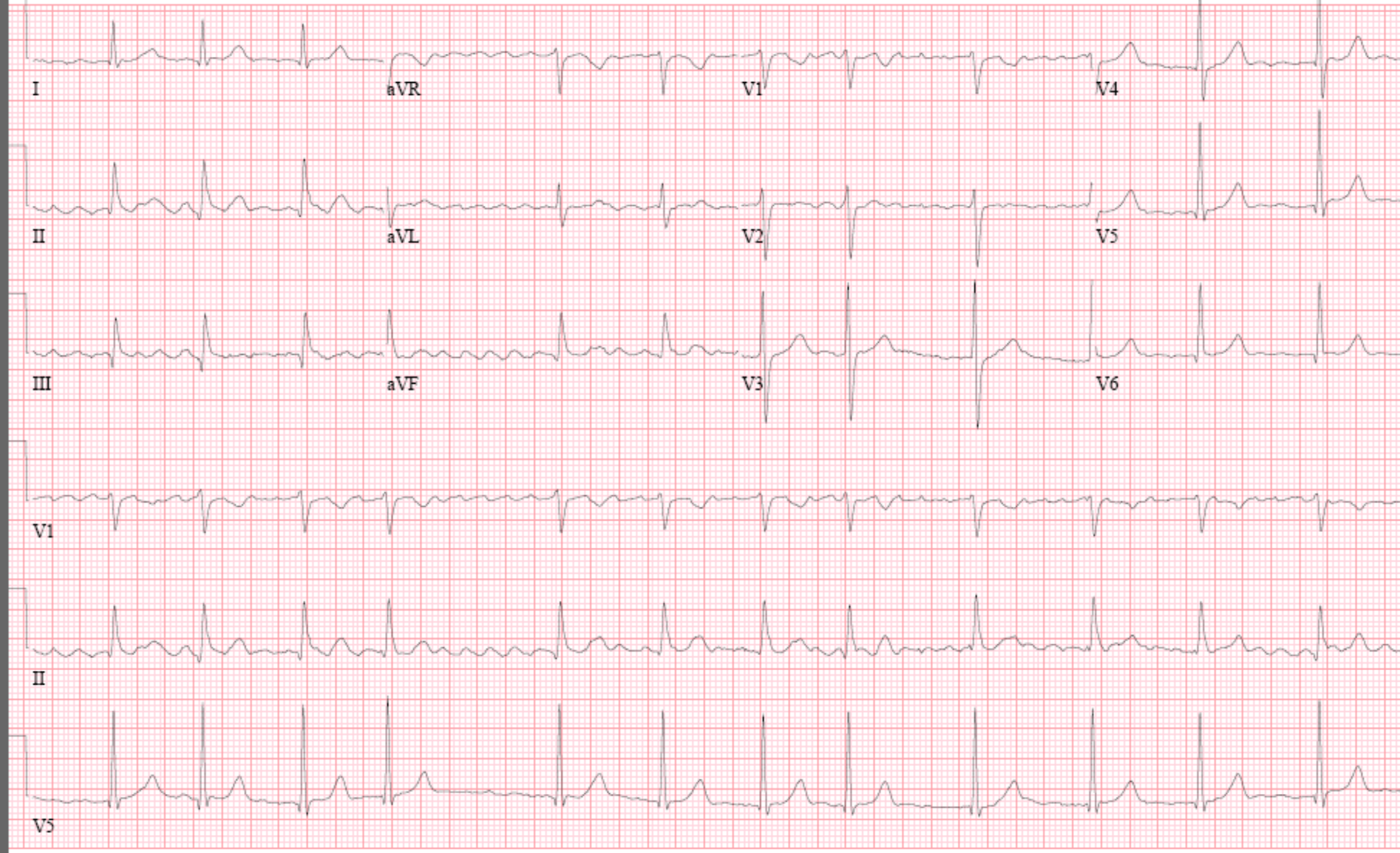


Clinic Case

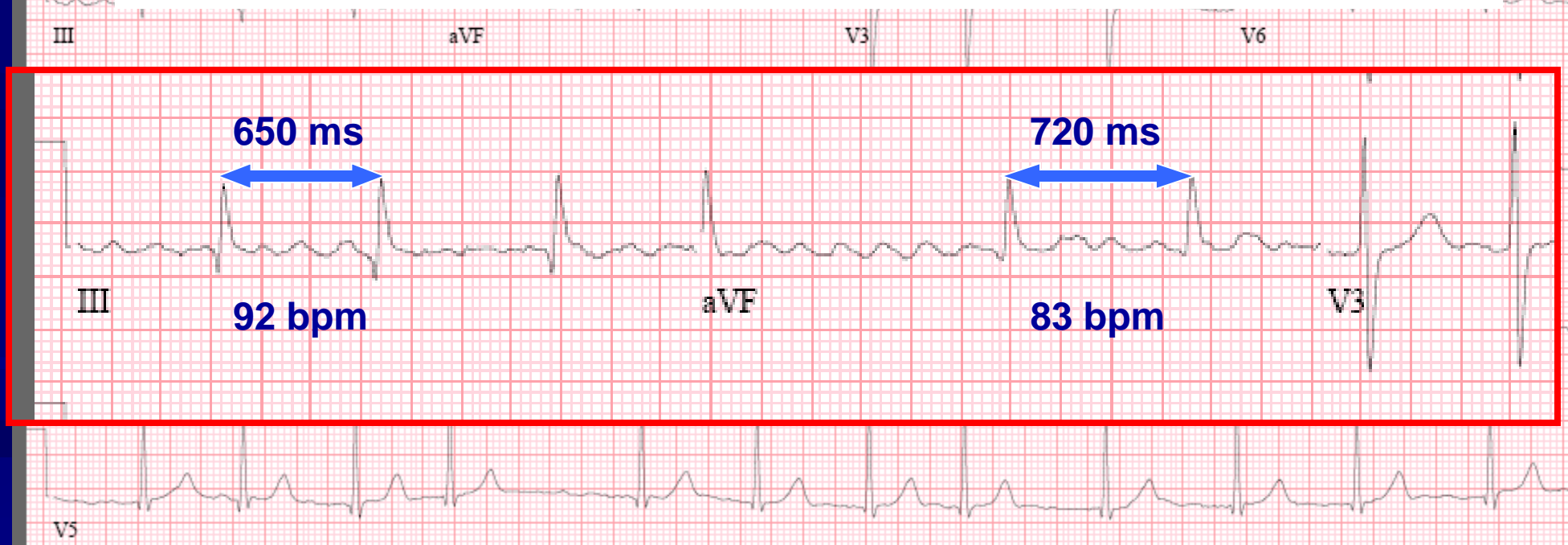
- 70 year old man
- Fatigue and weakness
- Palpitations
- No chest pain, dyspnea, syncope
- PMHx: HTN
- SHx: Tobacco, quit 1970. Prior 2ppd x10 years. 1 martini Q3 days
- FHx: none
- Metoprolol 100 mg BID
- Warfarin per Coumadin Clinic
- Levothyroxine 112 mcg daily
- Zocor 40 mg daily
- Coenzyme Q10
- Prilosec 20 mg daily

Section:

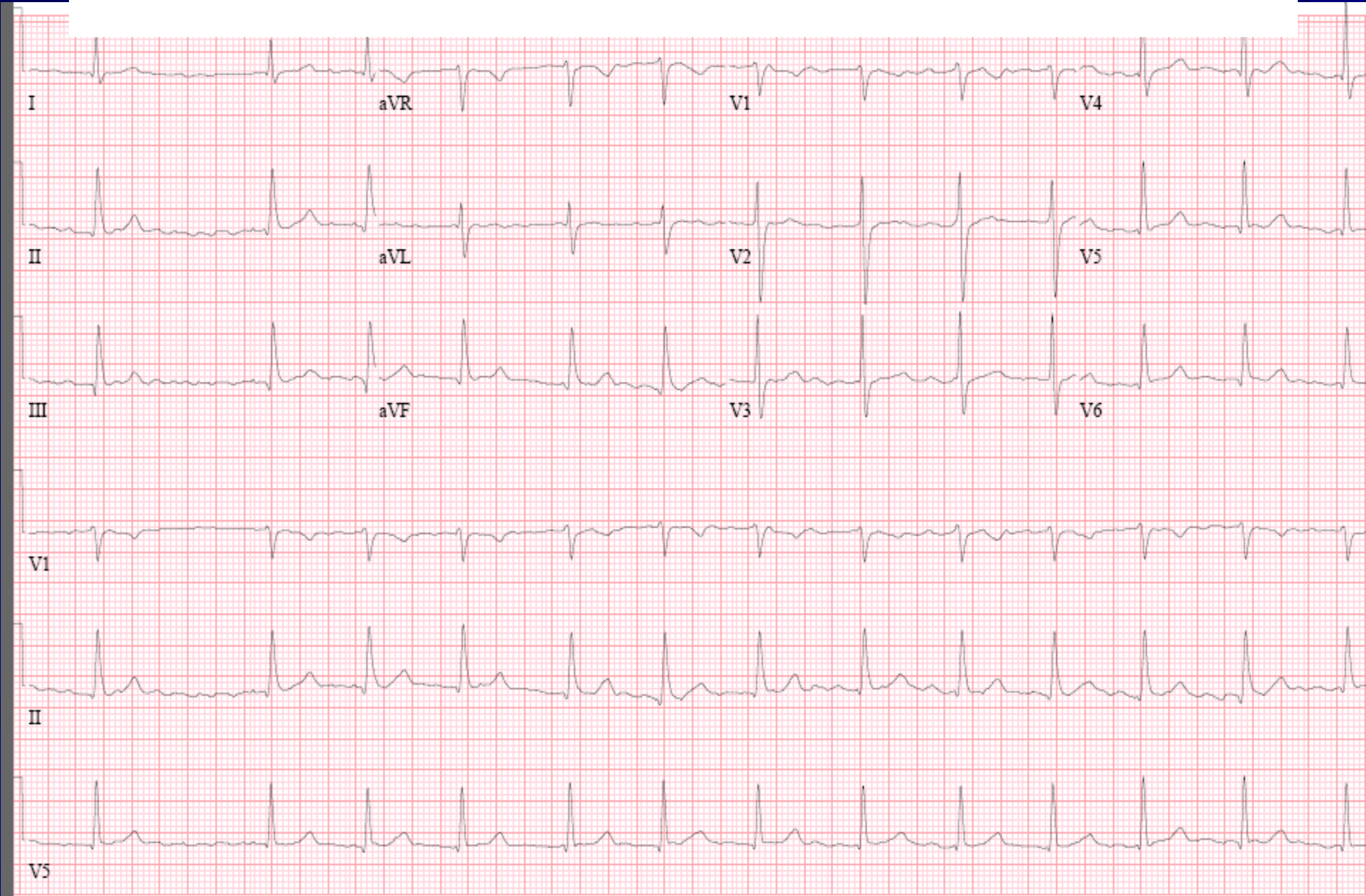
Floor:



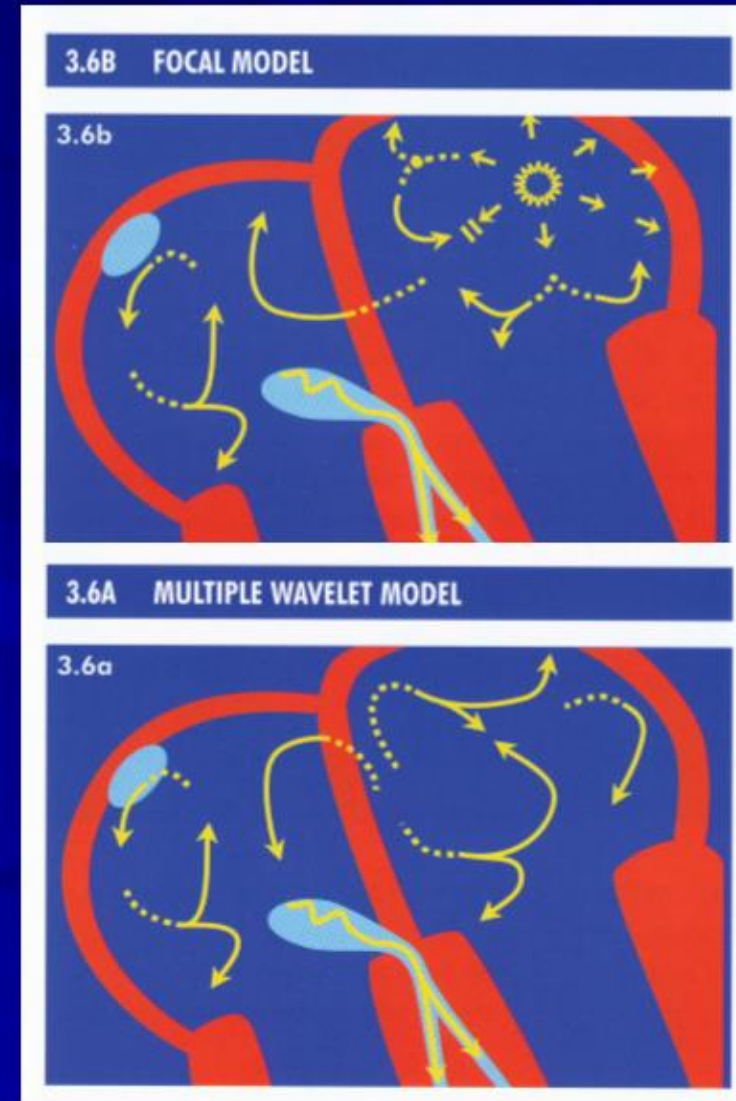
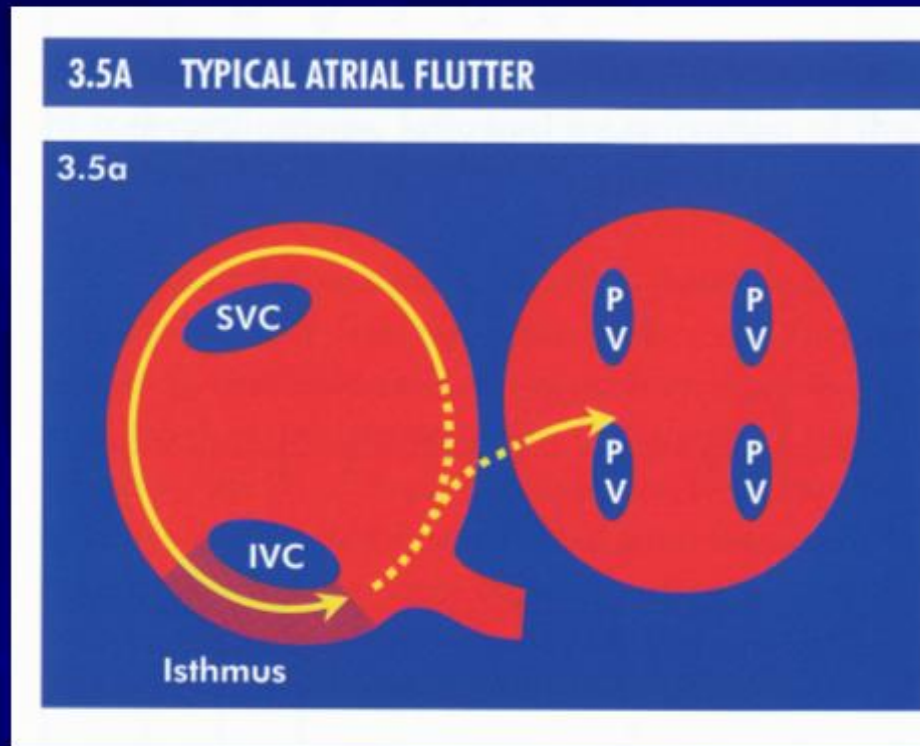
If these are both 4:1 conduction, the rate should be the same, meaning the P-P interval varies here



Another ECG



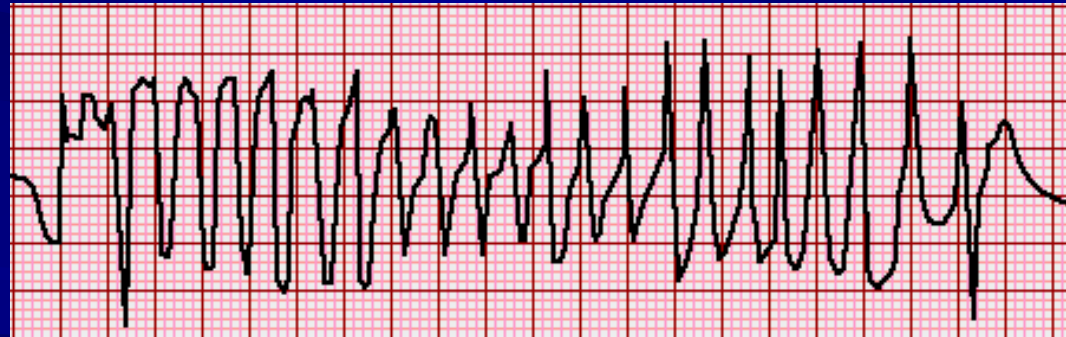
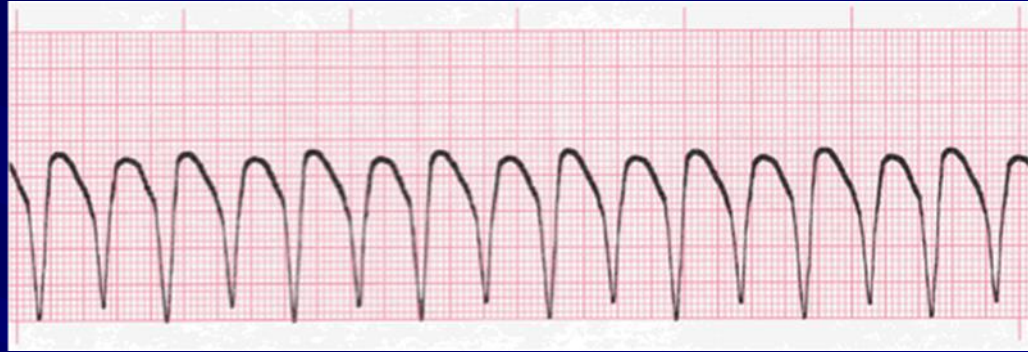
Models of Atrial Flutter and Fibrillation



Ventricular Tachycardia

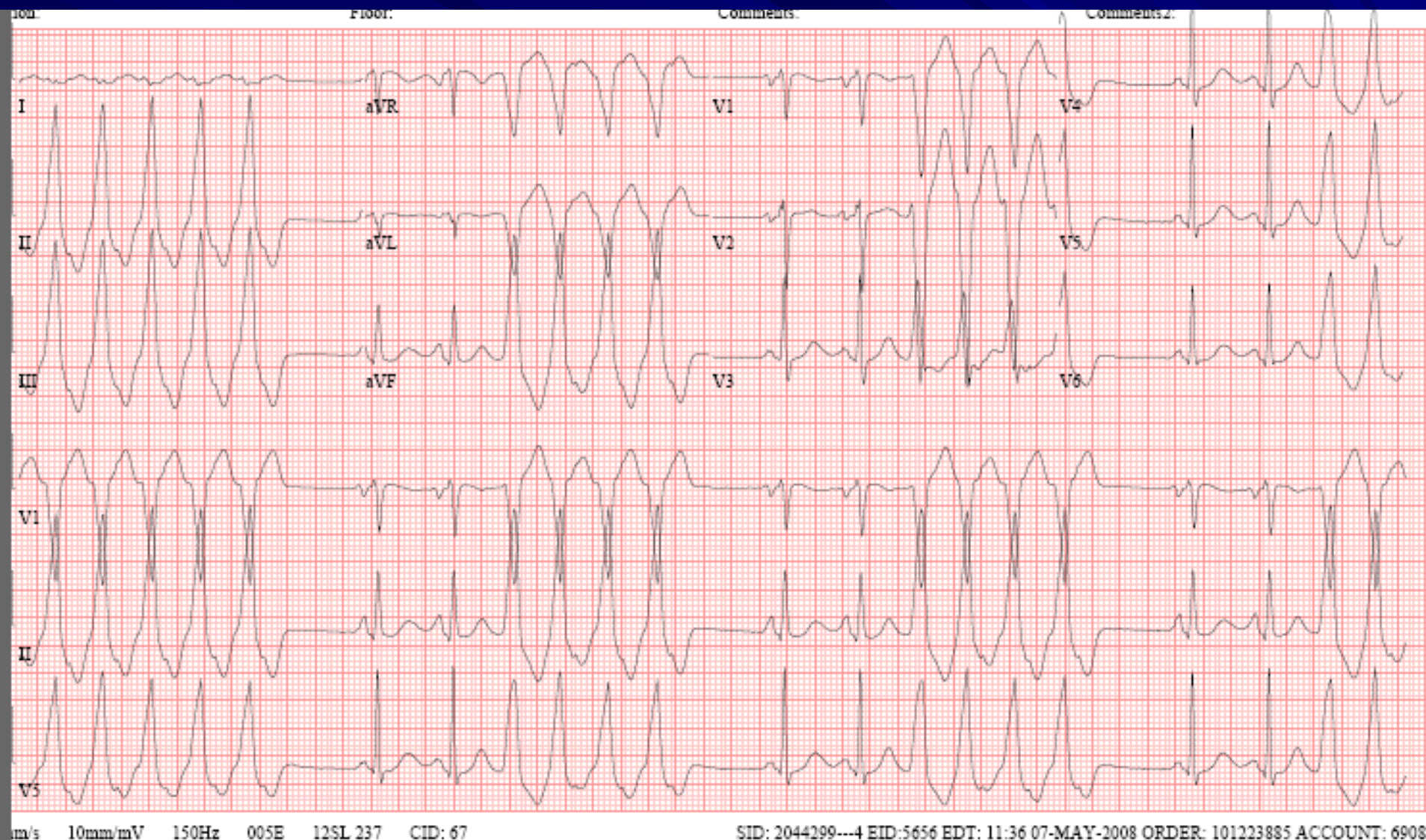- Monomorphic VT
- Polymorphic VT
- NSVT

Ventricular Tachycardia (VT)



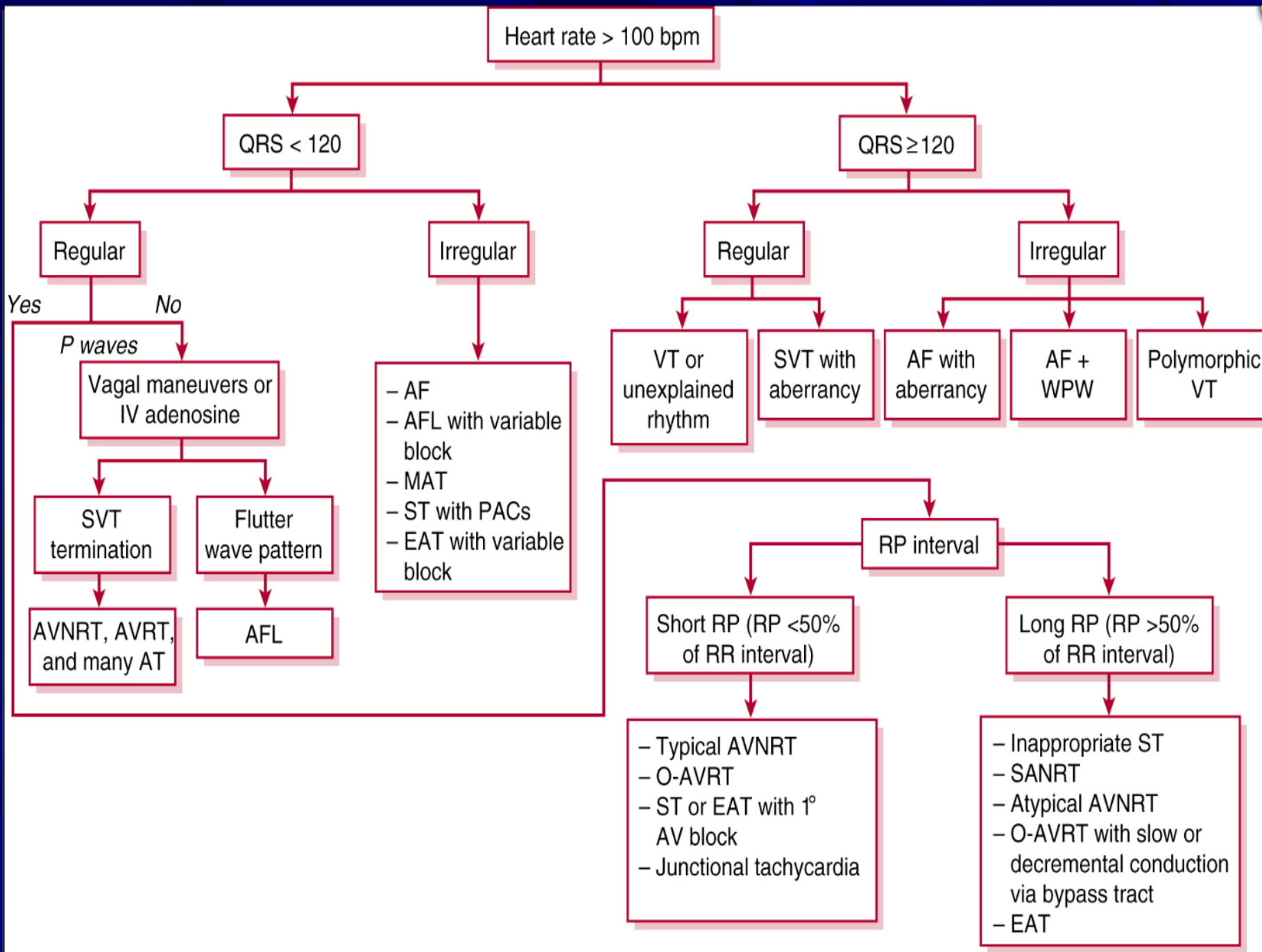
Criteria for VT

- Rapid succession of 3 or more ventricular premature complexes at ≥ 100 bpm
- RR interval is usually regular but may be irregular
- Abrupt onset and termination of arrhythmia is evident
- AV dissociation is common (P and QRS complexes at different rates)




m/s 10mm/mV 150Hz 005E 12SL 237 CID: 67

SID: 2044299---4 EID:5656 EDT: 11:36 07-MAY-2008 ORDER: 101223885 ACCOUNT: 6908

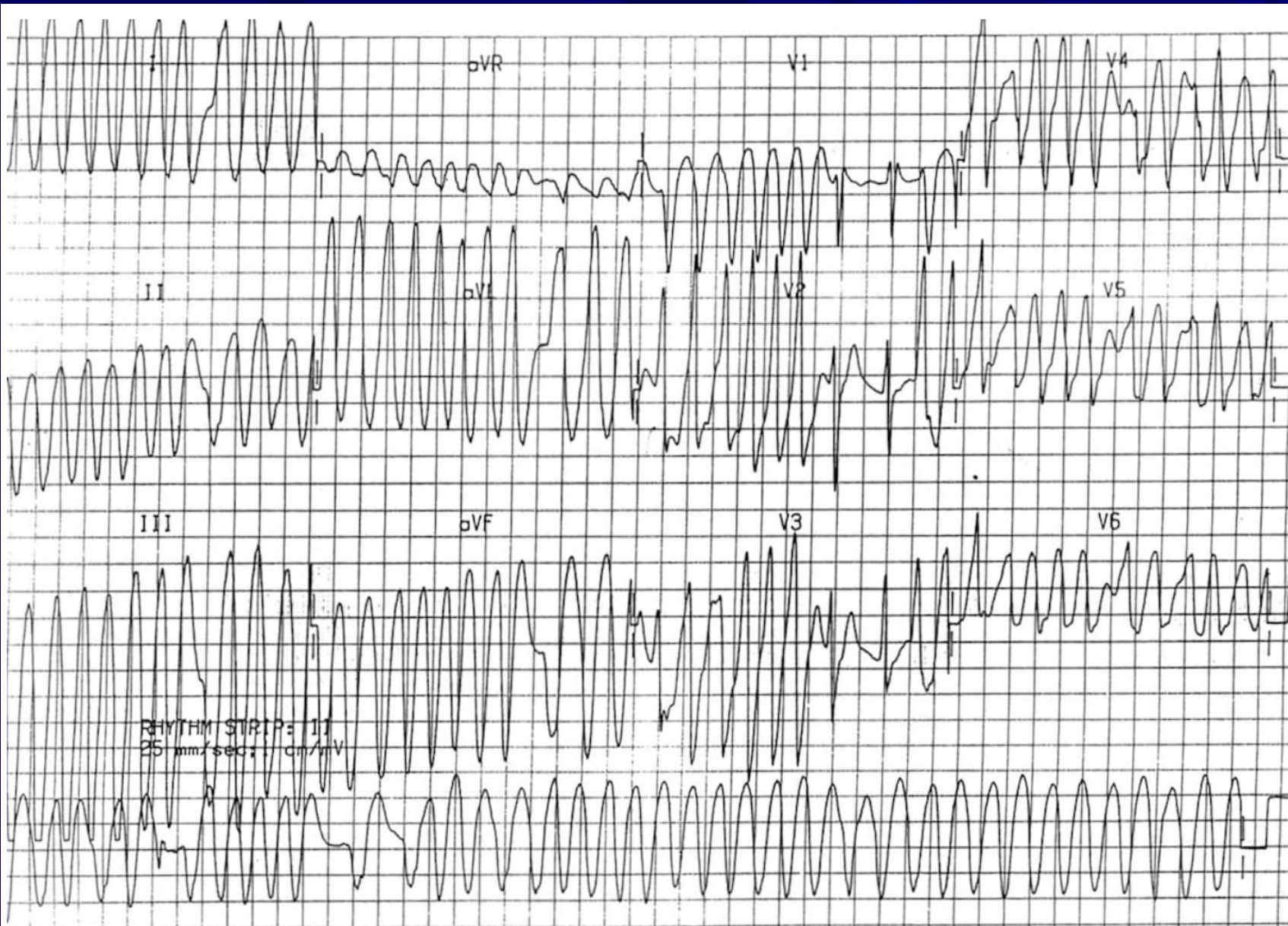

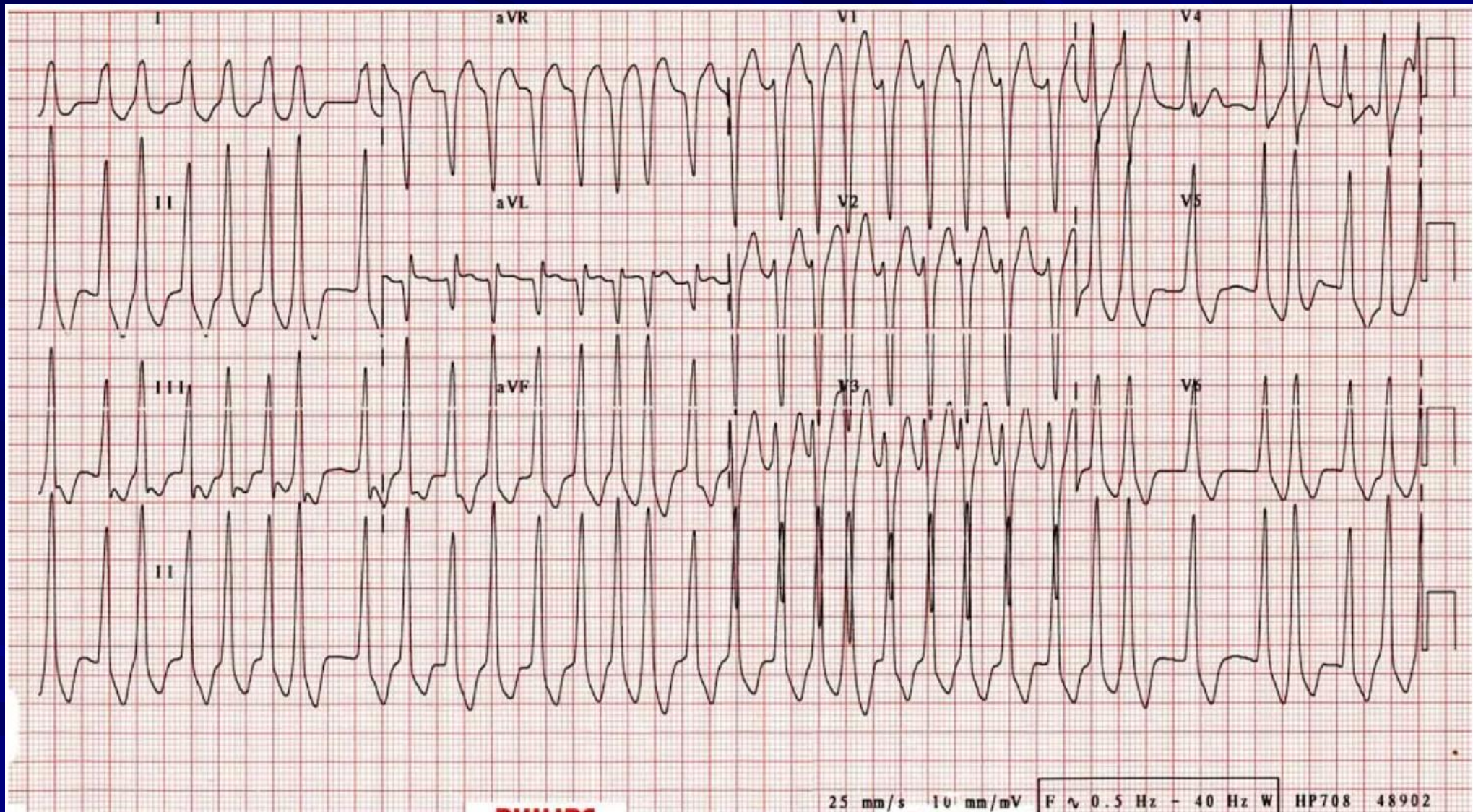
DO YOU HAVE ANY IDEA
HOW FAST YOU WERE GOING?



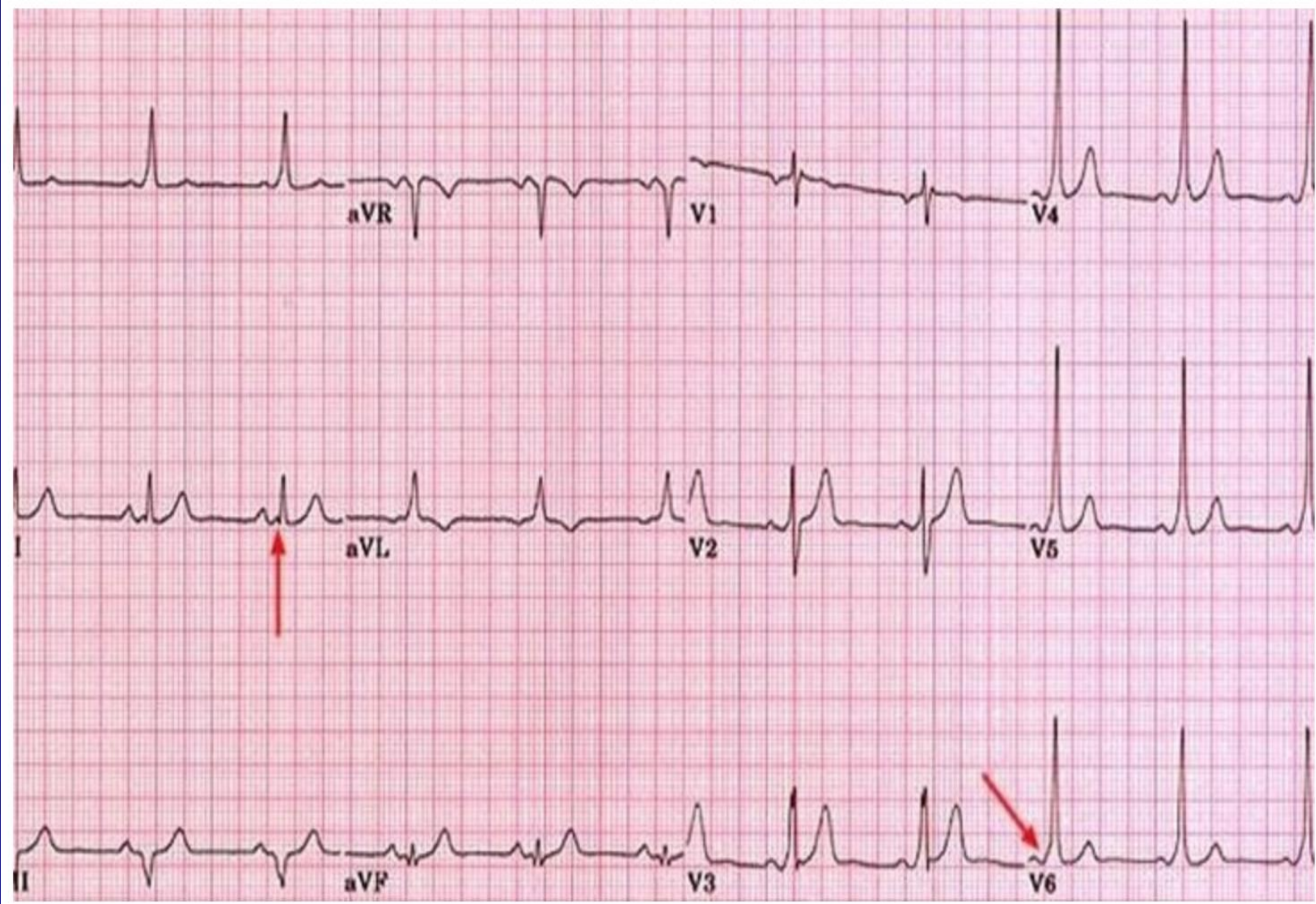
CARDIAC ARREST







25 mm/s 10 mm/mV F ~ 0.5 Hz - 40 Hz W HP708 48902



Name:

12-Lead 1

HR 199 bpm

• Abnormal ECG **Unconfirmed**

ID:

15:28:09

• Supraventricular tachycardia

Patient ID:

PR 0.090s

QRS 0.070s

• Left axis deviation

Incident:

QT/QTc

0.214s/0.389s

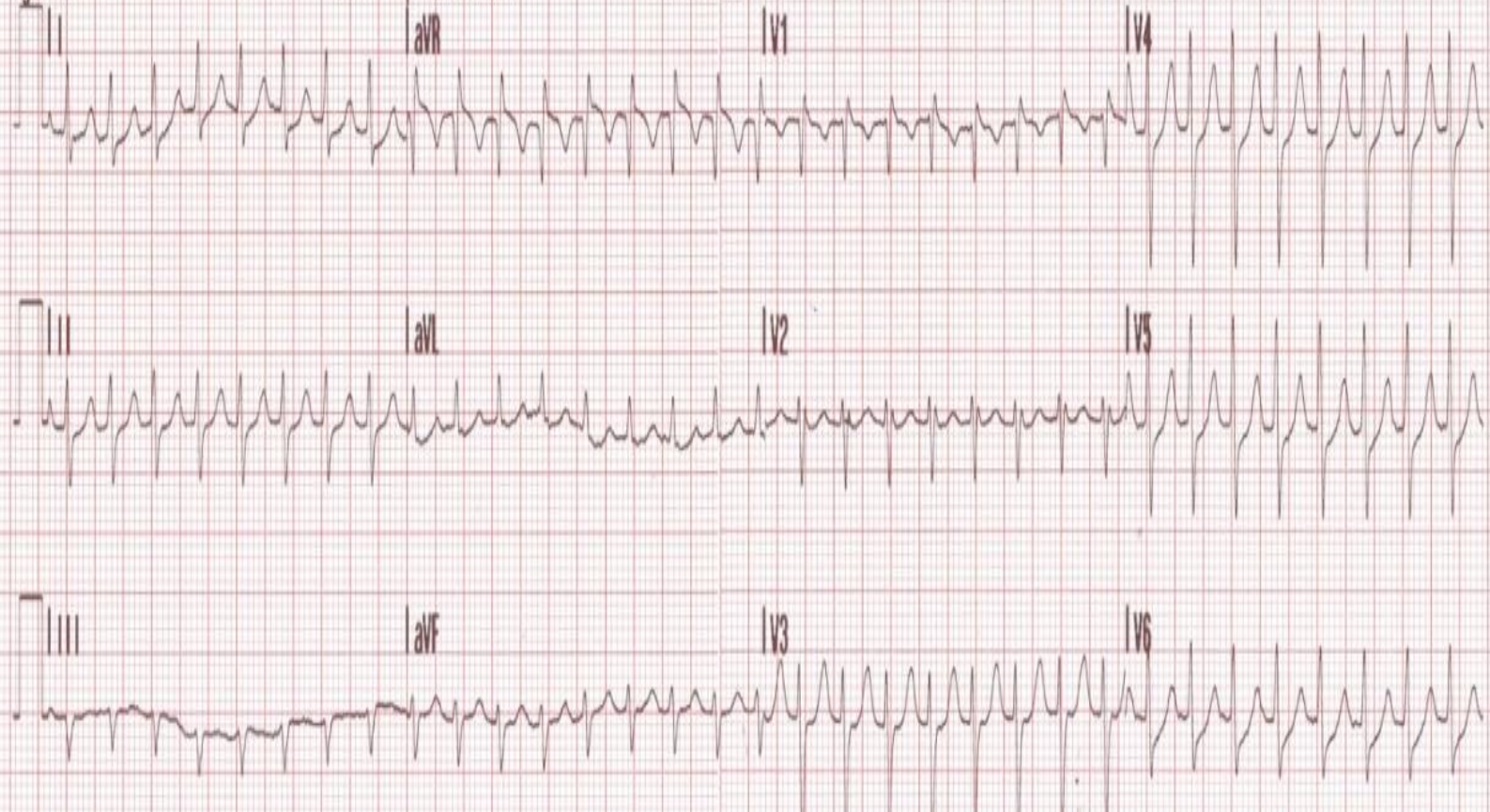
• Nonspecific ST and T wave abnormality

Age: 53

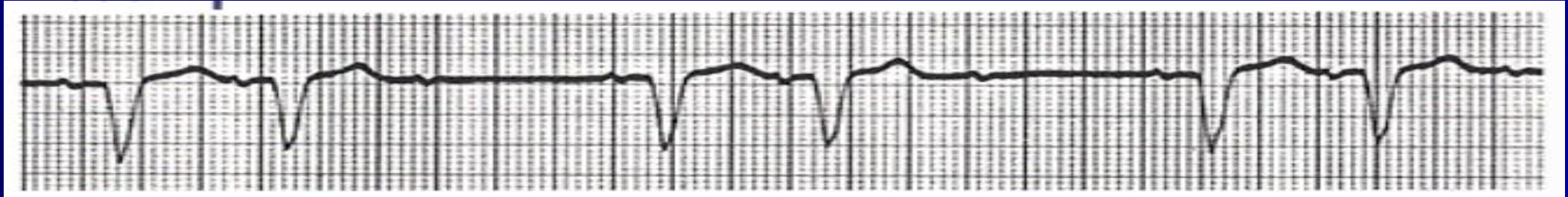
Sex:

P-QRS-T Axes

0° -31° 45°







ECG Findings in Pulmonary Embolism

#1 most common finding is...

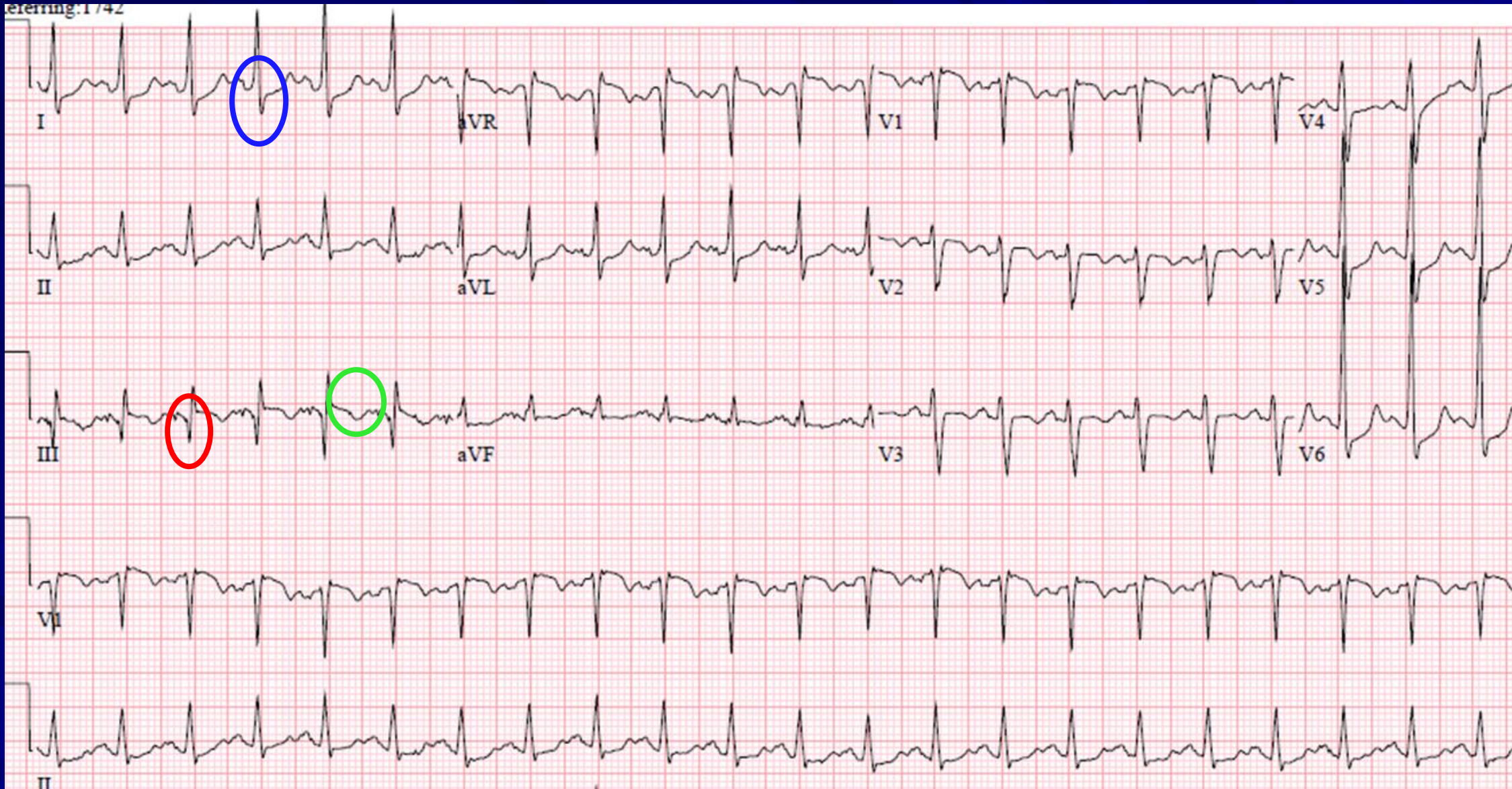
Tachycardia

S1Q3T3

- S wave in Lead 1
- Q wave in Lead 3
- T wave inversion in Lead 3

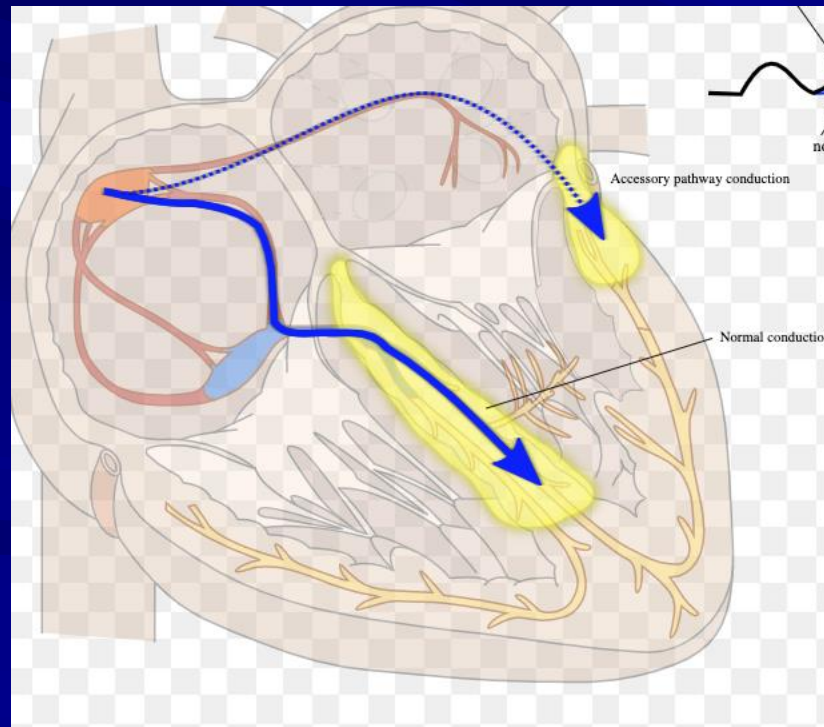
S1Q3T3

referring:1742



Wolff-Parkinson-White (WPW) Syndrome

- Pre-excitation
- The Delta wave is a slurred upstroke in the QRS complex with a short PR interval.



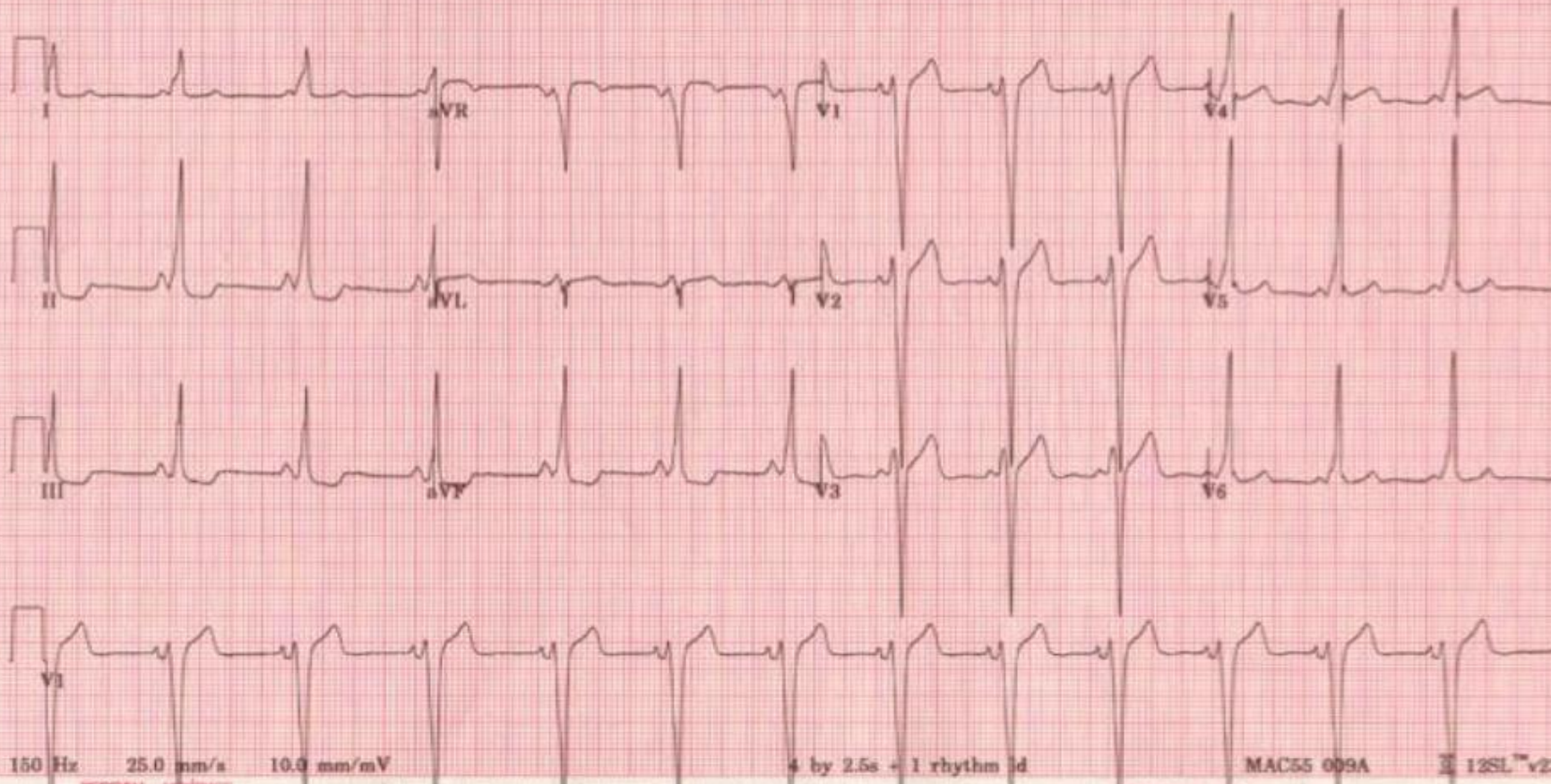
21 years
Male Caucasian
Vent. rate 80 bpm
PR interval 128 ms
QRS duration 146 ms
QT/QTc 390/449 ms
P-R-T axes 82 68 -89

Loc: 1

Technician: 5

Referred by: ELLIS, CHRIS

Unconfirmed

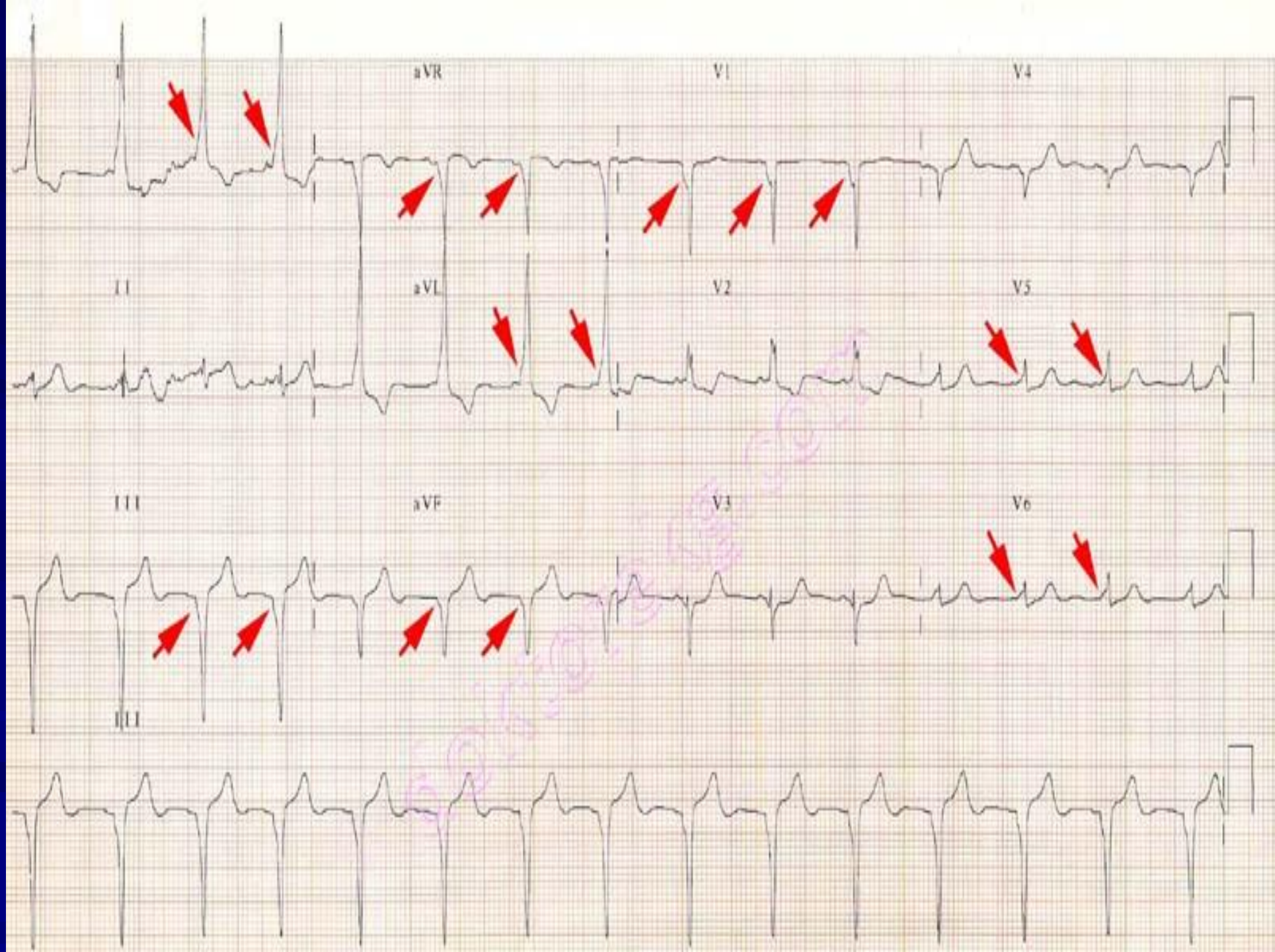


150 Hz 25.0 mm/s 10.0 mm/mV

4 by 2.5s - 1 rhythm id

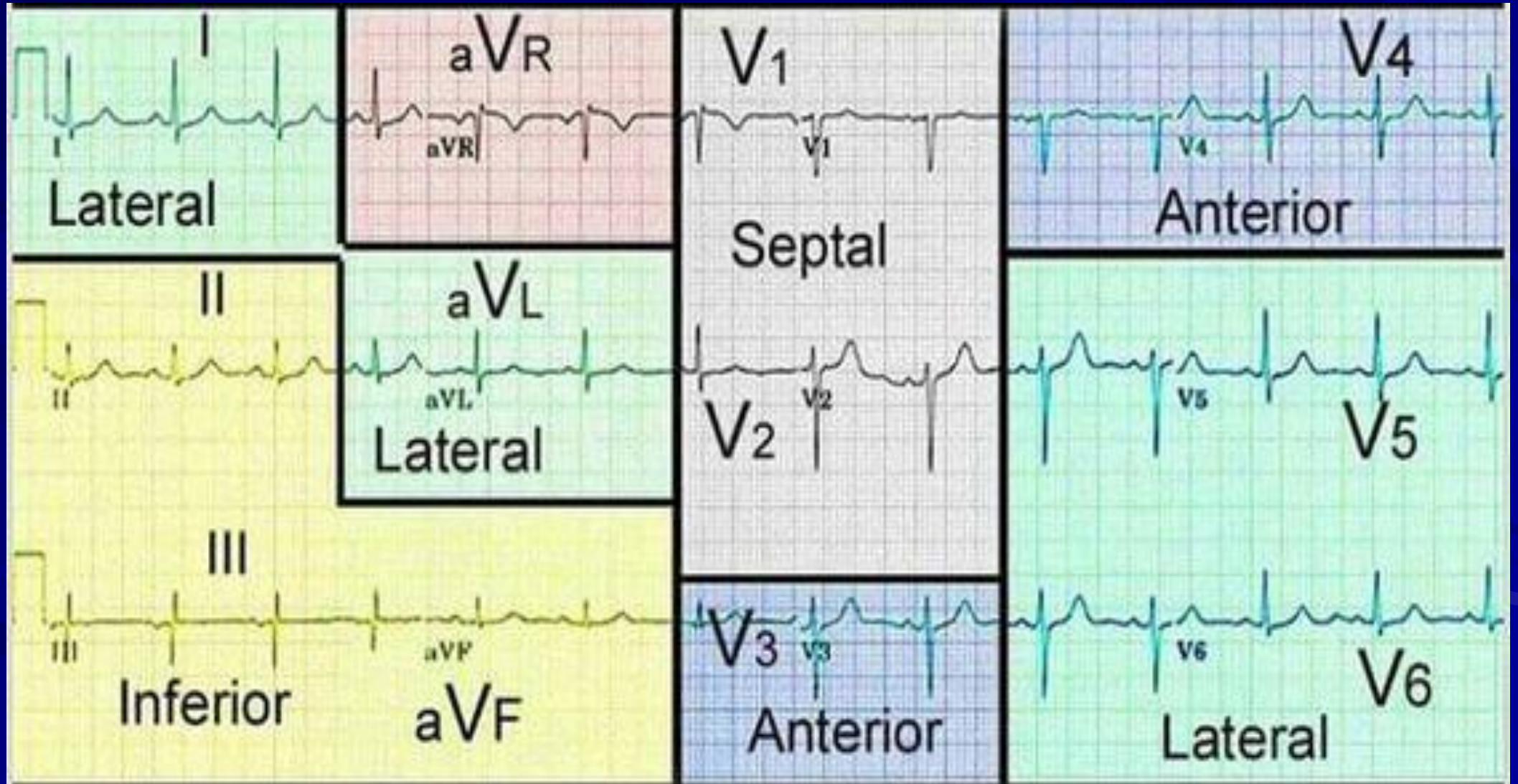
MAC55 009A

12SL™ v22

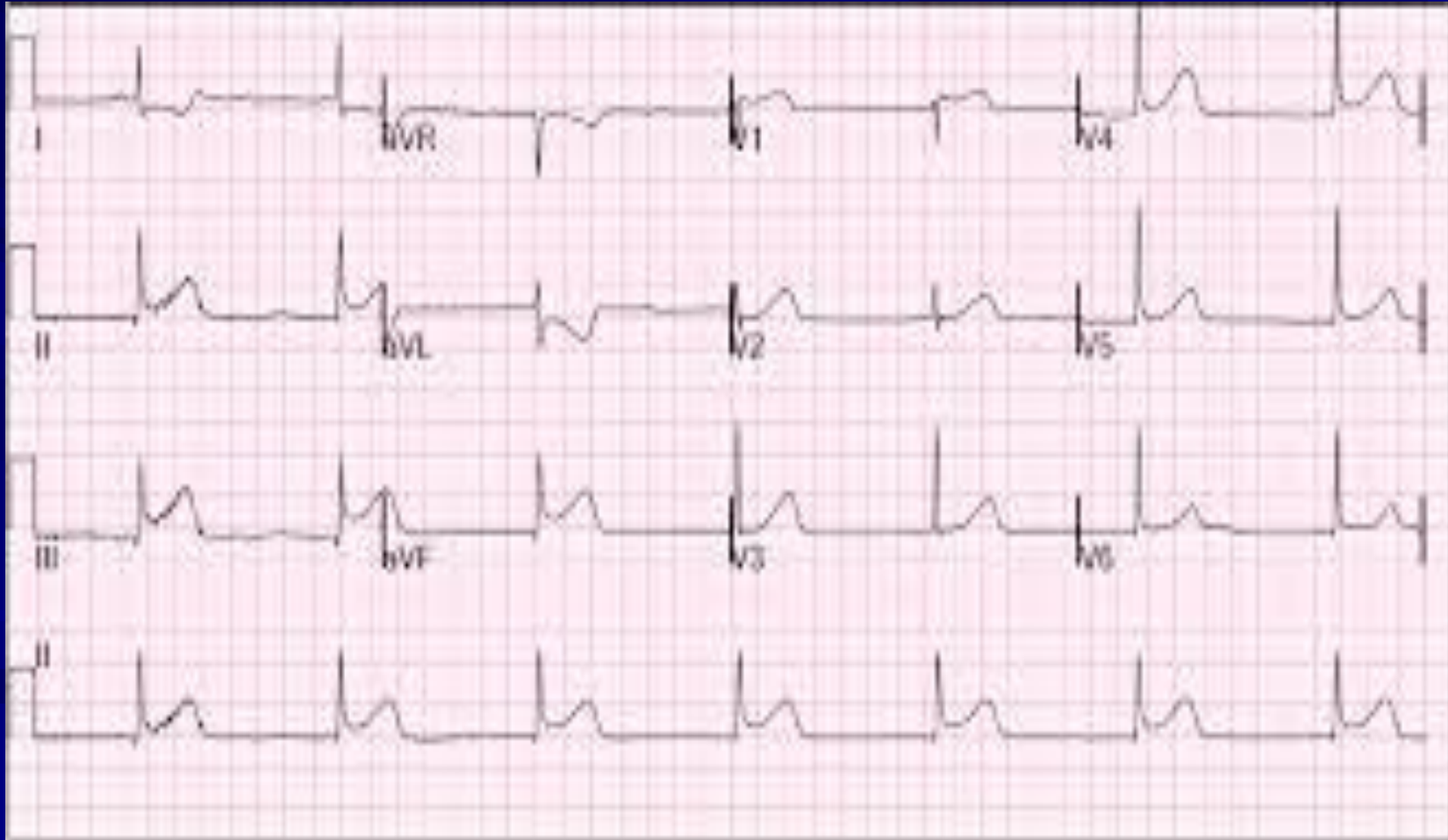


Ischemia, Injury, Infarct

STEMI Location by ECG



Where is the STEMI?



Location of Infarct (ST elevation MI)	Reciprocal changes* seen (ST depression)
Anterior (V1-V6)	Inferior leads (II, III, aVF)
Anteroseptal (V1-V2)	Inferior (II, III, aVF) or lateral leads (I, aVL, V5, V6)
Lateral (I, aVL, V5-V6)	Inferior (II, III, aVF) <i>In some cases leads V1-V2**</i>
Inferior (II, III, aVF)	Lead I and aVL <i>In some cases leads V1-V3**</i>

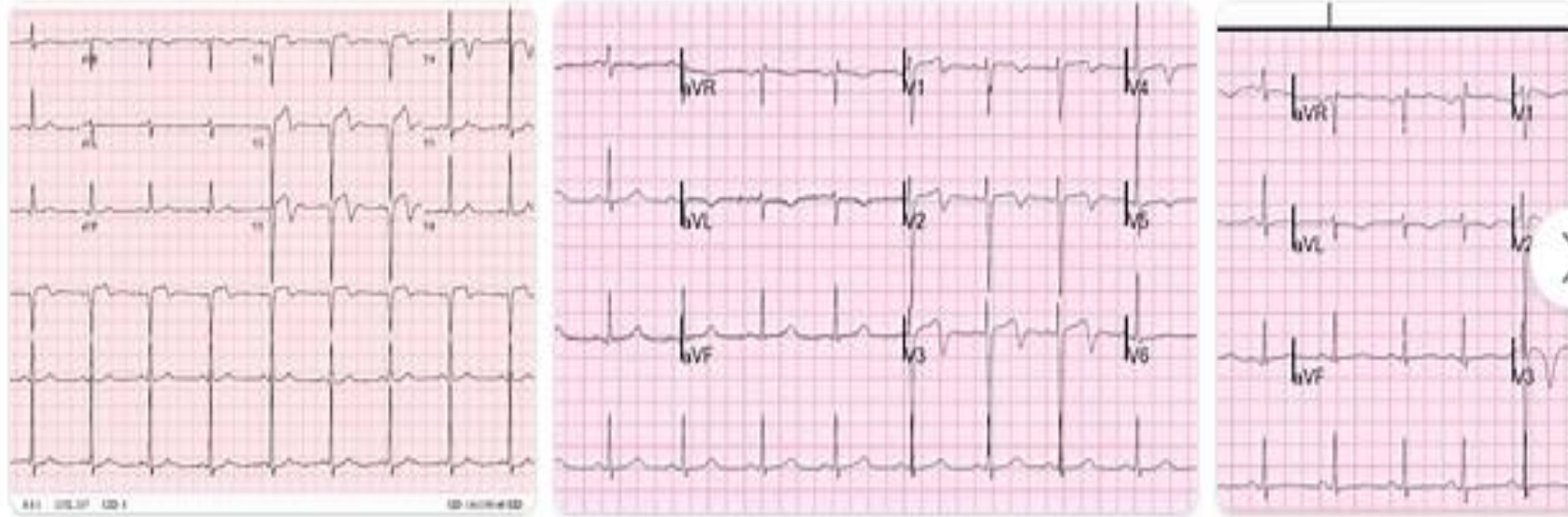
*Reciprocal changes are the same ST segment shifts as seen from a different angle or direction.

**May be reciprocal, but more likely represents posterior MI.

Posterior wall MI may be missed on typical ECG!

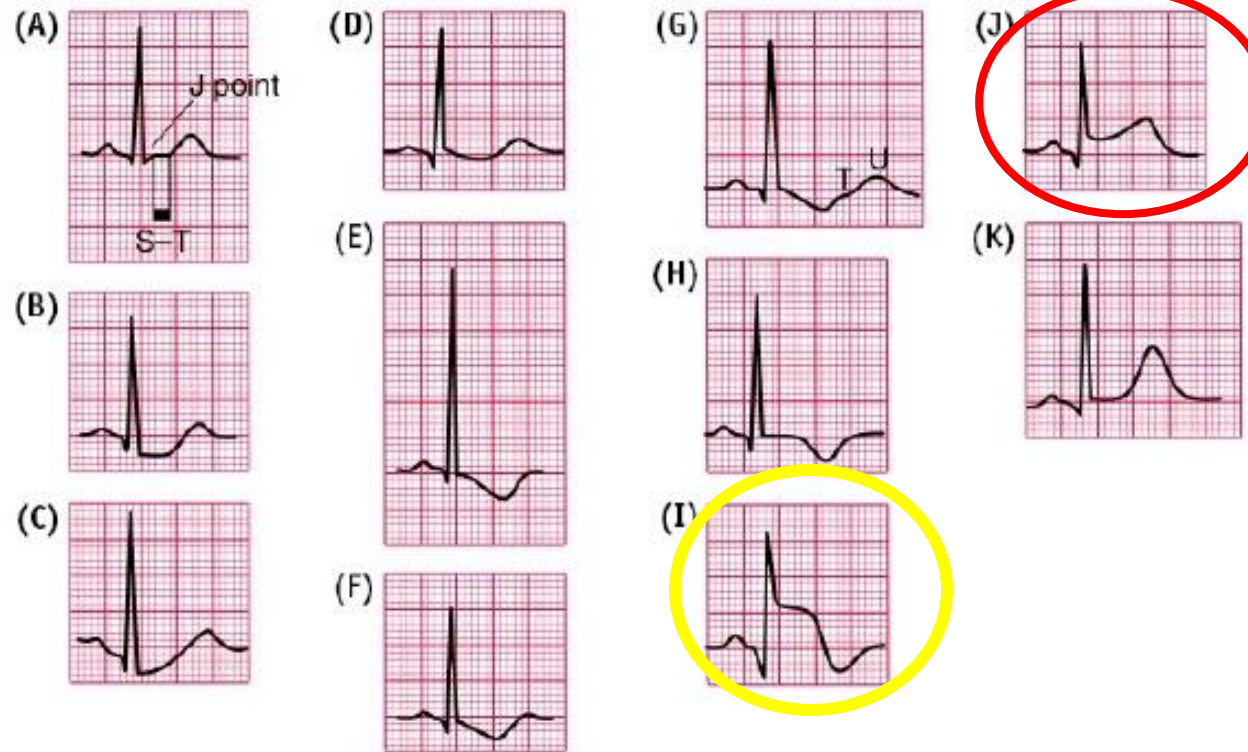
➤ **High degree of suspicion** if ST depression in V1-V3

Wellen's Sign



Wellens' ECG (sometimes referred to as Wellens syndrome or sign) is an ECG manifestation of **proximal left anterior descending stenosis** in patients with acute coronary syndrome. It is characterized by symmetrical, often deep (>2 mm), T wave inversions in the anterior precordial leads.

NORMAL AND ABNORMAL ST SEGMENTS AND T WAVES

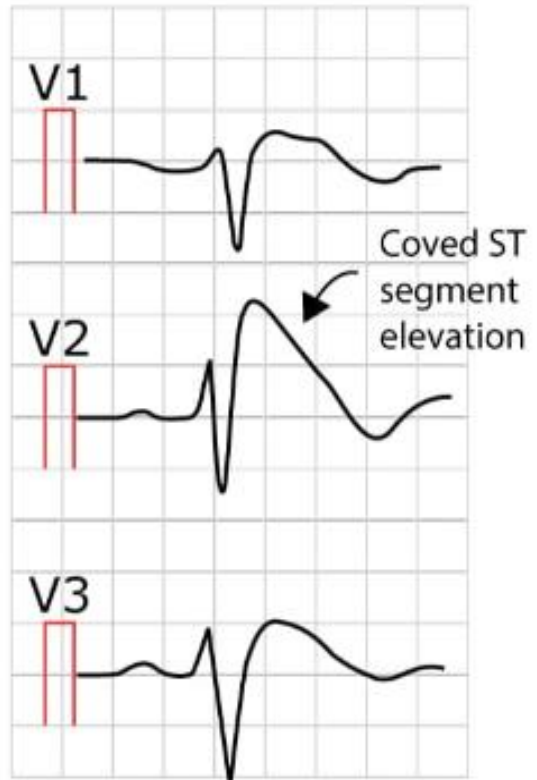


(A) Normal *ST* segment with J point. (B) Horizontal *ST* depression in myocardial ischaemia. (C) *ST* segment sloping upwards in sinus tachycardia. (D) *ST* sagging in digitalis therapy. (E) Asymmetrical *T* wave inversion associated with ventricular hypertrophy. (F) Similar pattern sometimes seen without voltage changes in hypertrophy – ‘strain’. (G) *ST* sagging and prominent *U* waves of hypokalaemia. (H) Symmetrically inverted *T* wave of myocardial ischaemia or infarction. (I) *ST* elevation in acute myocardial infarction. (J) *ST* elevation in acute pericarditis. (K) Peaked *T* wave in hyperkalaemia.

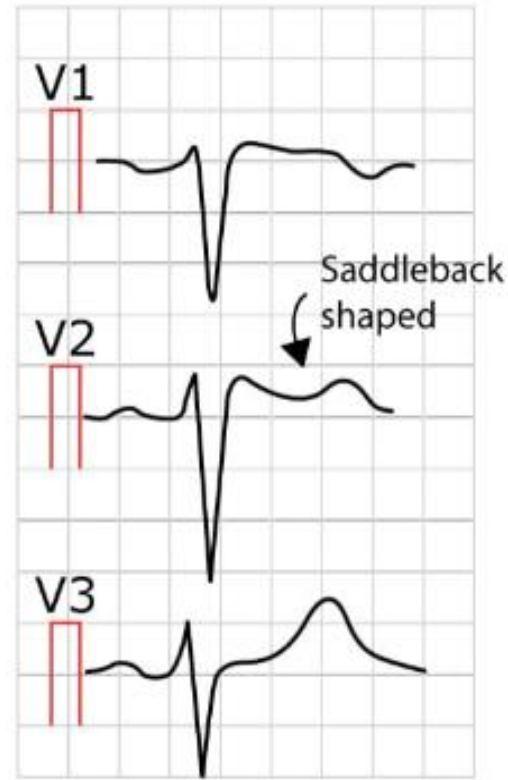
Brugada 1,2,3

The ECG in Brugada syndrome

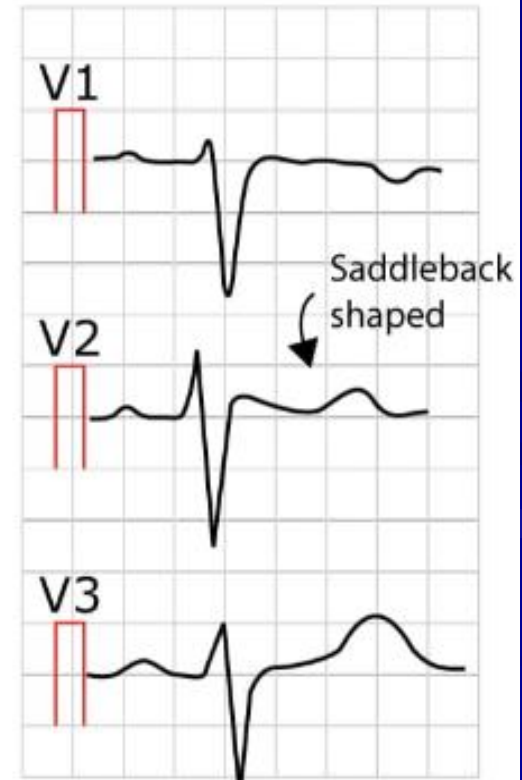
A Type 1 Brugada

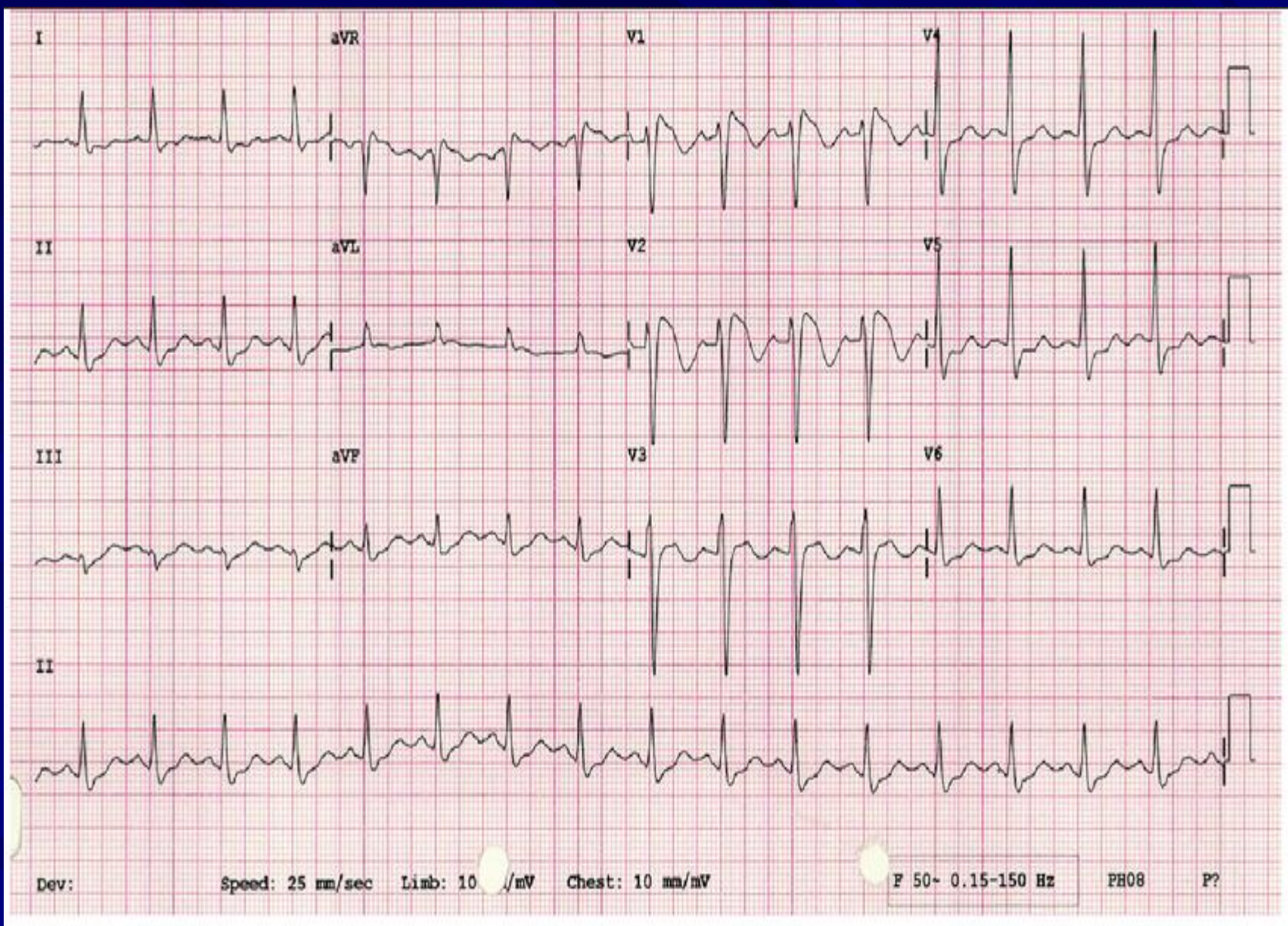


B Type 2 Brugada

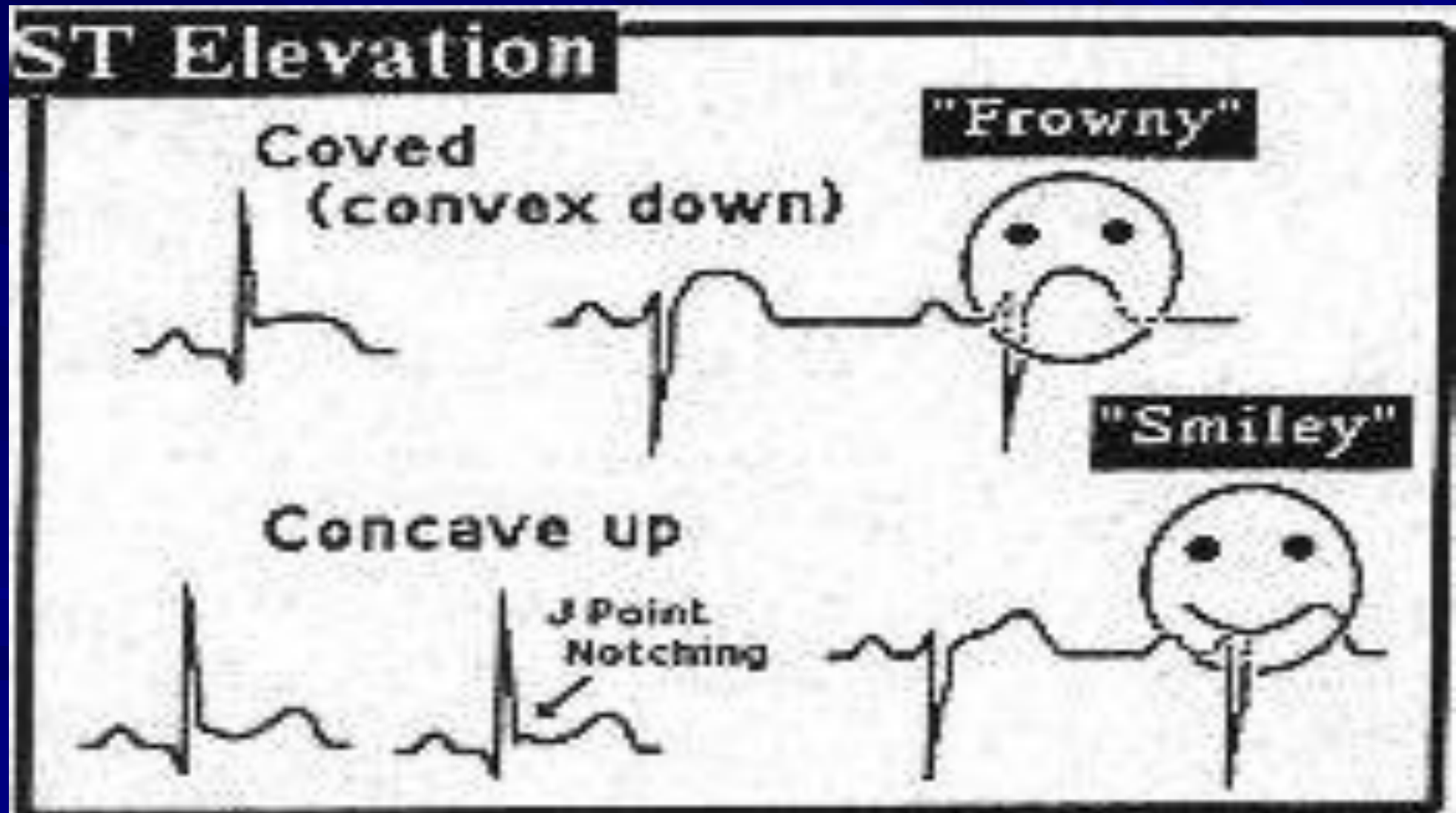


C Type 3 Brugada

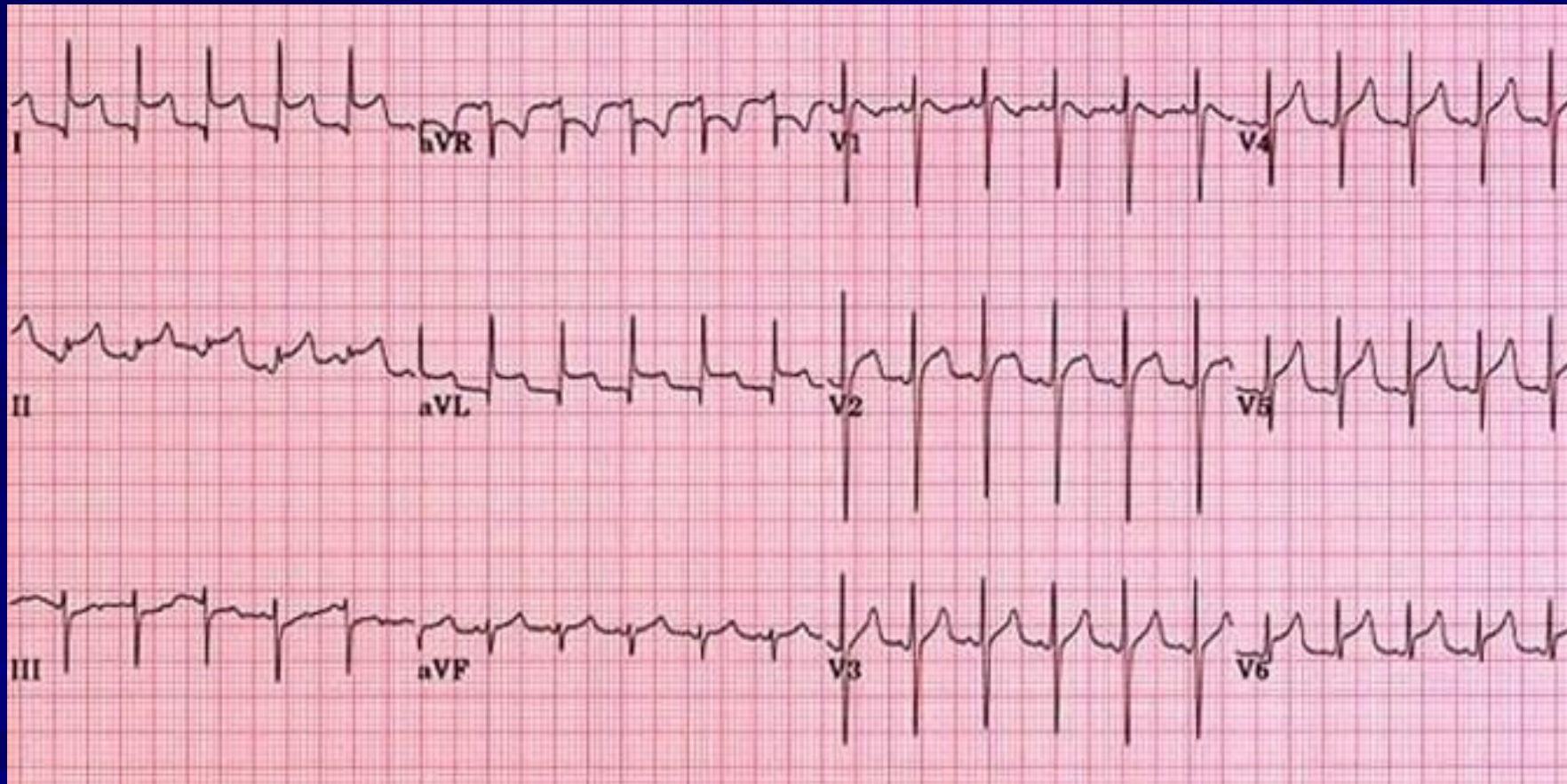




Pericarditis



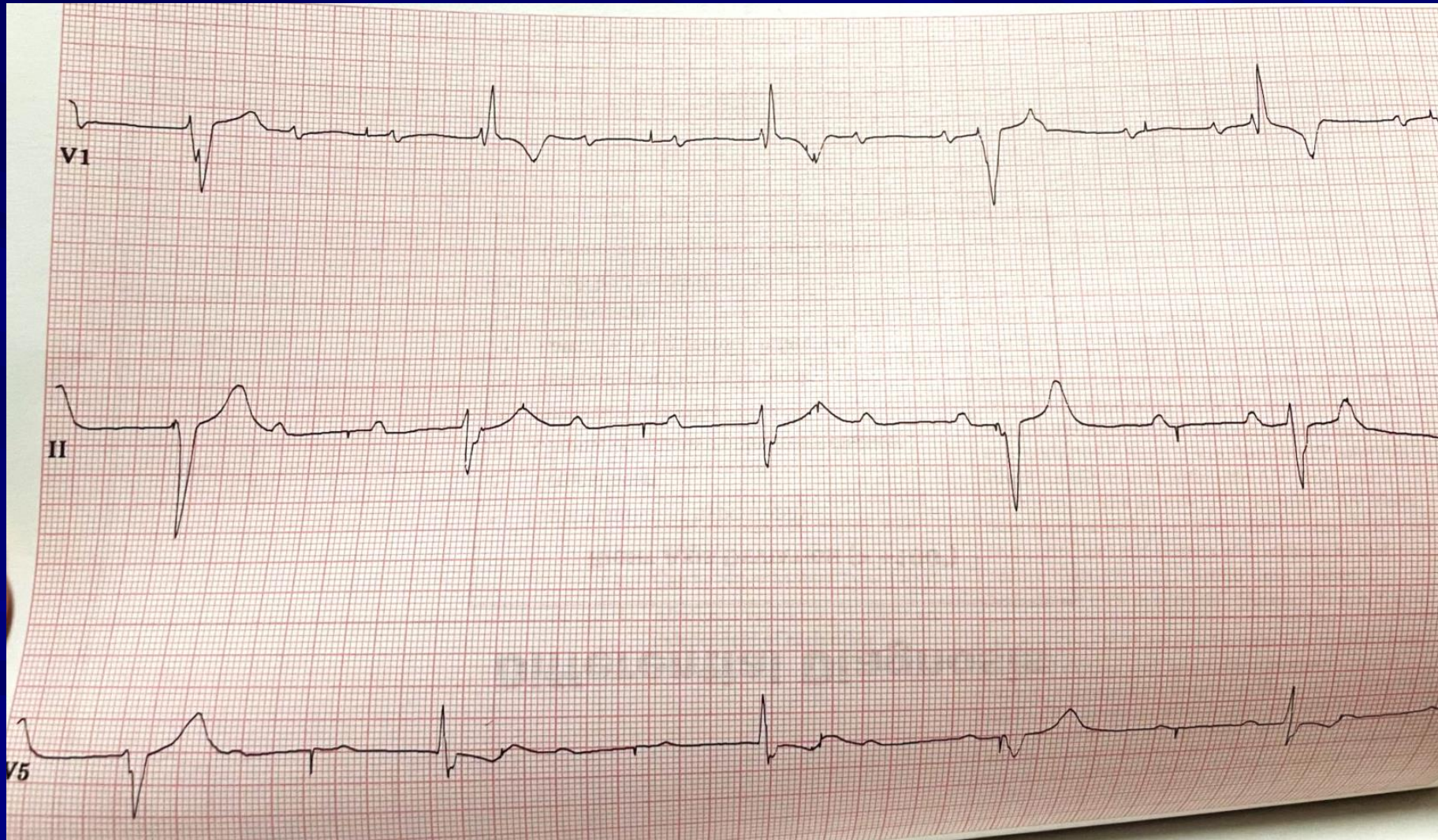
STEMI or Pericarditis?

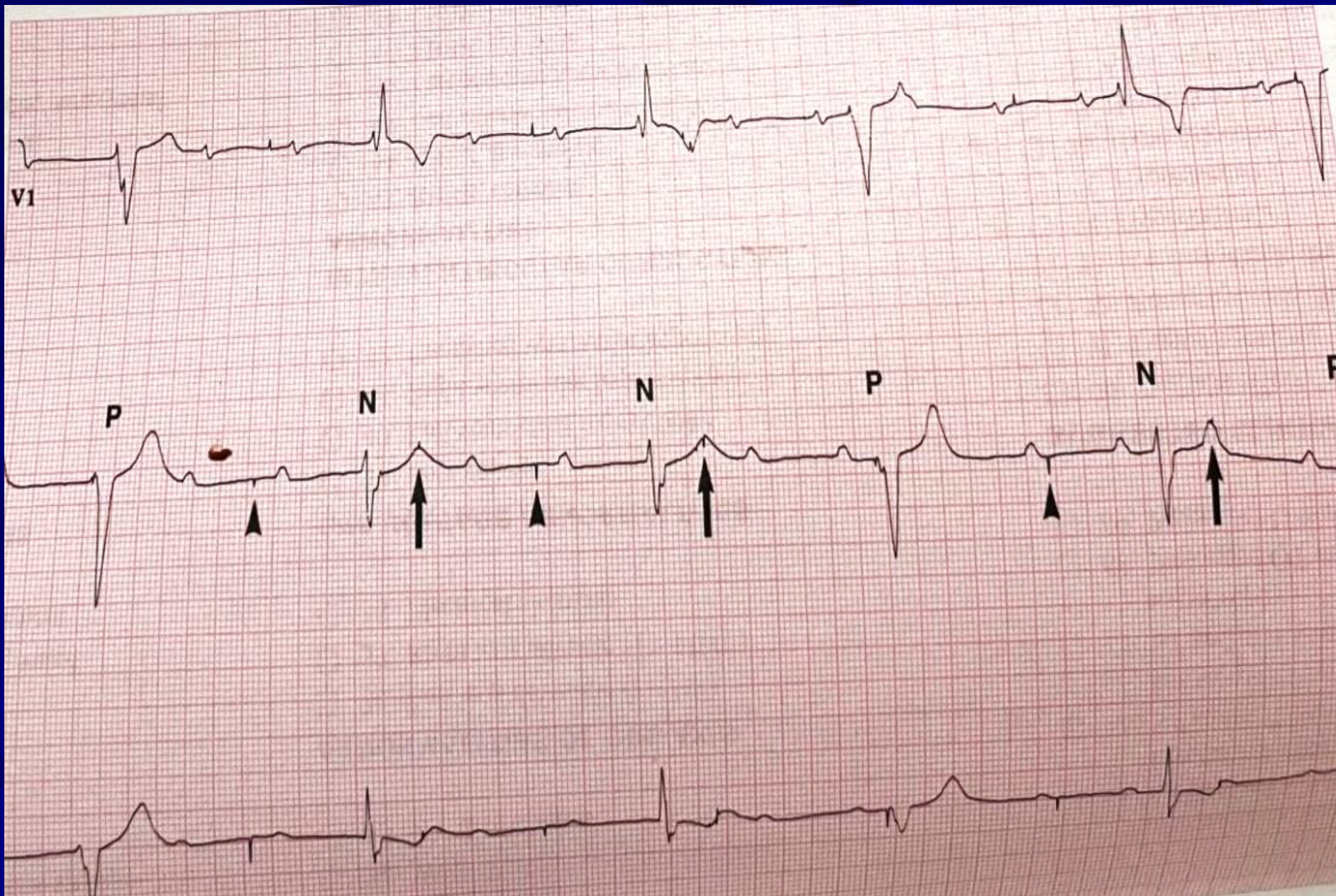


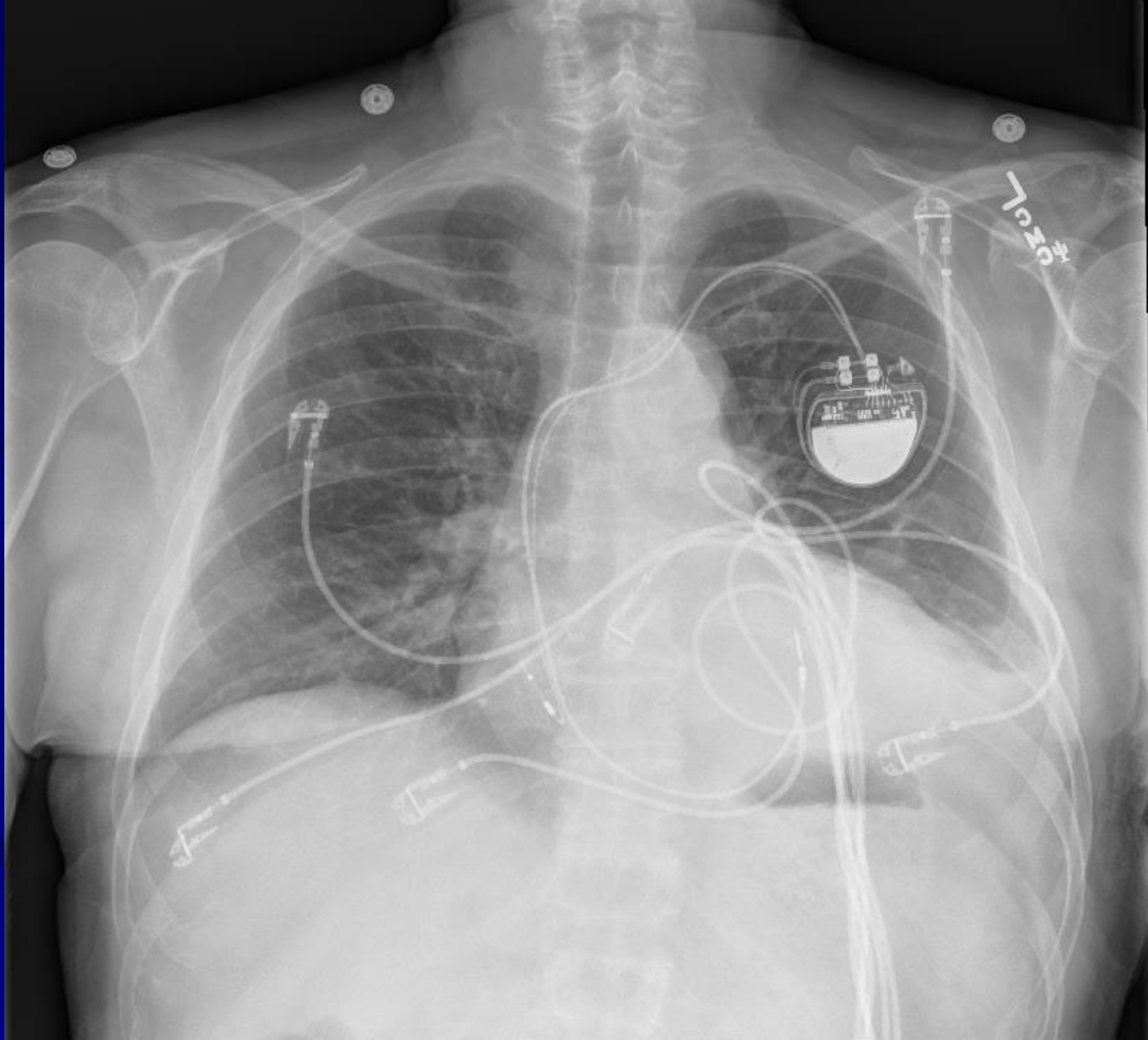
Correlate to history and clinical presentation

- Pacer spikes?
- Pt presenting symptoms & labs
- Aberrancy vs VT- Remember the basics

54 yr old F presenting with lightheadedness








Take home pearls

- Its like a free-throw; the same every time
- Rate of 150, sometimes we clinically may not be sure, yet. How do we help ourselves better understand the rhythm?
SLOW IT DOWN.
- Where are the P waves?
- Compare arrhythmia ECG with NSR ECG
(if able)



**When you feel like giving up, look at
this picture and remember just how
strong the human spirit really is.**

THE BLUE STREET JOURNAL

References

- O'Keefe, James H., et al. *The Complete Guide to ECGS: A Comprehensive Study Guide to Improve ECG Interpretation Skills*. Jones & Bartlett Learning, 2019.
- Chan TC, Vilke GM, Pollack M, Brady WJ. Electrocardiographic manifestations: pulmonary embolism. *Journal of Emergency Medicine*. 2001 Oct;21(3):263–70.
- Ullman E, Brady WJ, Perron AD, Chan T, Mattu A. Electrocardiographic manifestations of pulmonary embolism. *American Journal of Emergency Medicine*. 2001 Oct;19(6):514–9.
- Life in the Fastlane. Retrieved on July, 12, 2017 from <https://lifeinthefastlane.com/ecg-library/basics/delta-waves/>



5 ECG Practice Questions

Austin, Texas Sept 2022

Question #1

What is the most common ECG finding for Pulmonary Embolus (PE)?

- A. S1Q3T3 Sign (S wave in lead I, Q wave & inverted T wave lead III)
- B. Tachycardia
- C. Lateral T wave inversion
- D. Bradycardia

Answer: B

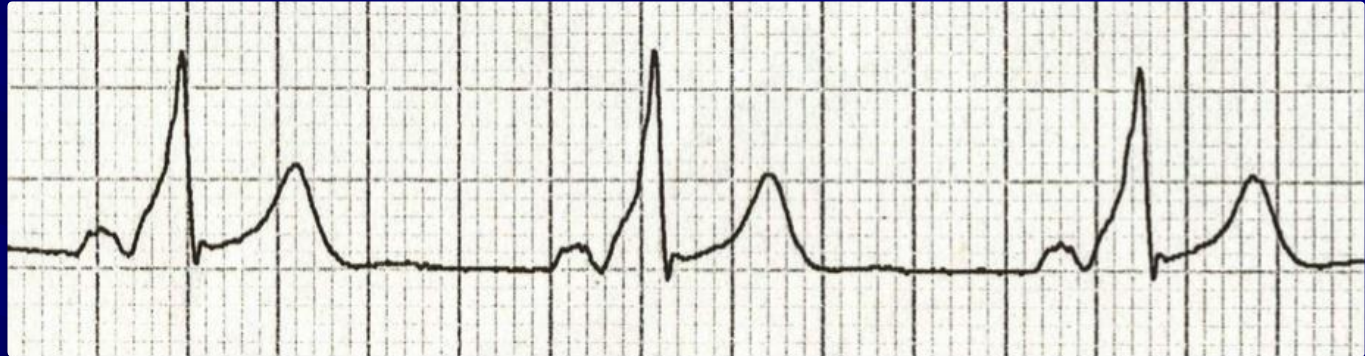- **Answer: B. Tachycardia is the most common ECG finding in PE. The S1Q3T3 is a sign of acute cor pulmonale (acute pressure and volume overload of the right ventricle because of pulmonary hypertension) and reflects right ventricular strain. However, this finding is present in 15% to 25% of patients ultimately diagnosed with PE. T wave inversion is occasionally present, but is typically anterior V1-V4.**

References

- Chan TC, Vilke GM, Pollack M, Brady WJ. Electrocardiographic manifestations: pulmonary embolism. *Journal of Emergency Medicine*. 2001 Oct;21(3):263–70.
- Ullman E, Brady WJ, Perron AD, Chan T, Mattu A. Electrocardiographic manifestations of pulmonary embolism. *American Journal of Emergency Medicine*. 2001 Oct;19(6):514–9.

Question #2:

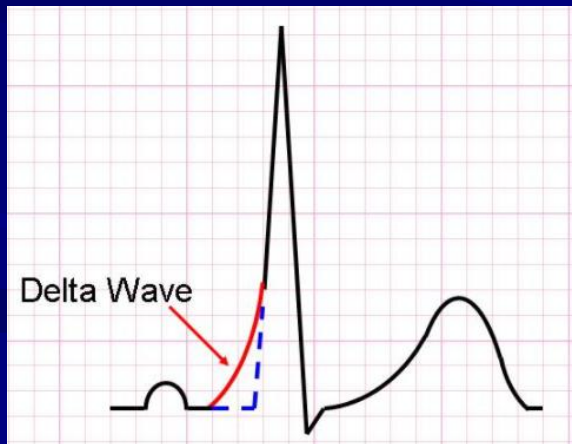
What prominent ECG finding below is characteristic of Wolff-Parkinson-White (WPW) Syndrome:



- A. Prolonged QT Interval
- B. Delta Wave
- C. Long PR interval
- D. Peaked T waves

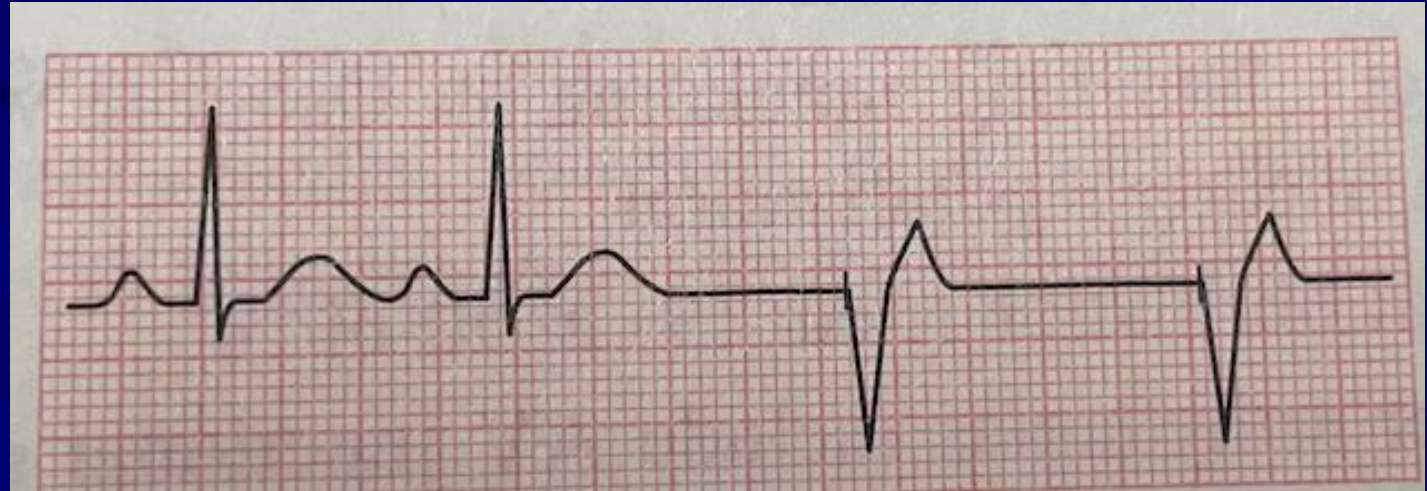Answer: B

- **Answer: B. The Delta wave is a slurred upstroke in the QRS complex often associated with a short PR interval. It is most commonly associated with pre-excitation syndrome such as WPW. The other common findings are Short PR Interval and a broad QRS.**



Question #3

What sense
can you
make of this
ECG



- Ventricular demand pacing, oversensing
- Ventricular demand pacing, normal function
- Ventricular demand pacing, under sensing
- Ventricular demand pacing, lead fractured

Answer: B

- **Answer: B Ventricular demand pacing, normal function.** Pacemaker stimulus followed by a QRS complex of different morphology than intrinsic QRS. A VVI pacemaker senses and paces only in the ventricle and is oblivious to native atrial activity. Appropriately sensed ventricular activity resets pacemaker timing clock. After an interval of time with no sensed ventricular activity, a ventricular paced beat is delivered and a new cycle begins. A spontaneous QRS arising before the end of the V-V interval is sensed and the ventricular output of the pacemaker is inhibited. A new timing cycle begins.
- O'Keefe, James H., et al. *The Complete Guide to ECGS: A Comprehensive Study Guide to Improve ECG Interpretation Skills.* Jones & Bartlett Learning, 2019.

Question #4

Pt is a 65 year old male with known coronary artery disease s/p PCI to LAD, ischemic cardiomyopathy s/p dual chamber ICD placement and paroxysmal atrial fibrillation. APP noticed an increase in atrial fibrillation burden from 1% to 30% with last ICD interrogation. Pt presents as a direct admit for Tikosyn loading. Why does the patient need to be monitored in the hospital for the first 5 doses of Tikosyn?

- QRS monitoring; risk of polymorphic ventricular tachycardia
- QRS monitoring; risk of monomorphic ventricular tachycardia
- QTc monitoring; risk of polymorphic ventricular tachycardia
- QTc monitoring; risk of monomorphic ventricular tachycardia

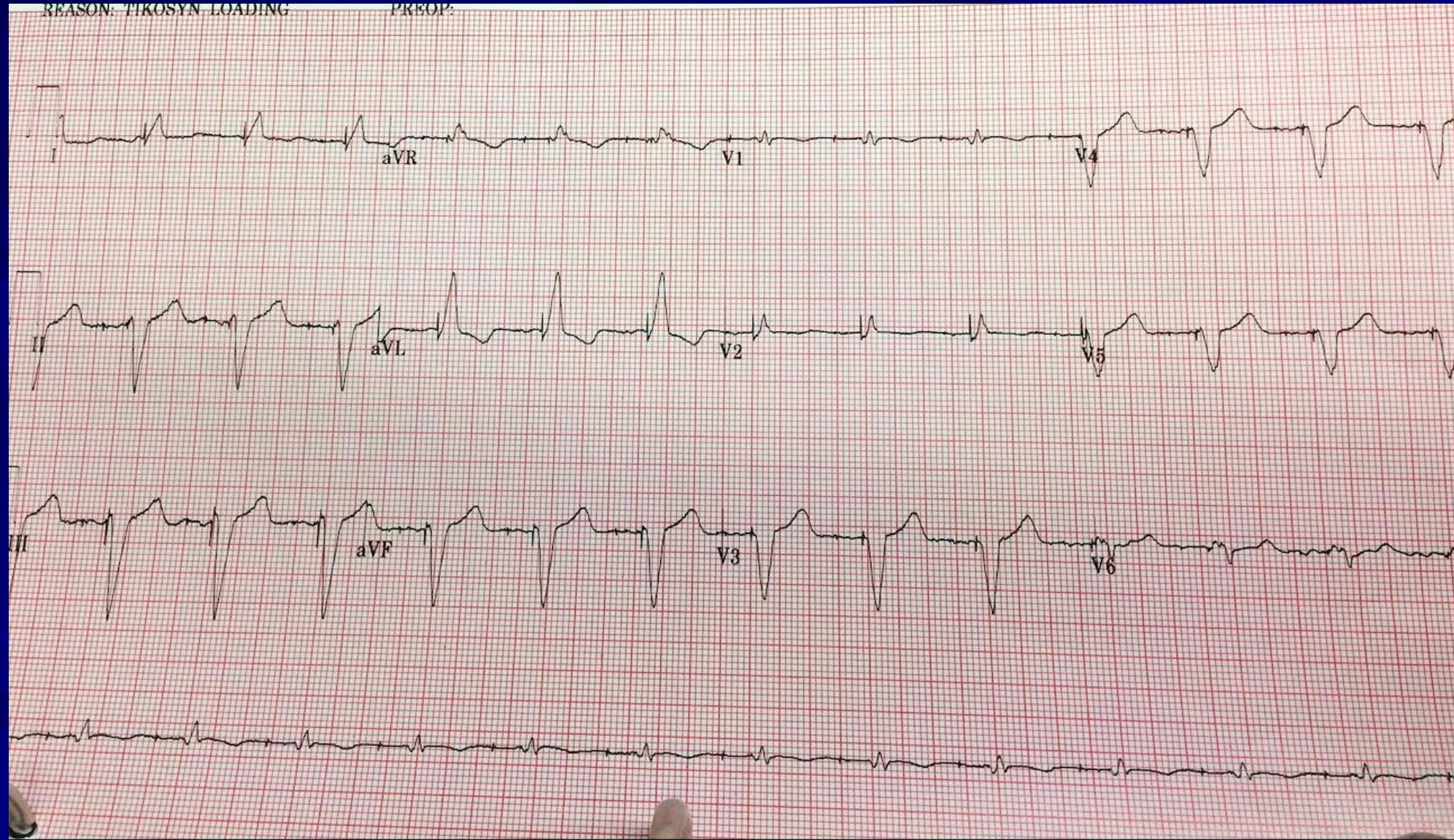
Answer: C

■ **Answer: C**

QTc monitoring; risk of polymorphic ventricular tachycardia

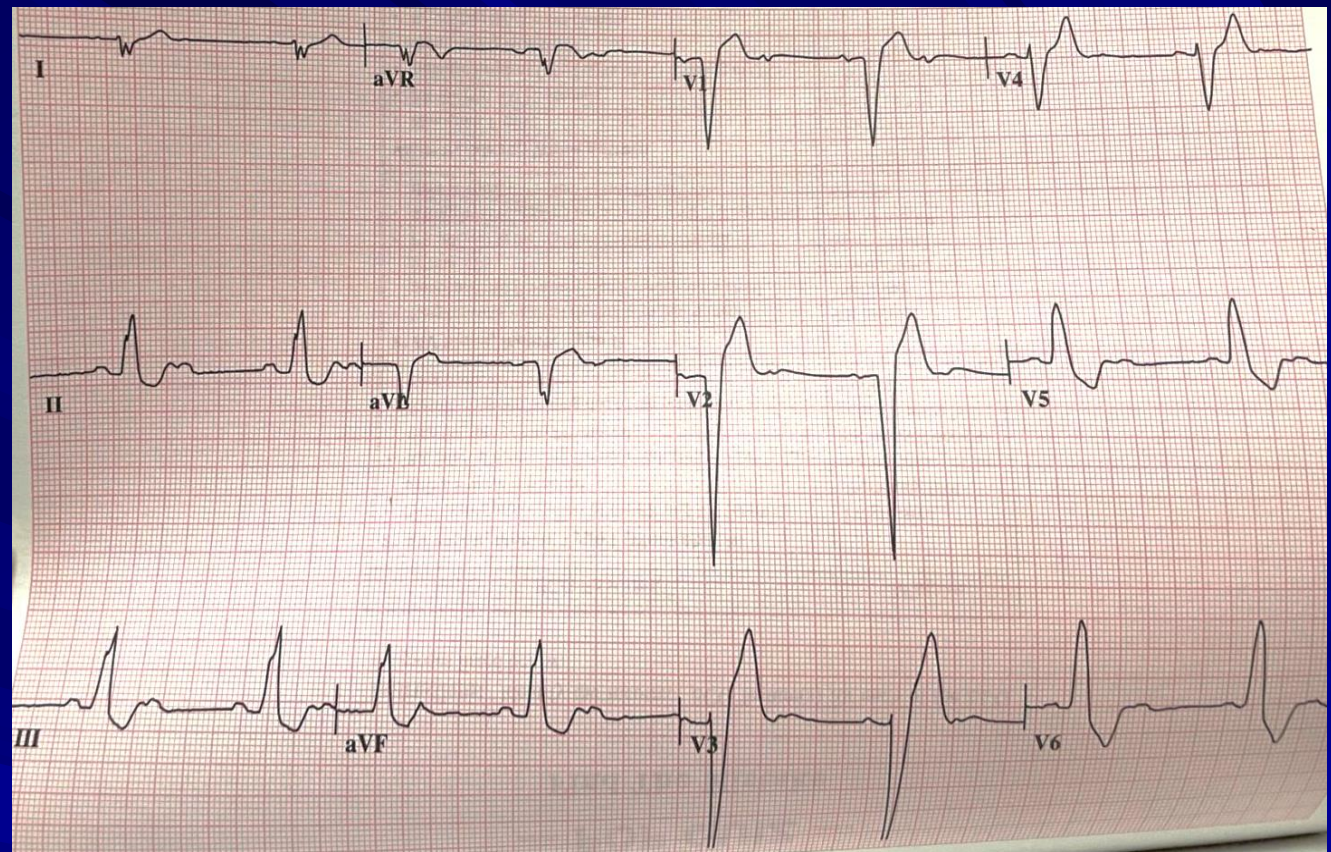
REASON: TIKOSYN LOADING

PREOP:



Question # 5

51 year-old F
presenting with
orthopnea and
paroxysmal
nocturnal
dyspnea. What
rhythm do you
see here that
may be the
culprit of her
symptoms?



- Mobitz Type I (Wenckebach)
- Mobitz Type II
- 2:1 AV block
- Sinus bradycardia with pre-atrial complex (PACs)

Answer: A

- **Answer: A. ECG shows sinus bradycardia with predominantly 2:1 AV block (arrowheads mark P waves), LBBB with secondary ST-T changes and right axis deviation. Close inspection reveals Mobitz Type I – the third P wave conducts at a normal PR interval, the fourth P wave at a prolonged PR interval, and the fifth P wave (hidden in the T wave) is blocked. The Q waves and ST elevation in leads V1-V3 are most likely due to LBBB, rather than acute anteroseptal MI (LBBB often results in a pseudoinfarct pattern).**

Questions

