

Role of the Lateral Extraarticular Procedure (ALL/LET) in ACL Reconstruction

Aman Dhawan MD

Associate Professor

Department of Orthopaedics and Rehabilitation

Penn State Health System

Penn State College of Medicine



PennState Health

Penn State Orthopaedics

Disclosures

Paid Consultant: Smith & Nephew, Avenue Therapeutics

Research Funding: U.S. Department of Defense, NIH, Revotek Inc, Smith & Nephew

Arthroscopy Journal Associate Editor

AJSM Principal Reviewer

OJSM Editorial Board

AANA Research Committee

AOSSM Publications Committee



Why are we even talking about this?

Primary ACL Reconstructions
without augmentation all do
GREAT!!!



ACL Outcomes

- RTS: 50% - 90% – approx. 65% are at pre-injury level
- Re-injury: 30% risk of 2nd ACL injury (ipsi- or contra-lateral) within 2 year after RTS in athletes <25 years old
 - 21% contralateral
 - 9% ipsilateral
- OA: 20% - 55% within 10-20 years
- Persistent laxity, especially rotational, on objective knee testing in approx. 40%



Constant Evolution of Technique

- Open ACL Reconstruction
- Two incision technique, Rear Entry Guide
- Arthroscopic Transtibial Technique
- Double Bundle Arthroscopic ACLR
- Femoral Independent Drilling Techniques

- And now what's up with the ALL (Anterolateral Ligament)????



High grade AL laxity is not just an ACL injury

Prevalence and Classification of Injuries of Anterolateral Complex in Acute Anterior Cruciate Ligament Tears



Andrea Ferretti, M.D., Edoardo Monaco, M.D., Mattia Fabbri, M.D., Barbara Maestri, M.D.,
and Angelo De Carli, M.D.

Arthroscopy
2017

- Macroscopic tears of the lateral capsule were clearly identified at surgery in 54 of 60 patients
- Type I: 19/60 Type II: 16/60 Type III: 13/60 Type IV: 6/60
- In all cases, repair resulted in a marked reduction or apparent disappearance of the pivot-shift phenomenon
- Positive correlation between lesions of the lateral compartment and a pivot shift graded 2 or 3



The
New York
Times

NBC NEWS

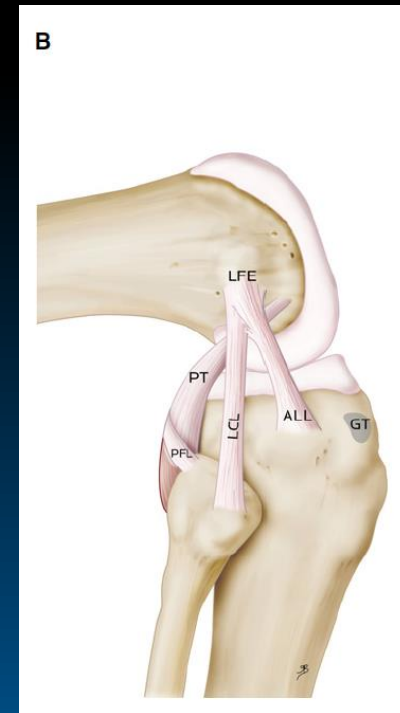
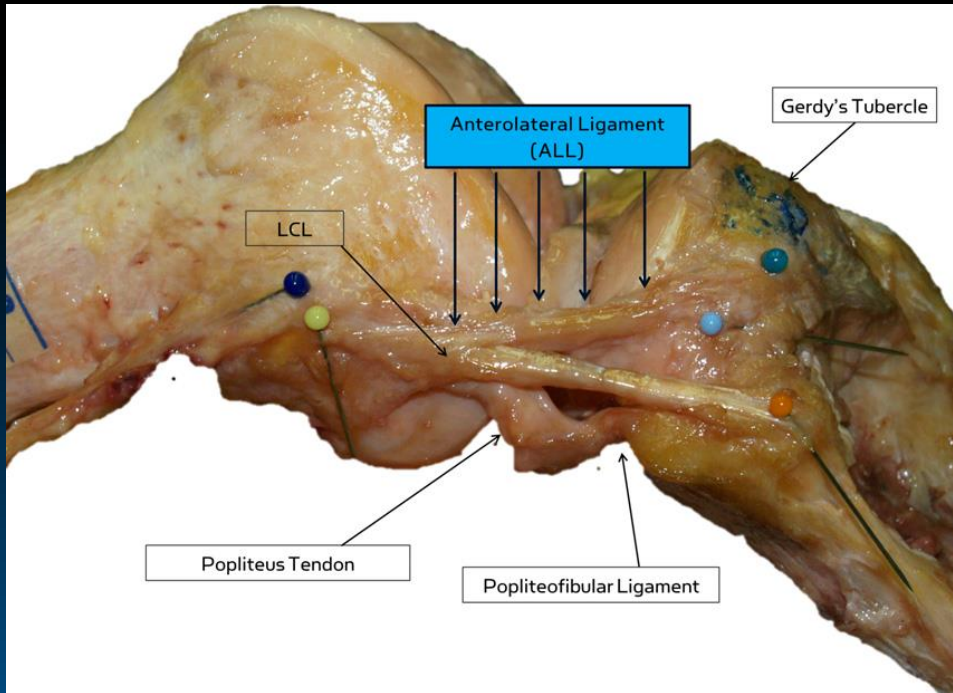
BBC
NEWS

Doctors Identify a New Knee Ligament

By GRETCHEN REYNOLDS

NOVEMBER 13, 2013 12:01 AM

64



Claes J Anat 2013




PennState Health

Penn State Orthopaedics


Anterolateral Ligament (ALL)

- There's still a lot of debate
 - Is this New?
 - Does it Really Exist?
 - What does it do?
 - How do we treat?



New Ligament or New Name?

- Fibrous bunches that reinforce the capsule (Weitbrecht, 1752)
- Pearly, resistant, fibrous band (Segond, 1879)



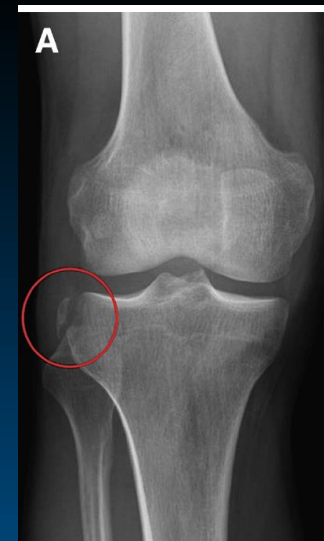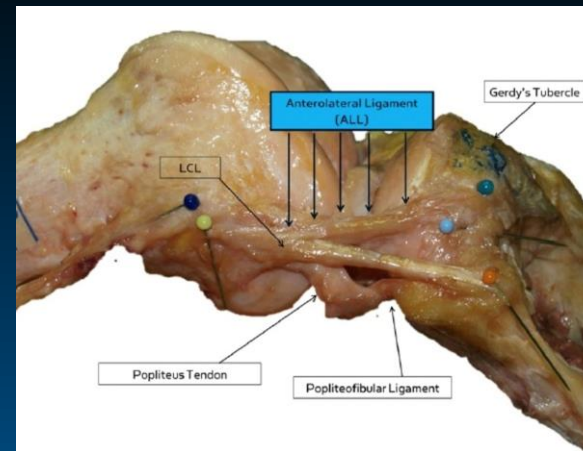
Journal of **Anatomy**

J. Anat. (2013) 223, pp321–328 doi: 10.1111/joa.12087

Anatomy of the anterolateral ligament of the knee

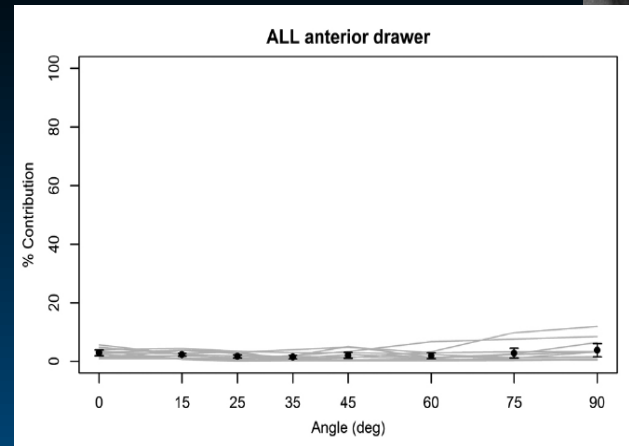
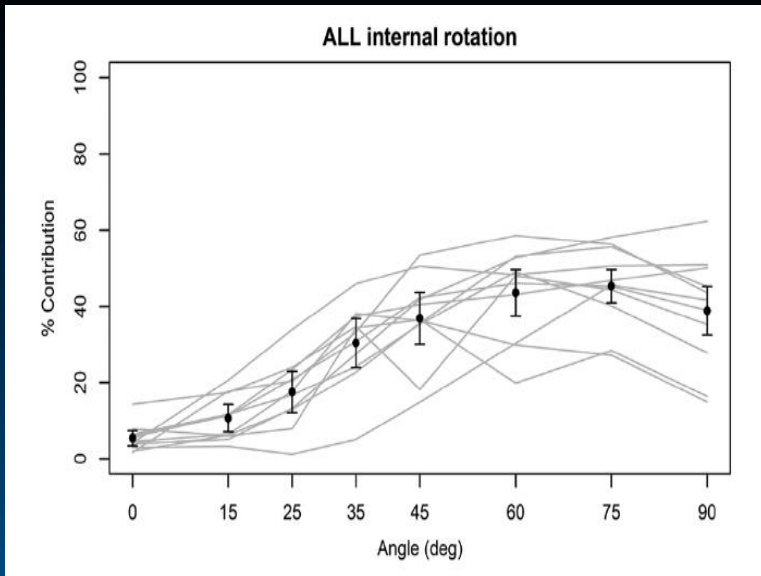
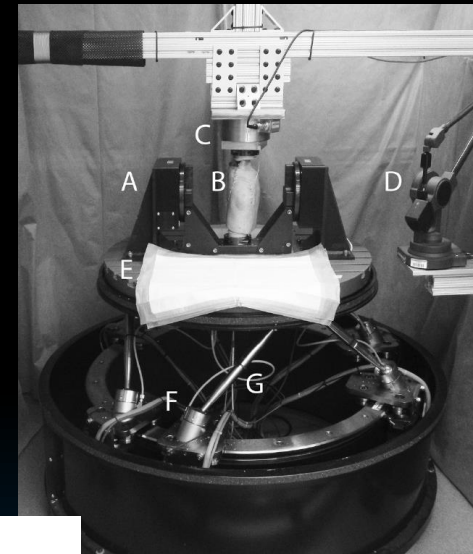
Steven Claes,¹ Evie Vereecke,² Michael Maes,¹ Jan Victor,³ Peter Verdonk⁴ and Johan Bellemans¹

¹Department of Orthopedic Surgery & Traumatology, University Hospitals Leuven, Leuven, Belgium
²Department of Development and Regeneration, Faculty of Medicine@Kulak, Catholic University Leuven, Kortrijk, Belgium
³Department of Orthopedic Surgery & Traumatology, University Hospital Gent, Ghent, Belgium
⁴Antwerp Orthopedic Center, Monica Hospitals, Antwerp, Belgium



ALL Biomechanics

- ALL limits Internal Rotation
 - Flexion >35 degrees
- Not involved in anterior translation

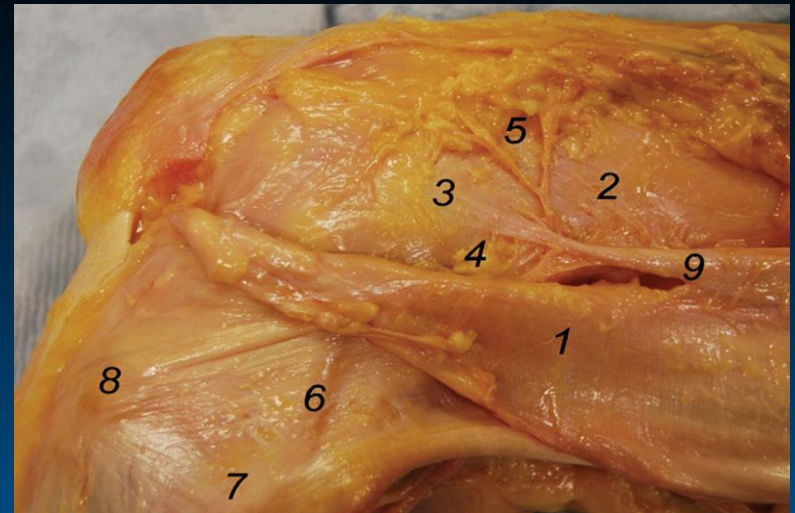
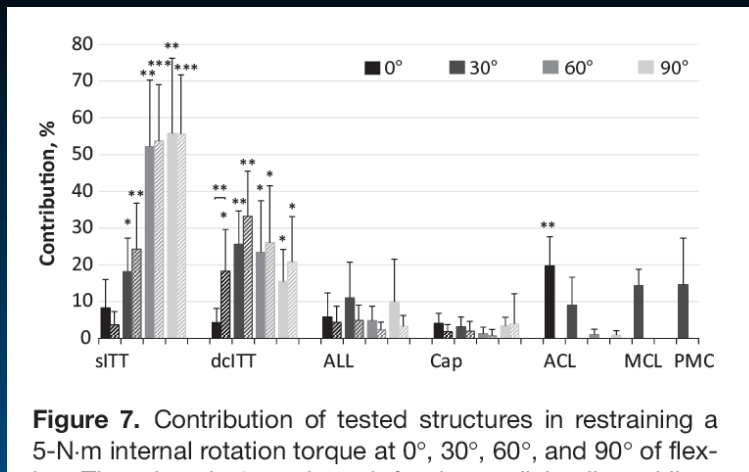


Parsons, Gee AJSM 2015; Rasmussen AJSM 2015; Spencer AJSM 2015



ALL Biomechanics

- Kittl AJSM 2015
 - IT band is the key structure, more than the ALL
 - Superficial and espec Deep (capsulo-osseous layer) of IT band resist IR & Ant. translation
 - Both Intact and ACL deficient state



Biomechanics Summary

The Anterolateral Ligament of the Knee: An Updated Systematic Review of Anatomy, Biomechanics, and Clinical Outcomes



Connor P. Littlefield, B.A., John W. Belk, B.A., Darby A. Houck, B.A.,
Matthew J. Kraeutler, M.D., Robert F. LaPrade, M.D., Ph.D., Jorge Chahla, M.D., Ph.D., and
Eric C. McCarty, M.D.

Arthroscopy 2021

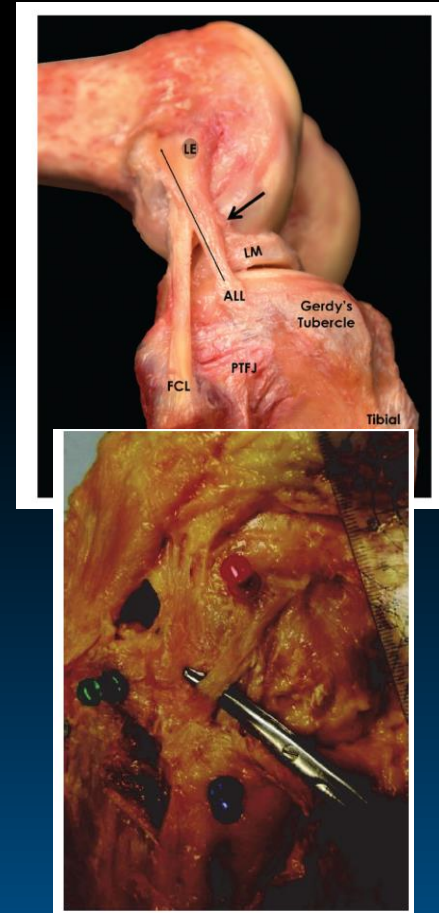
- Five articles analyzed the biomechanics of the ALL

“The Anterolateral Ligament Complex acts as a secondary stabilizer to the anterior cruciate ligament and helps resist internal knee rotation and possibly anterior tibial translation”



ALL Anatomy is confusing...

- Anatomy can be subjective
- Confusion as different terms describe the same structures
 - Mid-third lateral capsular ligament
 - Capsulo-osseous layer
 - Anterolateral ligament
- Varying dissection techniques

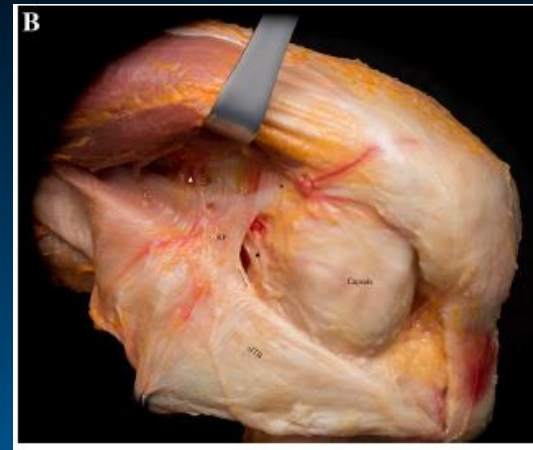
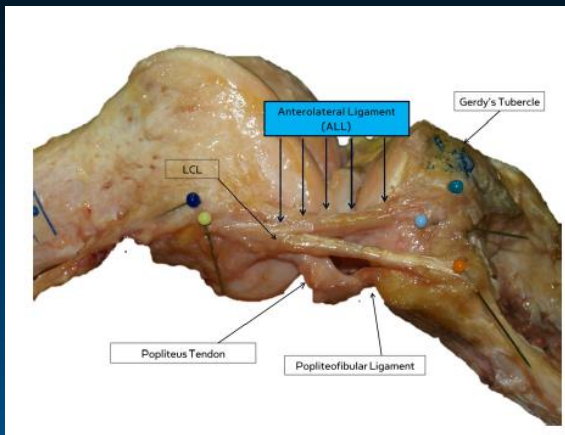


Dodds, Bone Joint J 2014, Kraetler AJSM 2017



Controversy about Anatomy

- The dissection studies are not consistent
 - Fresh-Frozen vs. Embalmed Specimens
 - Dissection of overlying IT Band
 - Knee flexion at the time of dissection



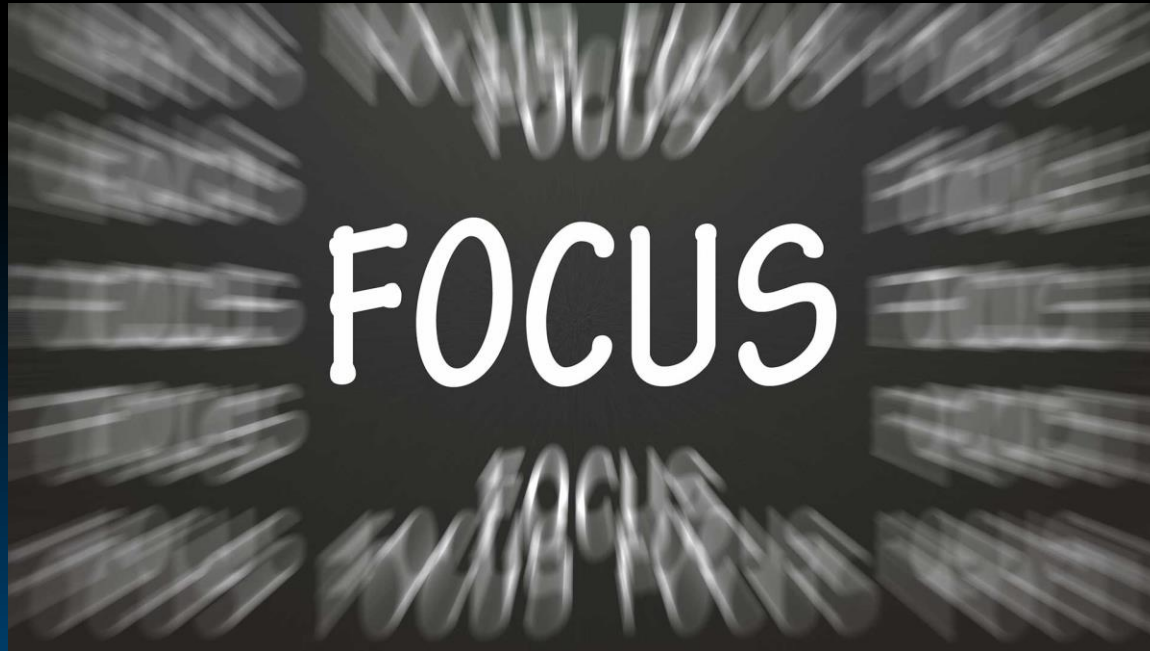Claes J Anat 2013; Herbst KSSTA 2017



PennState Health

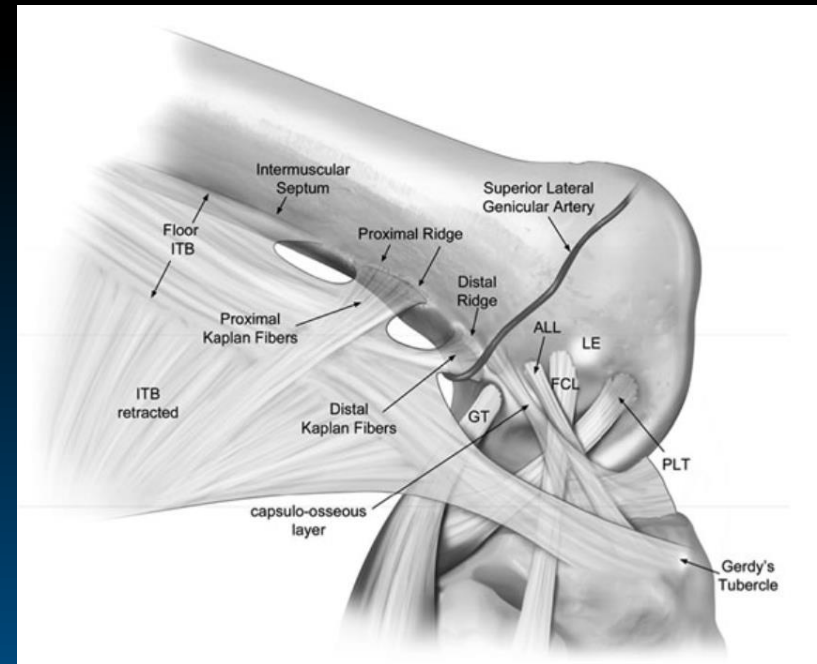
Penn State Orthopaedics

Don't Lose Focus...



The lateral side of the knee helps with biomechanics of the knee

- Anterolateral Complex (ALC) instead of ALL
- ALC includes:
IT Band and its components
Underlying anterolateral capsule
- May or may not have a specific capsular “ligament”
- Biomechanical studies - The ALC is a 2° stabilizer to the ACL and helps resist internal knee rotation and possibly anterior tibial translation



High grade AL laxity is not just an ACL injury

Prevalence and Classification of Injuries of Anterolateral Complex in Acute Anterior Cruciate Ligament Tears



Andrea Ferretti, M.D., Edoardo Monaco, M.D., Mattia Fabbri, M.D., Barbara Maestri, M.D.,
and Angelo De Carli, M.D.

Arthroscopy
2017

- Macroscopic tears of the lateral capsule were clearly identified at surgery in 54 of 60 patients
- Type I: 19/60 Type II: 16/60 Type III: 13/60 Type IV: 6/60
- In all cases, repair resulted in a marked reduction or apparent disappearance of the pivot-shift phenomenon
- Positive correlation between lesions of the lateral compartment and a pivot shift graded 2 or 3



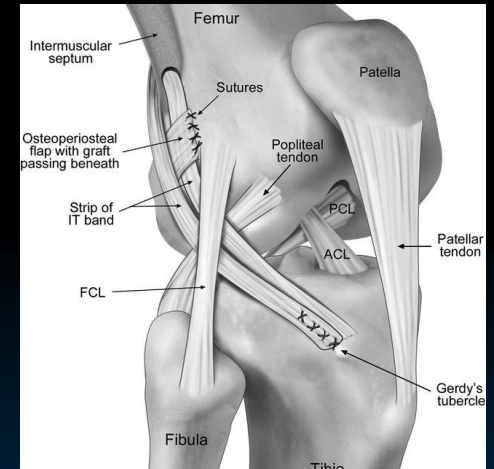
Can we use this information to help
improve ACL reconstruction technique and
outcomes???



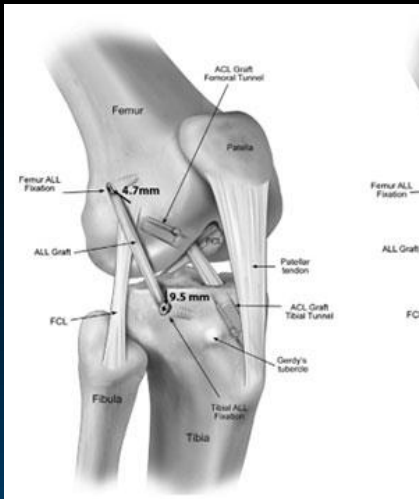
1980's Extra-articular tenodesis

- Non-anatomic procedures
- Concerns about over-constraining knee → Arthritis
- Often required long periods of casting → Stiffness
- Outcomes fairly poor across techniques
 - Fell out of favor
 - Evolution toward the modern intra-articular ACL reconstruction techniques

Dodds JBJS(b) 2014



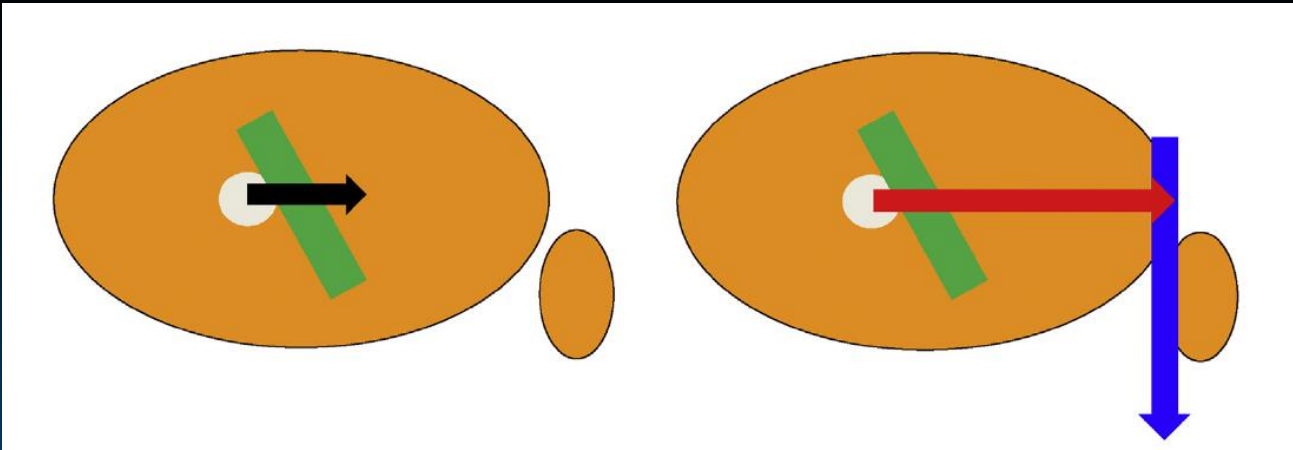
Are Lateral Augmentation Procedures Bringing Us “Back to the Future”???



Maybe we can keep the baby. but
throw out the bathwater....



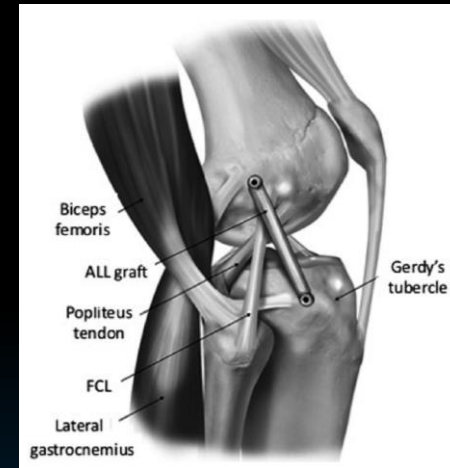
- Lateral extra-articular tenodesis (LET) vs ACLR
 - Moment arm of LET >> ACLR



2 Major Lateral Augmentation Procedures

- ALL Reconstruction

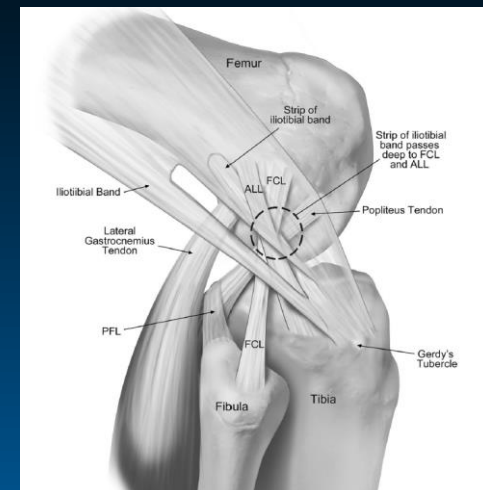
- Allograft or autograft
- Tunnel on tibia 1/2 way Fib- Gerdy
- Graft superficial to LCL



- Lateral extra-articular tenodesis (LET)

- ITB left attached at Gerdy's
- Using different fixation on femur
- Variability in tunnel positions on femur
- Graft deep to LCL and slings around

Geeslin AJSM 2017



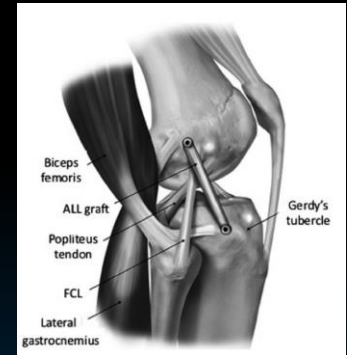
What is the best method to control rotation?

Biomechanical Comparison of Anterolateral Procedures Combined With Anterior Cruciate Ligament Reconstruction

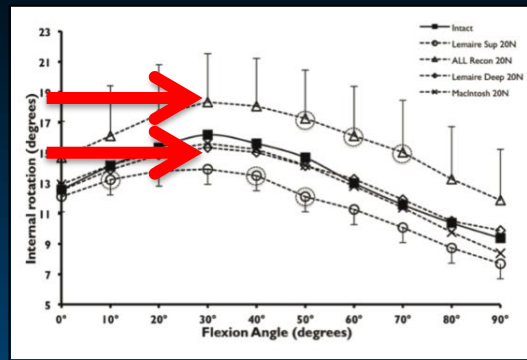
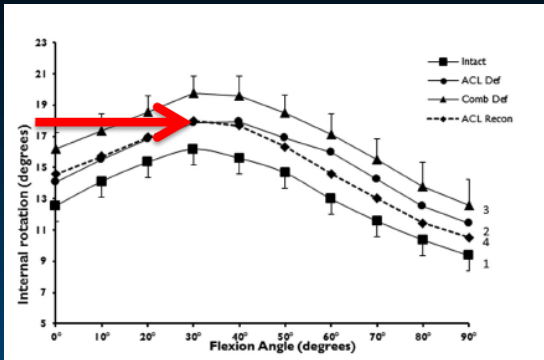
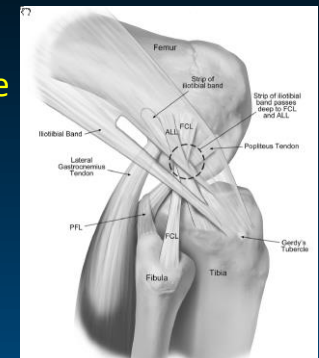
Eivind Inderhaug,^{*†} MD, PhD, Joanna M. Stephen,^{**‡} PhD, Andy Williams,[‡] FRCS(Orth), FFSEM, and Andrew A. Amis,^{*§||} FEng, DSc(Eng)
 Investigation performed at Imperial College London, London, UK

ALL Recon

AJSM 2016



Lemaire LET

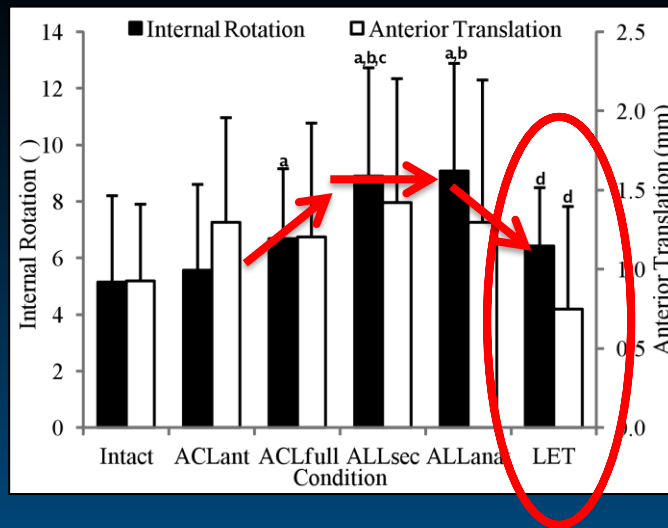


Biomechanical Studies of ALC

Biomechanical Analysis of Simulated Clinical Testing and Reconstruction of the Anterolateral Ligament of the Knee

Luke Spencer,* MBBS, FRACS(Orth), Timothy A. Burkhart,[†] PhD, EIT, RegKin, Michael N. Tran,* MD, FRCSC, Alex James Rezansoff,* MD, FRCSC, Shanel Deo,* BHB(Hons), MBChB, FRACS(Orth), Scott Catherine,*[†] BSc, MSc, and Alan M. Getgood,*[§] MPhil, MD, FRCS(Tr&Orth)
Investigation performed at the Department of Mechanical and Materials Engineering, Western University, London, Ontario, Canada

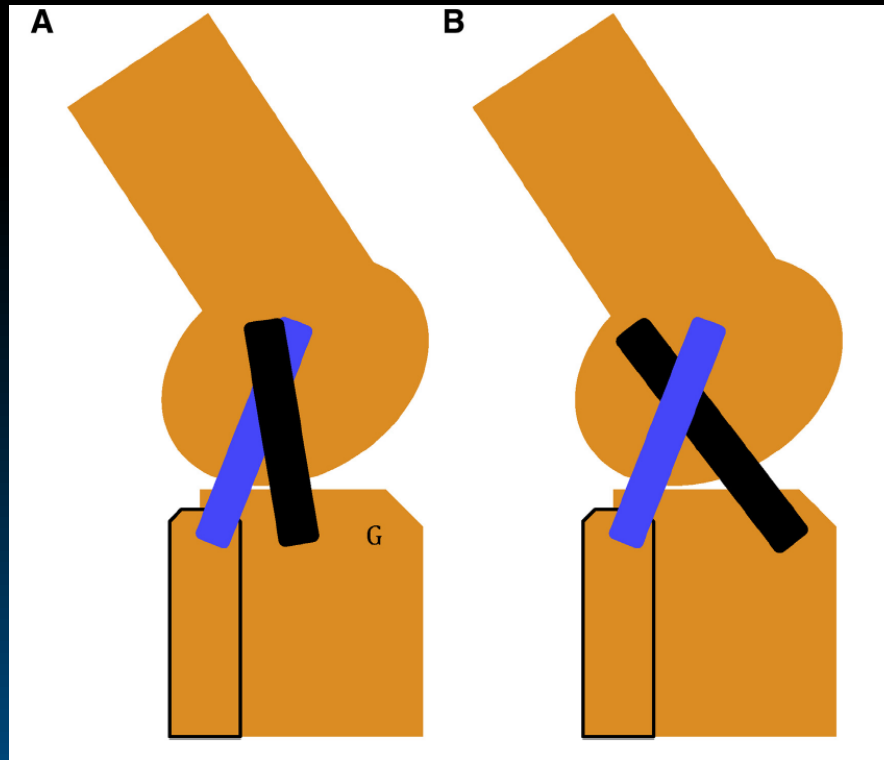
AJSM 2015



- Statistically significant increase in internal rotation with ALL sectioning
- No significant improvement with ALL recon
- LET - Significant improvement in controlling rotation and translation



More obliquity of LET vs ALL = More control over IR



Williams Arthroscopy 2018



PennState Health

Penn State Orthopaedics

Clinical Results of LET

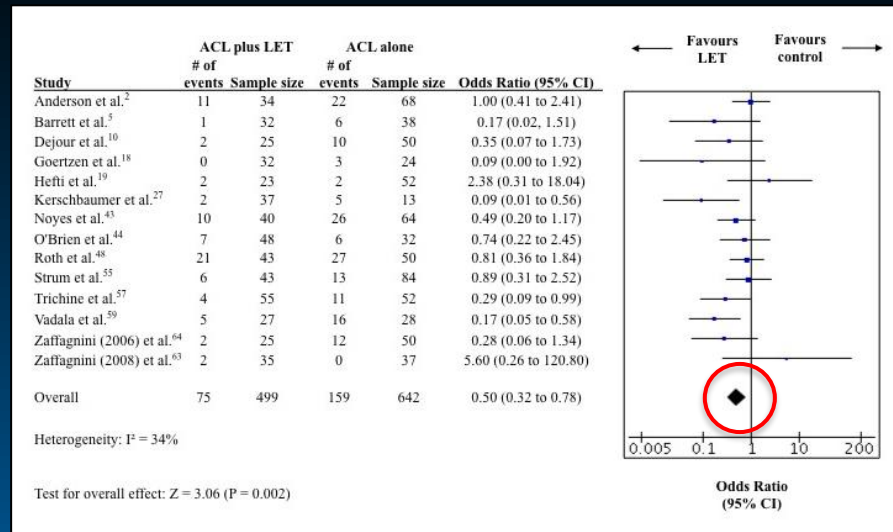
Systematic Review

Lateral Extra-articular Tenodesis Reduces Rotational Laxity When Combined With Anterior Cruciate Ligament Reconstruction: A Systematic Review of the Literature

Christopher E. Hewison, B.Sc.(Kin), Michael N. Tran, M.D., F.R.C.S.C., Nicole Kaniki, A.T.C., M.Sc., Alliya Remtulla, B.Sc.(Kin), M.Sc., Dianne Bryant, Ph.D., and Alan M. Getgood, M.Phil., M.D., F.R.C.S.(Tr&Orth), Dip.S.E.M.

Arthroscopy 2015

- Metaanalysis demonstrates a statistically significant reduction in pivot shift with the combined procedure (ACLR + LET)



Stability Study

- RCT ACLR vs ACLR + LET
- 624 patients randomized / 523 at 2 years f/u
- Age 18.9
- 2+ or greater pivot
- High Beighton score (hyperlaxity)
- ACLR with HS
- 41% graft failure in ACLR (vs 25% ACL + LET)
- PROs same

Conclusion: The addition of LET to a single-bundle hamstring tendon autograft ACLR in young patients at high risk of failure results in a statistically significant, clinically relevant reduction in graft rupture and persistent rotatory laxity at 2 years after surgery.

Getgood et al AJSM 2020



So we got it figured out then right???

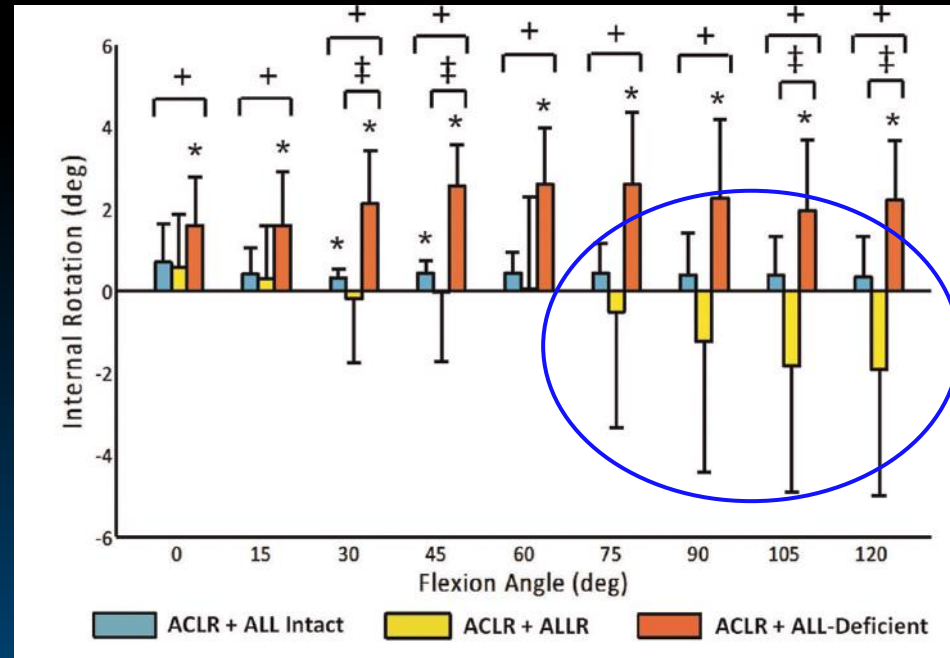
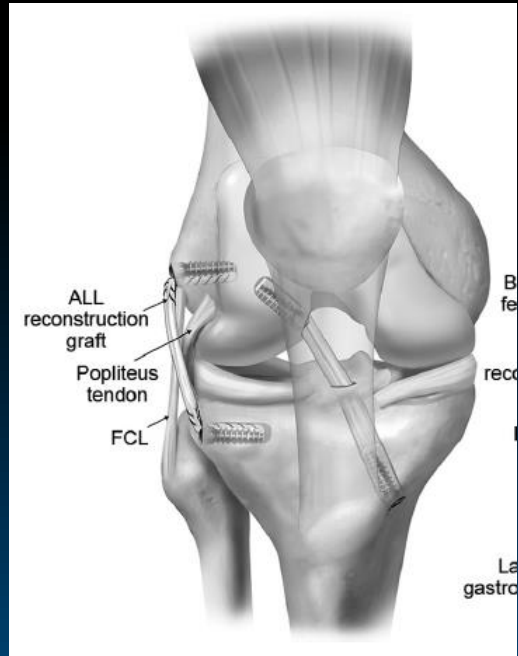


PennState Health

Penn State Orthopaedics

Potential Overconstraint

- ACLR + ALLR decreases native IR



Indications need to be defined

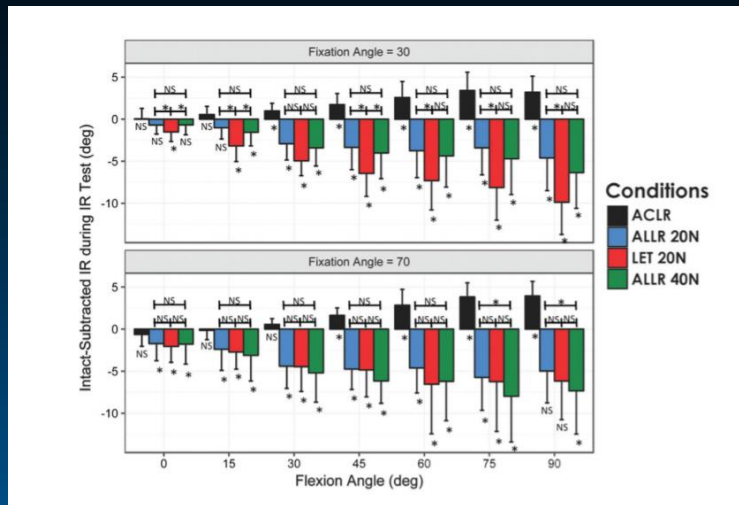


Overconstraint...

Anterolateral Knee Extra-articular Stabilizers

A Robotic Study Comparing Anterolateral Ligament Reconstruction and Modified Lemaire Lateral Extra-articular Tenodesis

Geslin et al AJSM 2017



Mean intact-subtracted tibial internal rotation (IR) is shown for tested conditions at knee flexion angles 0 to 90. A negative value represents overconstraint as compared to the intact state.



So Where Are We?



Current State

- Consensus has been reached to call it Anterolateral complex (ALC)
- Anterolateral complex reconstruction clearly has role alongside ACL reconstruction in improving ACL injuries
- Concerns about over constraint when both performed
- Indications continue to evolve

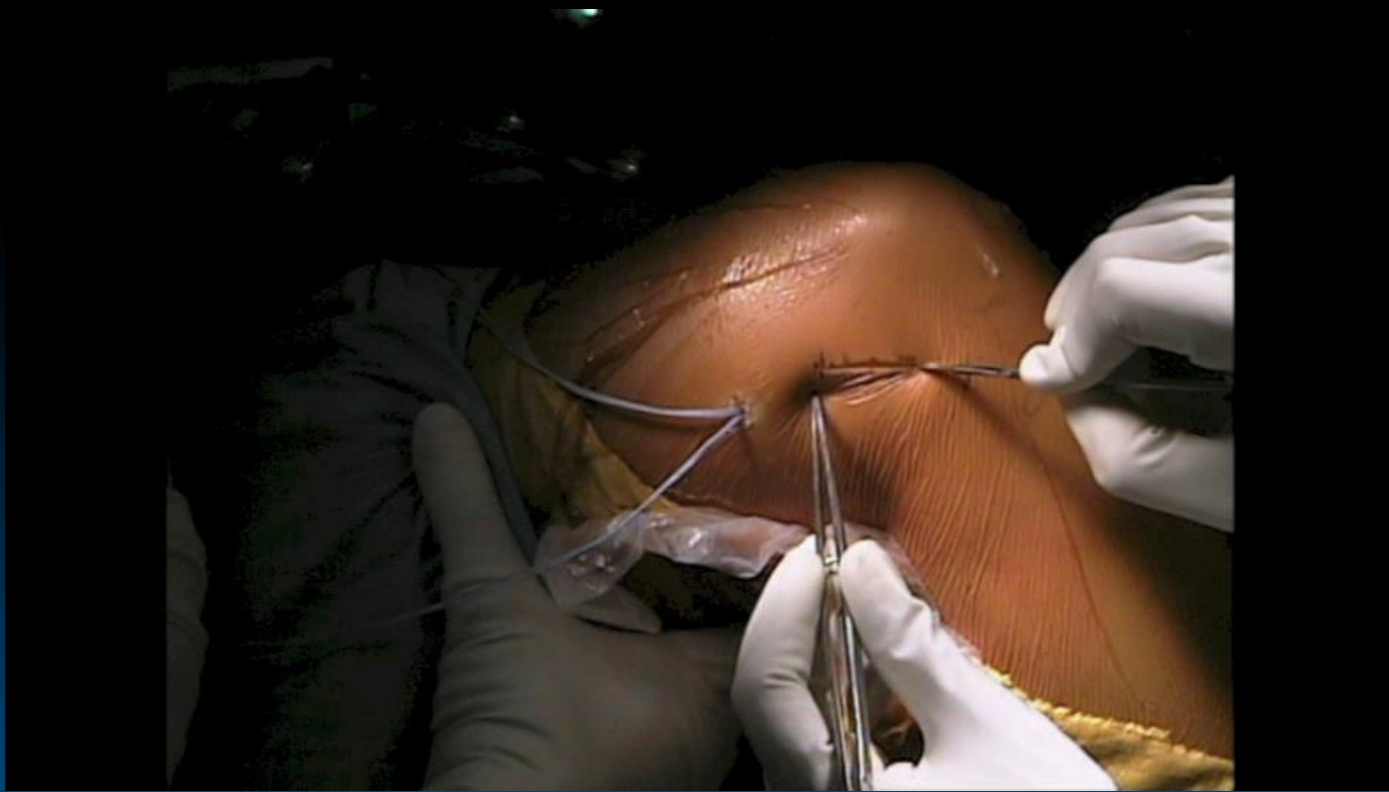


Summary

- Level 5 considerations for use of “ALC recon” (Musahl KSSTA 2017)
 - Revision ACL
 - With primary ACLR in high-grade pivot shift or ligamentous laxity
- Other factors remain in ACL treatment
 - Meniscus, Bony morphology of joint surfaces, Alignment, etc
- Research ongoing, indications continue to evolve



Modified Lemaire Lateral Extraarticular Tenodesis



Thank You



PennState Health

Penn State Orthopaedics