

PAOS in the Music City

Pediatric Elbow

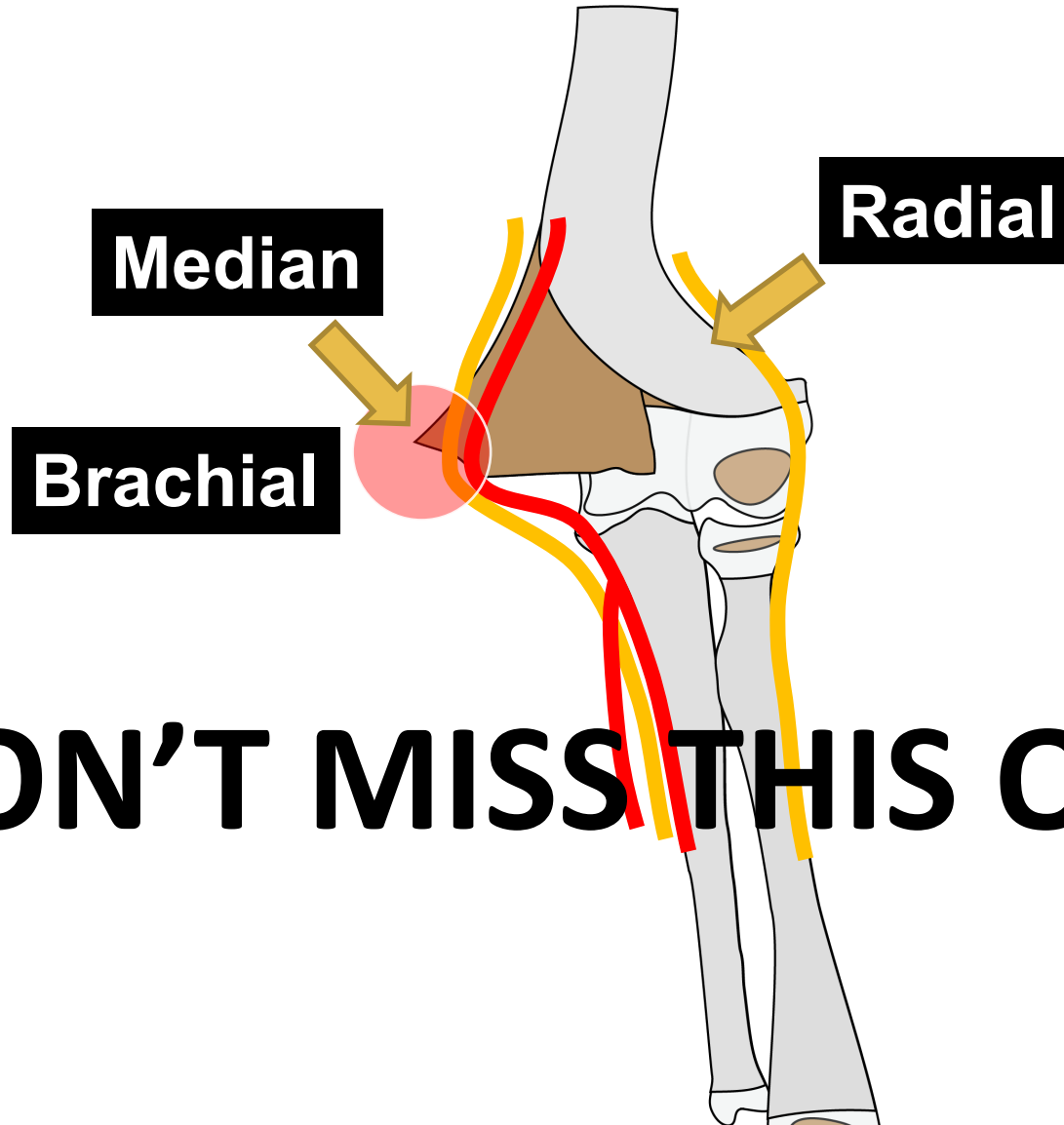


Jonathan Schoenecker

Associate Professor Orthopaedics Pharmacology Pathology Pediatrics
Jeffrey Mast Chair of Trauma and Hip Surgery
Vanderbilt University



Elbow Pearls



DON'T MISS THIS ONE!!!

Fracture

Team-Effort

Fracture

Team-Effort

Periosteum

Fracture

Team-Effort

Periosteum

4 QUESTIONS

Fracture

Team-Effort

Periosteum

Where Is It Torn?

4 QUESTIONS

Fracture

Team-Effort

Periosteum

Where Is It Torn?

What Could Be Hurt?

4 QUESTIONS

Fracture

Team-Effort

Periosteum

Where Is It Torn?

What Could Be Hurt?

Where Is It Intact?

4 QUESTIONS

Fracture

Team-Effort

Periosteum

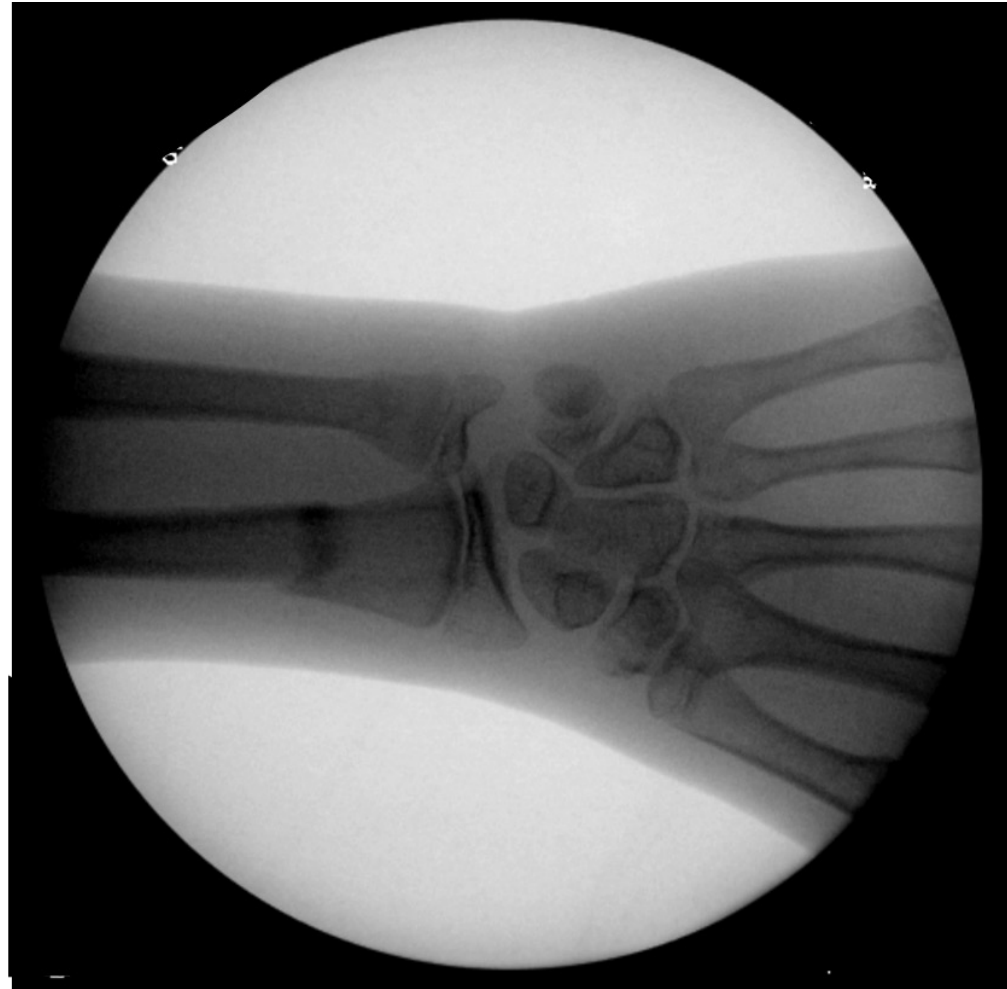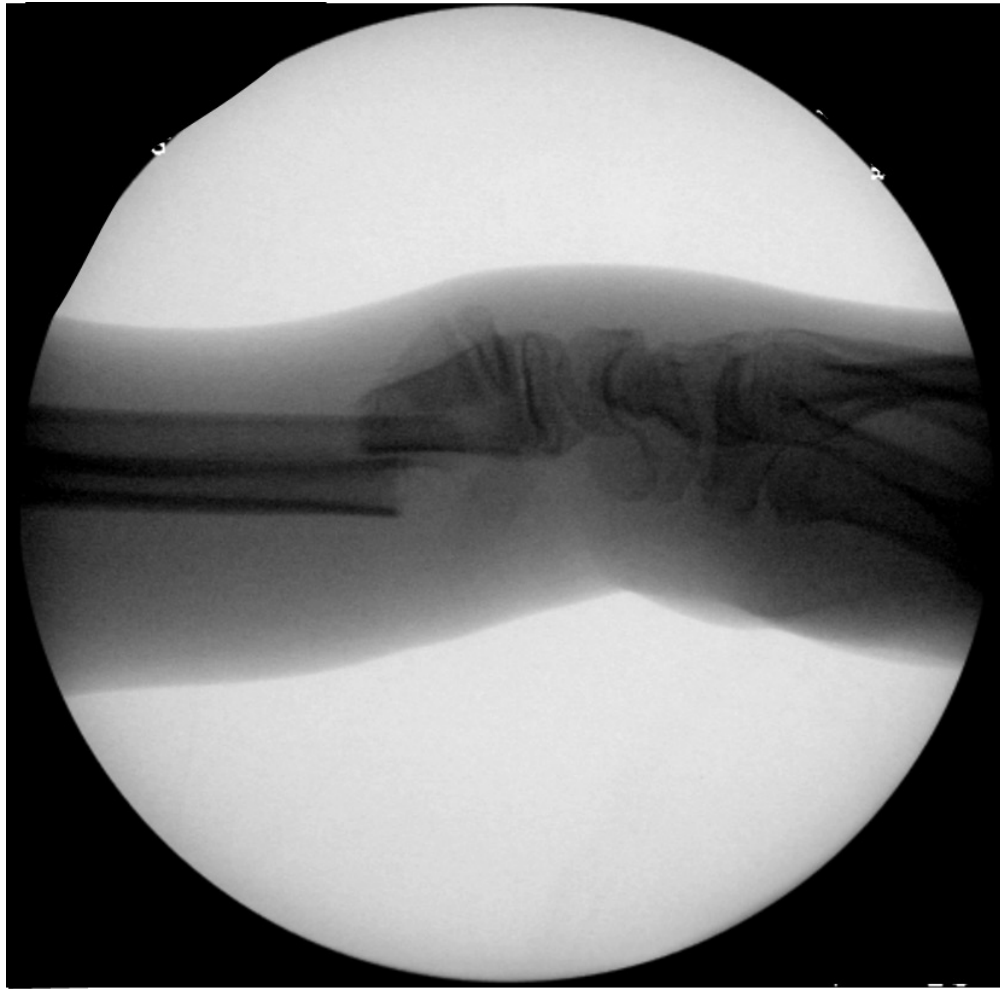Where Is It Torn?

What Could Be Hurt?

Where Is It Intact?

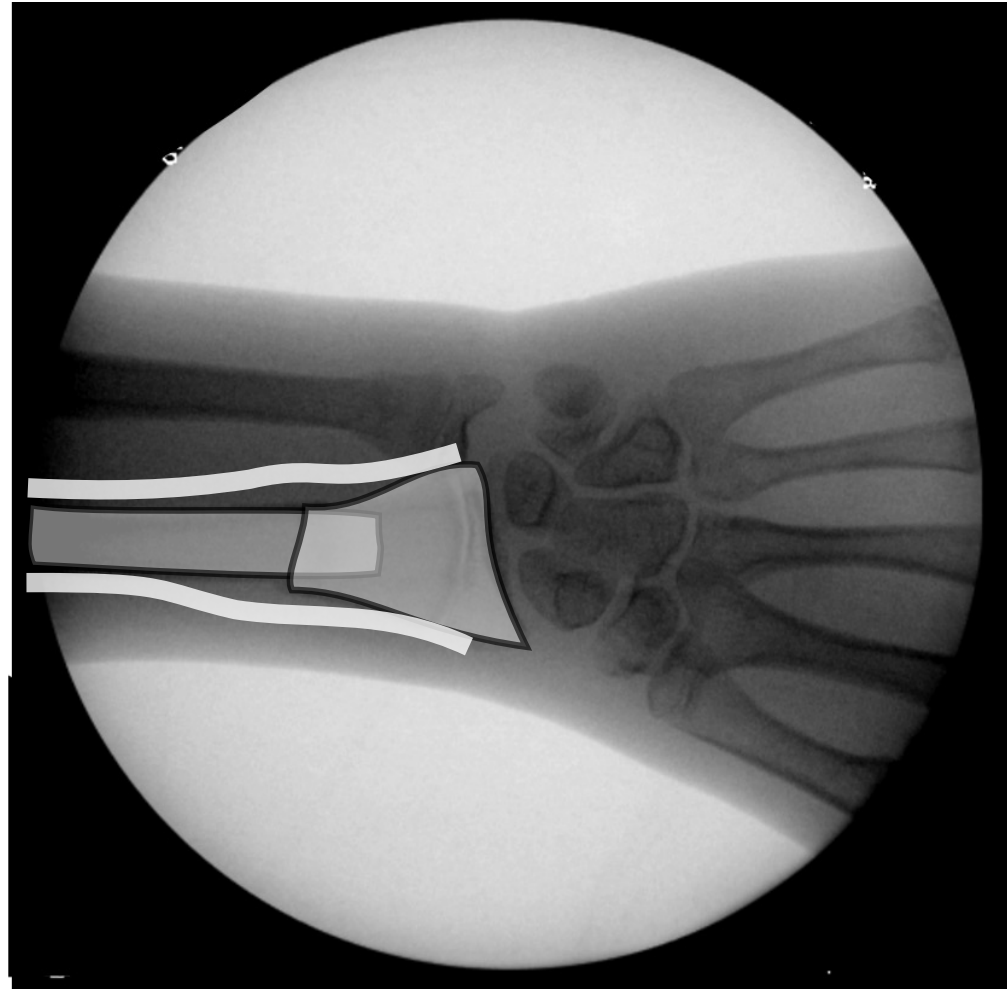
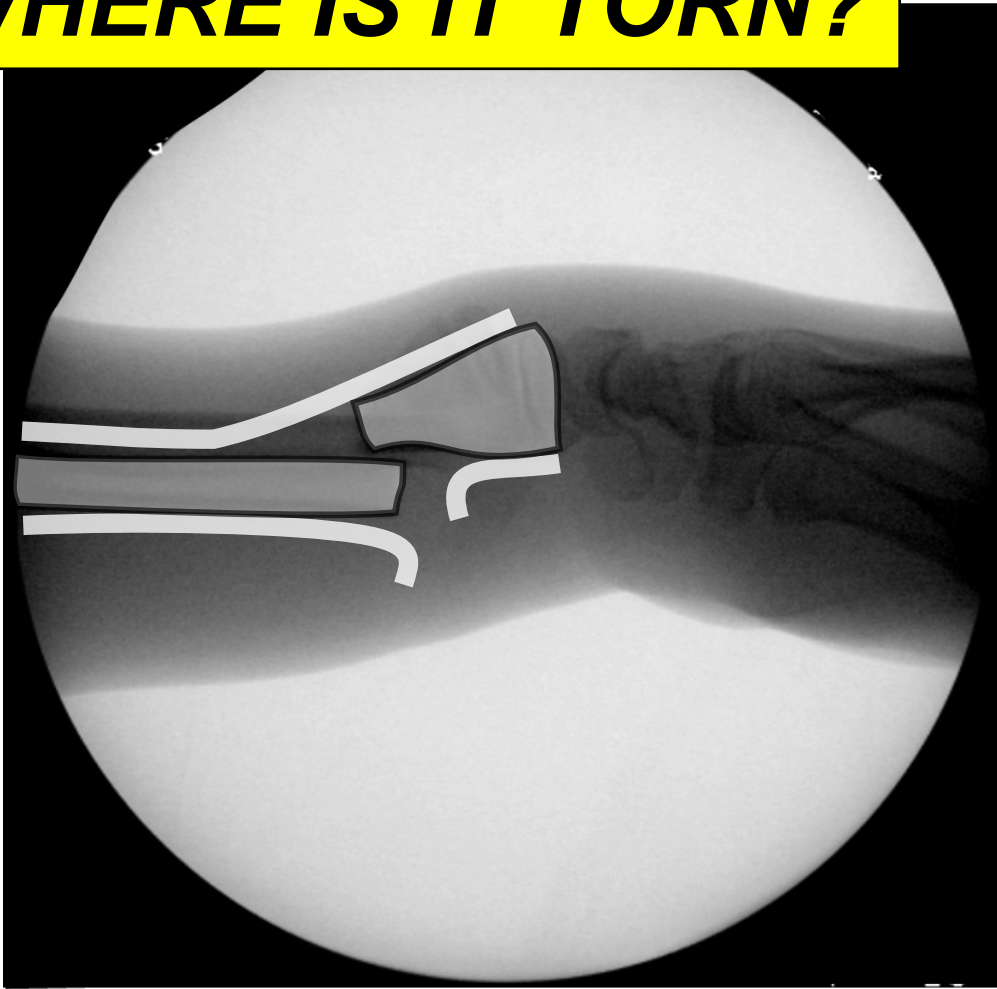How To Replace It?

4 QUESTIONS



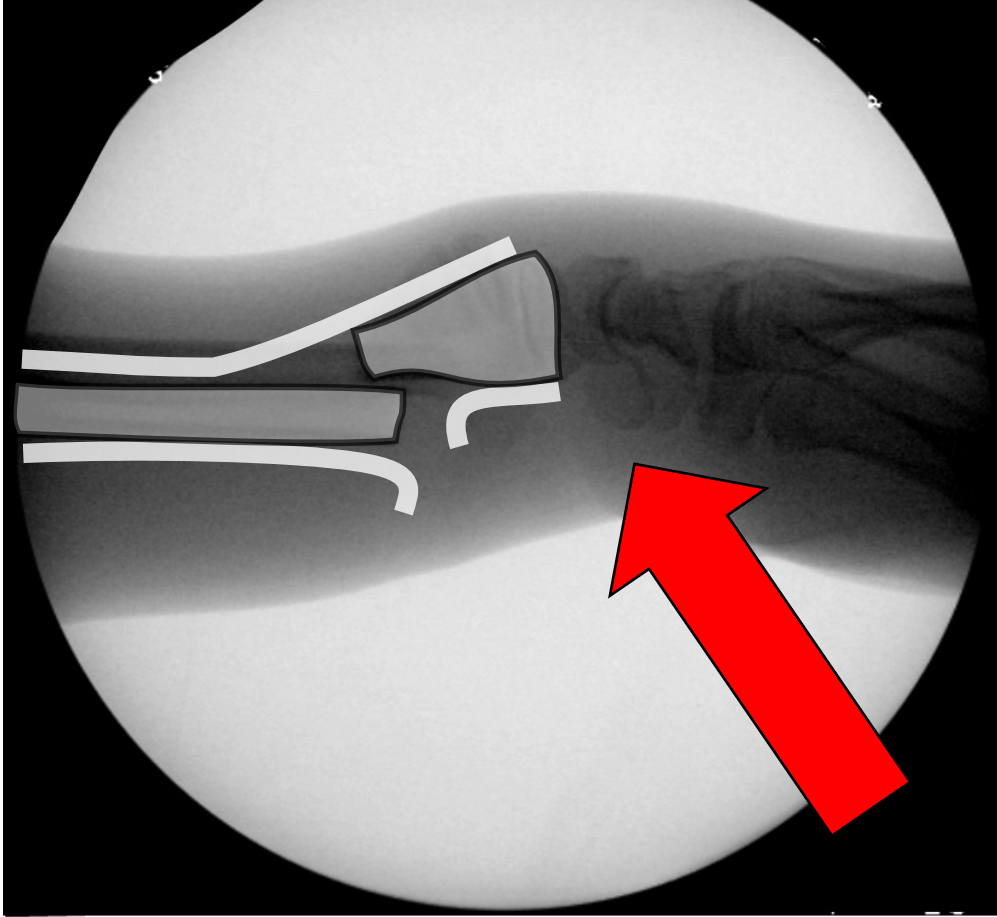
PERIOSTEUM

WHERE IS IT TORN?

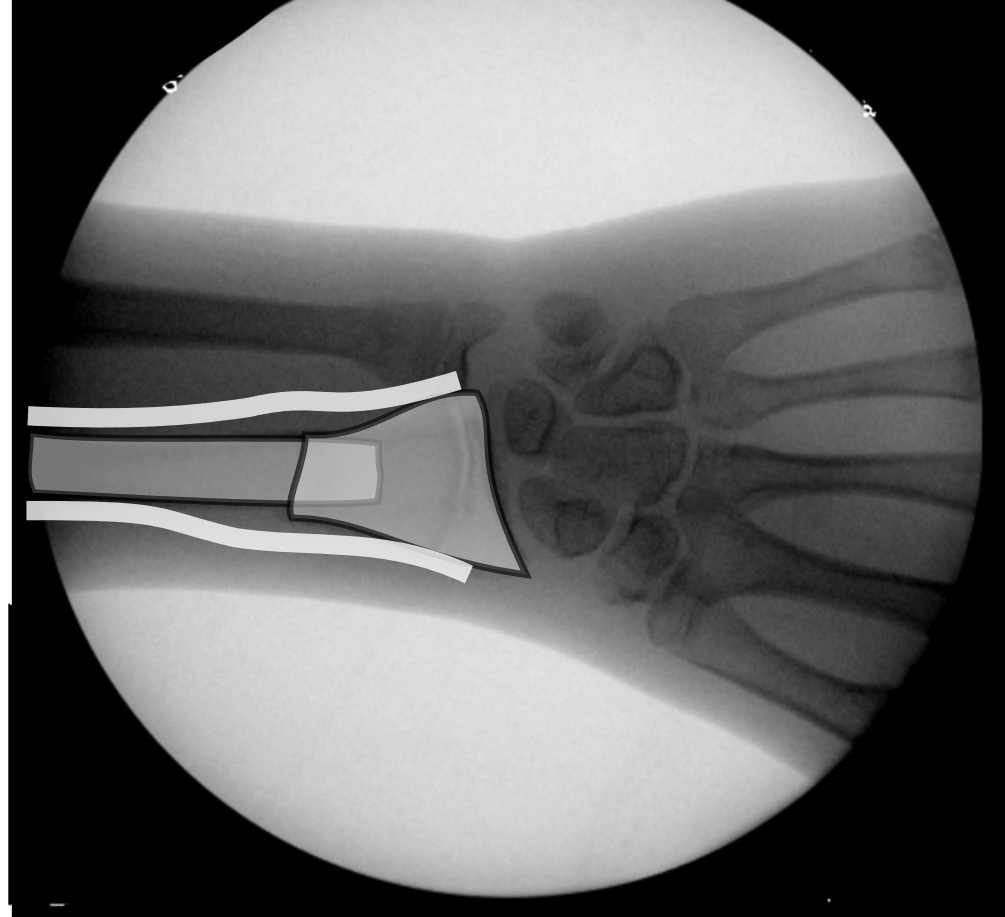


PERIOSTEUM

WHERE IS IT TORN?

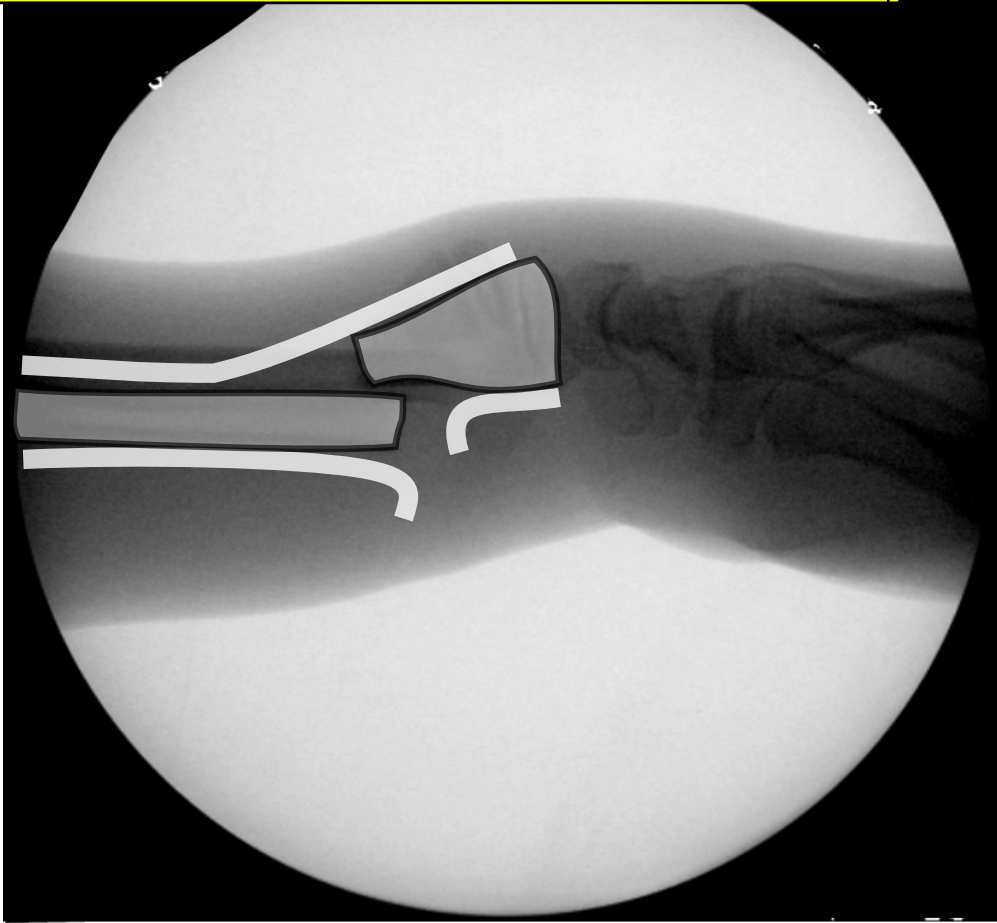

Pathomechanism

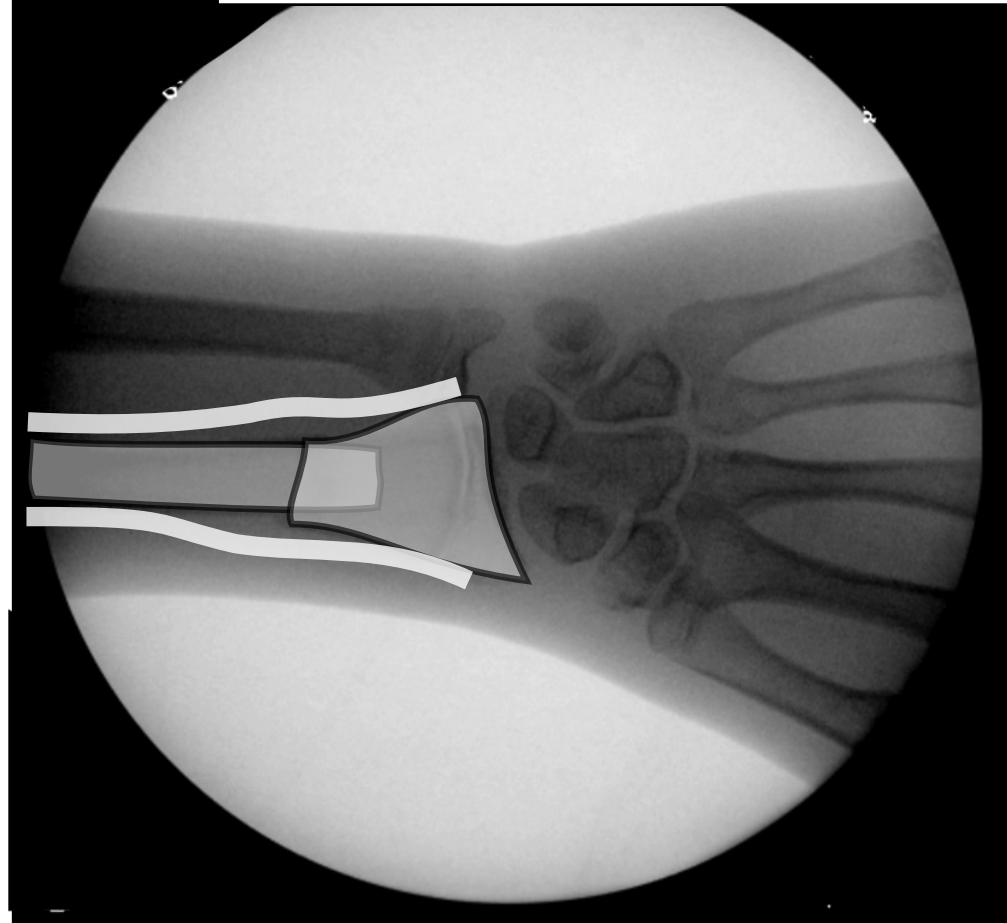


PERIOSTEUM

LOSS PROTECTION

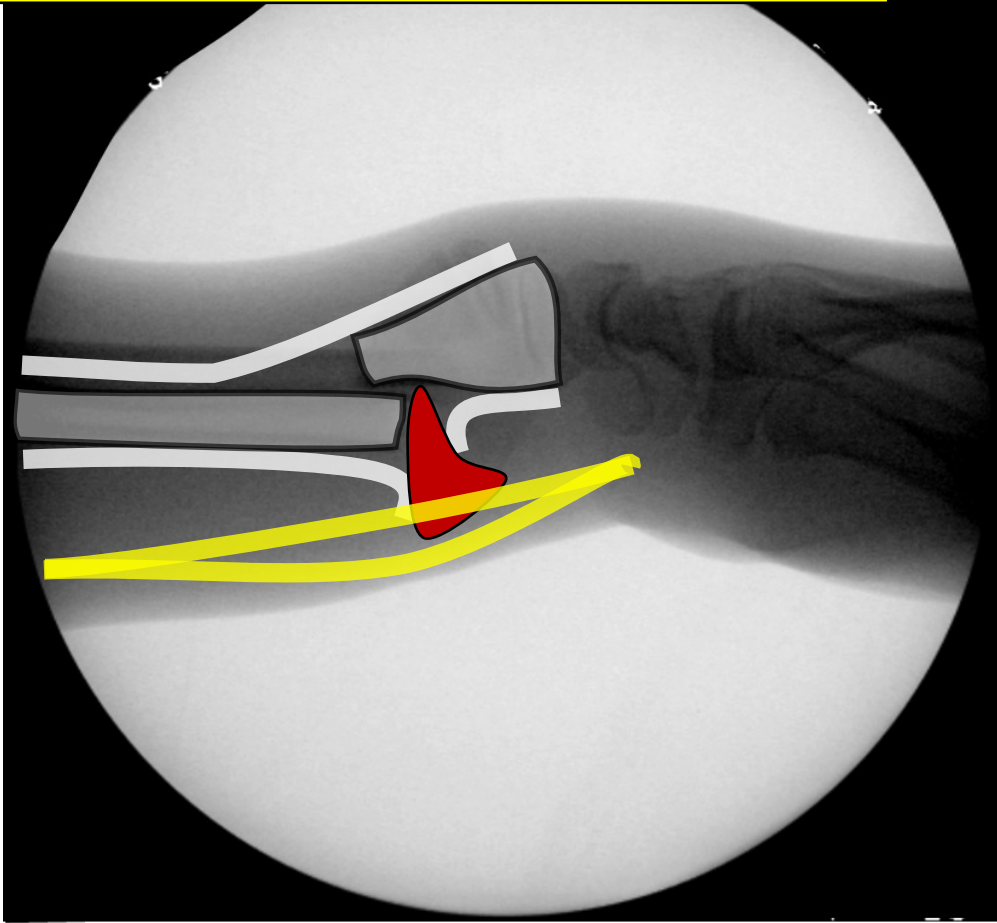


Pathomechanism

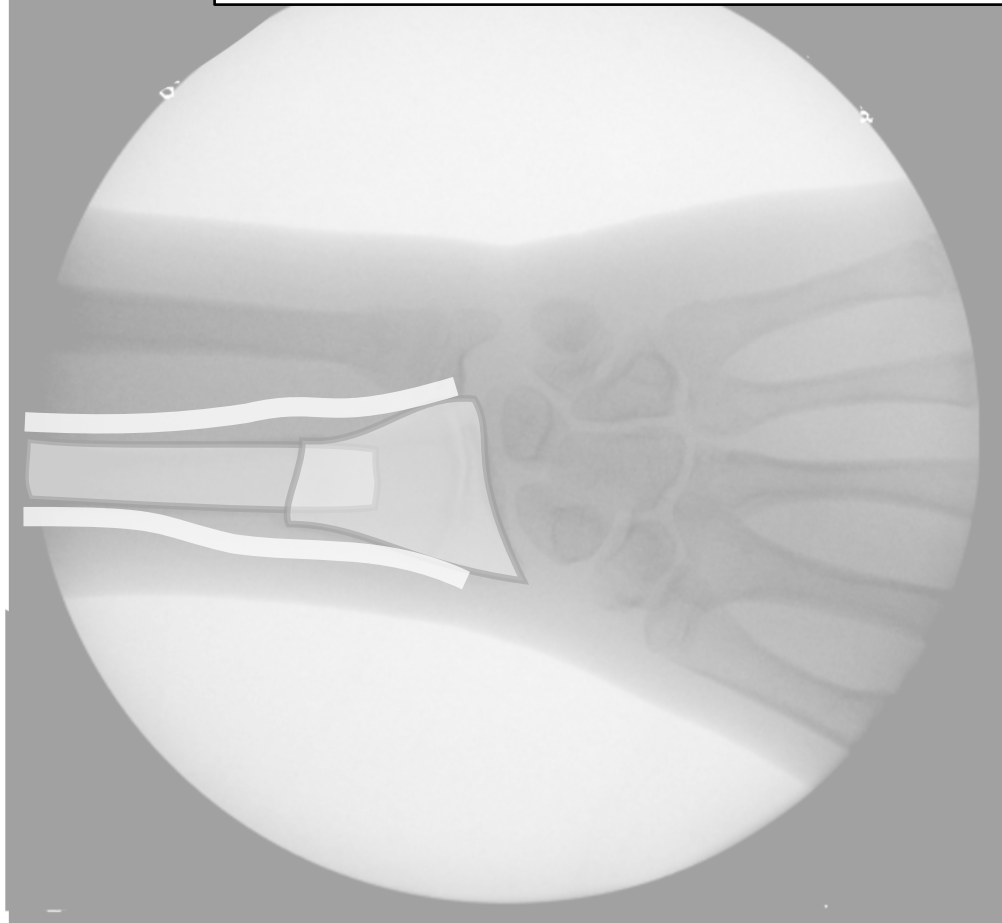


PERIOSTEUM

LOSS PROTECTION

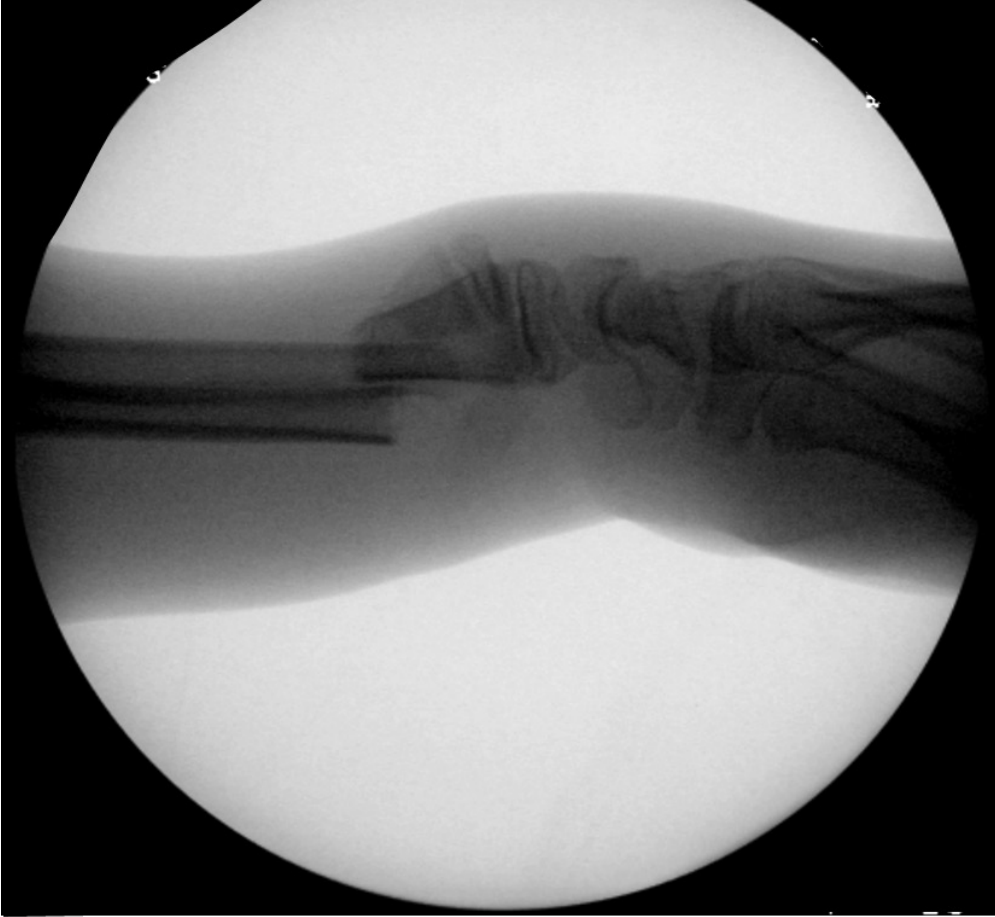

Collateral Damage

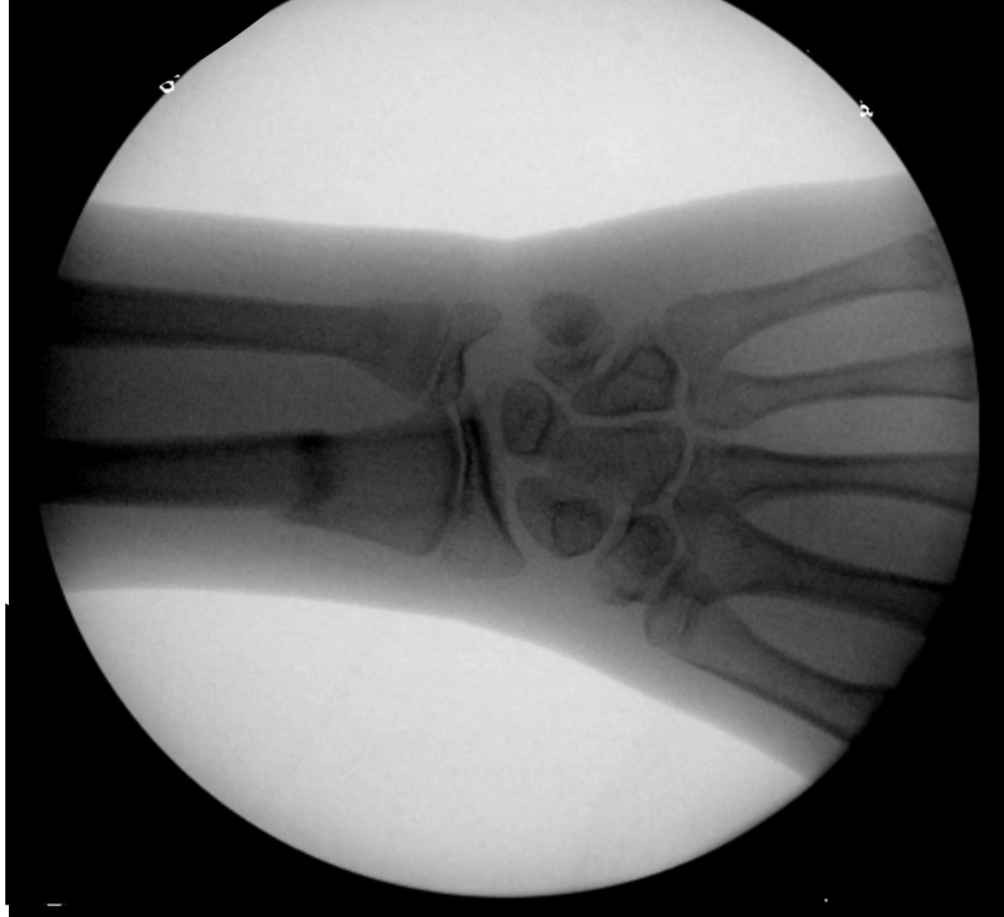

PERIOSTEUM

LOSS PROTECTION

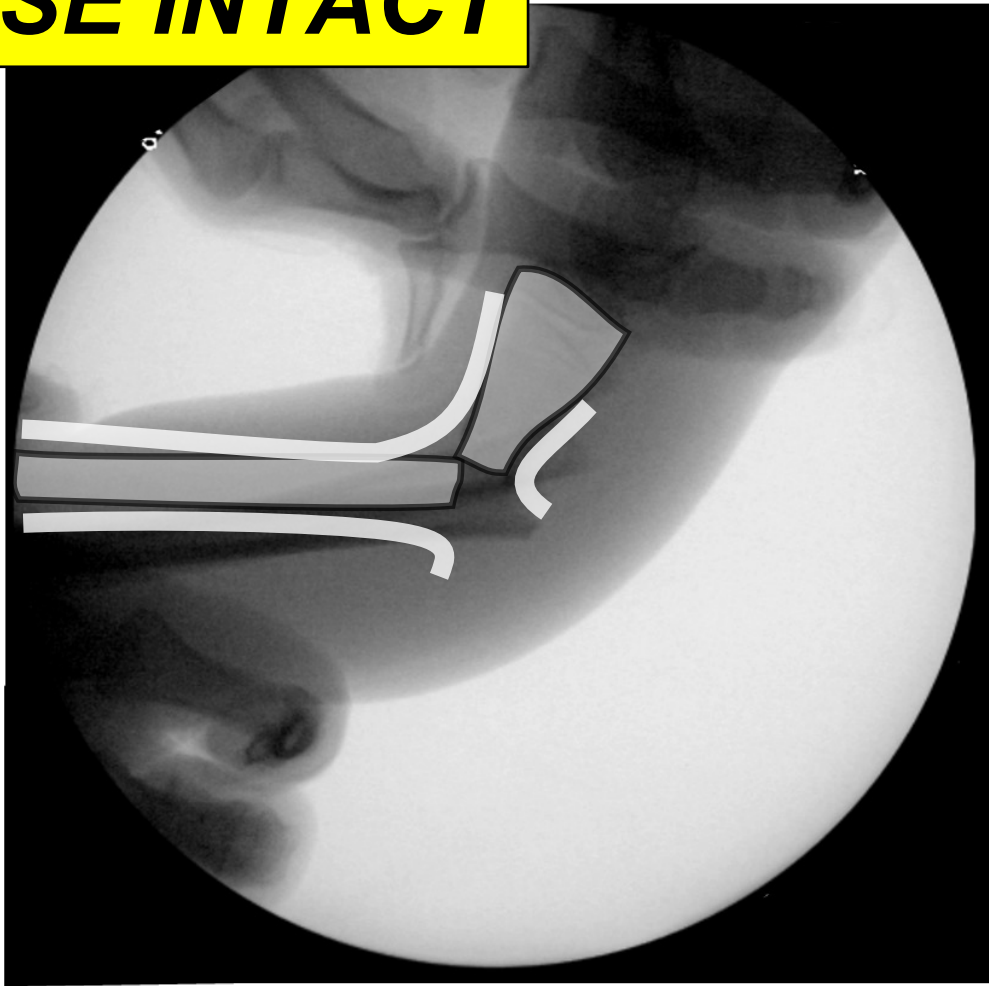


Collateral Damage

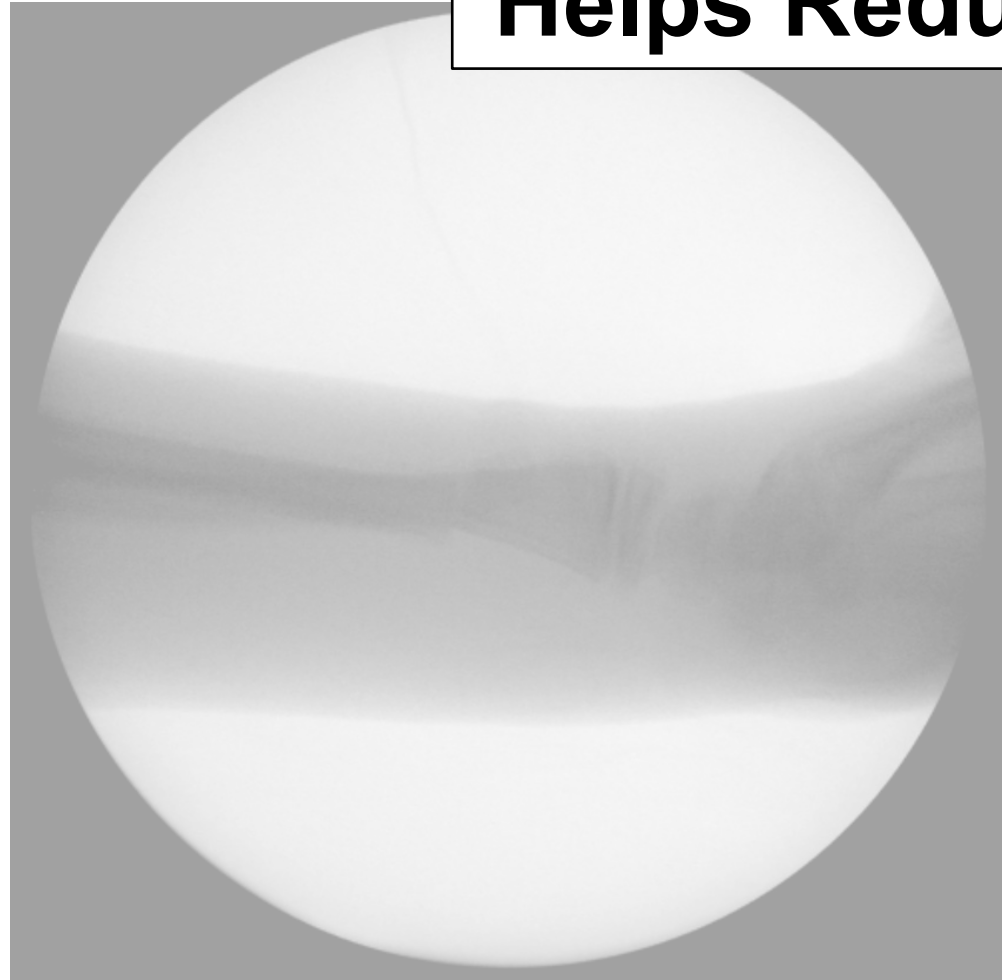


PERIOSTEUM

USE INTACT



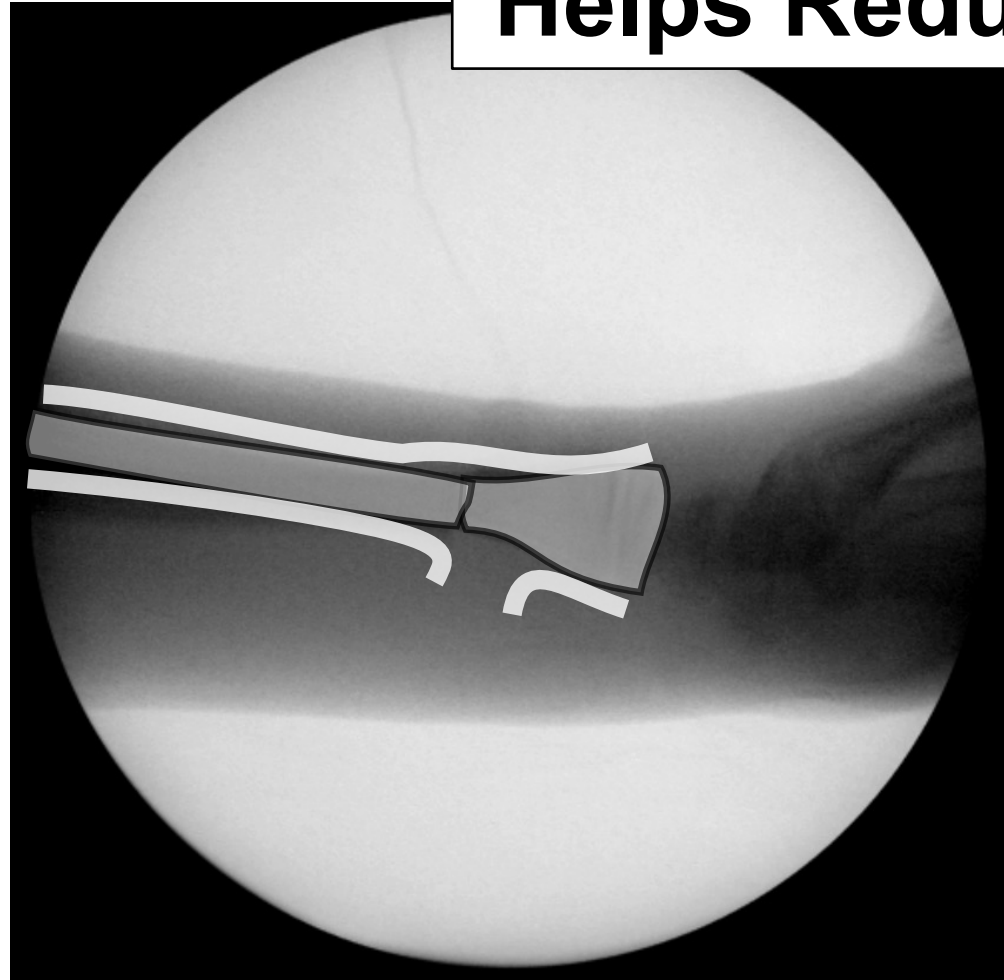
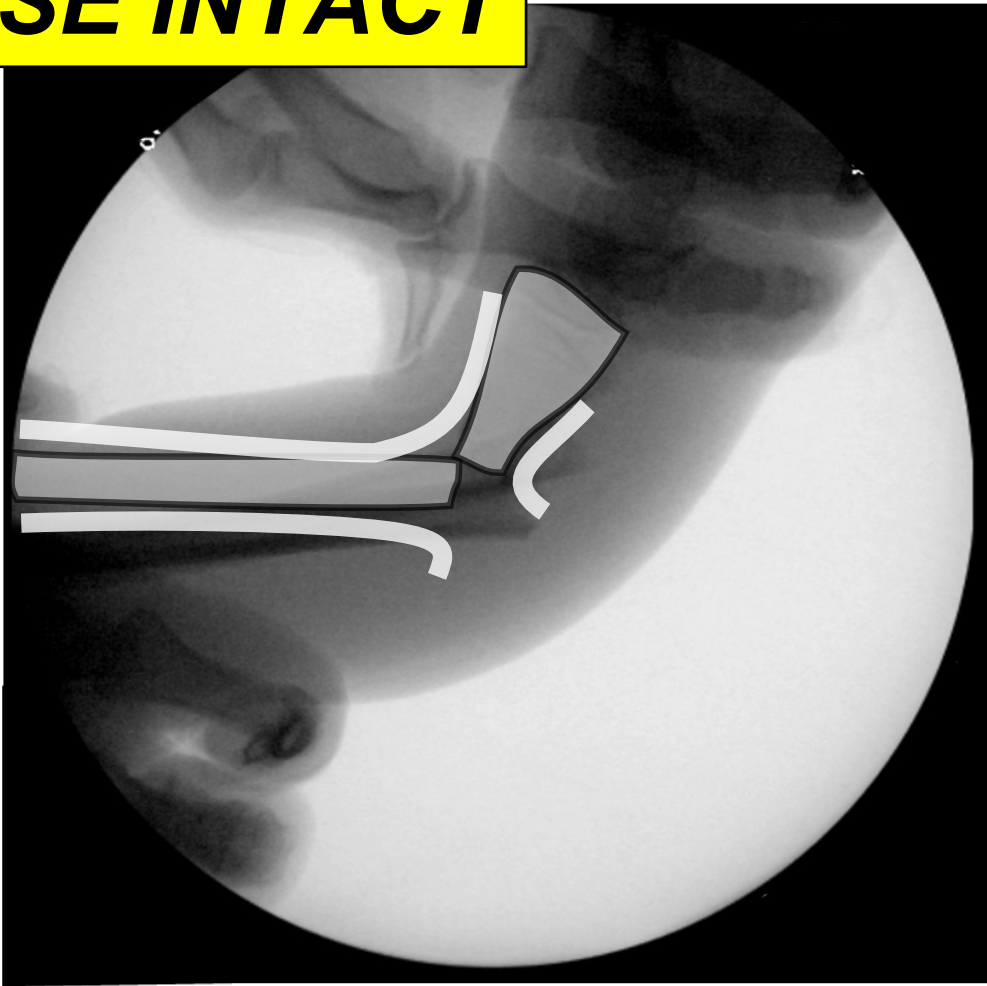
Helps Reduce



PERIOSTEUM

USE INTACT

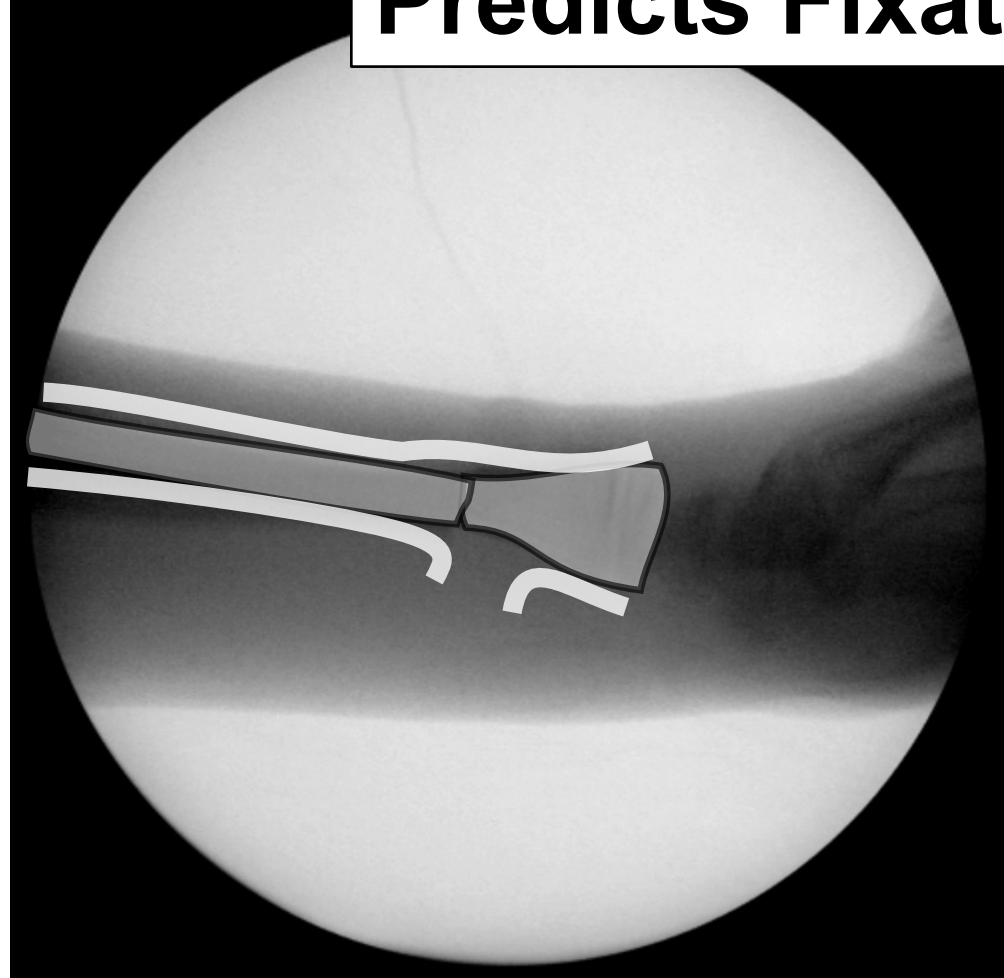
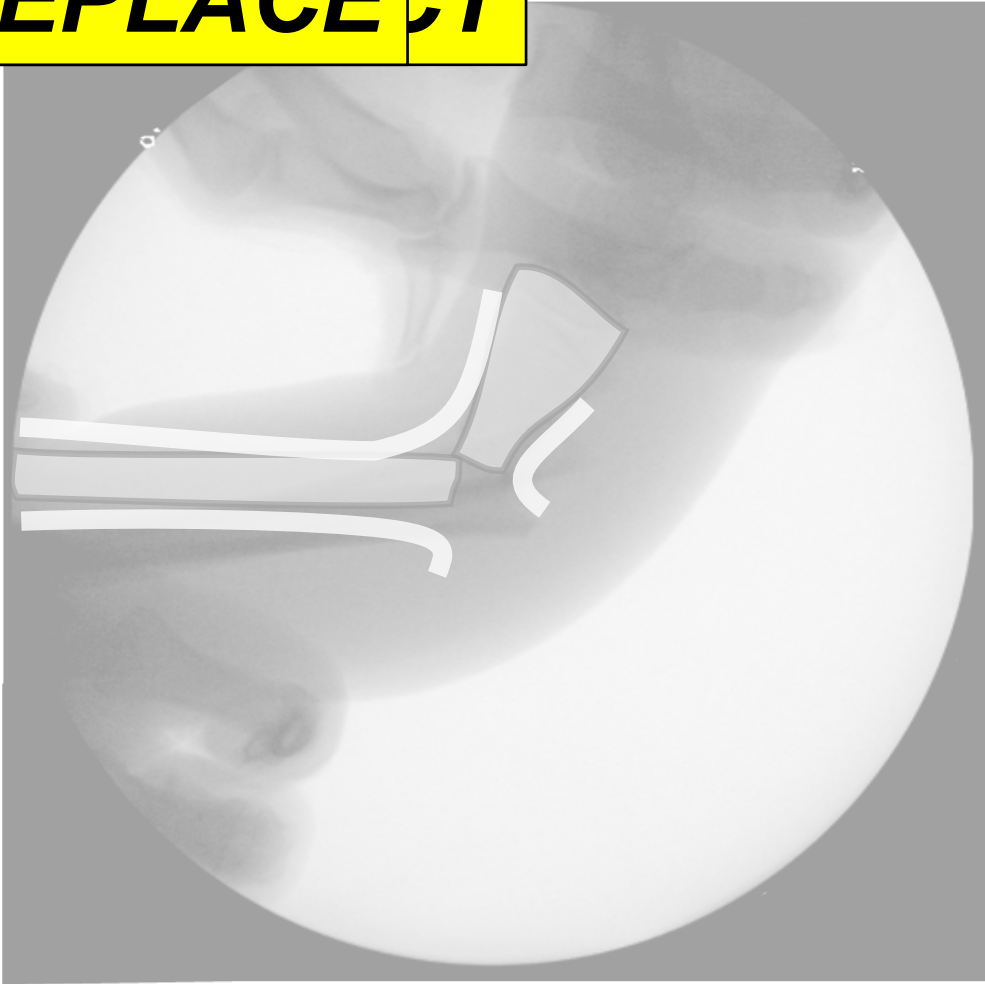Helps Reduce



PERIOSTEUM

REPLACE CT

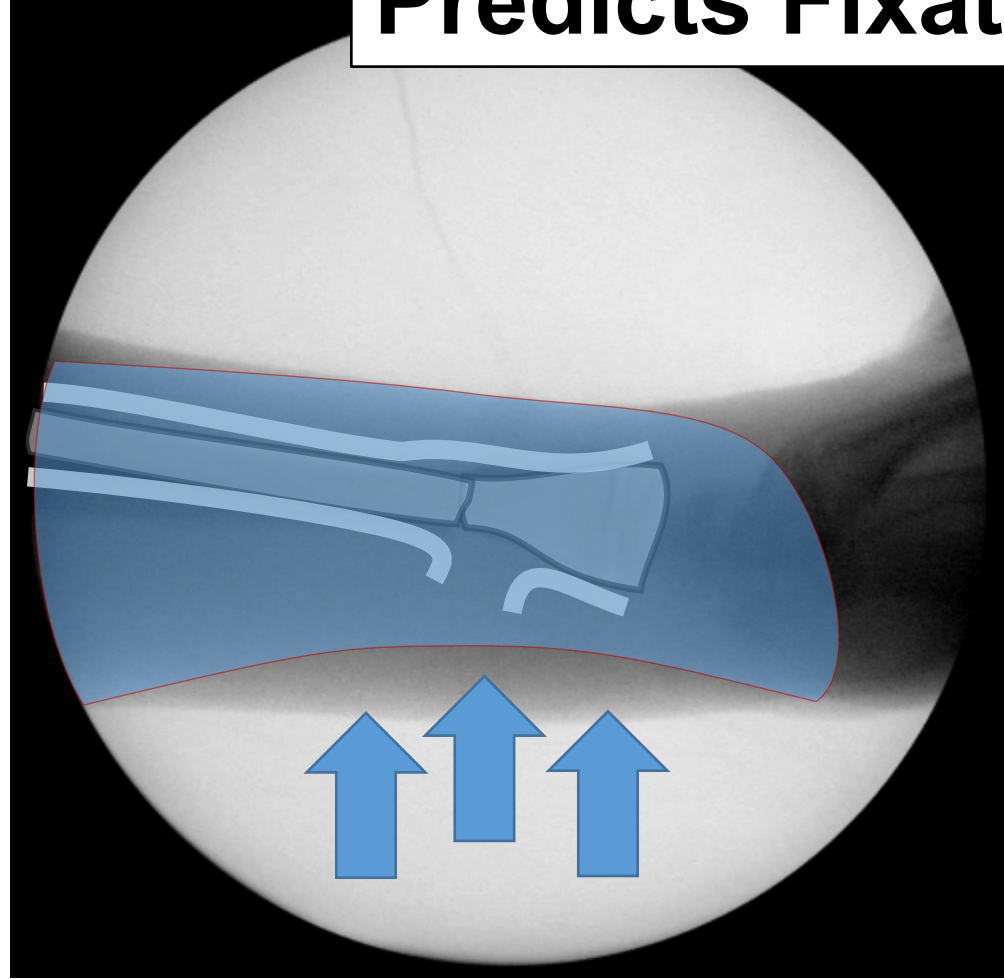
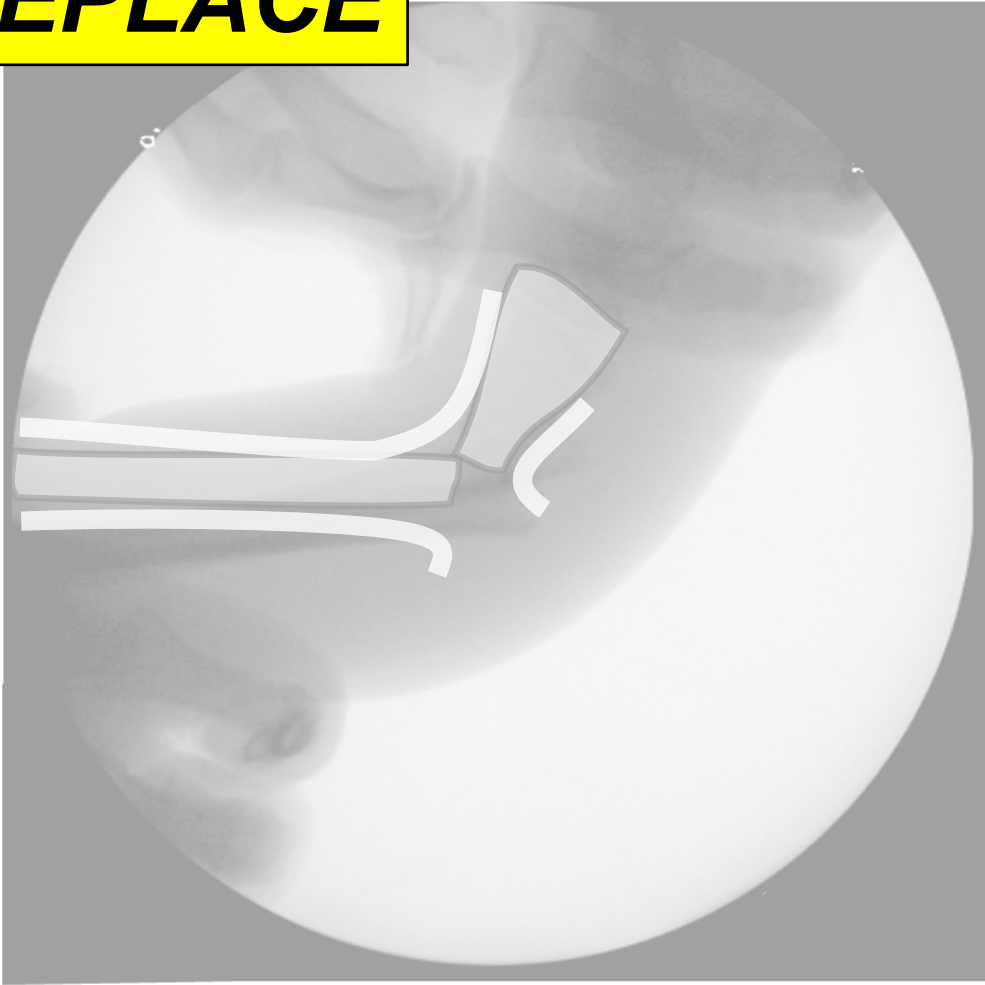Predicts Fixation



PERIOSTEUM

REPLACE

Predicts Fixation



PERIOSTEUM

Pediatric Elbow



Elbow

Team-Effort

What Is It Torn?

4 QUESTIONS

Elbow

Team-Effort

What Is It Torn?

Soft Tissues

4 QUESTIONS

Elbow

Team-Effort

What Is It Torn?

Soft Tissues

Periosteum

Capsule

Ligament

4 QUESTIONS

Elbow

Team-Effort

What Could Be Hurt?

Neurovascular

4 QUESTIONS

Elbow

Team-Effort

Where Is It Intact?

Sometimes Nowhere

Medial Condyle

Lateral

Condyle

4 QUESTIONS

Elbow

Team-Effort

How To Replace It?

Complex

Intra-Articular

Neurovascular

4 QUESTIONS

Elbow

Team-Effort

Where Is It Torn?

What Could Be Hurt?

Where Is It Intact?

How To Replace It?

4 QUESTIONS

Elbow
Pearls

Pattern Recognition

Elbow
Pearls

Pattern Recognition

Anatomy

Elbow
Pearls

Pattern Recognition

Anatomy

Pathomechanism

Elbow
Pearls

Pattern Recognition

Anatomy

Pathomechanism

Age

Elbow
Pearls

Pattern Recognition

Anatomy

Elbow
Pearls

Pattern Recognition

Anatomy

TRANSCONDYLAR AND UP

Elbow
Pearls

Pattern Recognition

Anatomy

TRANSCONDYLAR AND UP

LATERAL / RADIAL

Elbow
Pearls

Pattern Recognition

Anatomy

TRANSCONDYLAR AND UP

LATERAL / RADIAL

MEDIAL / ULNAR

Elbow
Pearls

Pattern Recognition

Pathomechanism

Elbow
Pearls

Pattern Recognition

Pathomechanism


Impaction



Elbow
Pearls

Pattern Recognition
Pathomechanism

*Impaction
Distraction*




Elbow
Pearls

Pattern Recognition
Pathomechanism

Impaction

Distraction

Flexion/Extension



Elbow
Pearls


Pattern Recognition
Pathomechanism

Impaction

Distraction

Flexion/Extension

Varus/Valgus



Elbow
Pearls

Pattern Recognition
Pathomechanism


Impaction

Distraction

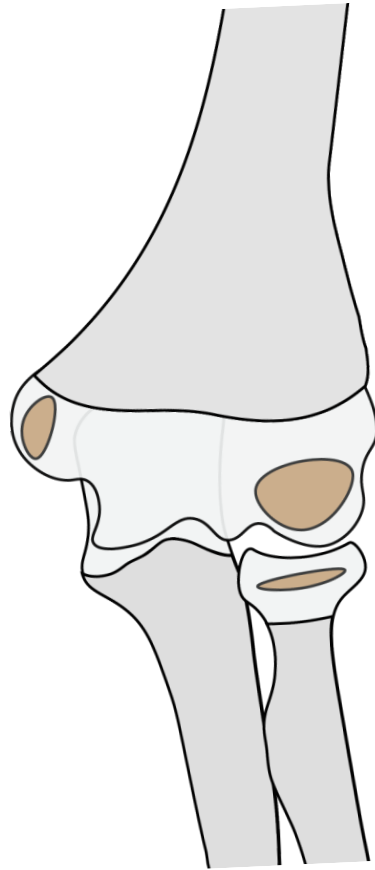
Flexion/Extension

Varus/Valgus

Rotation

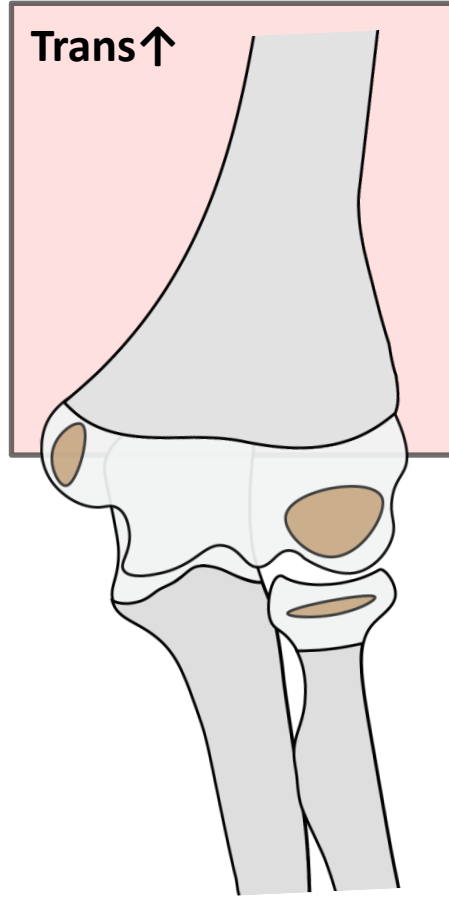


Elbow Pearls



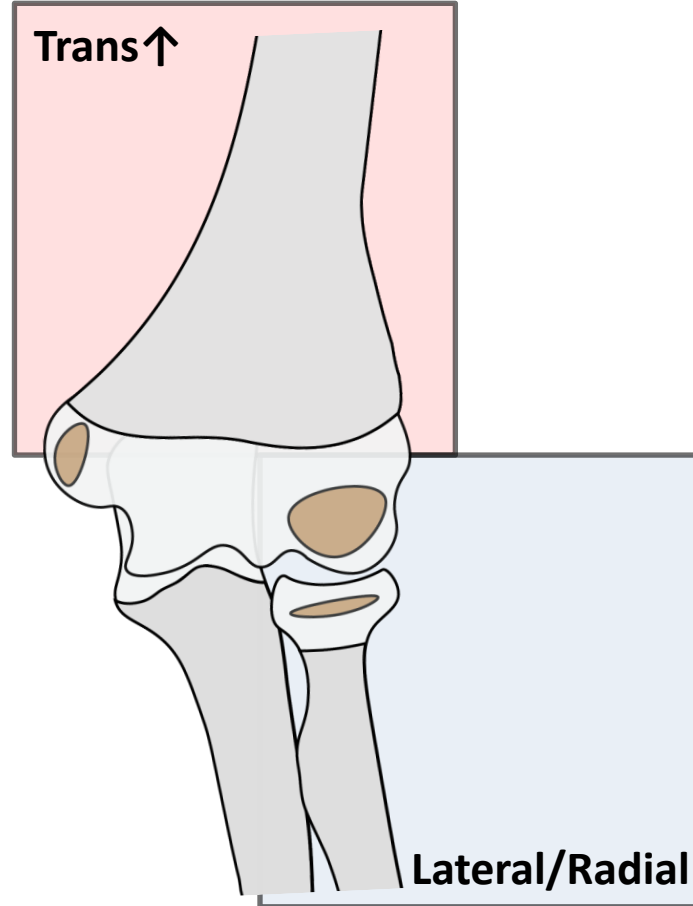
Pattern Recognition

Elbow Pearls



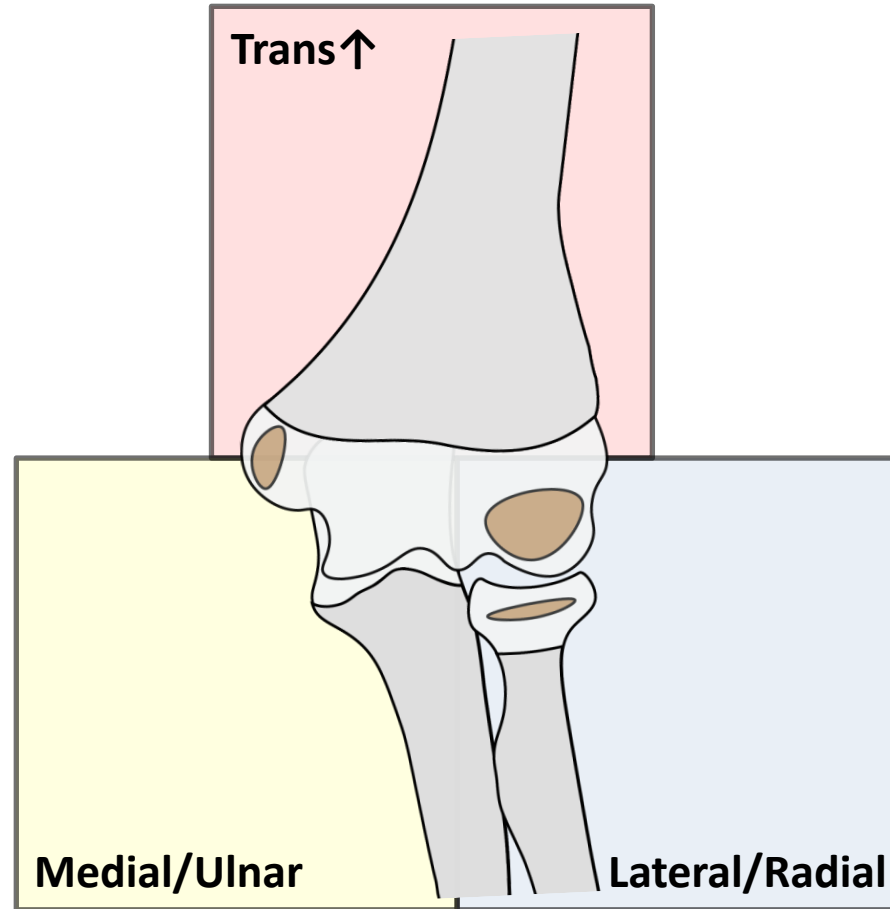
Pattern Recognition

Elbow Pearls



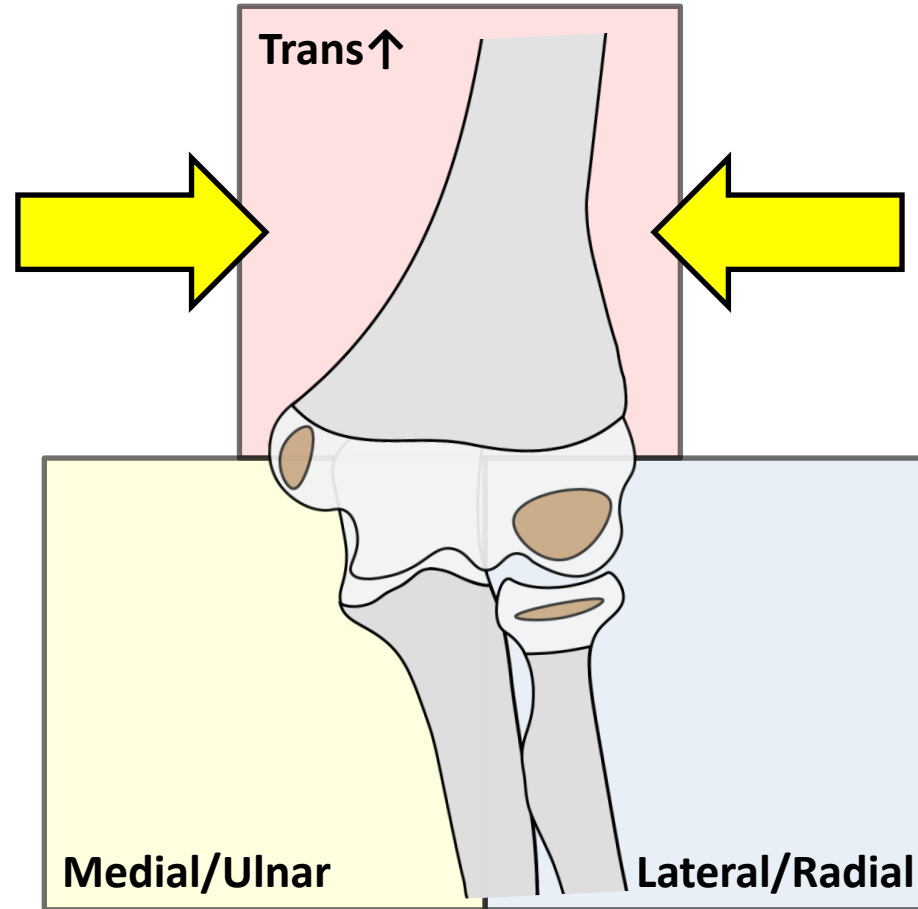
Pattern Recognition

Elbow Pearls



Pattern Recognition

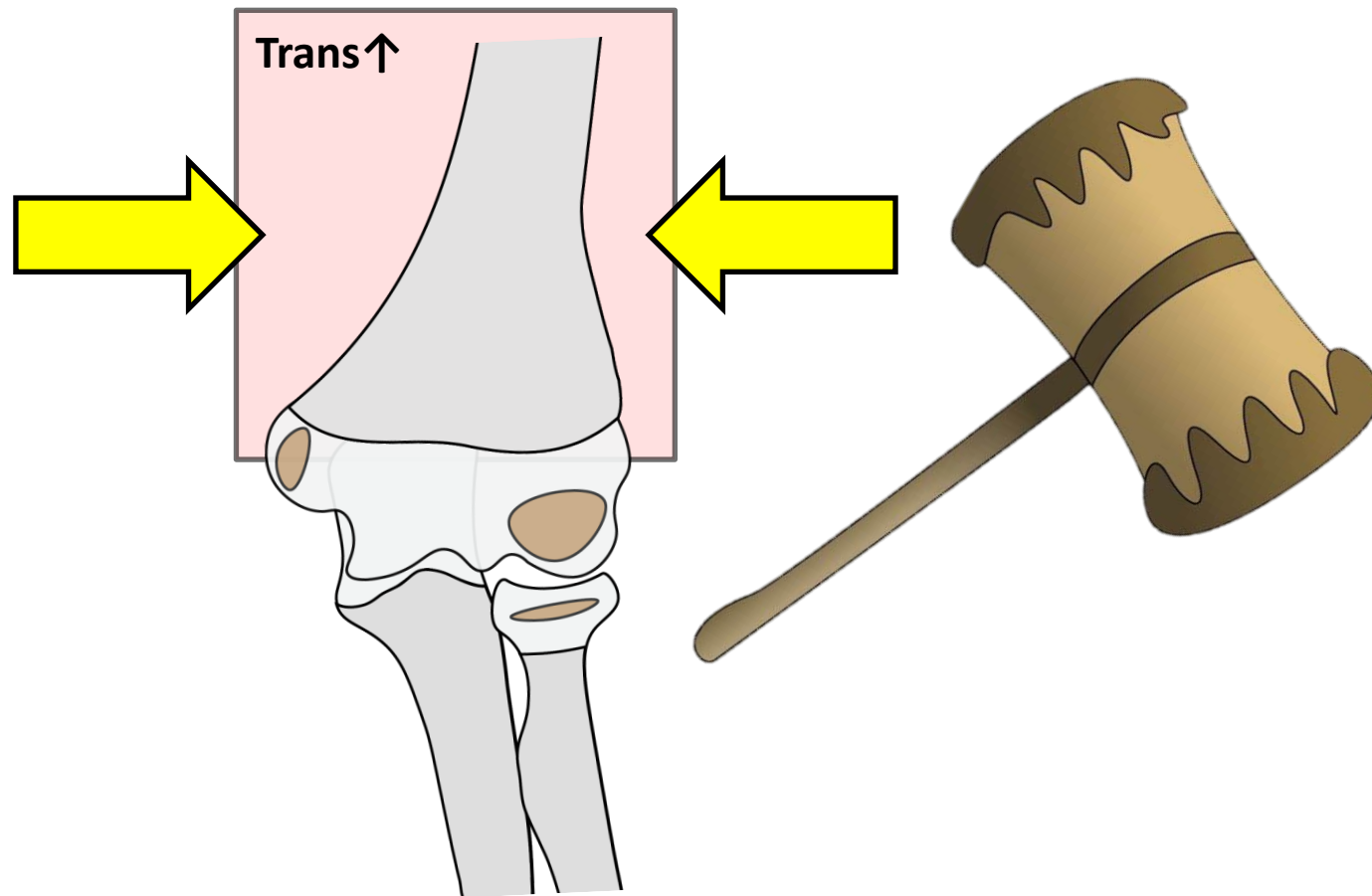
Elbow Pearls *TRANSCONDYLAR AND UP*



Pattern Recognition

Elbow Pearls

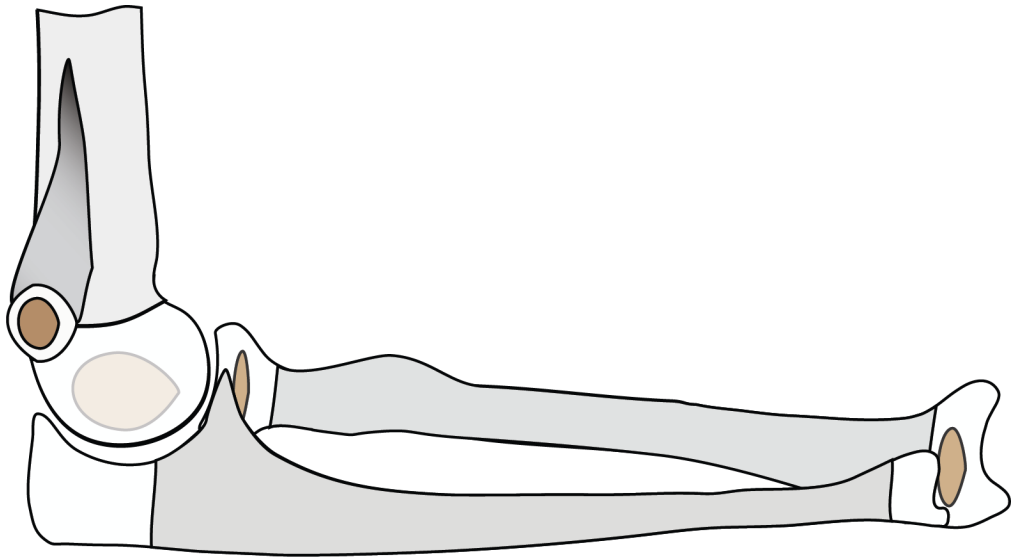
TRANSCONDYLAR AND UP - *IMPACTION*



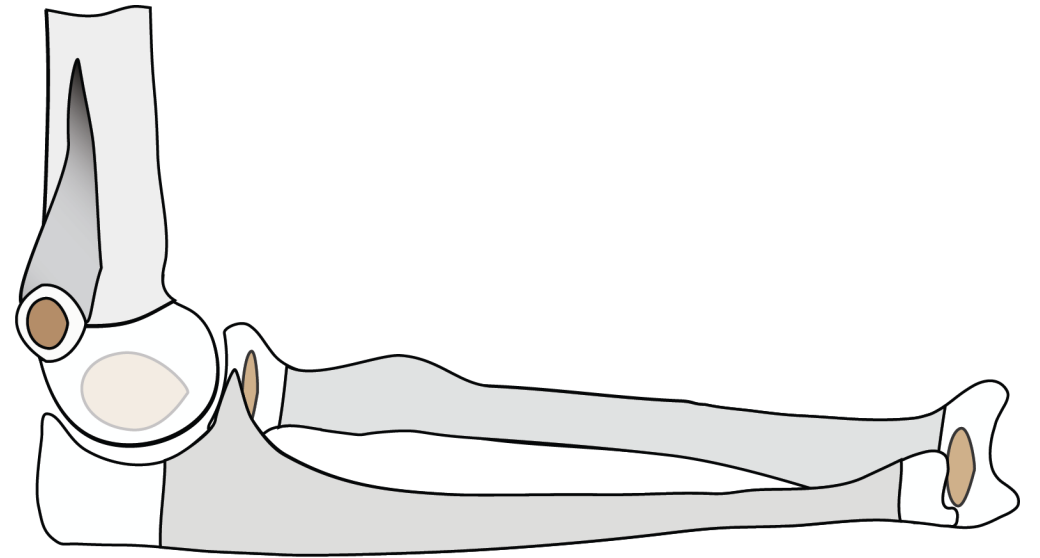
Elbow

Pearls

TRANSCONDYLAR AND UP - IMPACTION



Extension

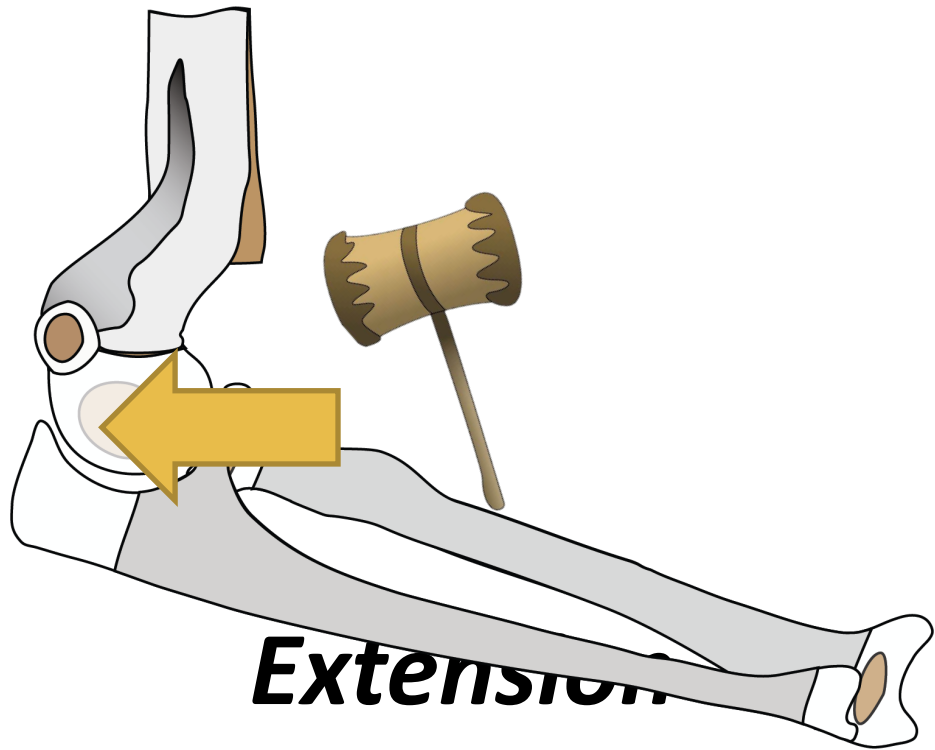


Flexion

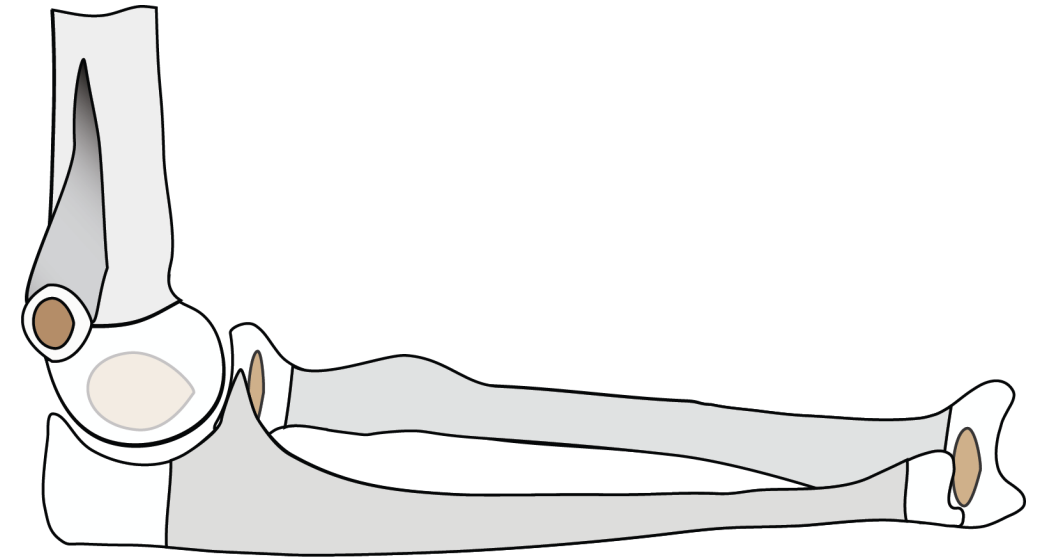
Supracondylar Humerus

Pattern Recognition

Elbow Pearls *TRANSCONDYLAR AND UP - IMPACTION*



Extension

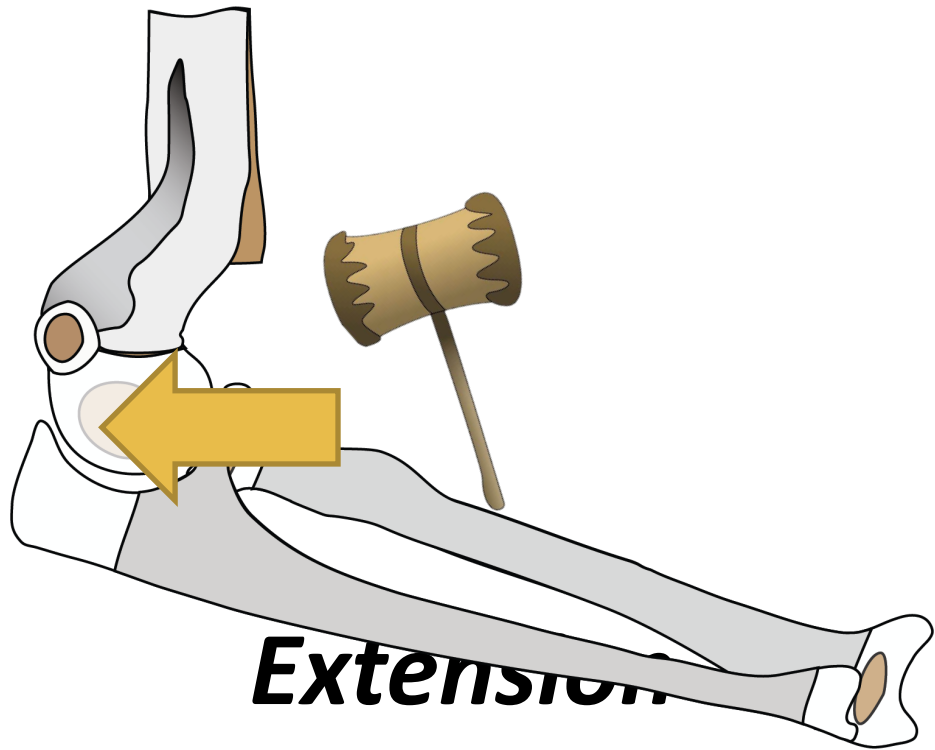


Flexion

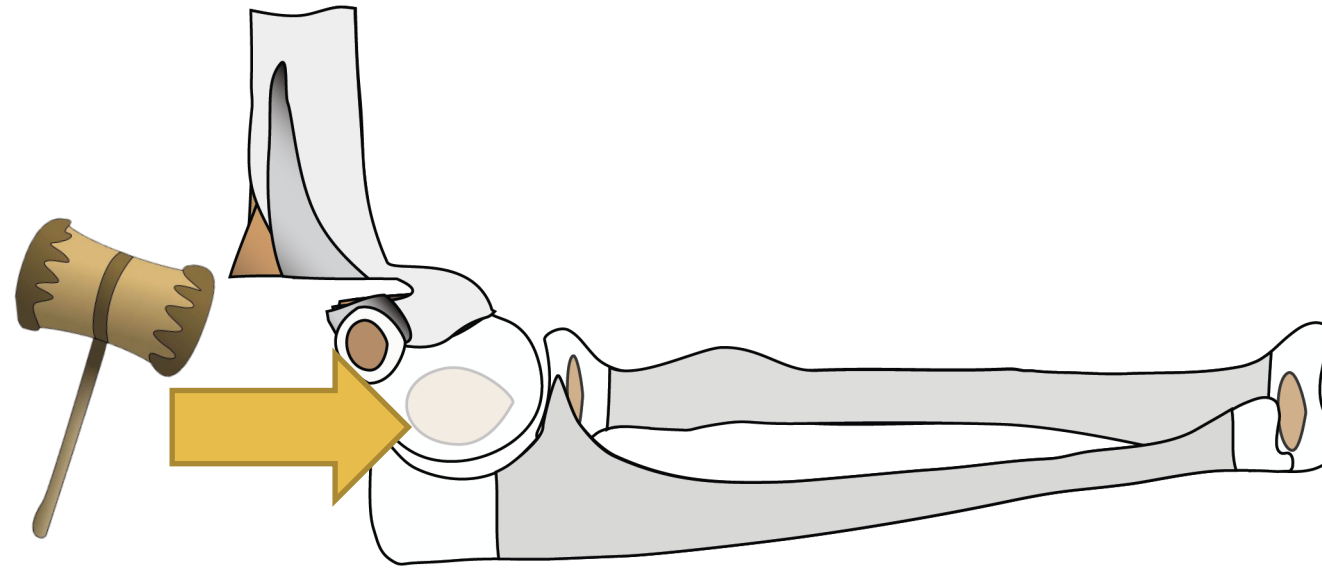
Supracondylar Humerus

Pattern Recognition

Elbow Pearls *TRANSCONDYLAR AND UP - IMPACTION*



Extension

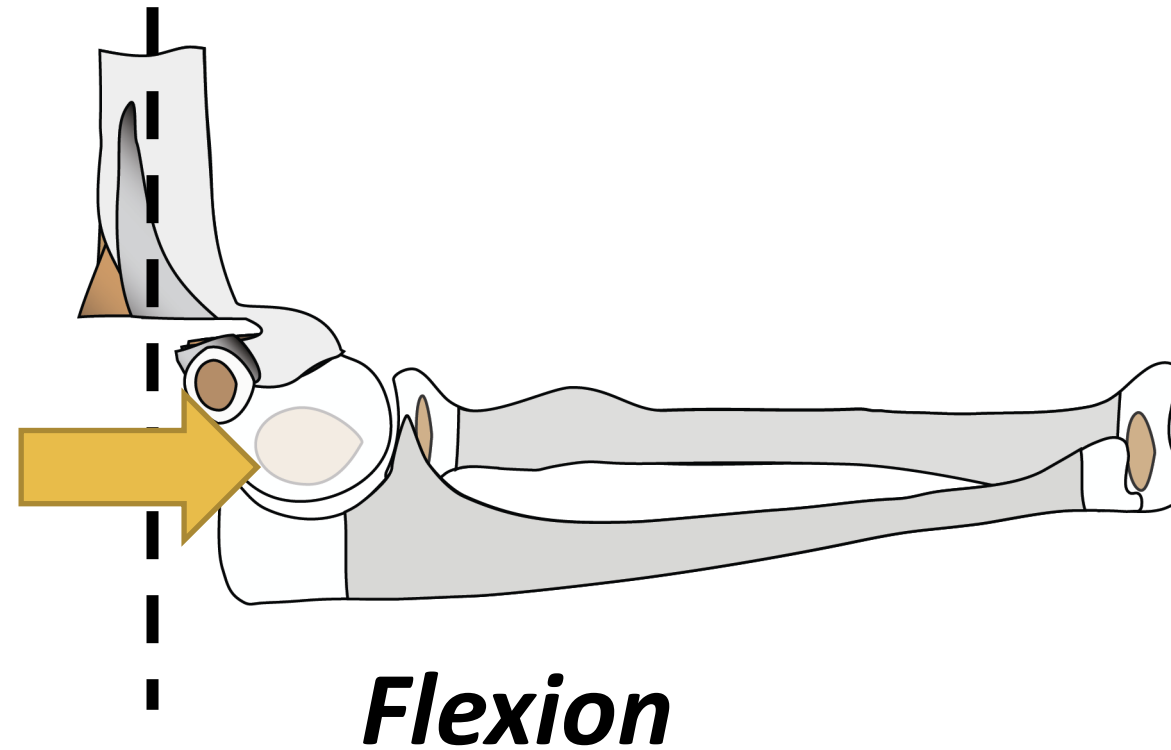
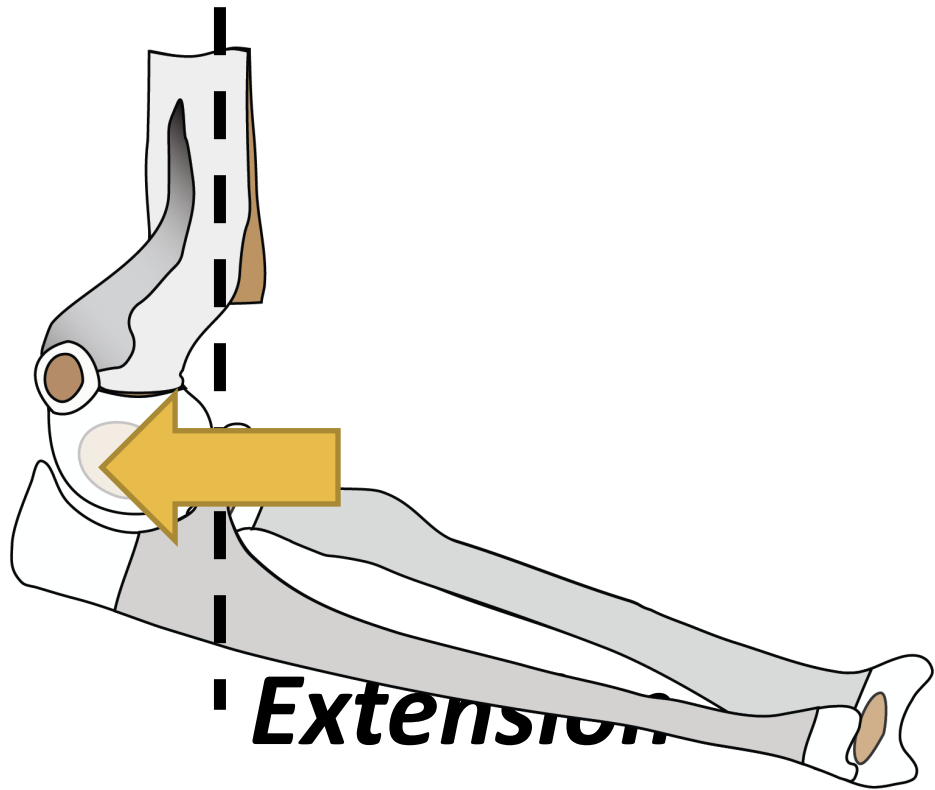


Flexion

Supracondylar Humerus

Pattern Recognition

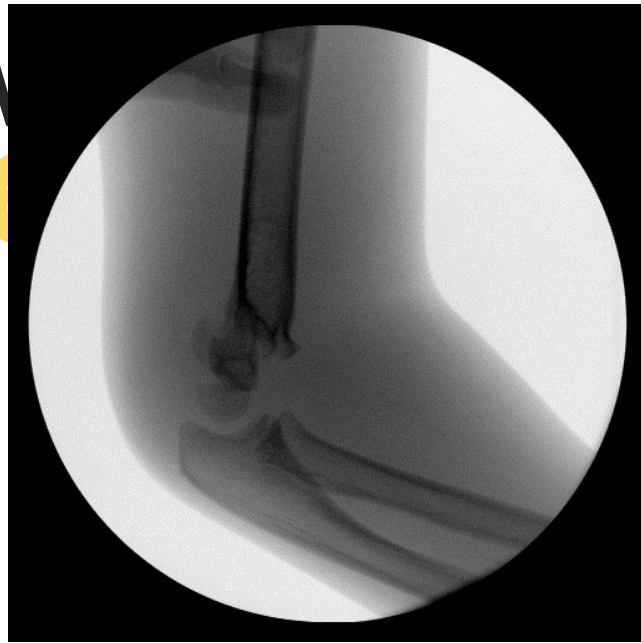
Elbow Pearls *TRANSCONDYLAR AND UP - IMPACTION*



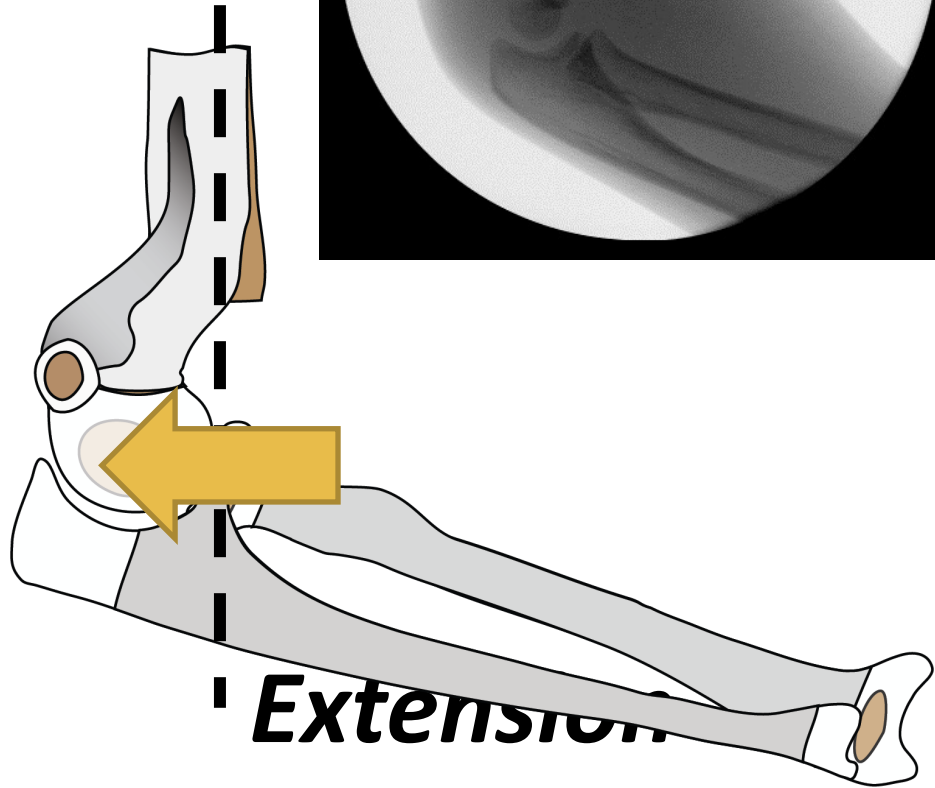
Supracondylar Humerus

Pattern Recognition

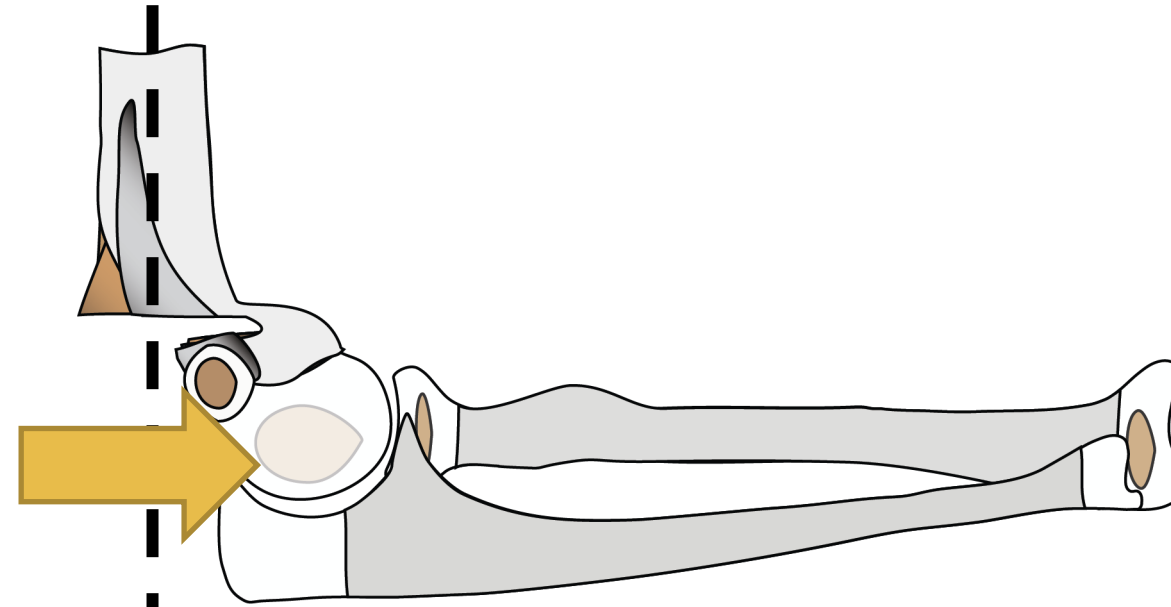
Elbow
PO



SCONDYLAR AND UP - **IMPACTION**



Extension

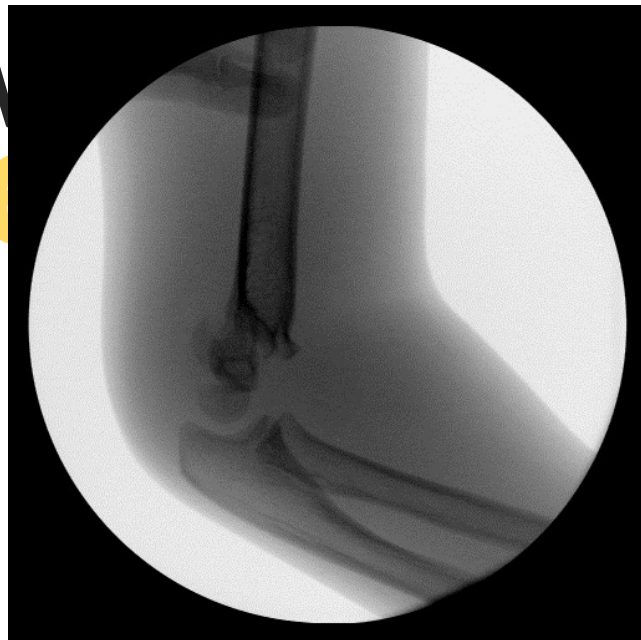

Flexion

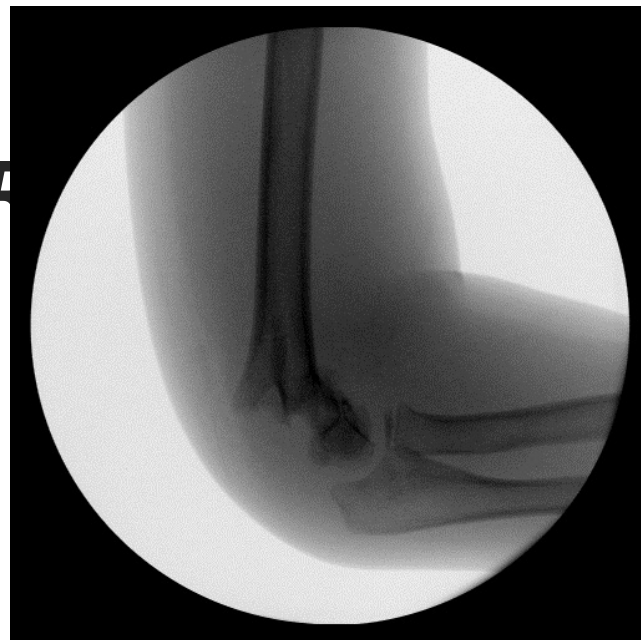Supracondylar Humerus

Pattern Recognition

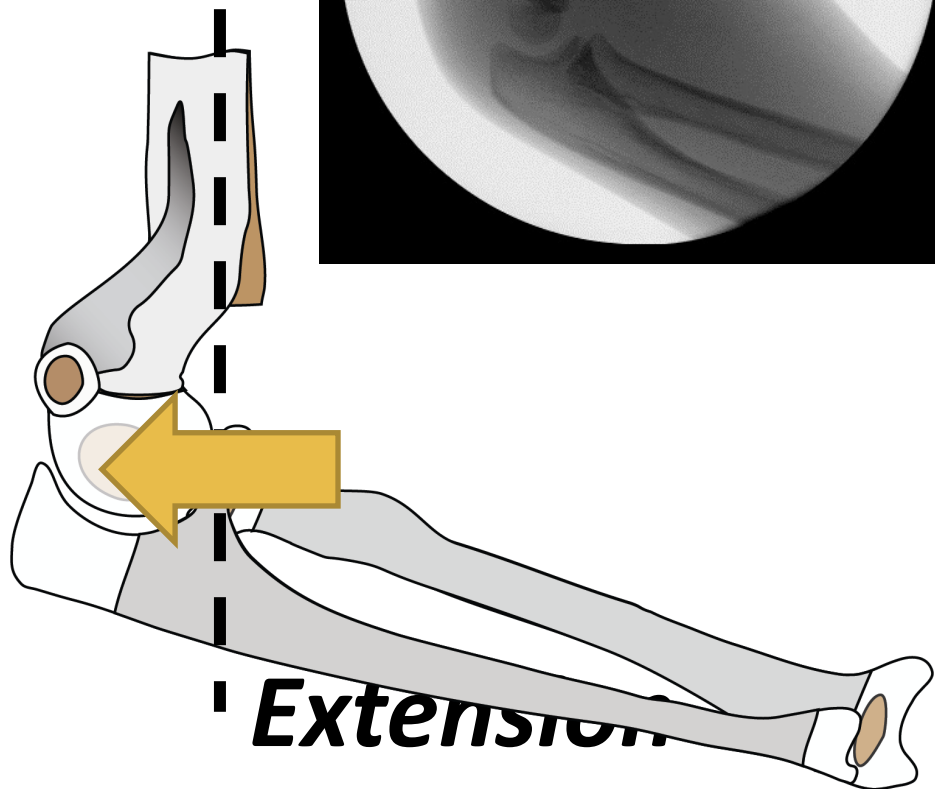
Elbow
P



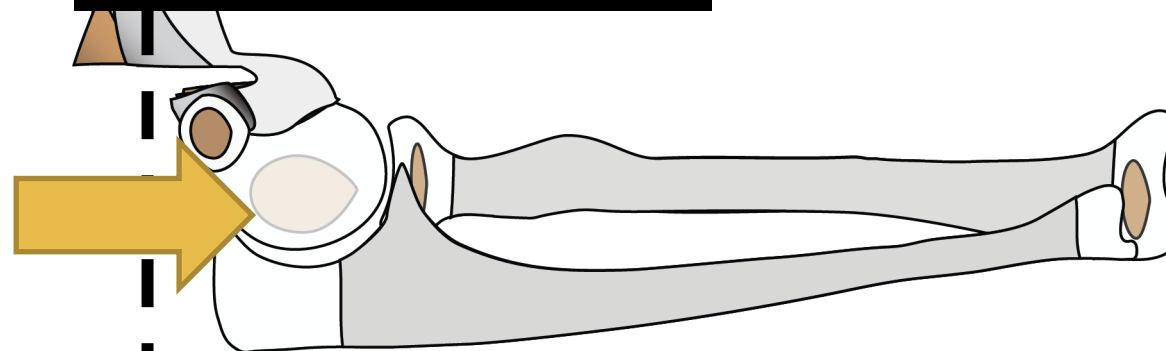
SCONDYLAR



PACTION



Extension

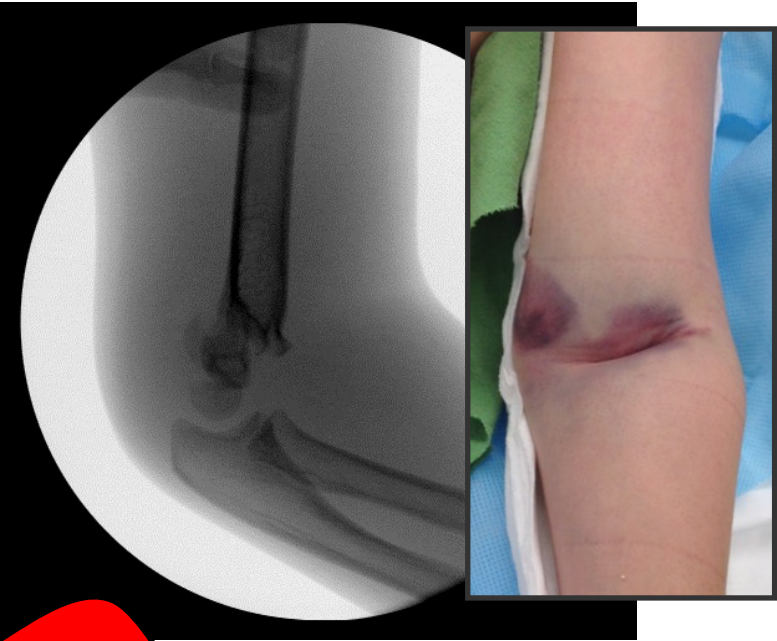


Flexion

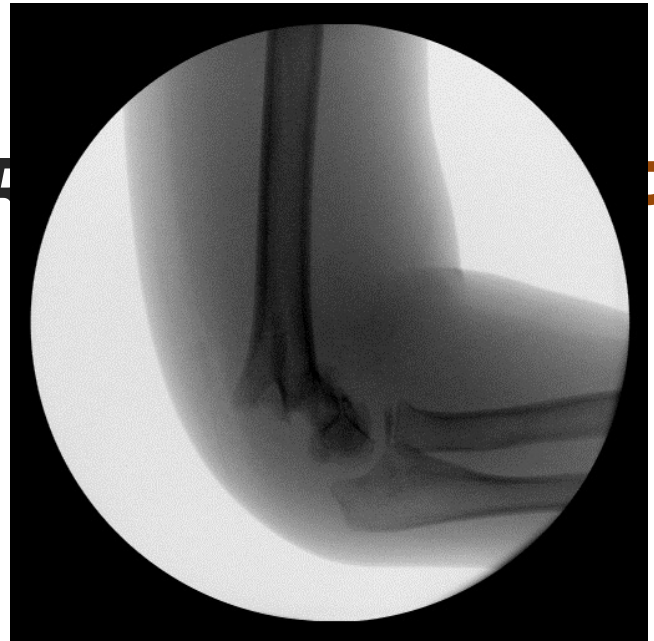Supracondylar Humerus

Pattern Recognition

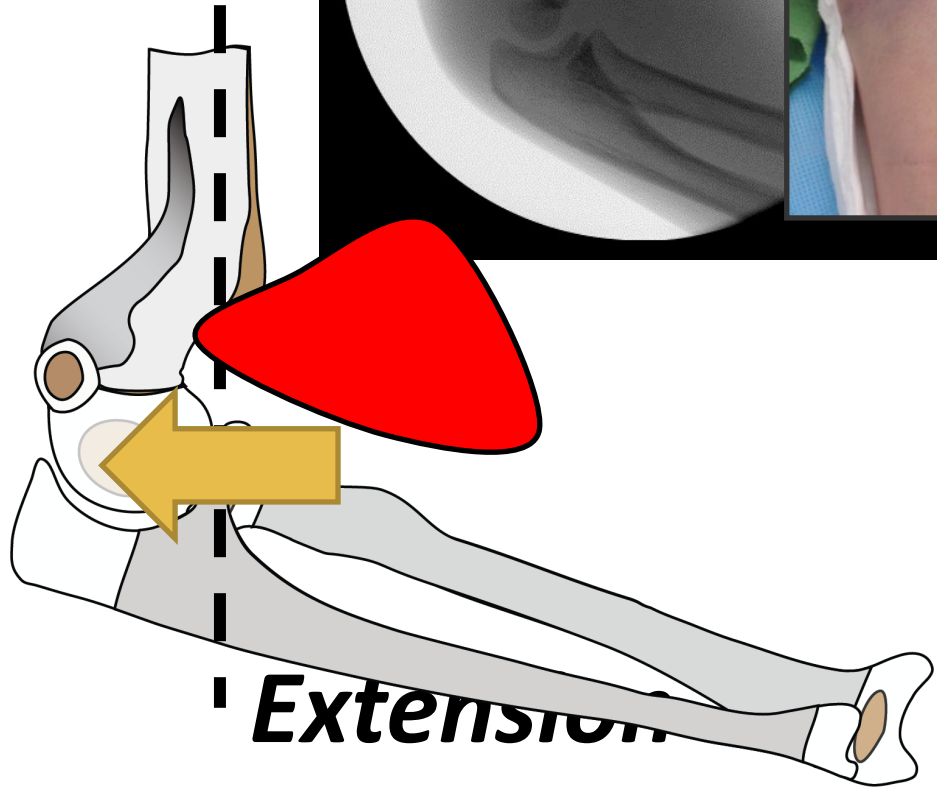
Elbow
PO



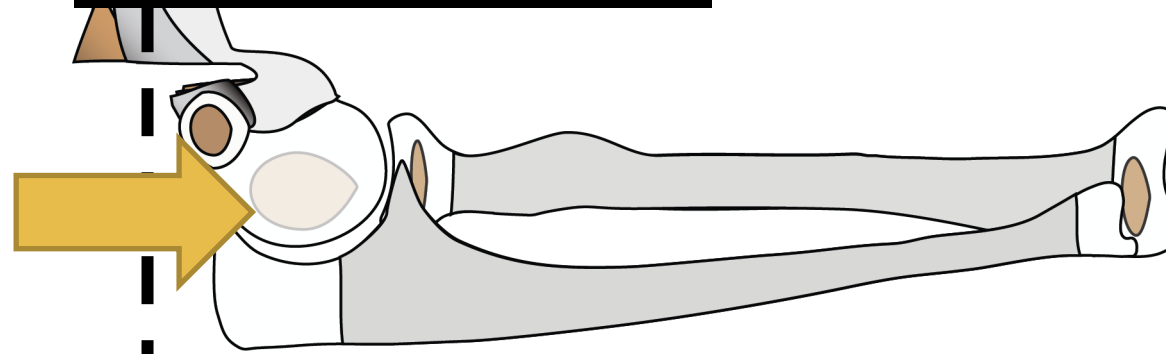
CONDYLAR



TRACTION



Extension



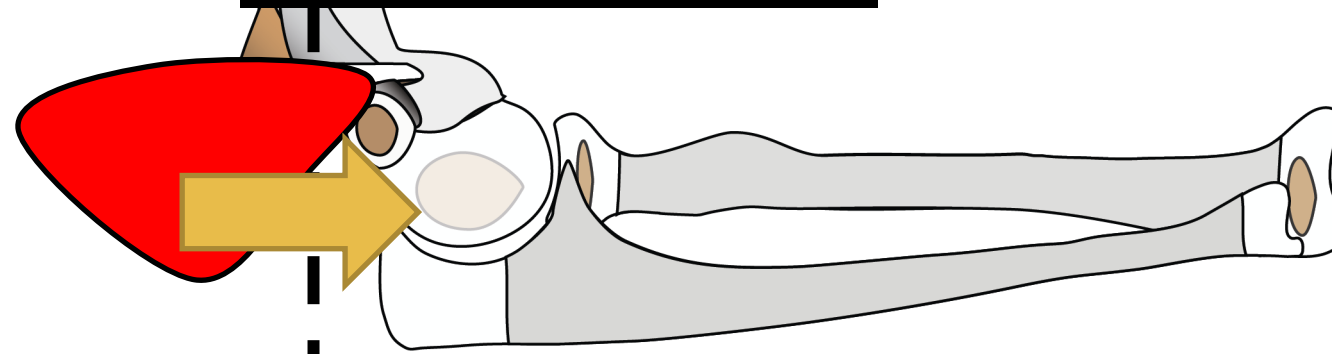
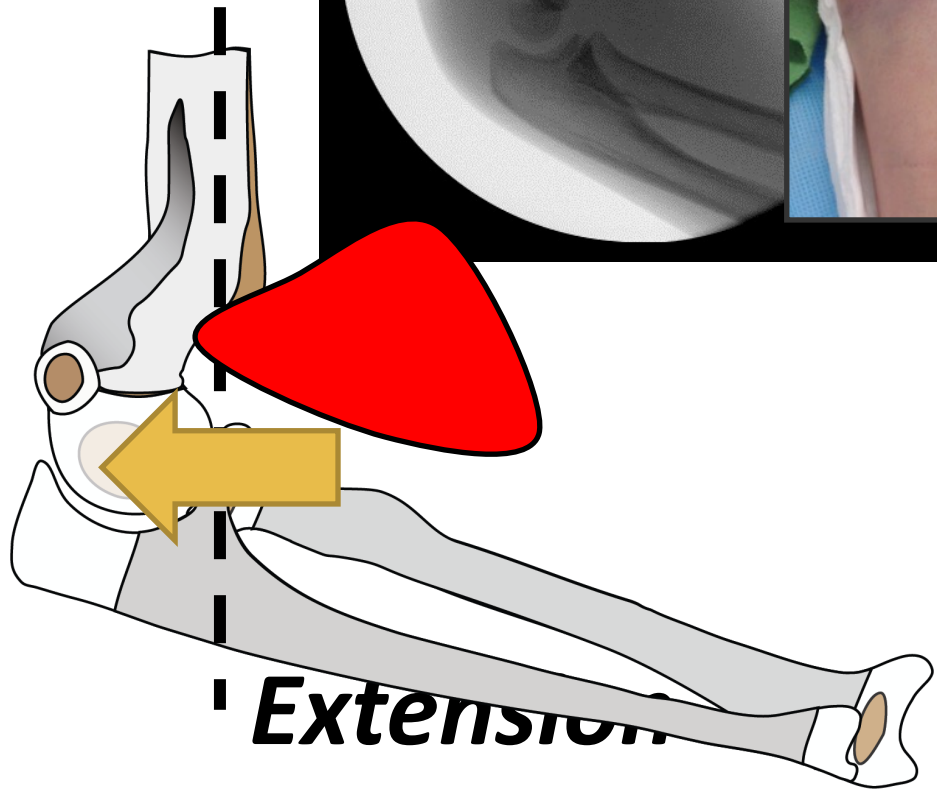
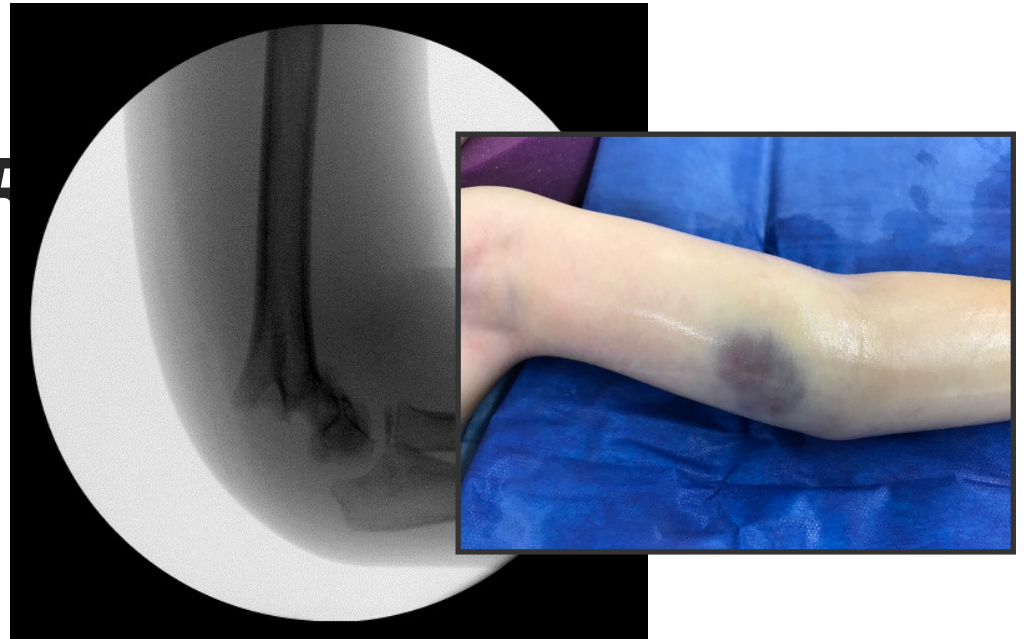
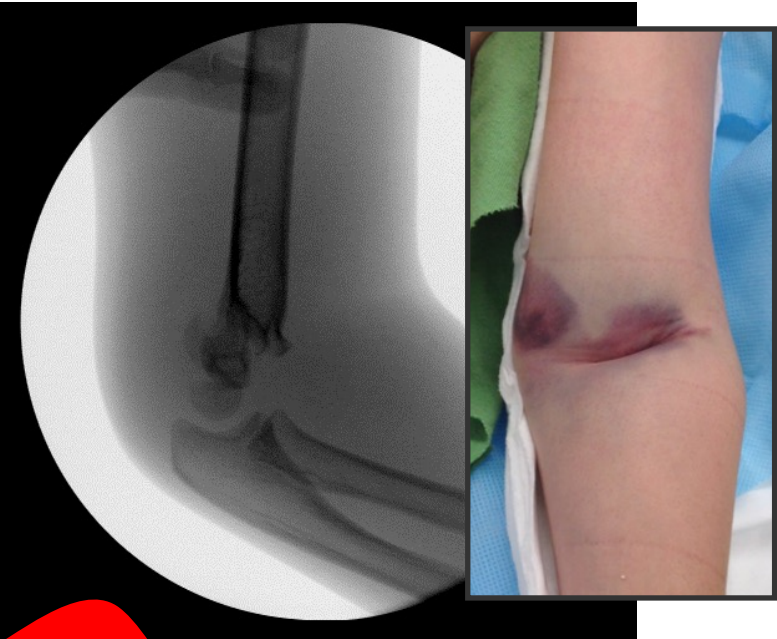
Flexion

Supracondylar Humerus

Pattern Recognition

Elbow
PO

CONDYLAR



Extension

Flexion

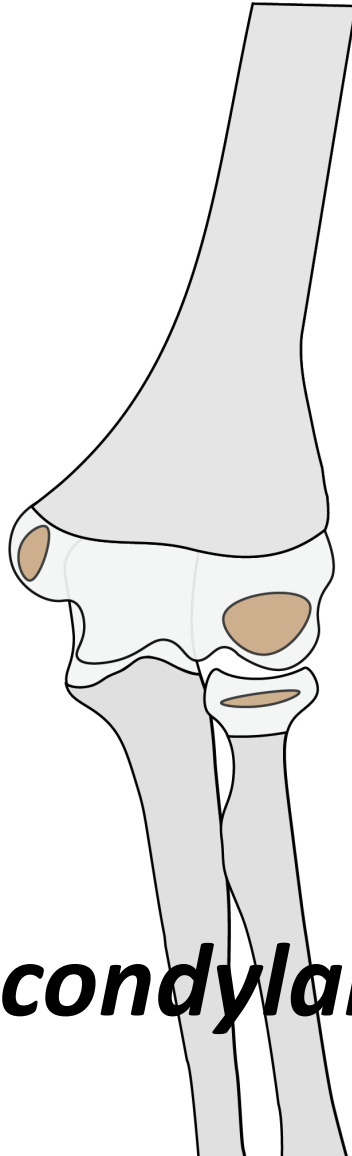
Supracondylar Humerus

Pattern Recognition

Elbow

Pearls

TRANSCONDYLAR AND UP - *IMPACTION*



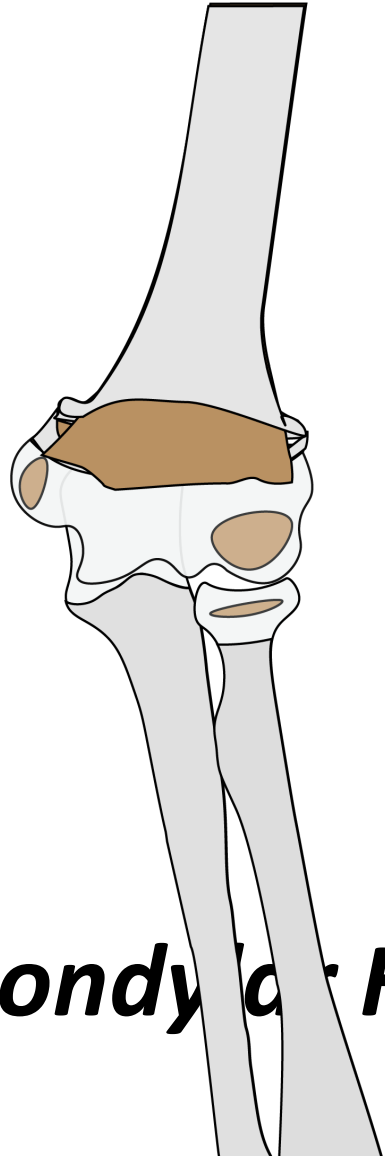
Extension Supracondylar Humerus

Pattern Recognition

Elbow

Pearls

TRANSCONDYLAR AND UP - IMPACTION

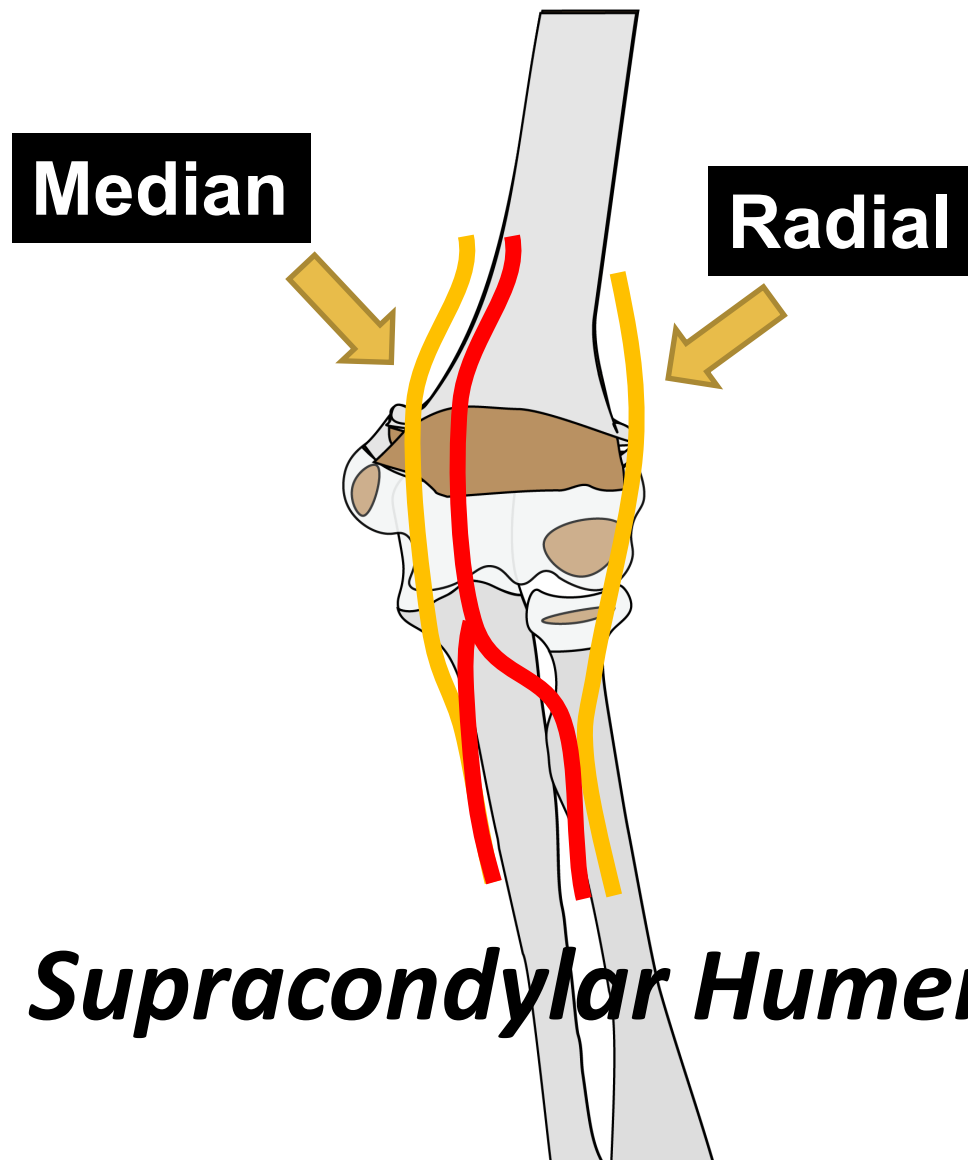


Extension Supracondylar Fracture of Humerus

Pattern Recognition

Elbow Pearls

TRANSCONDYLAR AND UP - *IMPACTION*



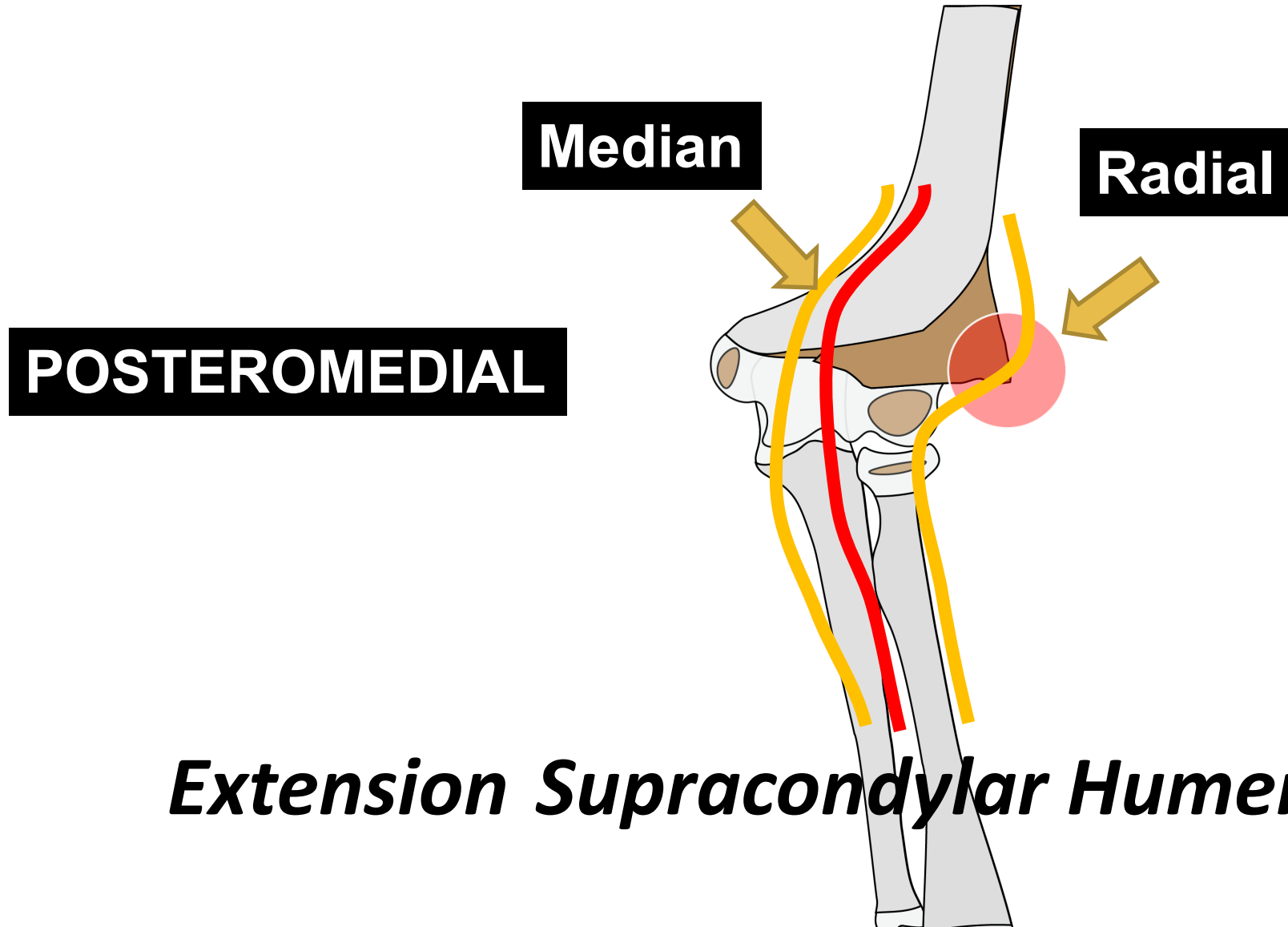
Extension Supracondylar Humerus

Pattern Recognition

Elbow

Pearls

TRANSCONDYLAR AND UP - IMPACTION

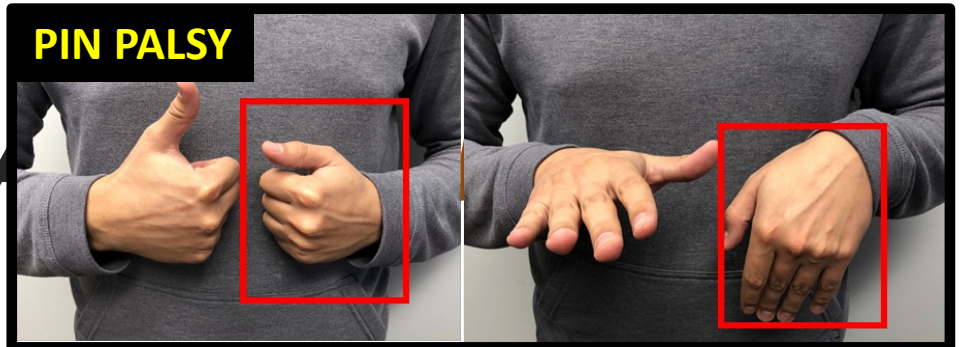


Extension Supracondylar Humerus

Pattern Recognition

Elbow Pearls

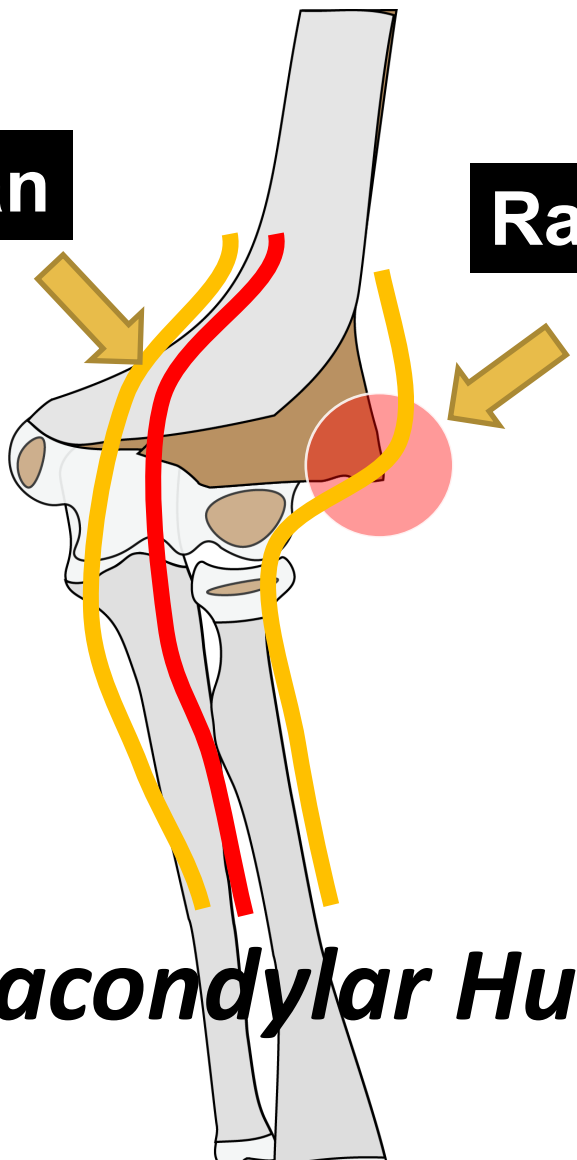
TRANSCONDYLAR A



Median

Radial

POSTEROMEDIAL

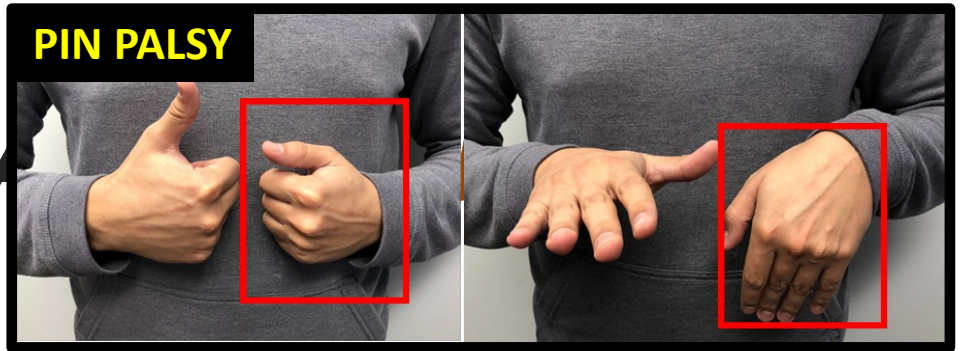


Extension Supracondylar Humerus

Pattern Recognition

Elbow Pearls

TRANSCONDYLAR



Median

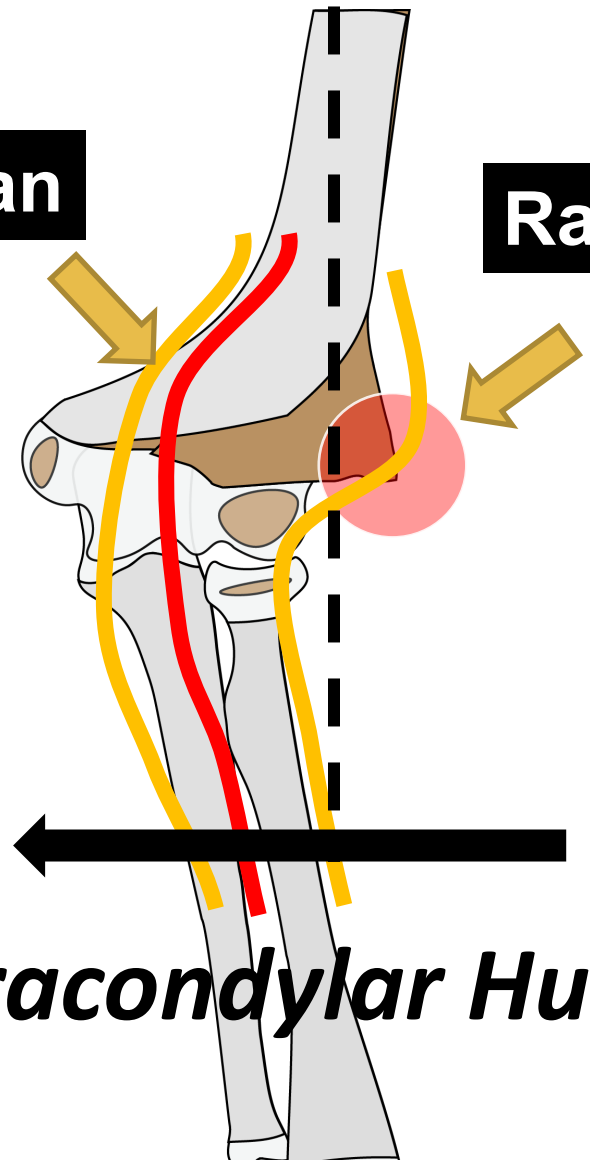
Radial

POSTEROMEDIAL

Capitellum Is Medial

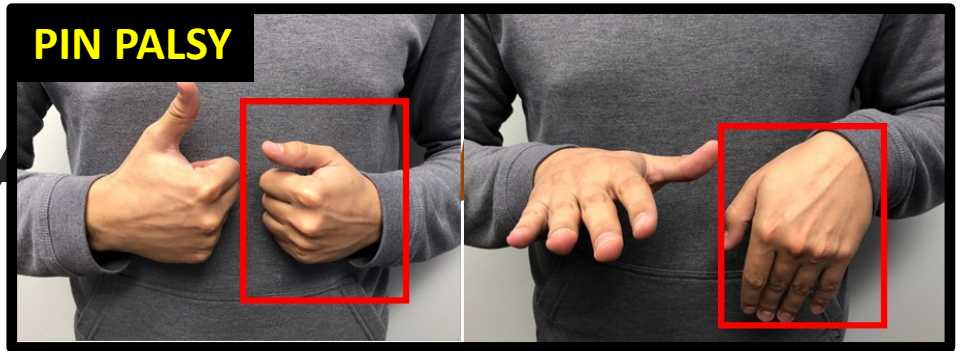
Extension Supracondylar Humerus

Pattern Recognition



Elbow Pearls

TRANSCONDYLAR



Median

Radial

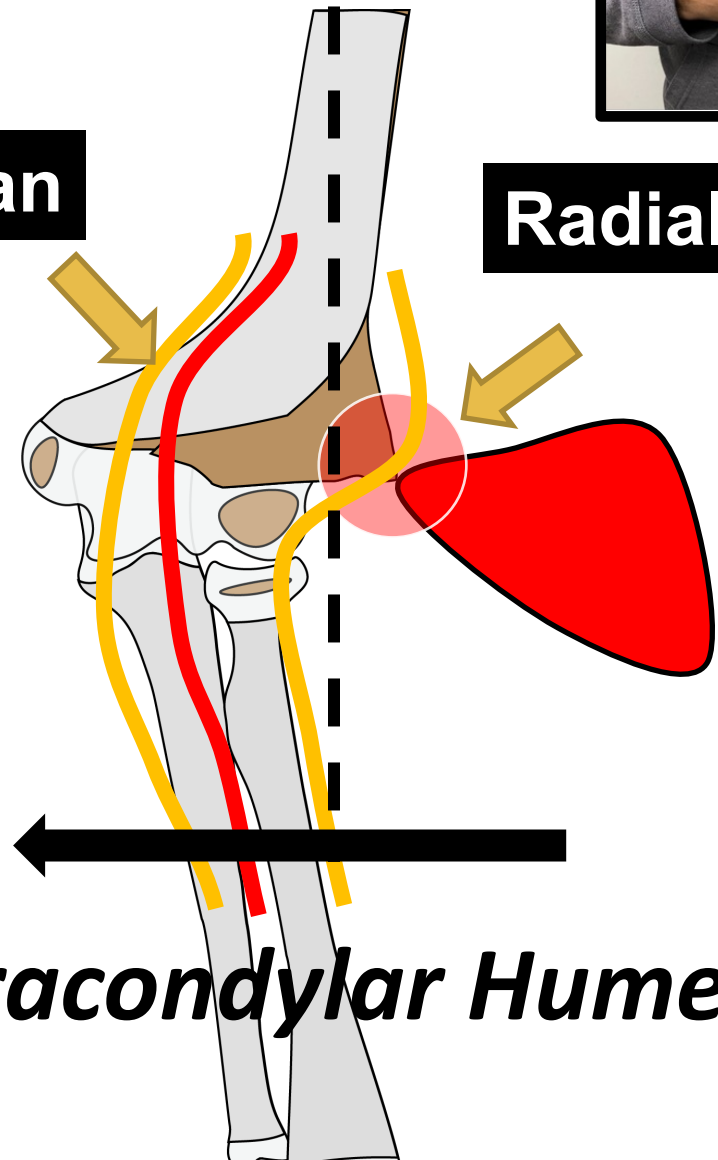
POSTEROMEDIAL

Bruise Is Lateral

Capitellum Is Medial

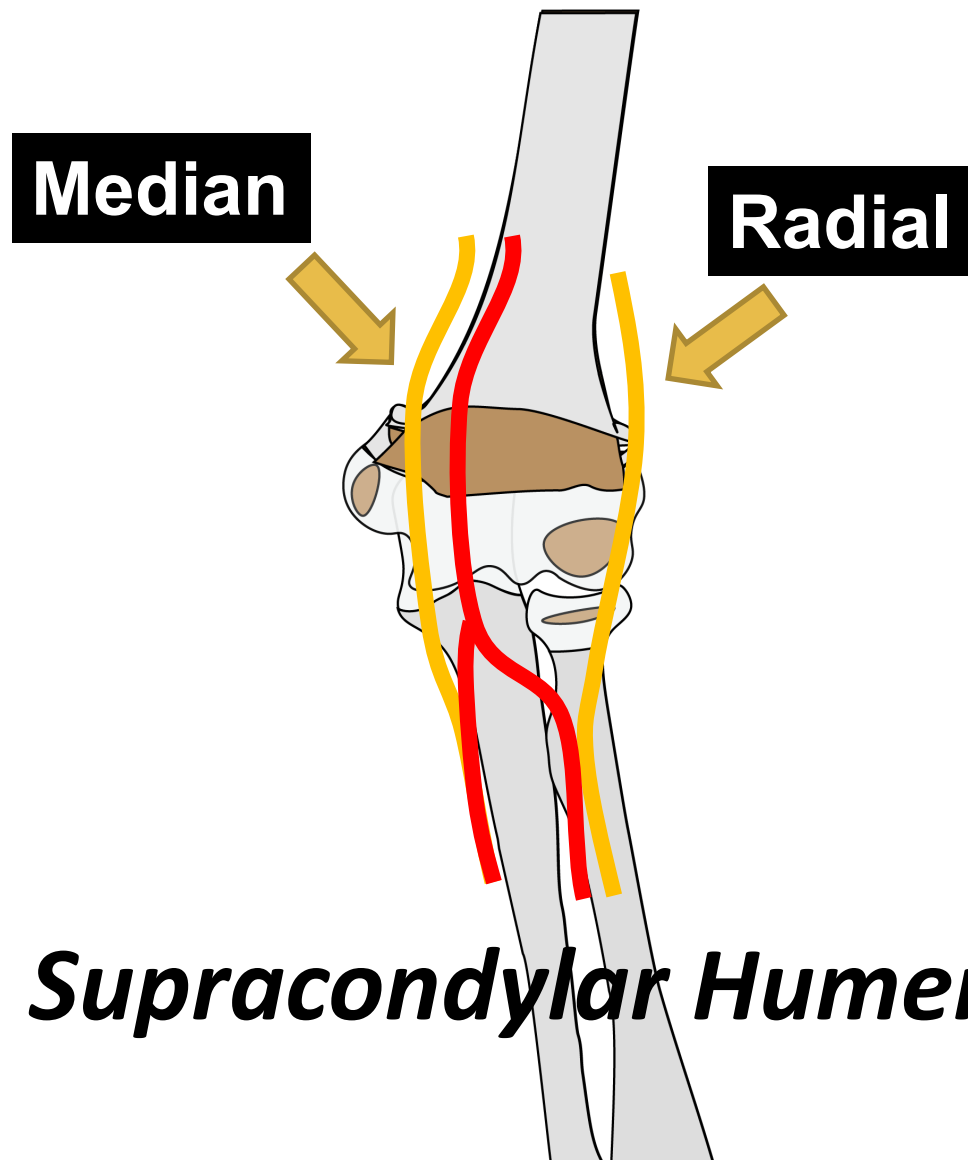
Extension Supracondylar Humerus

Pattern Recognition



Elbow Pearls

TRANSCONDYLAR AND UP - *IMPACTION*

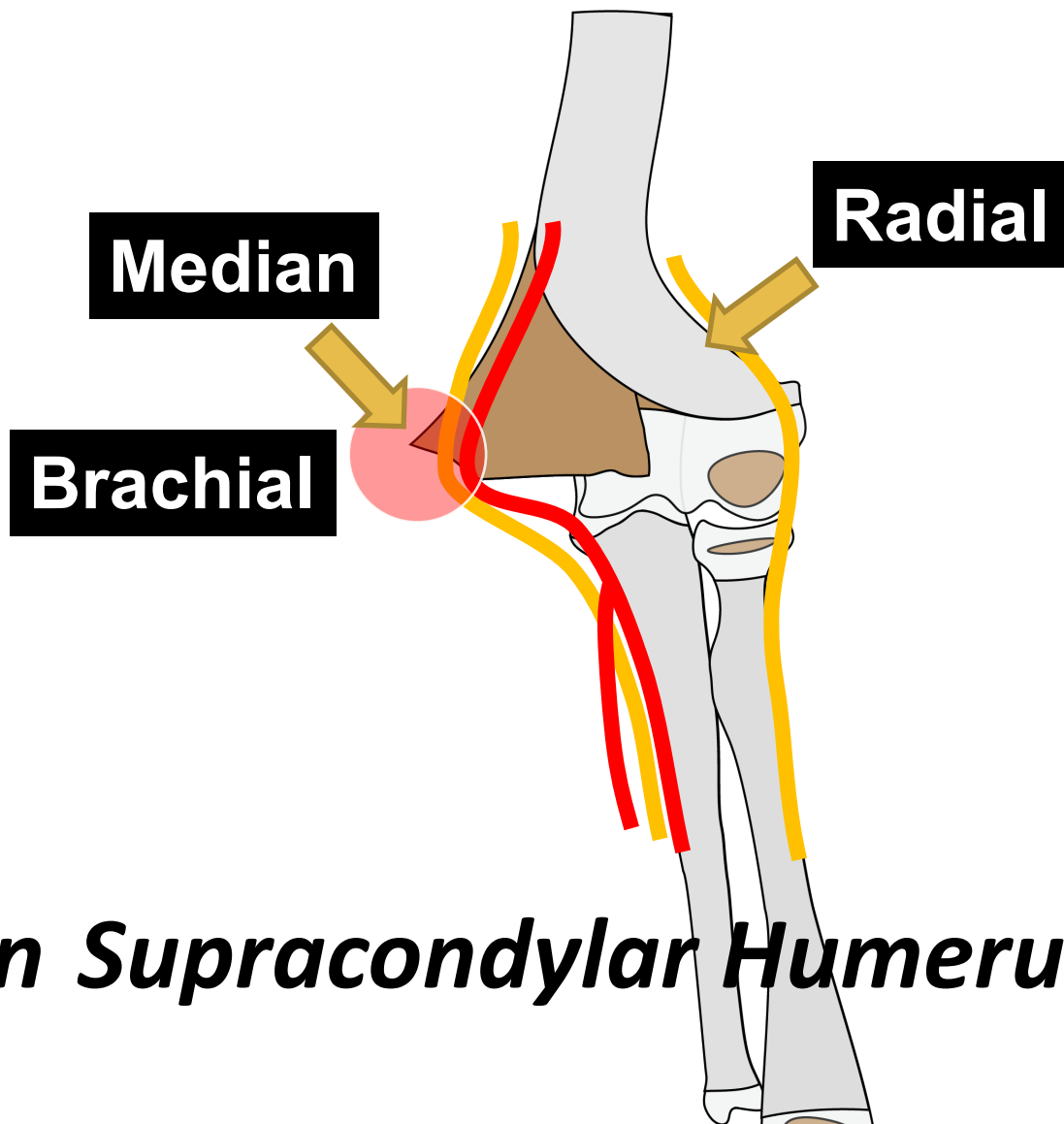


Extension Supracondylar Humerus

Pattern Recognition

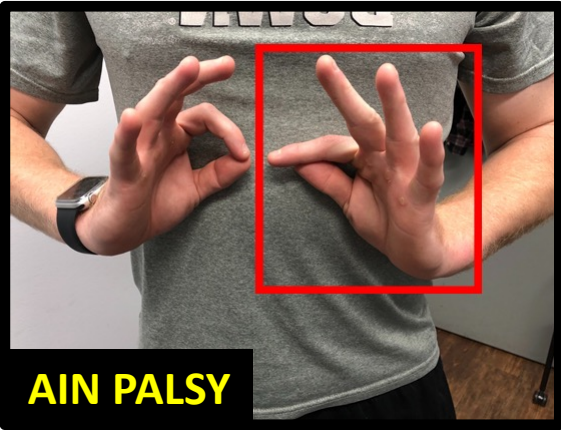
Elbow Pearls

TRANSCONDYLAR AND UP - *IMPACTION*



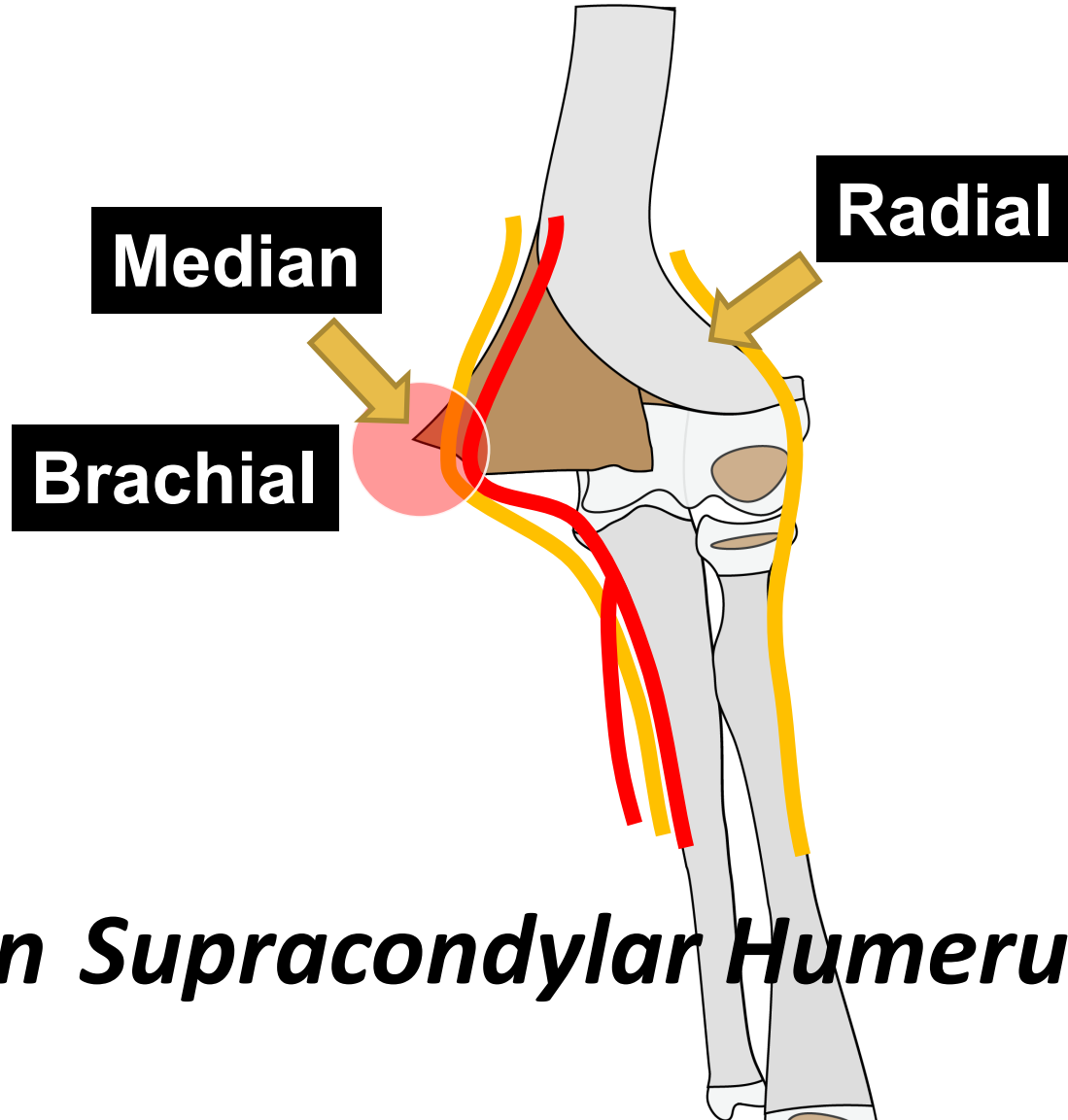
Extension Supracondylar Humerus

Pattern Recognition

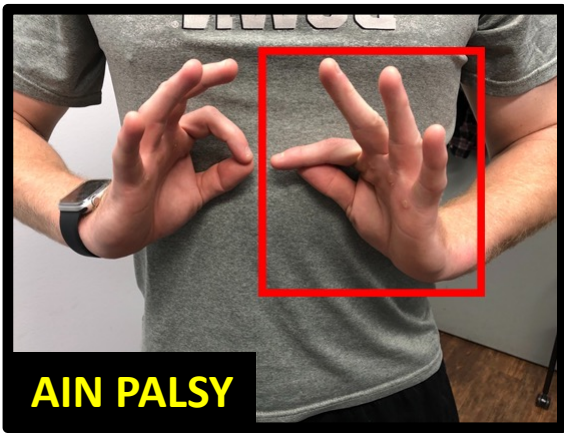


AIN PALSY

S **TRANSCONDYLAR AND UP - IMPACTION**

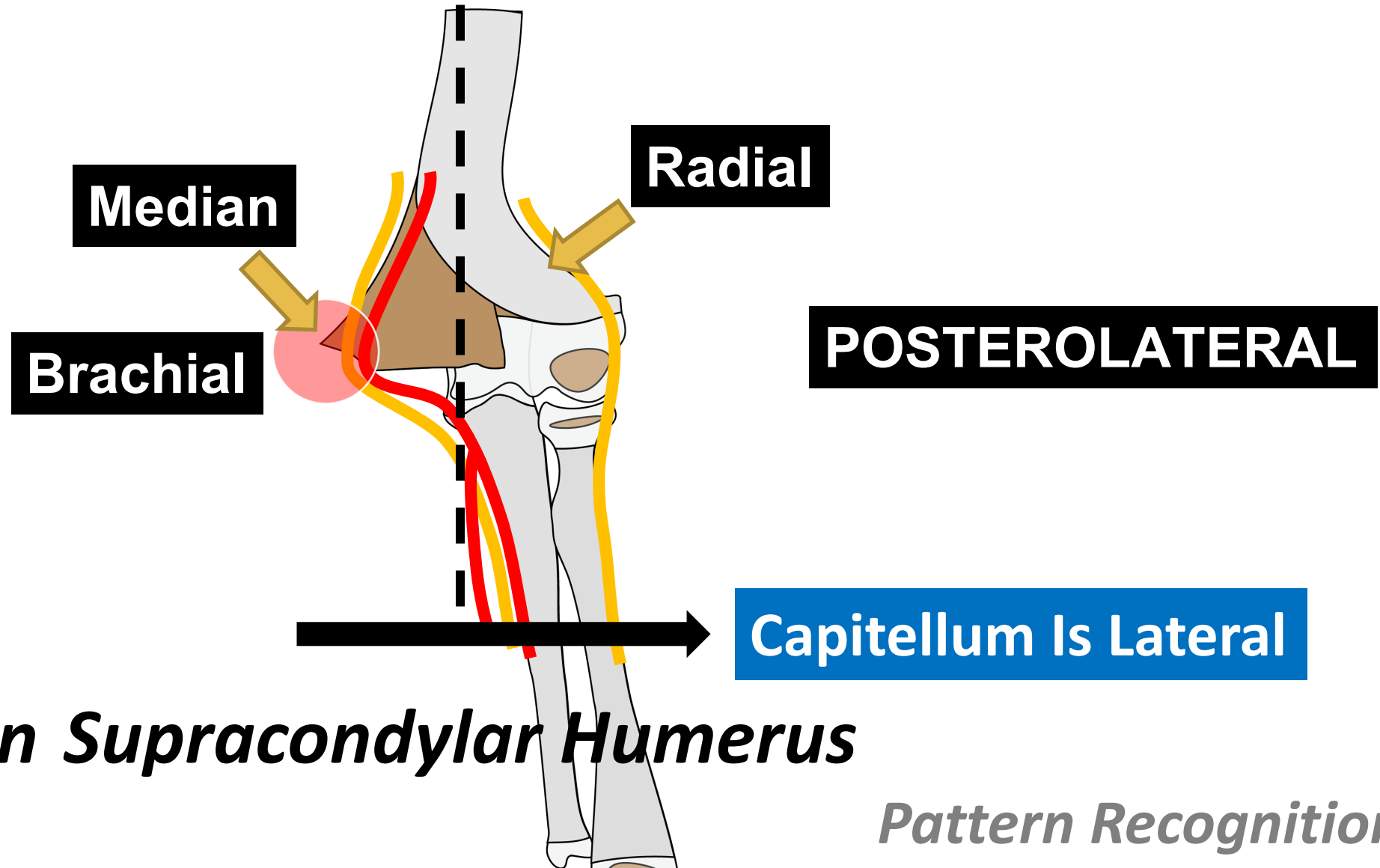


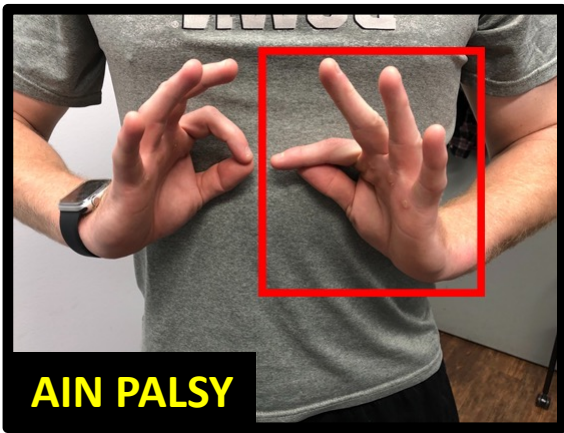
Extension Supracondylar Humerus



AIN PALSY

S *TRANSCONDYLAR AND UP - IMPACTION*

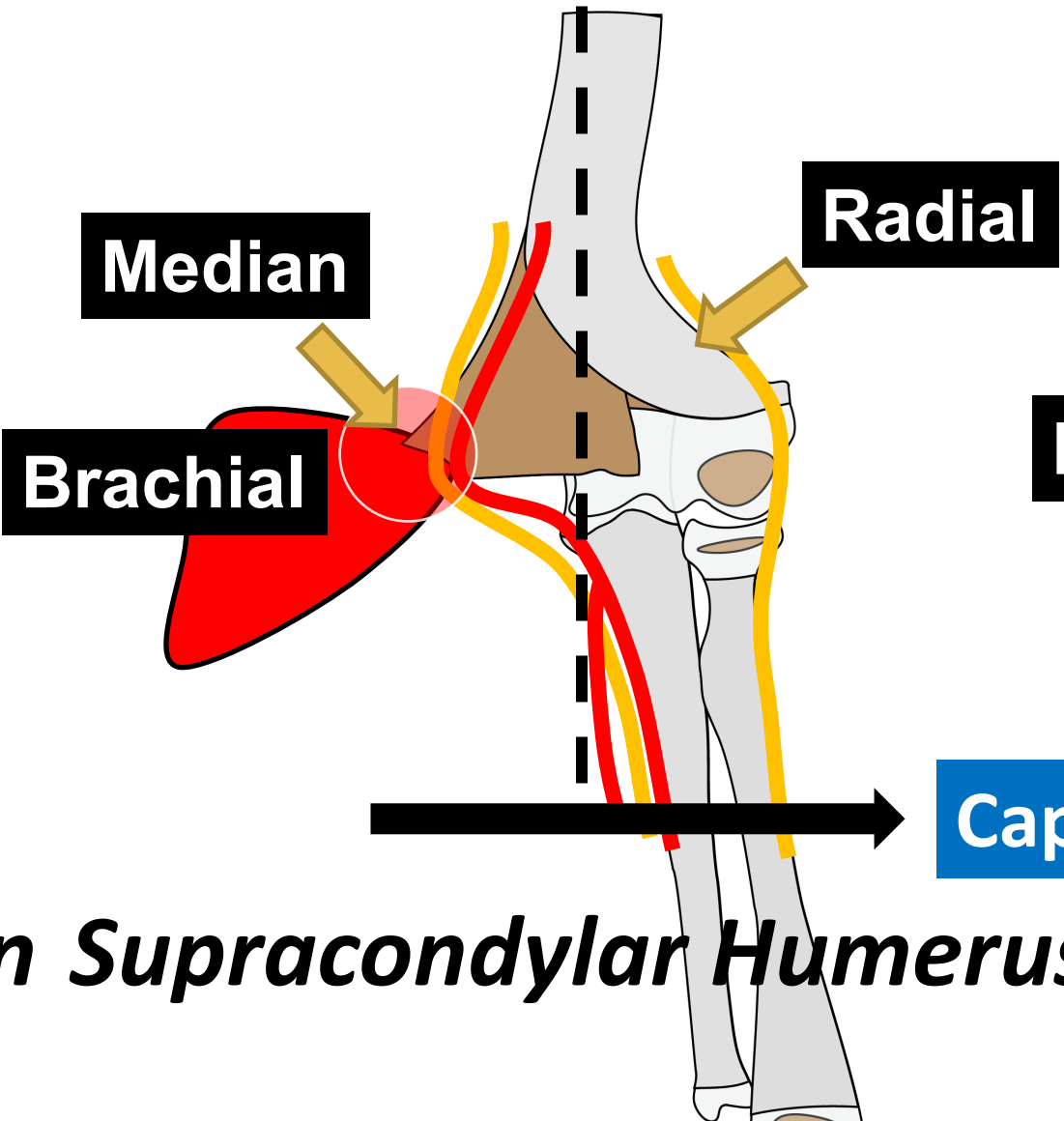




AIN PALSY

S *TRANSCONDYLAR AND UP - IMPACTION*

Bruise Is Medial



Median

Radial

Brachial

POSTEROLATERAL

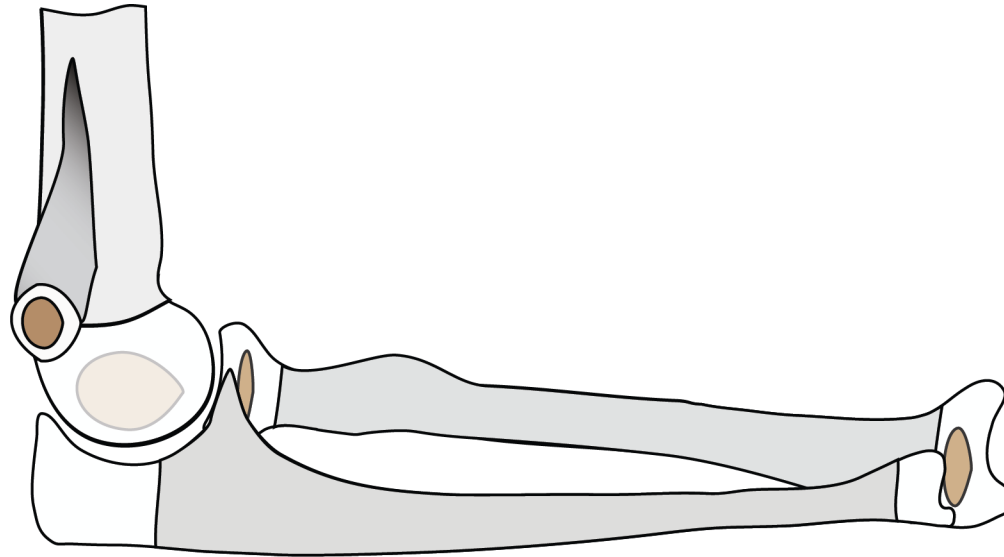
Capitellum Is Lateral

Extension Supracondylar Humerus

Elbow

Pearls

TRANSCONDYLAR AND UP - *IMPACTION*



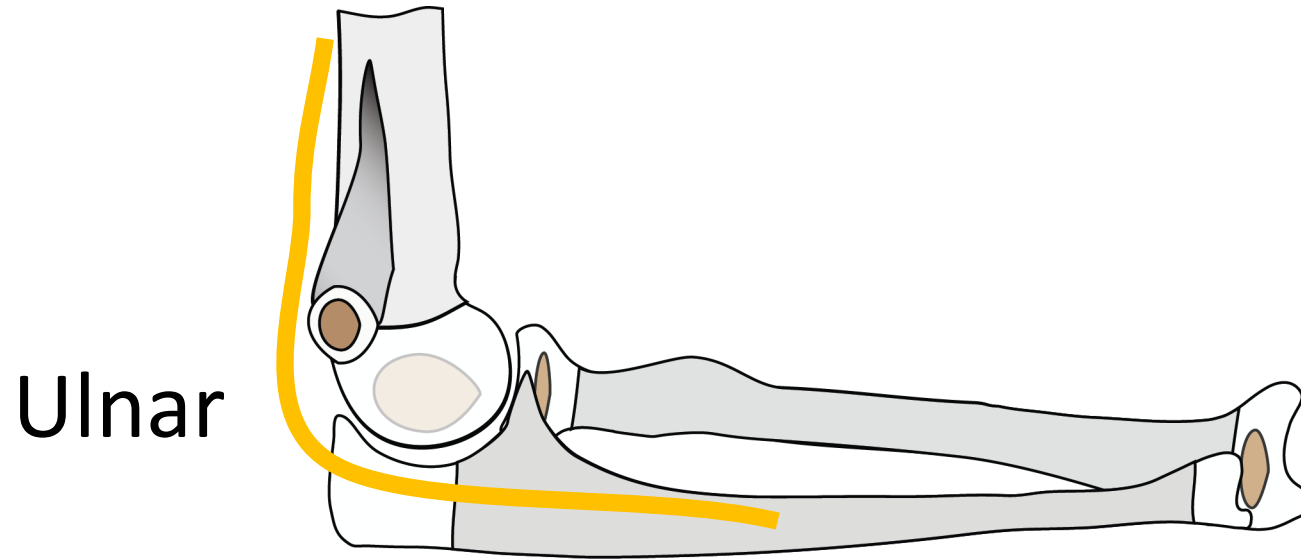
Flexion Supracondylar Humerus

Pattern Recognition

Elbow

Pearls

TRANSCONDYLAR AND UP - *IMPACTION*



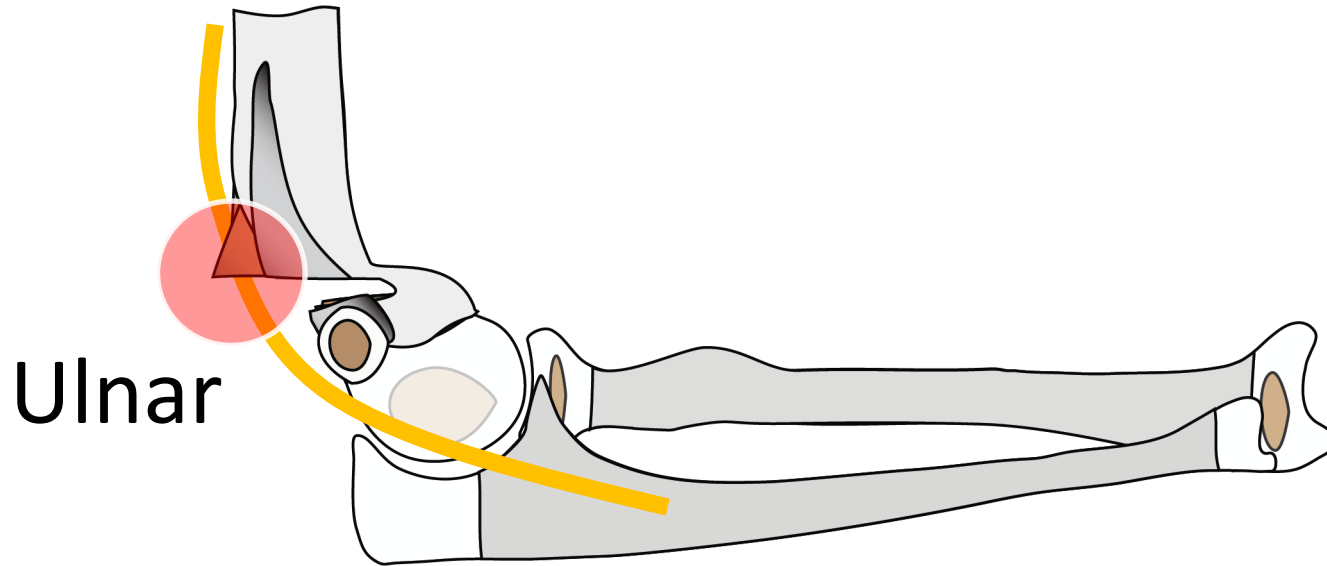
Flexion Supracondylar Humerus

Pattern Recognition

Elbow

Pearls

TRANSCONDYLAR AND UP - *IMPACTION*



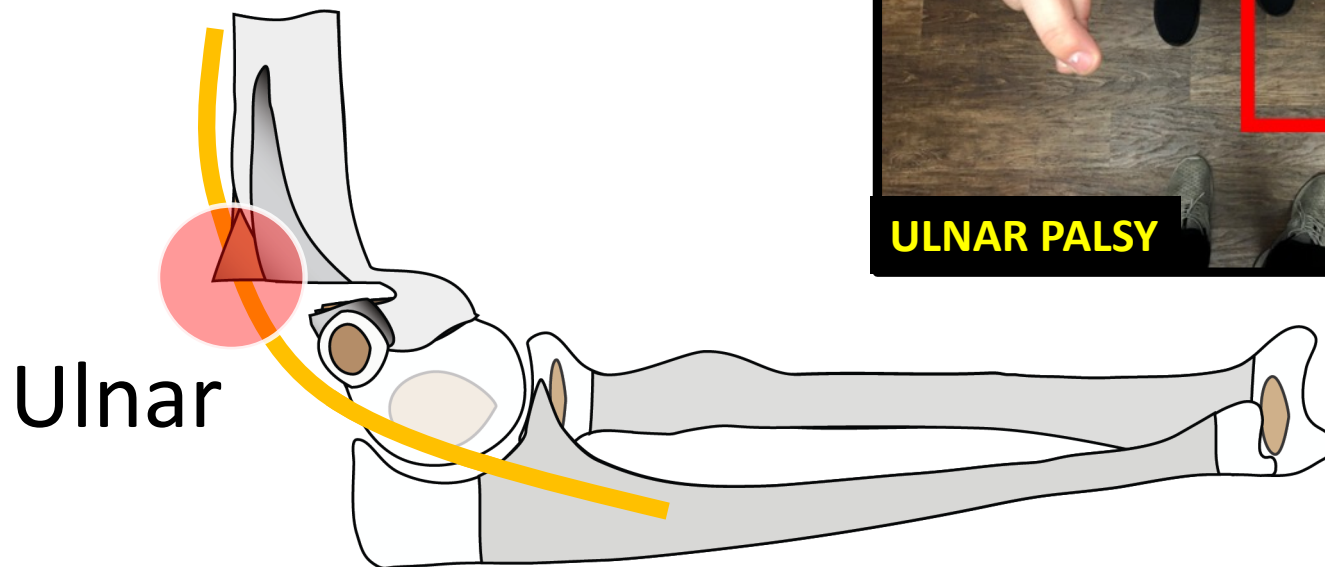
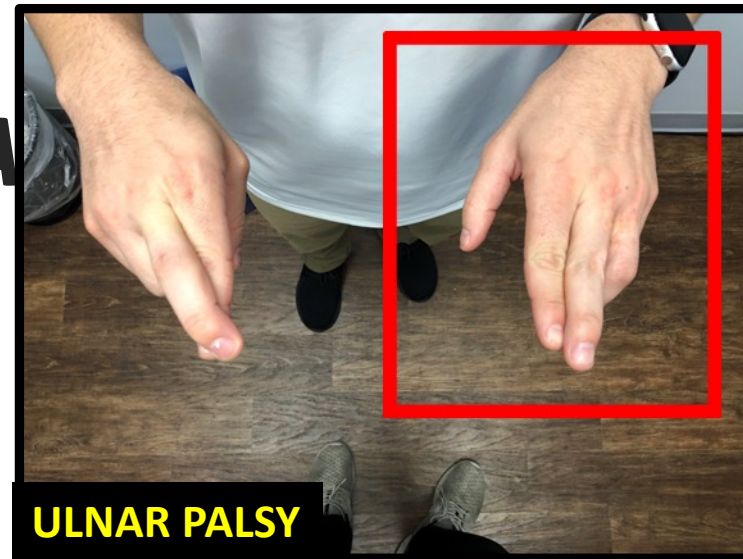
Flexion Supracondylar Humerus

Pattern Recognition

Elbow Pearls

TRANSCONDYLAR A

ION



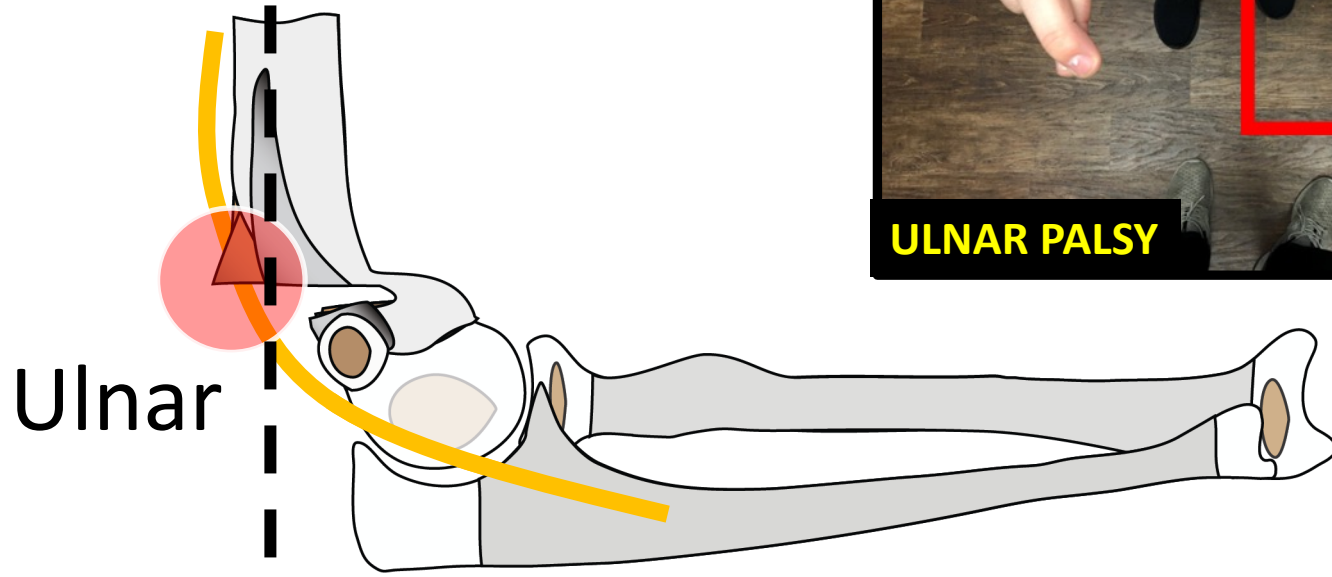
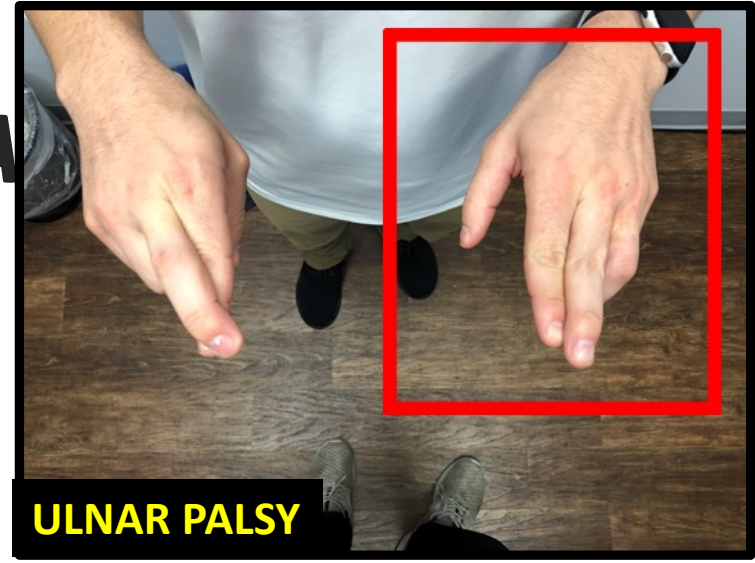
Flexion Supracondylar Humerus

Pattern Recognition

Elbow Pearls

TRANSCONDYLAR APPROACH

EVOLVING



Ulnar

→ **Capitellum Is Anterior**

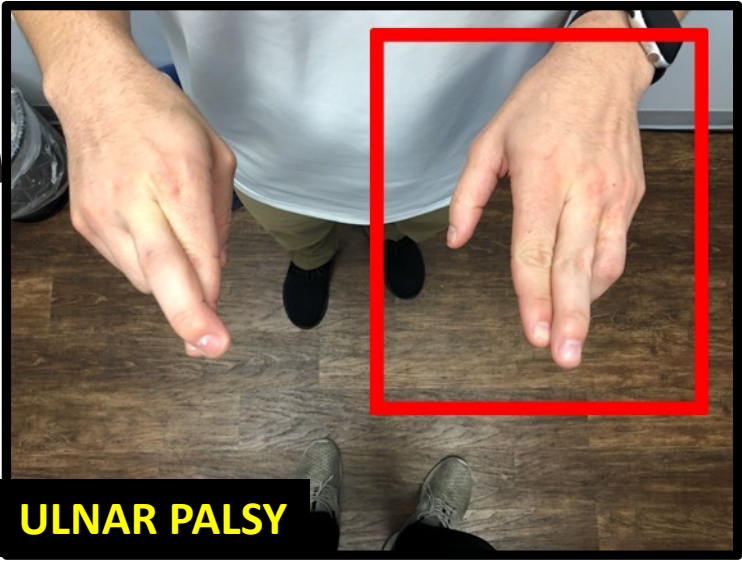
Flexion Supracondylar Humerus

Pattern Recognition

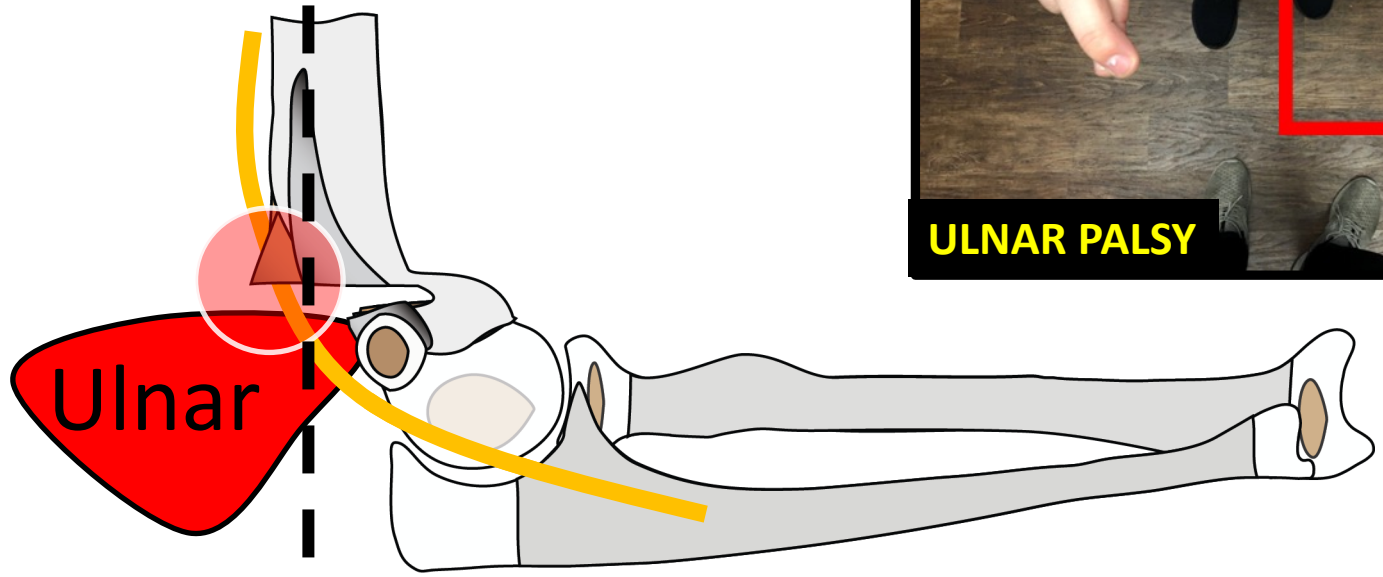
Elbow Pearls

TRANSCONDYLAR APPROACH

AVULSION



Bruise is Posterior



Capitellum Is Anterior

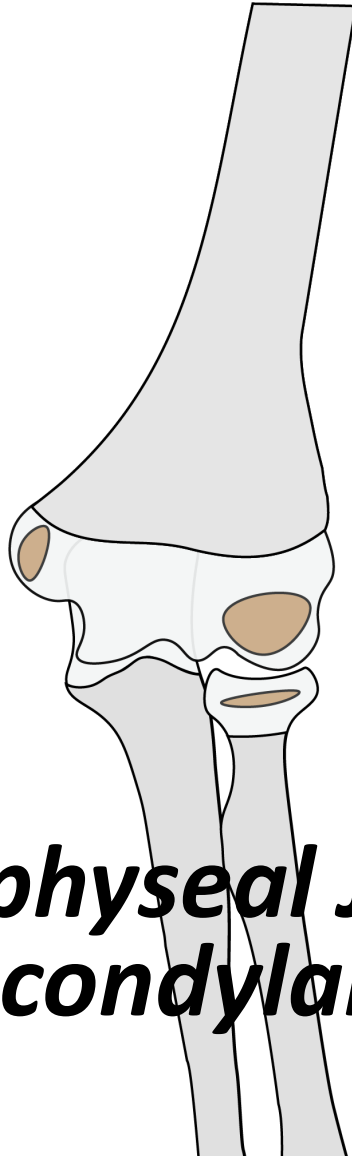
Flexion Supracondylar Humerus

Pattern Recognition

Elbow

Pearls

TRANSCONDYLAR AND UP - *IMPACTION*



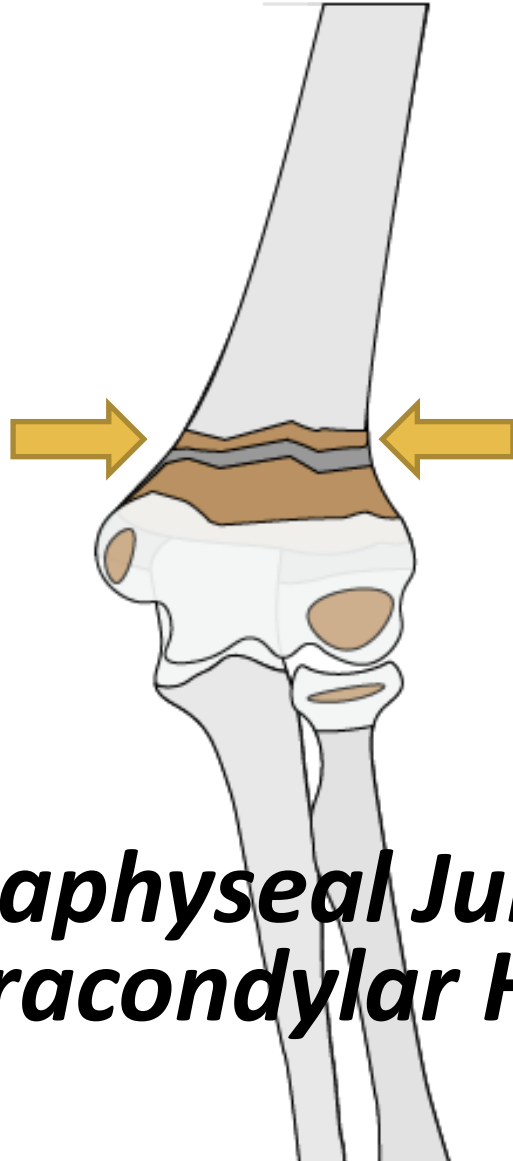
***Metadiaphyseal Junction (MDJ)
Supracondylar Humerus***

Pattern Recognition

Elbow

Pearls

TRANSCONDYLAR AND UP - *IMPACTION*



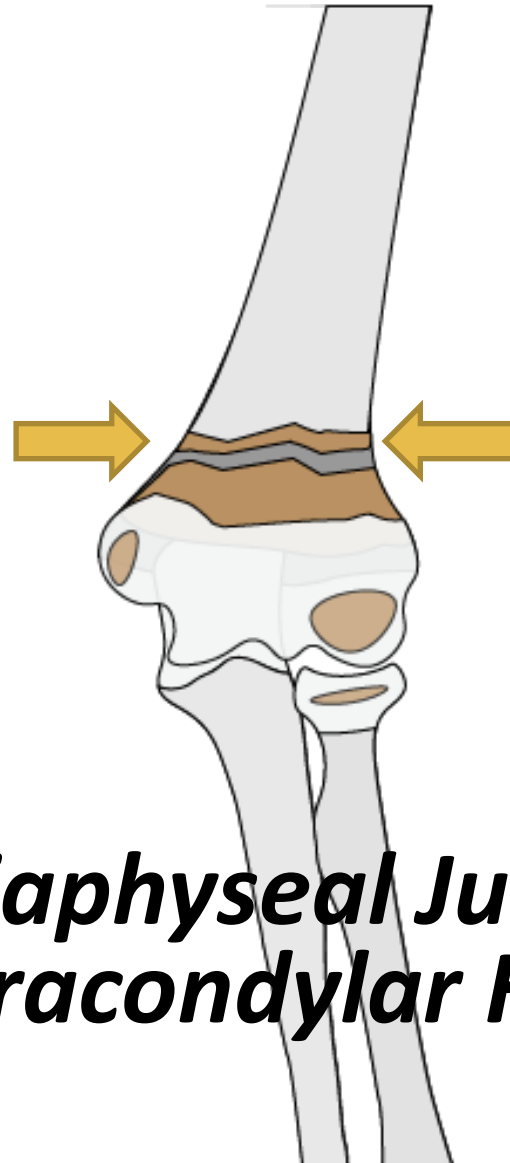
***Metadiaphyseal Junction (MDJ)
Supracondylar Humerus***

Pattern Recognition

Elbow

Pearls

TRANSCONDYLAR AND UP - *IMPACTION*



“High Supracondylar”

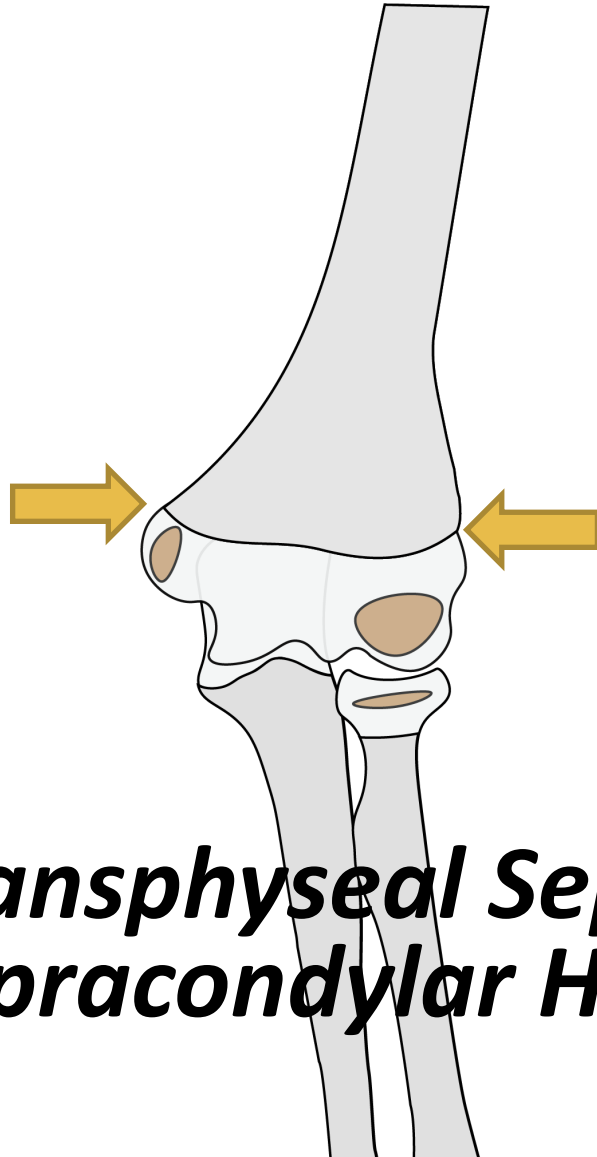
***Metadiaphyseal Junction (MDJ)
Supracondylar Humerus***

Pattern Recognition

Elbow

Pearls

TRANSCONDYLAR AND UP - *IMPACTION*

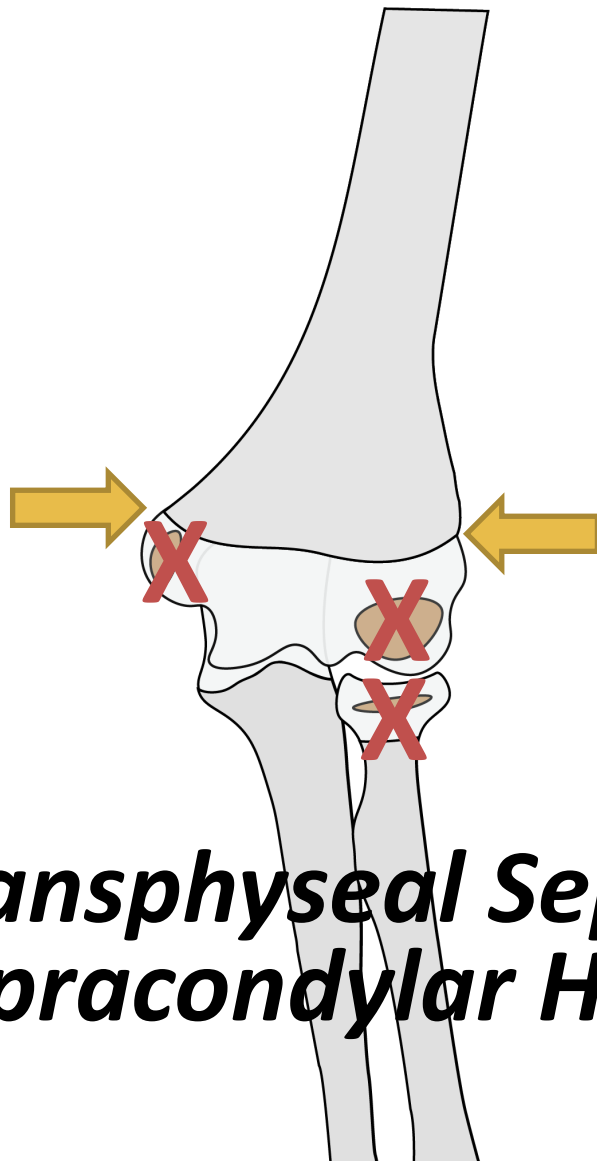


***Transphyseal Separation
Supracondylar Humerus***

Pattern Recognition

Elbow Pearls

TRANSCONDYLAR AND UP - *IMPACTION*



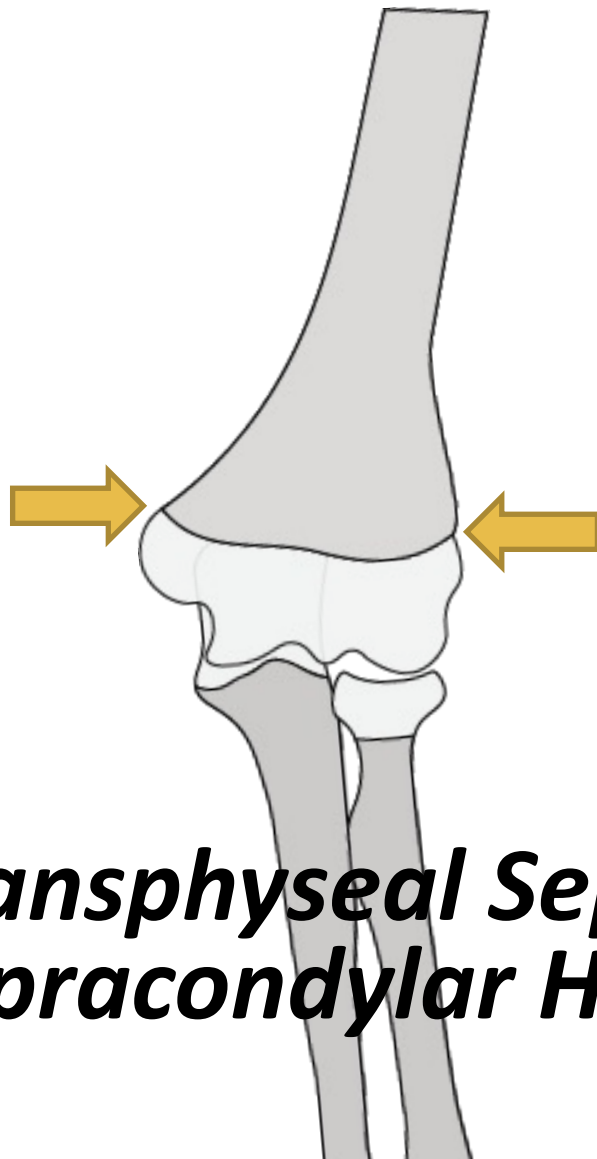
**UNDER THE
AGE OF 1!**

***Transphyseal Separation
Supracondylar Humerus***

Pattern Recognition

Elbow Pearls

TRANSCONDYLAR AND UP - *IMPACTION*



**UNDER THE
AGE OF 1!**

***Transphyseal Separation
Supracondylar Humerus***

Pattern Recognition

Elbow Pearls

TRANSCONDYLAR AND UP - **IMPACTION**

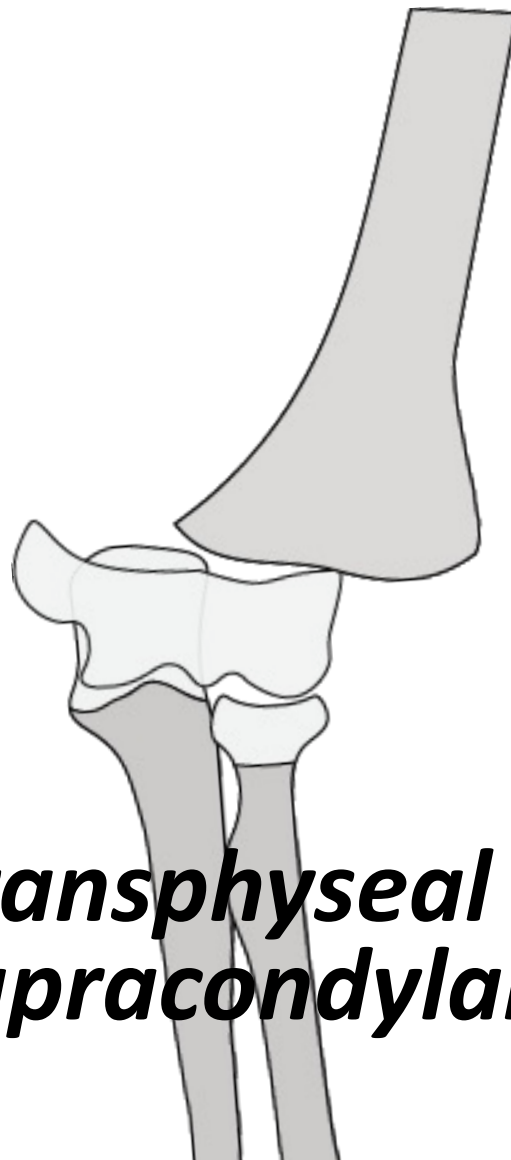
AVULSION

VERY EASILY MISSED

UNDER THE AGE OF 1!

*Transphyseal Separation
Supracondylar Humerus*

Pattern Recognition



Elbow Pearls

TRANSCONDYLAR AND UP - **IMPACTION**

AVULSION

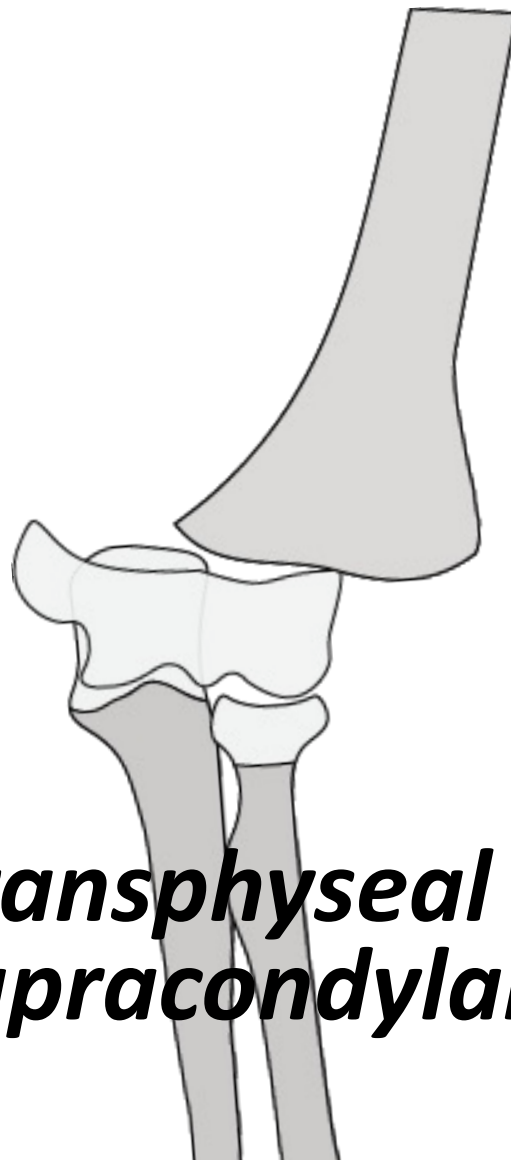
VERY EASILY
MISSED

HIGH NAT

UNDER THE
AGE OF 1!

*Transphyseal Separation
Supracondylar Humerus*

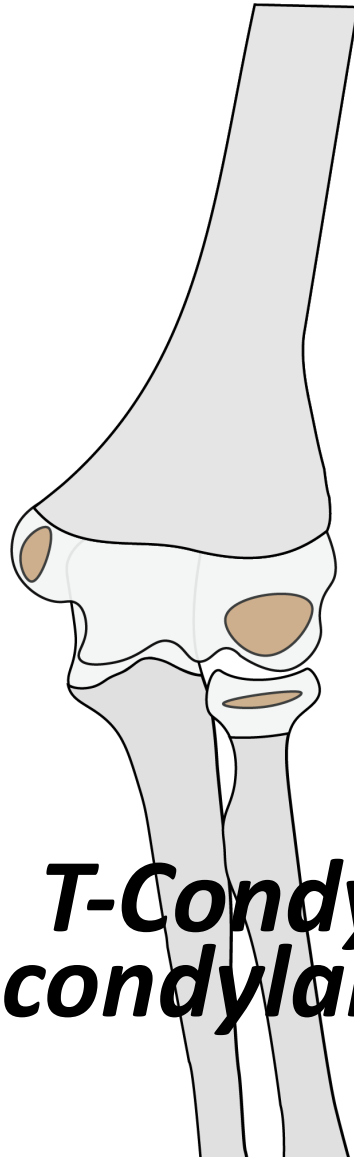
Pattern Recognition



Elbow

Pearls

TRANSCONDYLAR AND UP - *IMPACTION*



***T-Condylar
Supracondylar Humerus***

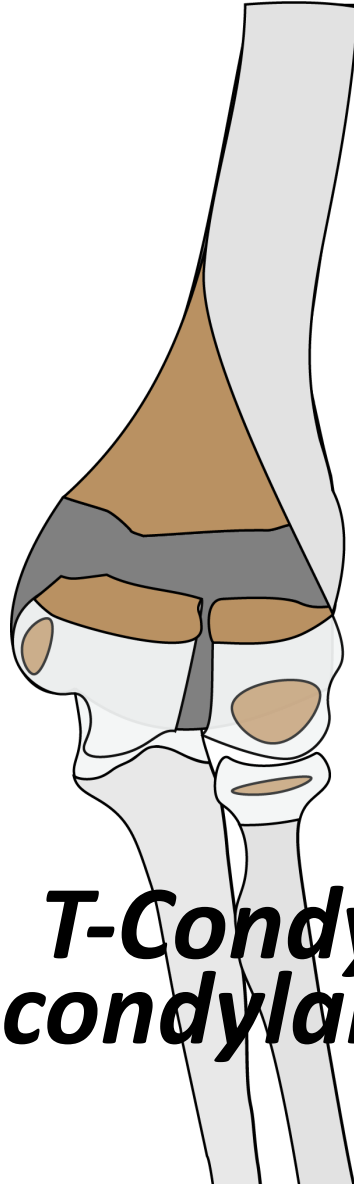
Pattern Recognition

Elbow

Pearls

TRANSCONDYLAR AND UP - IMPACTION

CT?



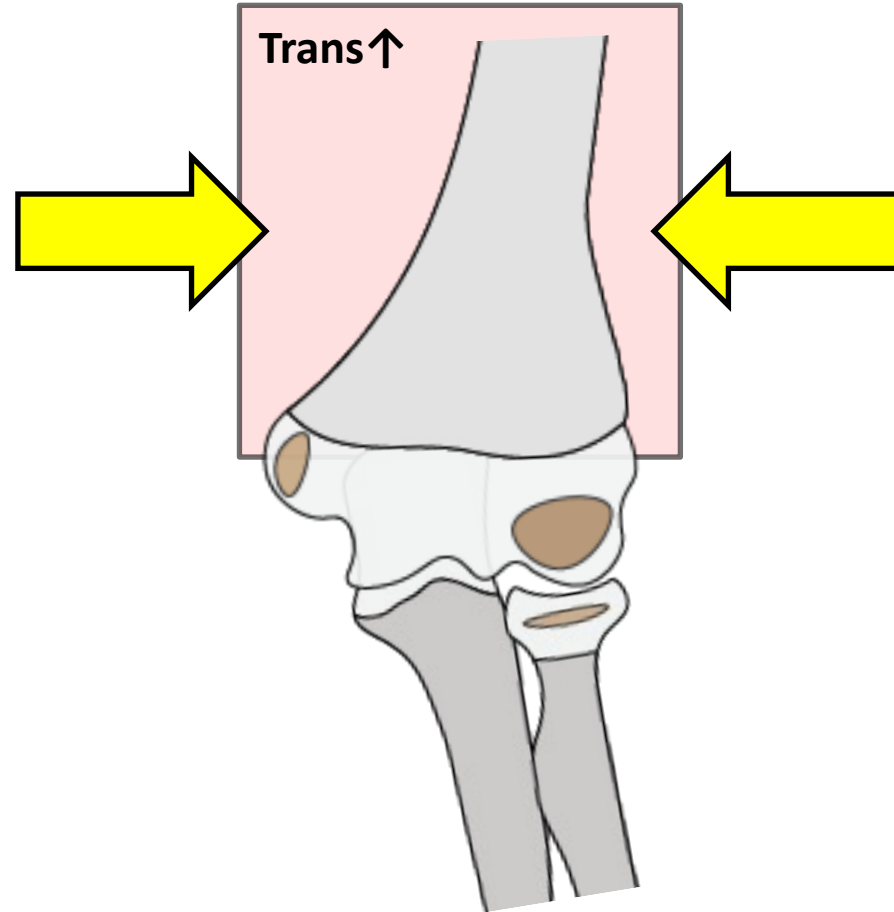
OVER THE
AGE OF 9!

***T-Condylar
Supracondylar Humerus***

Pattern Recognition

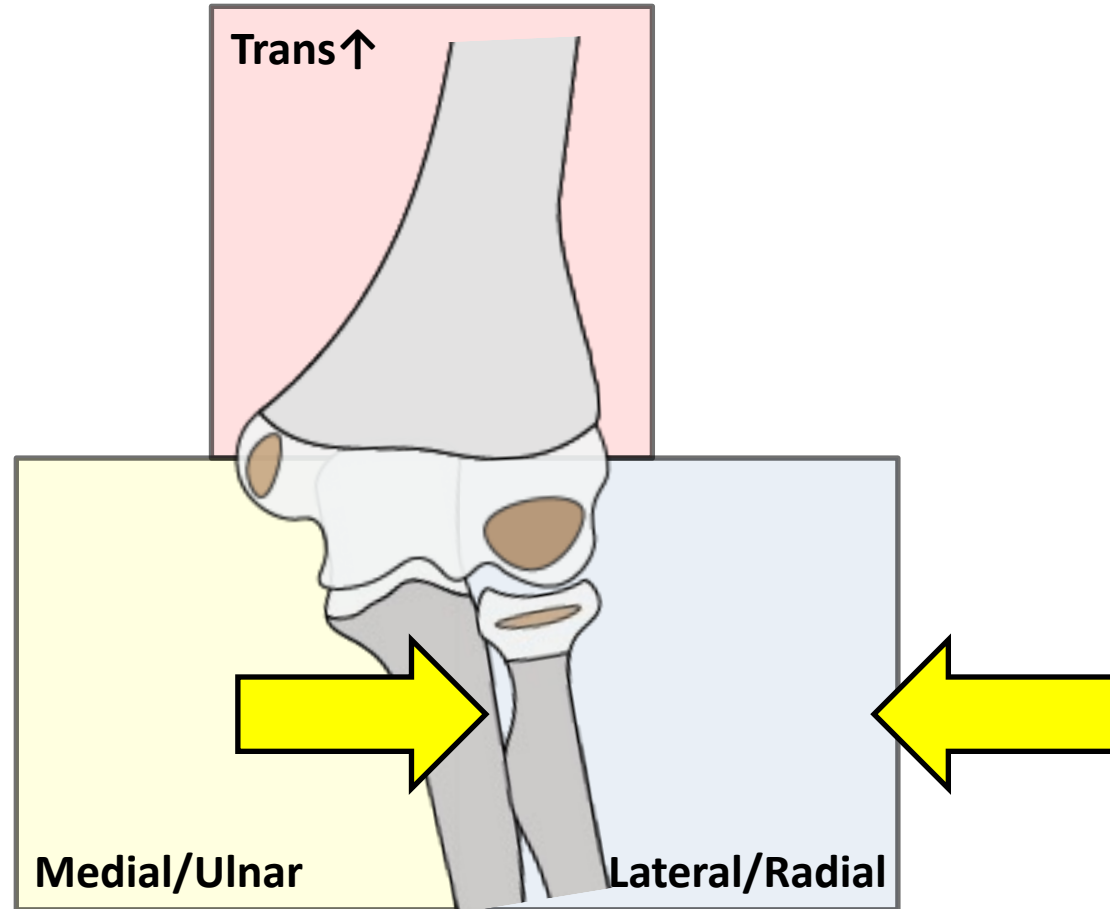
Elbow Pearls

TRANSCONDYLAR AND UP - *IMPACTION*



Elbow Pearls

LATERAL/RADIAL

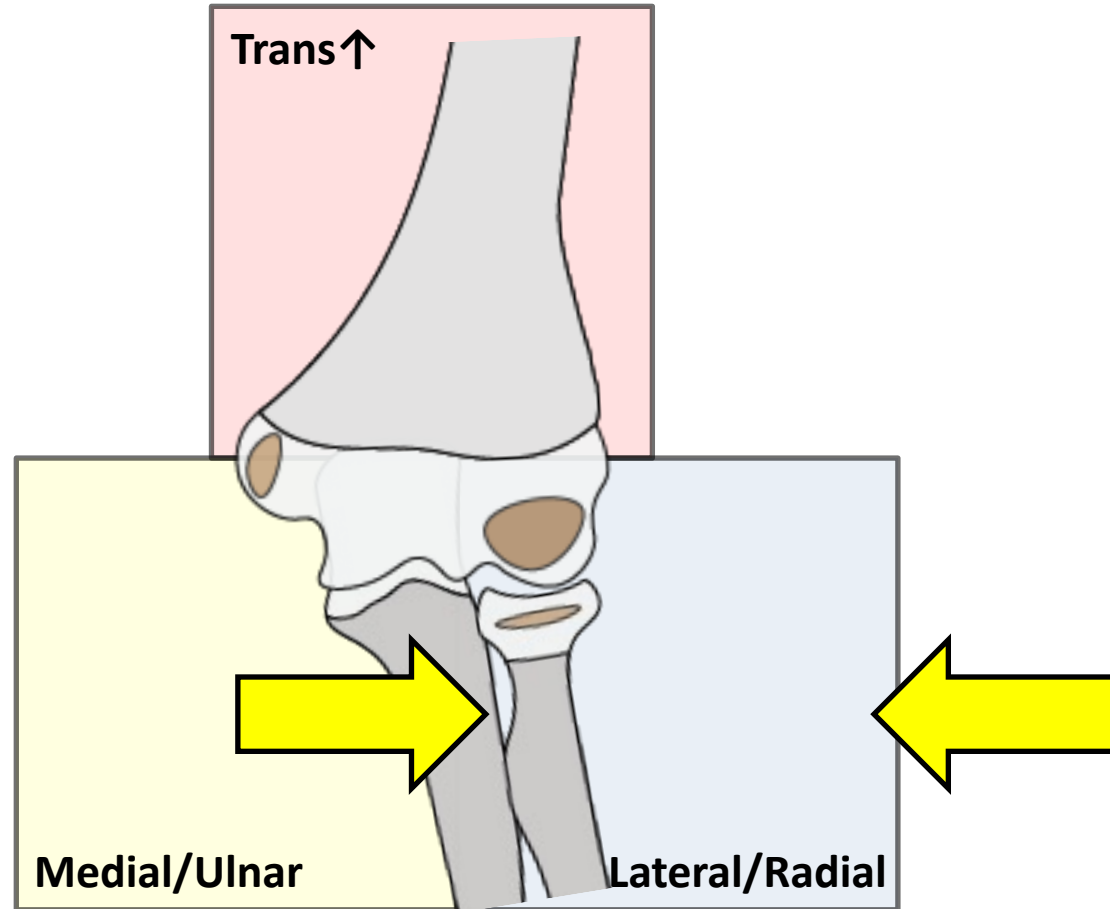


Pattern Recognition

Elbow Pearls

LATERAL/RADIAL

*IMPACTION
DISTRACTION*

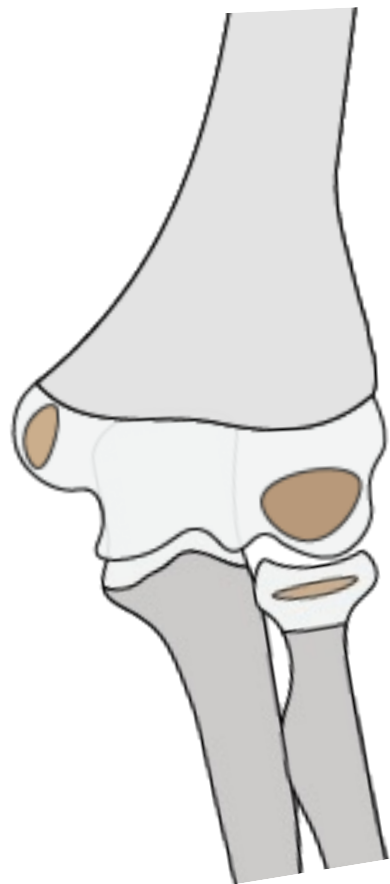


Pattern Recognition

Elbow Pearls

LATERAL/RADIAL

***IMPACTION
DISTRACTION***

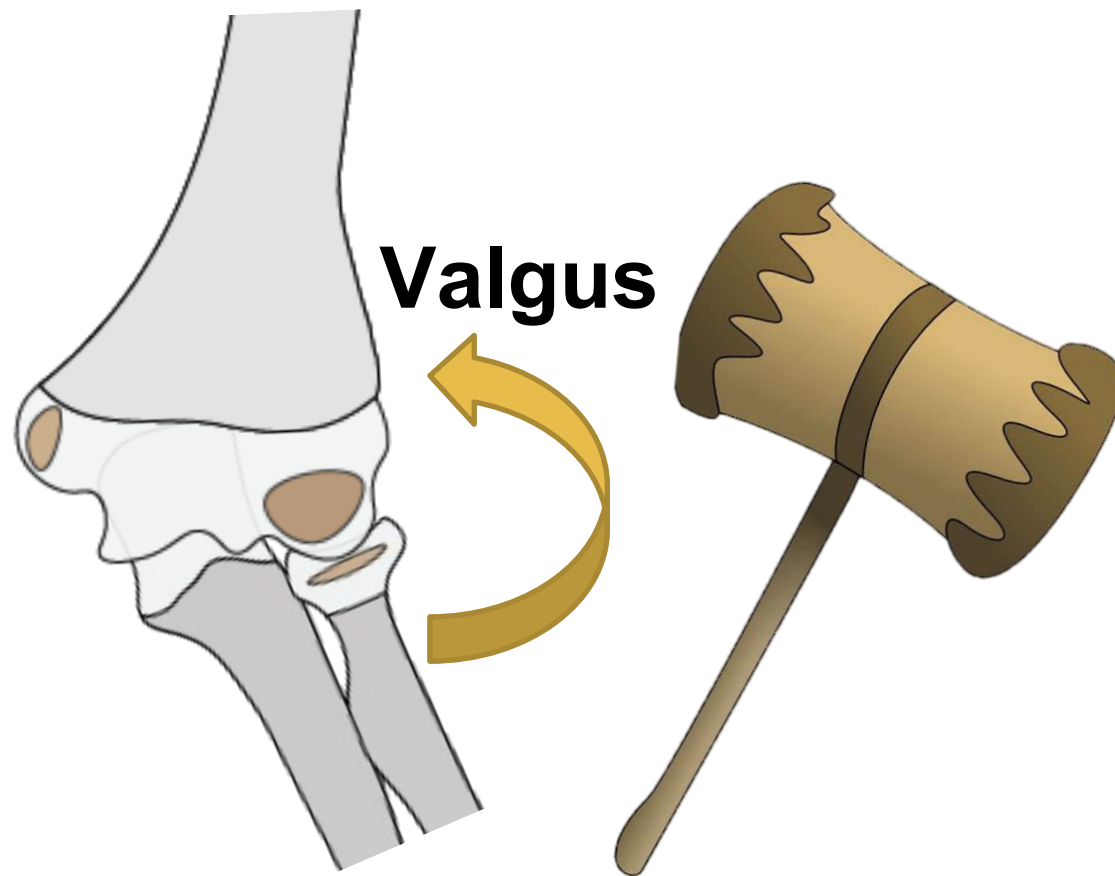


Pattern Recognition

Elbow Pearls

LATERAL/RADIAL

**IMPACTION
DISTRACTION**

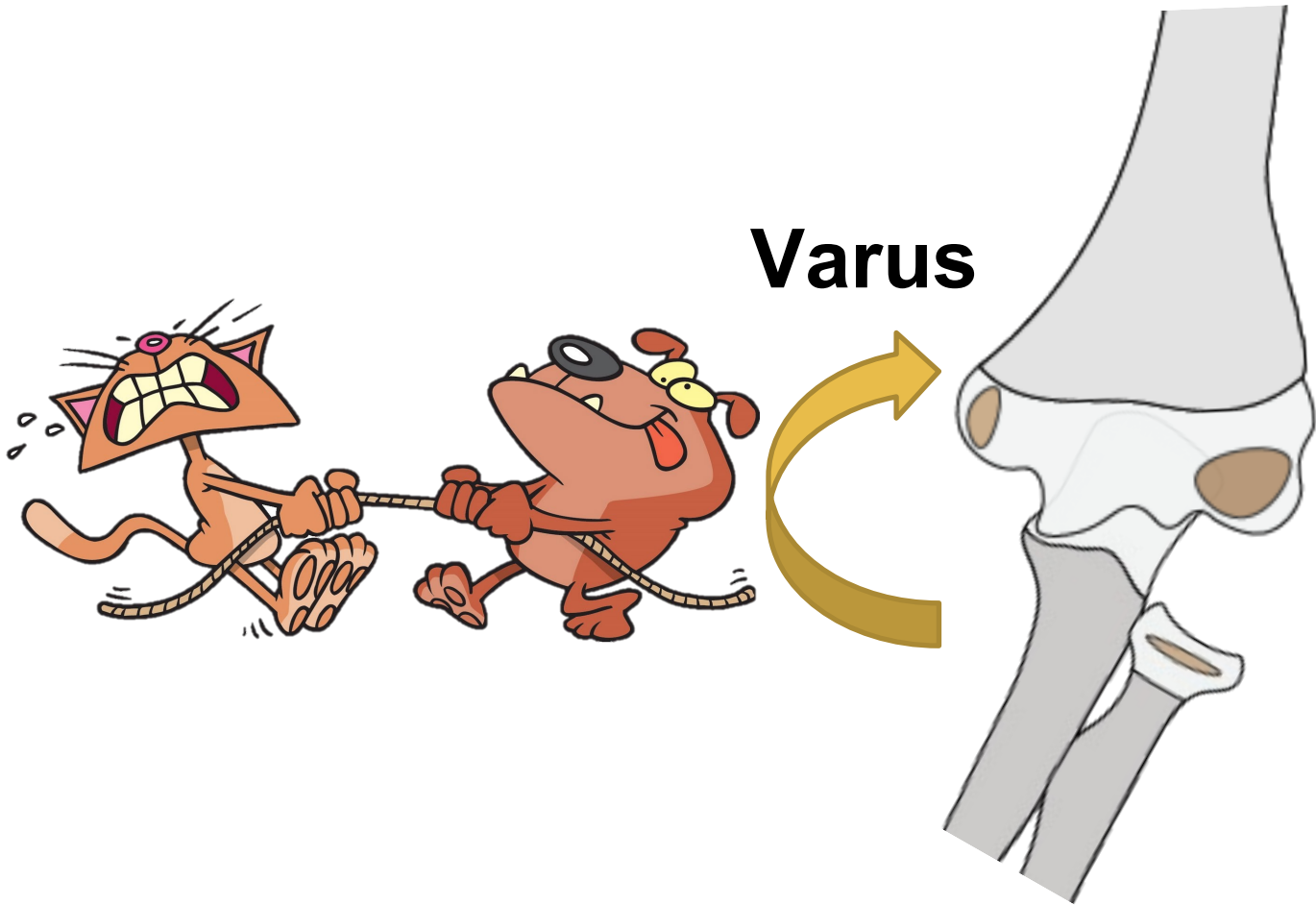


Pattern Recognition

Elbow Pearls

LATERAL/RADIAL

*IMPACTION
DISTRACTION*




Pattern Recognition

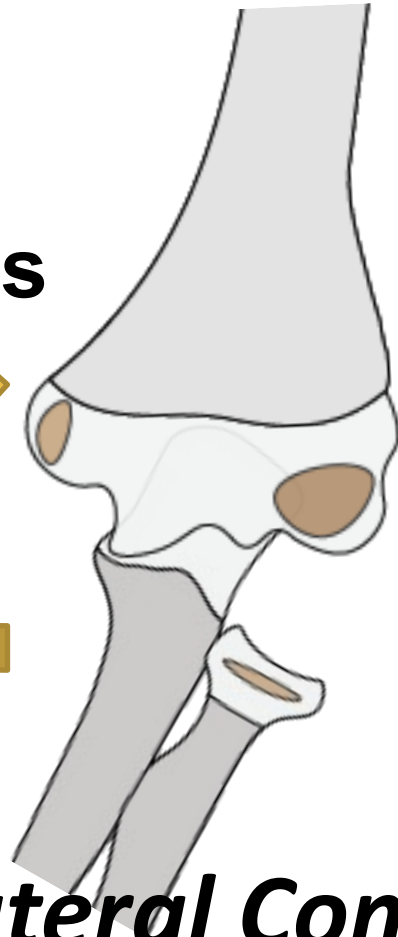Elbow Pearls

LATERAL/RADIAL

**IMPACTION
DISTRACTION**



Varus



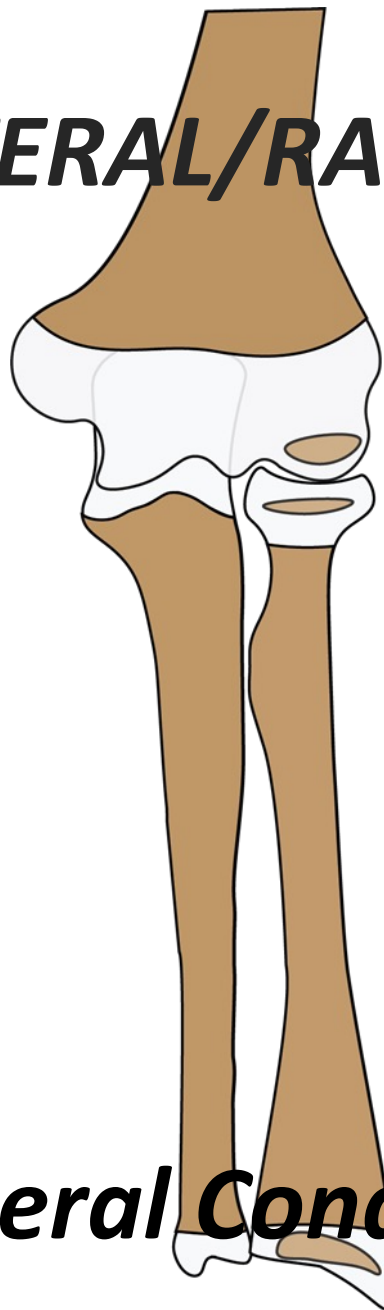
Lateral Condyle

Pattern Recognition

Elbow Pearls

LATERAL/RADIAL

***IMPACTION
DISTRACTION***



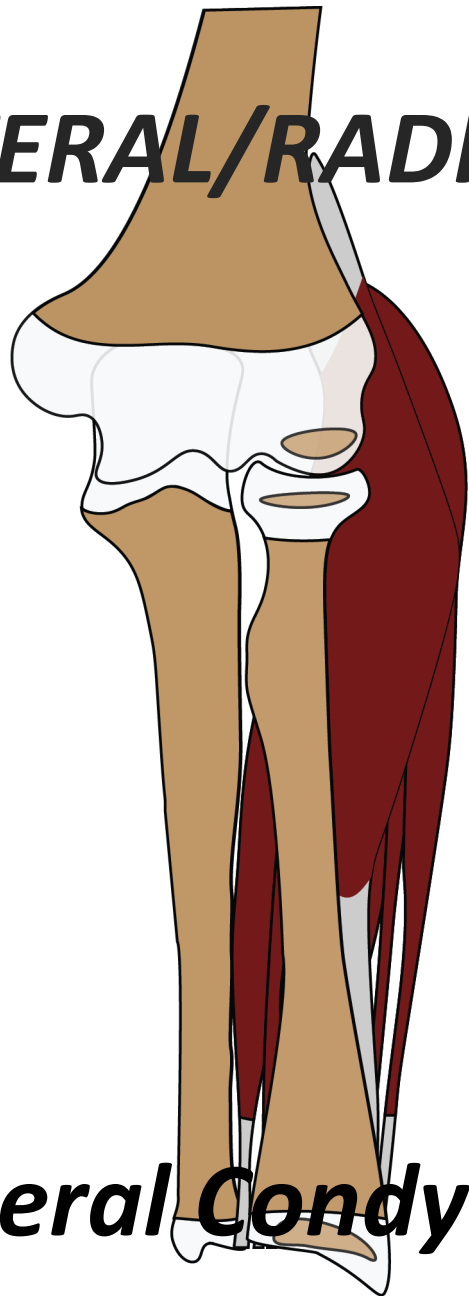
Lateral Condyle

Pattern Recognition

Elbow Pearls

LATERAL/RADIAL

**IMPACTION
DISTRACTION**



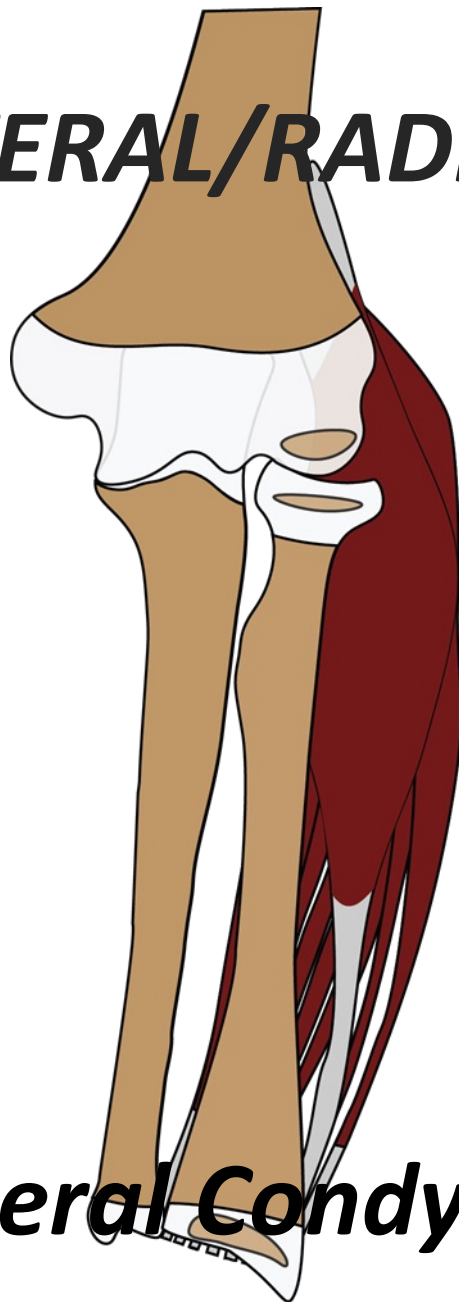
Lateral Condyle

Pattern Recognition

Elbow Pearls

LATERAL/RADIAL

**IMPACTION
DISTRACTION**



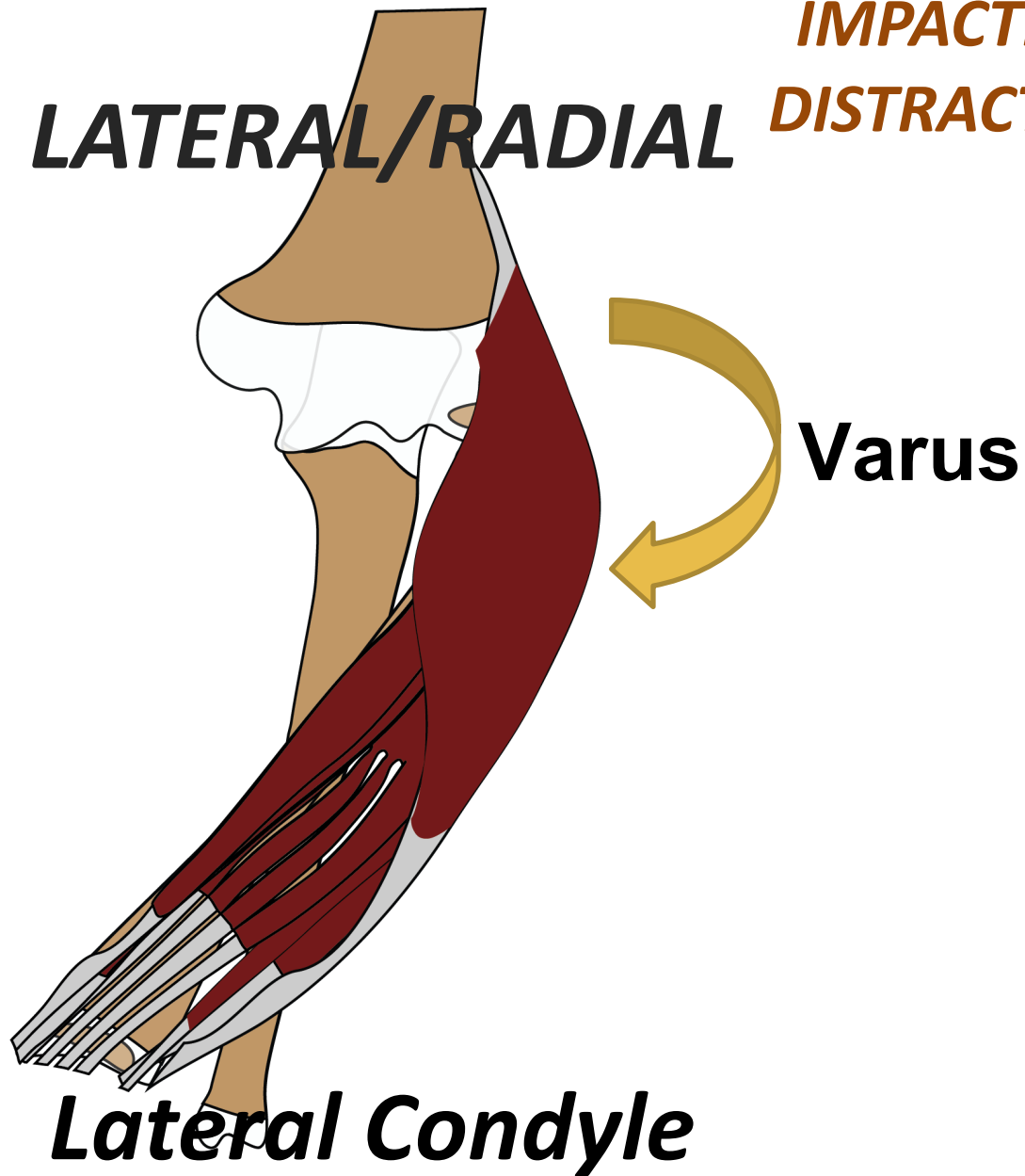
Lateral Condyle

Pattern Recognition

Elbow Pearls

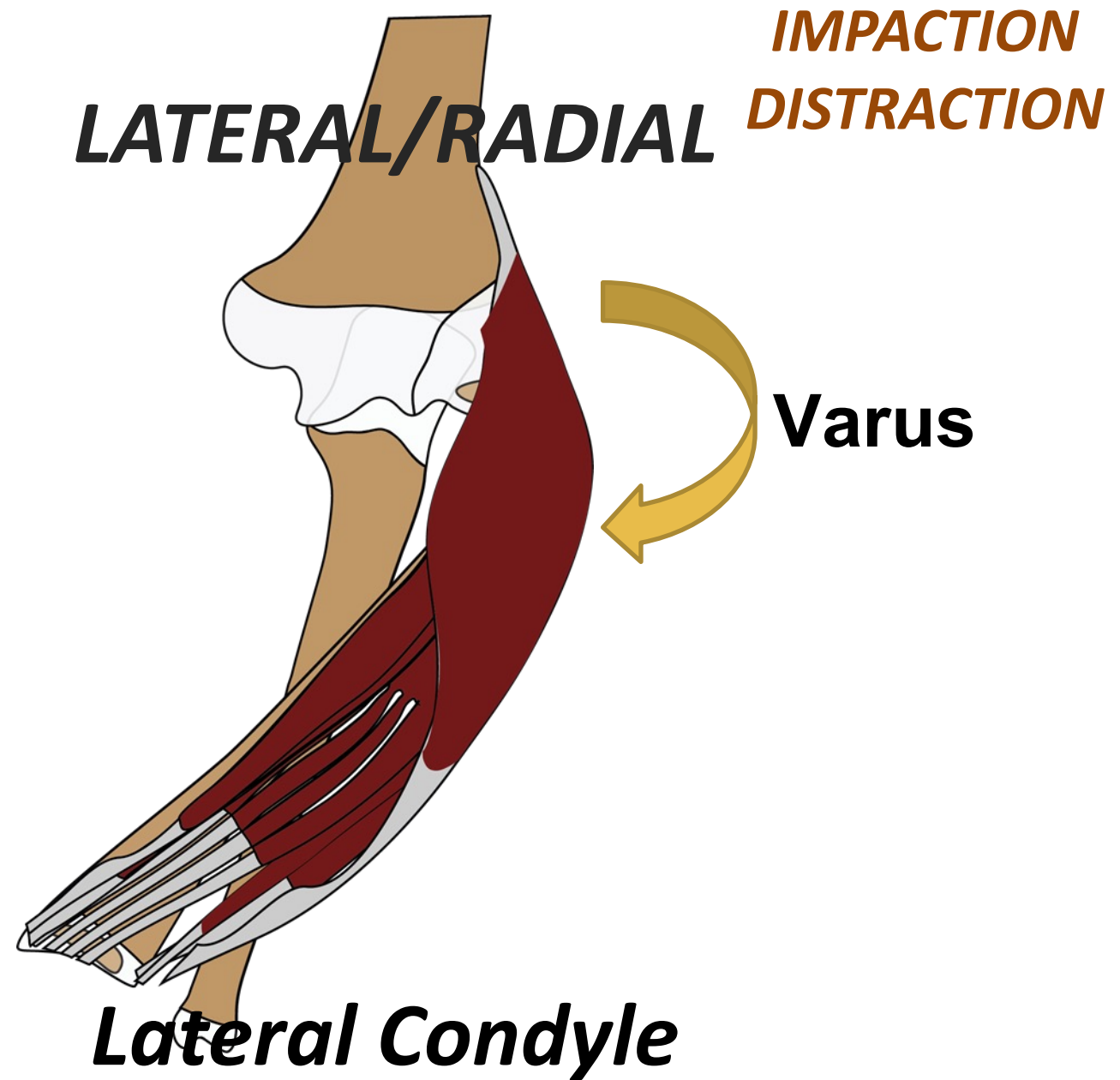
LATERAL/RADIAL

**IMPACTION
DISTRACTION**

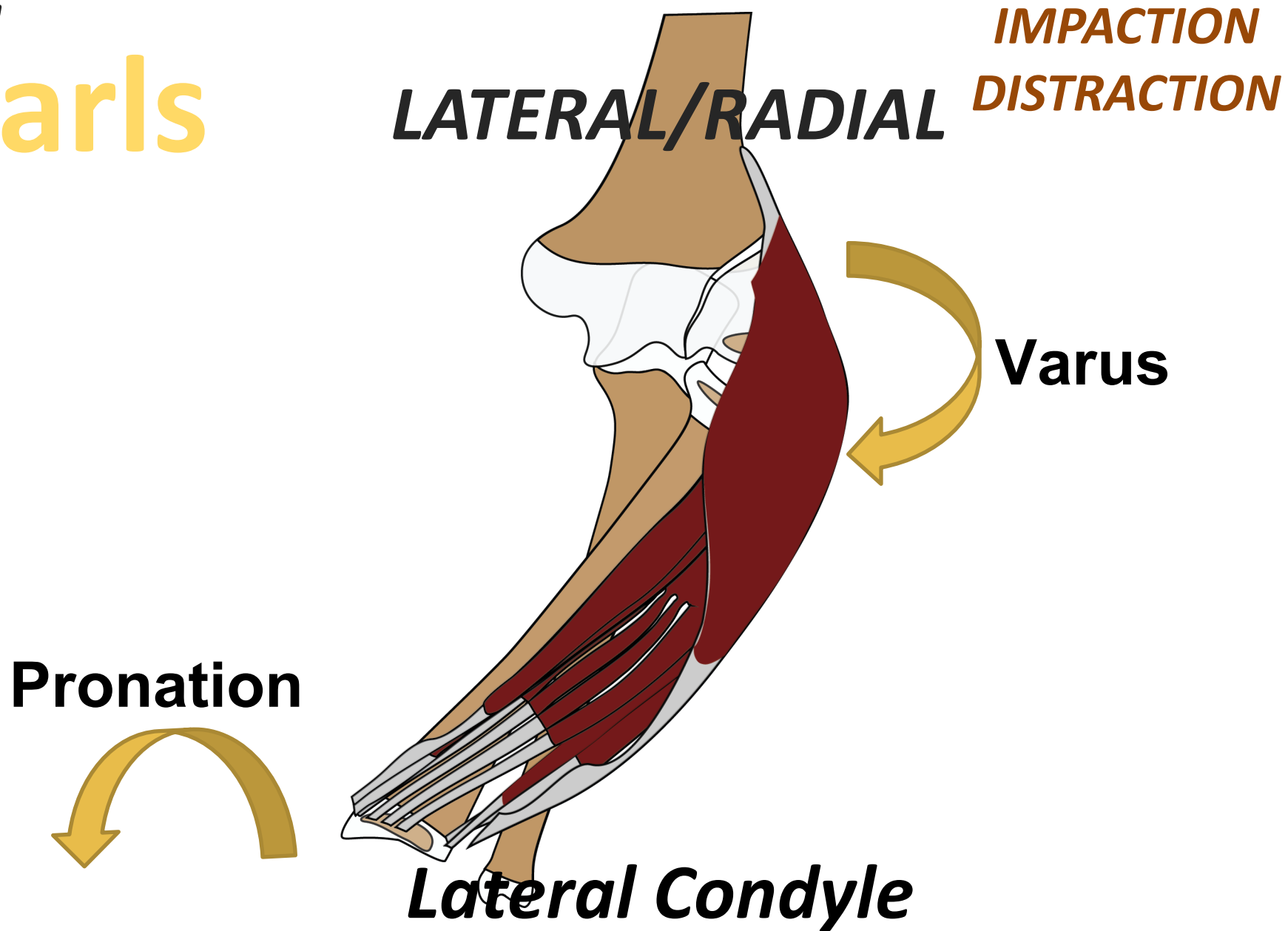


Pattern Recognition

Elbow Pearls




Elbow Pearls



Elbow Pearls

Pronation



LATERAL/RADIAL

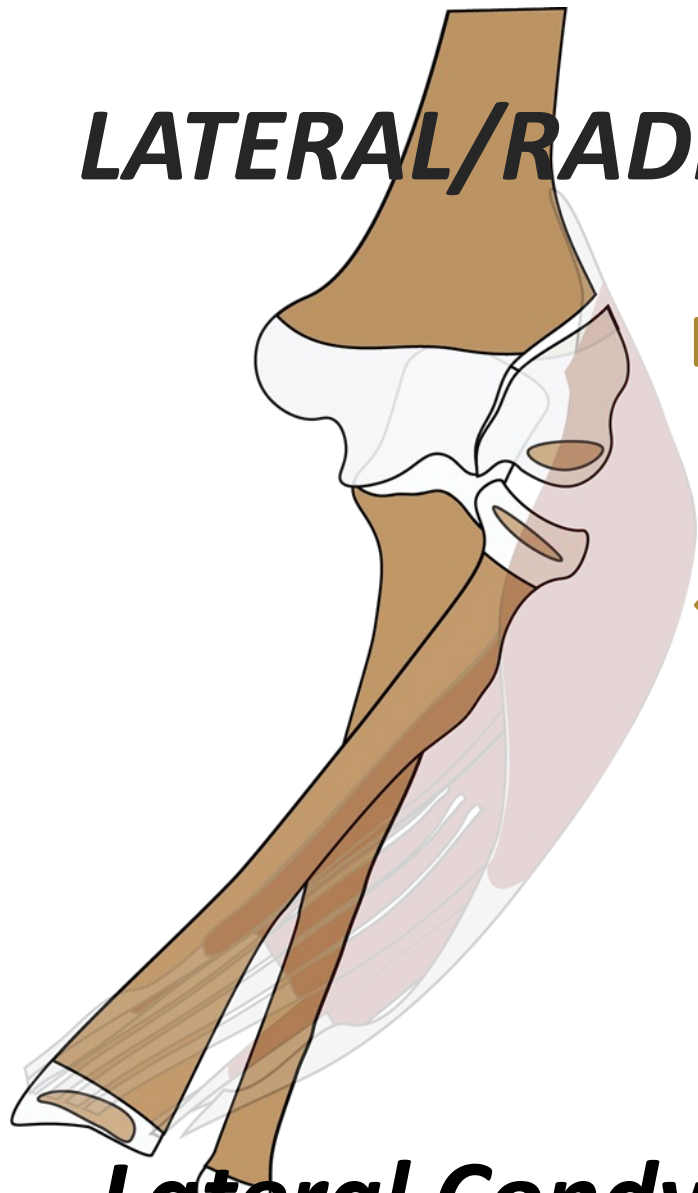**IMPACTION
DISTRACTION**

Varus

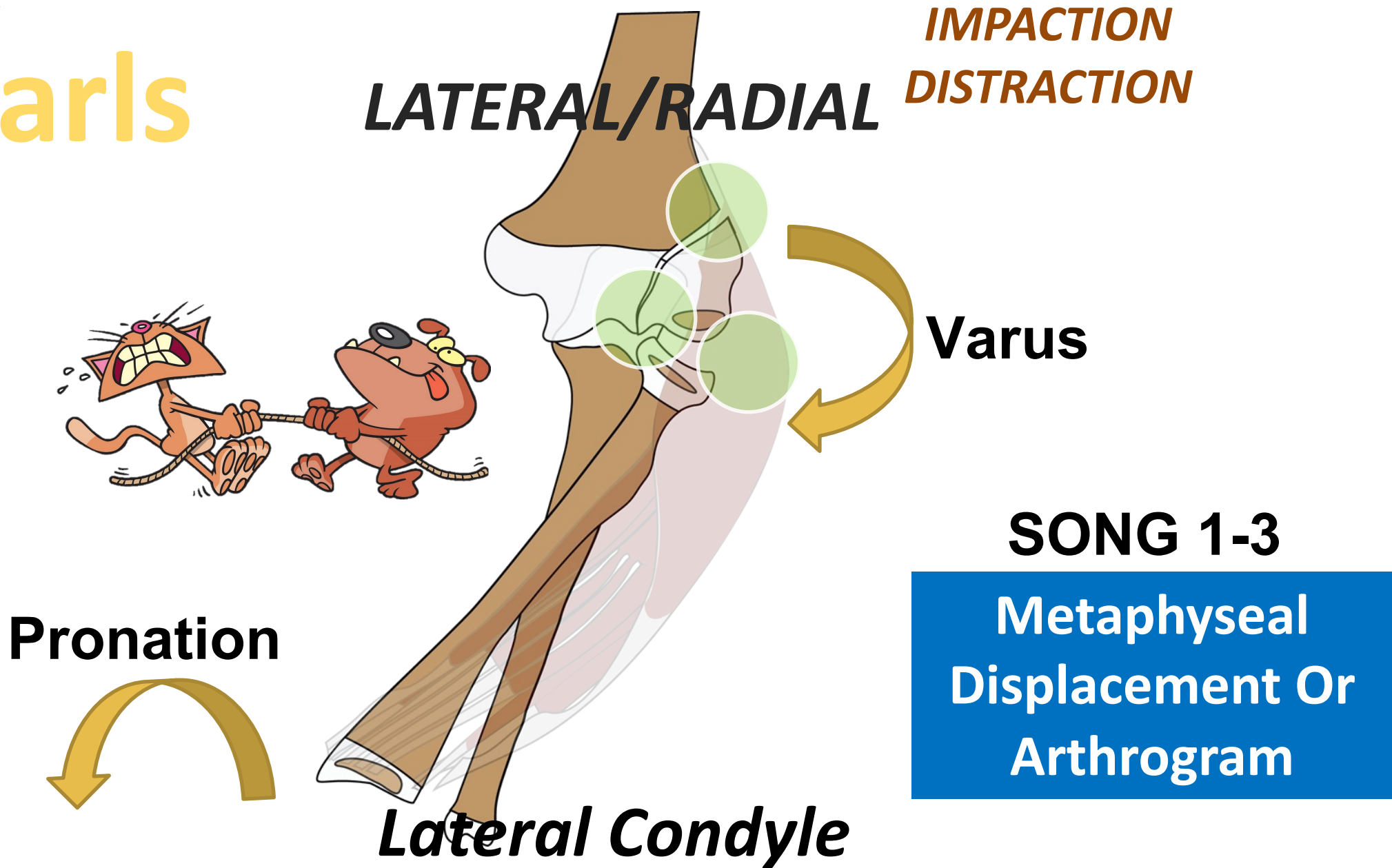


Lateral Condyle

Pattern Recognition

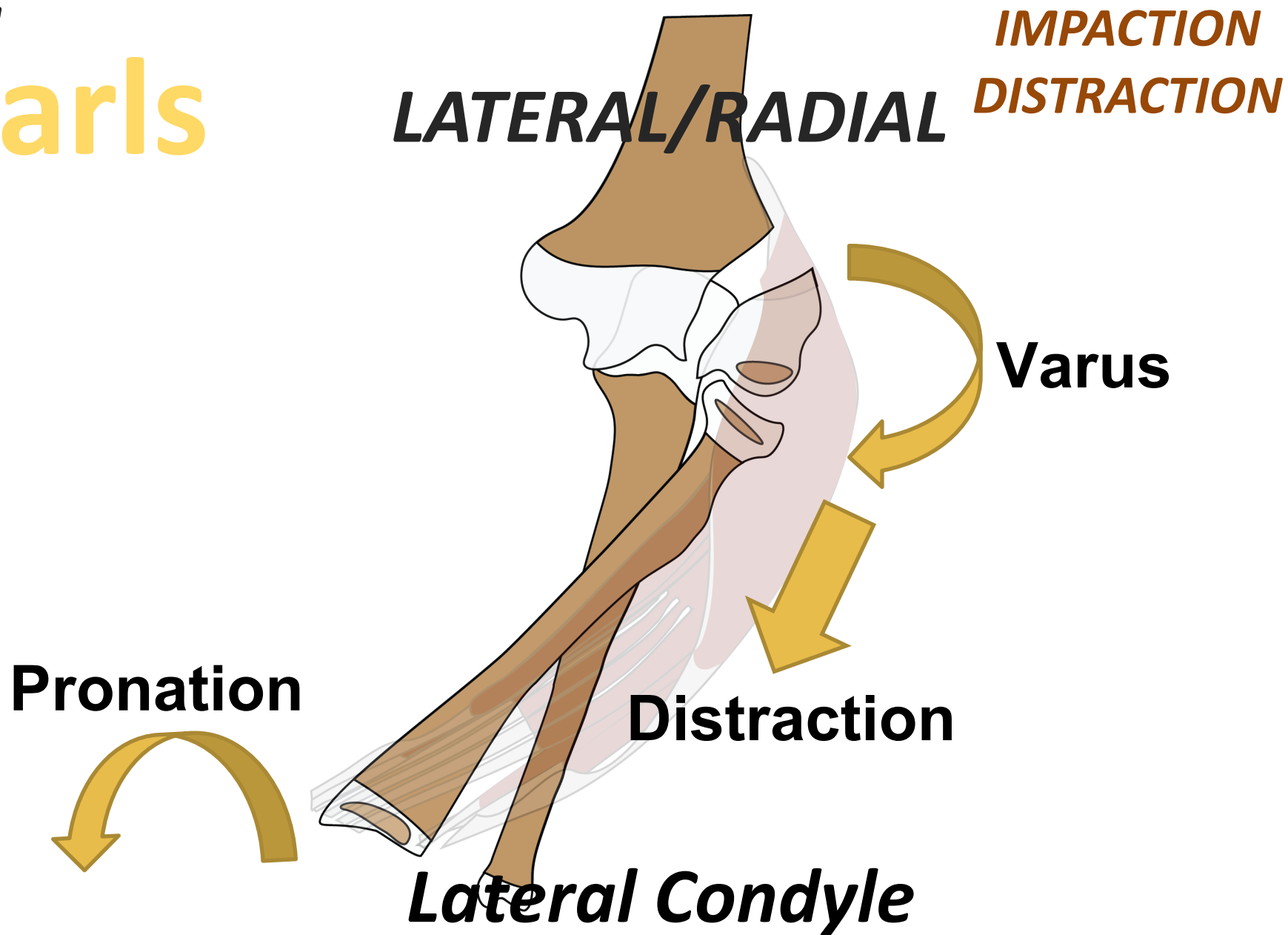


Elbow Pearls

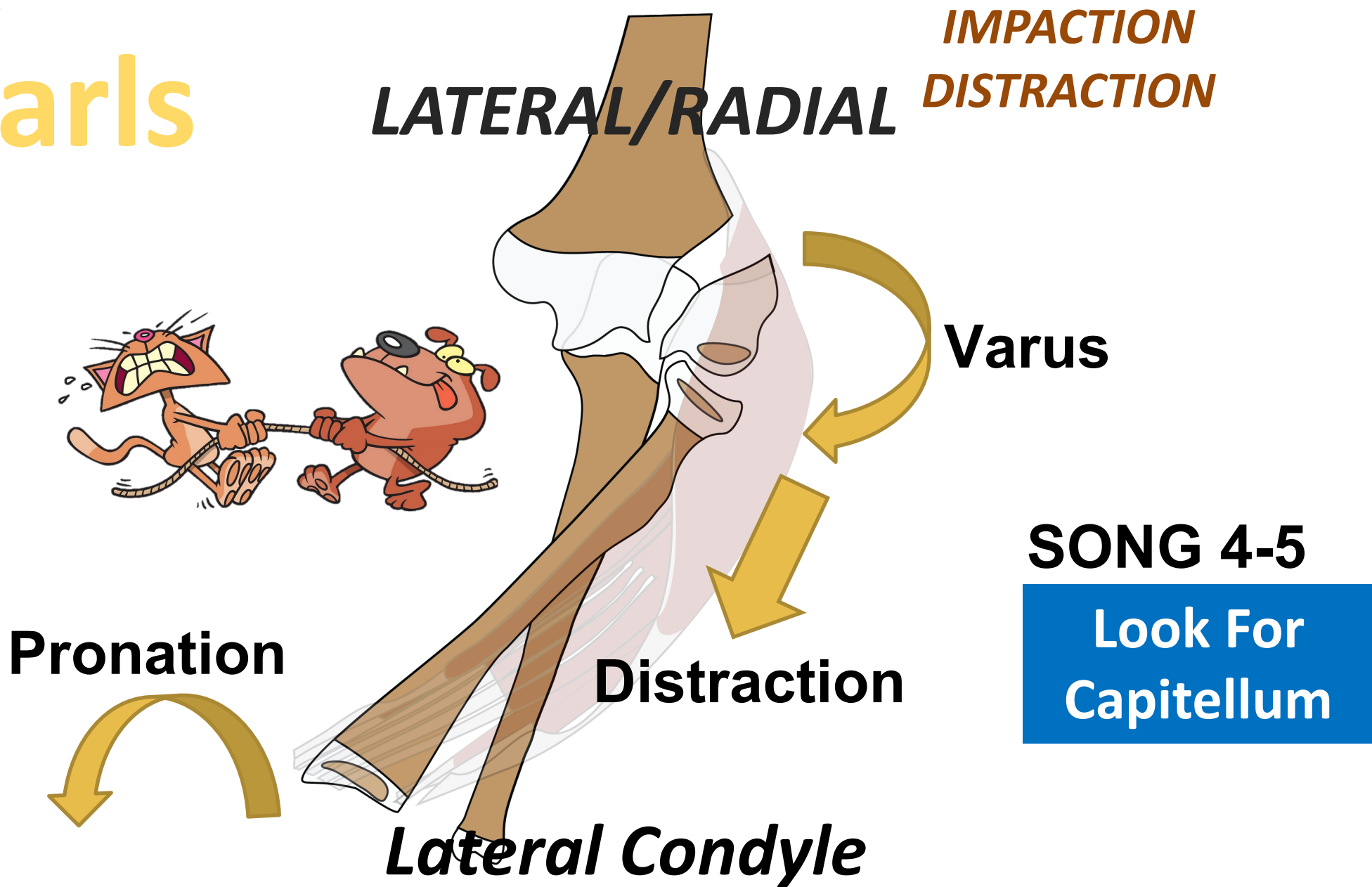


Pattern Recognition

Elbow Pearls



Elbow Pearls

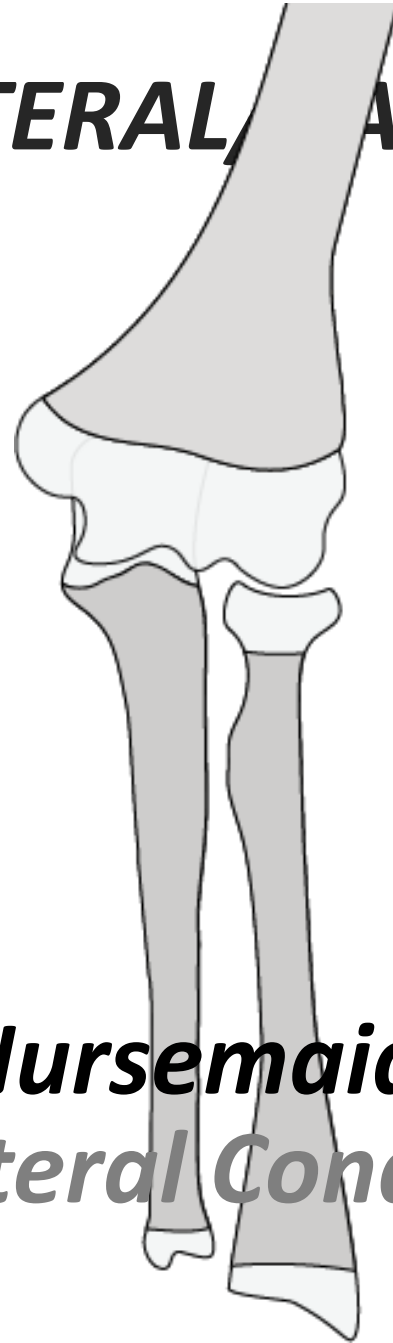


Pattern Recognition

Elbow Pearls

LATERAL/RADIAL

**IMPACTION
DISTRACTION**

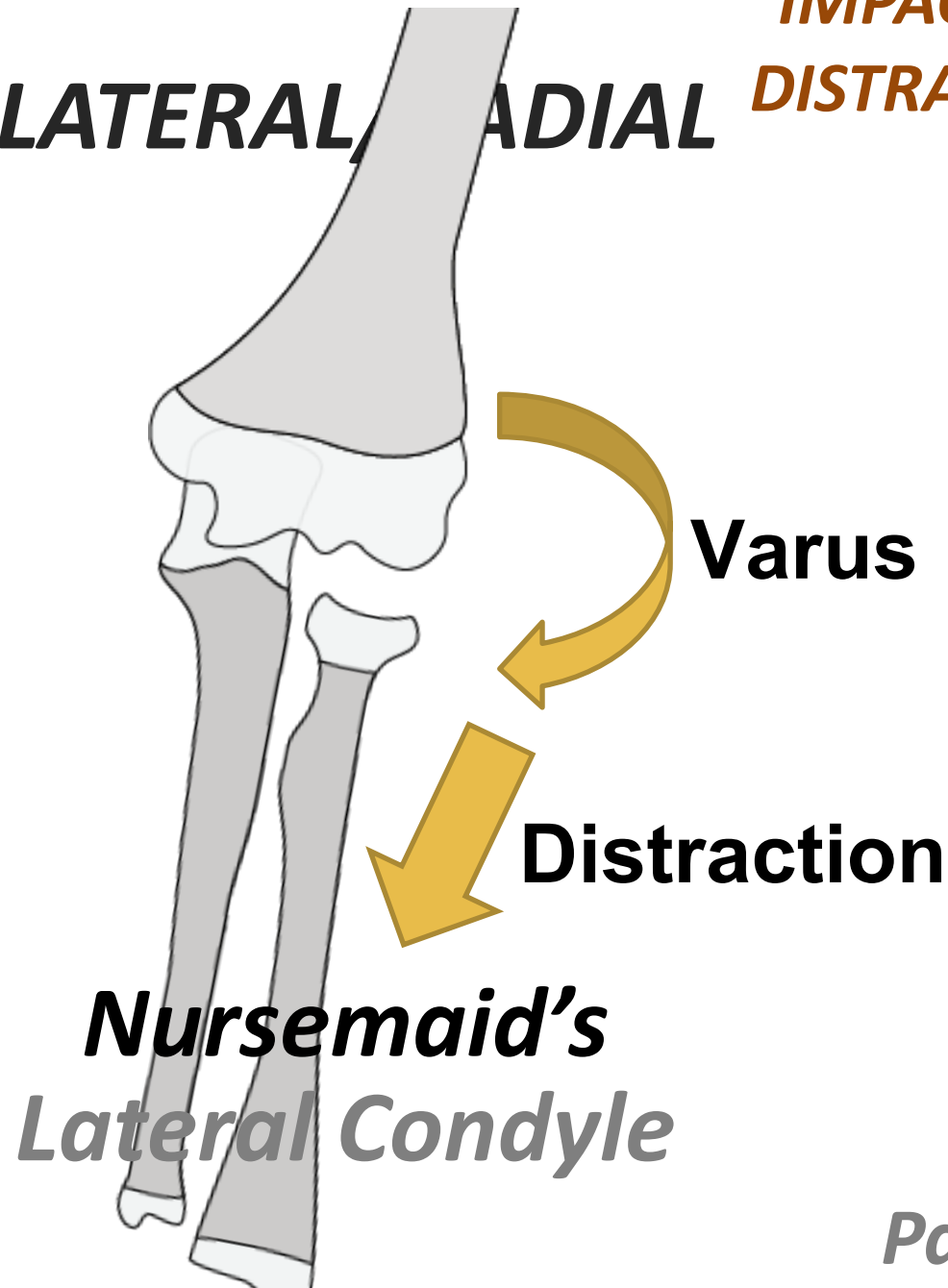


***Nursemaid's
Lateral Condyle***

Pattern Recognition

Elbow Pearls

LATERAL/RADIAL **IMPACTION**
DISTRACTION

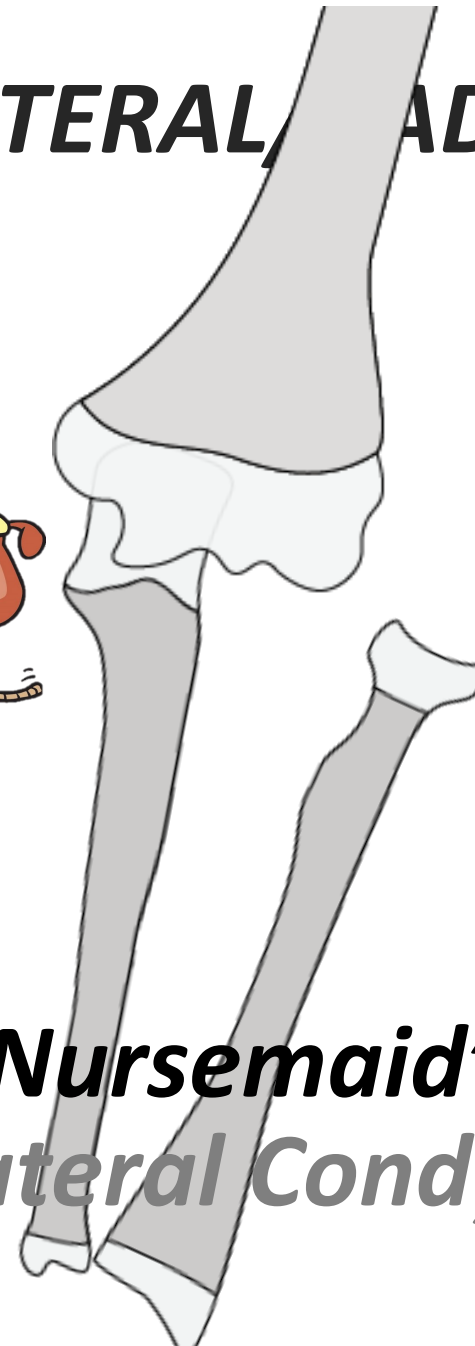



Pattern Recognition

Elbow Pearls

**IMPACTION
DISTRACTION**

LATERAL/RADIAL



***Nursemaid's
Lateral Condyle***

**Same
Mechanisms As
Song 1-5**

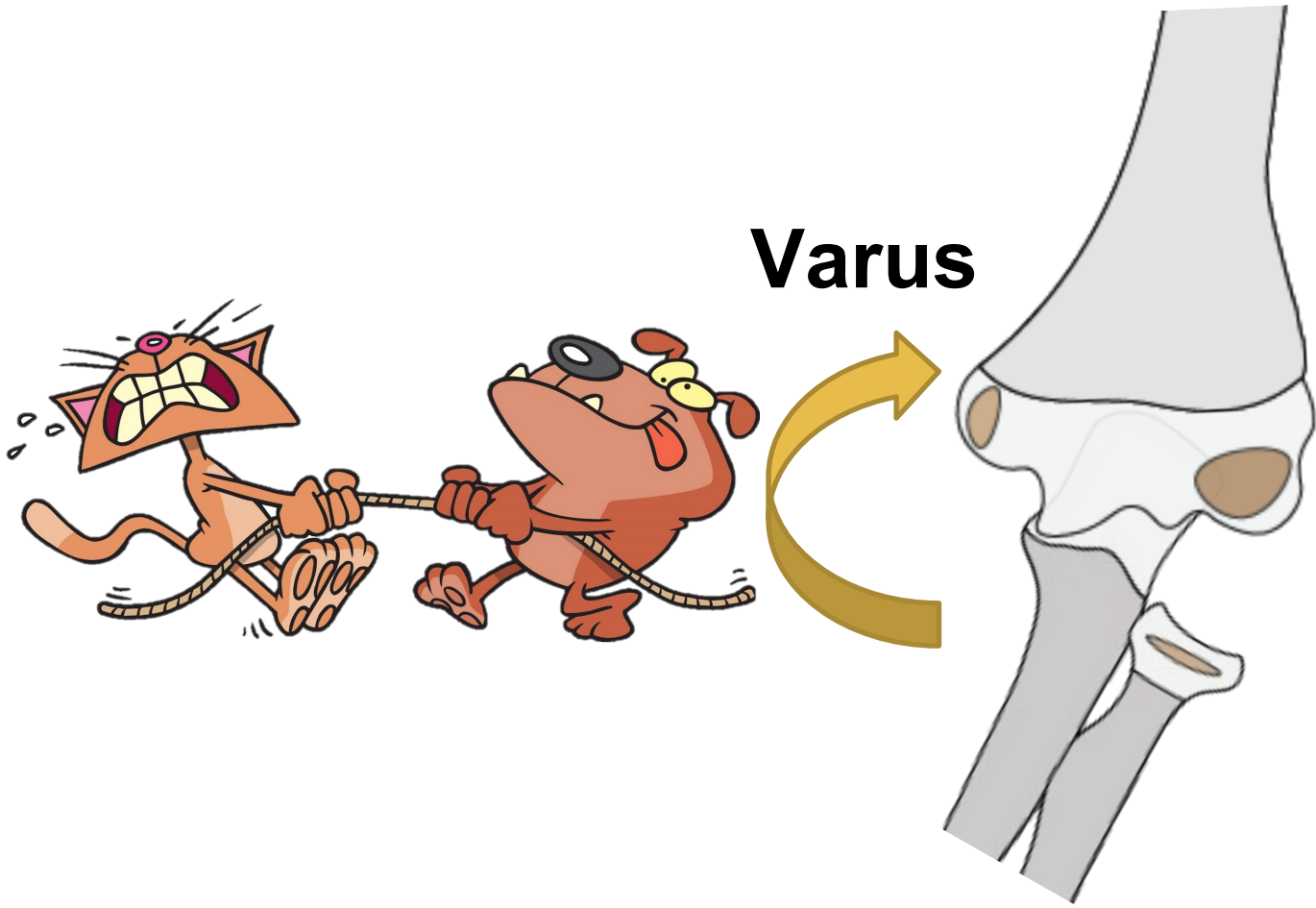
**Young Child
Radial Head
Often Not
Ossified**

Pattern Recognition

Elbow Pearls

LATERAL/RADIAL

**IMPACTION
DISTRACTION**

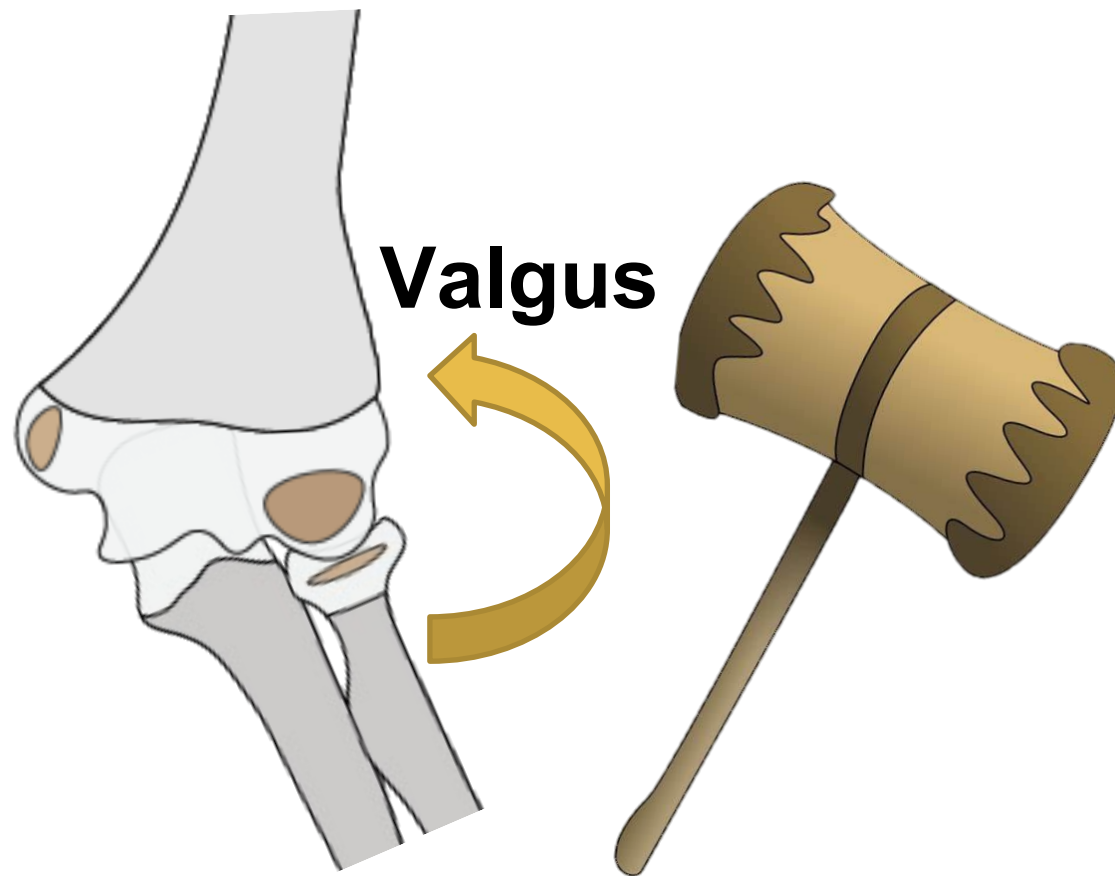


Pattern Recognition

Elbow Pearls

LATERAL/RADIAL

**IMPACTION
DISTRACTION**

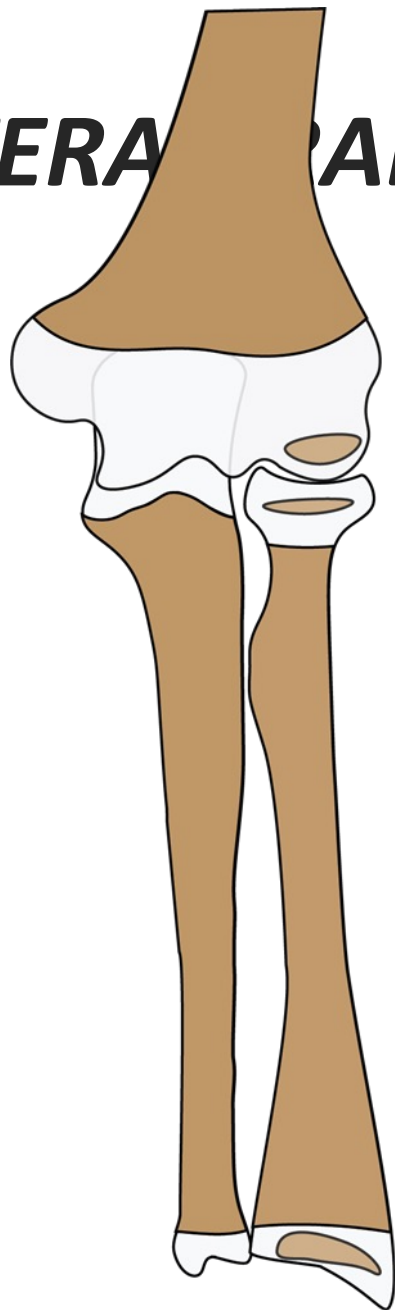


Pattern Recognition

Elbow Pearls

LATERAL RADIAL

**IMPACTION
DISTRACTION**



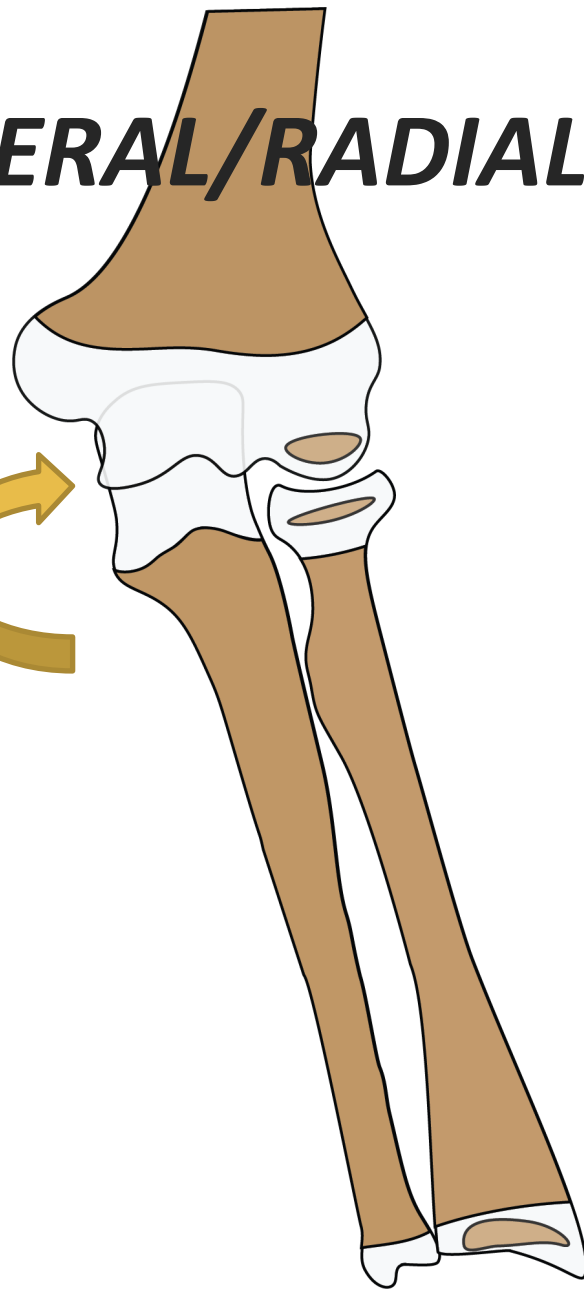
Pattern Recognition

Elbow Pearls

LATERAL/RADIAL

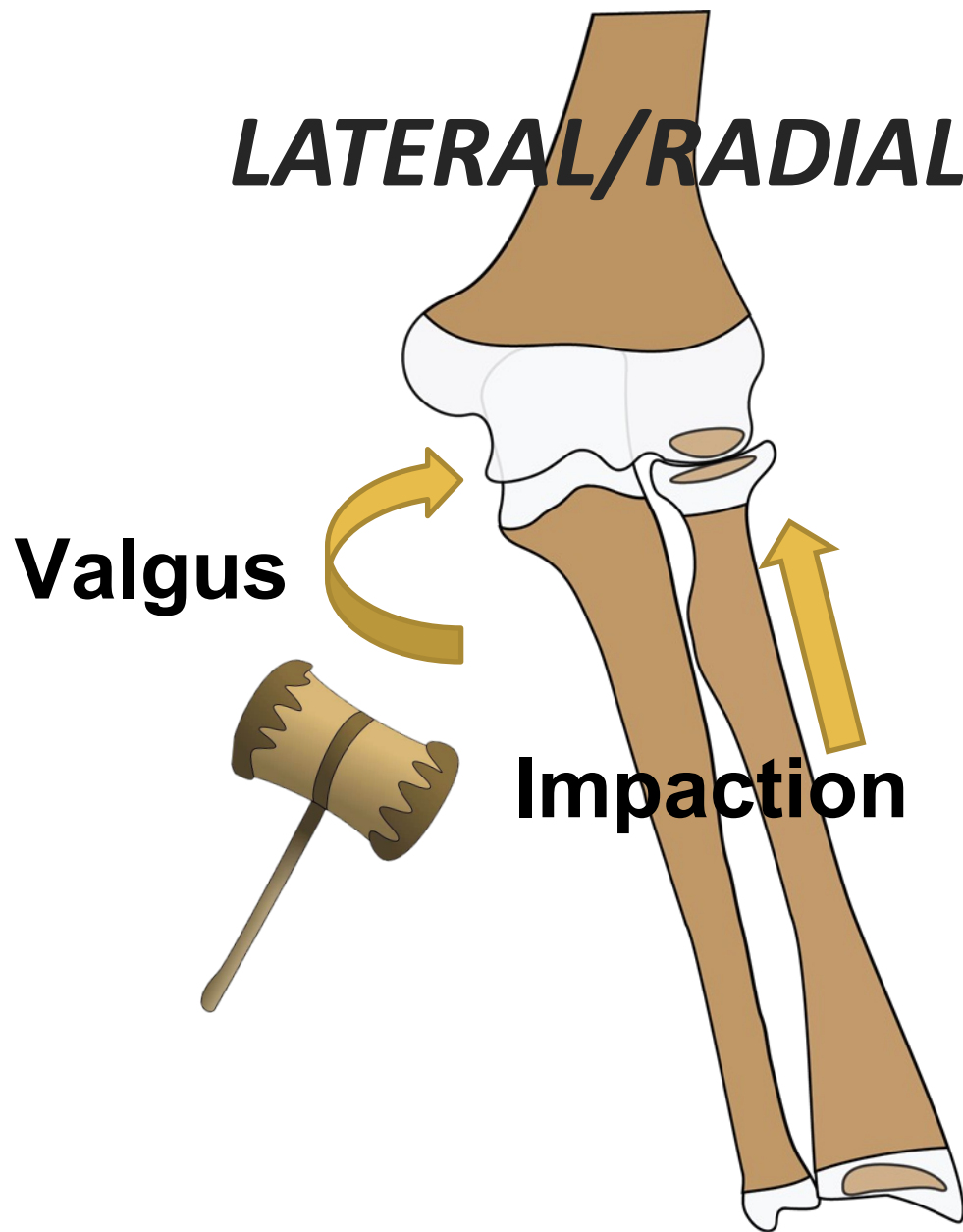
**IMPACTION
DISTRACTION**

Valgus



Pattern Recognition

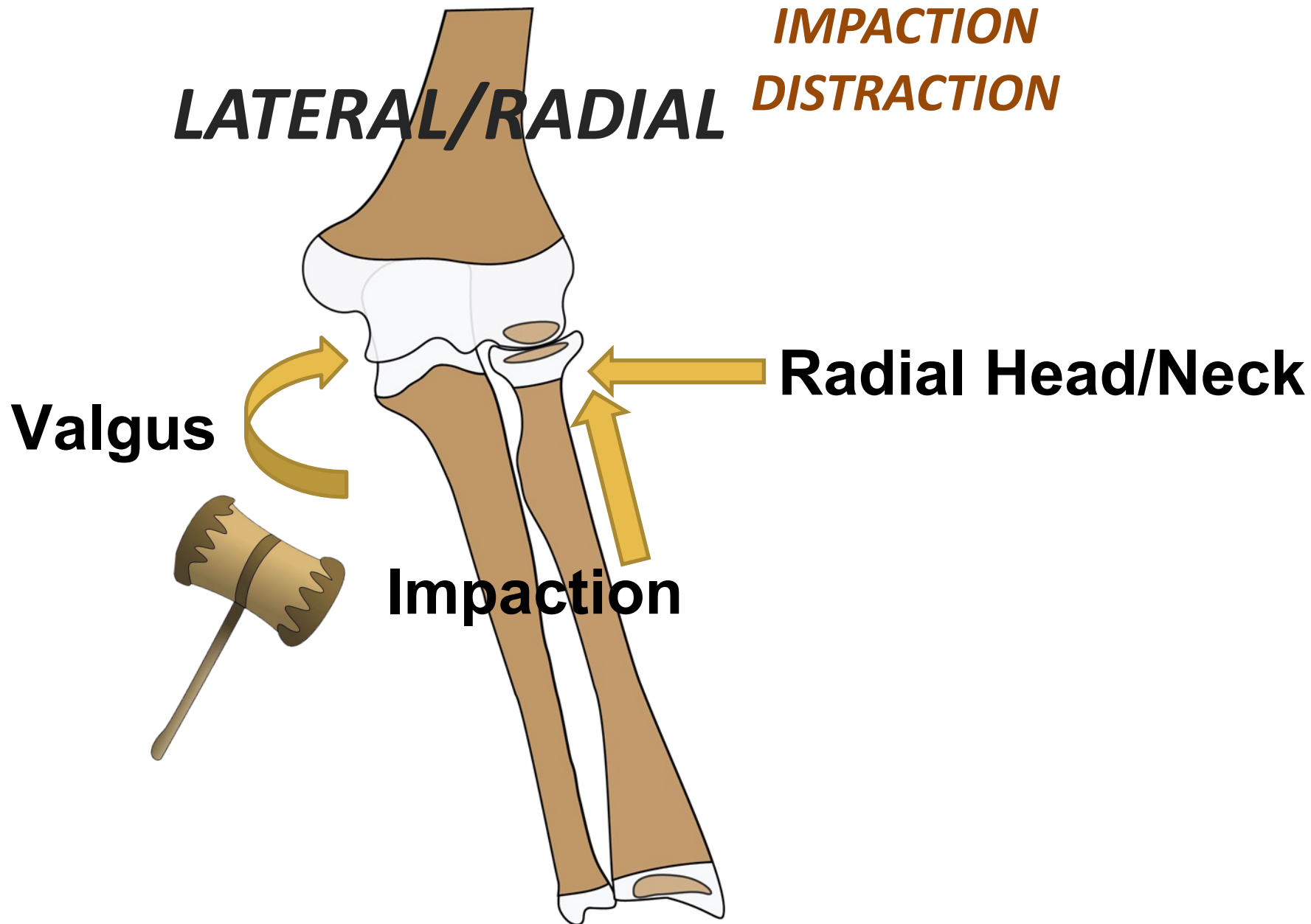
Elbow Pearls



IMPACTION
DISTRACTION

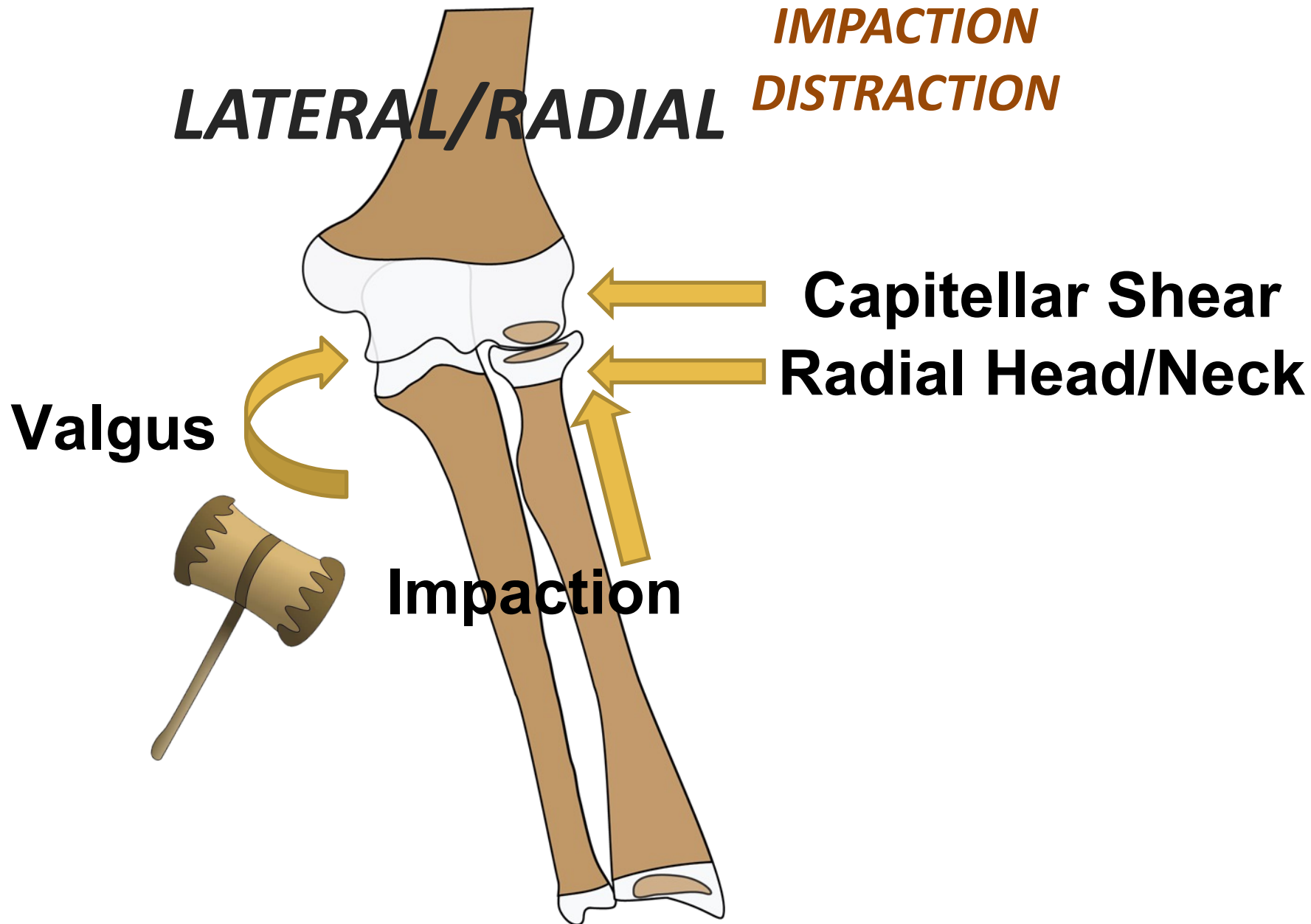
Pattern Recognition

Elbow Pearls



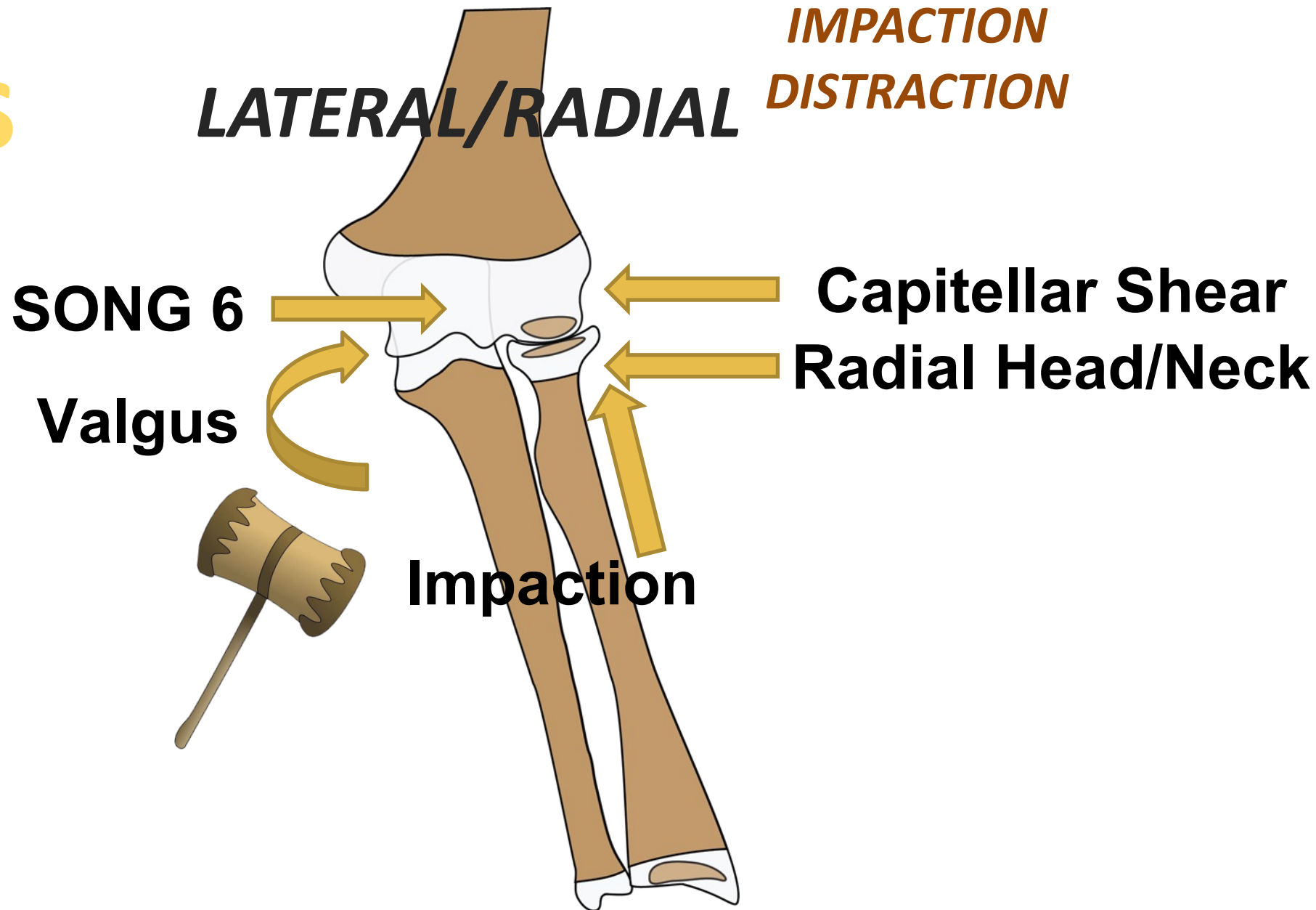
Pattern Recognition

Elbow Pearls

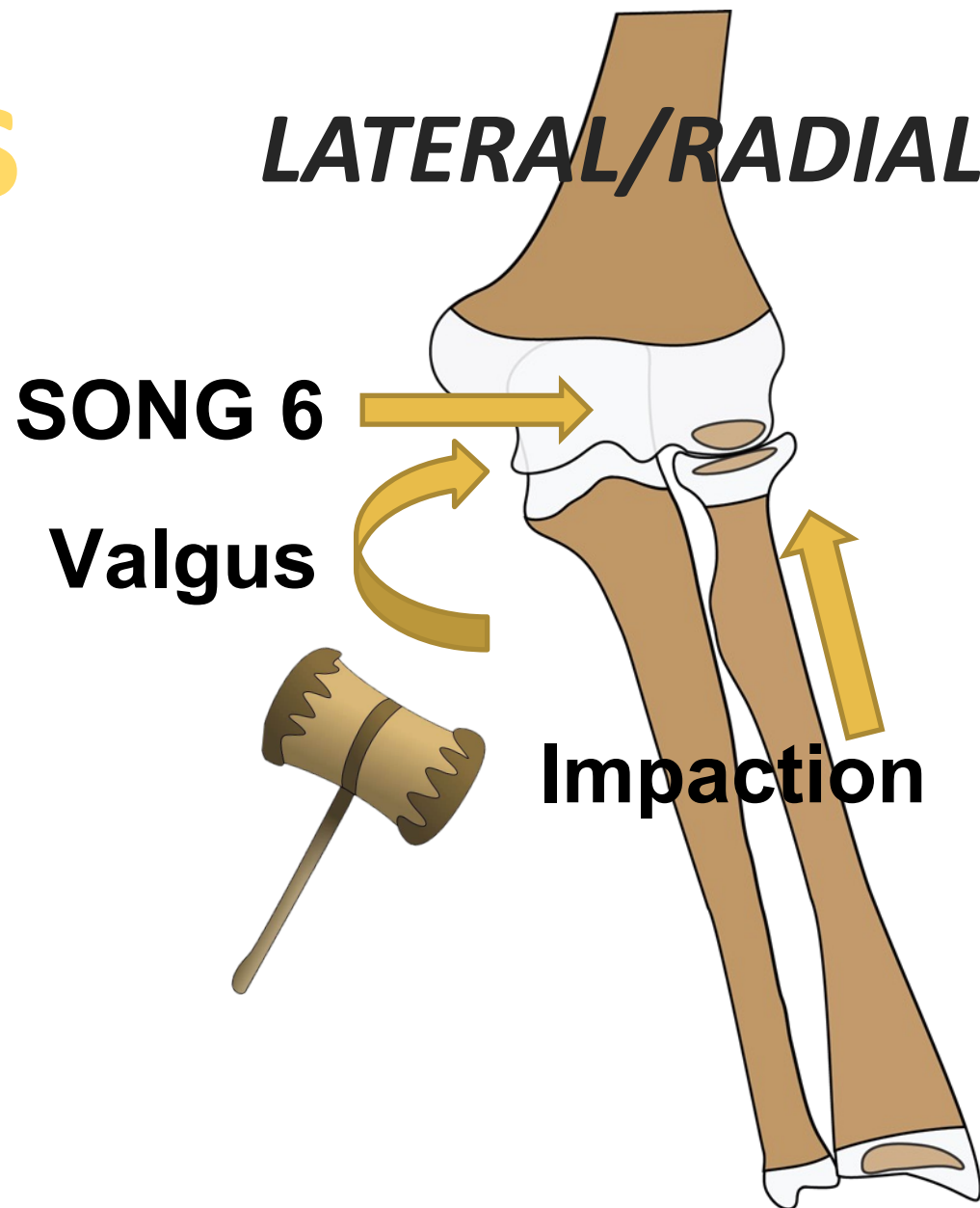


Pattern Recognition

Elbow Pearls



Elbow Pearls



IMPACTION
DISTRACTION


Pattern Recognition

Elbow Pearls

*IMPACTION
DISTRACTION*

LATERAL/RADIAL

SONG 6



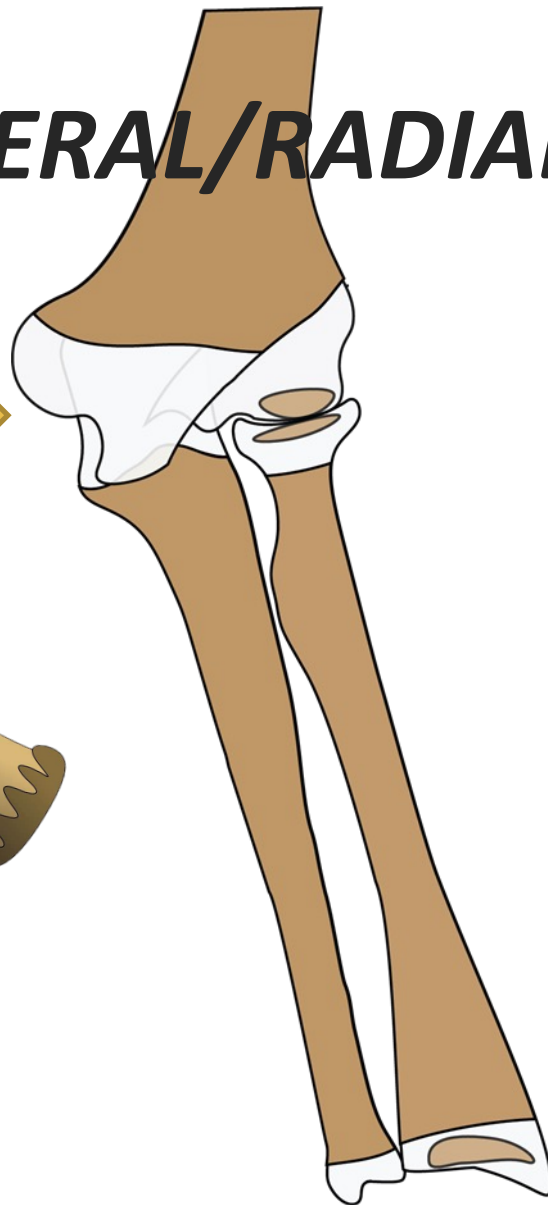
Pattern Recognition

Elbow Pearls

LATERAL/RADIAL

**IMPACTION
DISTRACTION**

SONG 6



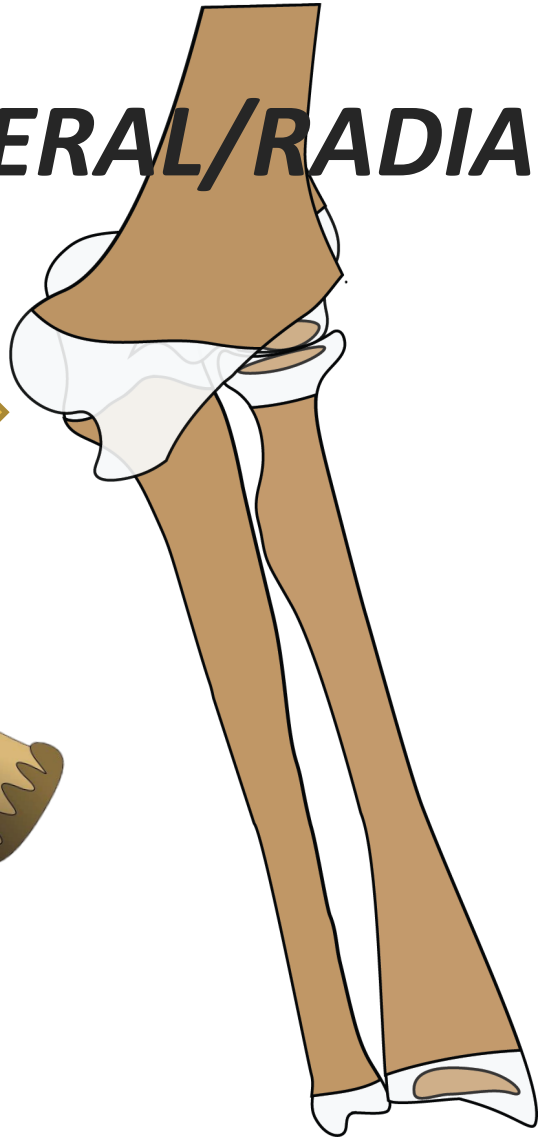
Pattern Recognition

Elbow Pearls

LATERAL/RADIAL

**IMPACTION
DISTRACTION**

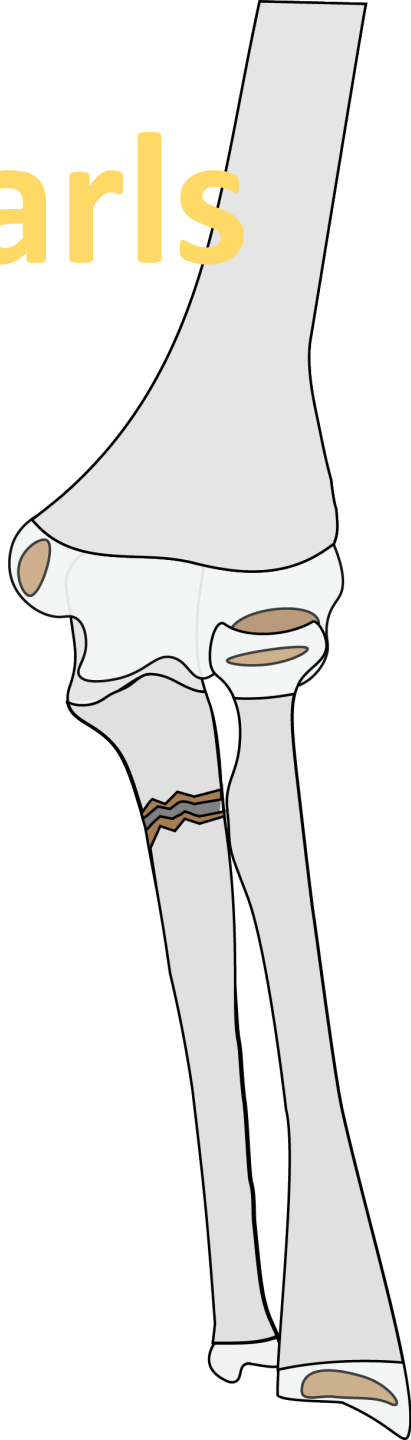
SONG 6



**DISLOCATES THE
ULNOHUMERAL
JOINT!**

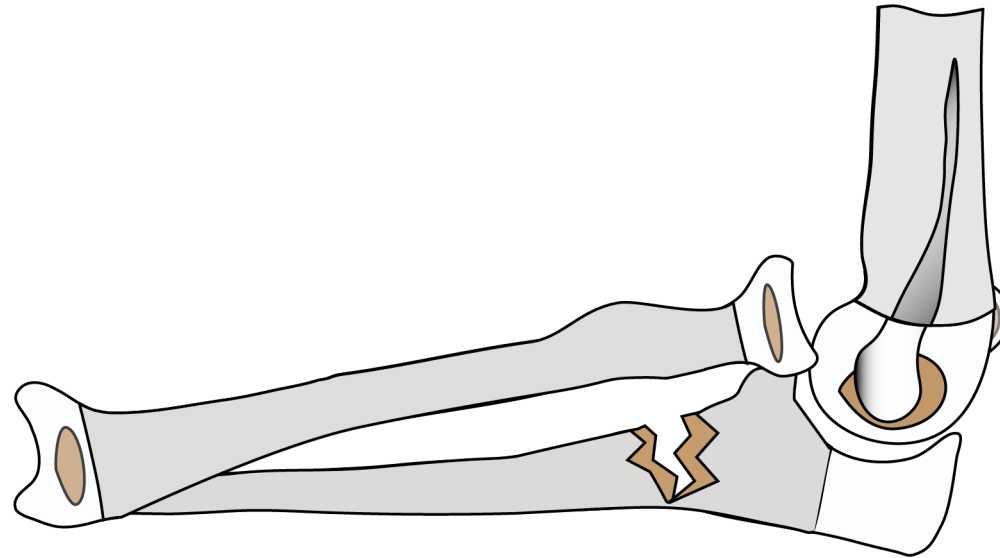
Pattern Recognition

Elbow Pearls



LATERAL/RADIAL

**IMPACTION
DISTRACTION**

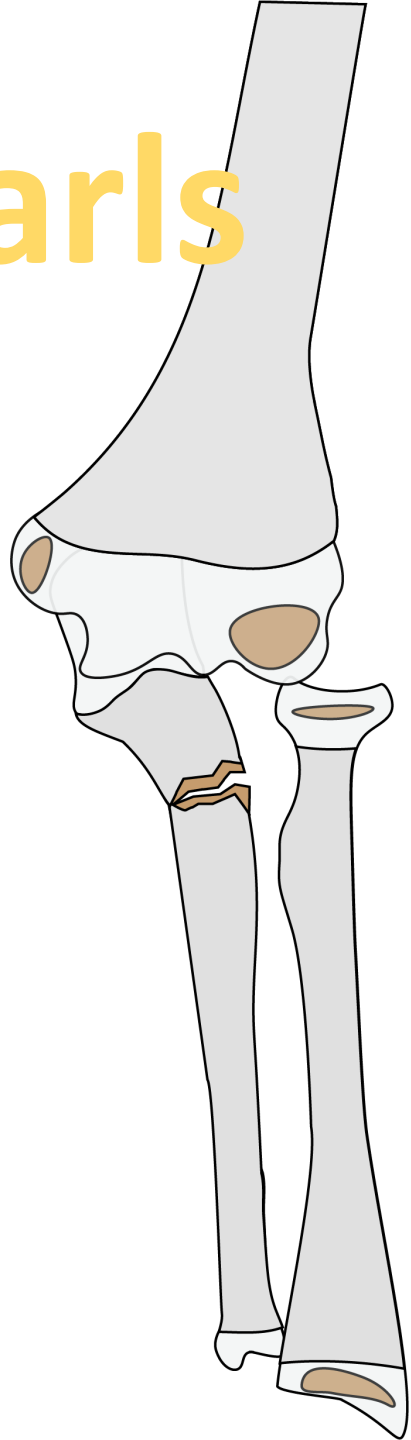


BADO 1

Monteggia

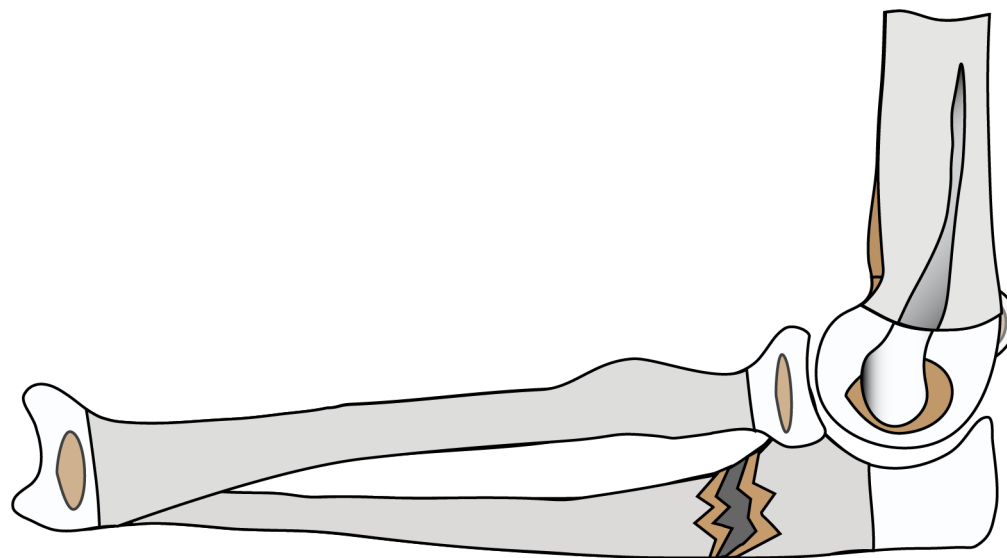
Pattern Recognition

Elbow Pearls



LATERAL/RADIAL

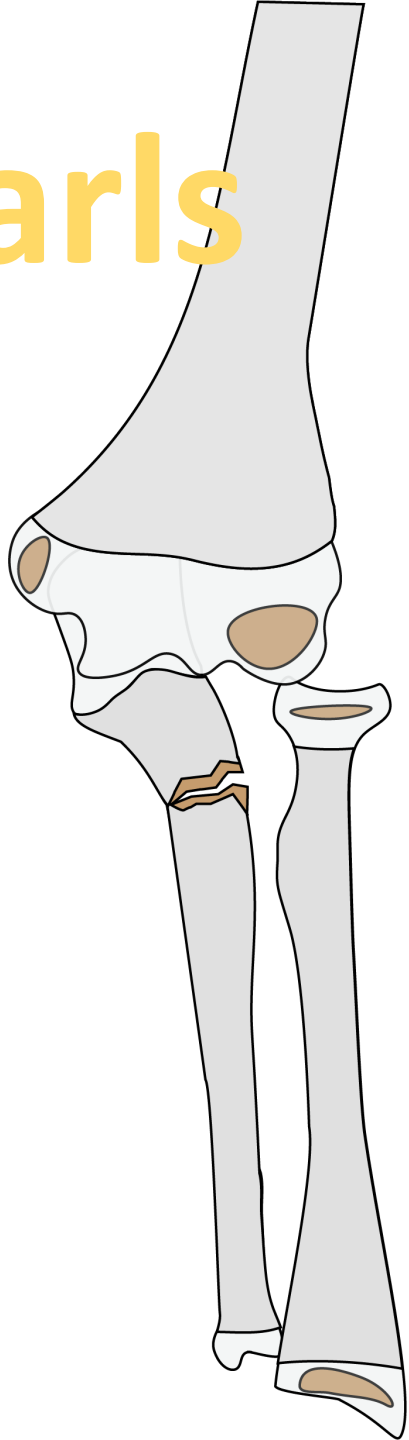
**IMPACTION
DISTRACTION**



**BADO 3
Monteggia**

Pattern Recognition

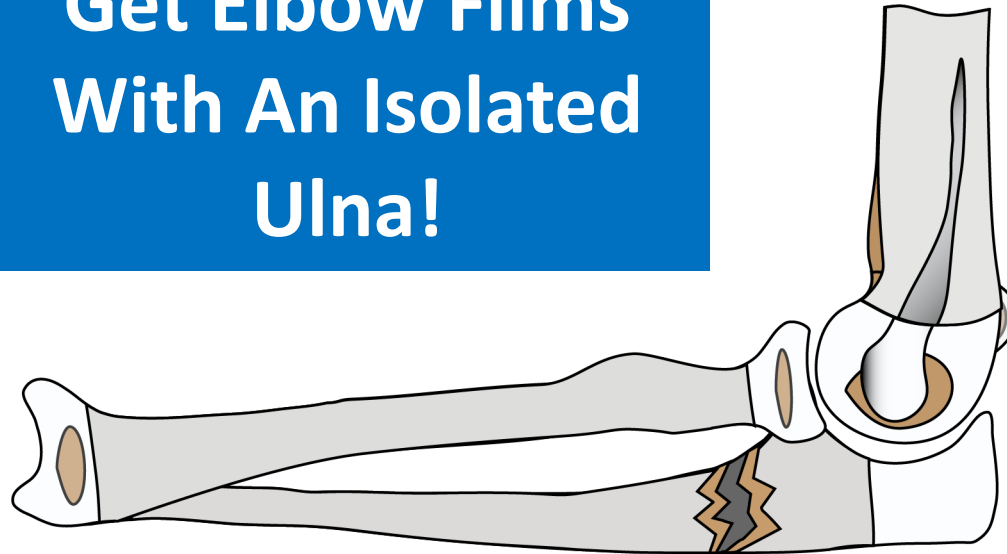
Elbow Pearls



LATERAL/RADIAL

**IMPACTION
DISTRACTION**

**Get Elbow Films
With An Isolated
Ulna!**



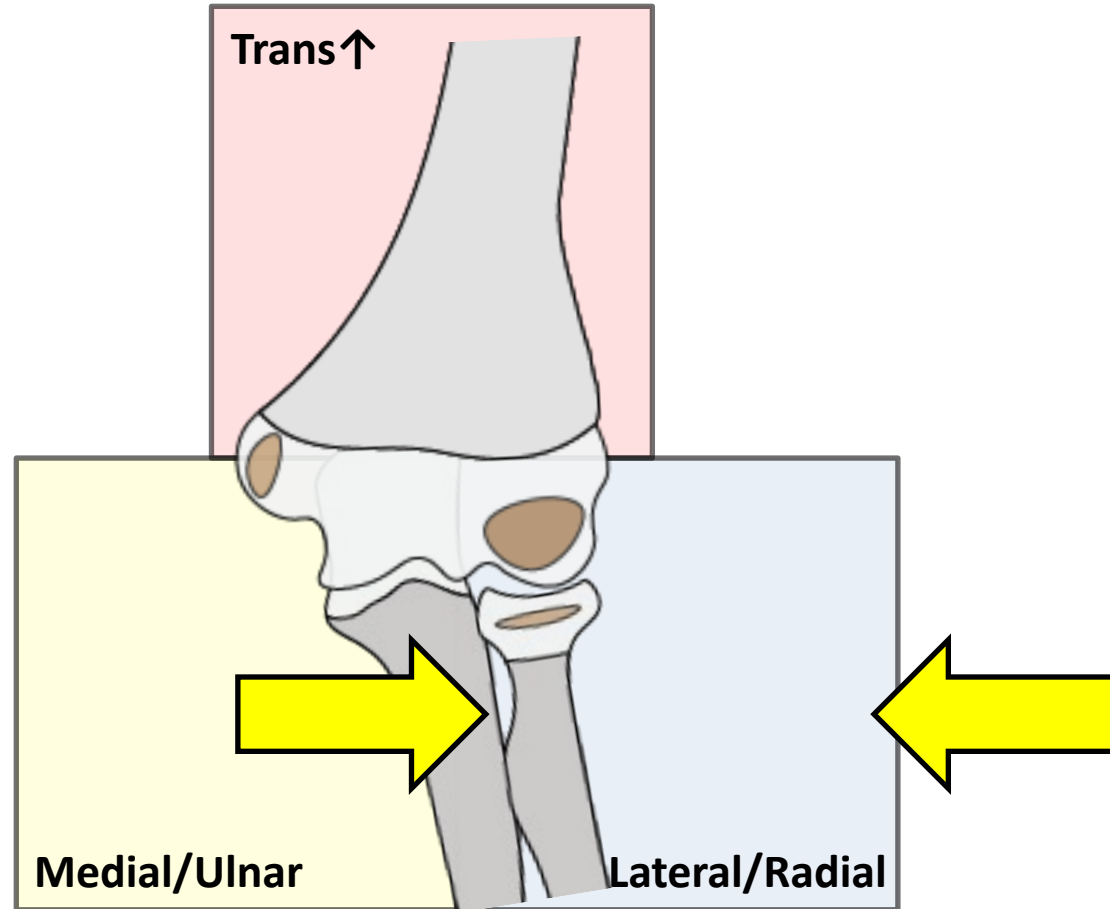
***BADO 3
Monteggia***

**Watch Out for A
PIN PALSY!**

Pattern Recognition

Elbow Pearls

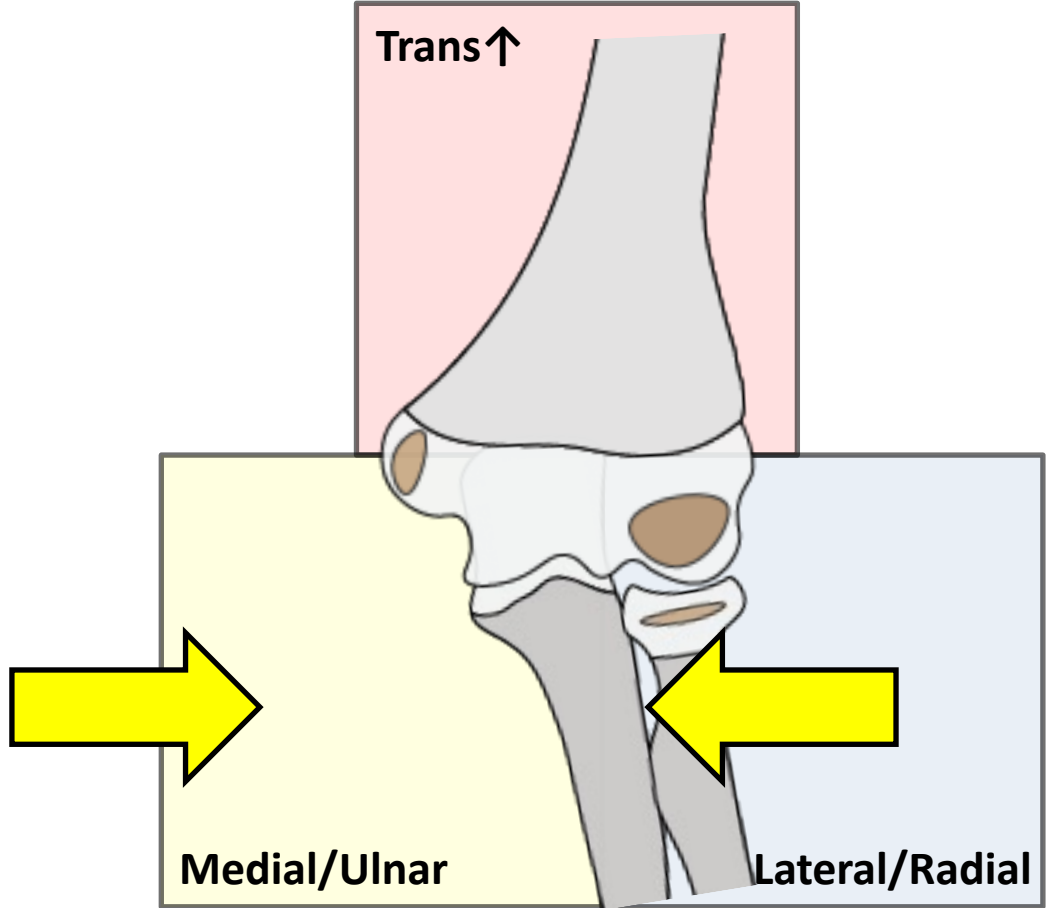
LATERAL/RADIAL



Pattern Recognition

Elbow Pearls

MEDIAL/ULNAR

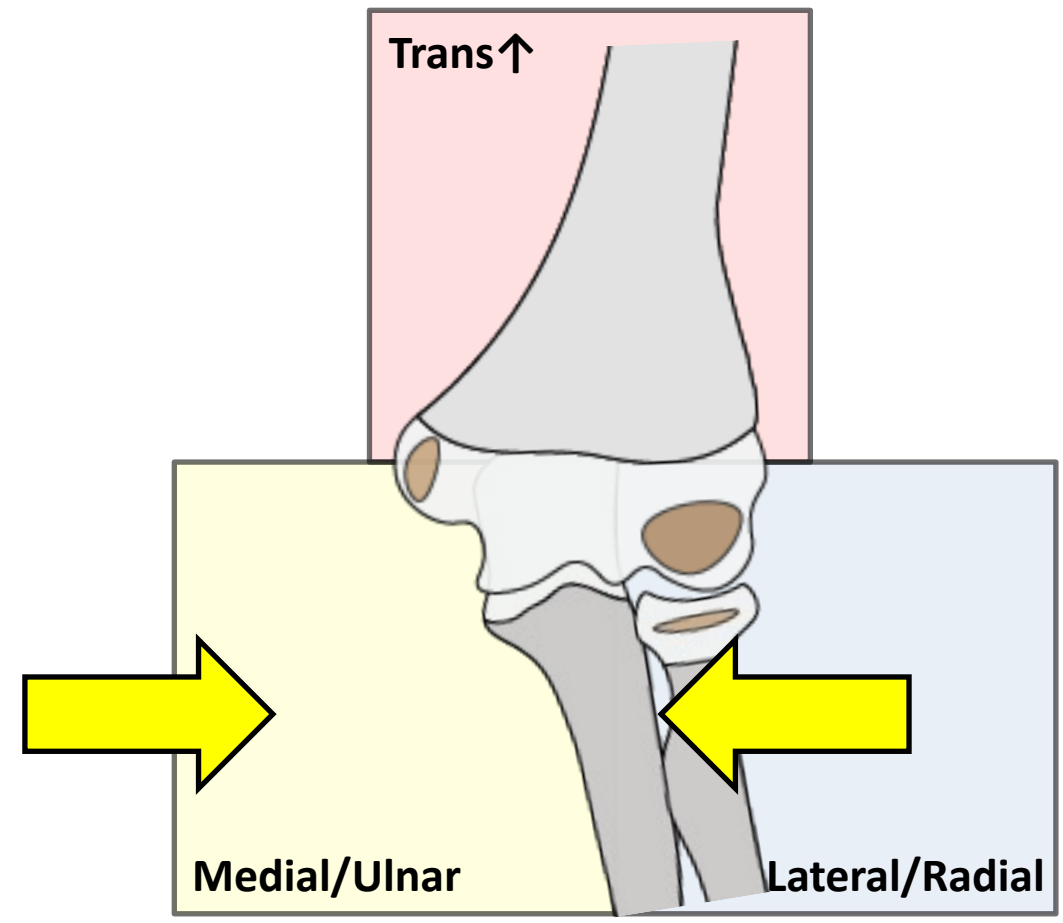


Pattern Recognition

Elbow Pearls

MEDIAL/ULNAR

*IMPACTION
DISTRACTION*

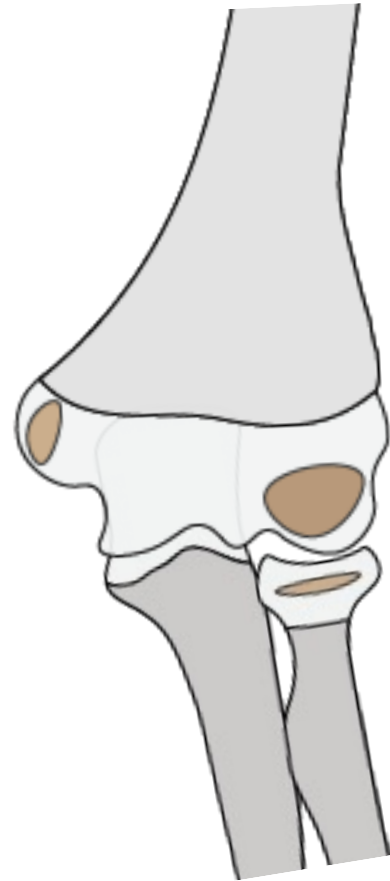


Pattern Recognition

Elbow Pearls

MEDIAL/ULNAR

***IMPACTION
DISTRACTION***

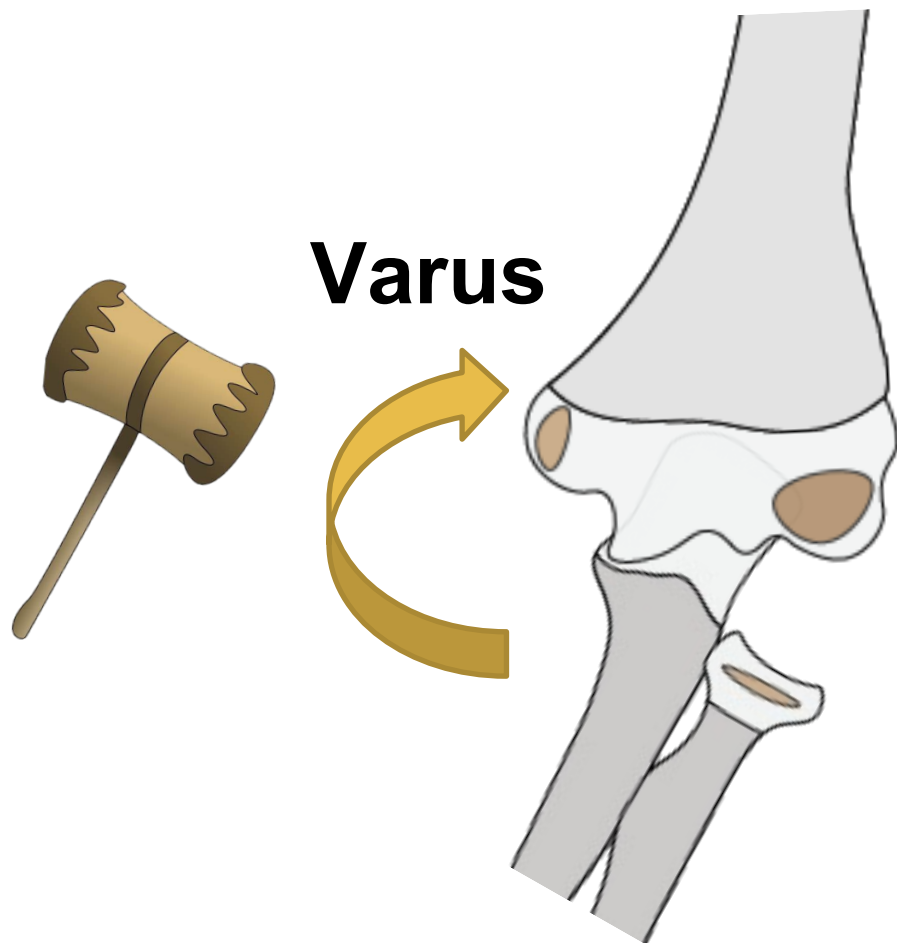


Pattern Recognition

Elbow Pearls

MEDIAL/ULNAR

***IMPACTION
DISTRACTION***

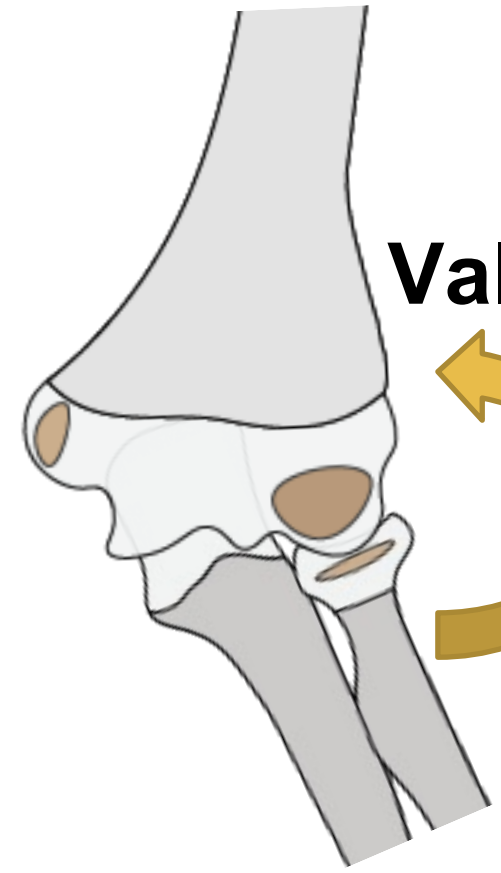


Pattern Recognition


Elbow Pearls

MEDIAL/ULNAR

*IMPACTION
DISTRACTION*



Valgus

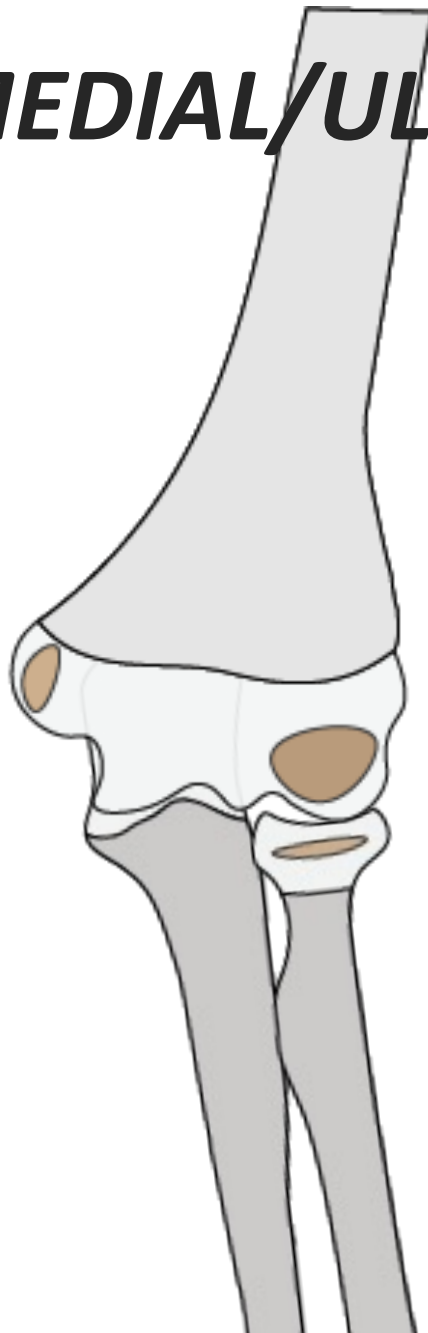


Pattern Recognition

Elbow Pearls

MEDIAL/ULNAR

***IMPACTION
DISTRACTION***

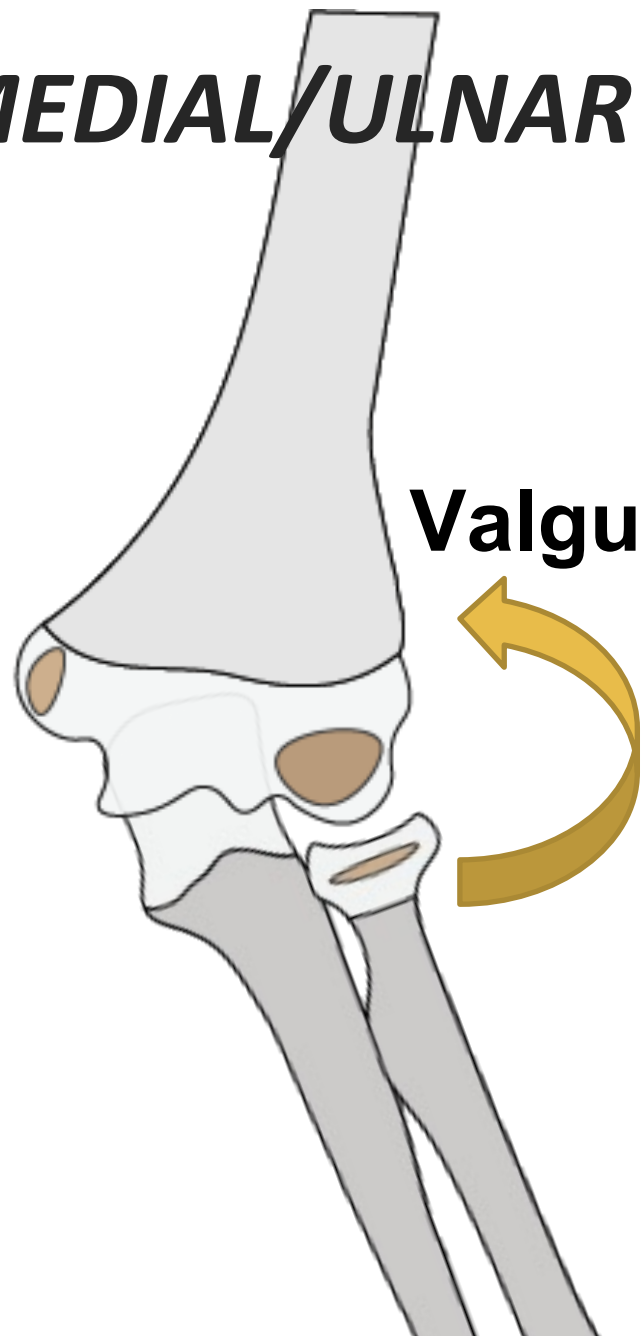


Pattern Recognition


Elbow Pearls

MEDIAL/ULNAR

**IMPACTION
DISTRACTION**



Valgus



Pattern Recognition

Elbow Pearls


MEDIAL/ULNAR

**IMPACTION
DISTRACTION**

Distraction

Valgus

Medial Epicondyle

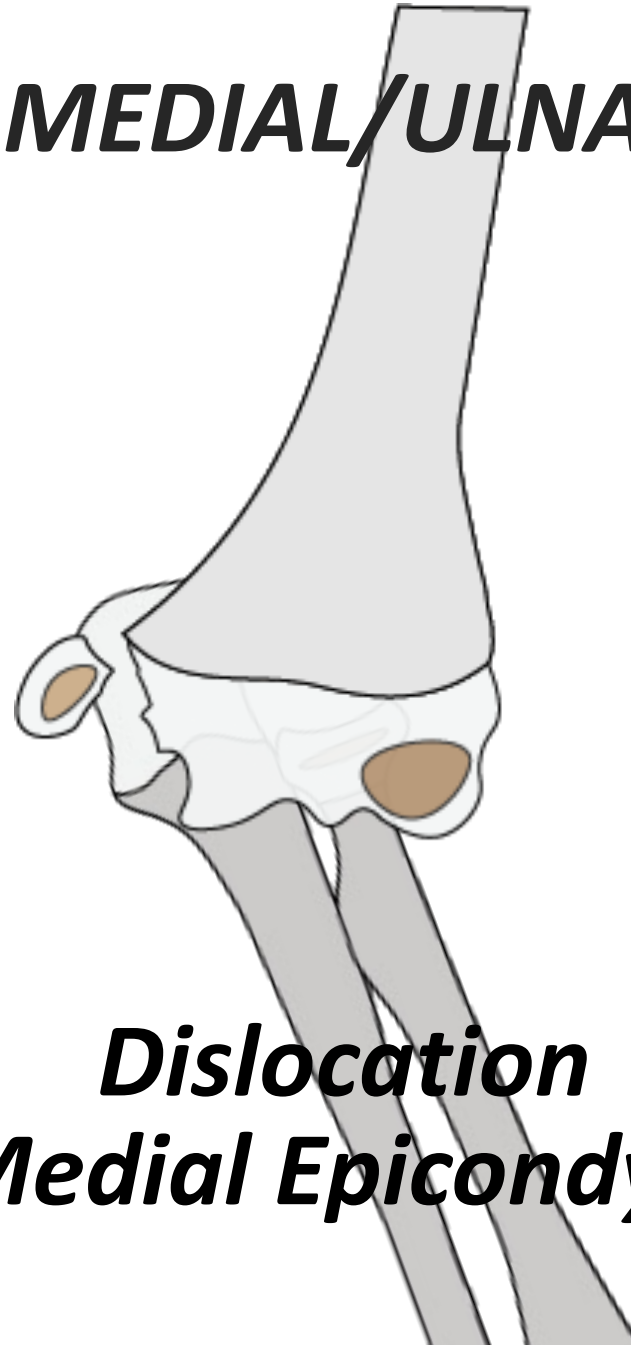


Pattern Recognition


Elbow Pearls

MEDIAL/ULNAR

**IMPACTION
DISTRACTION**



**Dislocation
Medial Epicondyle**



Pattern Recognition


Elbow Pearls

Make Sure Medial Epicondyle Not Trapped In Joint After Dislocation

MEDIAL/ULNAR

**IMPACTION
DISTRACTION**

**Dislocation
Medial Epicondyle**

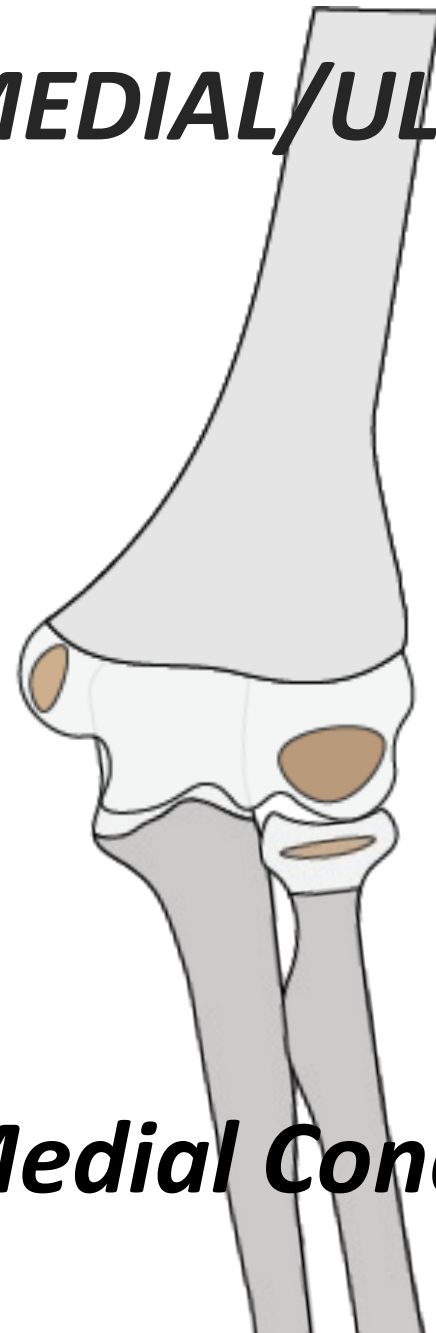



Pattern Recognition

Elbow Pearls

*IMPACTION
DISTRACTION*

MEDIAL/ULNAR




Medial Condyle

Pattern Recognition

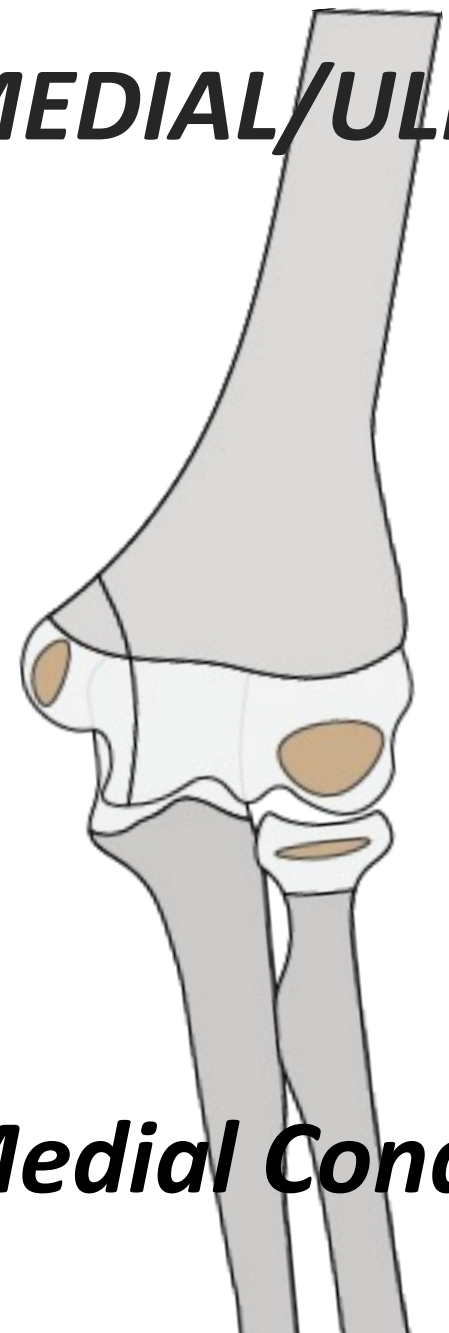
Elbow Pearls

*IMPACTION
DISTRACTION*

MEDIAL/ULNAR



Varus




Medial Condyle

Pattern Recognition

Elbow Pearls

*IMPACTION
DISTRACTION*

MEDIAL/ULNAR

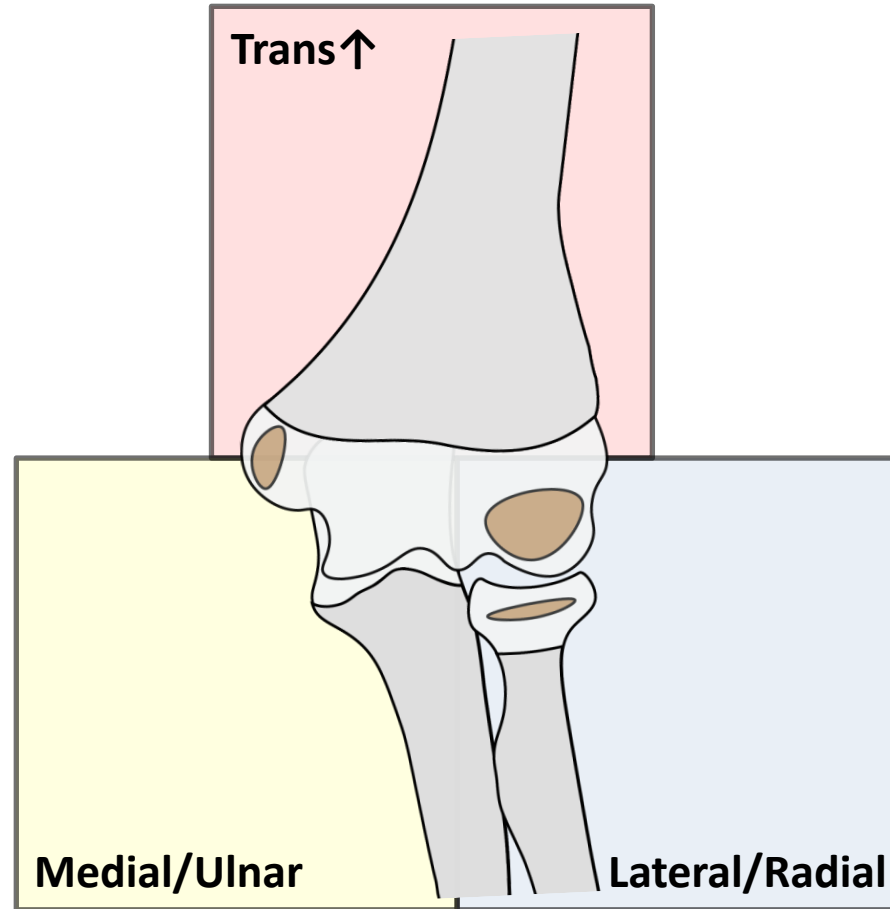


**Very Rare
High Complication
Rate For Healing**

Medial Condyle

Pattern Recognition

Elbow Pearls



Pattern Recognition

Elbow

Team-Effort

Where Is It Torn?

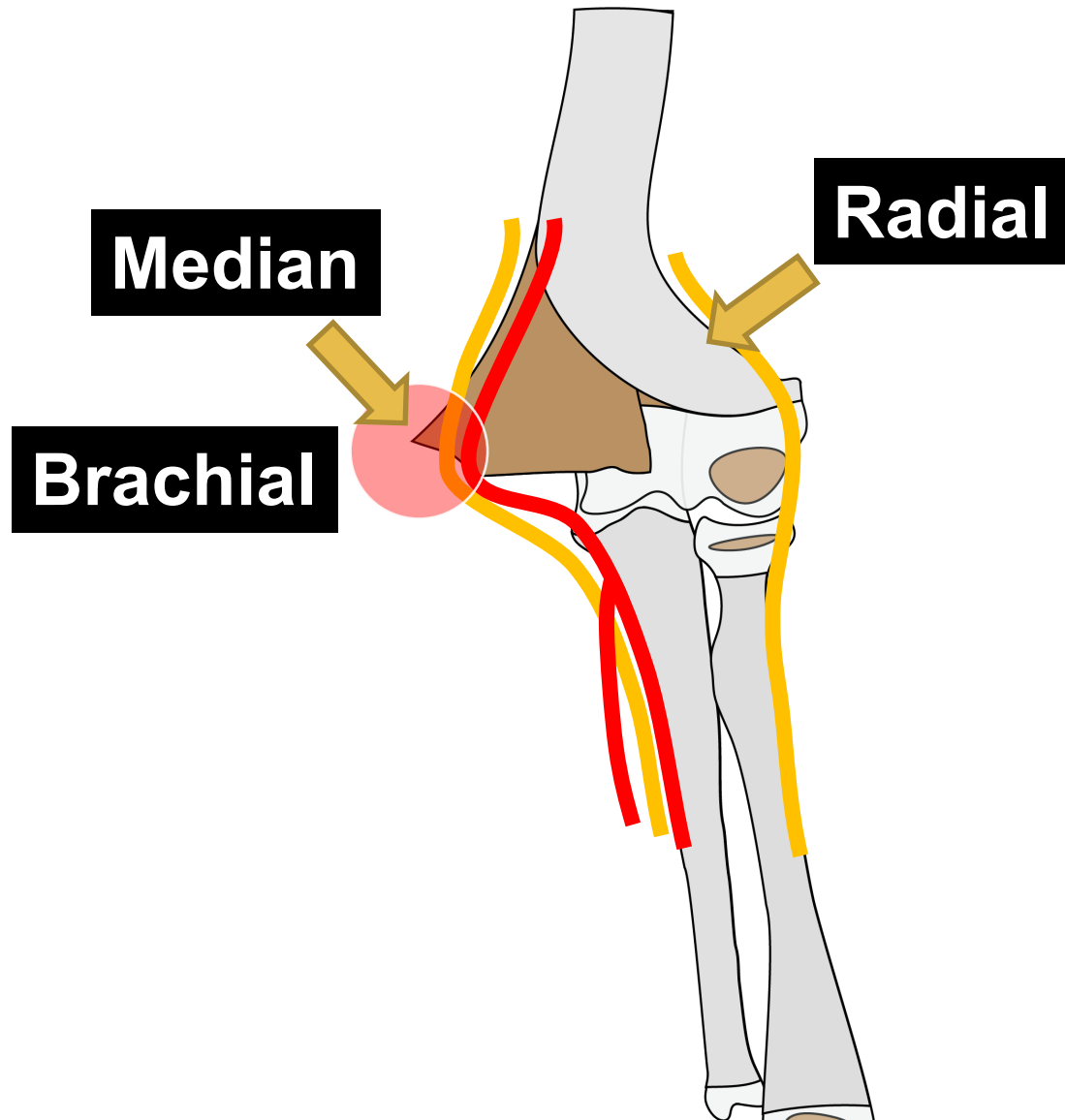
What Could Be Hurt?

Where Is It Intact?

How To Replace It?

4 QUESTIONS

Elbow Pearls



Pattern Recognition

THANK YOU

