

PAOS in the Music City

Pediatric Musculoskeletal Infection

<https://www.jposna.org/ojs/index.php/jposna/article/view/124>
Or just search JPOSNA Schoenecker

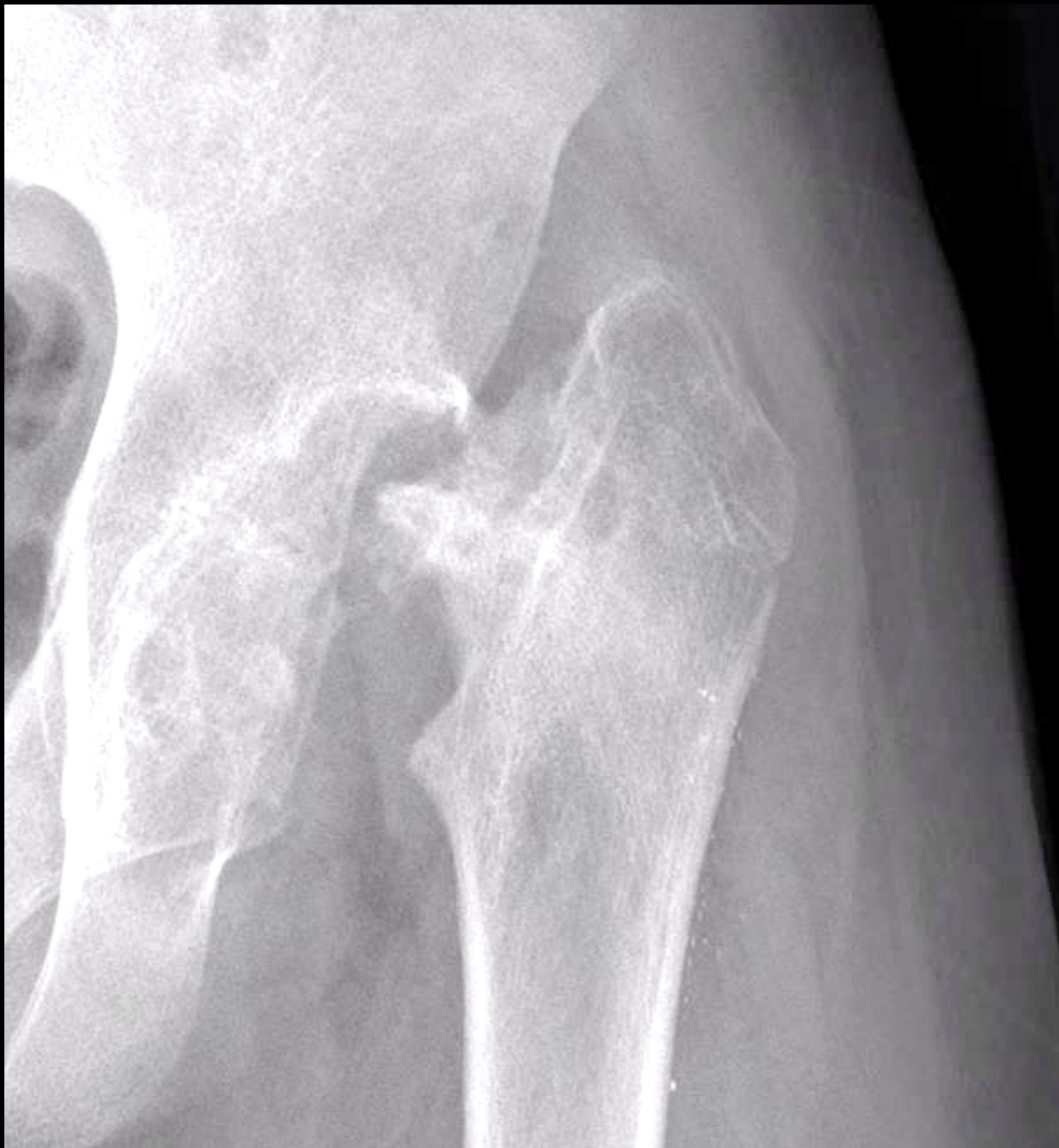Jonathan Schoenecker

Associate Professor Orthopaedics Pharmacology Pathology Pediatrics
Jeffrey Mast Chair of Trauma and Hip Surgery
Vanderbilt University



MSKI





LEARN TO
TRIAGE THE
SEVERITY



OSTEO

Team-Effort

4 QUESTIONS

OSTEO

Team-Effort

Where Is It?

4 QUESTIONS

OSTEO

Team-Effort

Where Is It?

Is It A Bug?

4 QUESTIONS

OSTEO

Team-Effort

Where Is It?

Is It A Bug?

How Severe Is It?

4 QUESTIONS

OSTEO

Team-Effort

Where Is It?

Is It A Bug?

How Severe Is It?

Treat It!

4 QUESTIONS

OSTEO

Team-Effort

Where Is It?

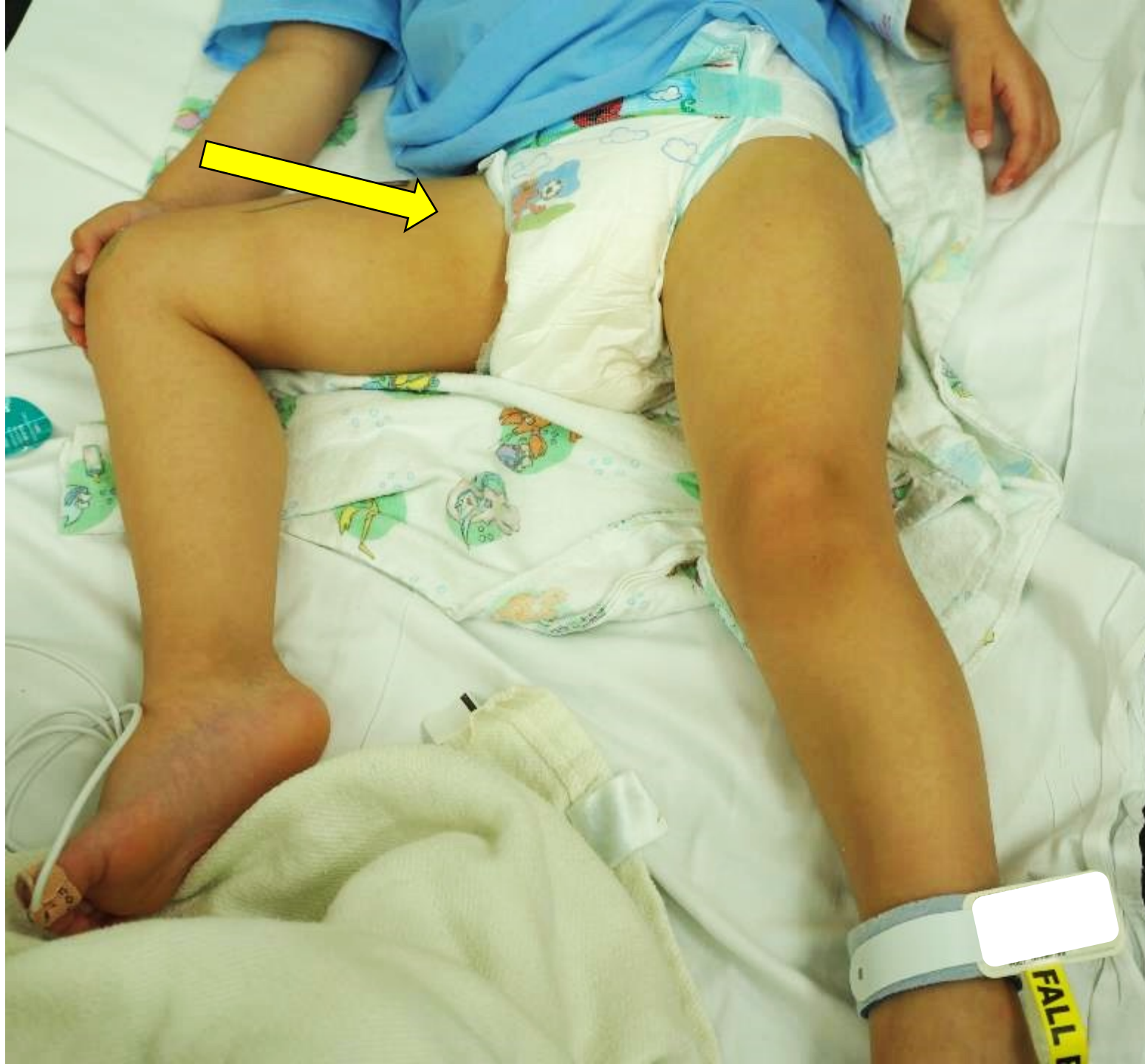Is It A Bug?

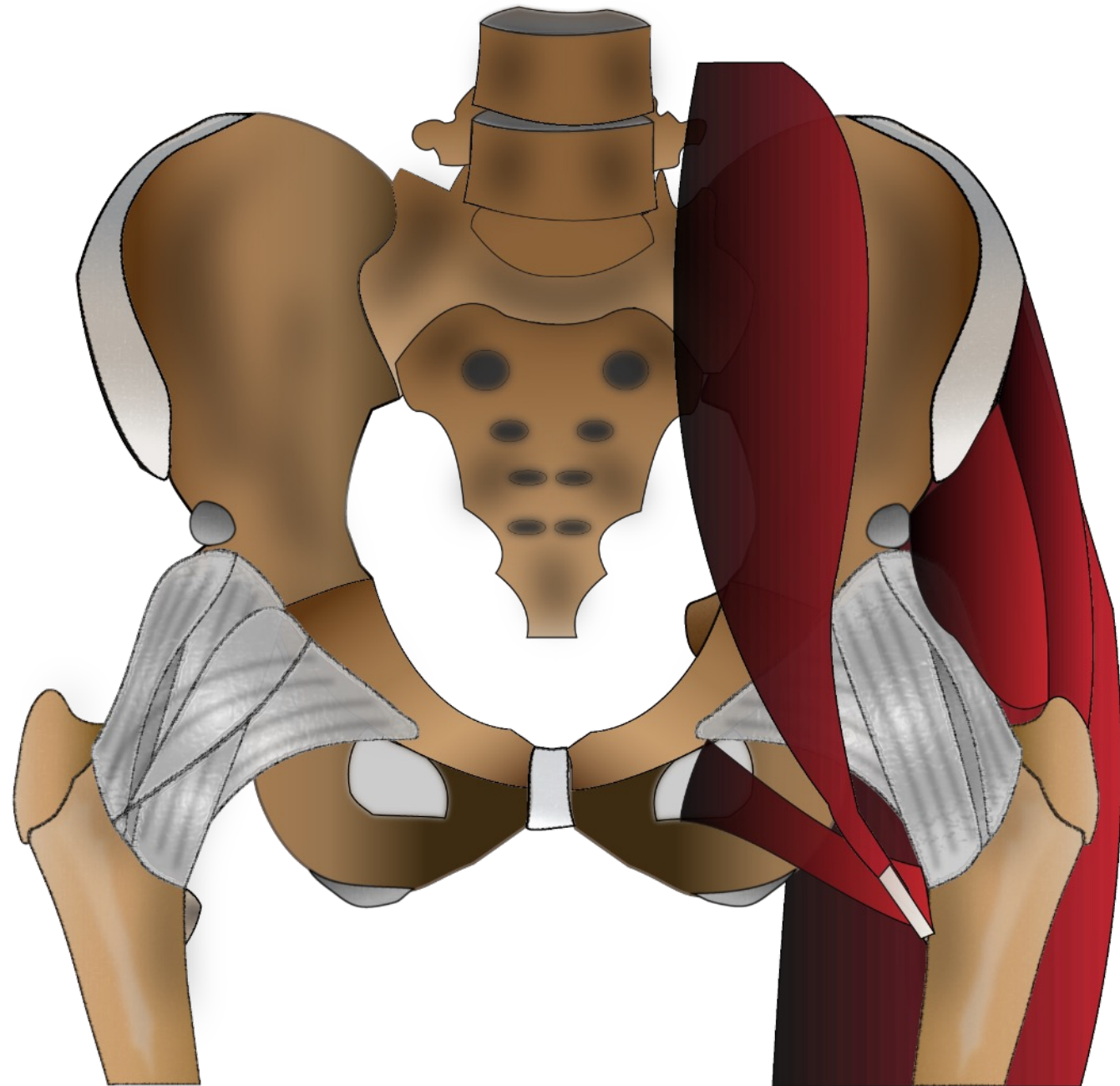
How Severe Is It?

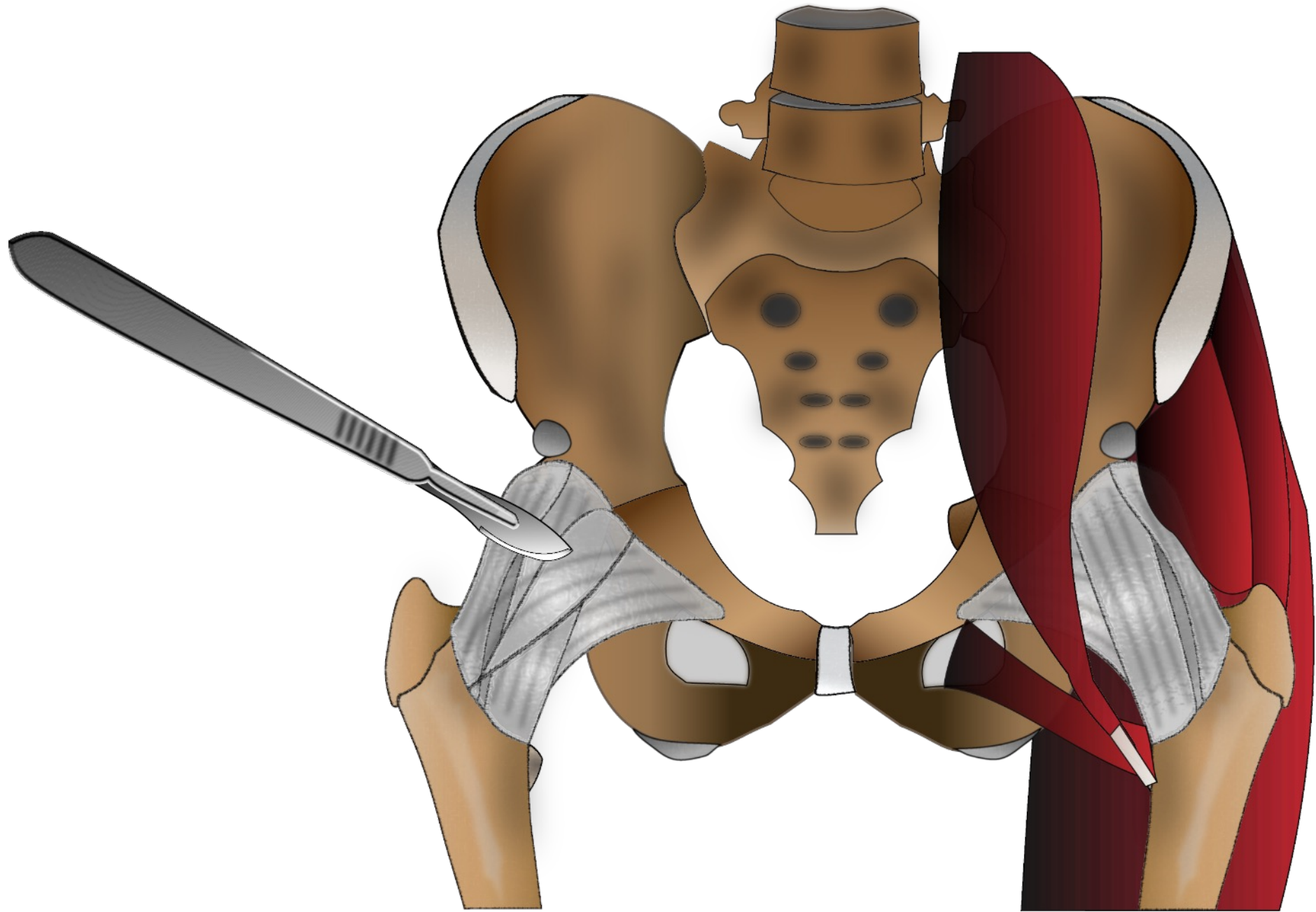
Treat It!

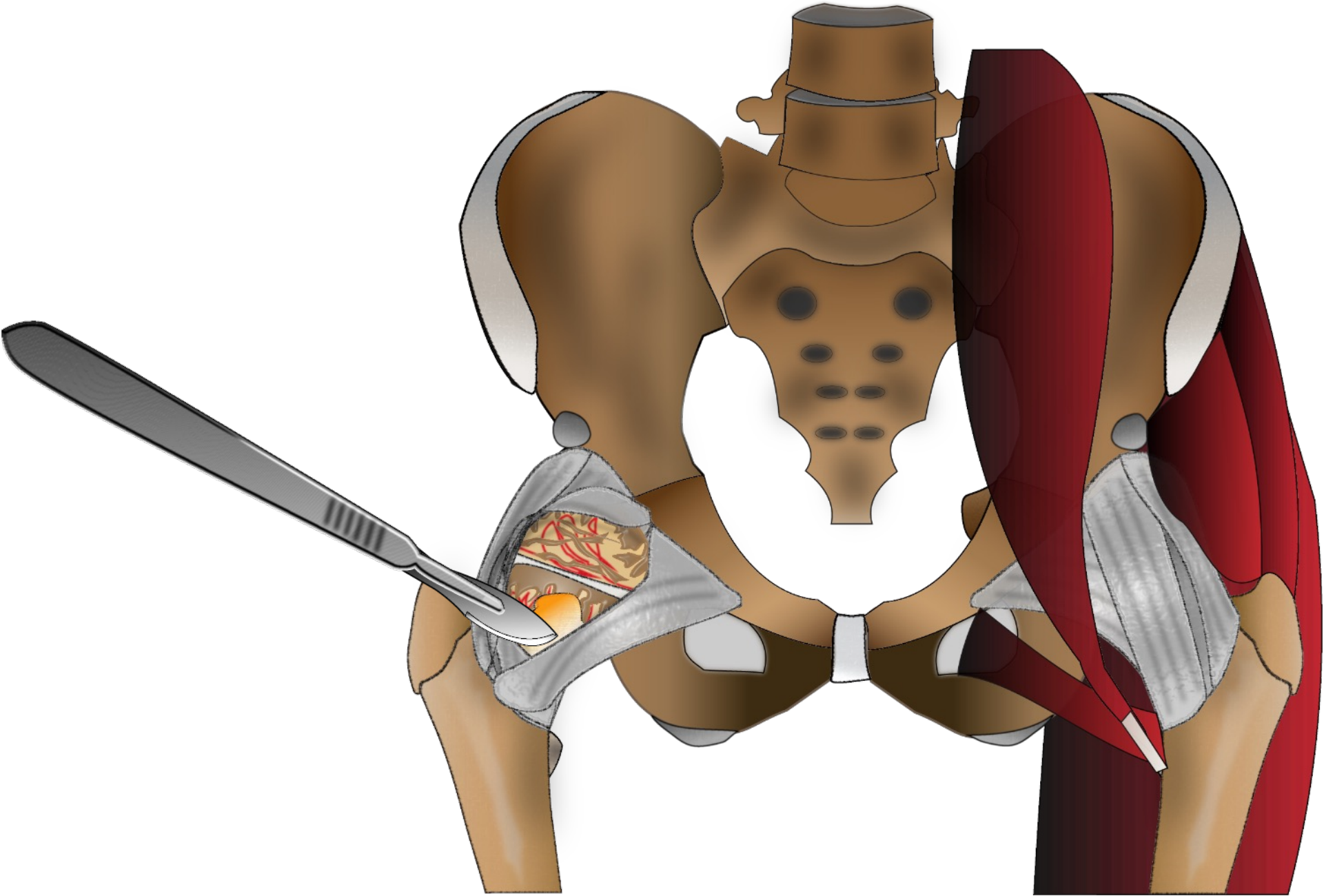
4 QUESTIONS

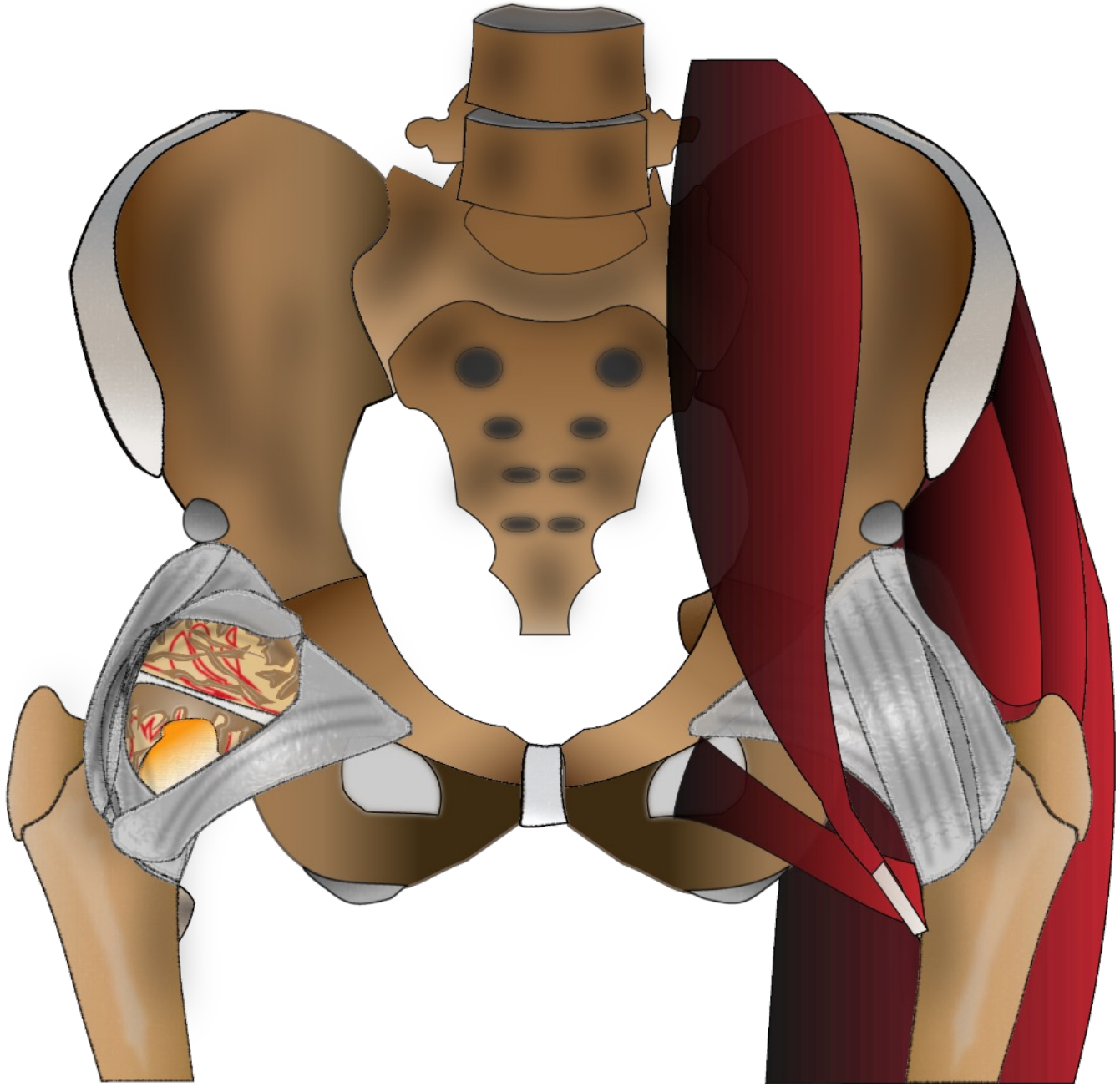
PHYSICAL EXAM

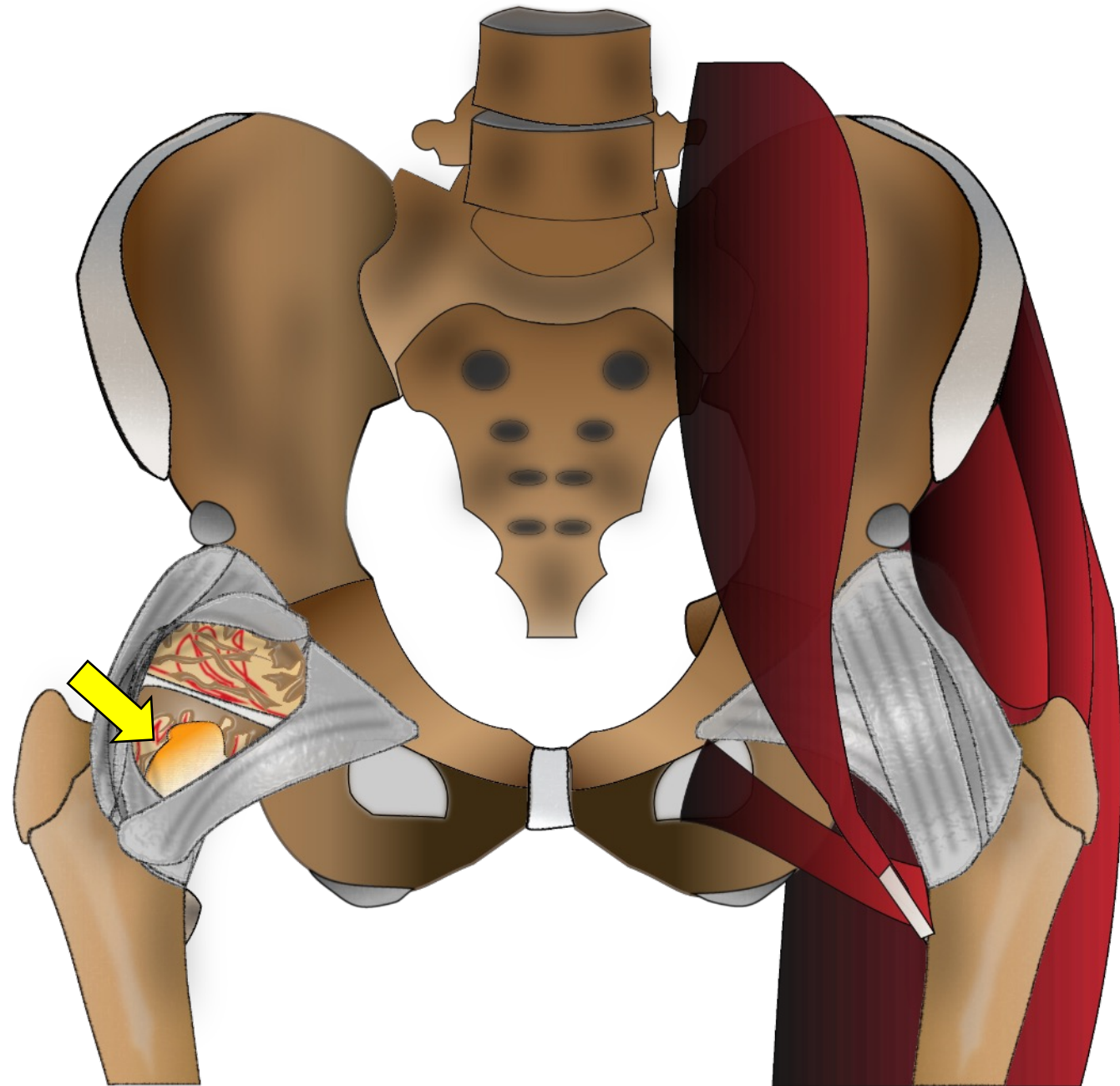


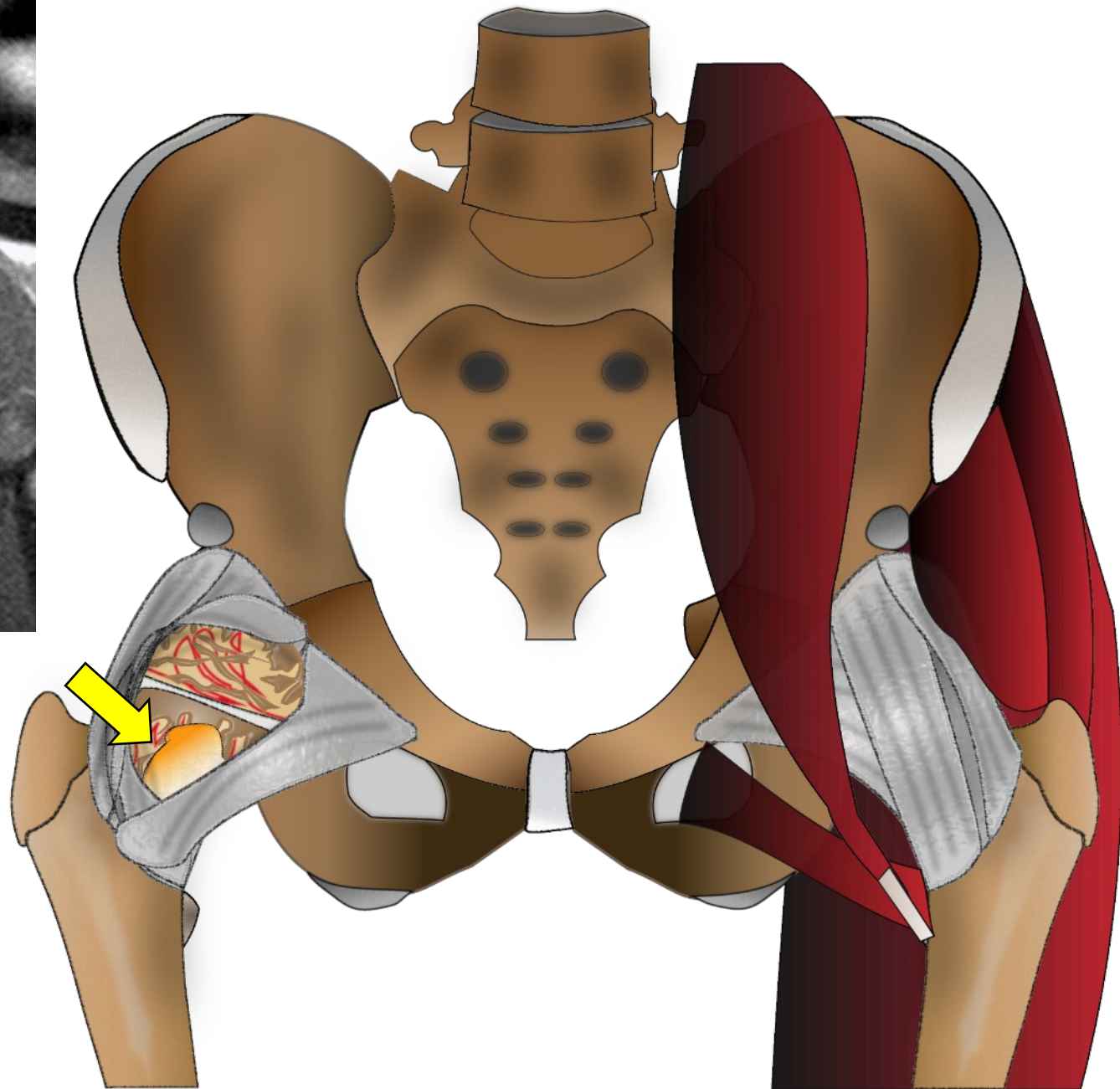
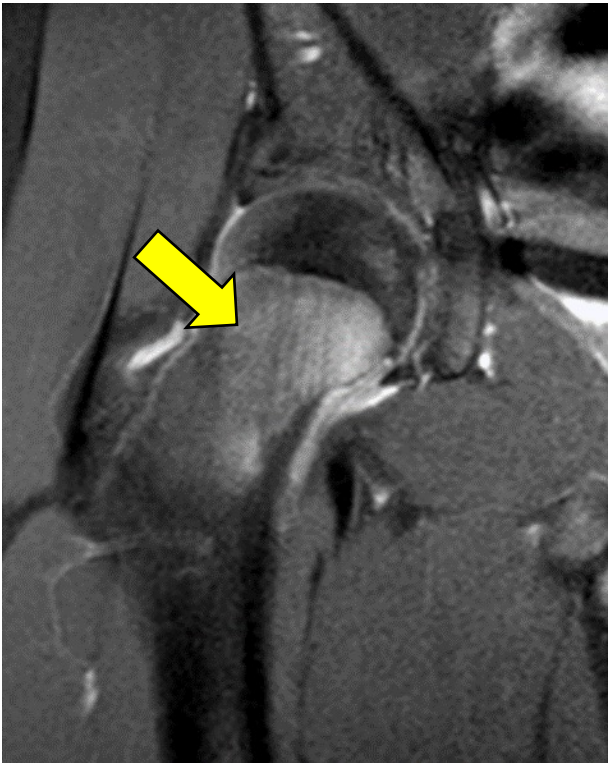


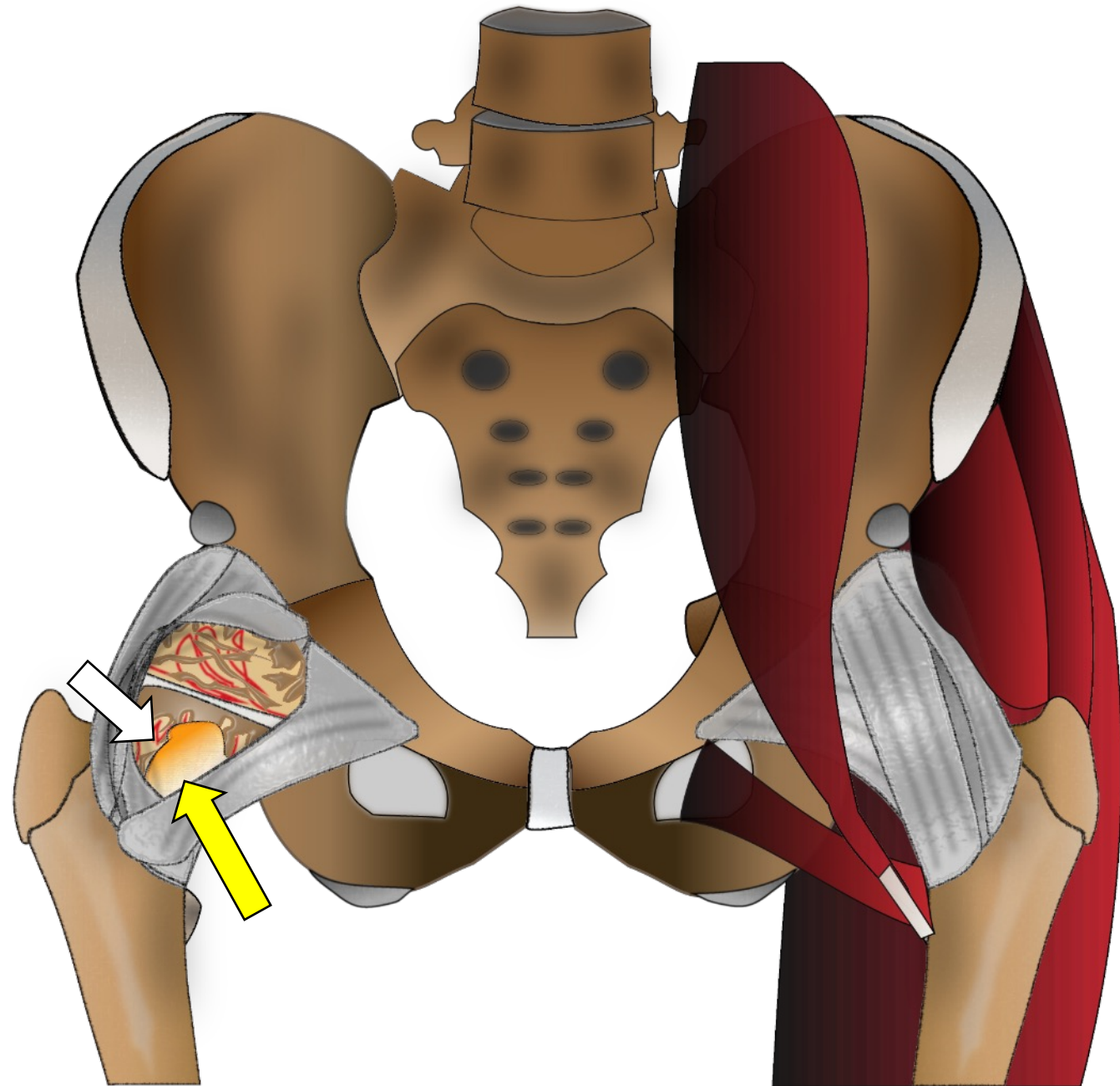


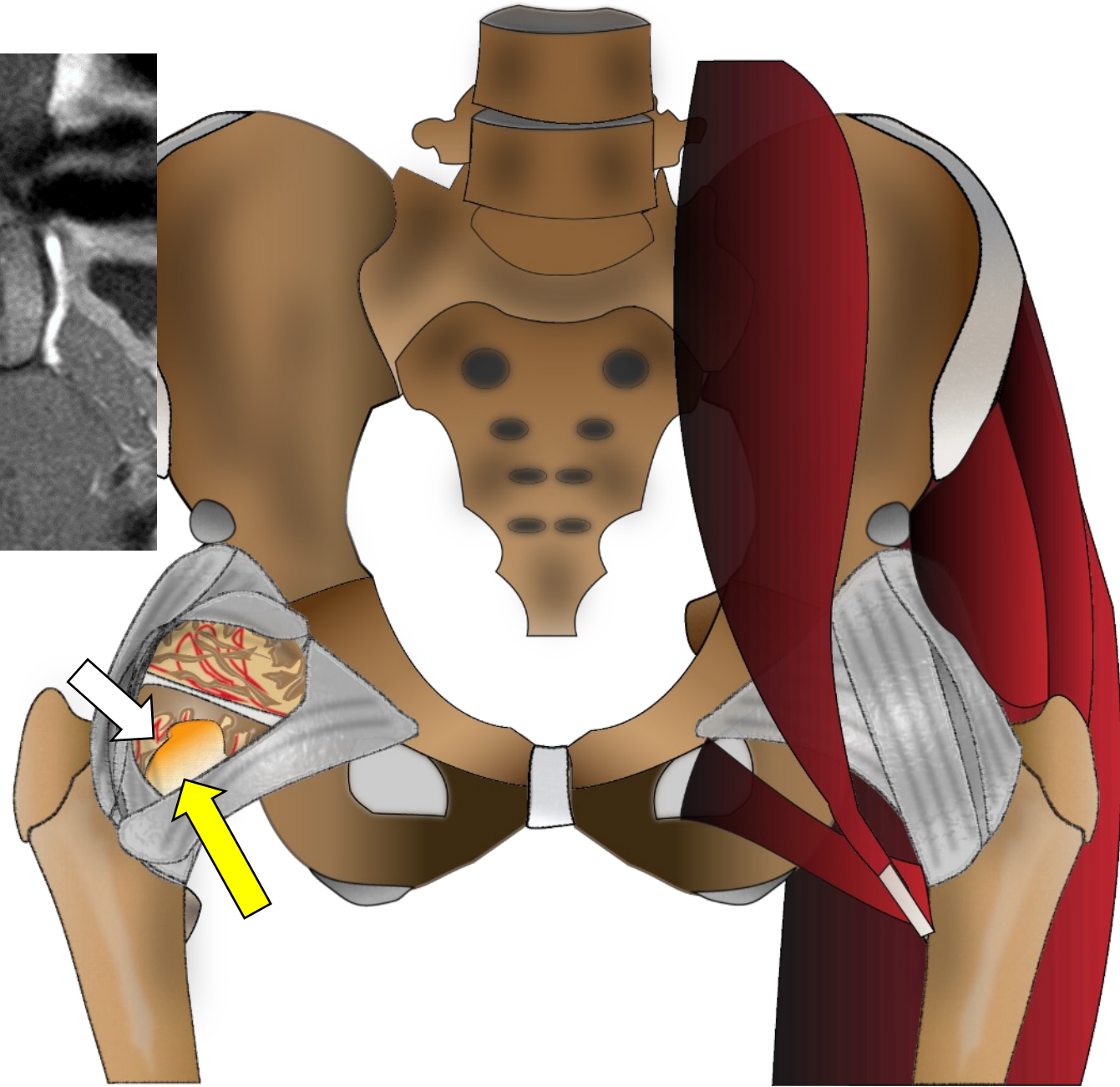
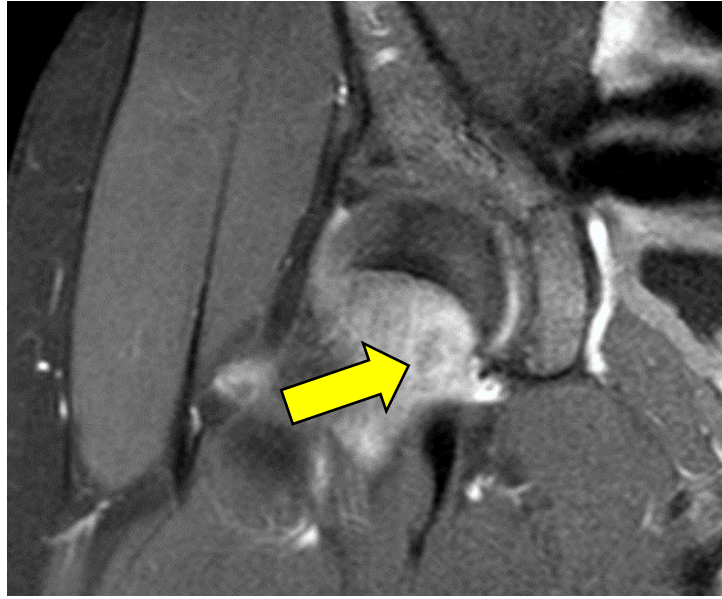


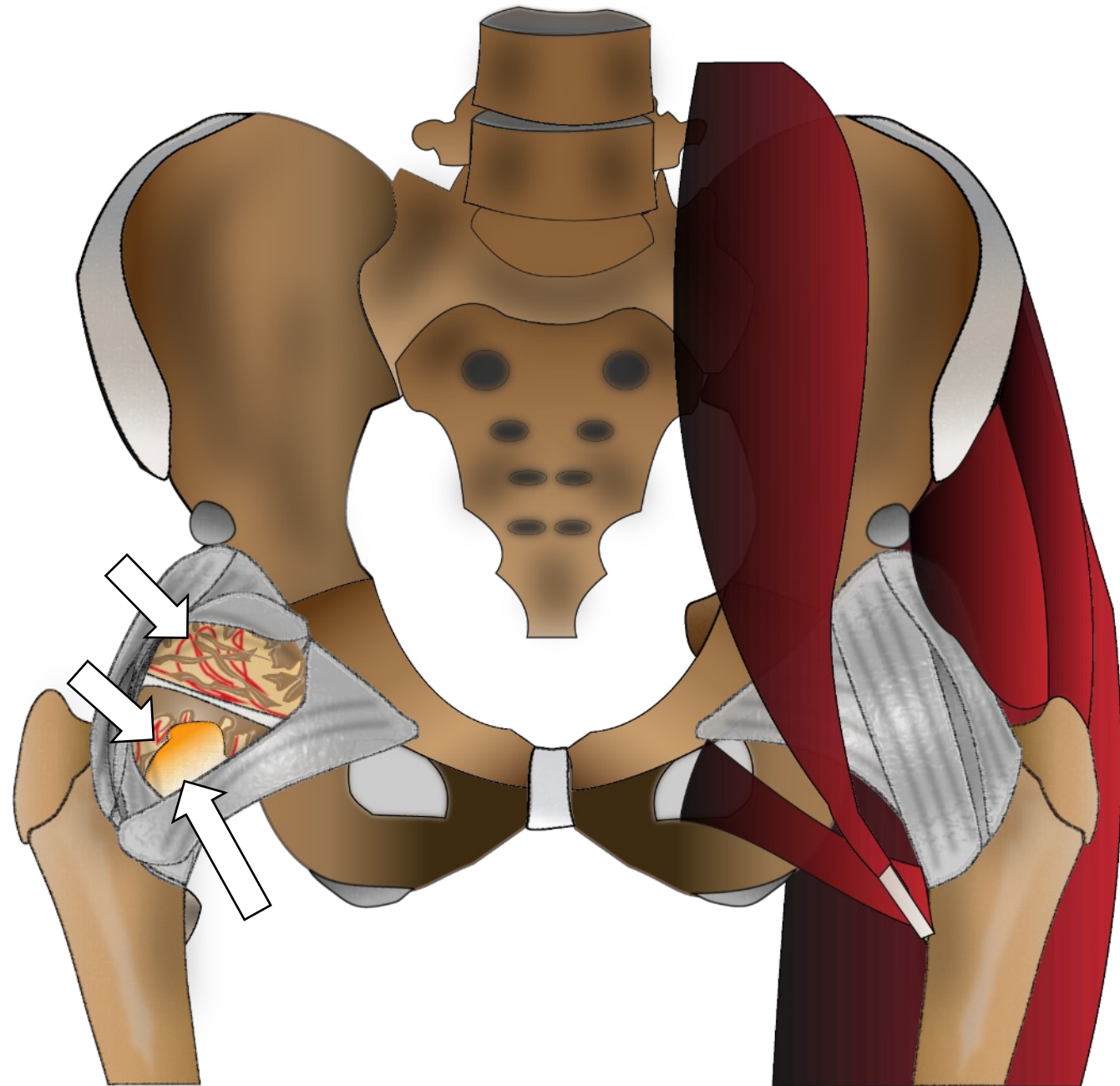


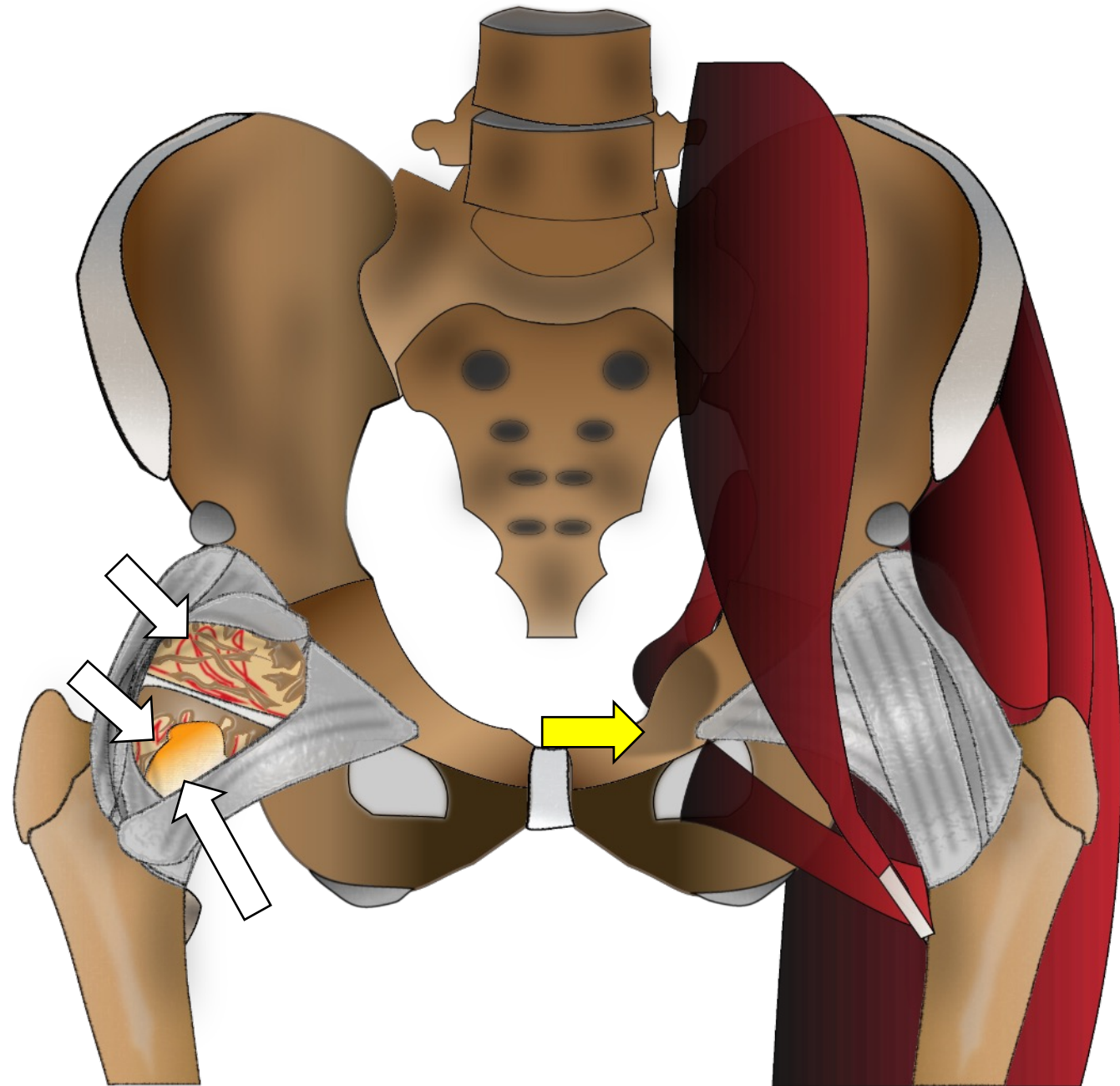


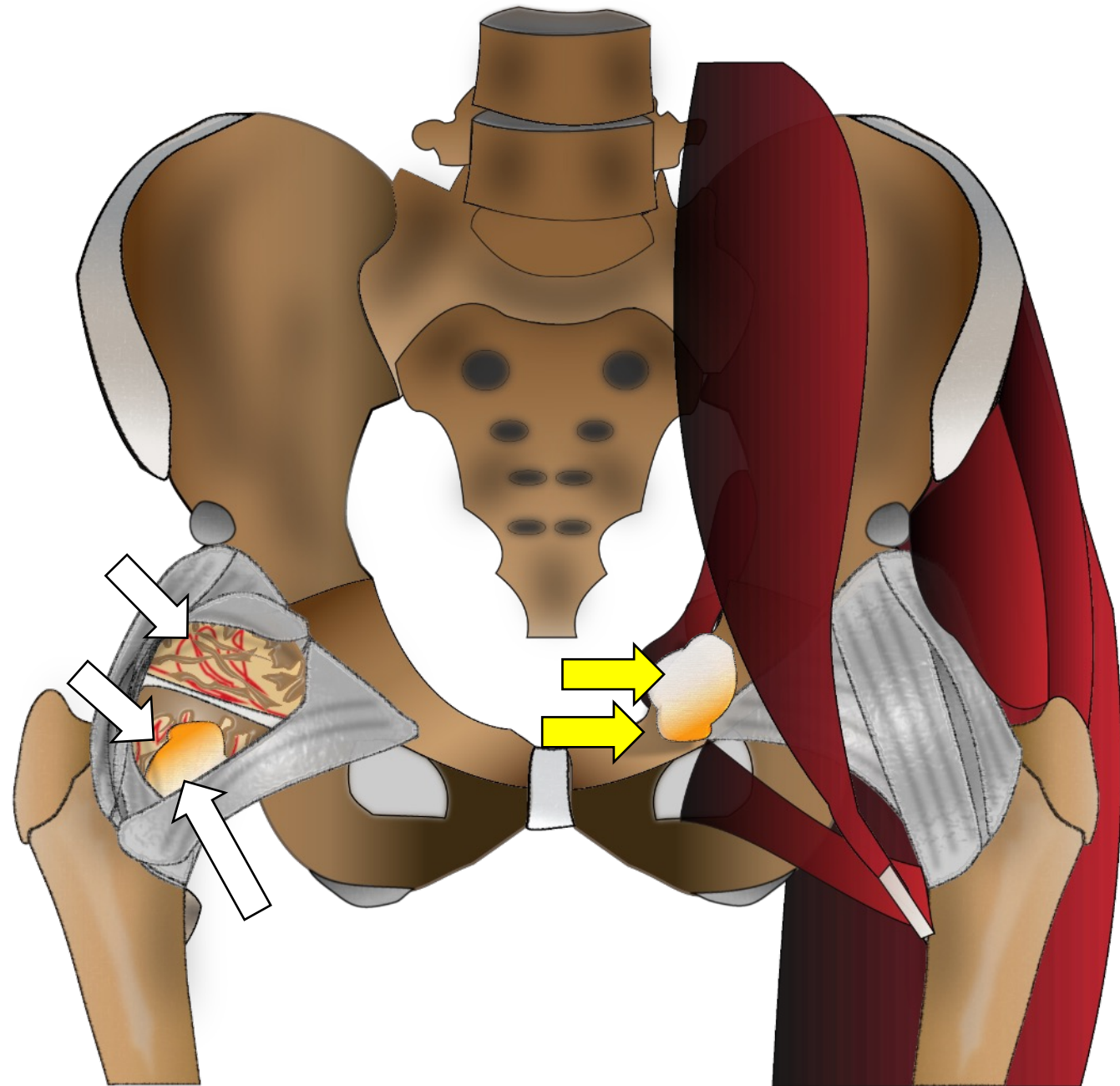


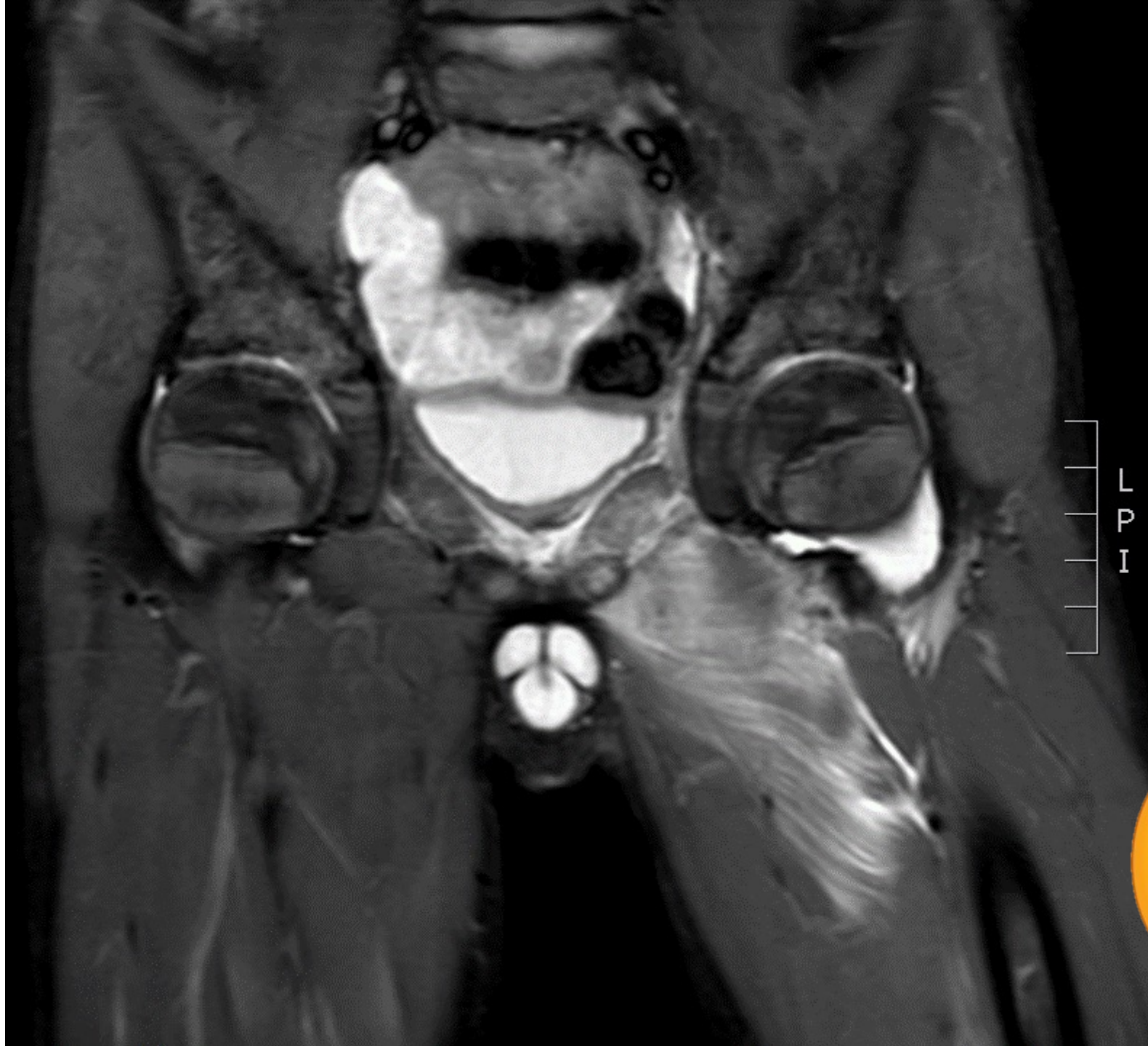


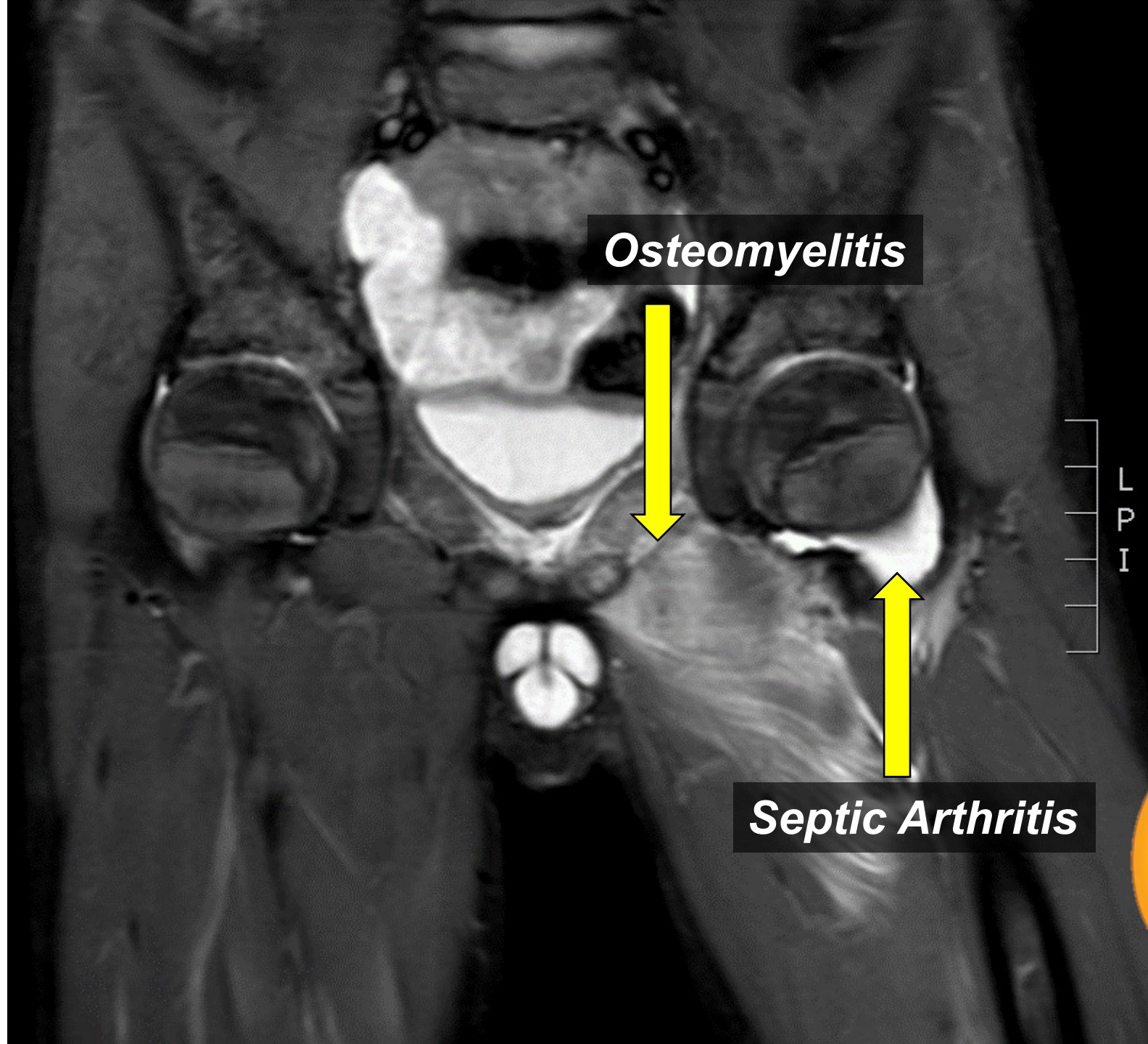








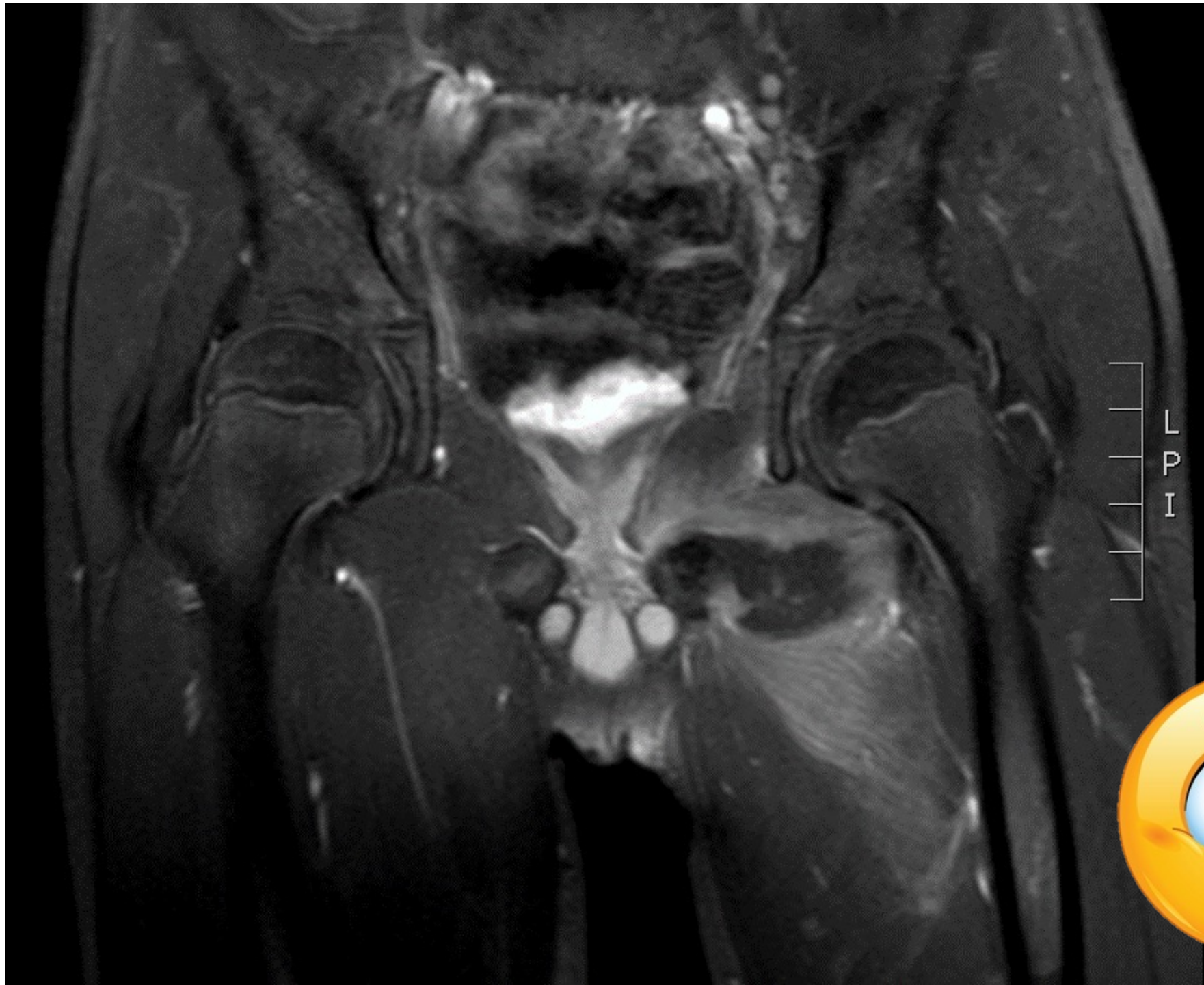


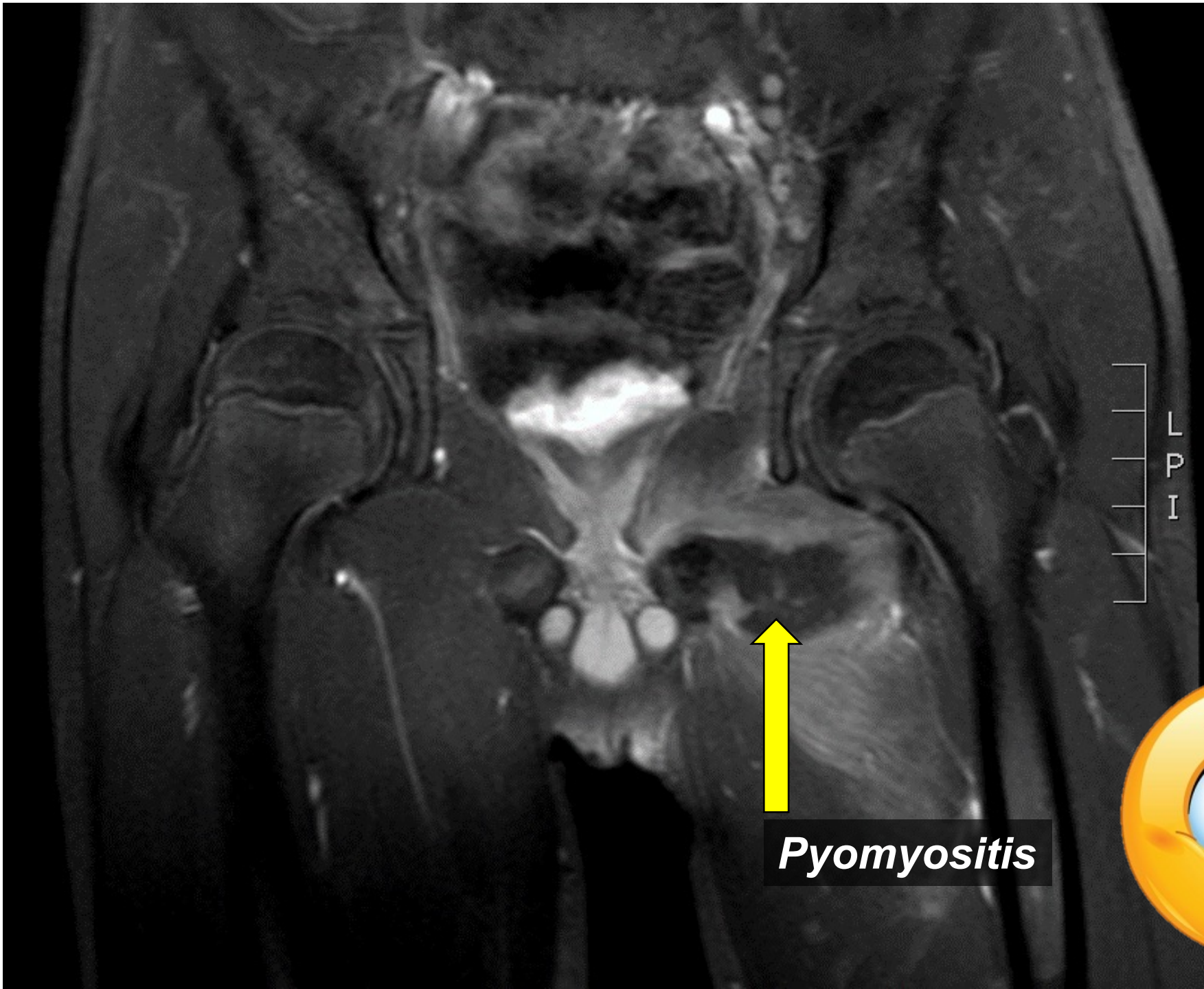


Osteomyelitis

Septic Arthritis

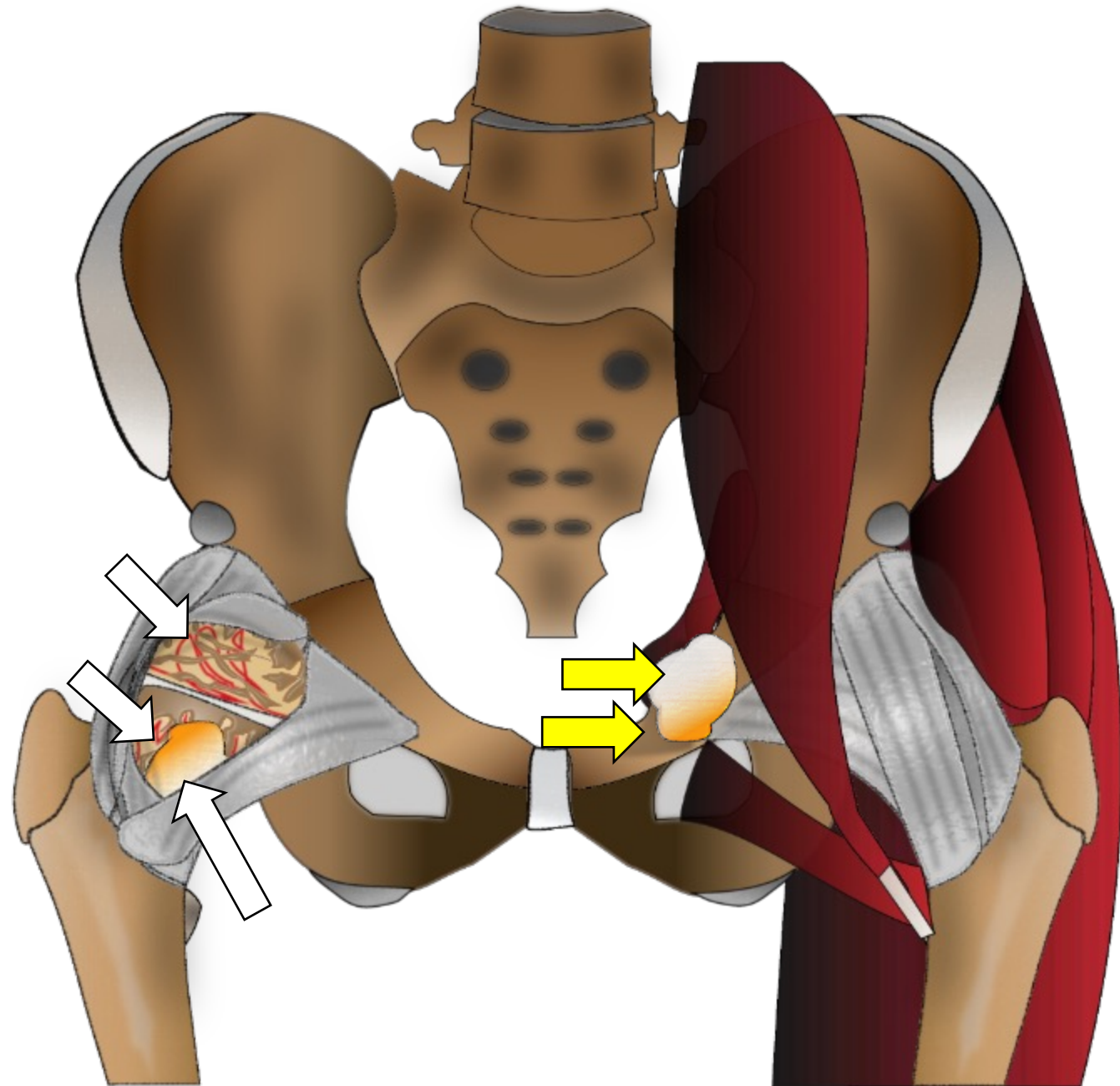


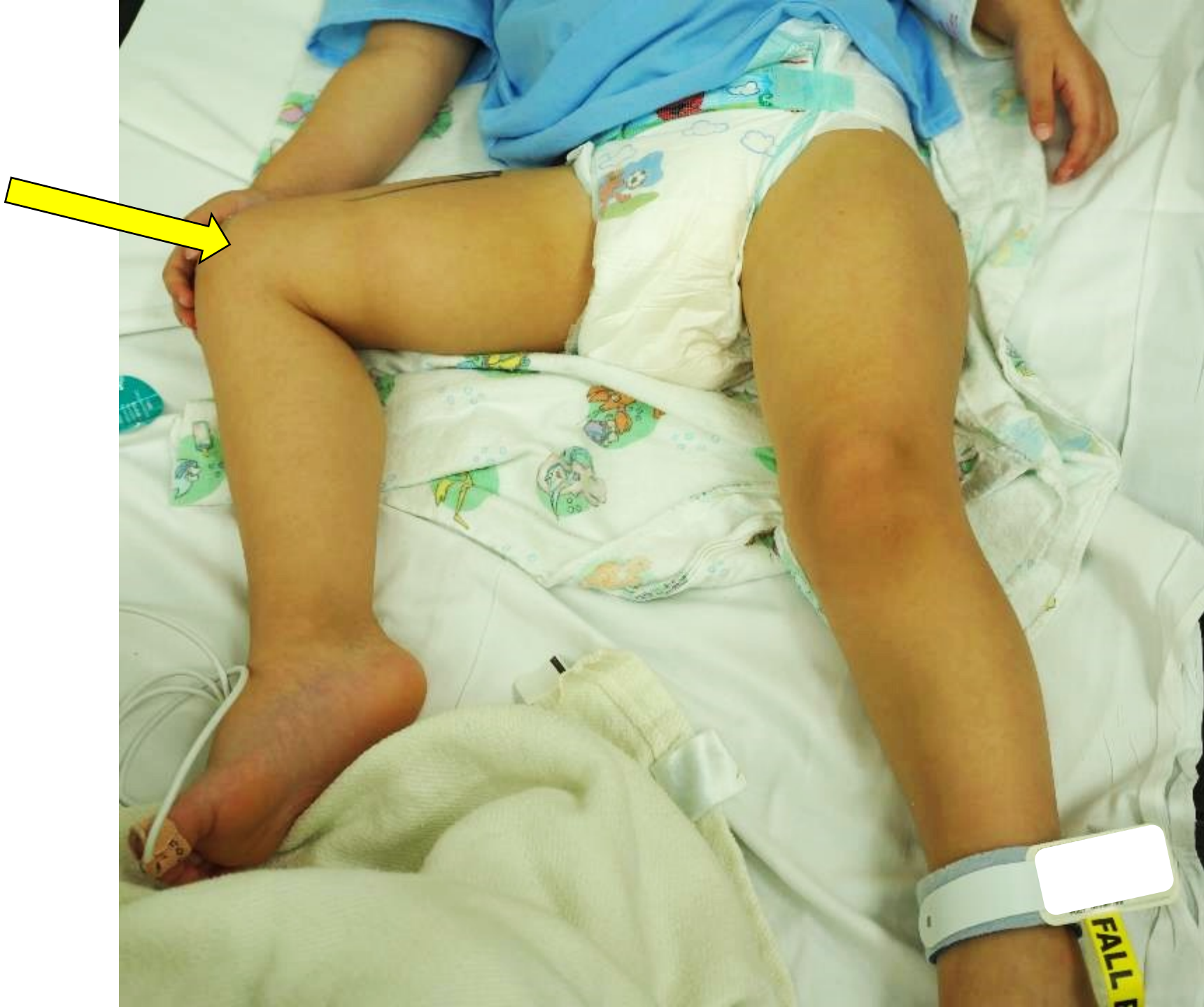

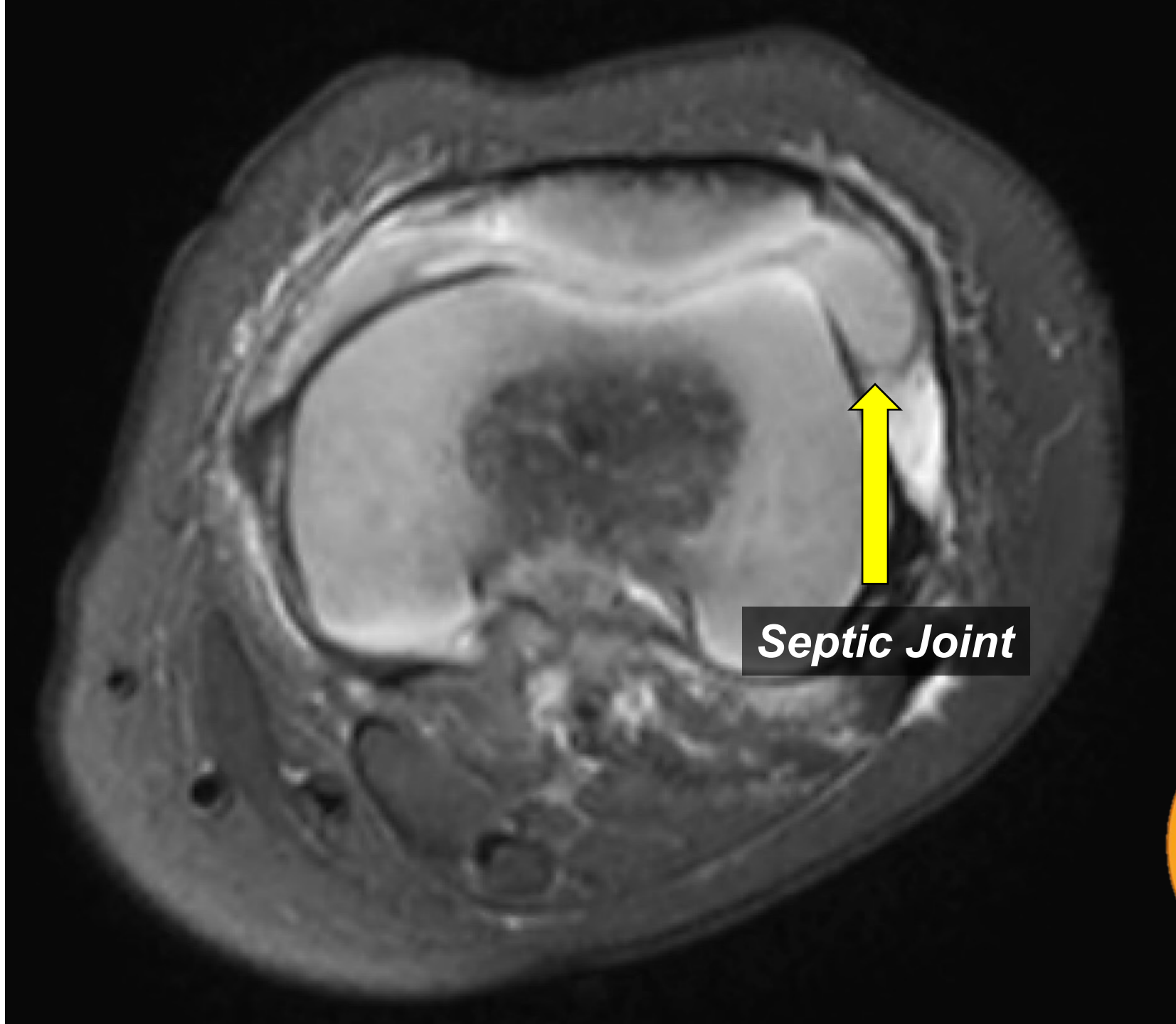


Pyomyositis



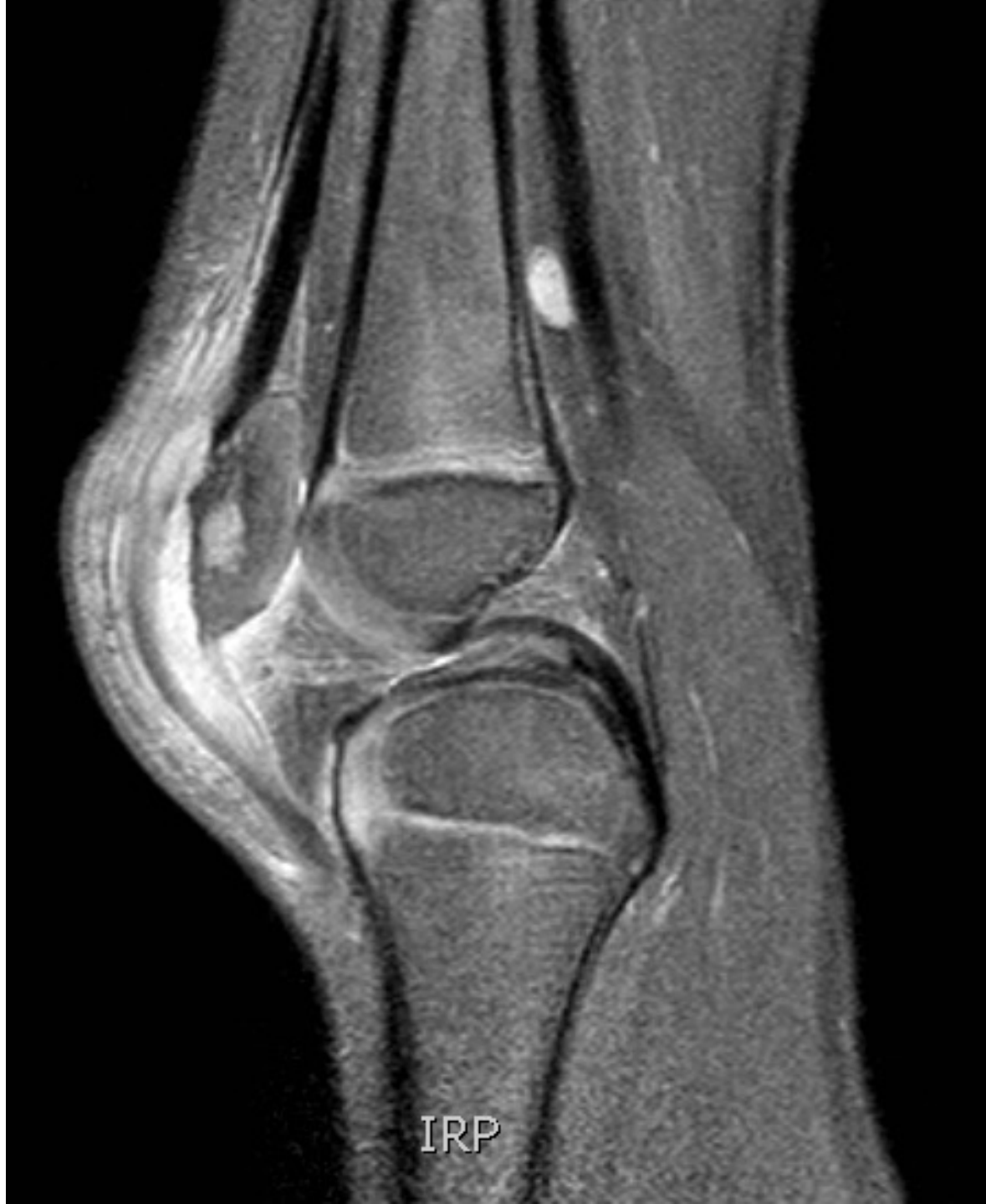





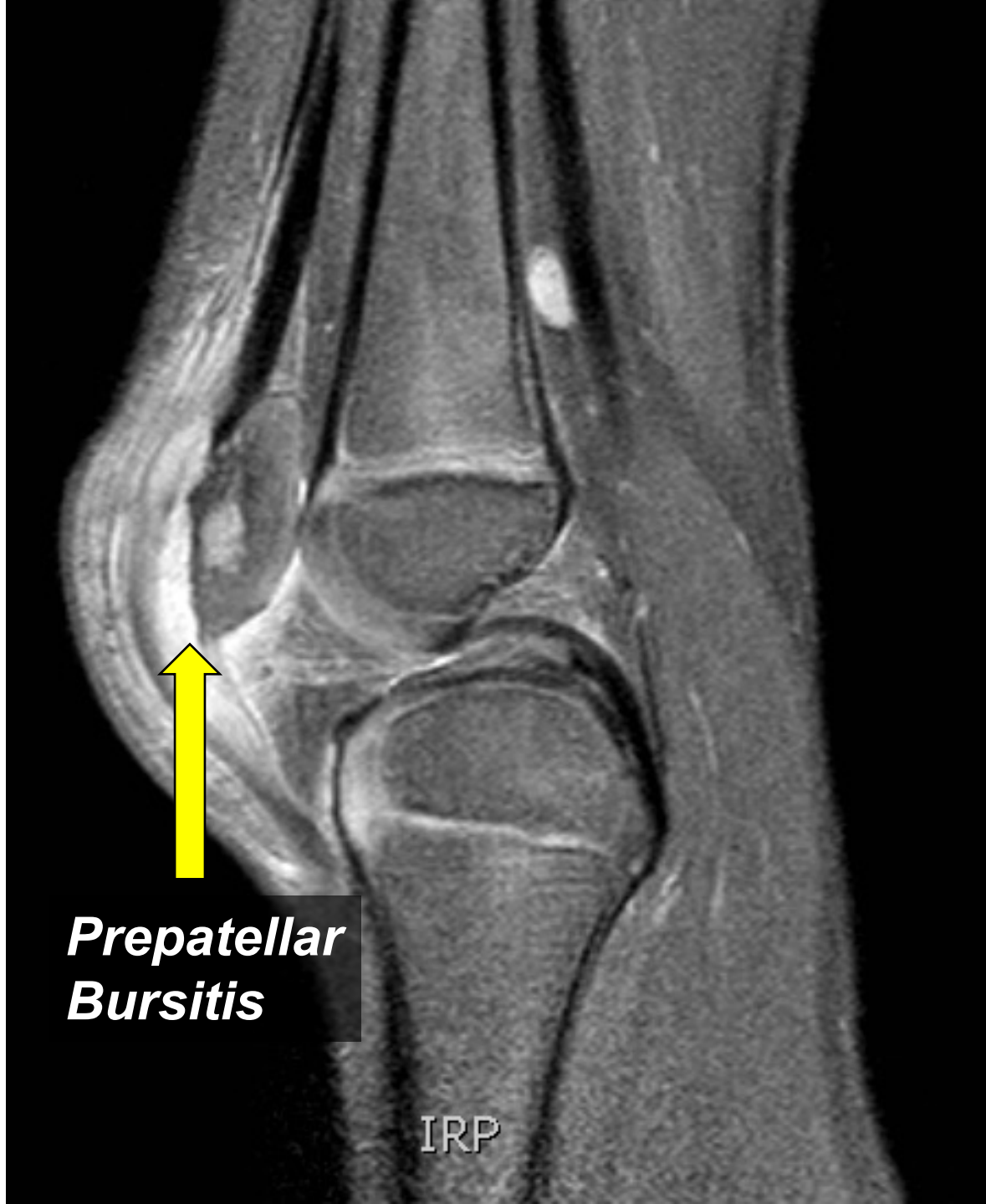
Septic Joint





IRP

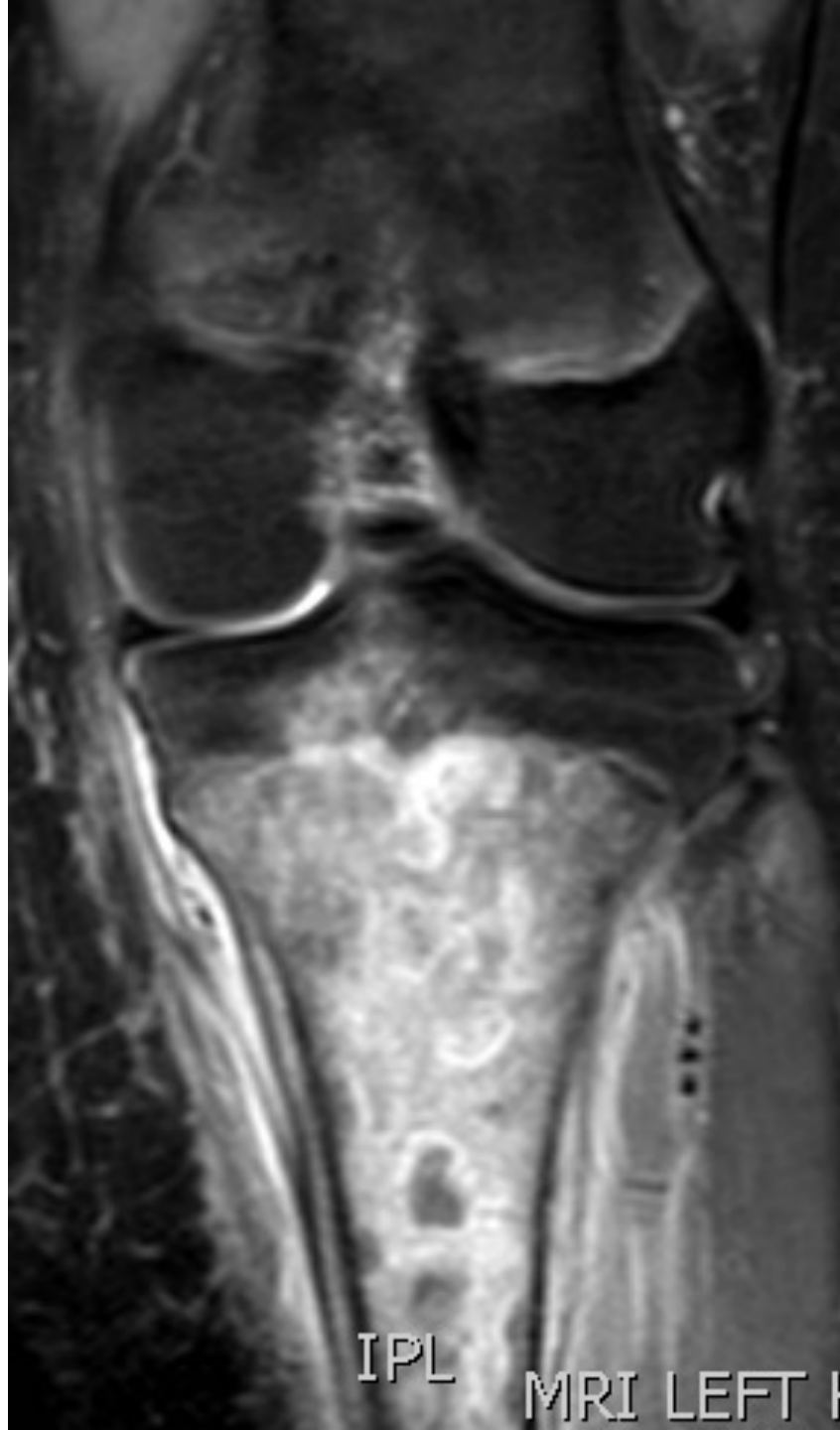


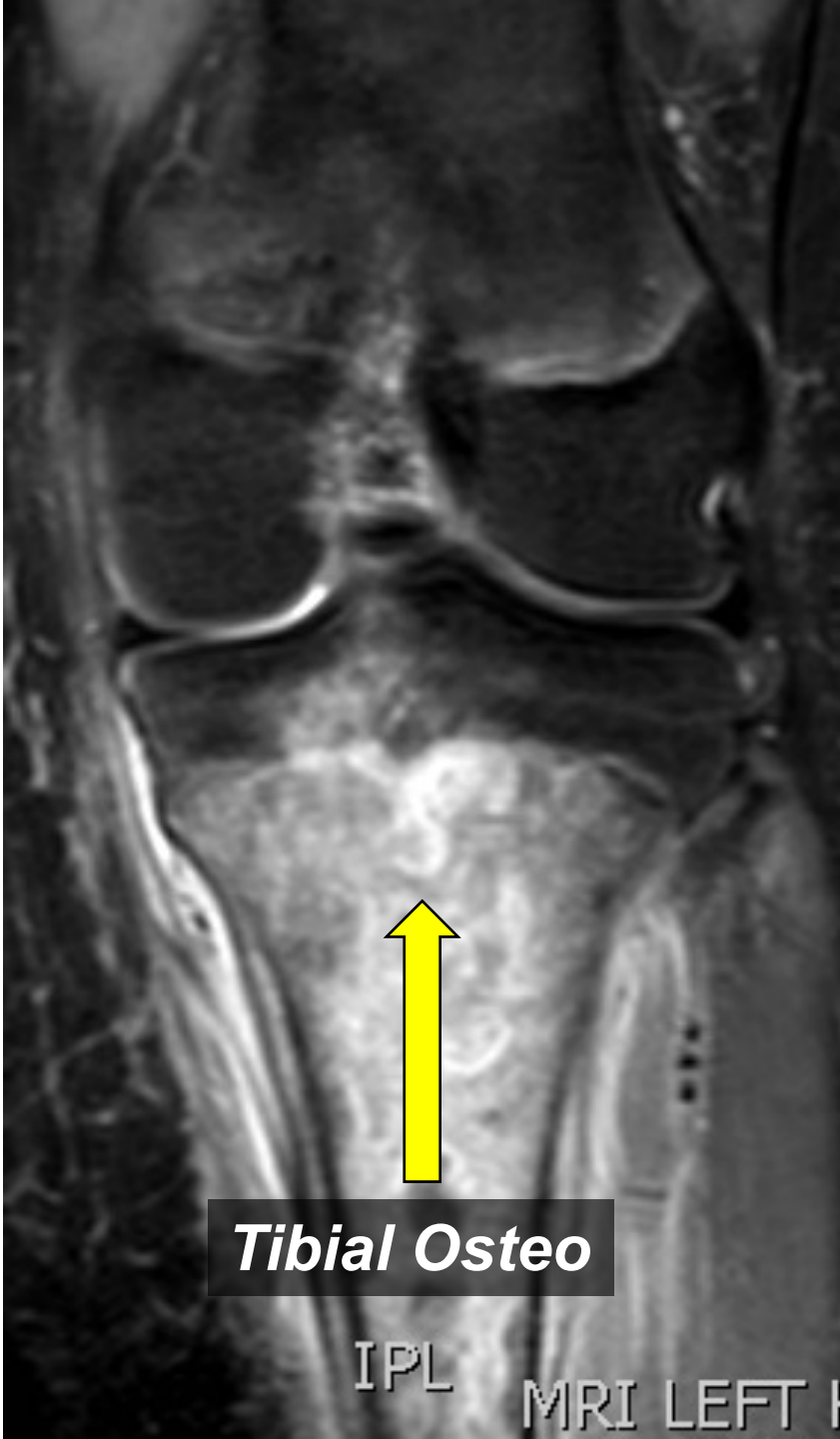
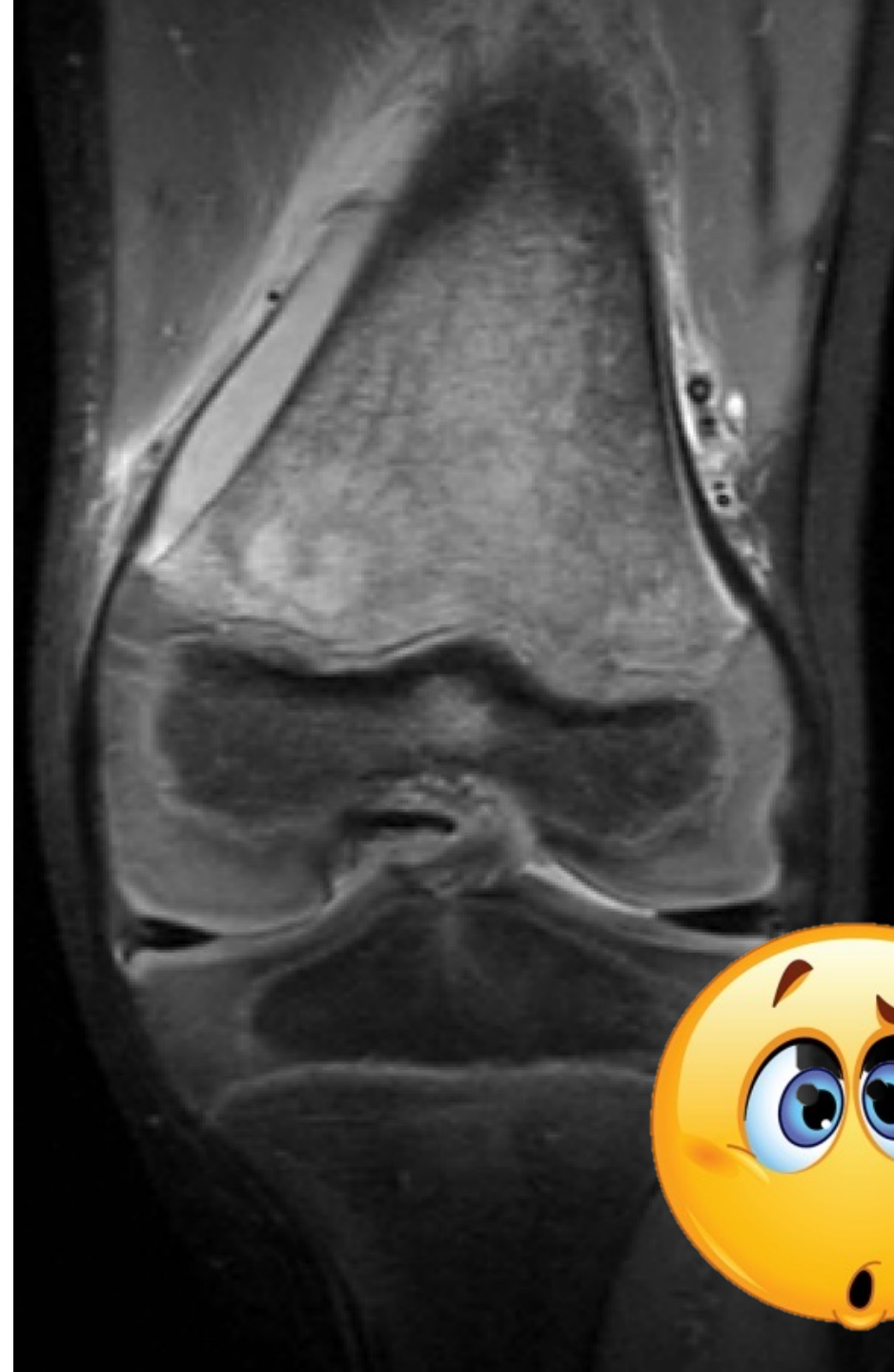**Prepatellar
Bursitis**

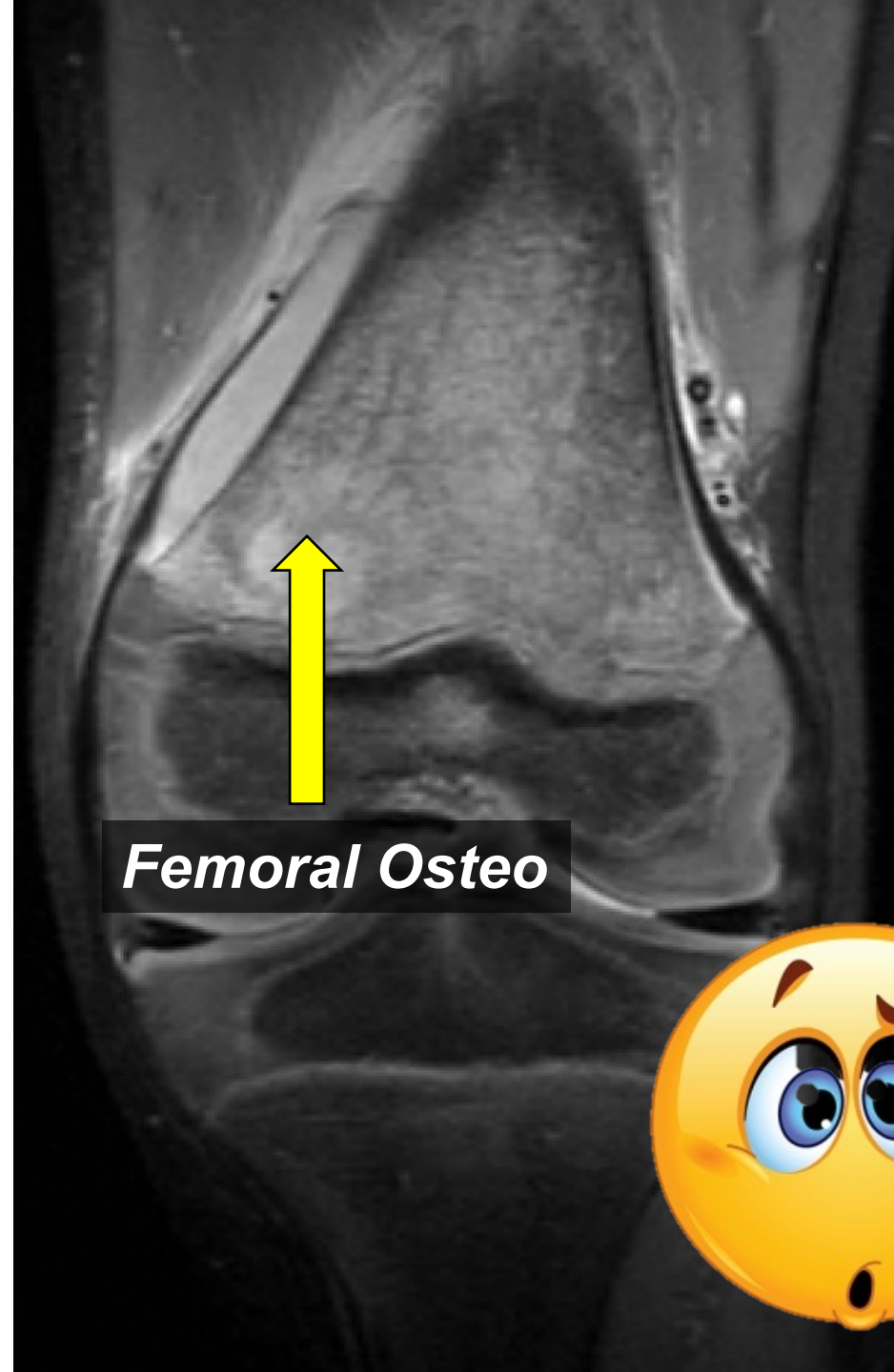
IRP

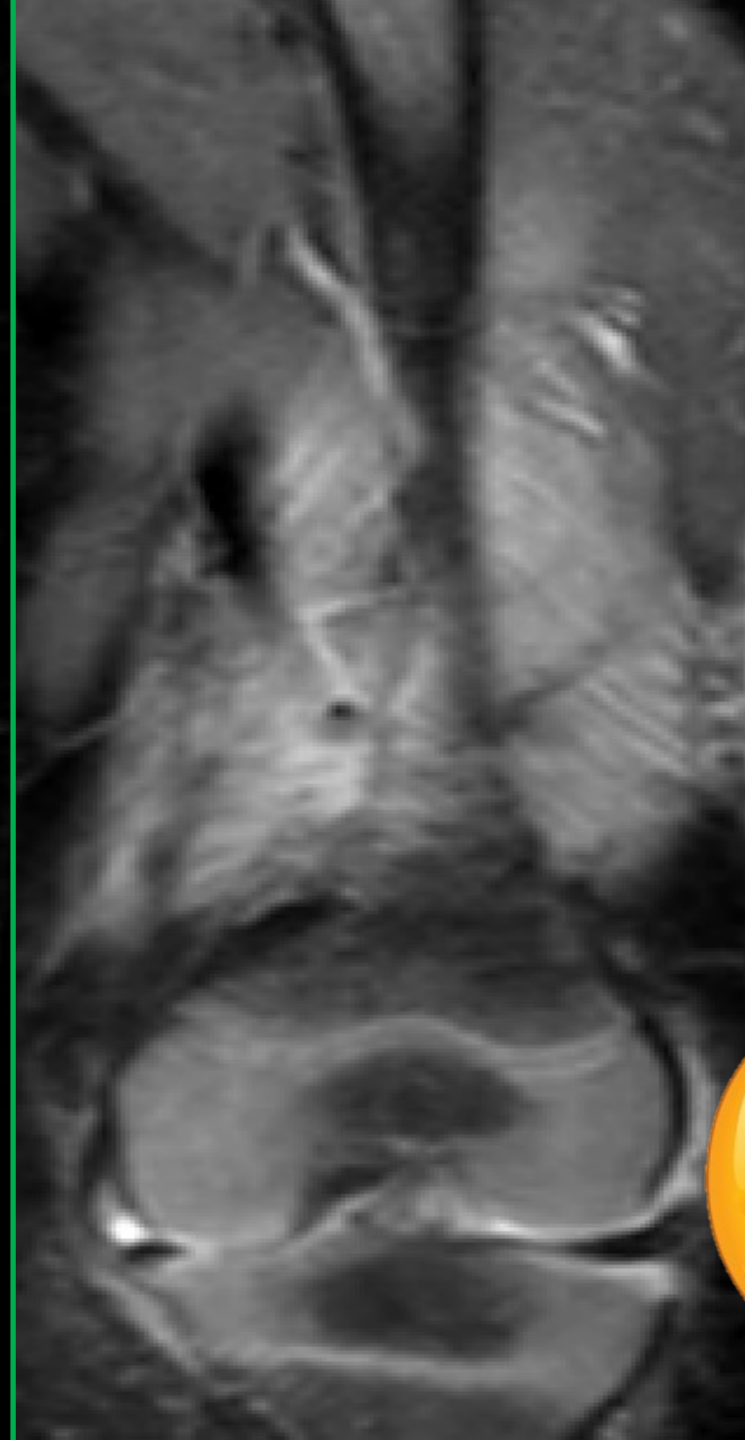
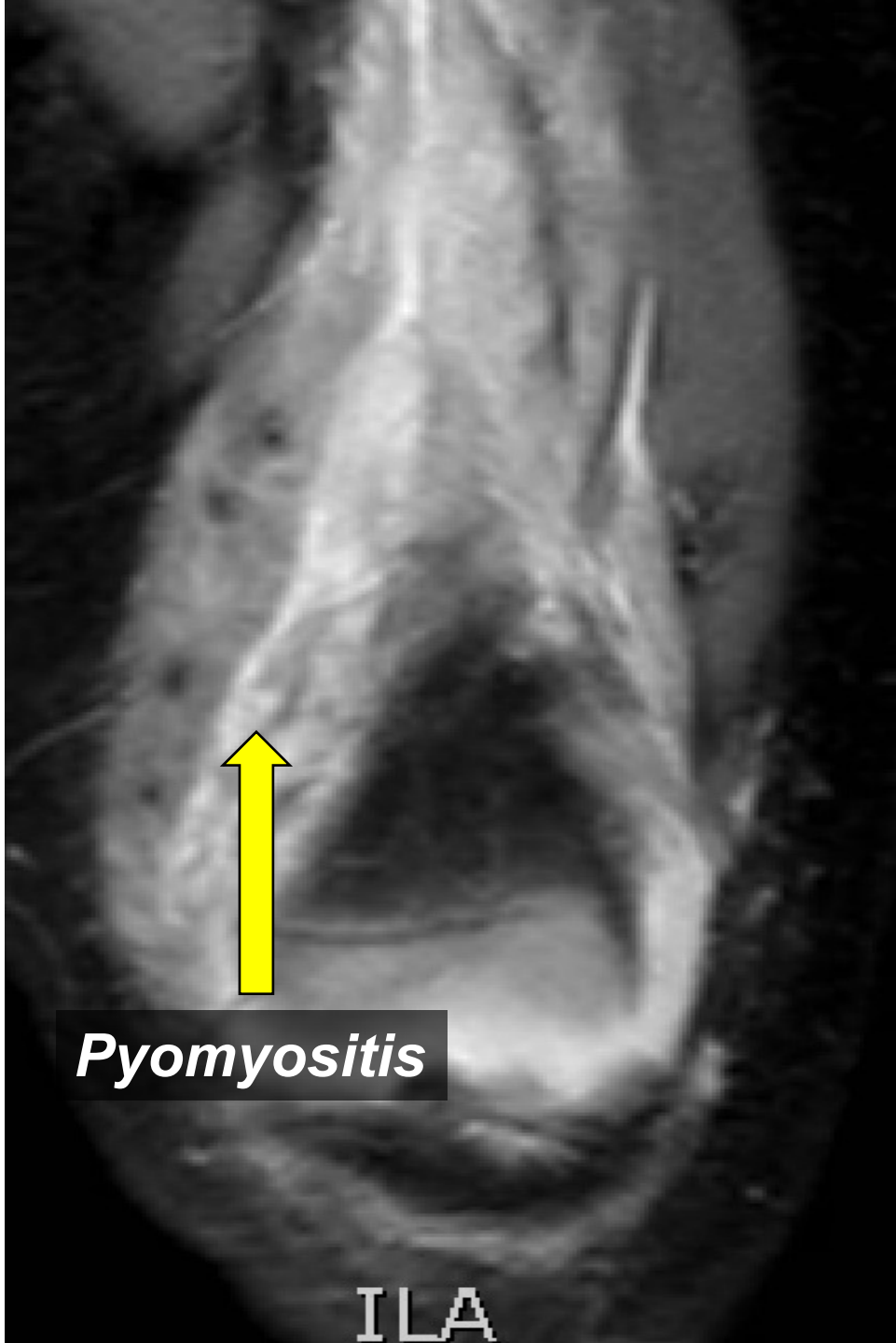












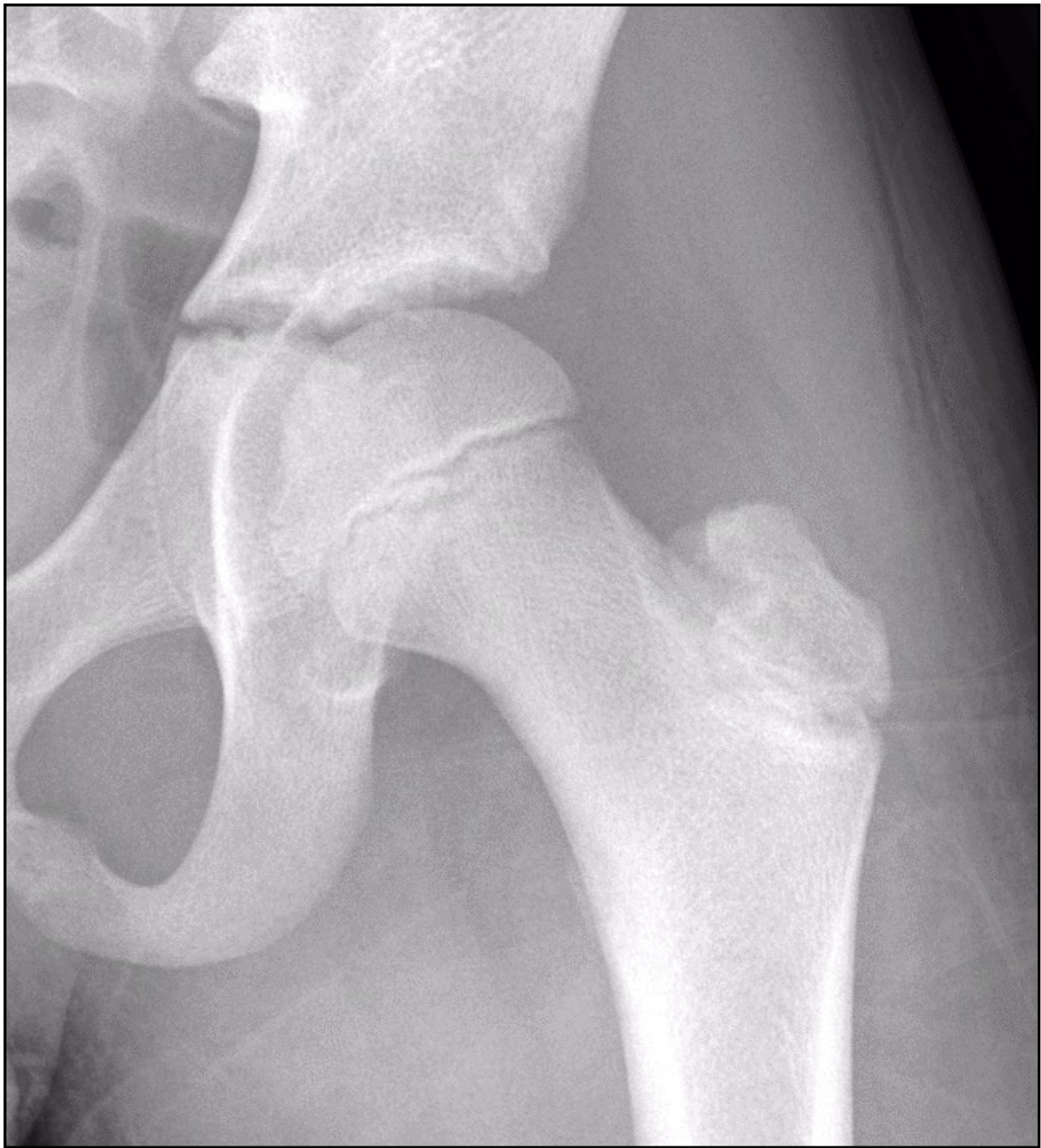
PHYSICAL EXAM

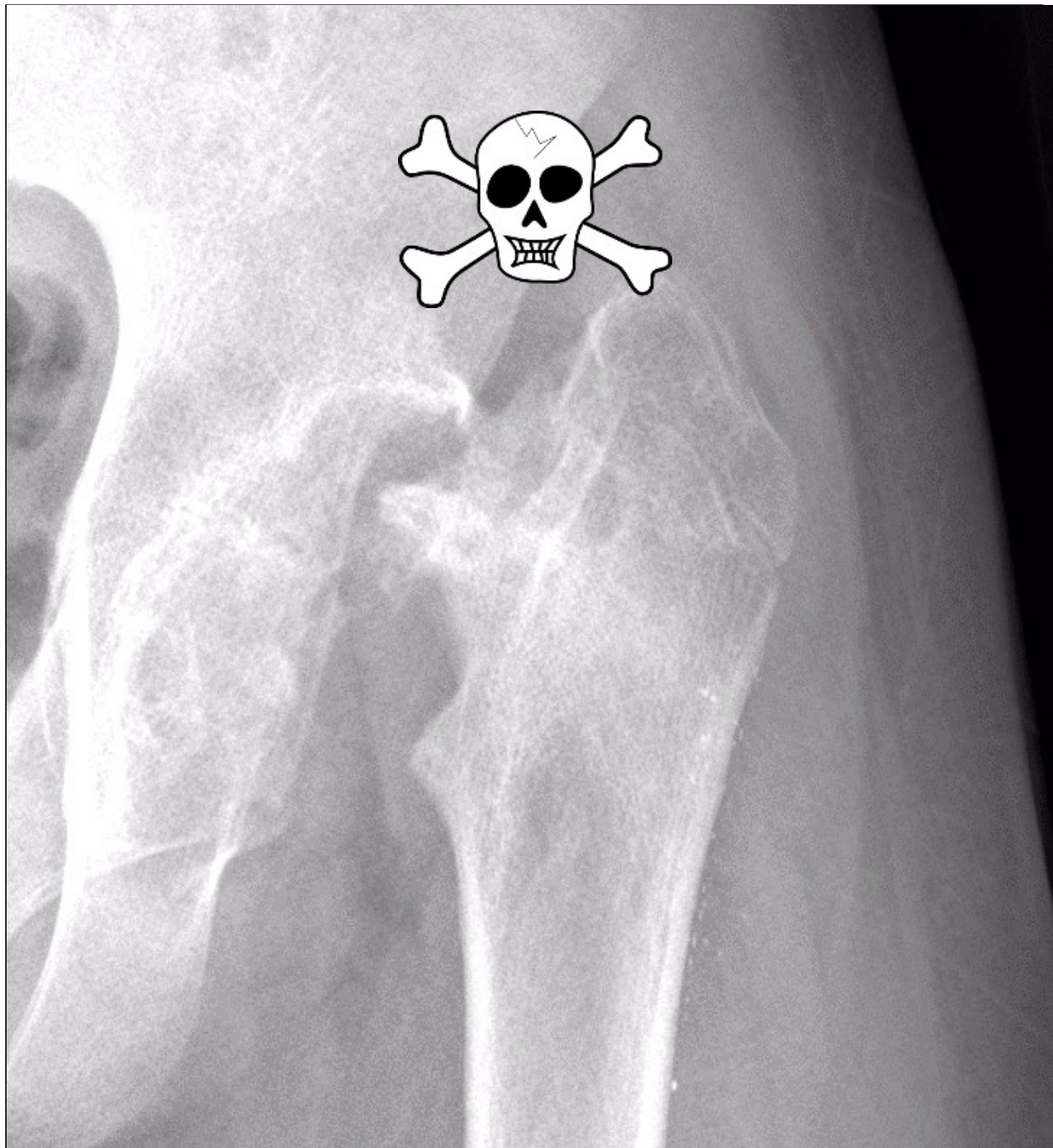
PHYSICAL

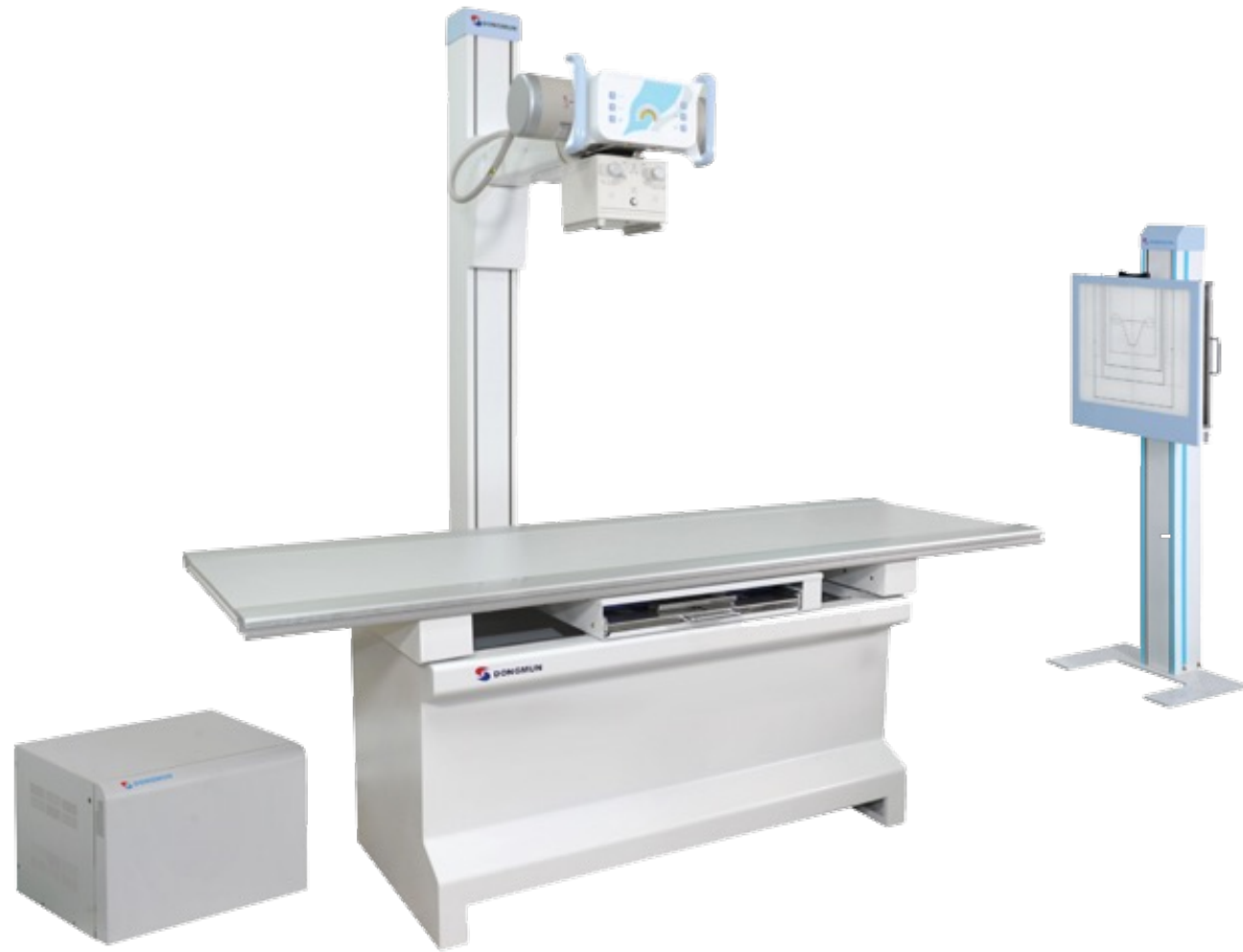EXAM

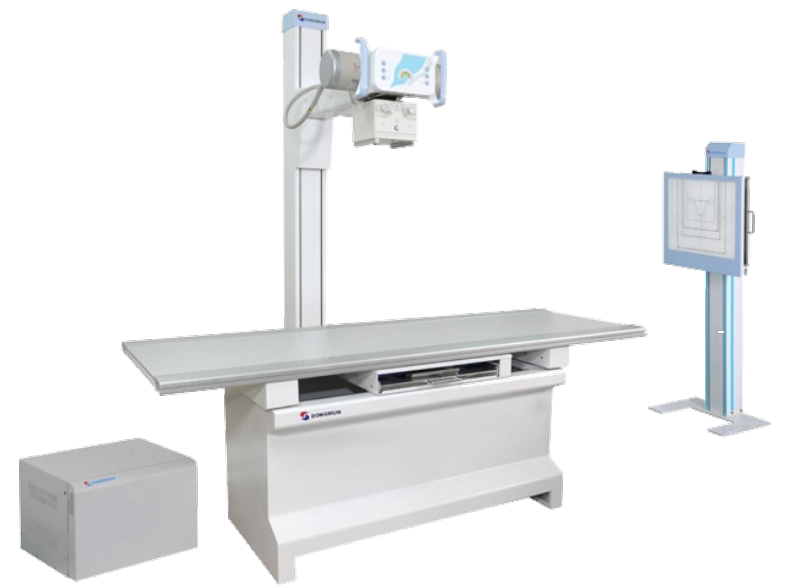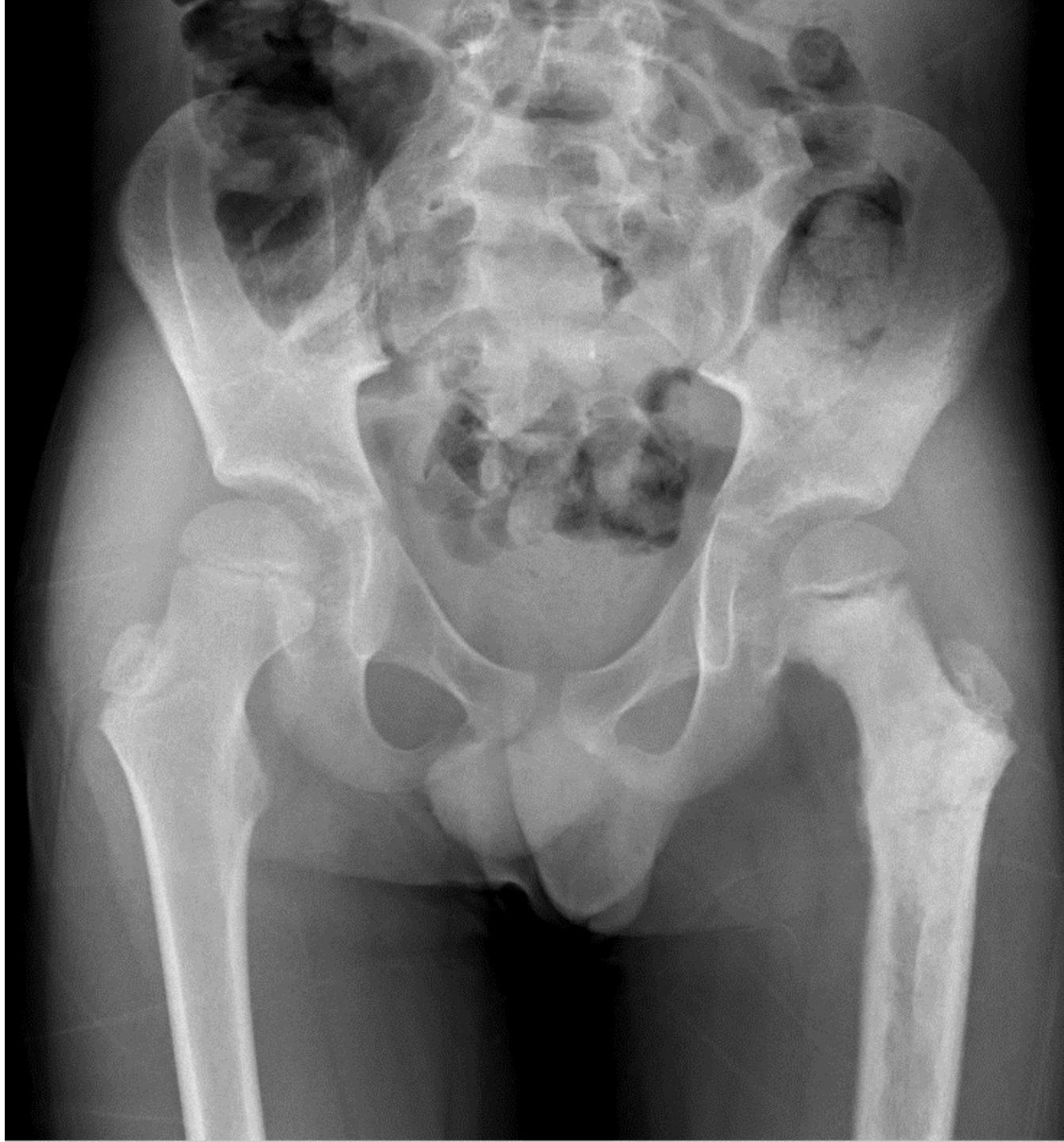+ IMAGING

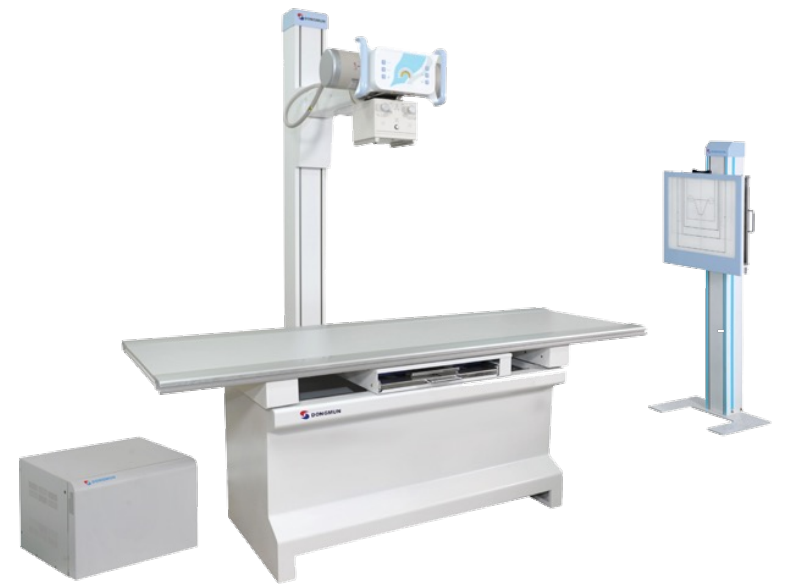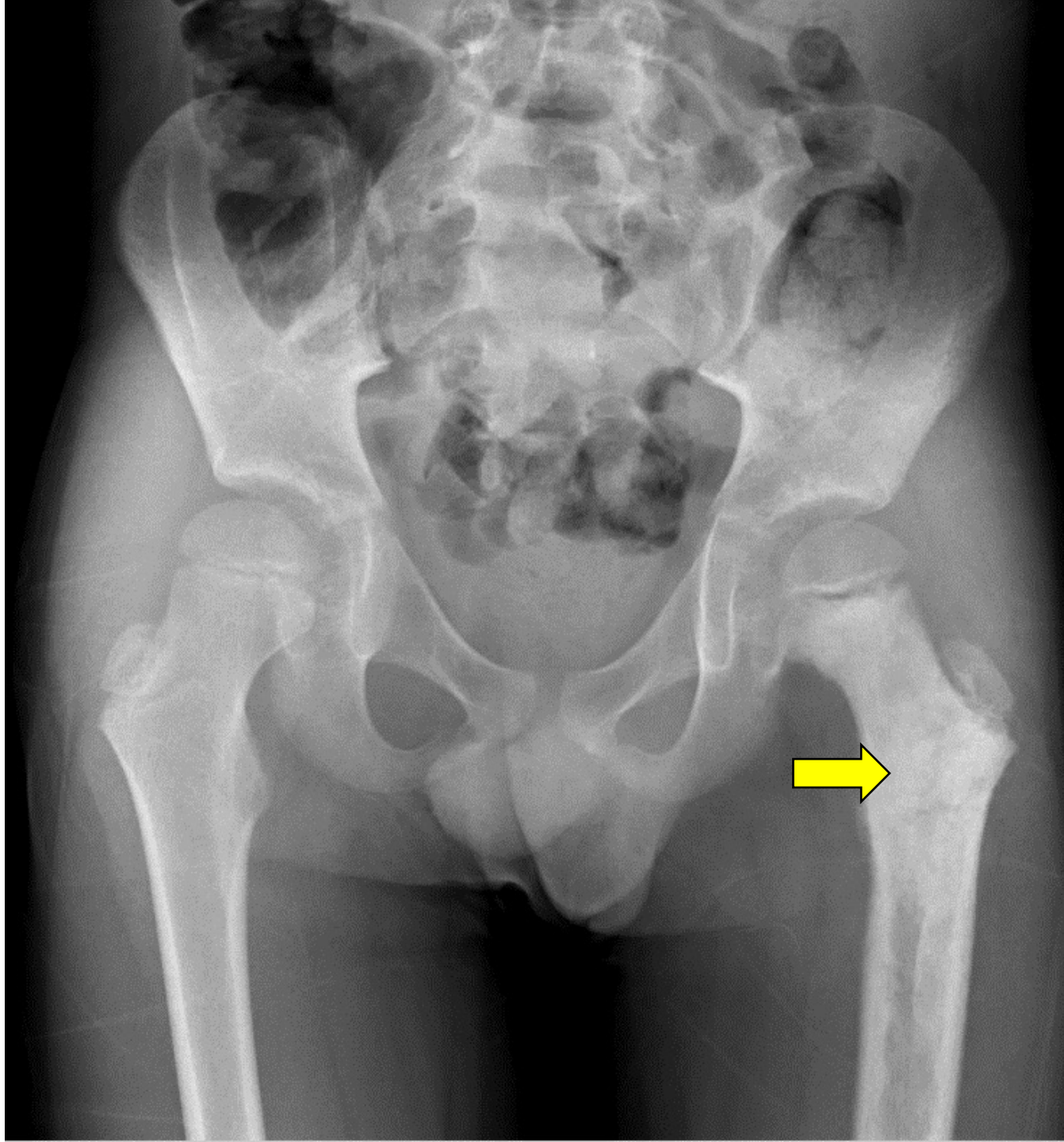
XRAY

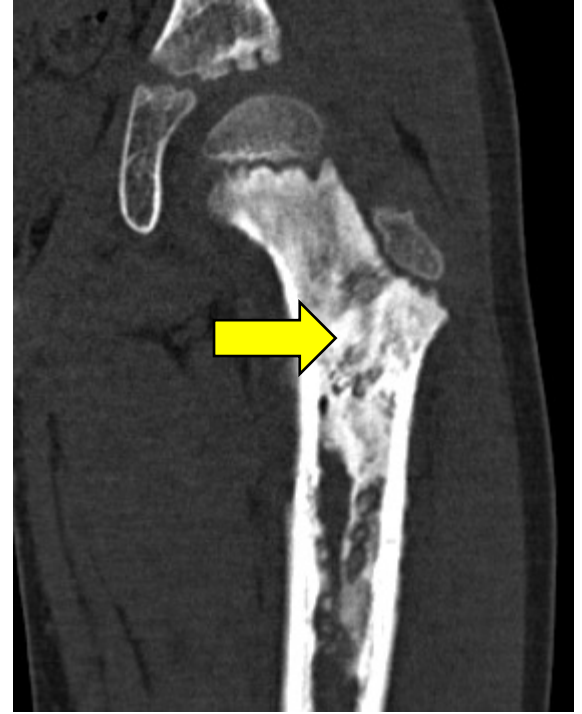
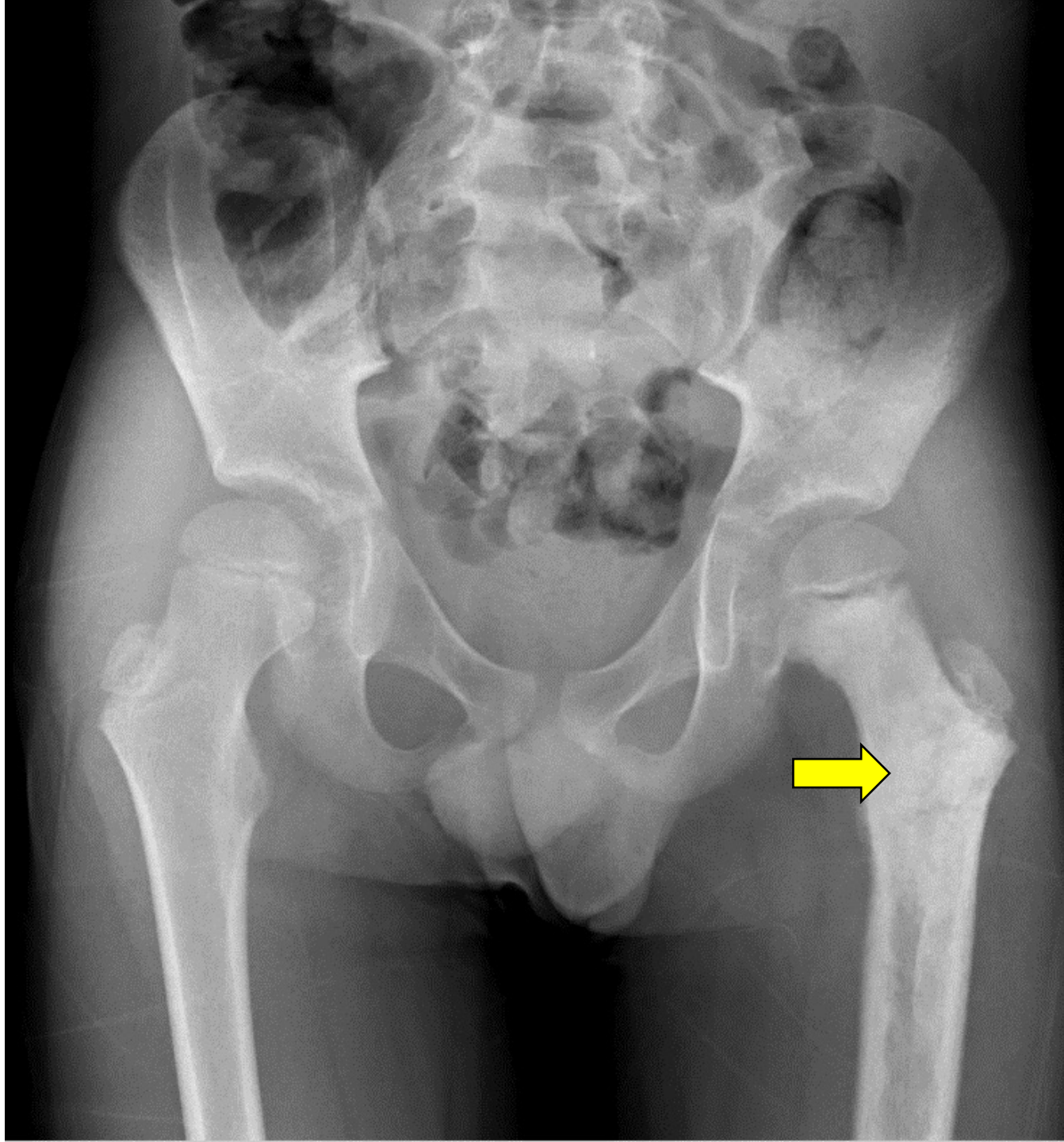


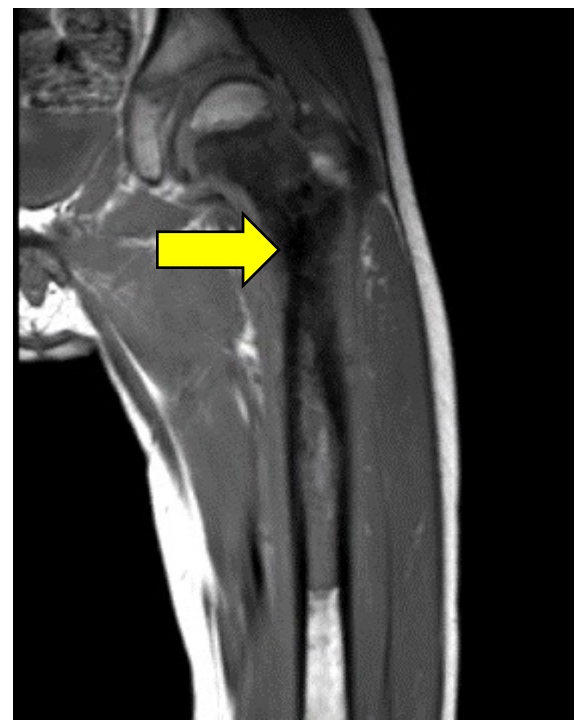
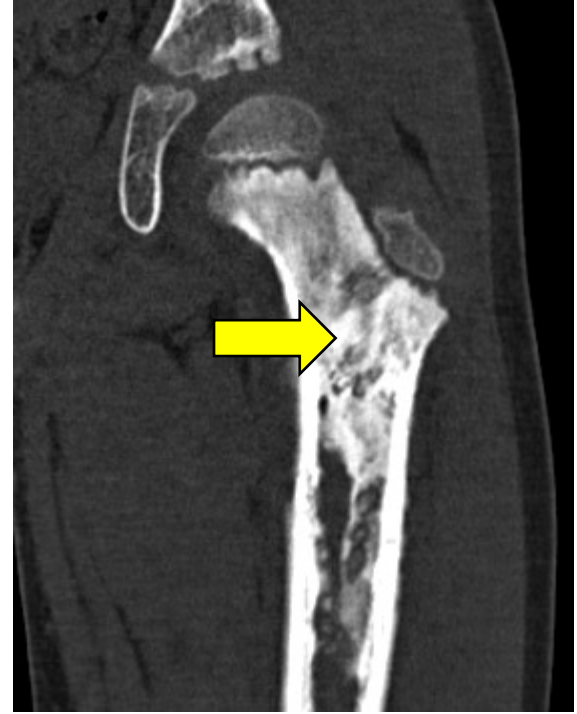
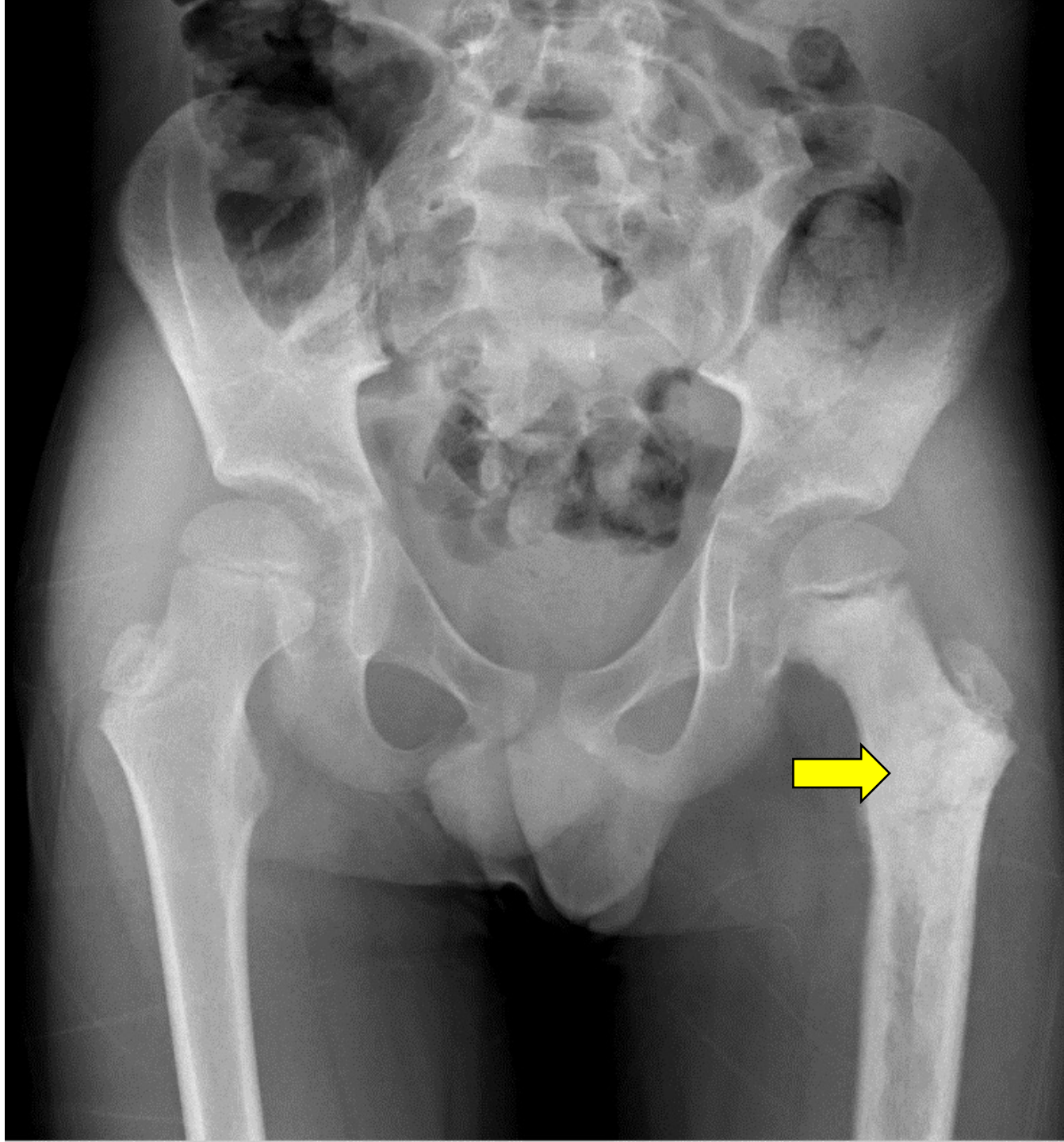




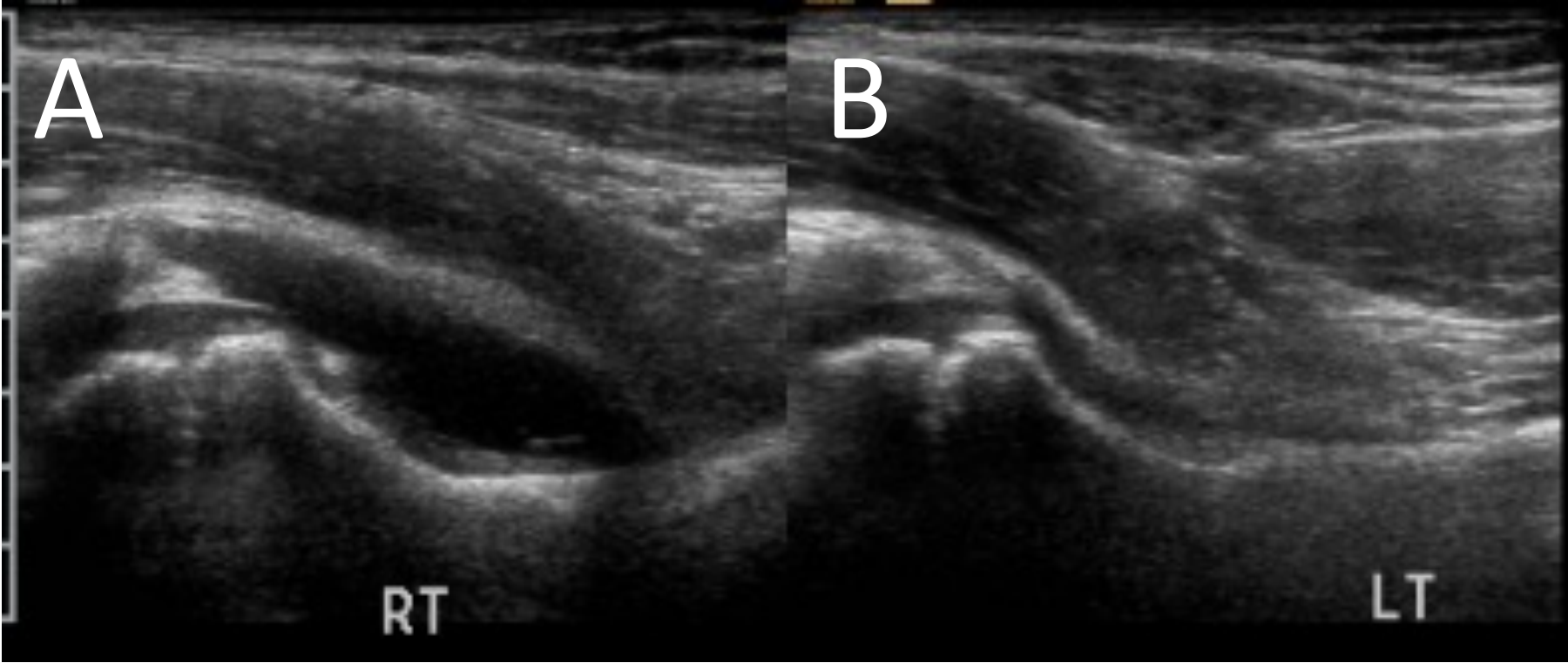


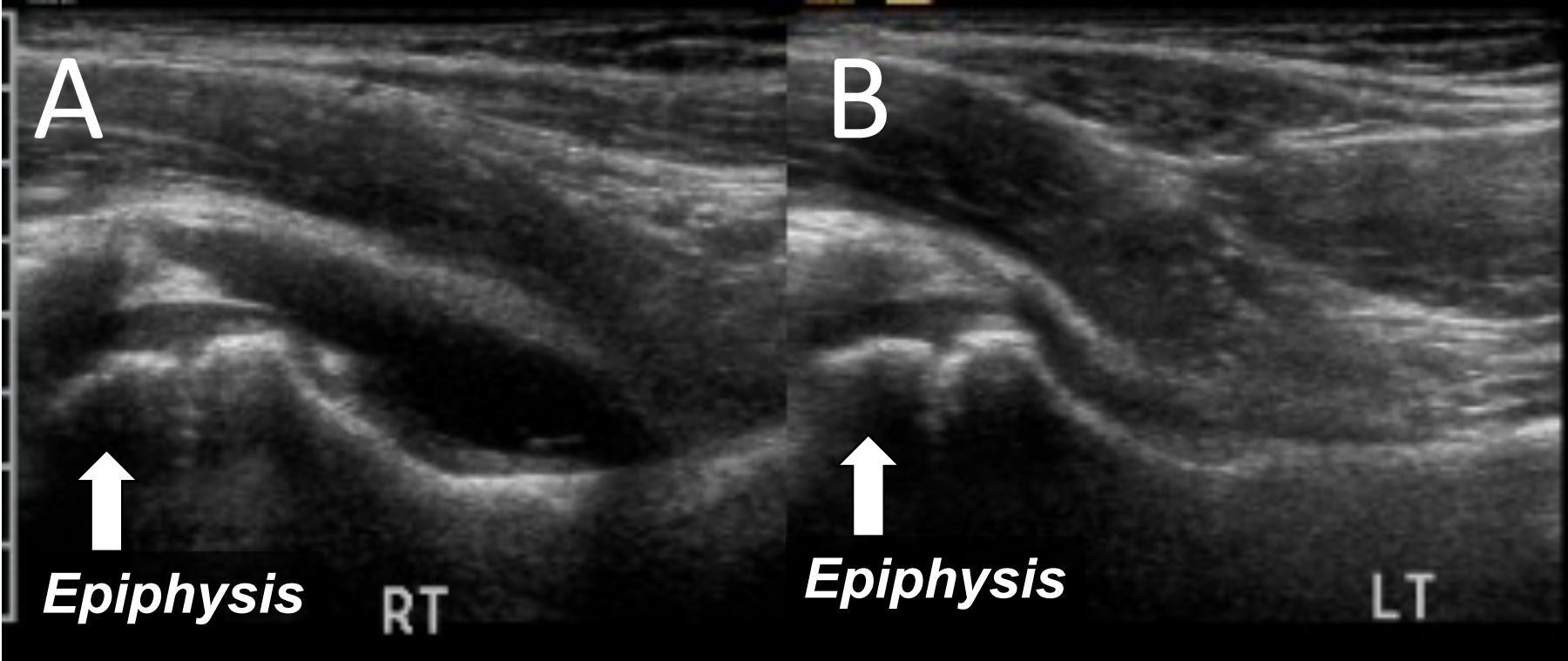


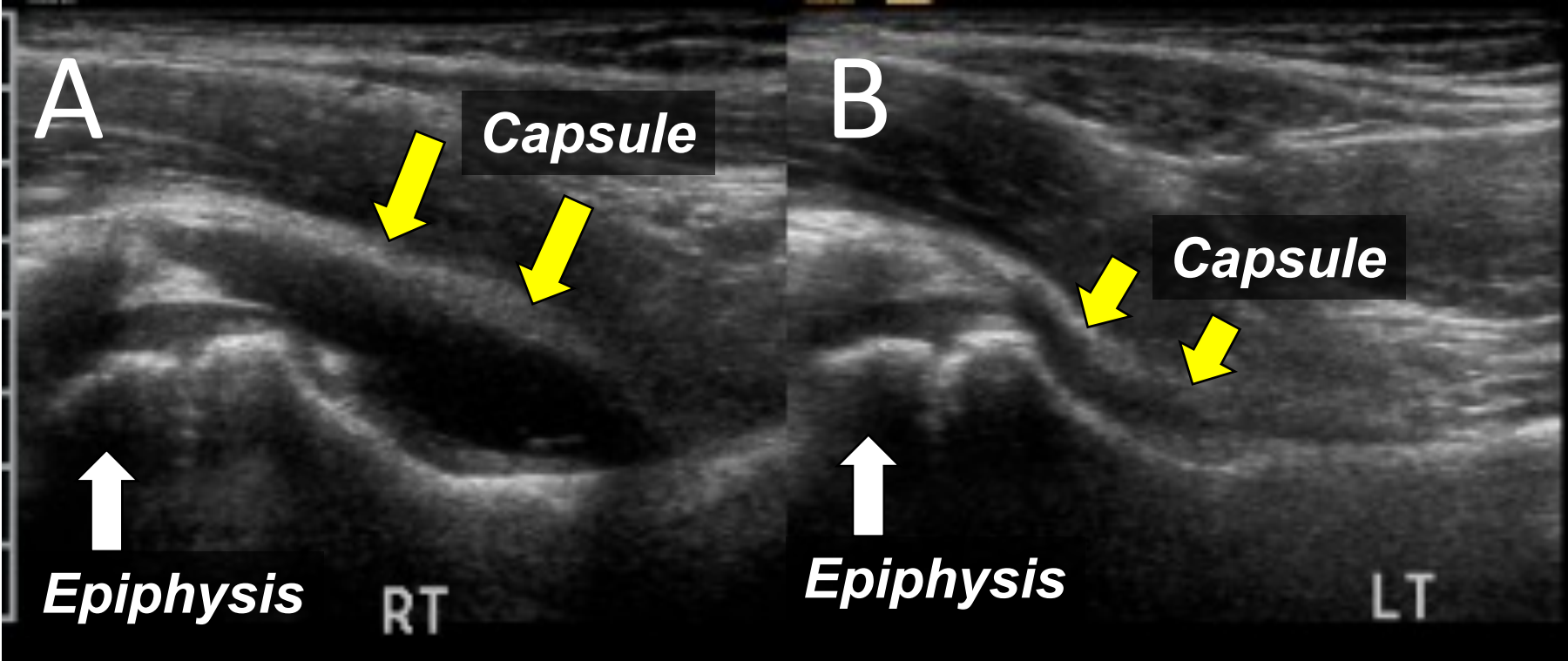


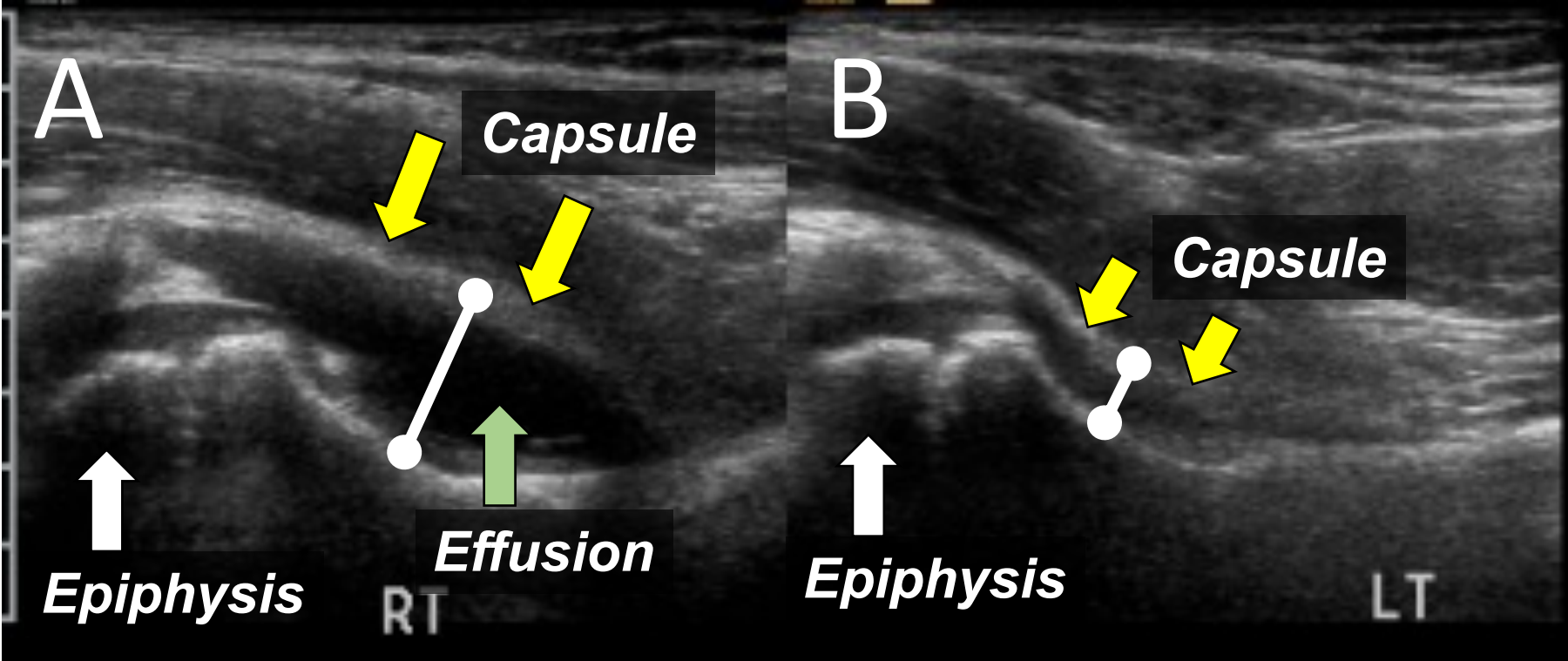


ULTRASOUND





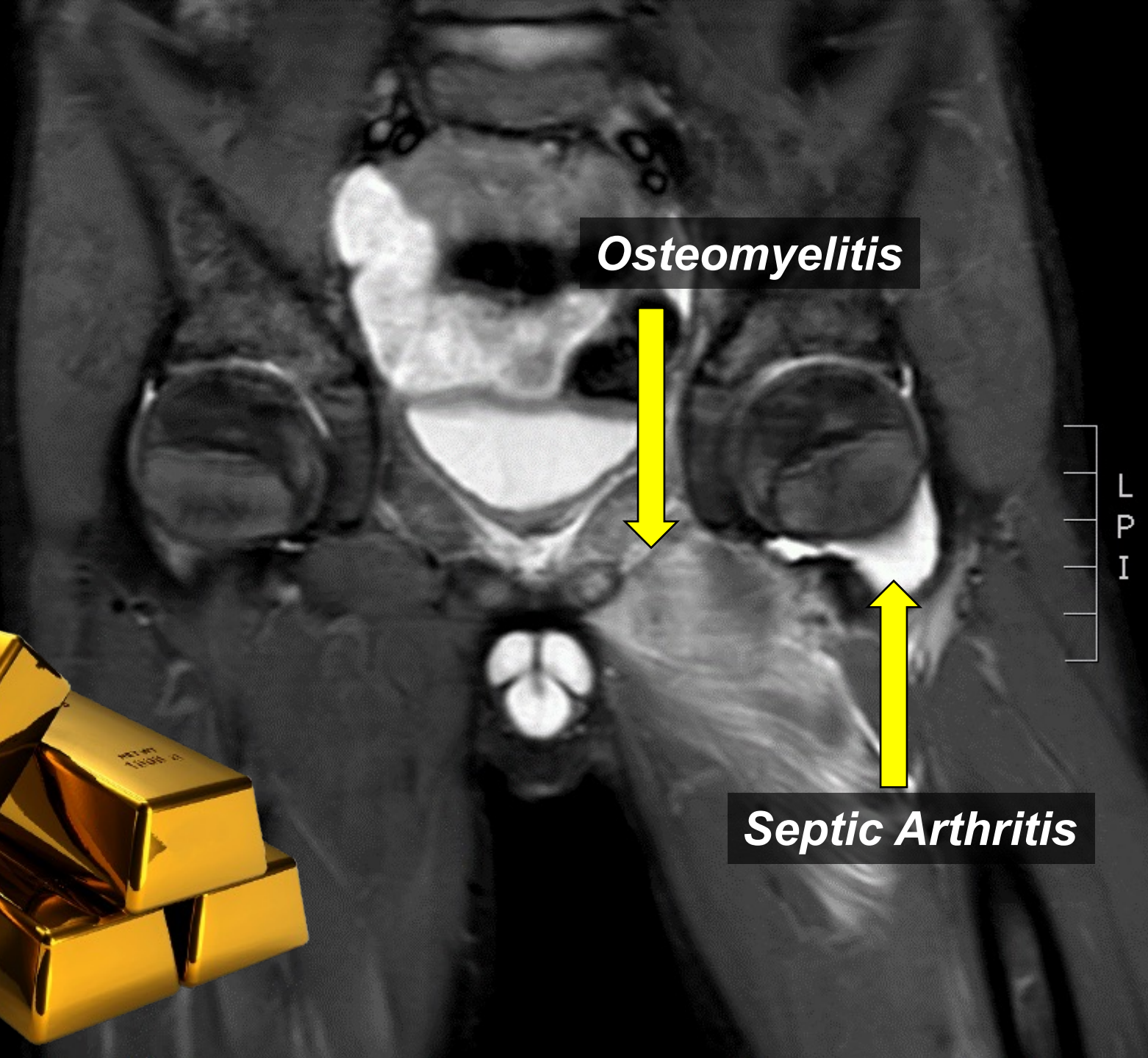




MRI

MRI



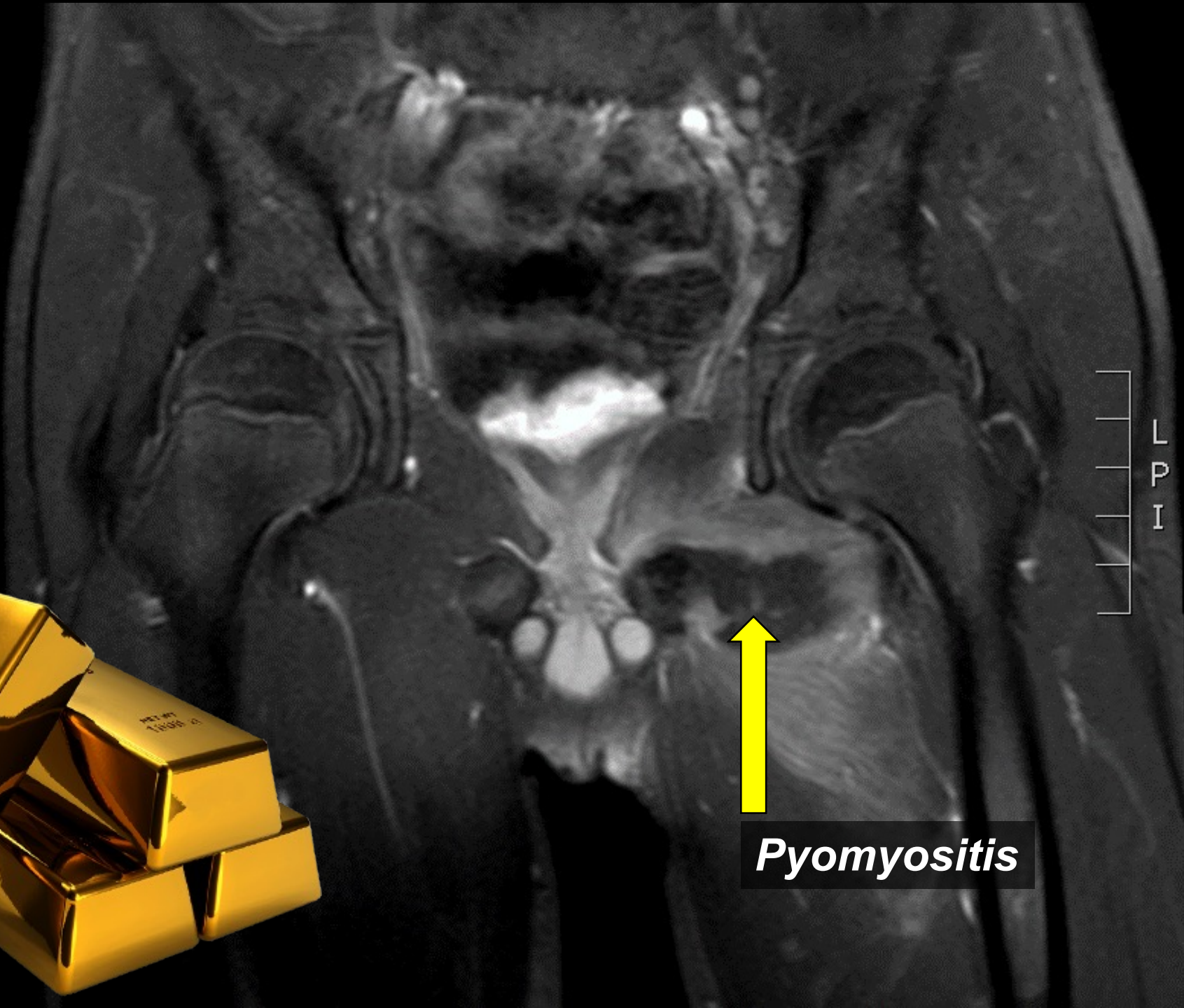


Osteomyelitis



Septic Arthritis

L
P
I



Pyomyositis

Table 1: Snapshot- Fast Sequence MRI for Pediatric MSKI								
	Suspected Focus of Pathology	MSK Infection Screening Protocol	Initial Field of View	1st sequence	2nd sequence	3rd sequence	4th sequence	Estimated Time (min)
Lower Body	Pelvis	Pelvis	Iliac crest to mid femur	Coronal STIR	Coronal T1	Axial T2 fat sat		10-15
	Hip	Pelvis	Iliac crest to mid femur	Coronal STIR	Coronal T1	Axial T2 fat sat		10-15
	Femur	Femur	Hip joint to knee joint	Coronal STIR	Coronal T1	Axial T2 fat sat		10-15
	Knee	Knee	Mid femur to mid tibia	Coronal STIR	Coronal T1	Axial T2 fat sat		10-15
	Tibia	Tibia	Knee joint to Ankle joint	Coronal STIR	Coronal T1	Axial T2 fat sat		10-15
	Ankle	Ankle & Foot	Mid tibia to toes / plantar foot	Coronal STIR	Coronal T1	Axial T2 fat sat	Sagittal STIR	12-18
	Foot	Ankle & Foot	Mid tibia to toes / plantar foot	Coronal STIR	Coronal T1	Axial T2 fat sat	Sagittal STIR	12-18
	Unknown LE	Screening LE with CTLS spine	Iliac crest to plantar foot	Coronal STIR	Coronal T1	Axial T2 fat sat		10-15
	Occiput to coccyx		Sagittal STIR	Sagittal T1	Axial T2		10-15	
Axial	Spine	CTLS spine	Occiput to coccyx	Sagittal STIR	Sagittal T1	Axial T2		
Upper Body	Shoulder	Shoulder	Shoulder joint to mid humerus	Coronal STIR	Coronal T1	Axial T2 fat sat		10-15
	Humerus	Humerus	Shoulder joint to elbow joint	Coronal STIR	Coronal T1	Axial T2 fat sat		10-15
	Elbow	Elbow	Mid humerus to mid forearm	Coronal STIR	Coronal T1	Axial T2 fat sat	Sagittal STIR	12-18
	Forearm	Forearm	Elbow joint to Wrist joint	Coronal STIR	Coronal T1	Axial T2 fat sat		10-15
	Wrist	Wrist & Hand	Mid forearm to finger tips	Coronal STIR	Coronal T1	Axial T2 fat sat		10-15
	Hand	Wrist & Hand	Mid forearm to finger tips	Coronal STIR	Coronal T1	Axial T2 fat sat		10-15
	Unknown UE	Screening UE	Shoulder joint to finger tips	Coronal STIR	Coronal T1	Axial T2 fat sat		10-15



PHYSICAL

EXAM

+ IMAGING

OSTEO

Team-Effort

Where Is It?

Is It A Bug?

How Severe Is It?

Treat It!

OSTEO

Team-Effort

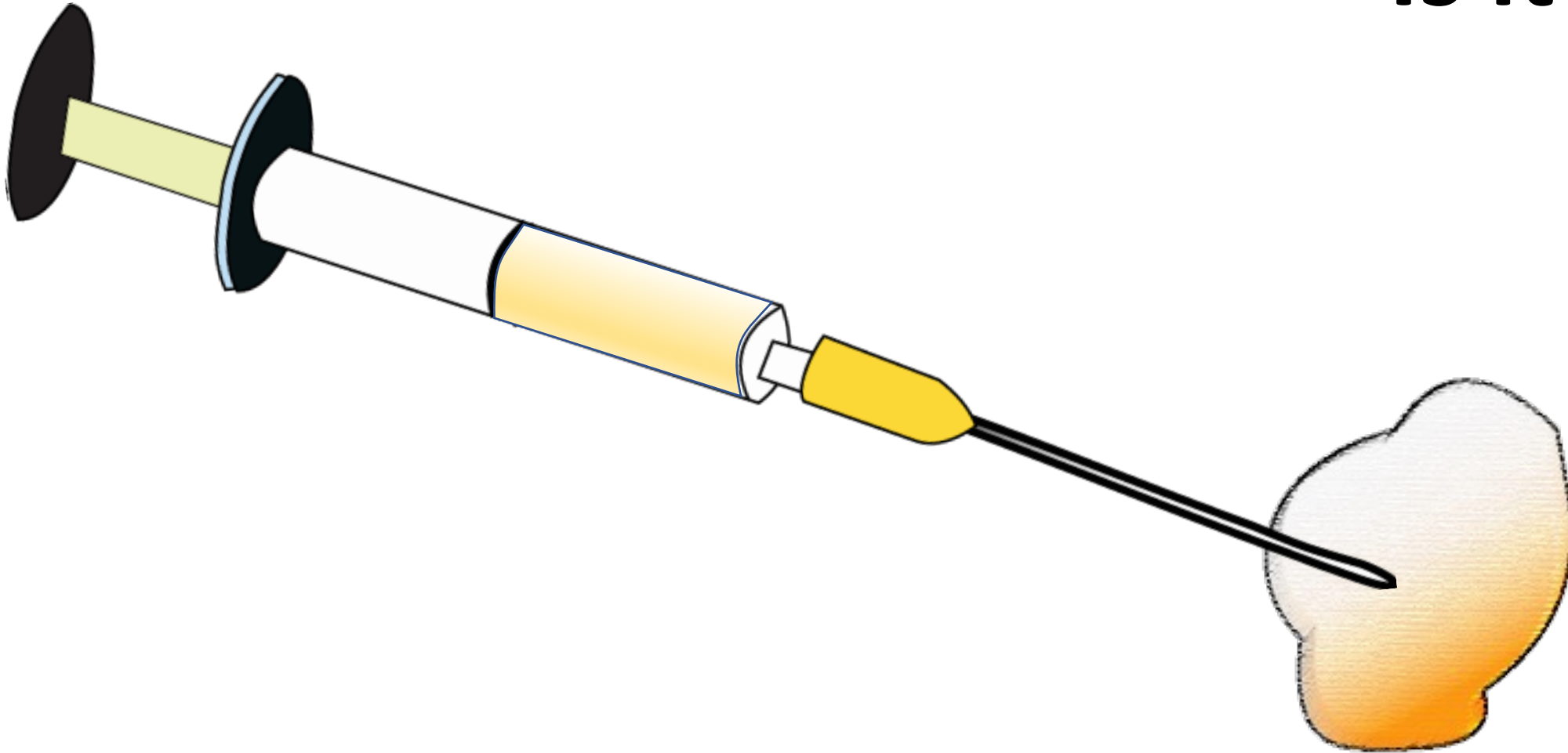
Where Is It?

Is It A Bug?

How Severe Is It?

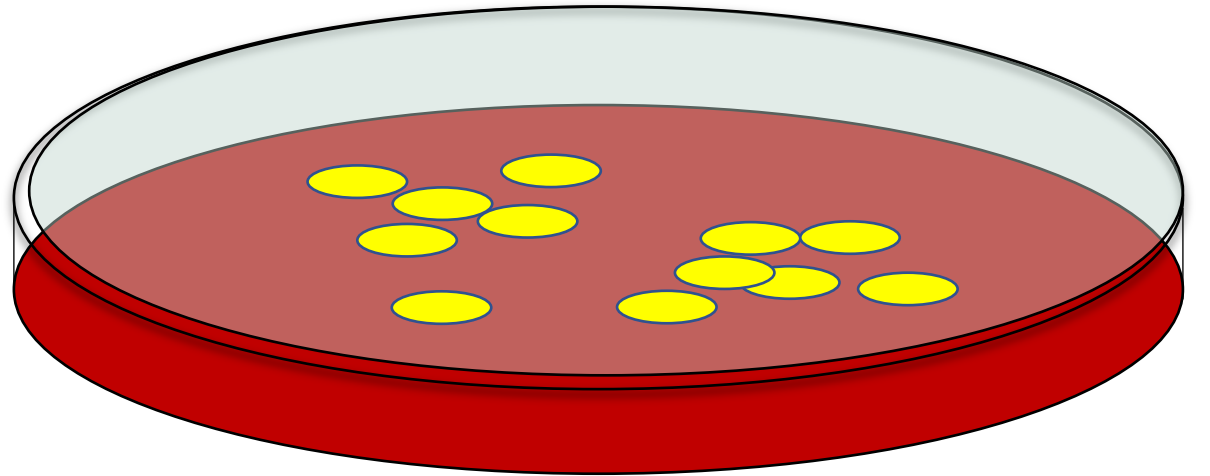
Treat It!

Is it a Bug?

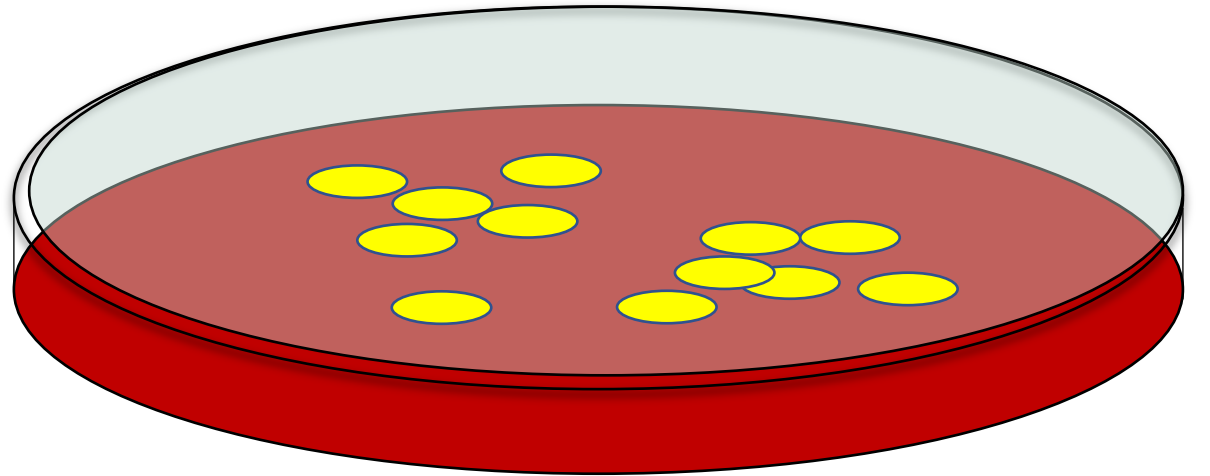


Aspiration

Is it a Bug?



Is it a Bug?

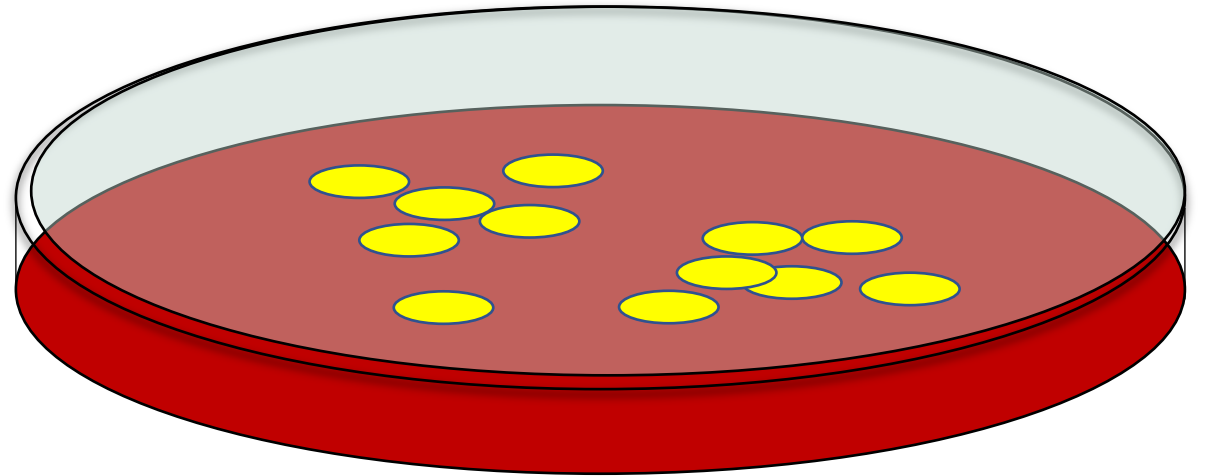


Staph & Strep

Is it a Bug?

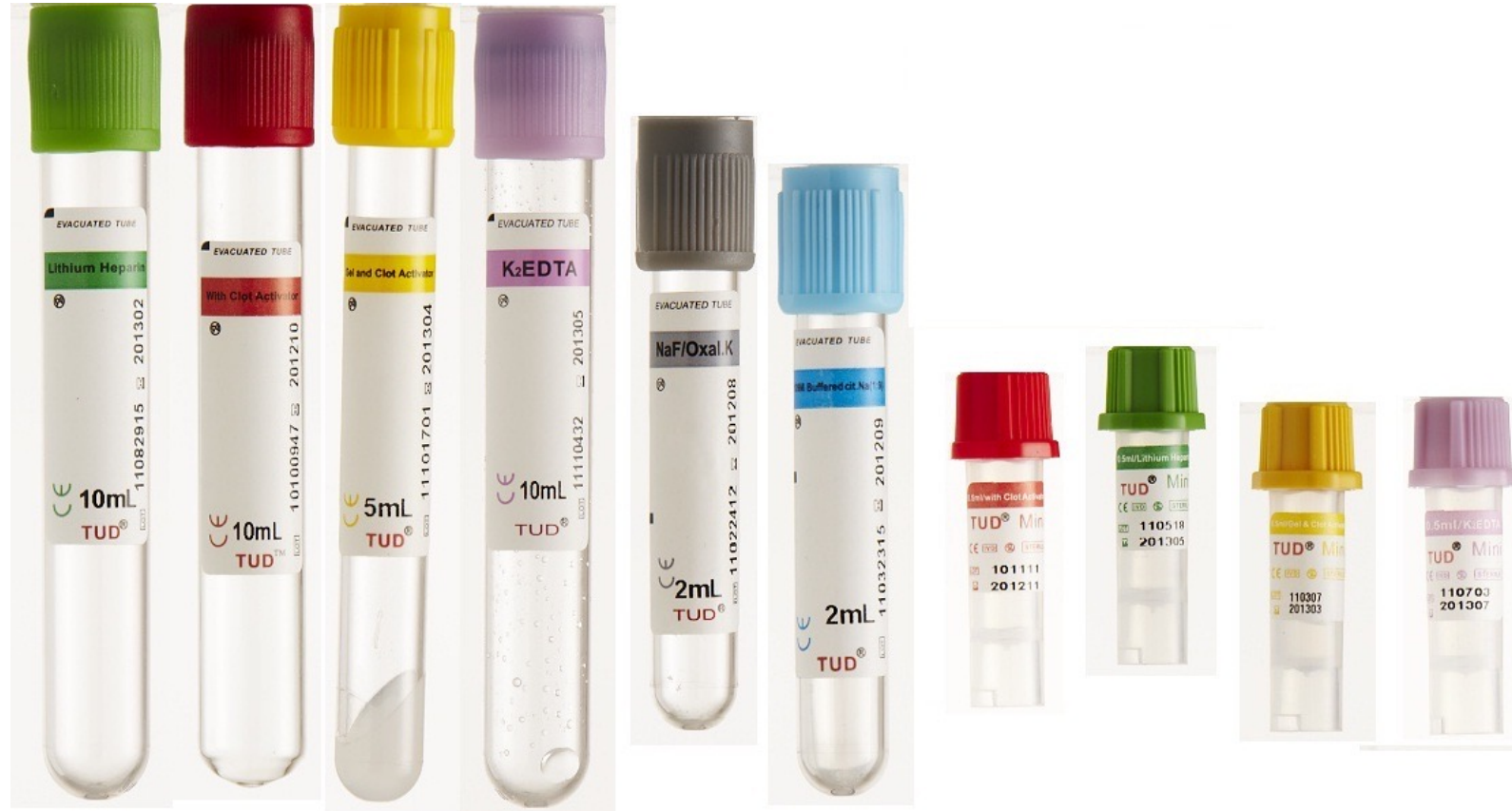


Kingella



Staph & Strep

Is it a Bug?



Labs

OSTEO

Team-Effort


Where Is It?

Is It A Bug?

How Severe Is It?

Treat It!

4 QUESTIONS



MSK Infection

ACUTE PHASE RESPONSE



ACUTE PHASE RESPONSE

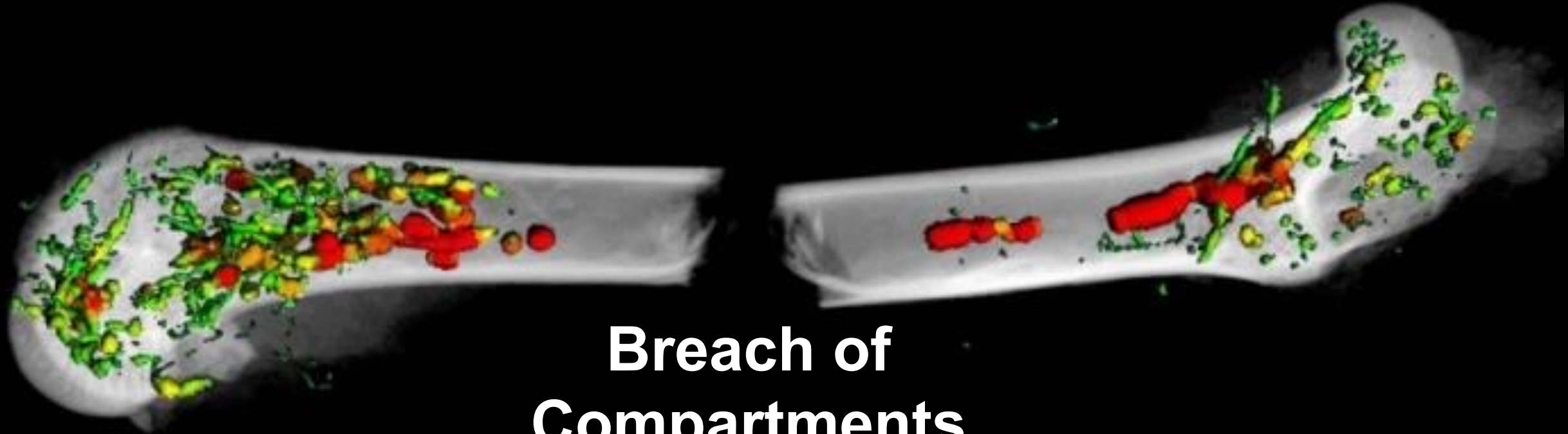FRACTURE

ACUTE PHASE RESPONSE



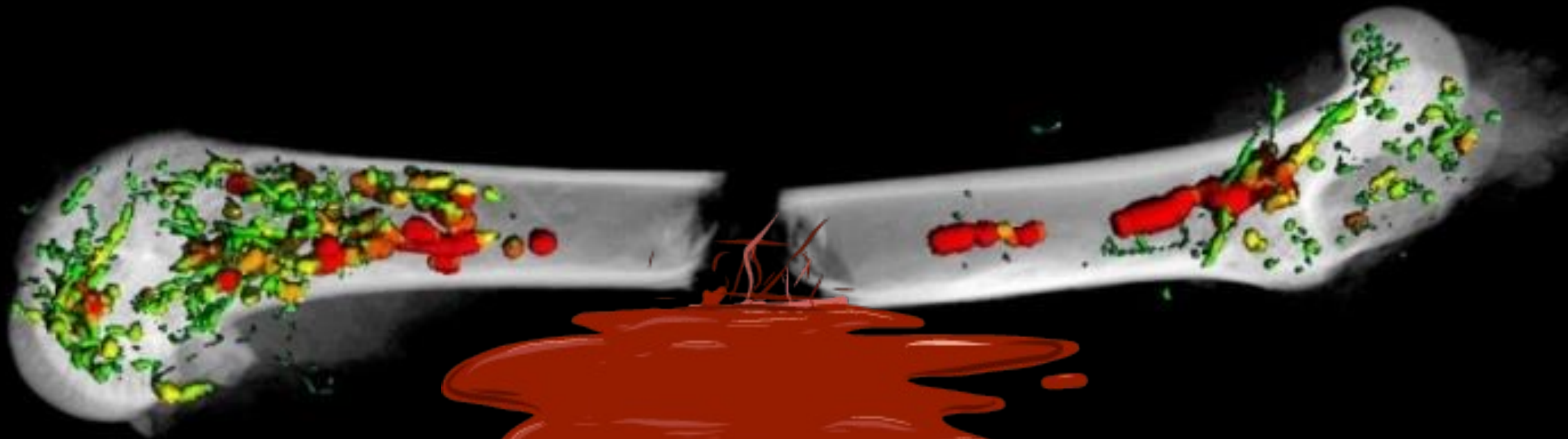
FRACTURE

ACUTE PHASE RESPONSE



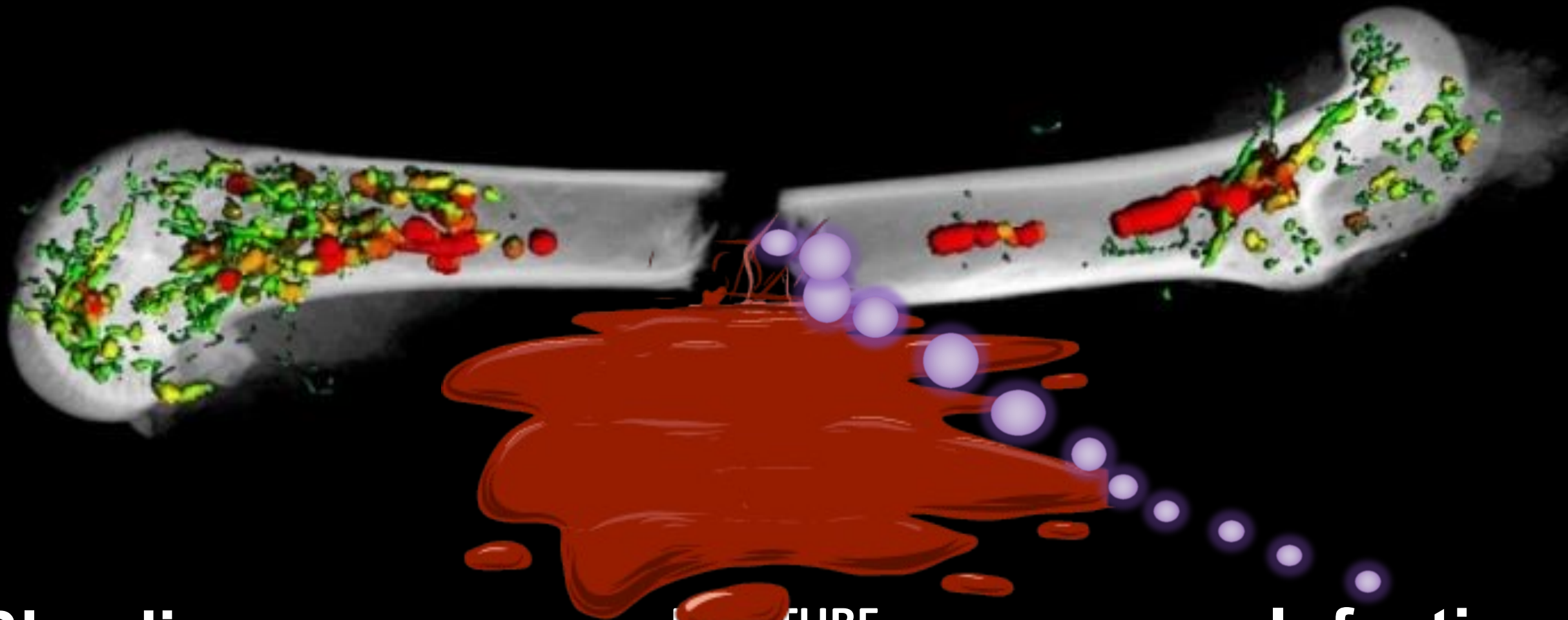**Breach of
Compartments**

FRACTURE



Bleeding

FRACTURE

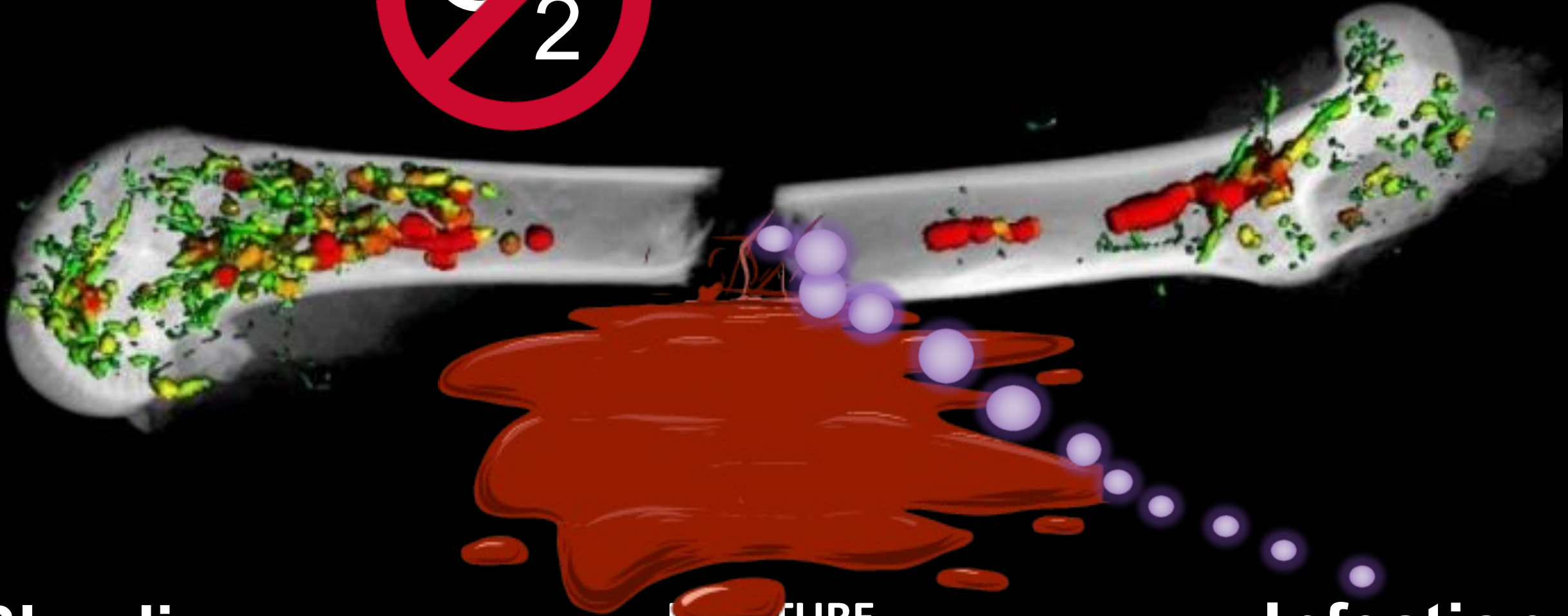
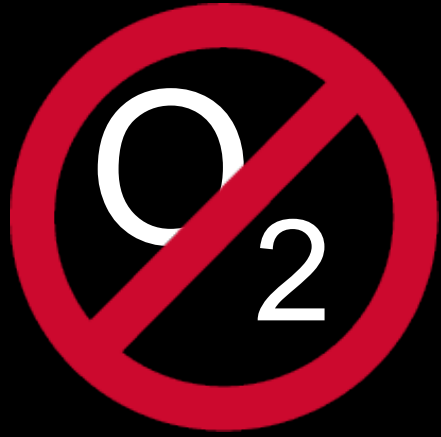

Bleeding

FRactURE

Infection

Hypoxia



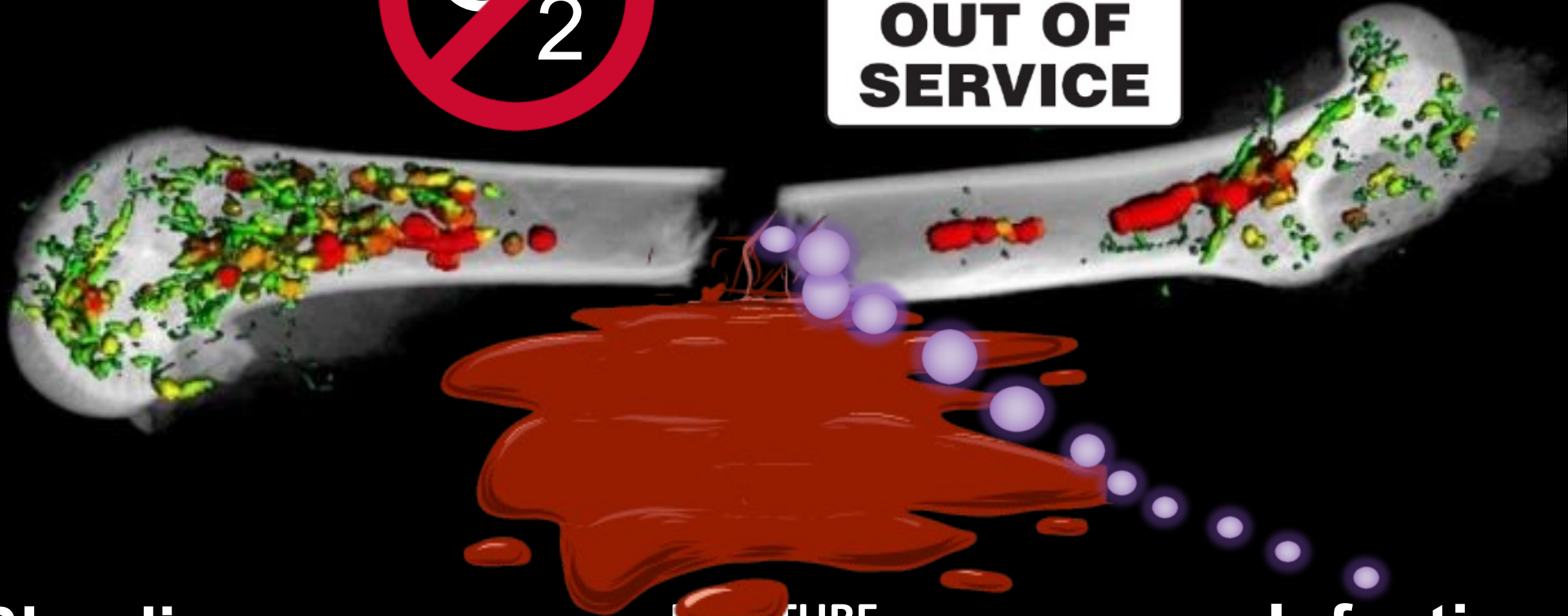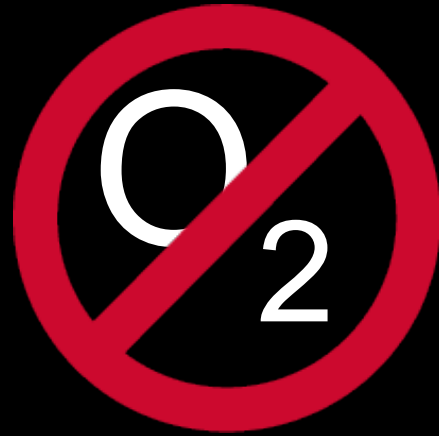Bleeding

FRactURE

Infection

Hypoxia

Dysfunction



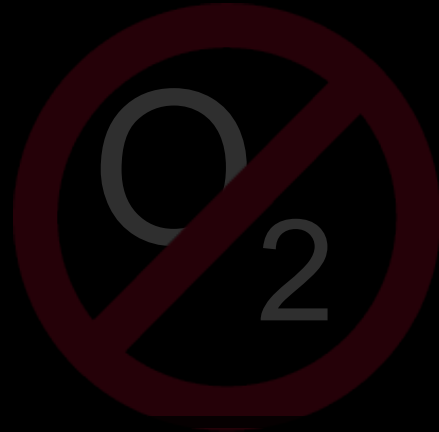
Bleeding

FRACTURE

Infection

Hypoxia

Dysfunction



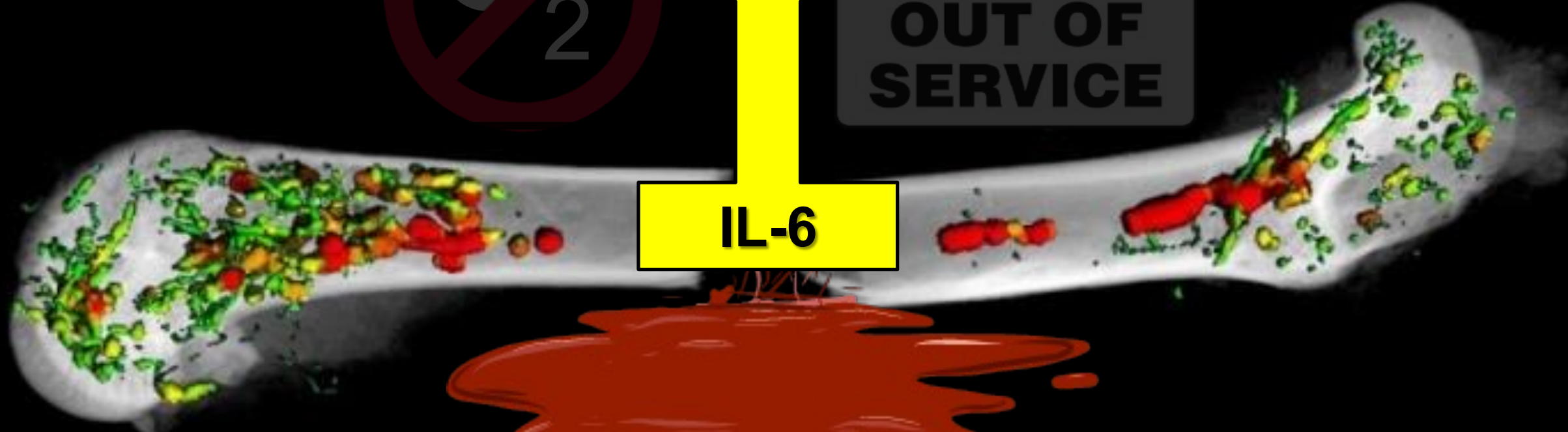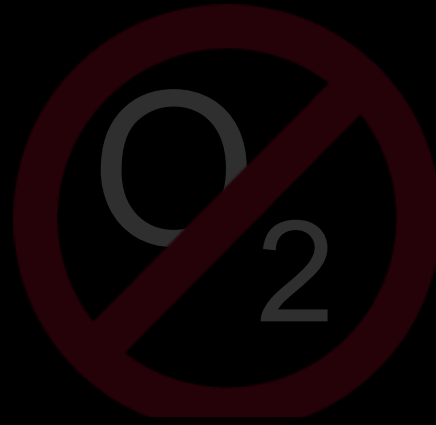Bleeding

FRACTURE

Infection

Hypoxia

Dysfunction



IL-6



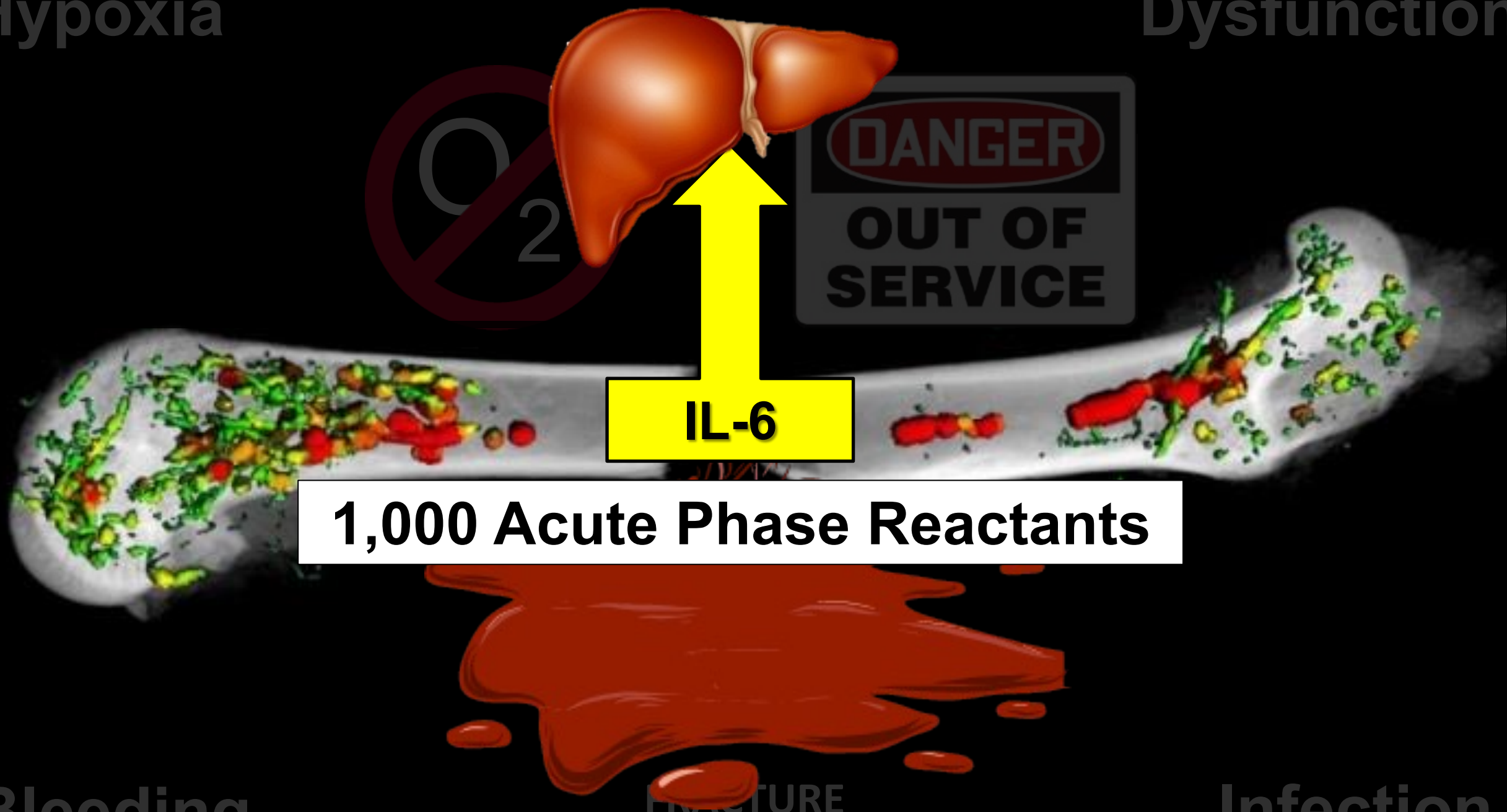
Bleeding

FRACTURE

Infection

Hypoxia

Dysfunction



1,000 Acute Phase Reactants

IL-6

**DANGER
OUT OF SERVICE**

No O₂

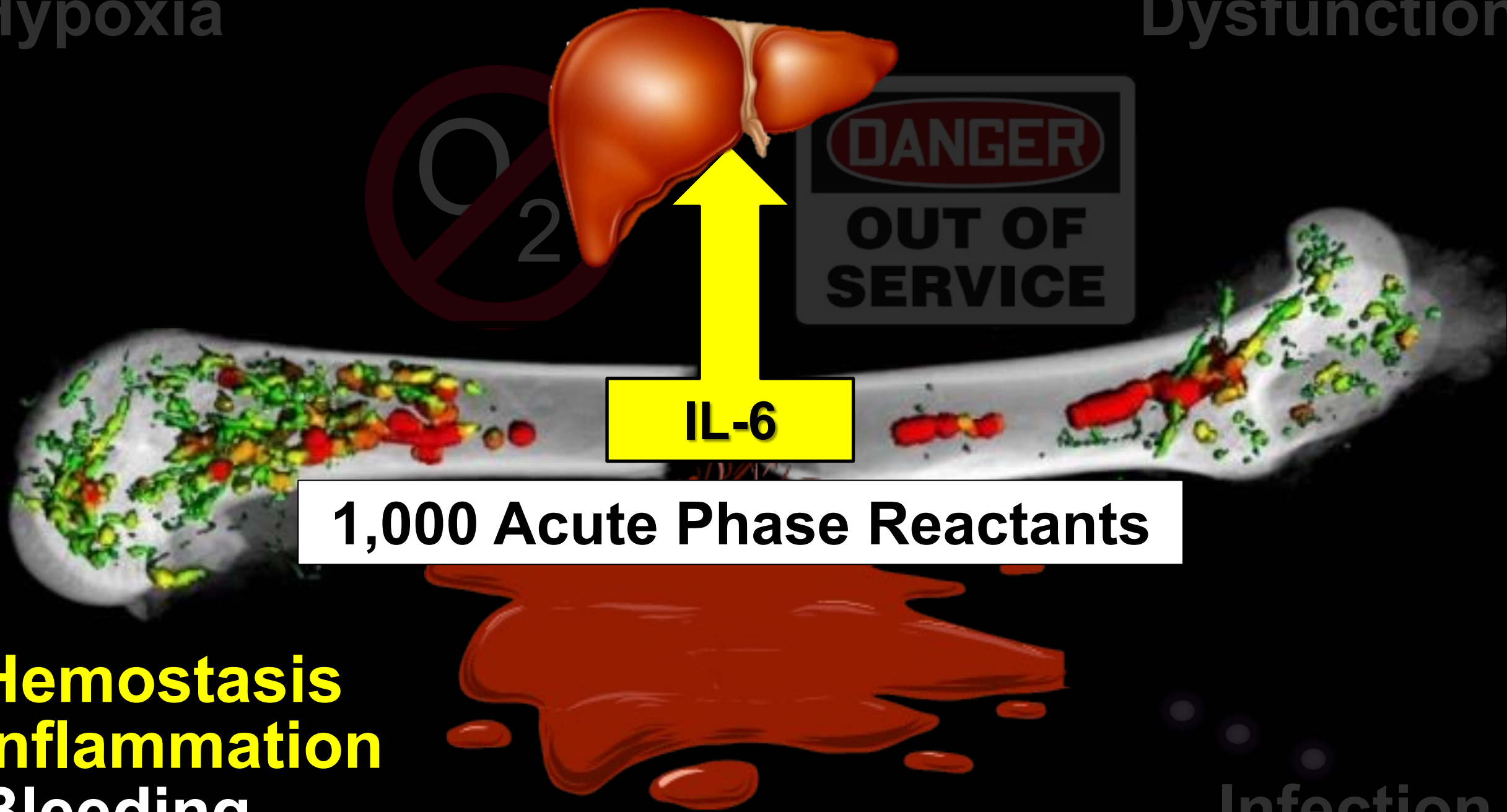
Bleeding

FRACTURE

Infection

Hypoxia

Dysfunction



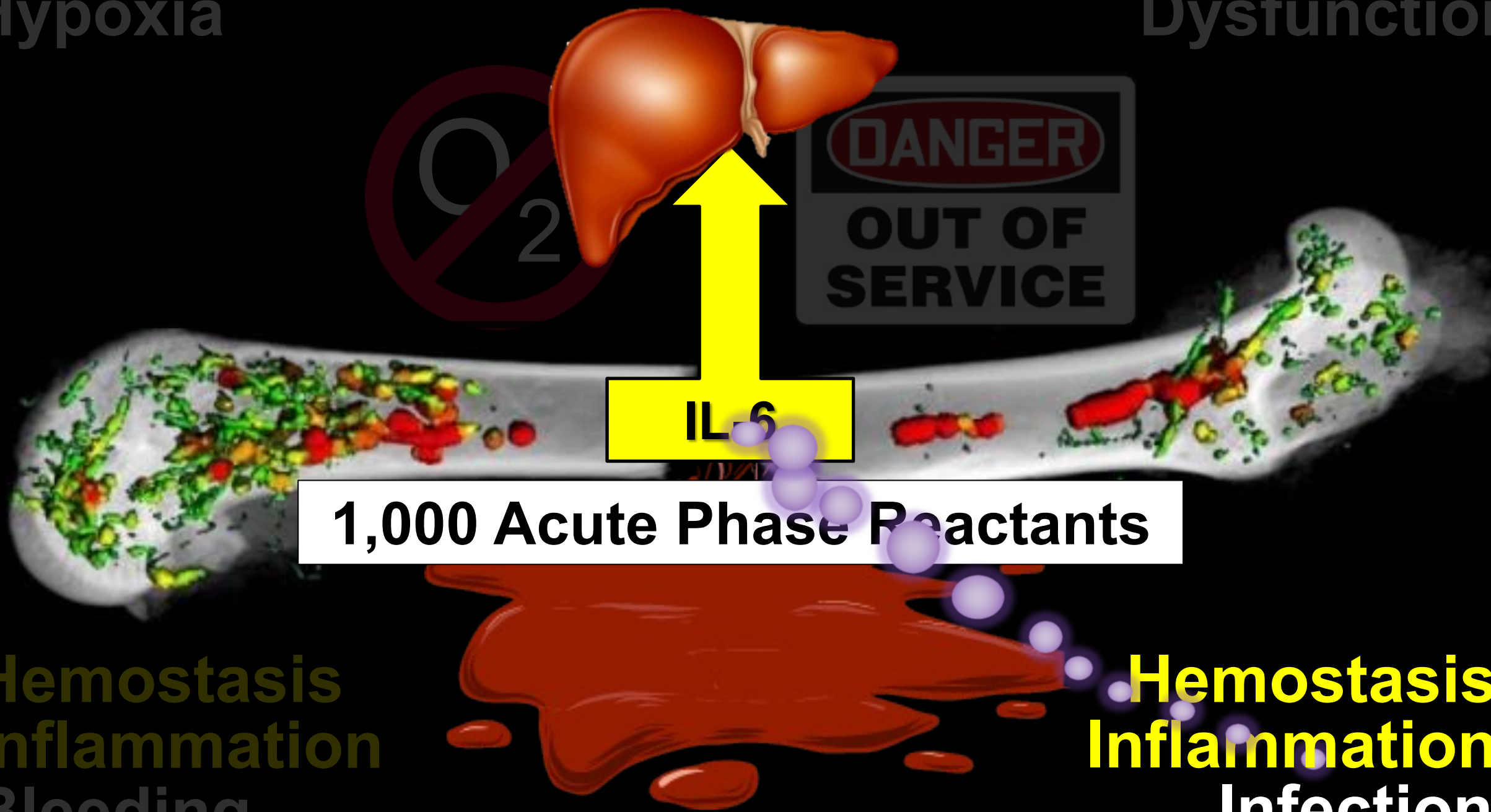
1,000 Acute Phase Reactants

Hemostasis
Inflammation
Bleeding

Infection

Hypoxia

Dysfunction



1,000 Acute Phase Reactants

IL-6

**DANGER
OUT OF SERVICE**

No O₂

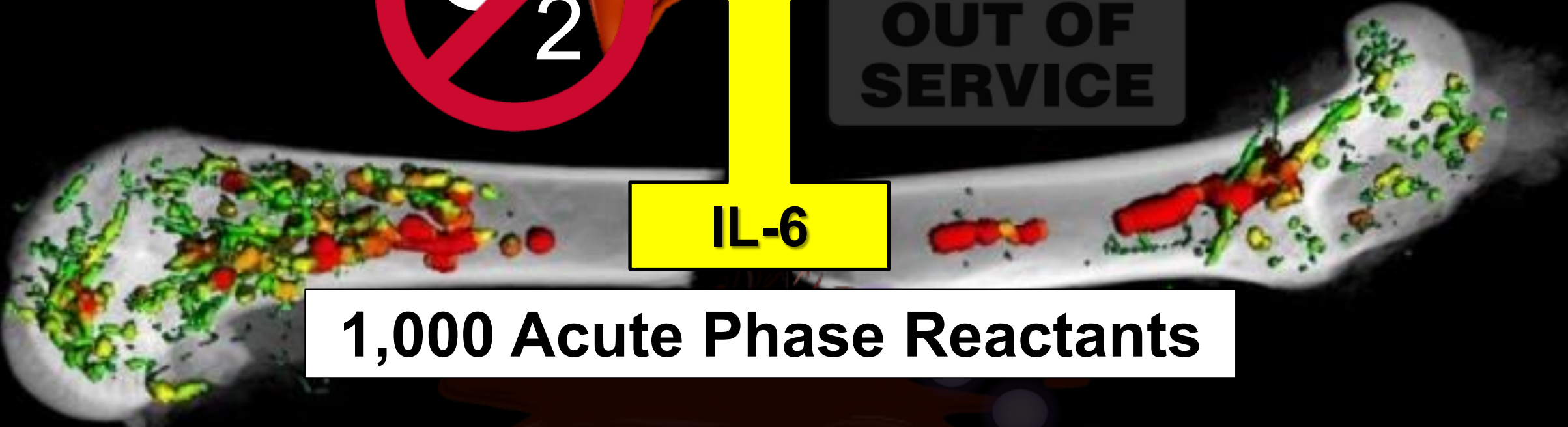
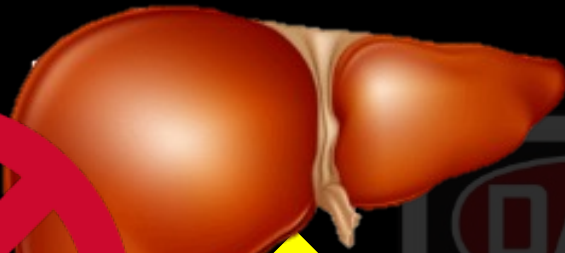
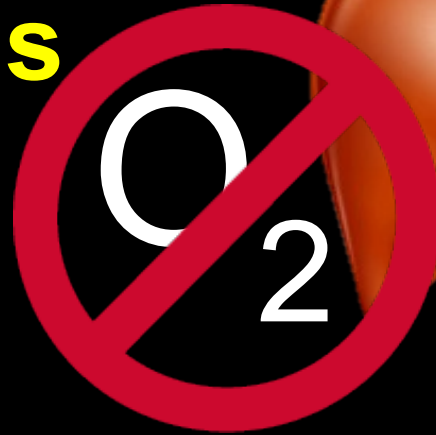**Hemostasis
Inflammation
Bleeding**

**Hemostasis
Inflammation
Infection**

Hypoxia

Angiogenesis

Dysfunction



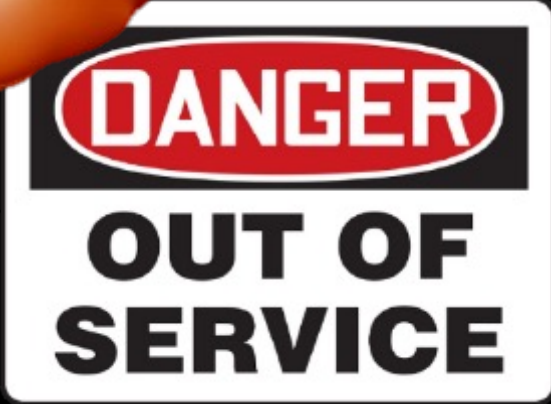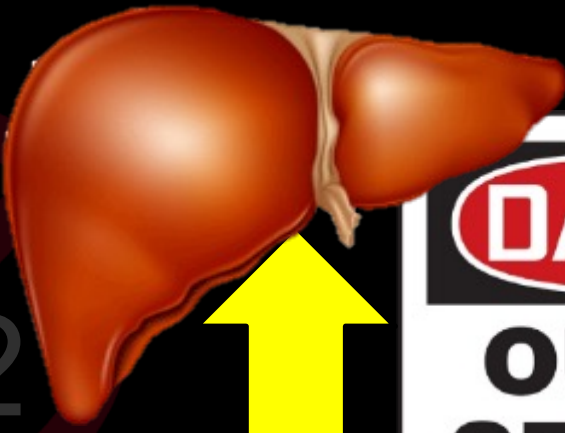1,000 Acute Phase Reactants

**Hemostasis
Inflammation
Bleeding**

**Hemostasis
Inflammation
Infection**

Hypoxia
Angiogenesis

Dysfunction
Ossification

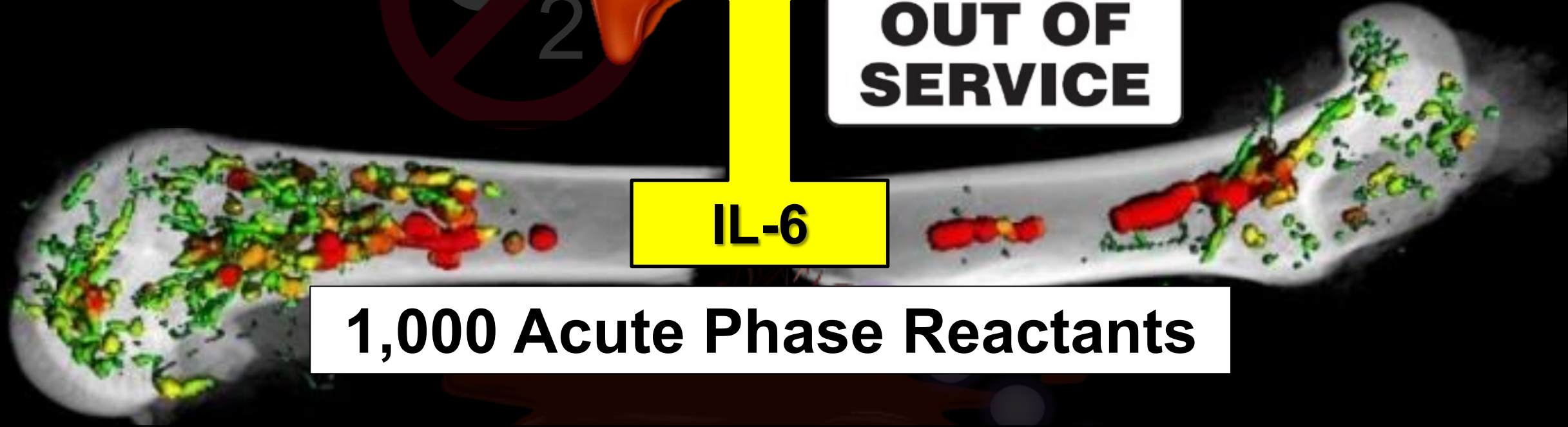


IL-6

1,000 Acute Phase Reactants

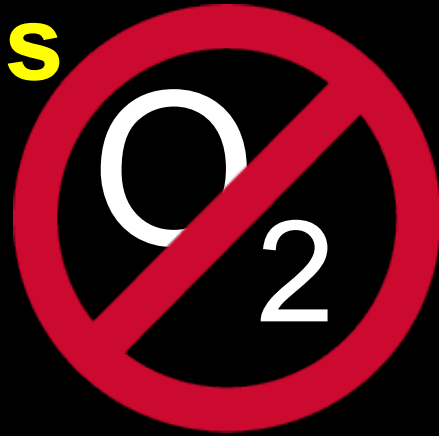Hemostasis
Inflammation
Bleeding

Hemostasis
Inflammation
Infection



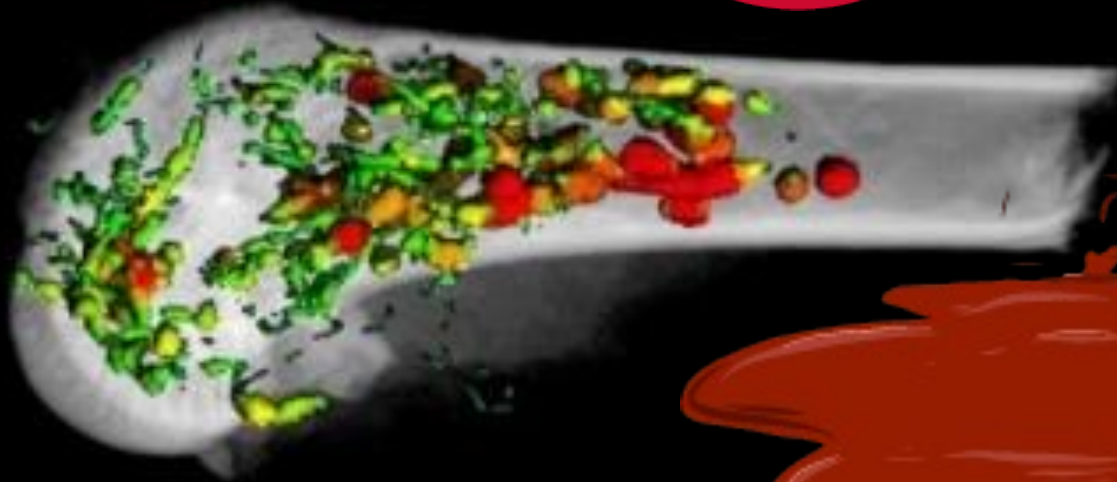
Hypoxia

Angiogenesis

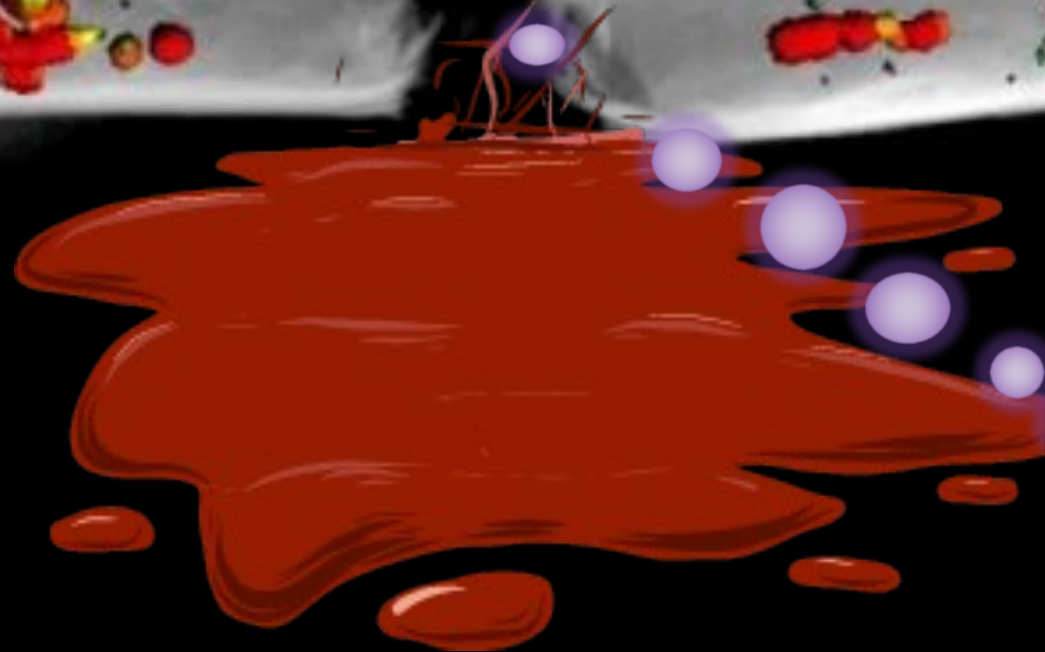

Dysfunction

Ossification

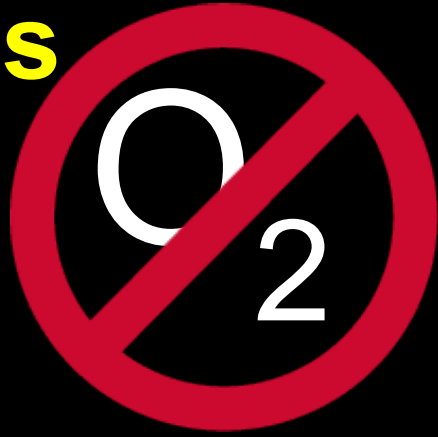


Hemostasis
Inflammation
Bleeding



Hemostasis
Inflammation
Infection

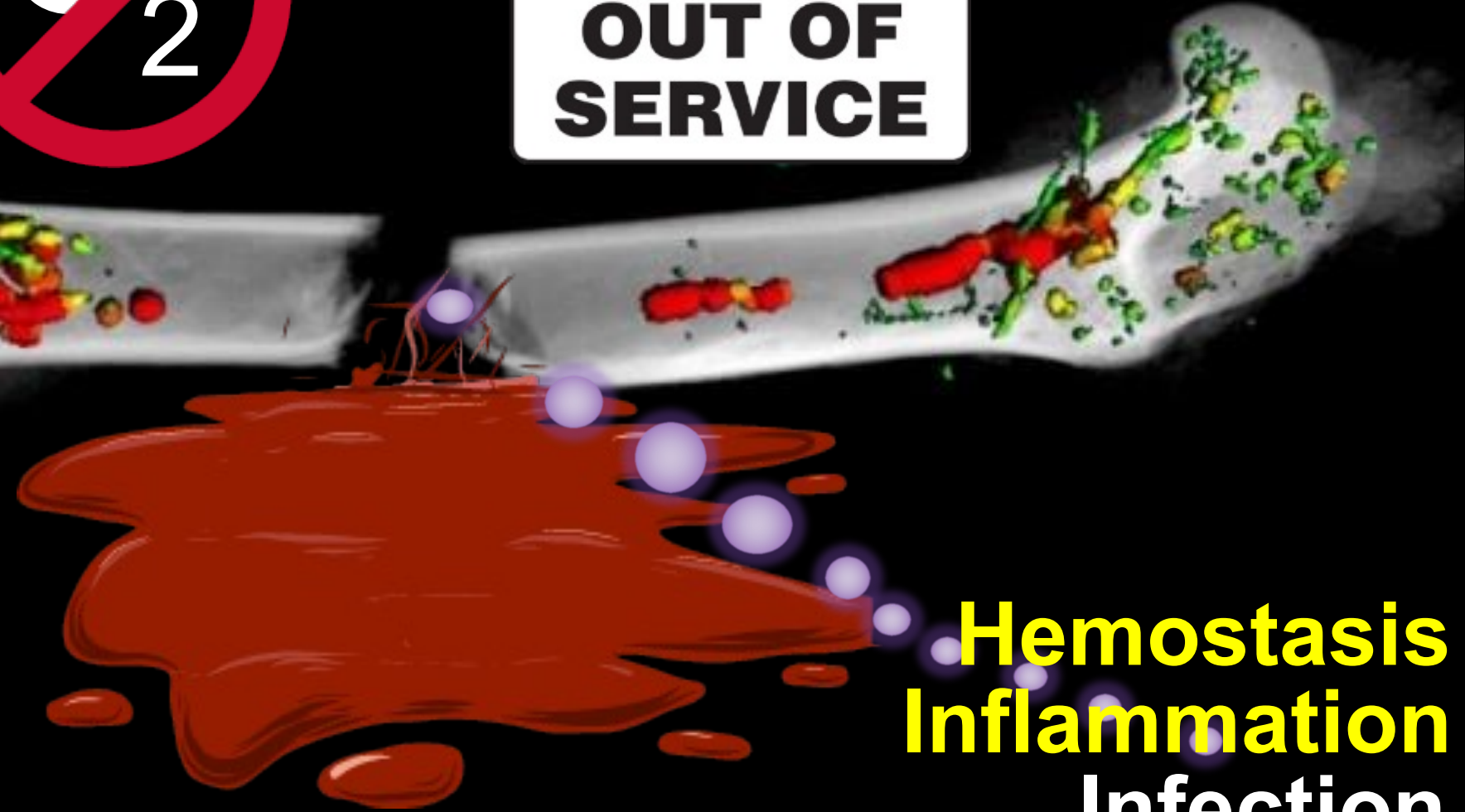Hypoxia
Angiogenesis



Dysfunction
Ossification

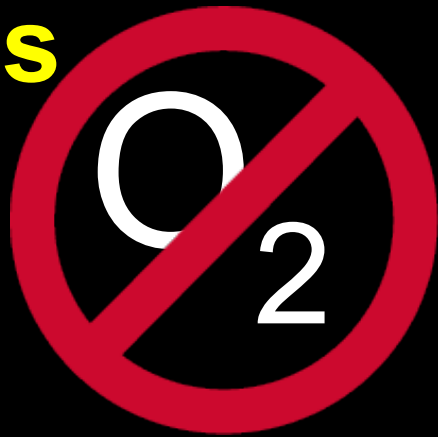1

Hemostasis
Inflammation
Bleeding




Hemostasis
Inflammation
Infection

Hypoxia
Angiogenesis



Dysfunction
Ossification

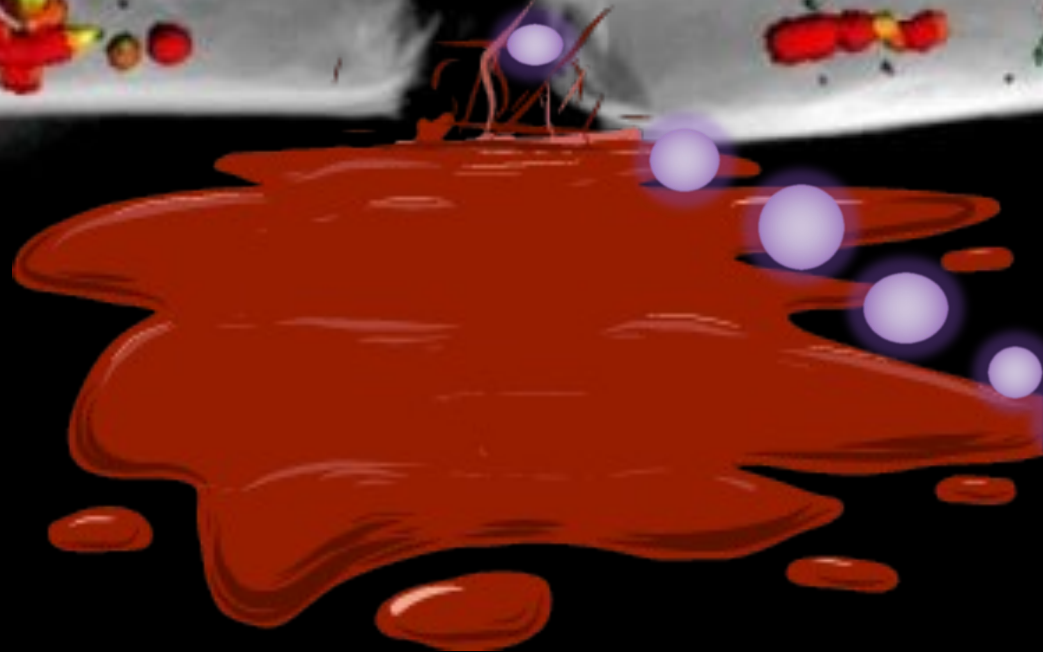1



2



Hemostasis
Inflammation
Bleeding

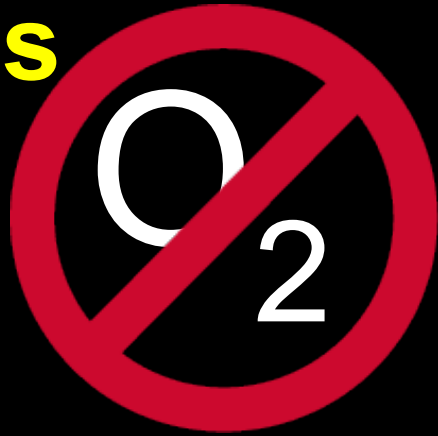

Hemostasis
Inflammation
Infection

Hypoxia

Angiogenesis

3



Dysfunction

Ossification


1

Hemostasis
Inflammation
Bleeding



2

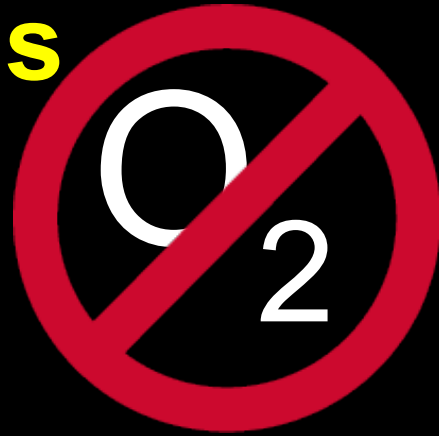
Hemostasis
Inflammation
Infection



Hypoxia

Angiogenesis

3



Dysfunction

Ossification

4

1

Hemostasis
Inflammation
Bleeding



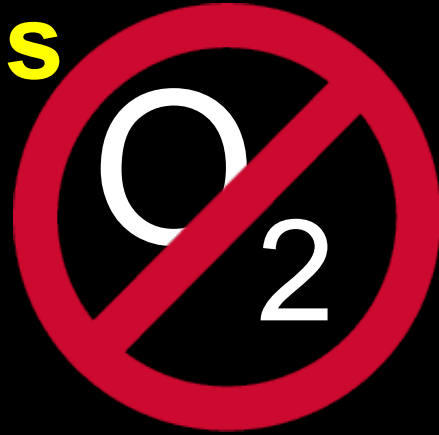
2

Hemostasis
Inflammation
Infection

Hypoxia

Angiogenesis

3



Dysfunction

Ossification

4

1

Hemostasis
Inflammation
Bleeding



SURVIVE

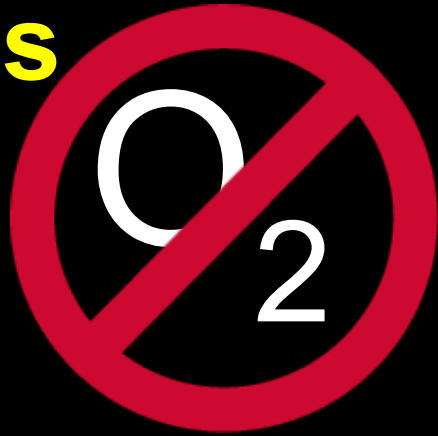
2

Hemostasis
Inflammation
Infection

Hypoxia

Angiogenesis

3



Dysfunction

Ossification

4



1

Hemostasis
Inflammation
Bleeding



SURVIVE

2

Hemostasis
Inflammation
Infection

Hypoxia

Angiogenesis

3



Dysfunction

Ossification

4

1

Hemostasis
Inflammation
Bleeding



SURVIVE

2

Hemostasis
Inflammation
Infection

Hypoxia

Angiogenesis

3



Dysfunction

Ossification

4

1

**Hemostasis
Inflammation
Bleeding**



**TEMPORARY
SEALANT**

SURVIVE

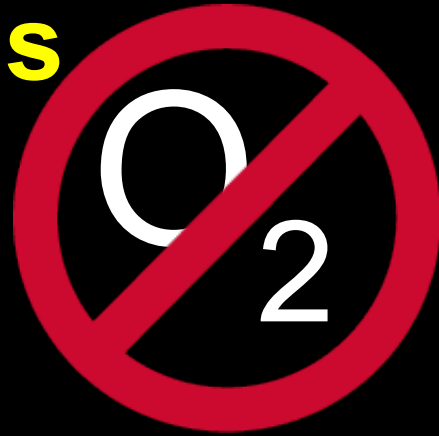
2

**Hemostasis
Inflammation
Infection**

Hypoxia

Angiogenesis

3



REPAIR



Dysfunction

Ossification

4

1

Hemostasis
Inflammation
Bleeding



TEMPORARY
SEALANT

SURVIVE

2

Hemostasis
Inflammation
Infection

Hypoxia

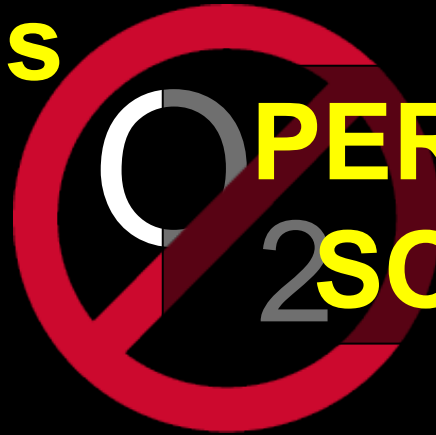REPAIR

Dysfunction

Angiogenesis

Ossification

3



PERMANENT SOLUTION



4



1

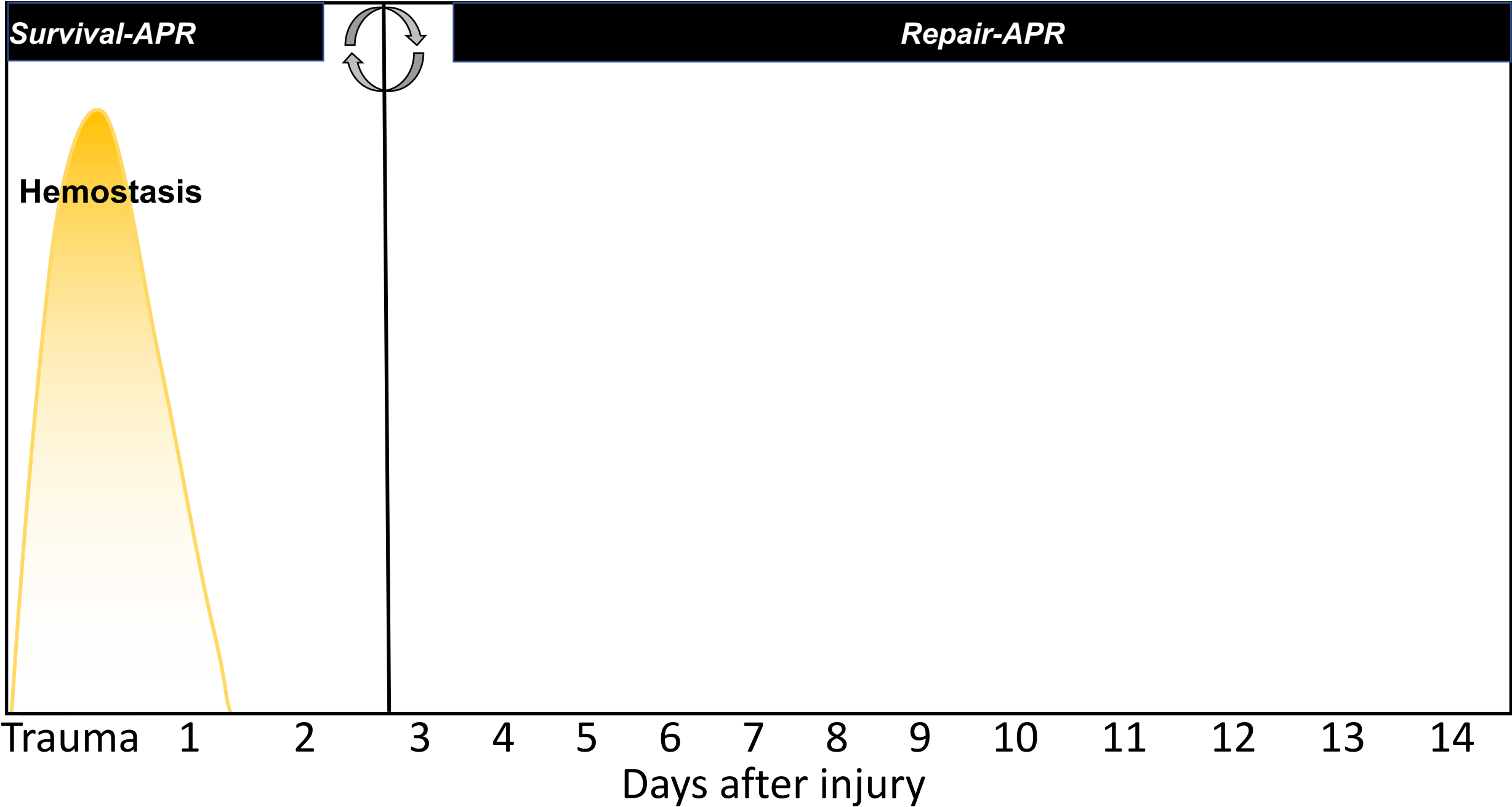
TEMPORARY SEALANT

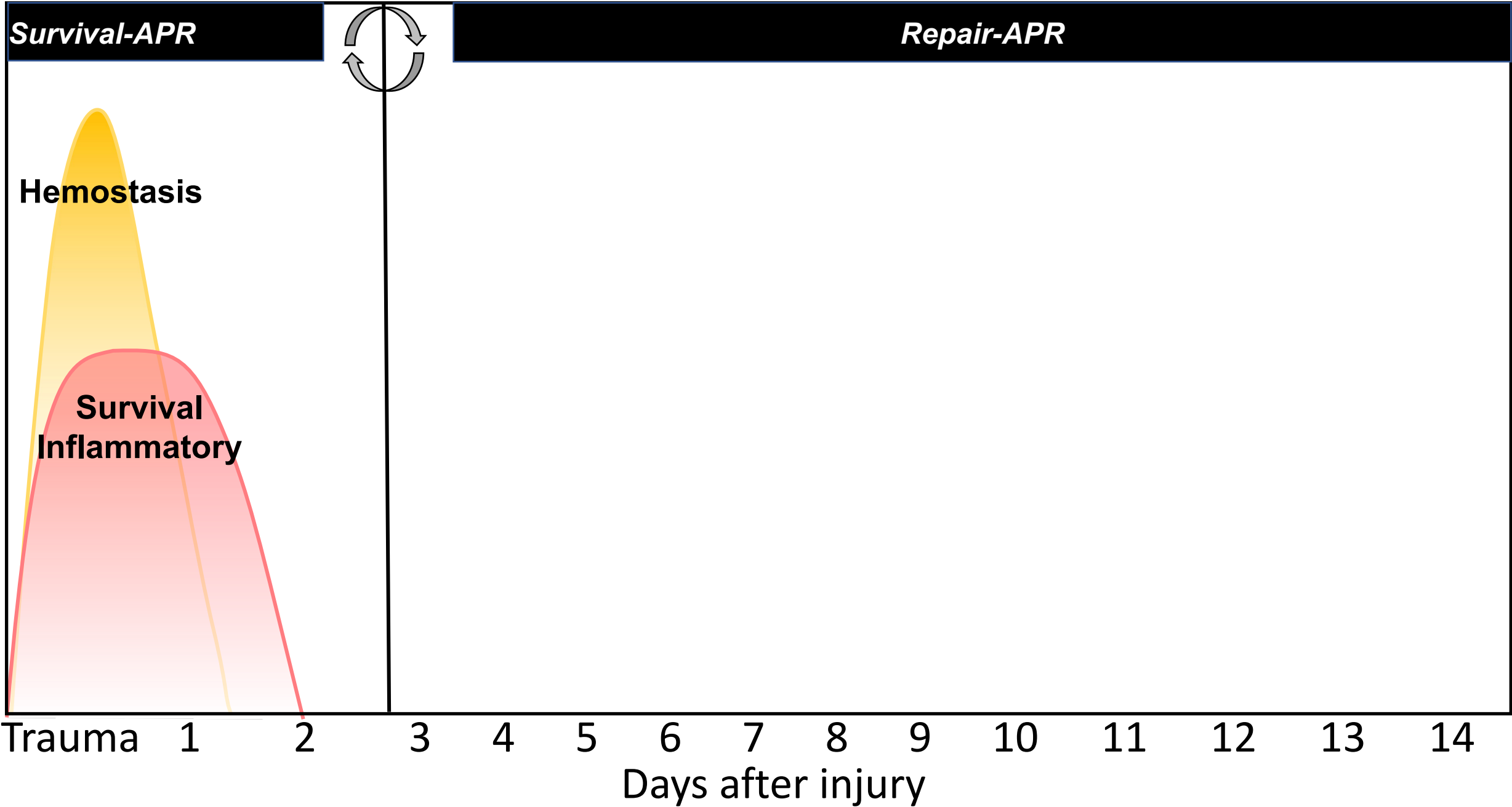
2

Hemostasis
Inflammation
Bleeding

SURVIVE

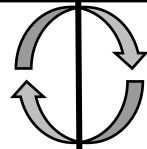
Hemostasis
Inflammation
Infection





Survival-APR

Repair-APR



Hemostasis

**Survival
Inflammatory**

Trauma

1

2

3

4

5

6

7

8

9

10

11

12

13

14

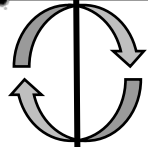
Days after injury

Survival

Repair-APR

Hemostasis

**Survival
Inflammation**



Trauma

1

2

3

4

5

6

7

8

9

10

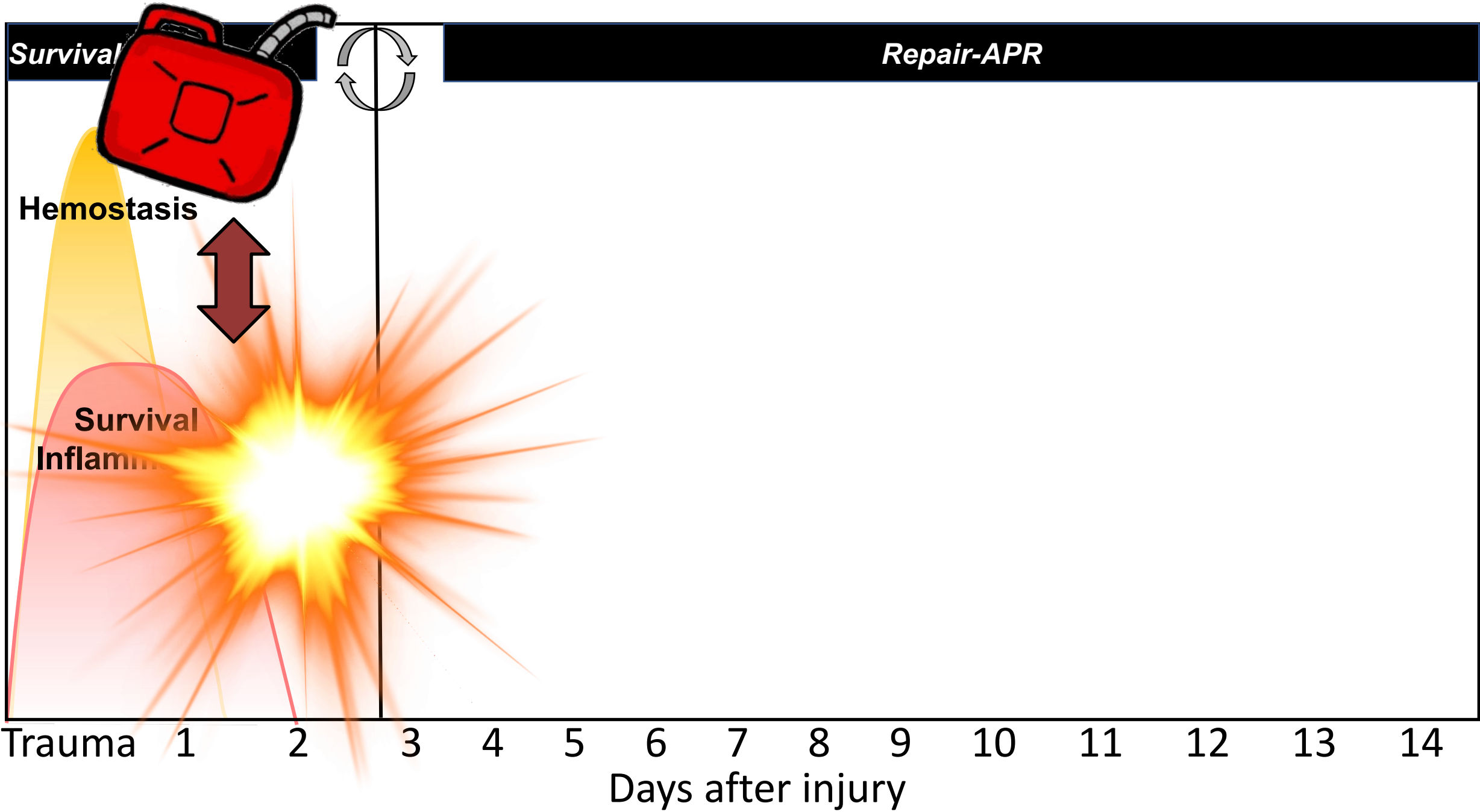
11

12

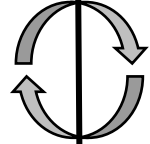
13

14

Days after injury



Survival-APR

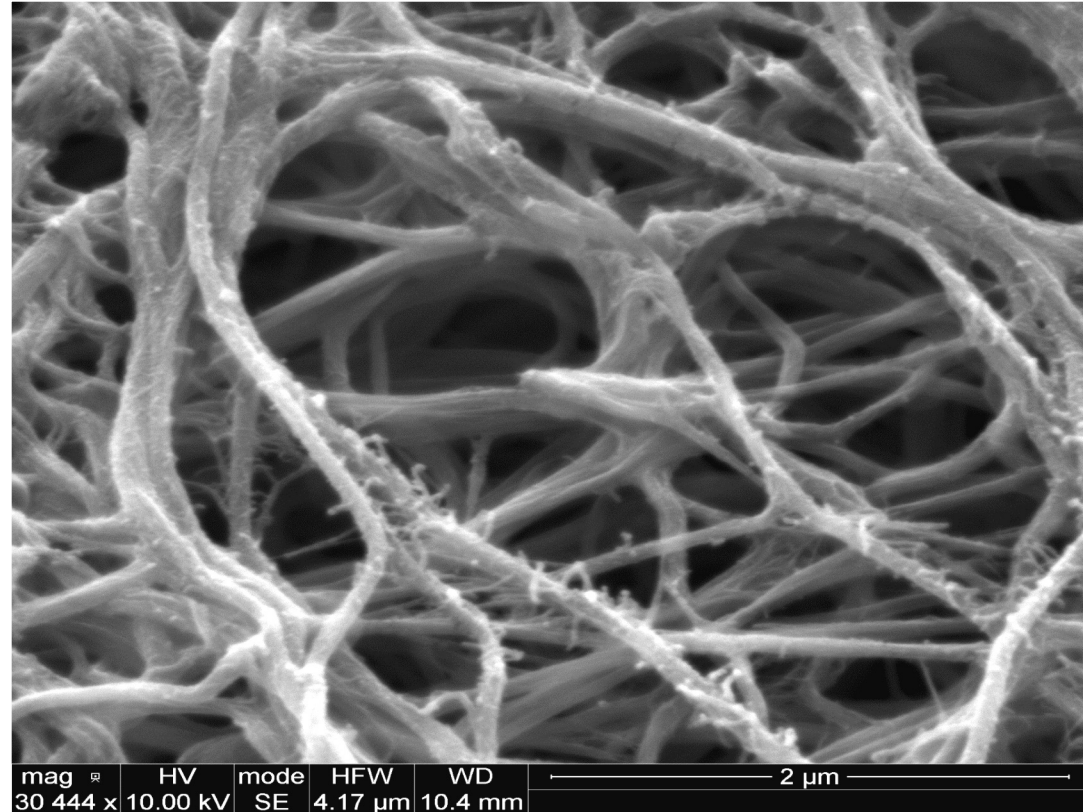


Repair-APR

Hemostasis

**FIBRIN & DNANets
CONTAINMENT**

**Survival
Inflammatory**



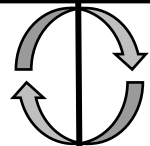
mag	HV	mode	HFW	WD
30 444 x	10.00 kV	SE	4.17 μm	10.4 mm

2 μm

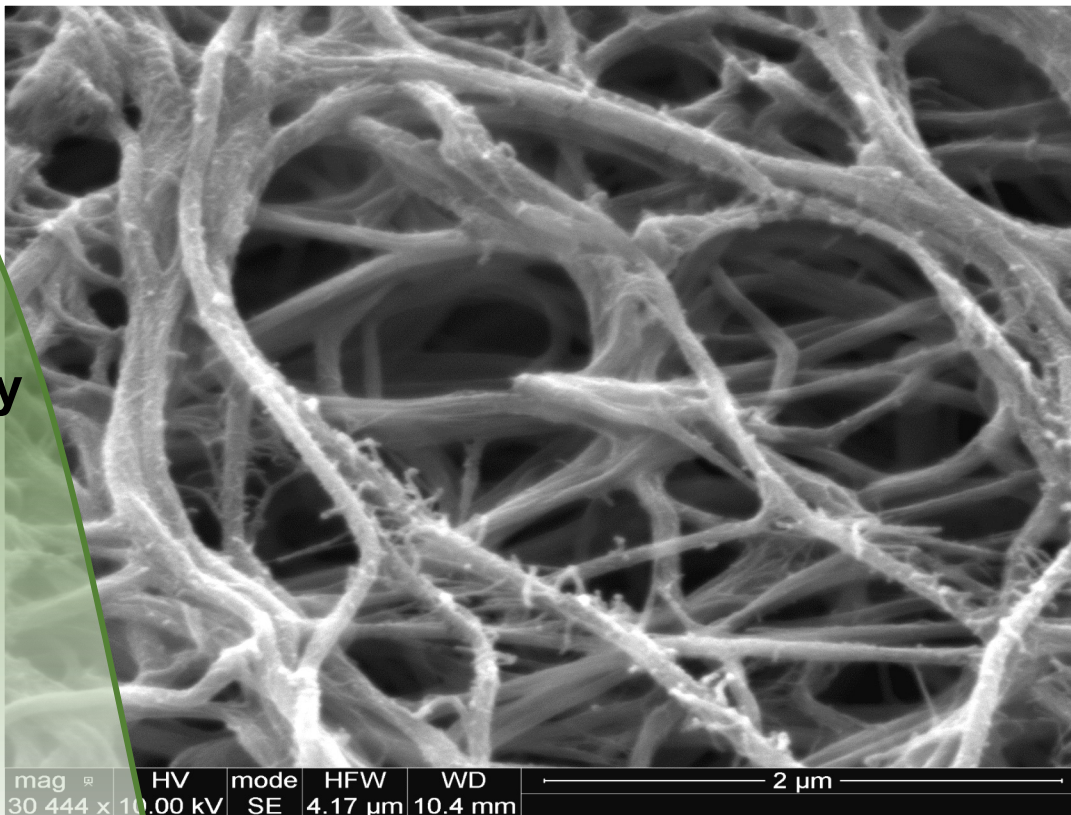
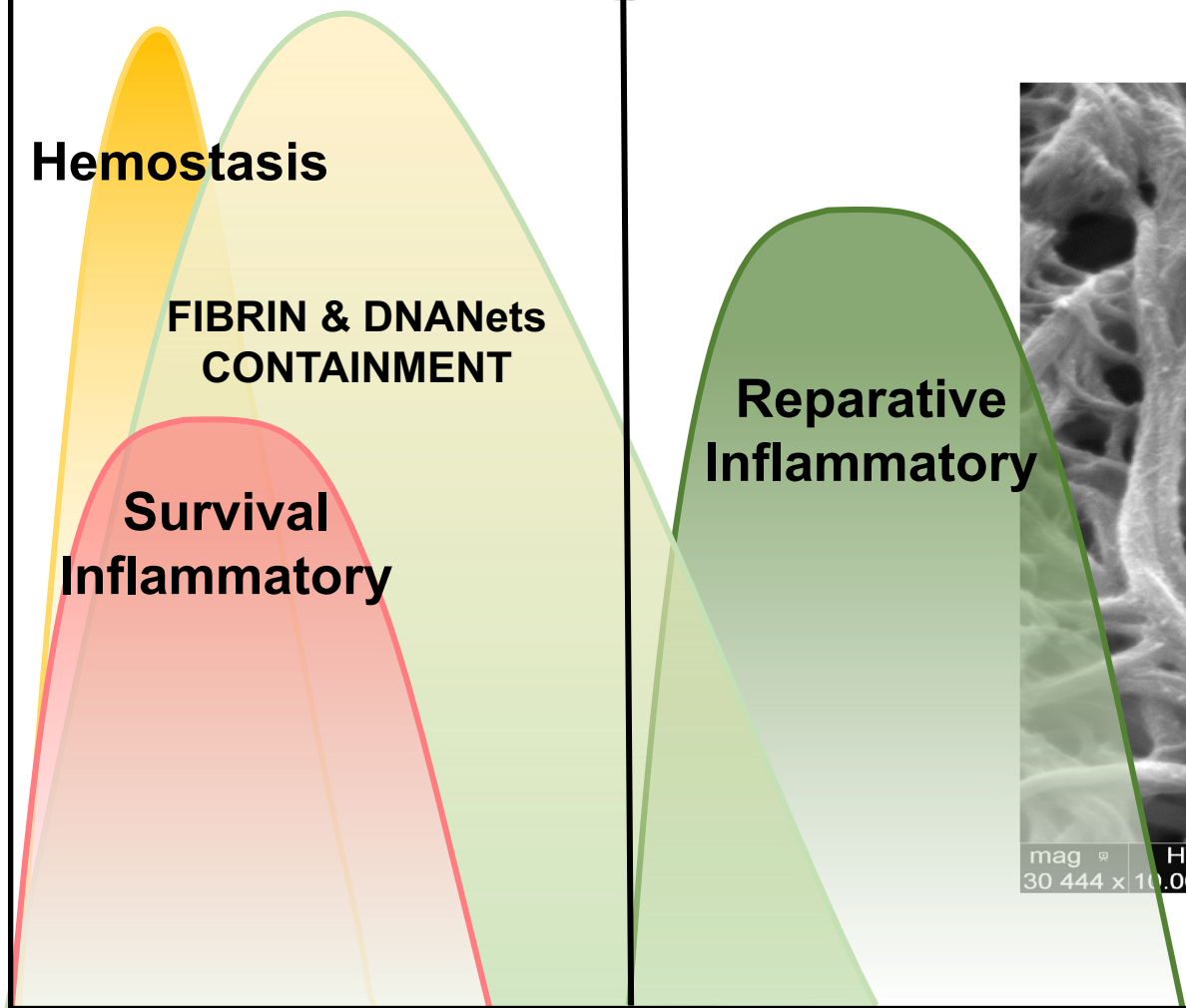
Trauma 1 2 3 4 5 6 7 8 9 10 11 12 13 14

Days after injury

Survival-APR



Repair-APR

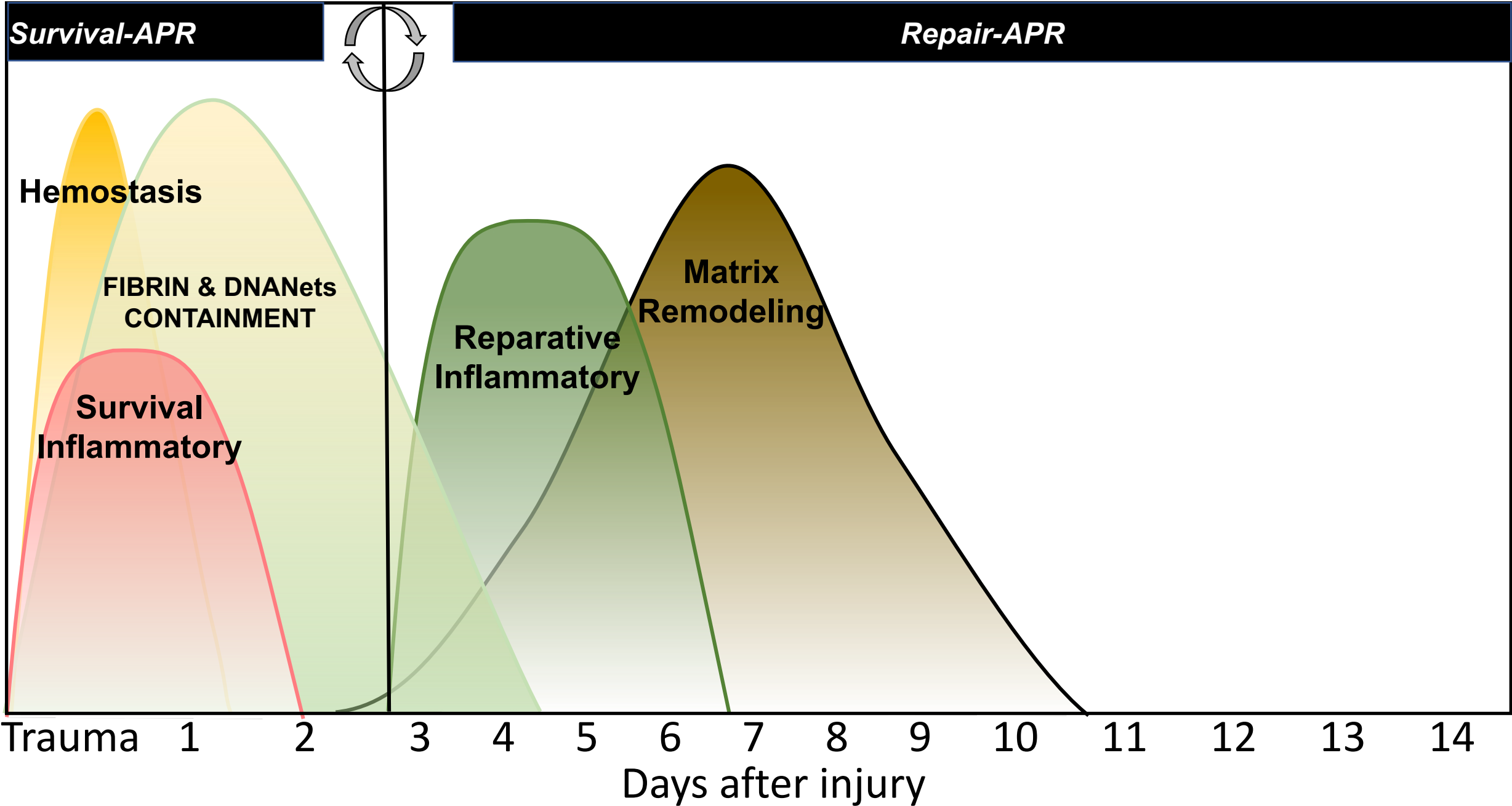


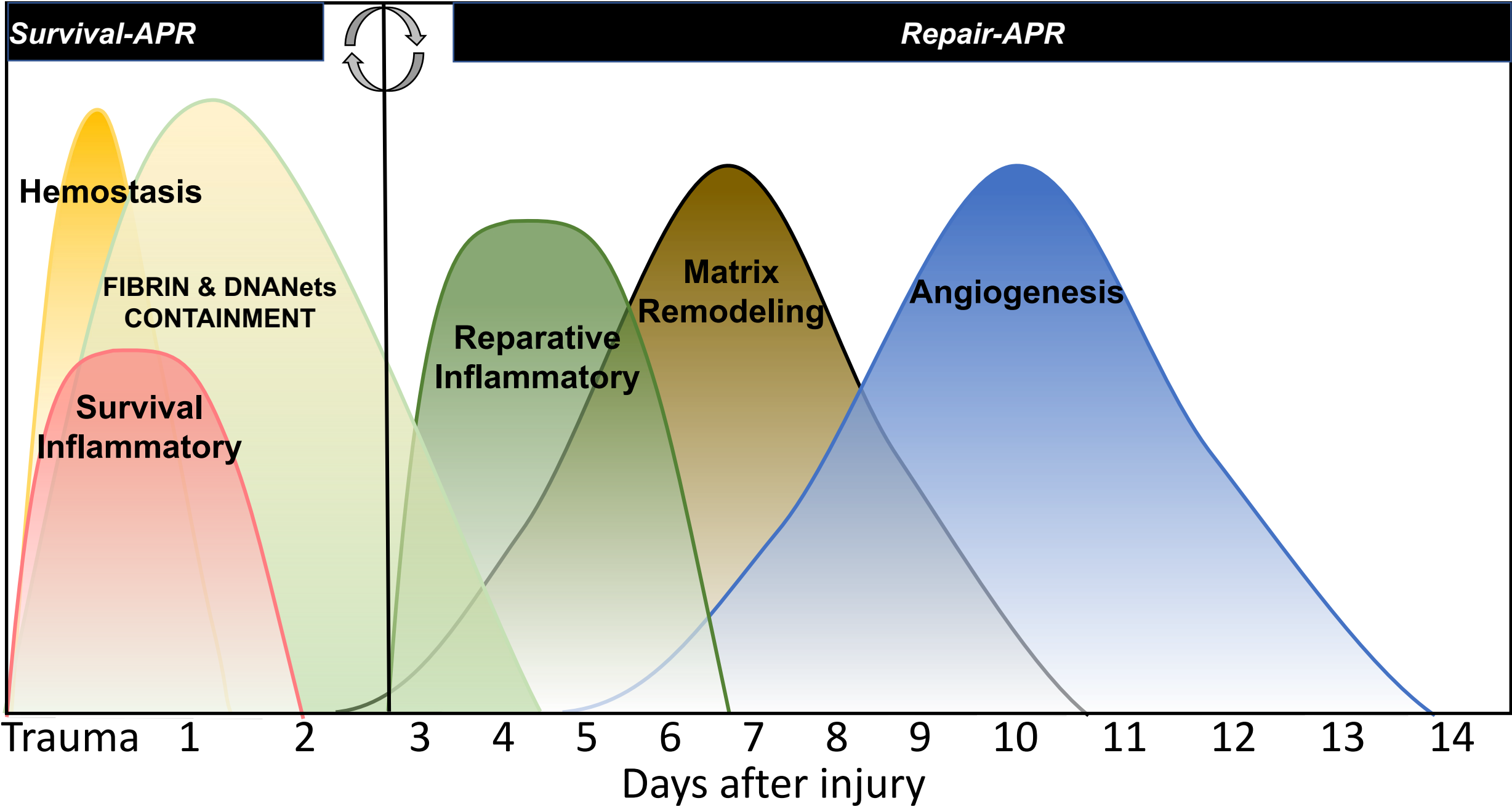
mag	HV	mode	HFW	WD
30 444 x	10.00 kV	SE	4.17 μm	10.4 mm

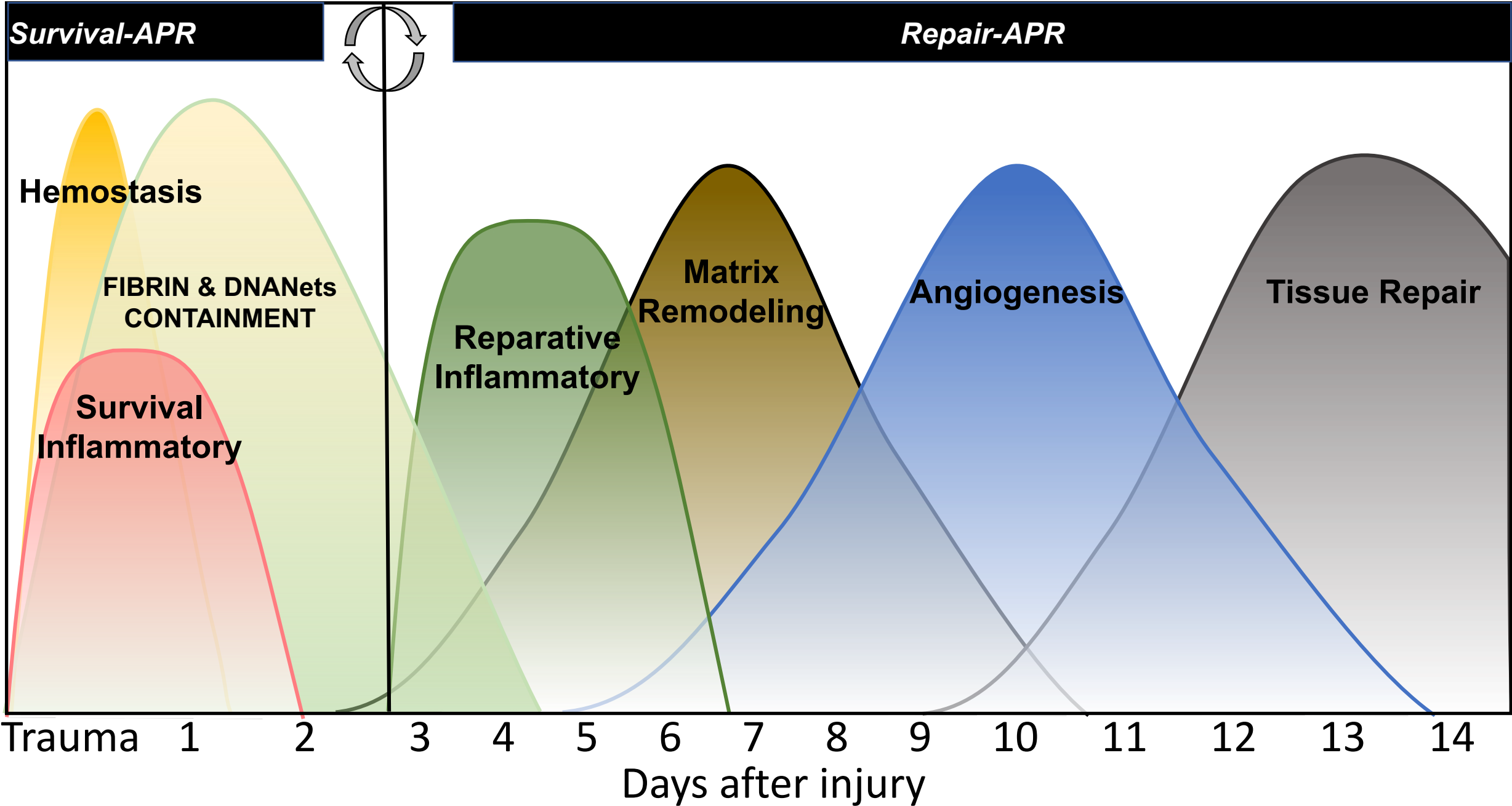
2 μm

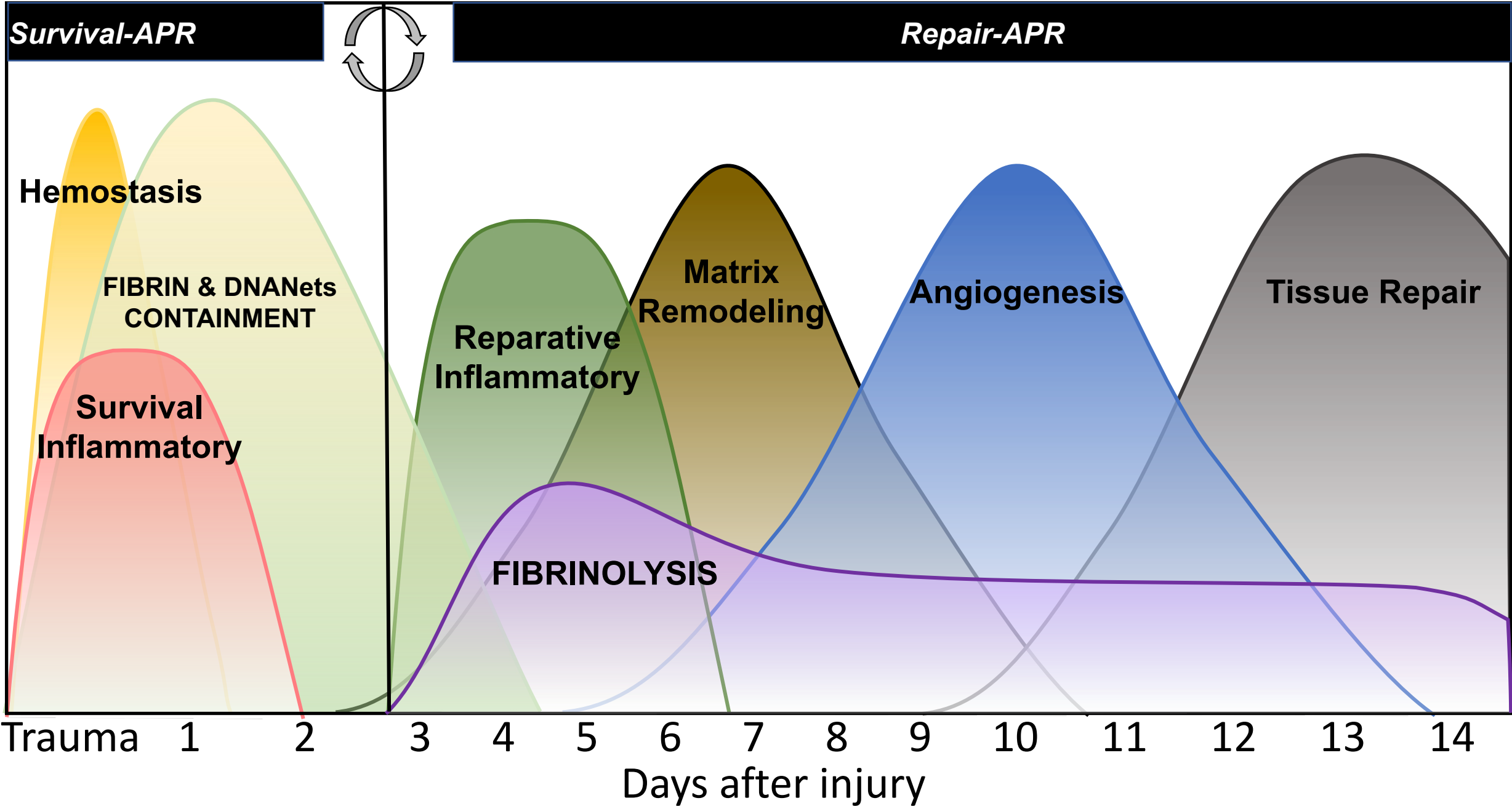
Trauma 1 2 3 4 5 6 7 8 9 10 11 12 13 14

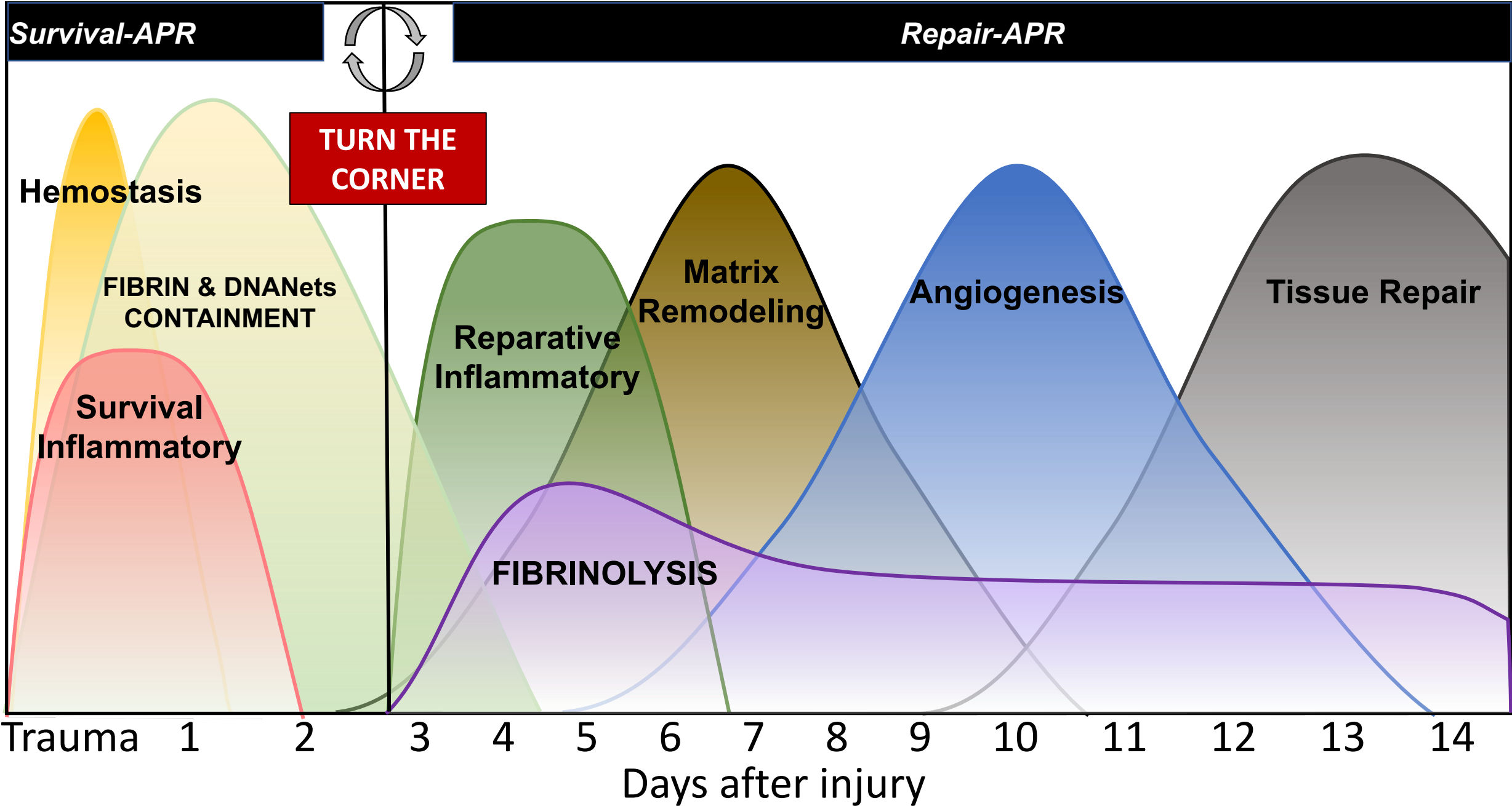
Days after injury

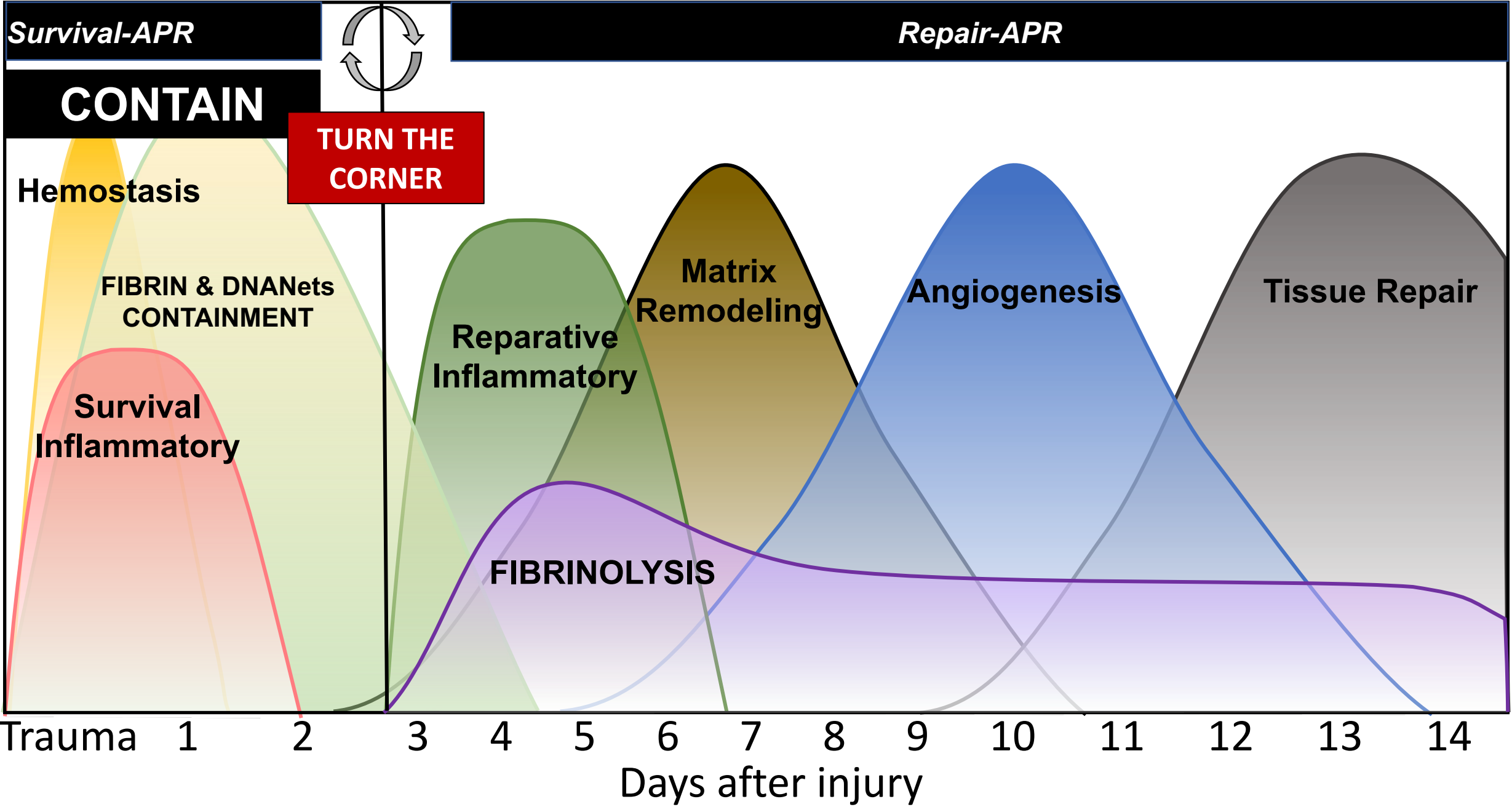




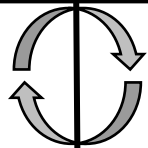








Survival-APR



Repair-APR

CONTAIN

RESTORE FUNCTION

**TURN THE
CORNER**

Hemostasis

**FIBRIN & DNANets
CONTAINMENT**

**Survival
Inflammatory**

**Reparative
Inflammatory**

**Matrix
Remodeling**

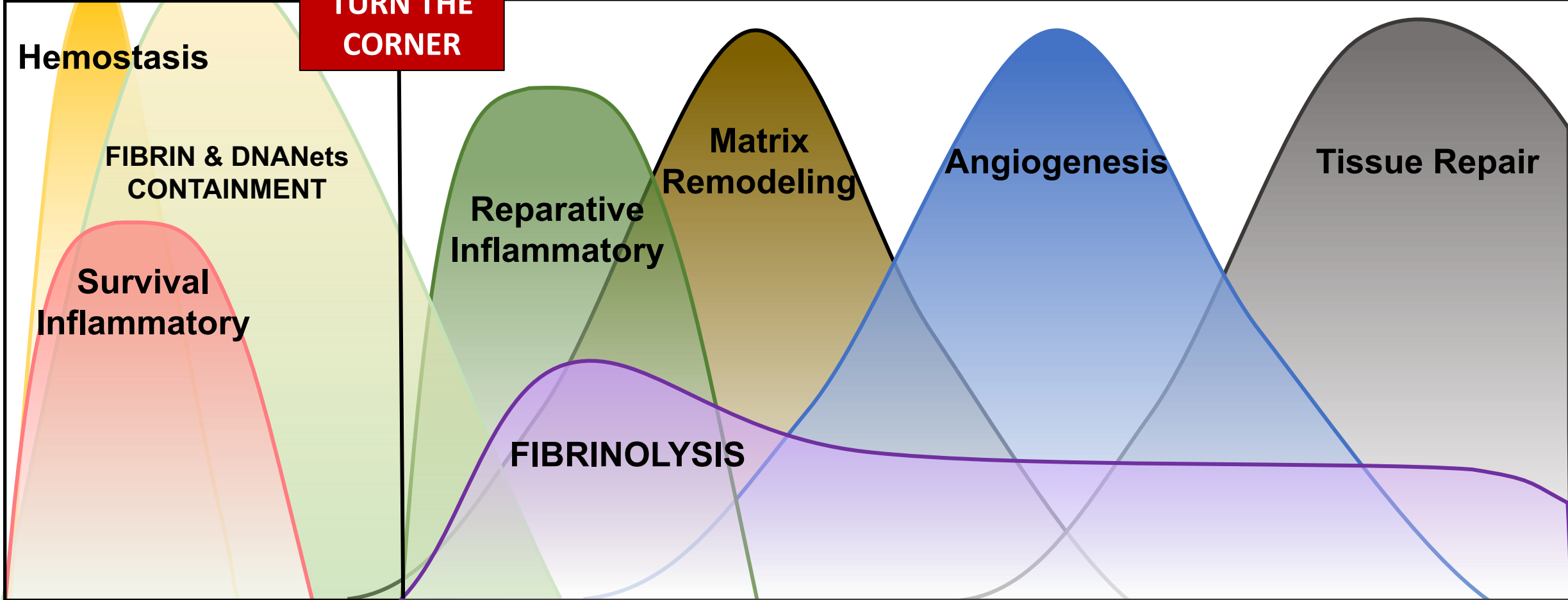
Angiogenesis

Tissue Repair

FIBRINOLYSIS

Trauma 1 2 3 4 5 6 7 8 9 10 11 12 13 14

Days after injury



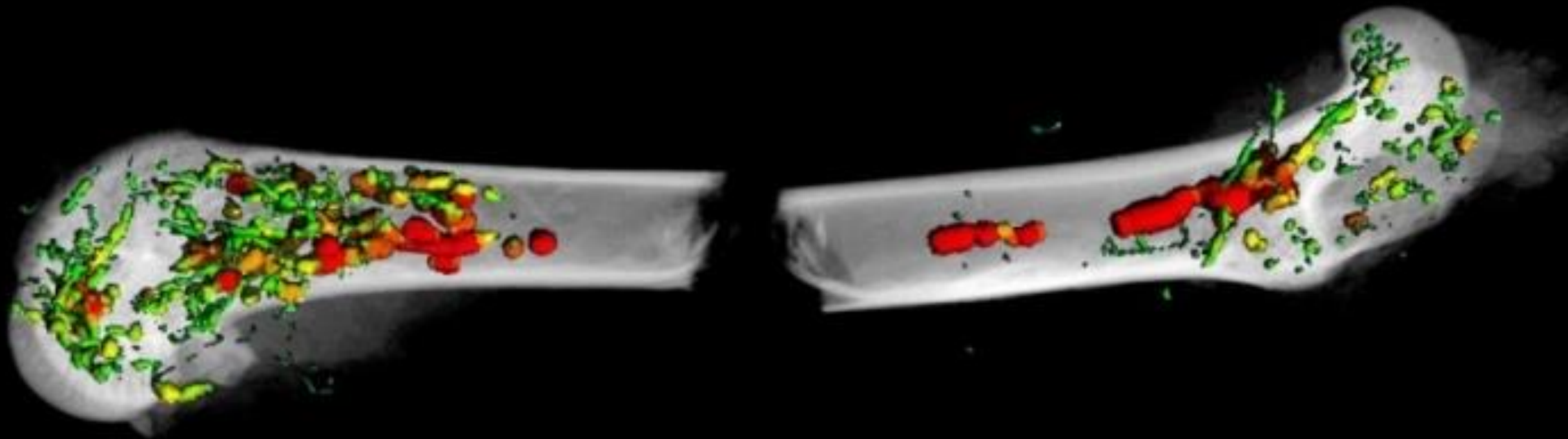
Musculoskeletal Infection

Musculoskeletal Infection

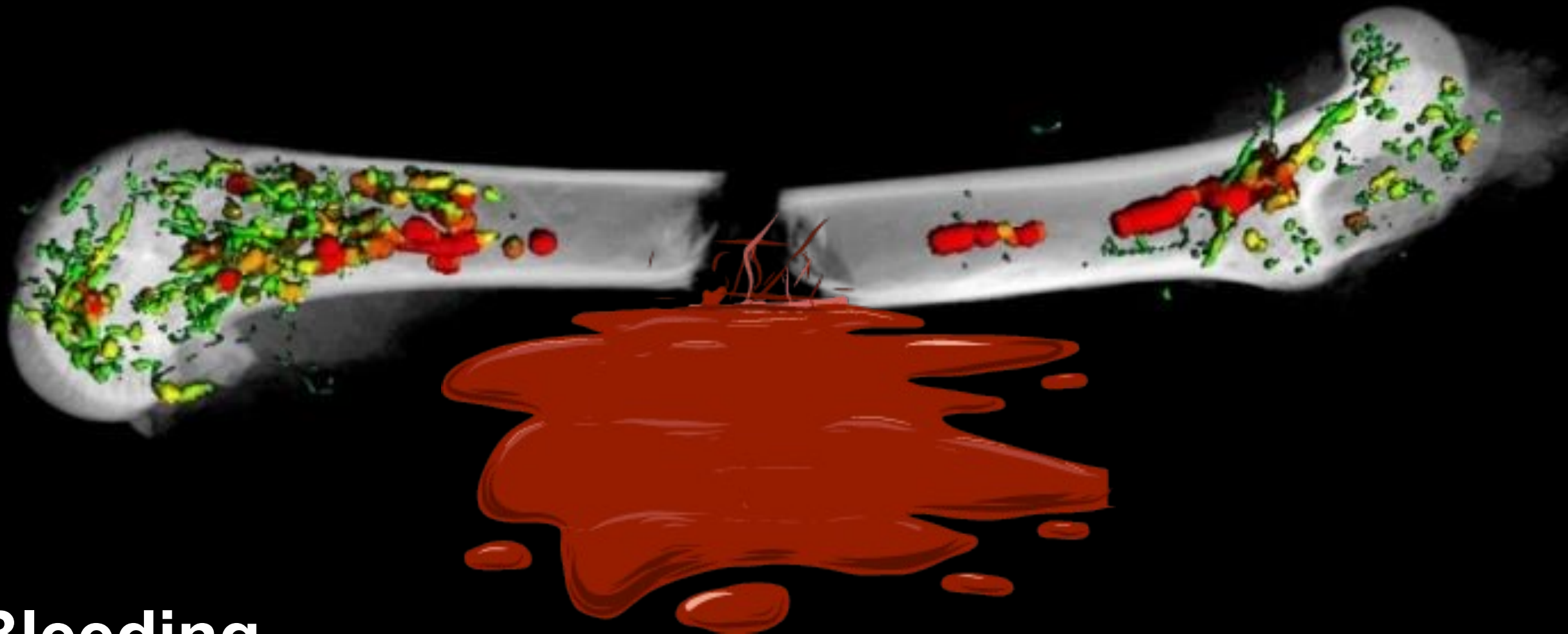
Why Injured Tissue?



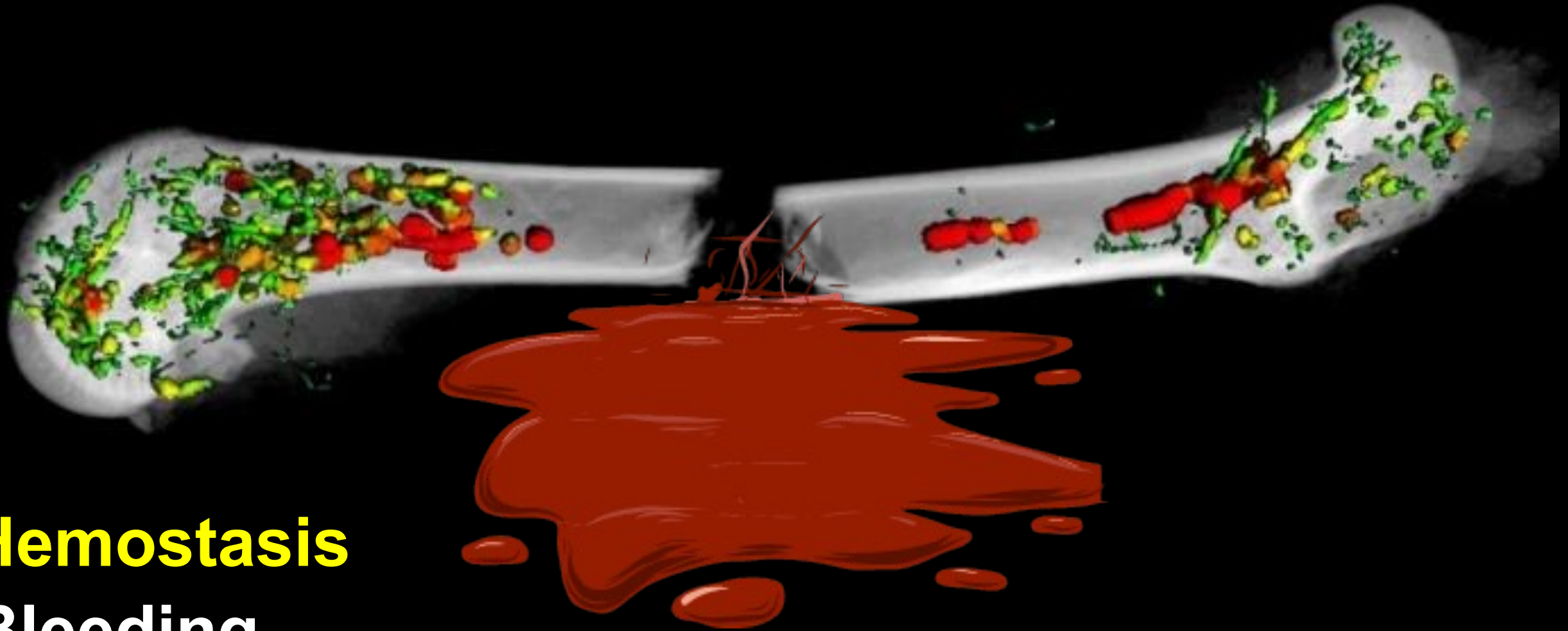
FRACTURE



FRACTURE



Bleeding

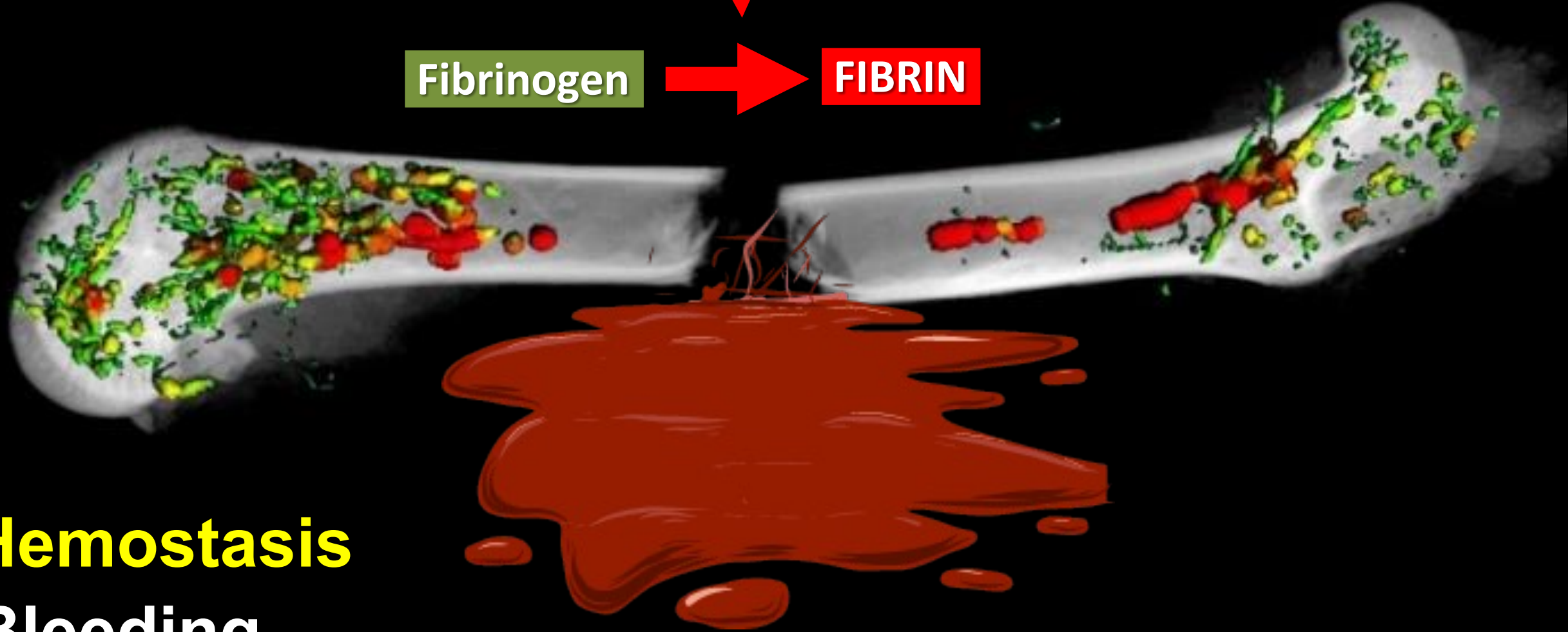


Hemostasis
Bleeding

Procoagulants

Fibrinogen

FIBRIN

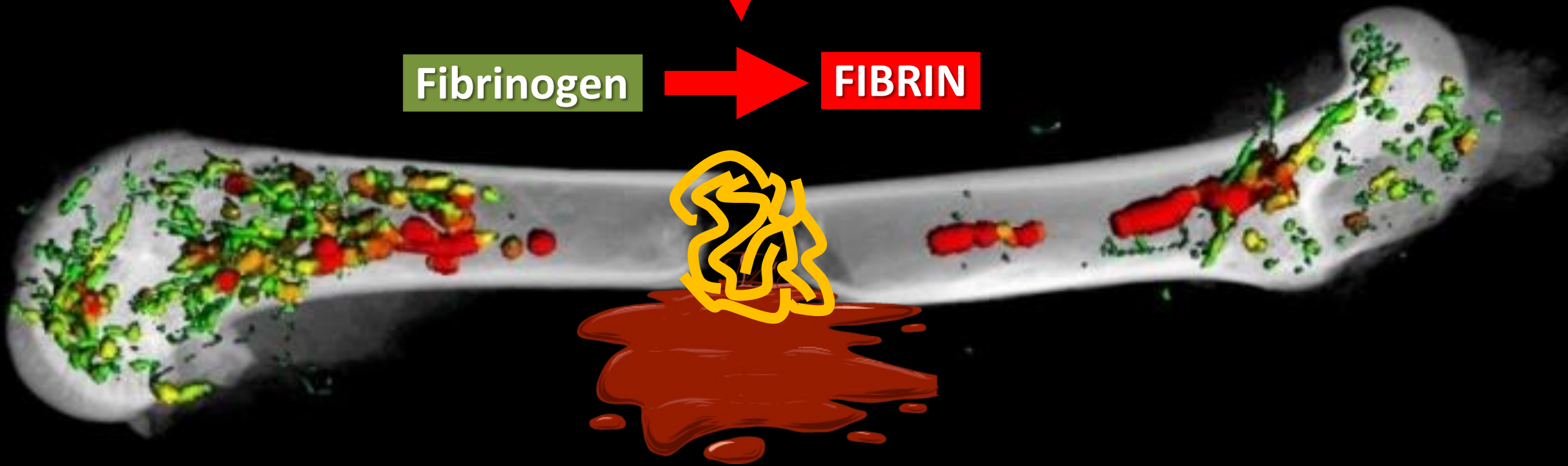


Hemostasis
Bleeding

Procoagulants

Fibrinogen

FIBRIN

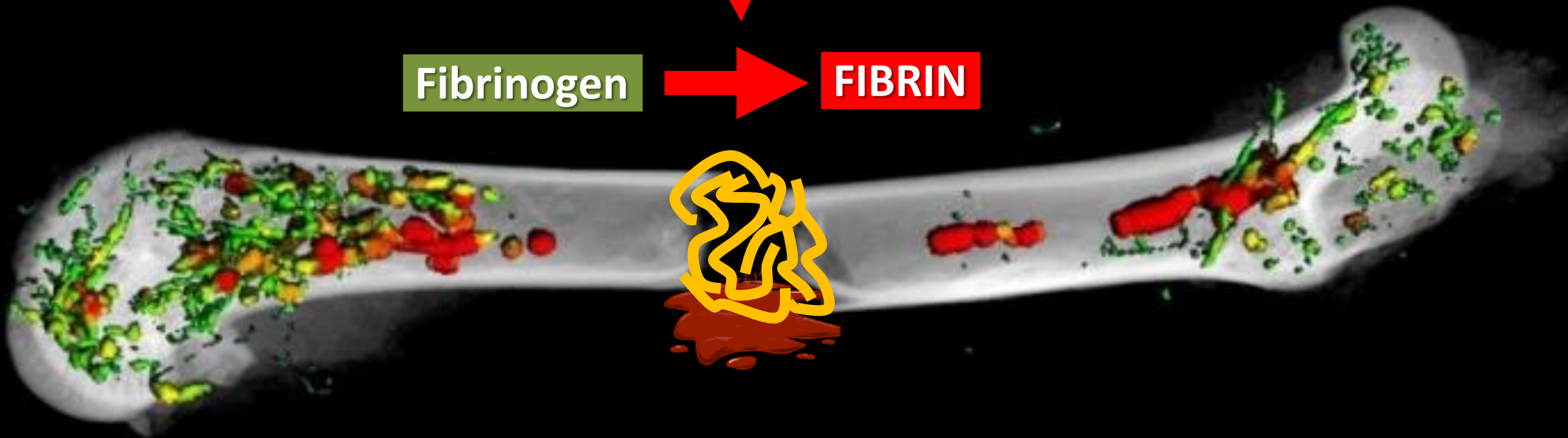


Hemostasis
Bleeding

Procoagulants

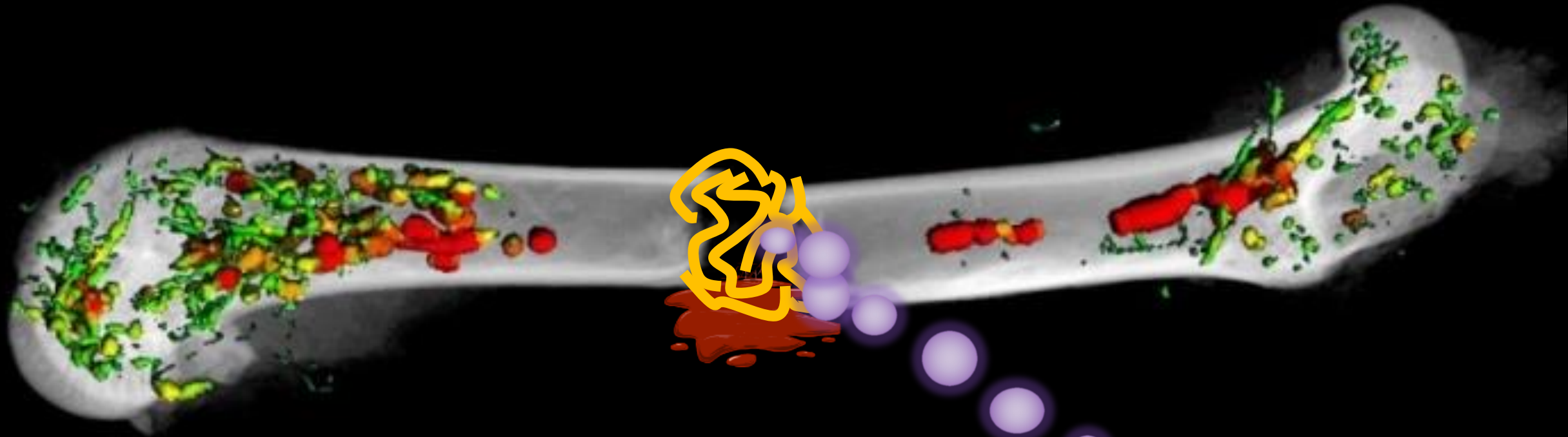
Fibrinogen

FIBRIN



Hemostasis
Bleeding

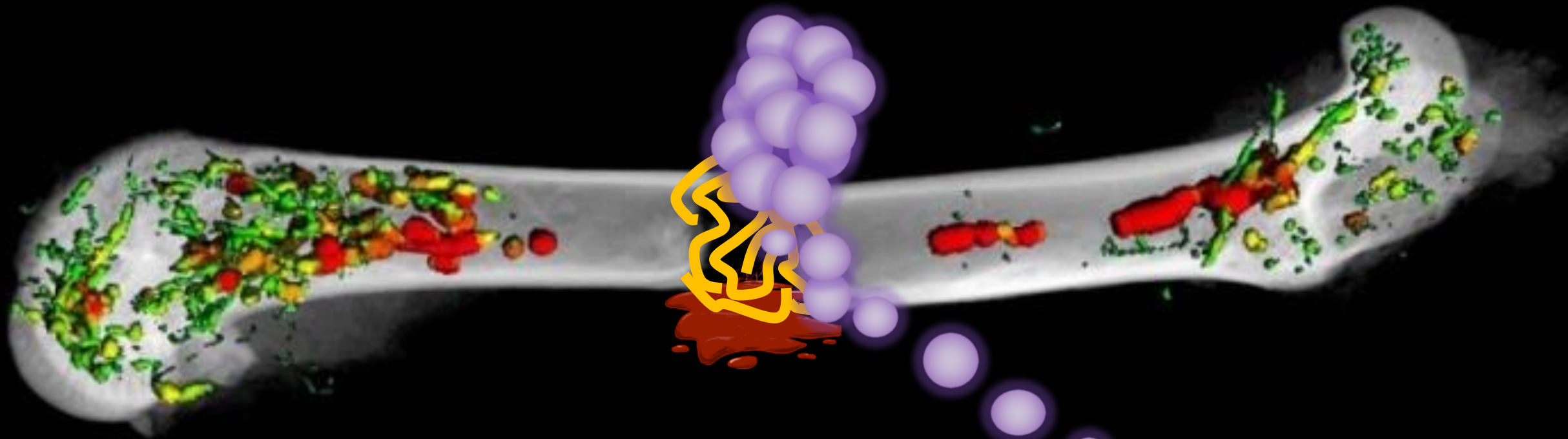
COMPARTMENTALIZATION



Hemostasis

Bleeding

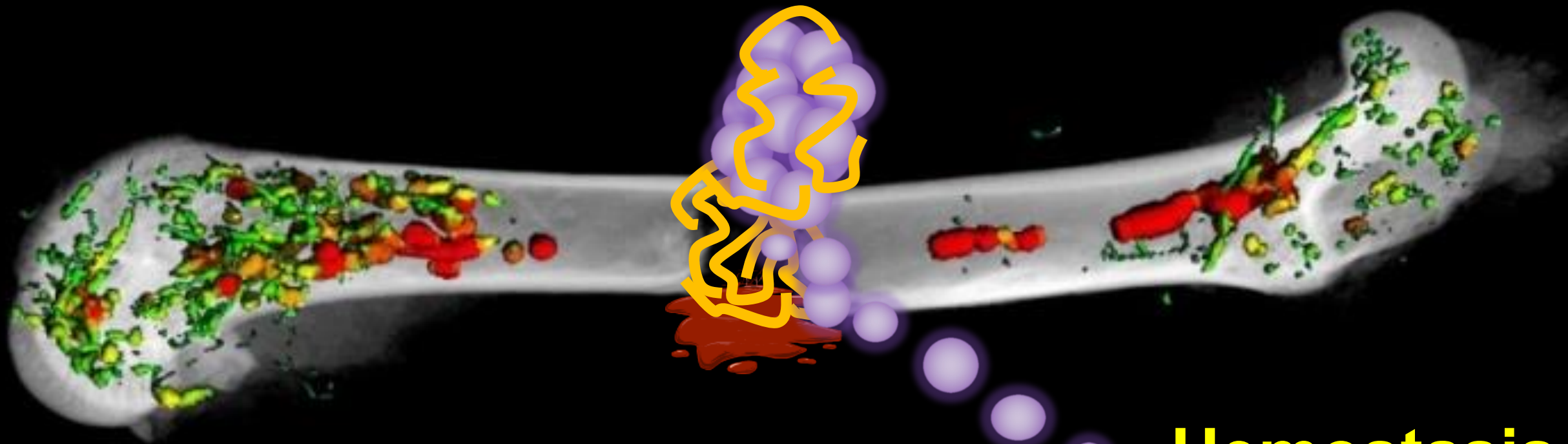
Infection



Hemostasis

Bleeding

Infection

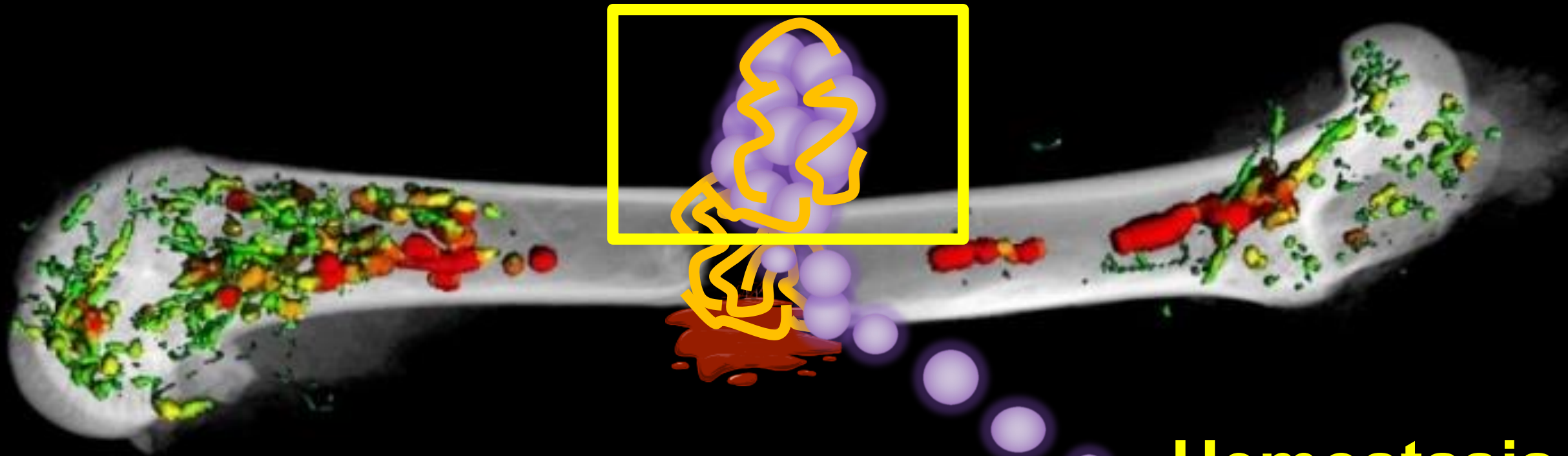


Hemostasis

Hemostasis

Bleeding

Infection

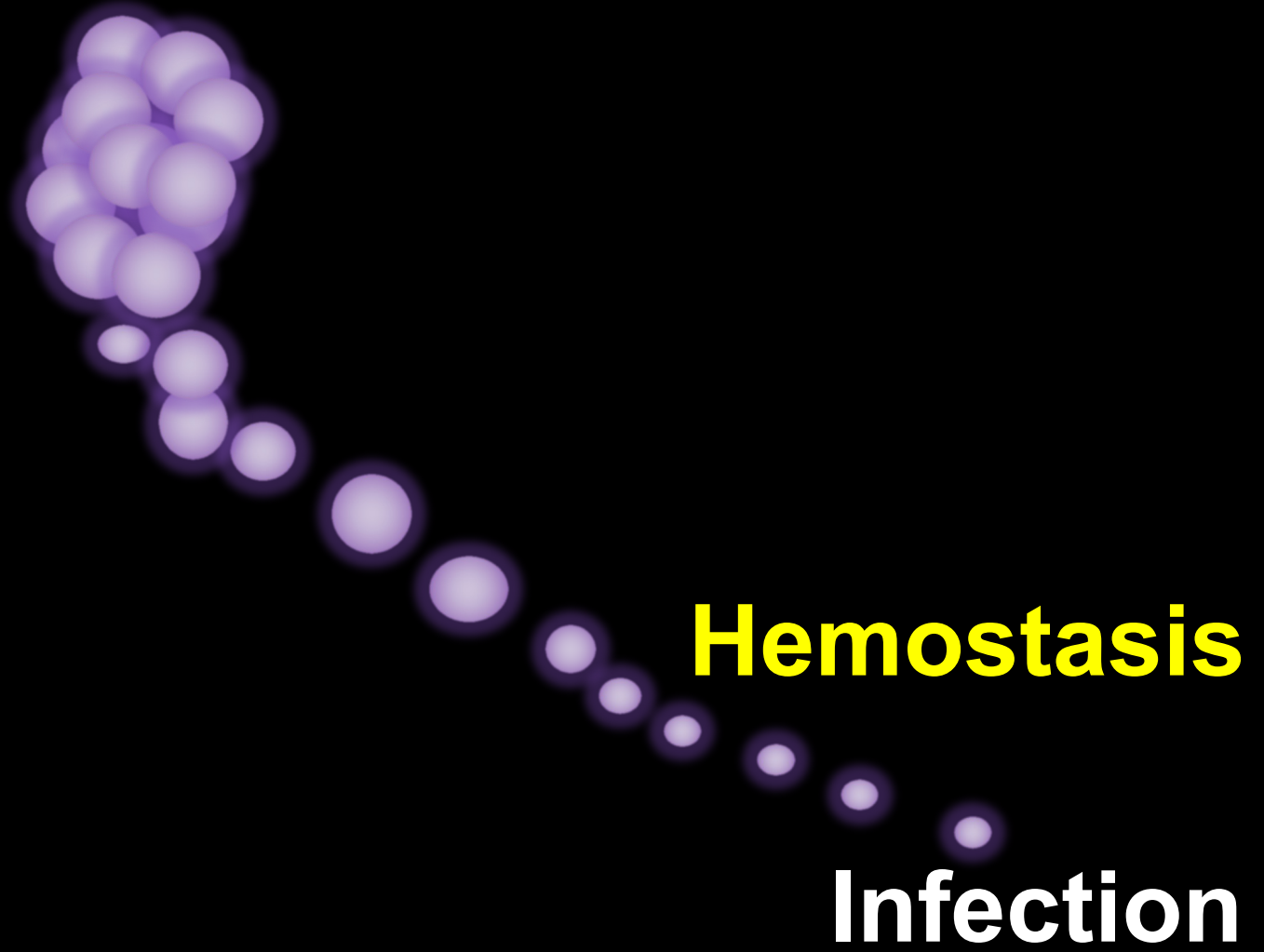


Hemostasis

Hemostasis

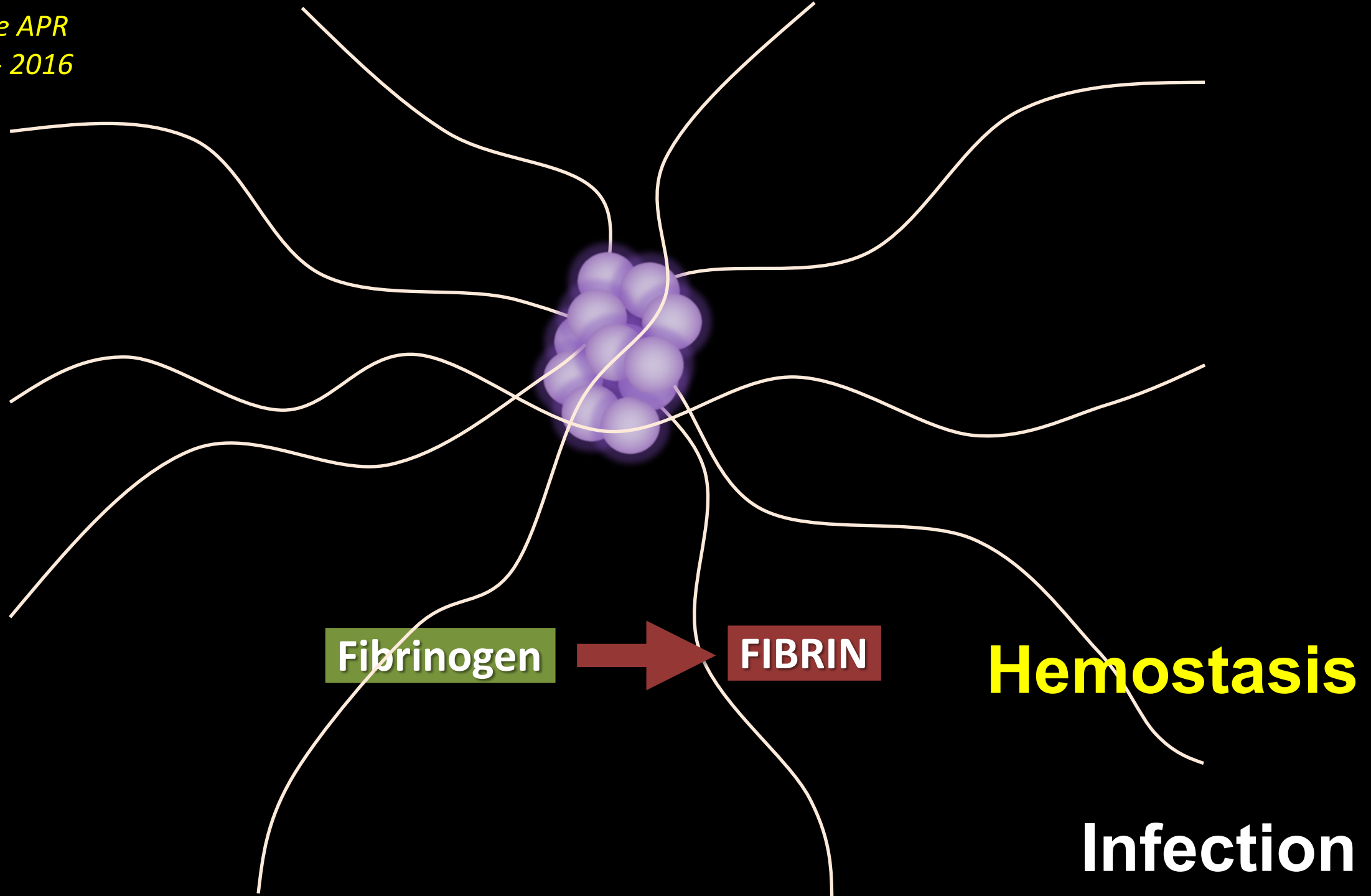
Bleeding

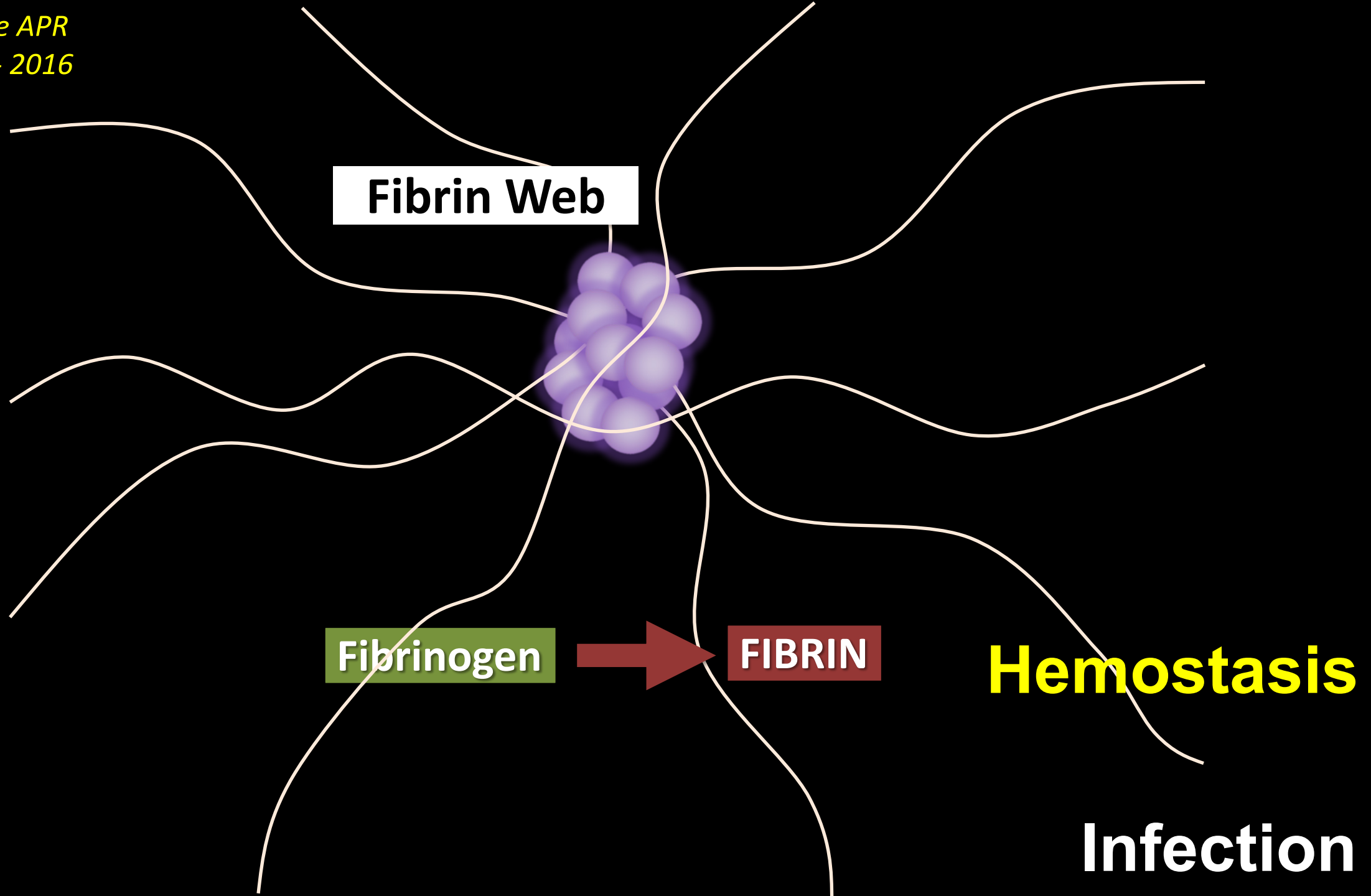
Infection




Hemostasis
Bleeding

Infection

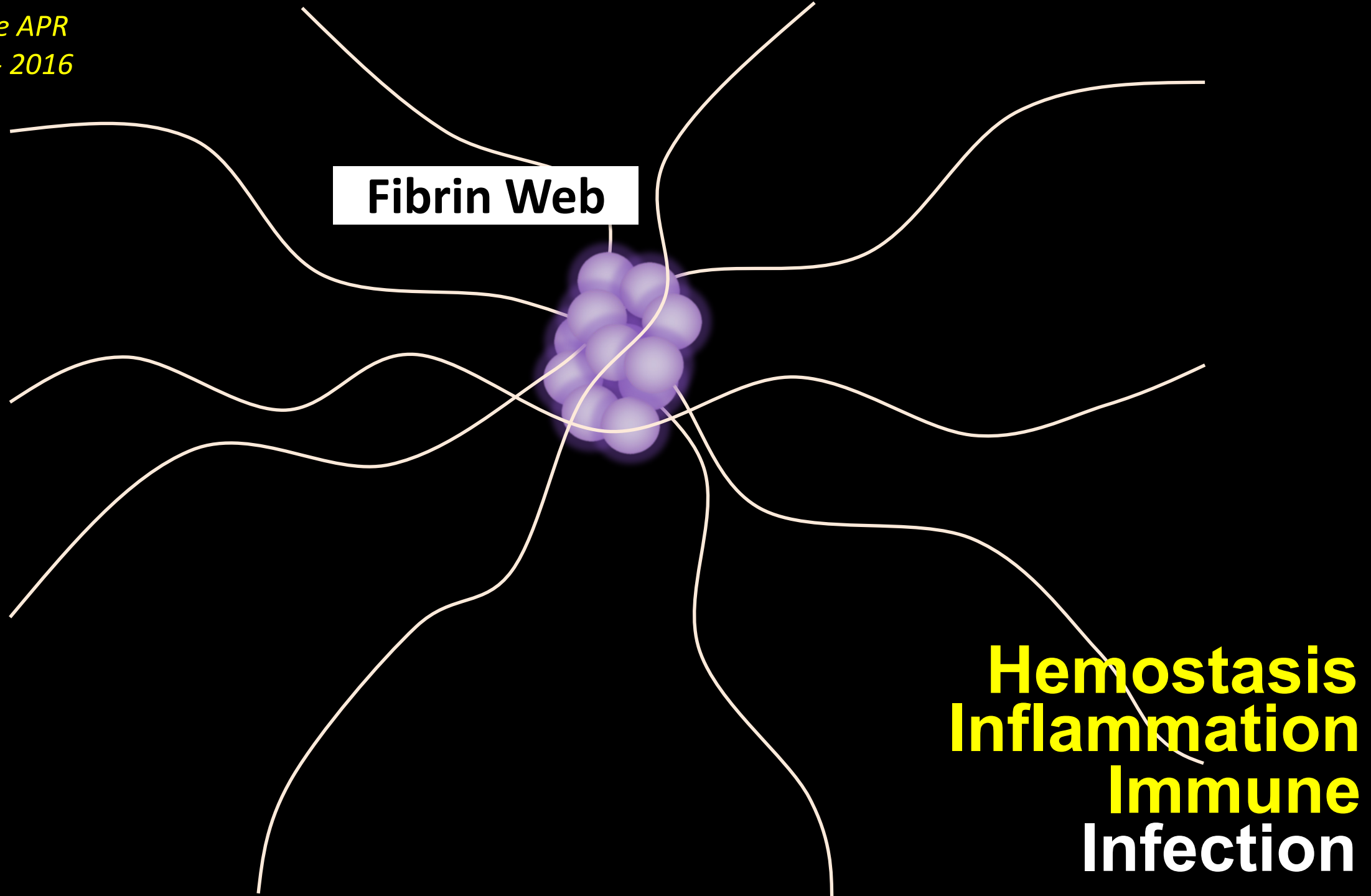






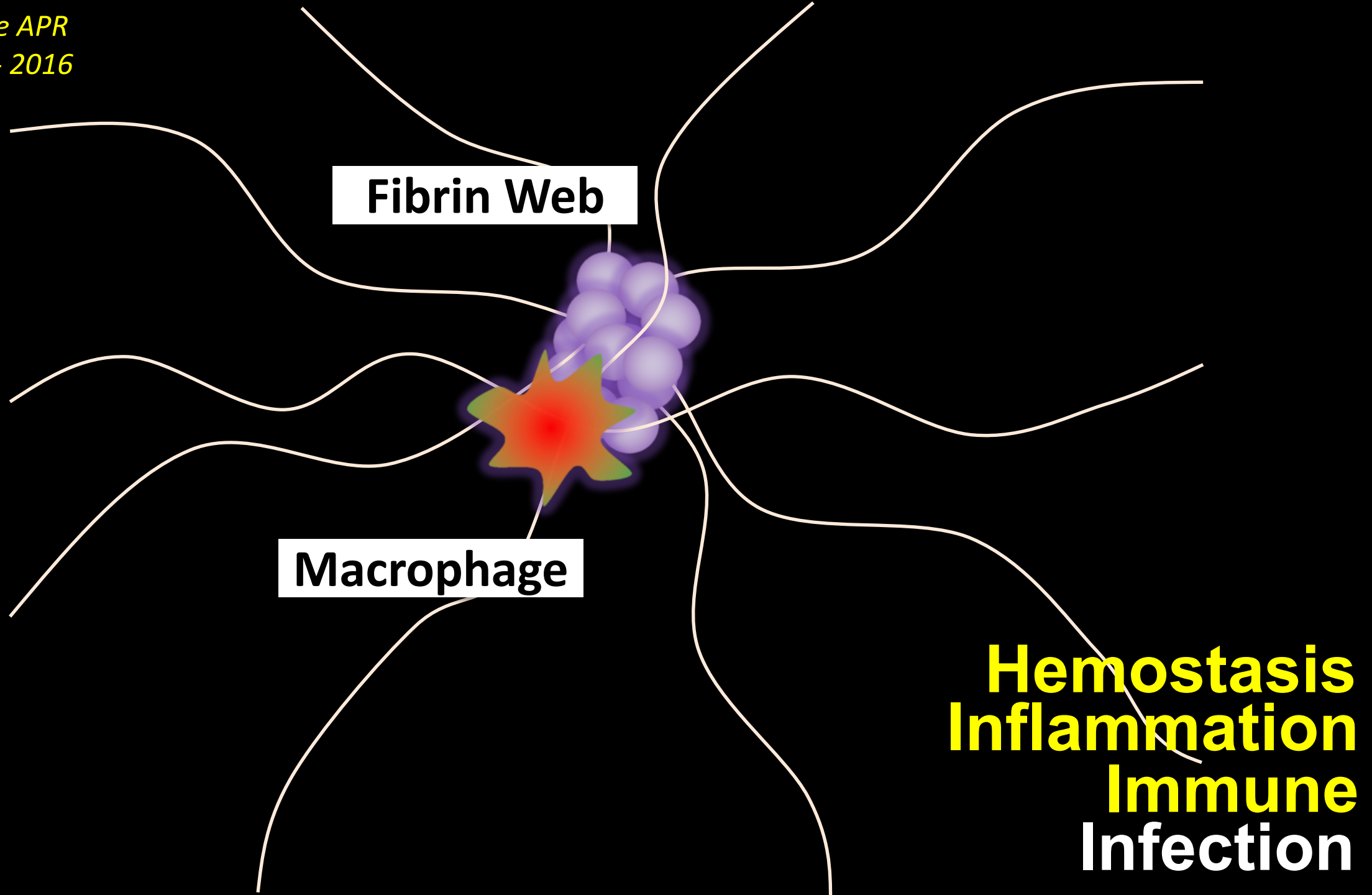
Hemostasis

Infection



Fibrin Web

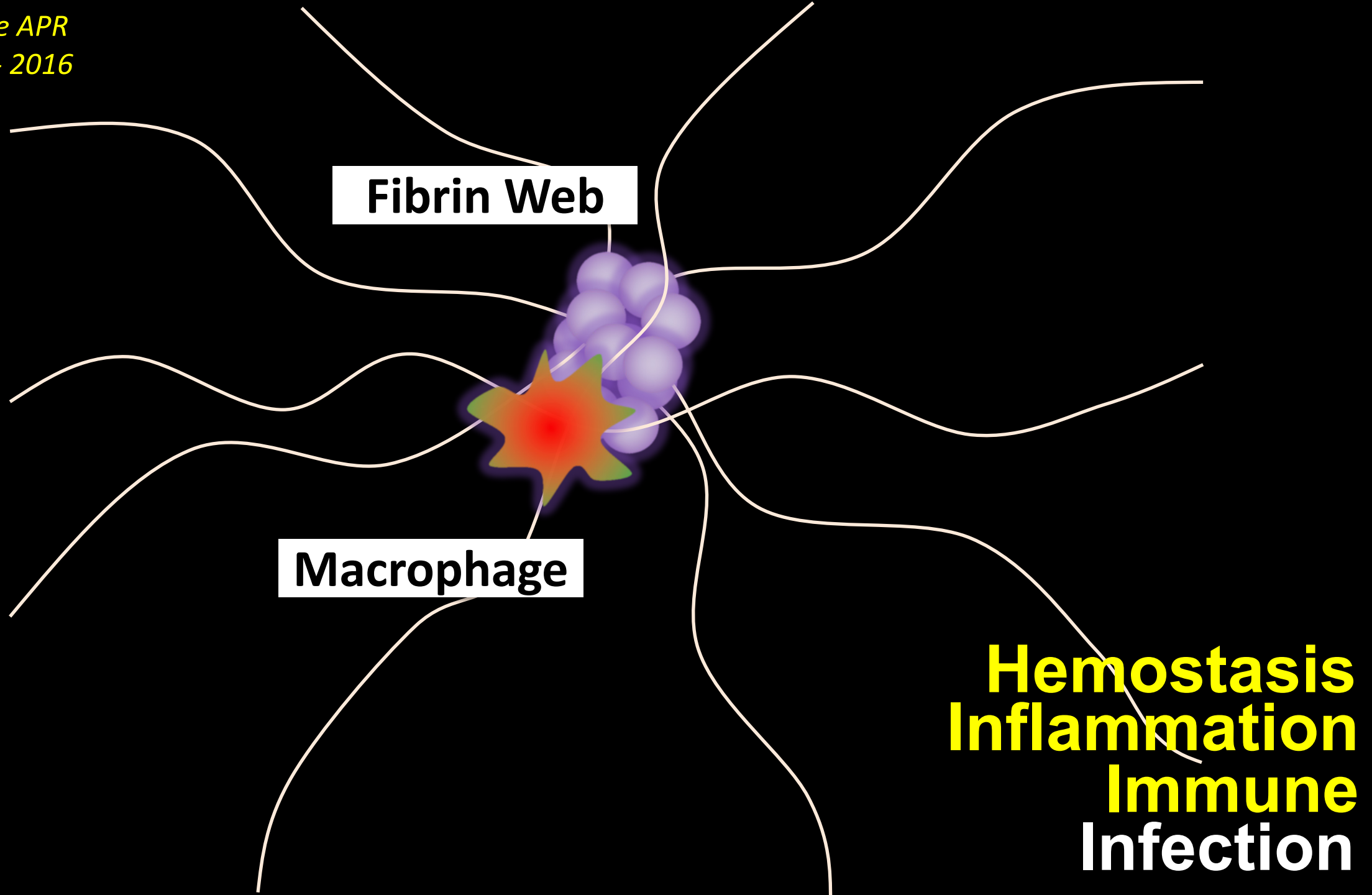
Hemostasis
Inflammation
Immune
Infection



Fibrin Web

Macrophage

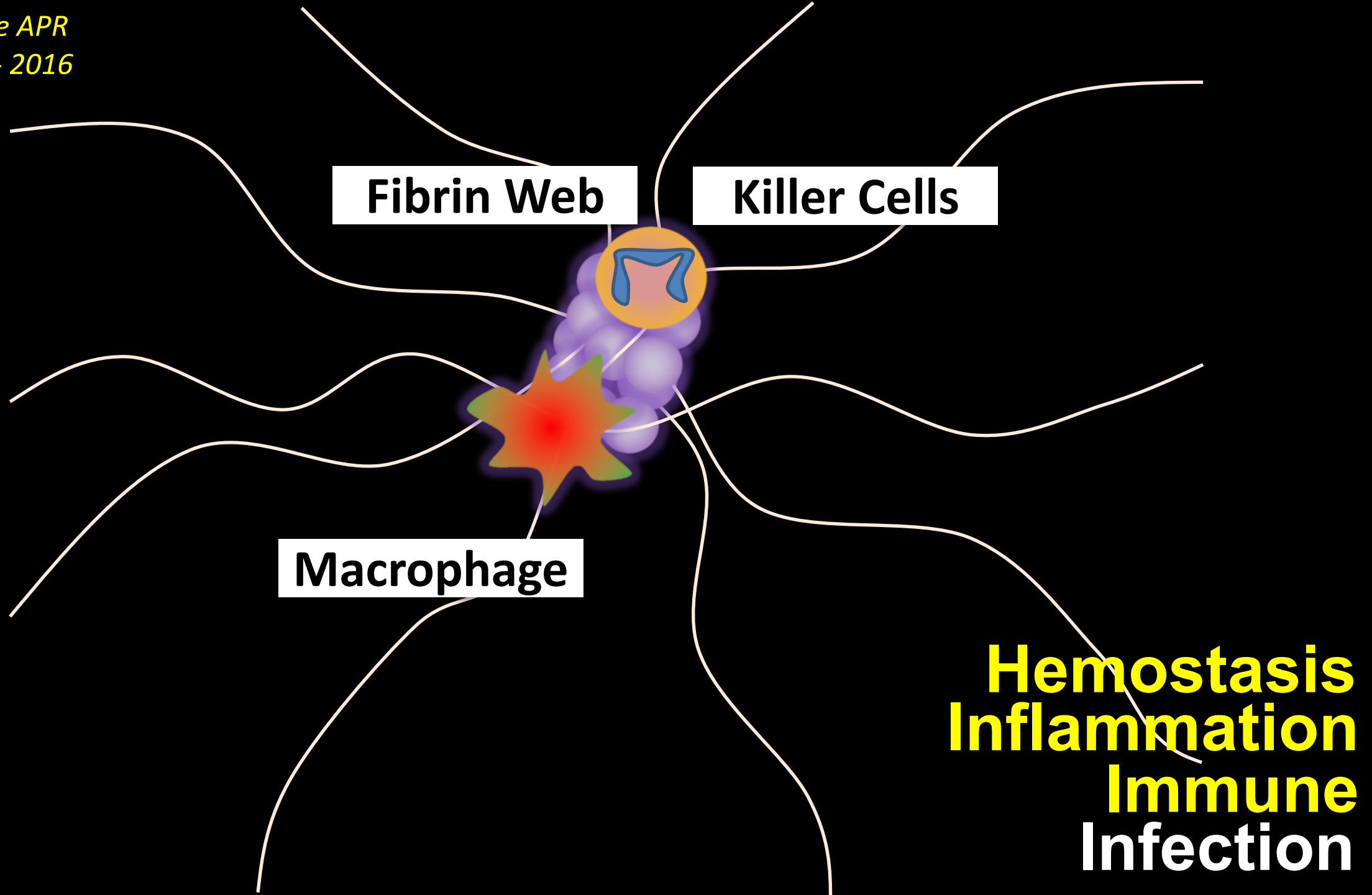
Hemostasis
Inflammation
Immune
Infection

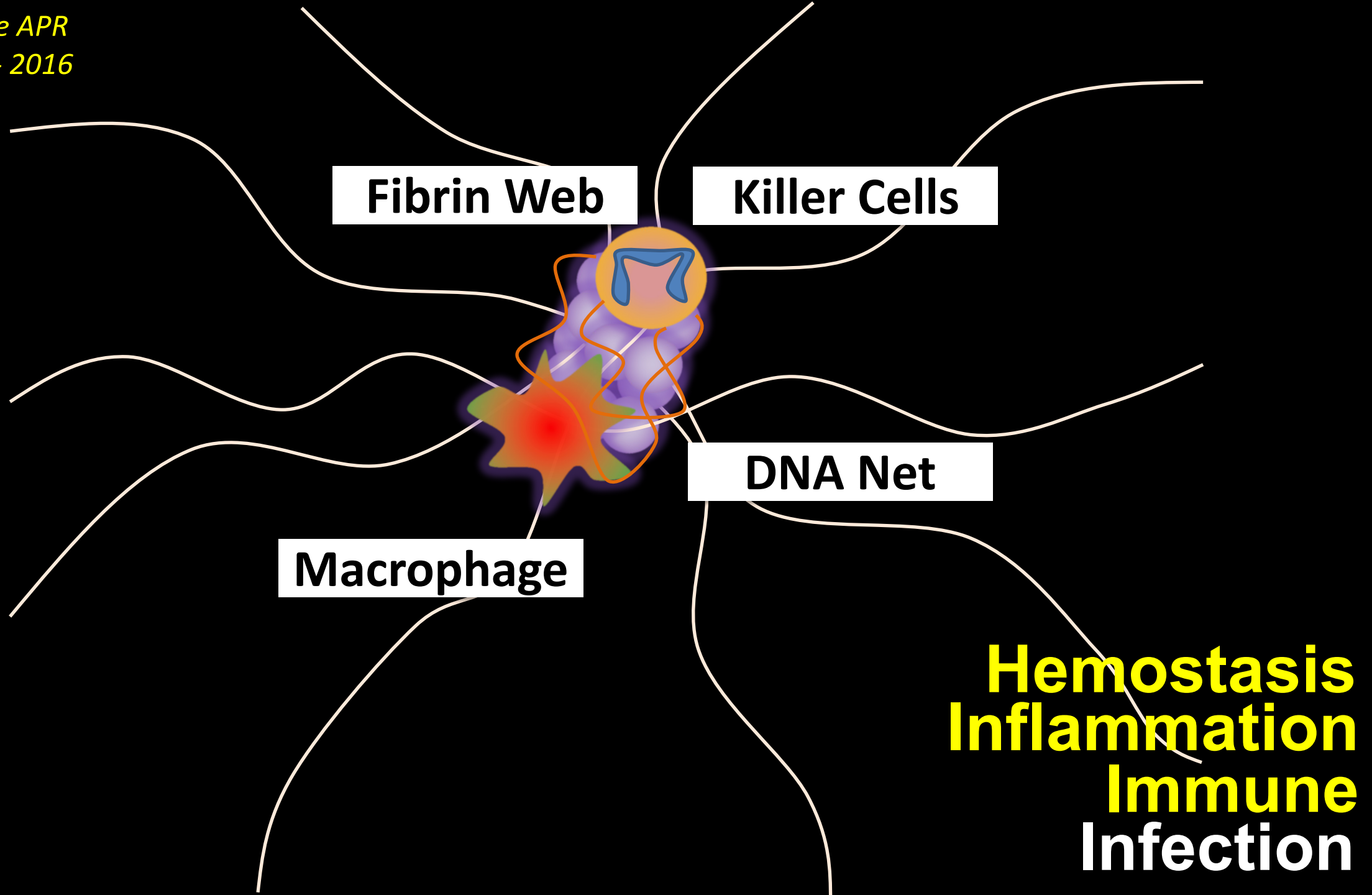


Fibrin Web

Macrophage

Hemostasis
Inflammation
Immune
Infection





Web Technique - Very Effective

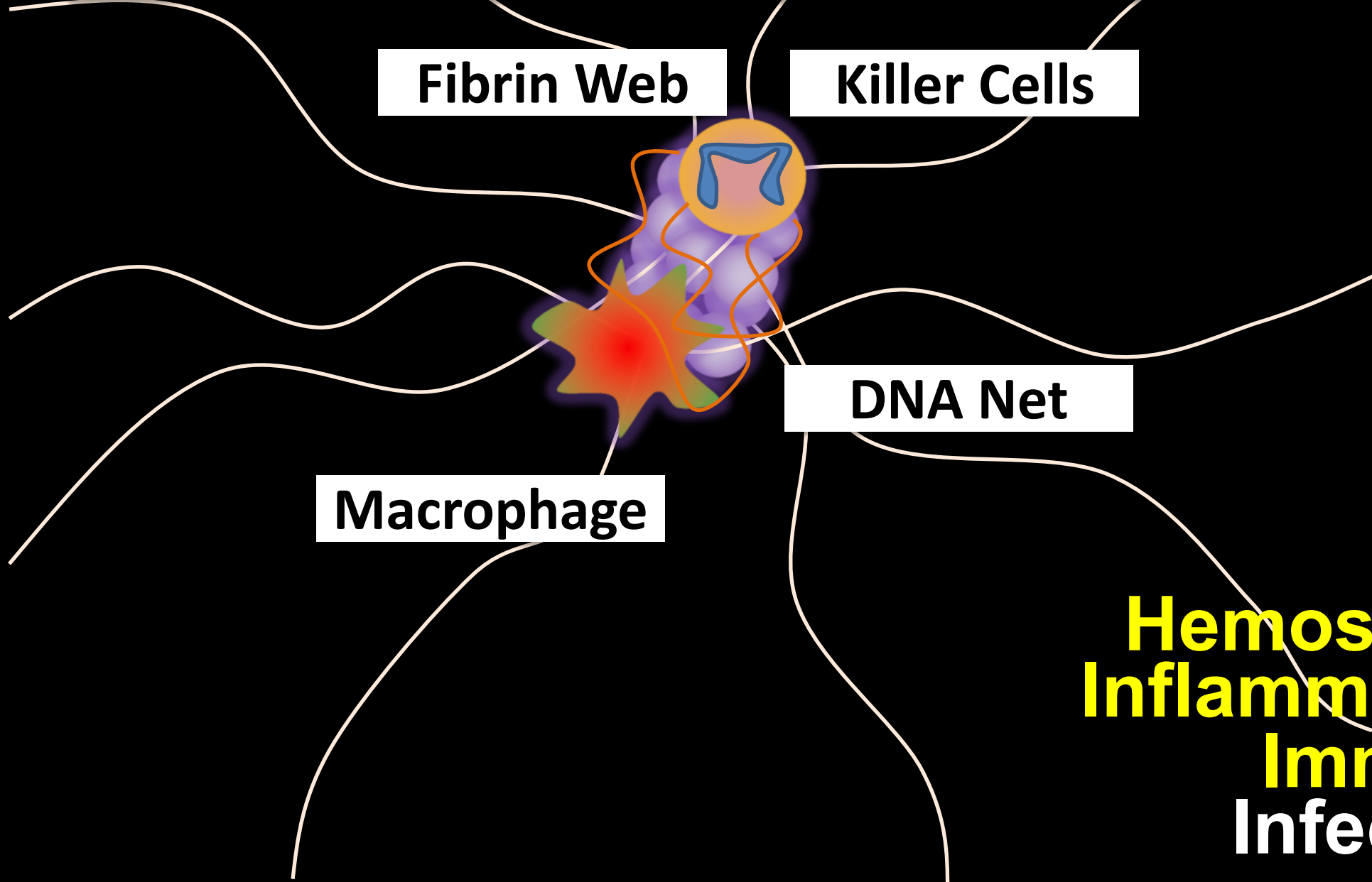
Fibrin Web

Killer Cells

DNA Net

Macrophage

Hemostasis
Inflammation
Immune
Infection



Web Technique - Very Effective

Fibrin Web

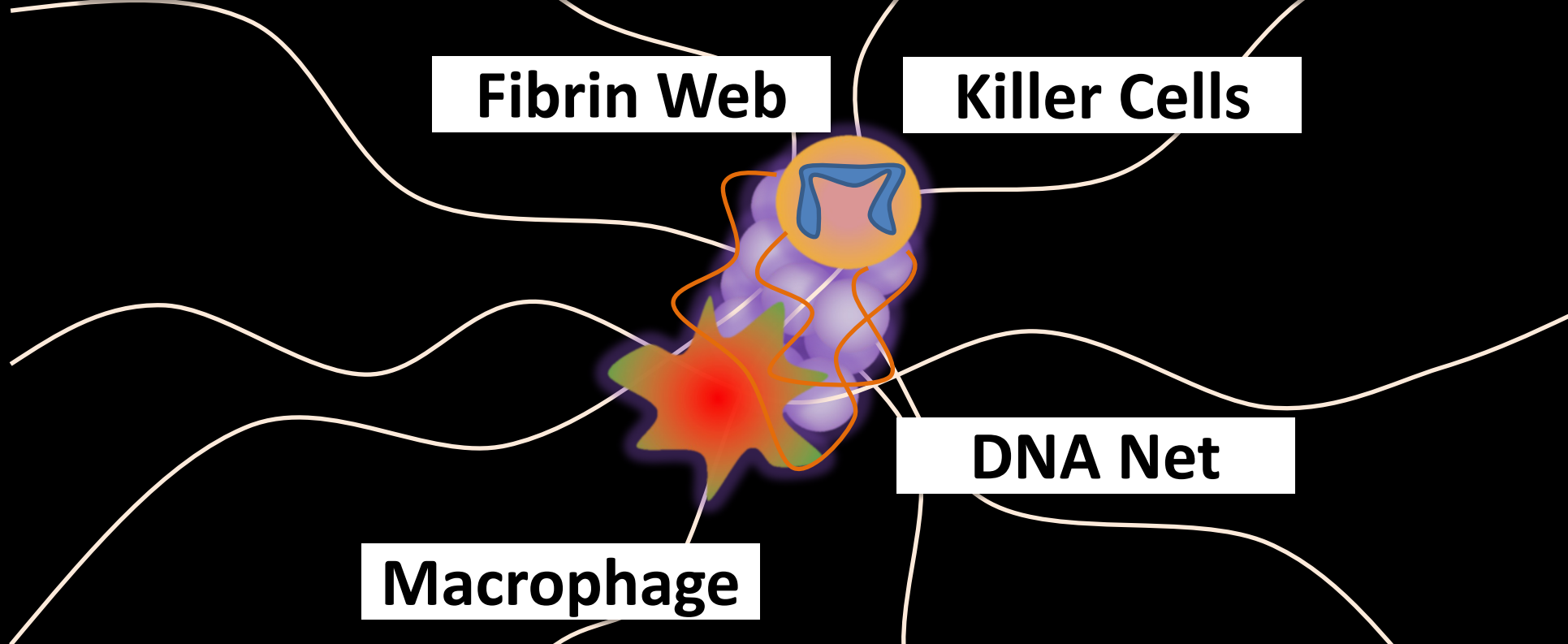
Killer Cells

DNA Net

Macrophage

Almost All Multi Cellular Organisms

Hemostasis
Inflammation
Immune
Infection

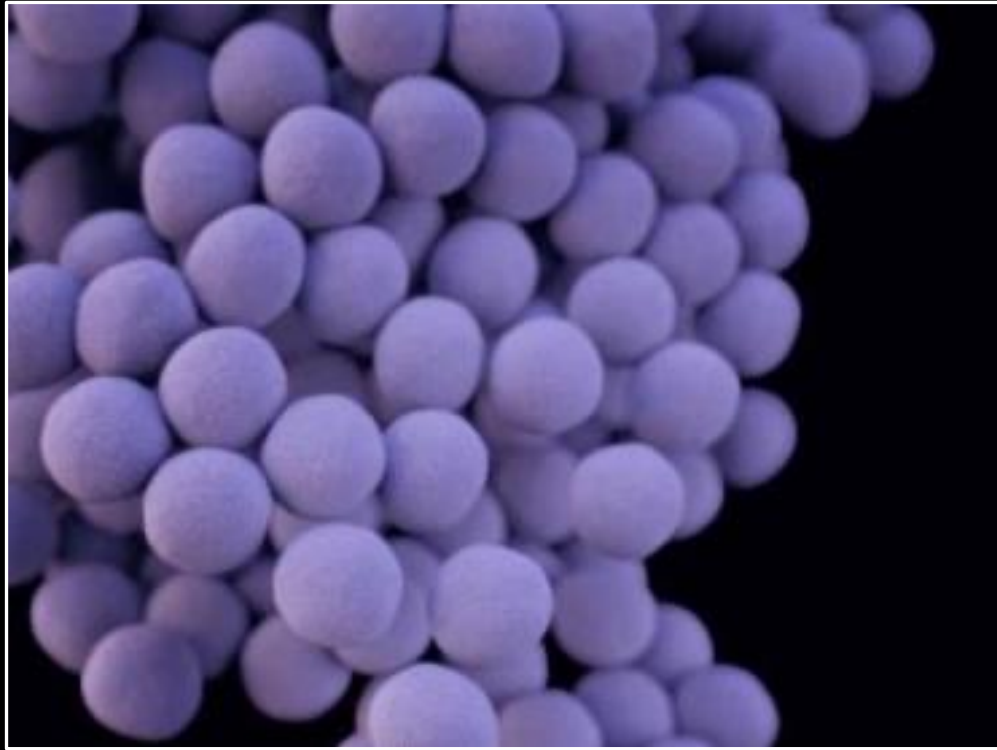

Musculoskeletal

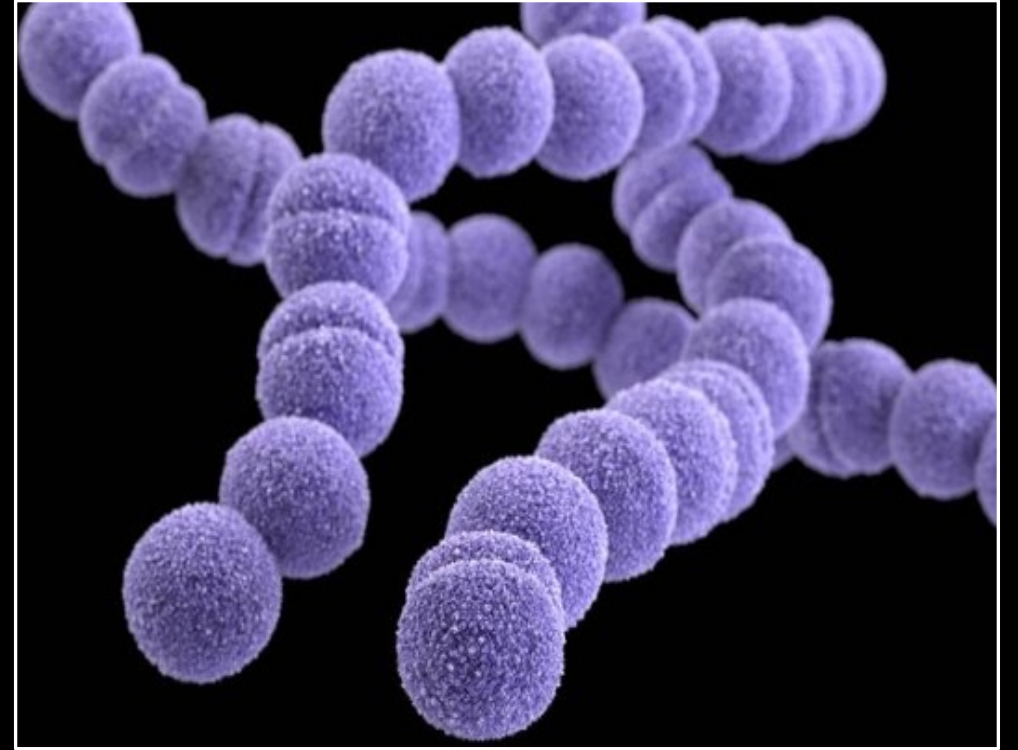
Infection

Hijacks The

Acute Phase Response



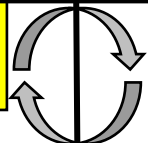
Staphylococcus Aureus



Streptococcus Pyogenes

Survival-APR

Repair-APR



Hemostasis

**FIBRIN
CONTAINMENT**

**Survival
Inflammatory**

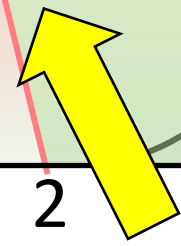
**Reparative
Inflammatory**

**Matrix
Remodeling**

Angiogenesis

Osteogenesis

FIBRINOLYSIS



trauma

1

2

3

4

5

6

7

8

9

10

11

12

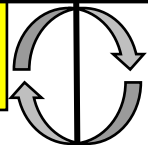
13

14

Days after injury

Survival-APR

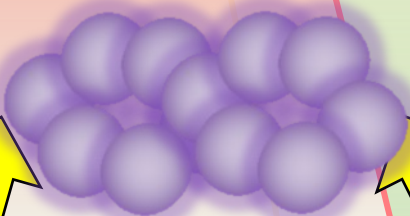
Repair-APR



Hemostasis

**FIBRIN
CONTAINMENT**

**Survival
Inflammatory**



**Reparative
Inflammatory**

**Matrix
Remodeling**

Angiogenesis

Osteogenesis

FIBRINOLYSIS

Trauma

1

2

3

4

5

6

7

8

9

10

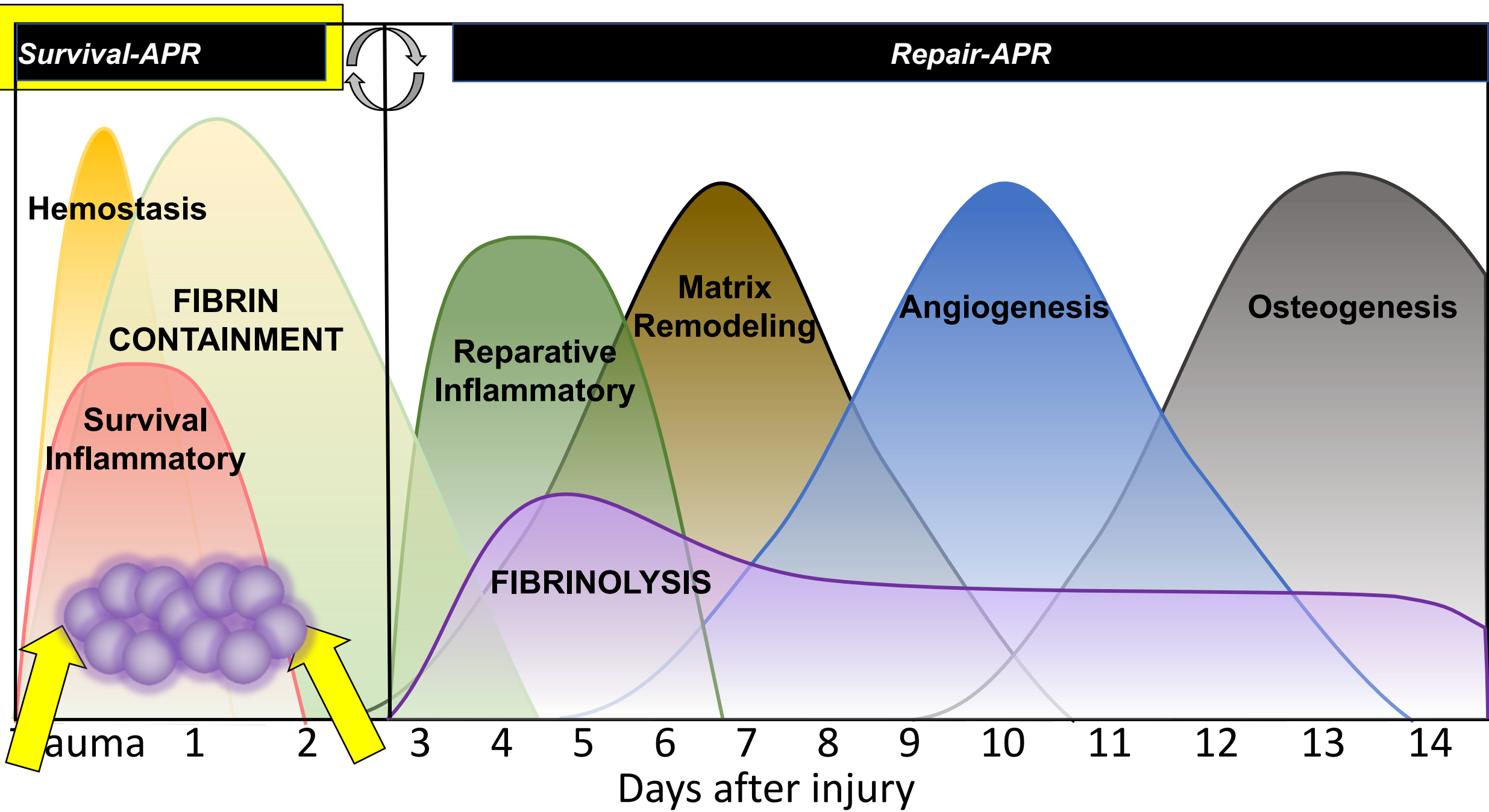
11

12

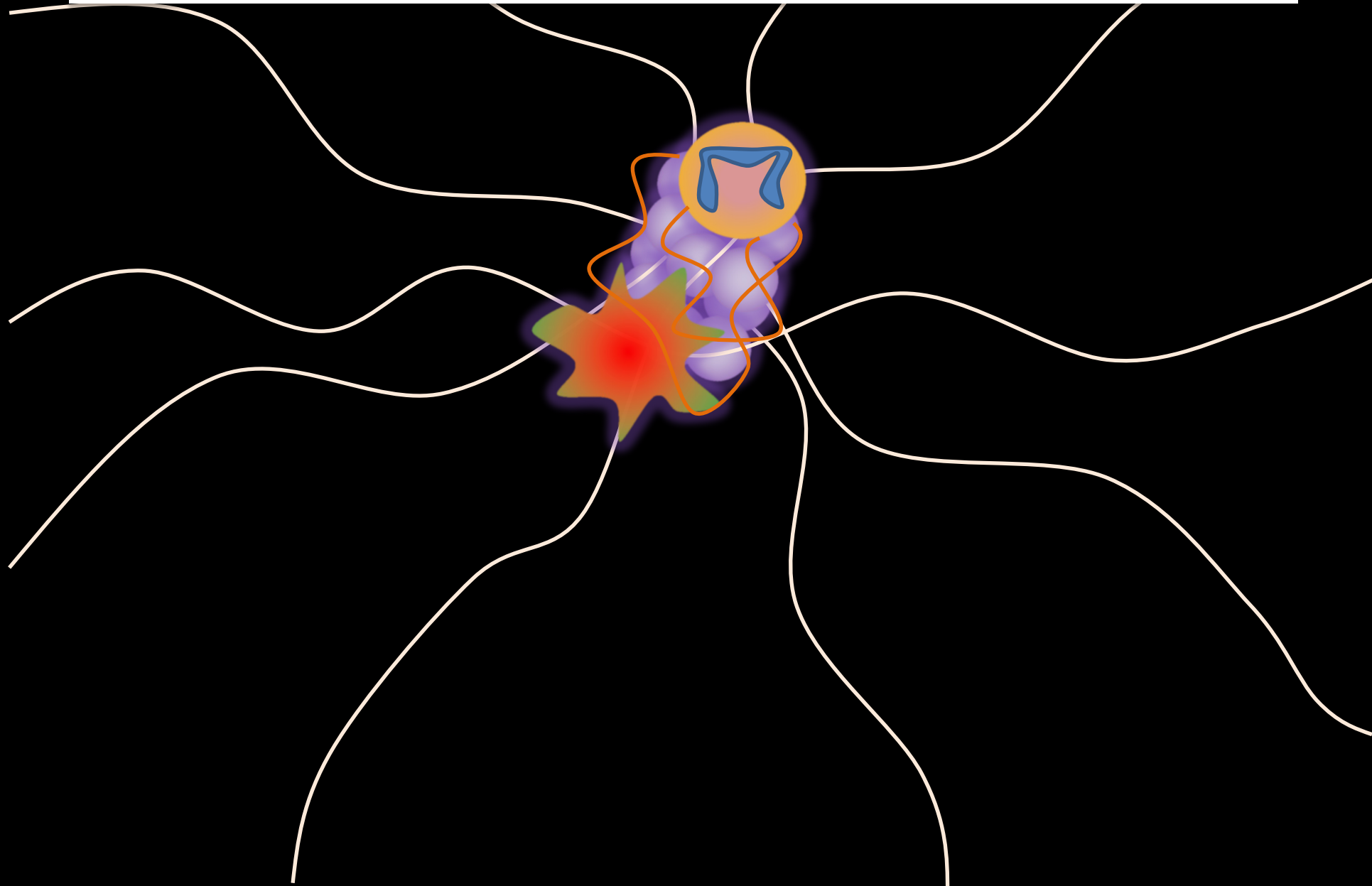
13

14

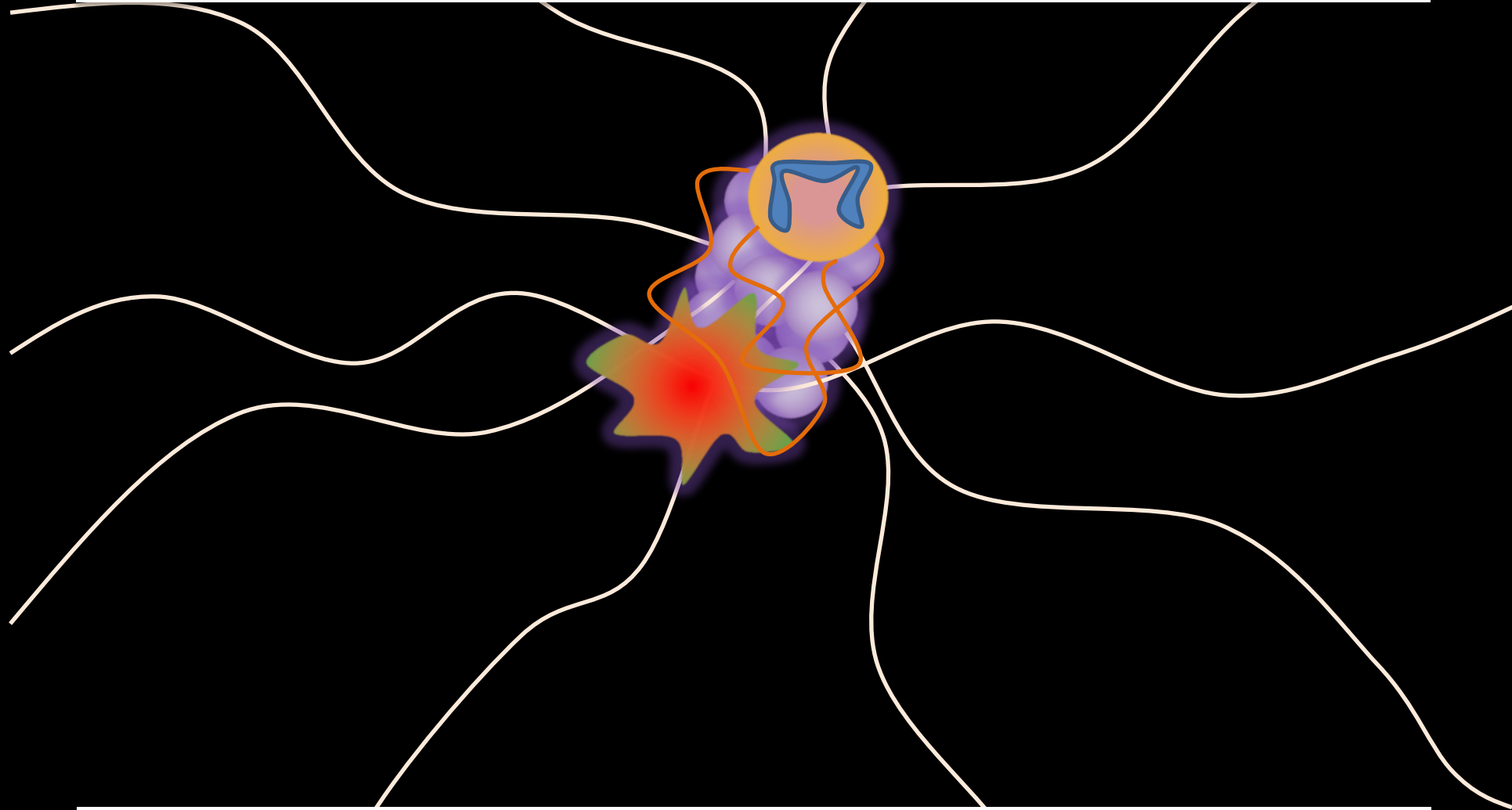
Days after injury




Web Technique - Very Effective




Web Technique - Very Effective



Staph Aureus Has Evolved

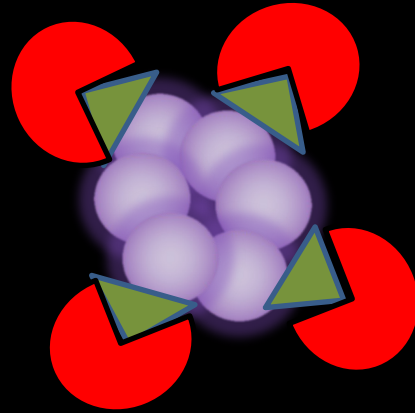


Staph Aureus Has Evolved



Coagulase

Staph Aureus Has Evolved

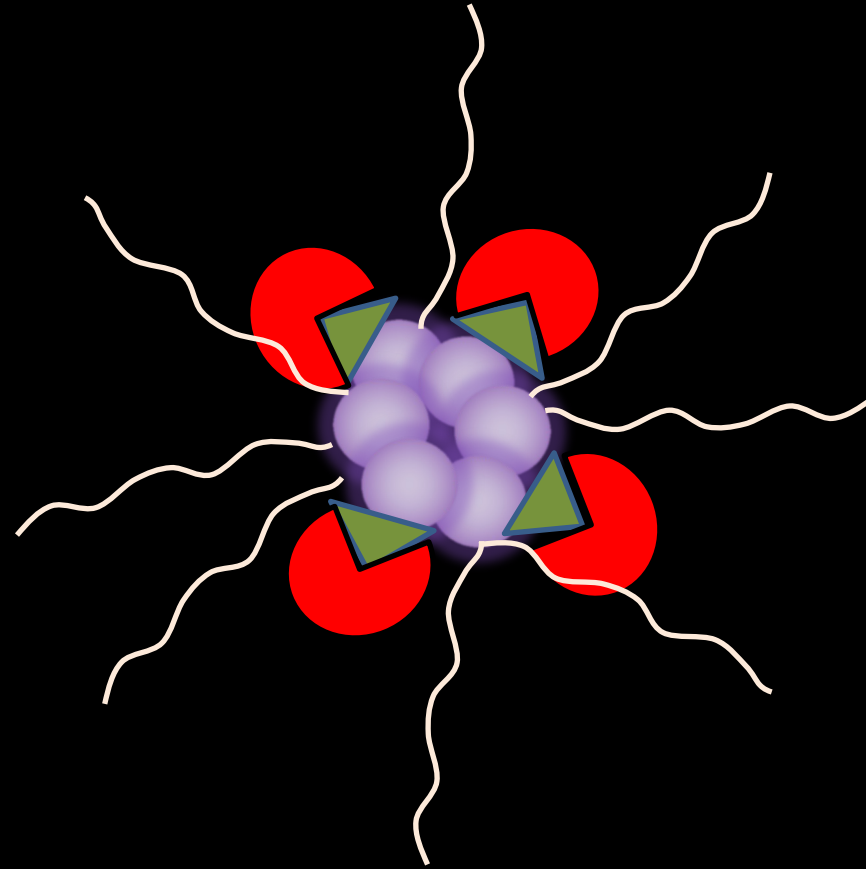


Prothrombin



Coagulase

Staph Aureus Has Evolved

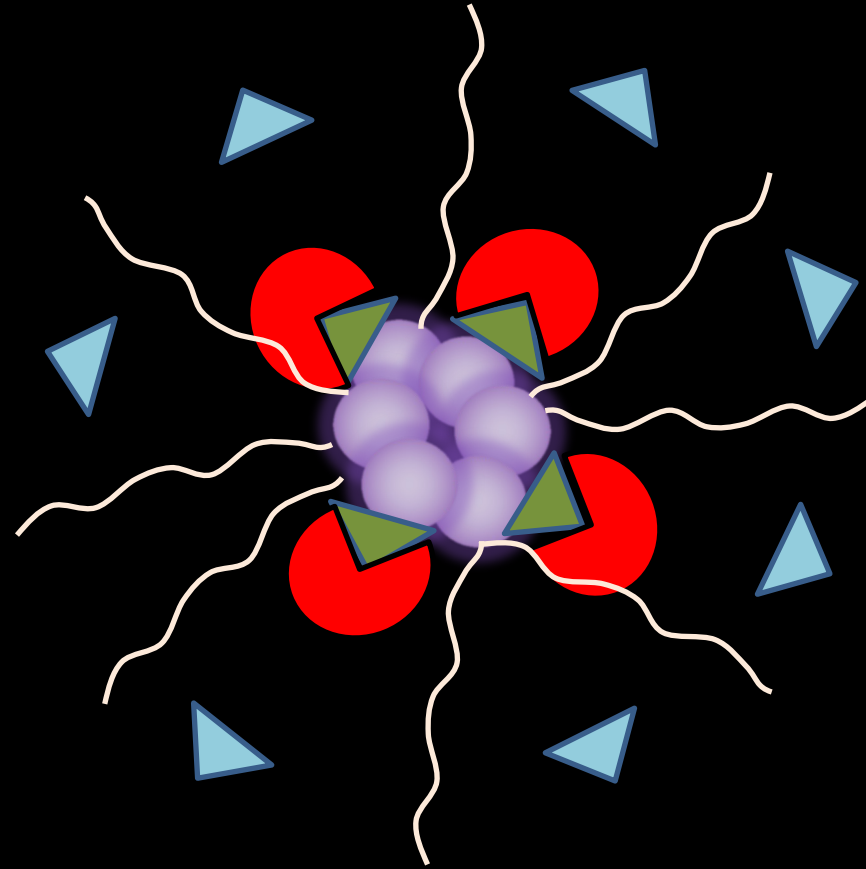


Prothrombin



Coagulase

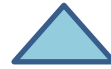Staph Aureus Has Evolved



Prothrombin

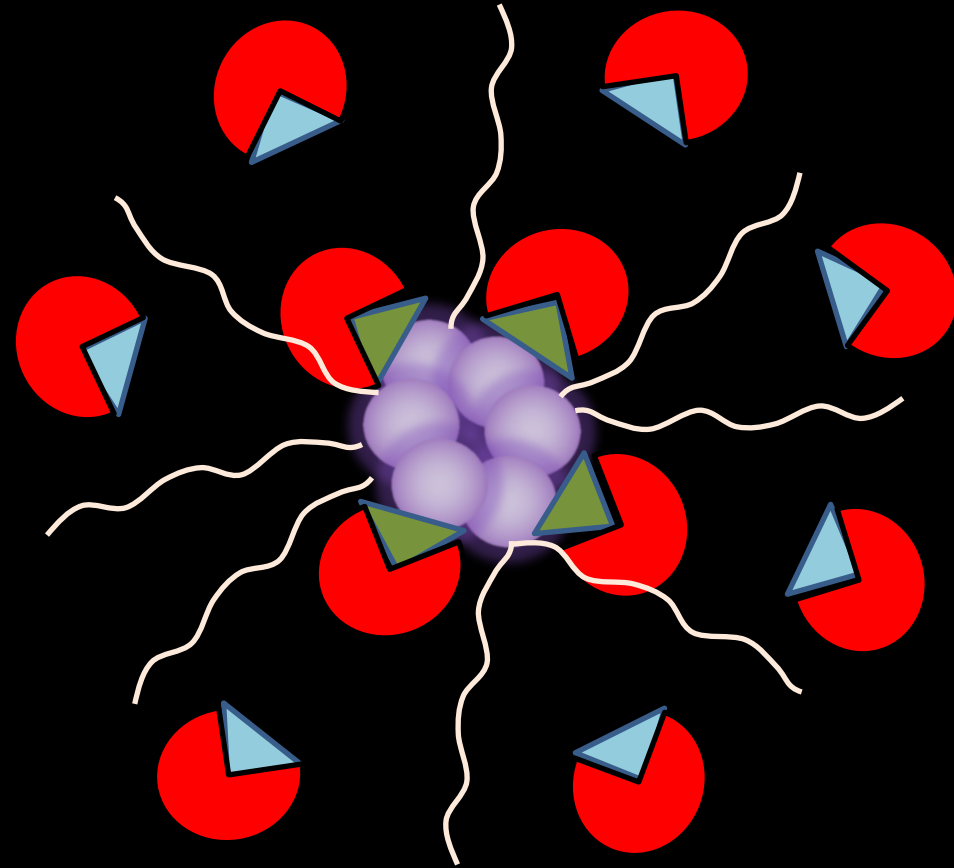


Coagulase



vWbp

Staph Aureus Has Evolved



Prothrombin

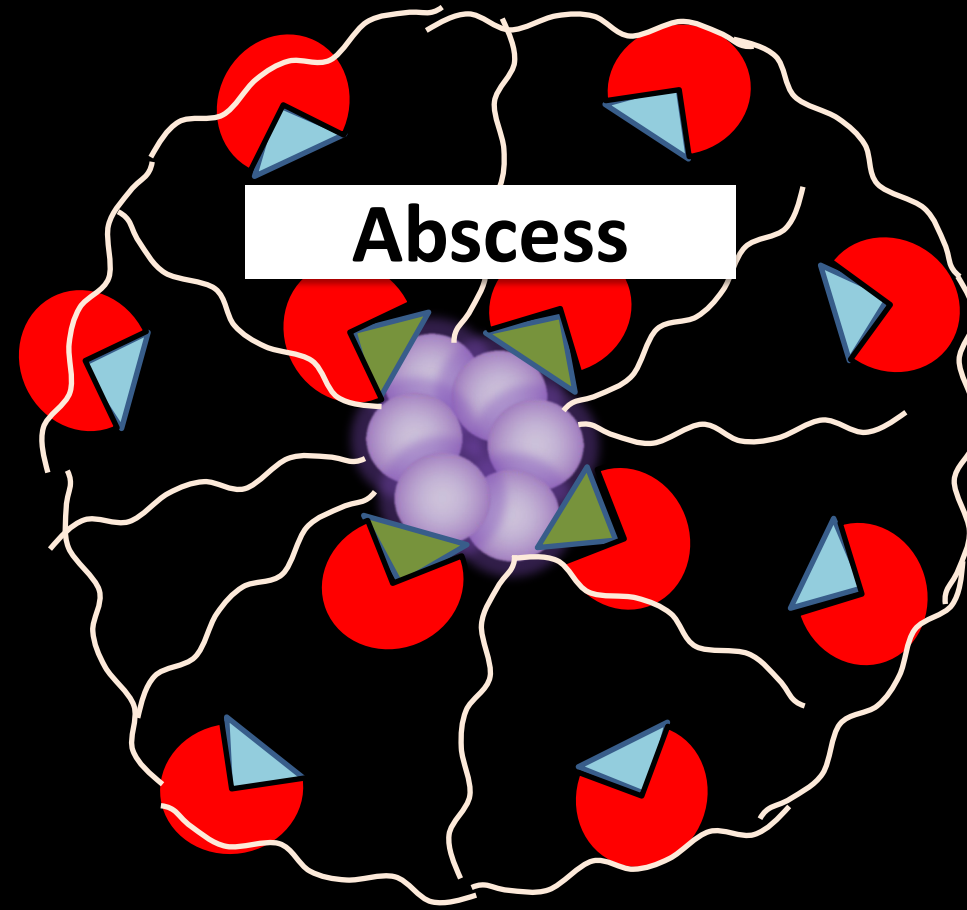


Coagulase



vWbp

Staph Aureus Has Evolved



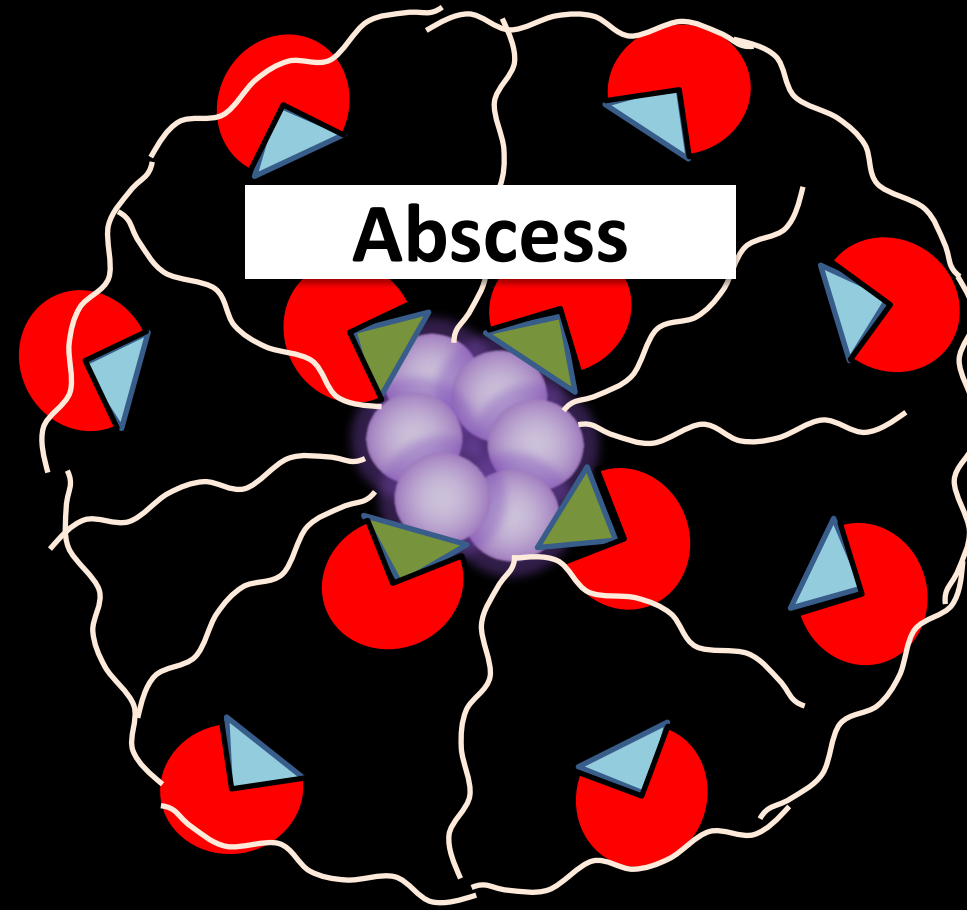
Abscess

 ***Prothrombin***

 ***Coagulase***

 ***vWbp***

Staph Aureus Has Evolved



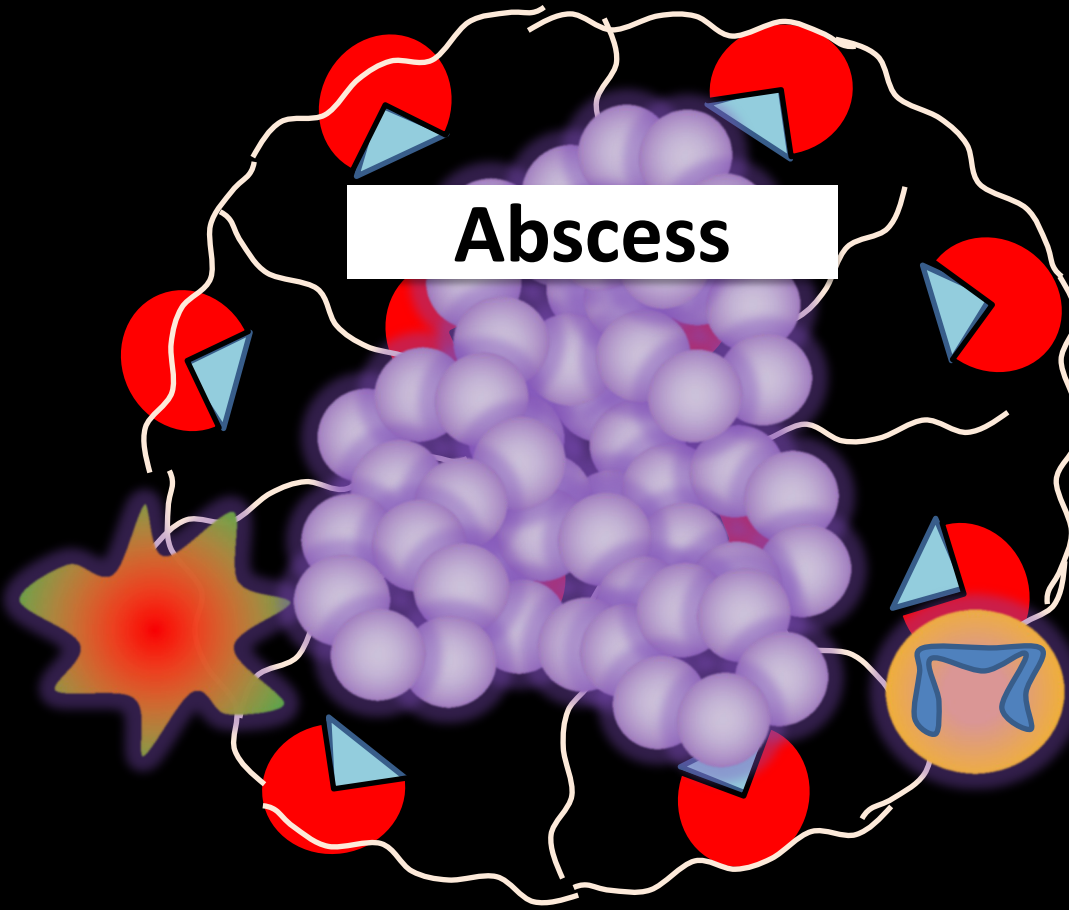
Abscess

 ***Prothrombin***

 ***Coagulase***

 ***vWbp***

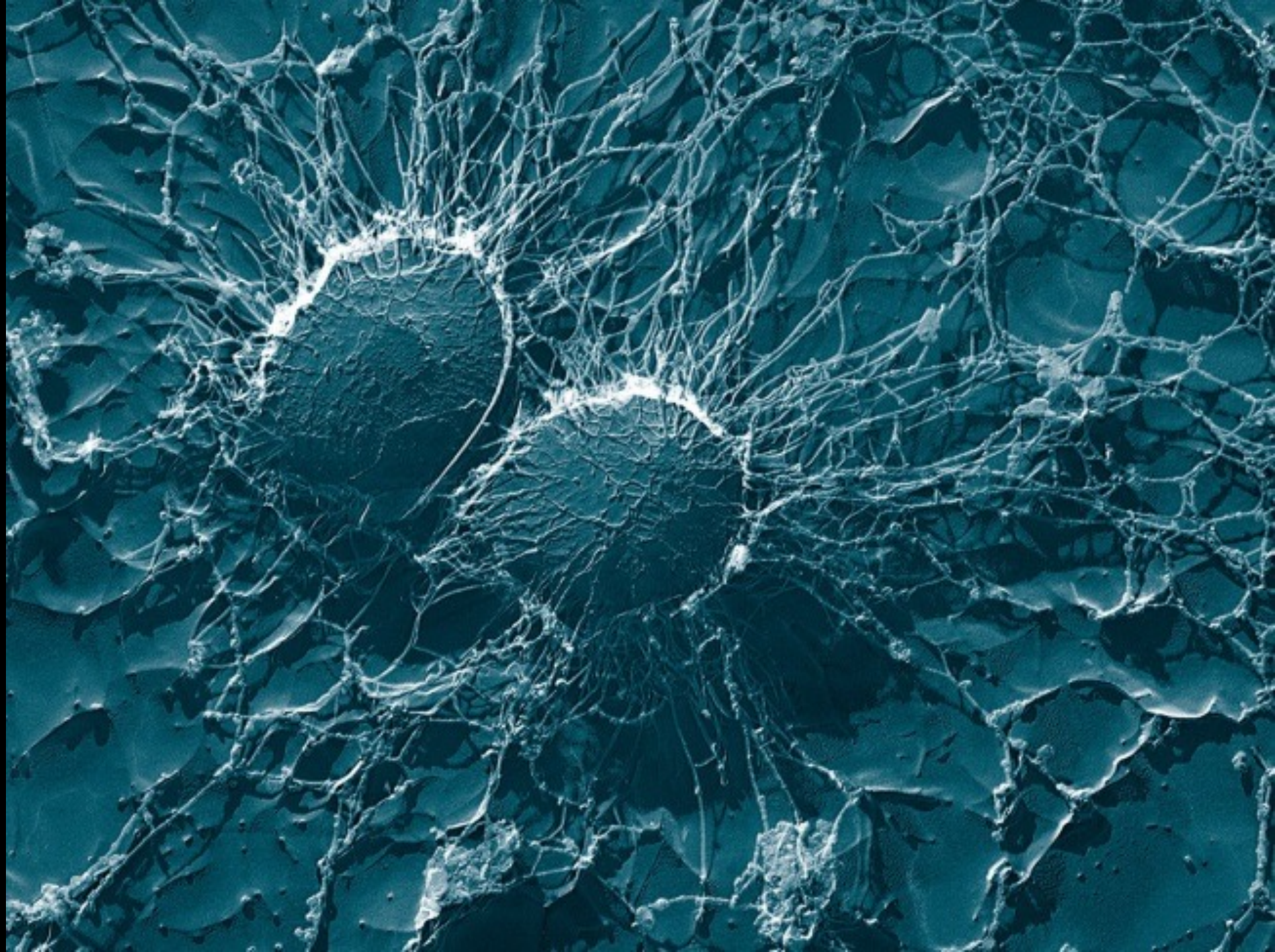
Staph Aureus Has Evolved



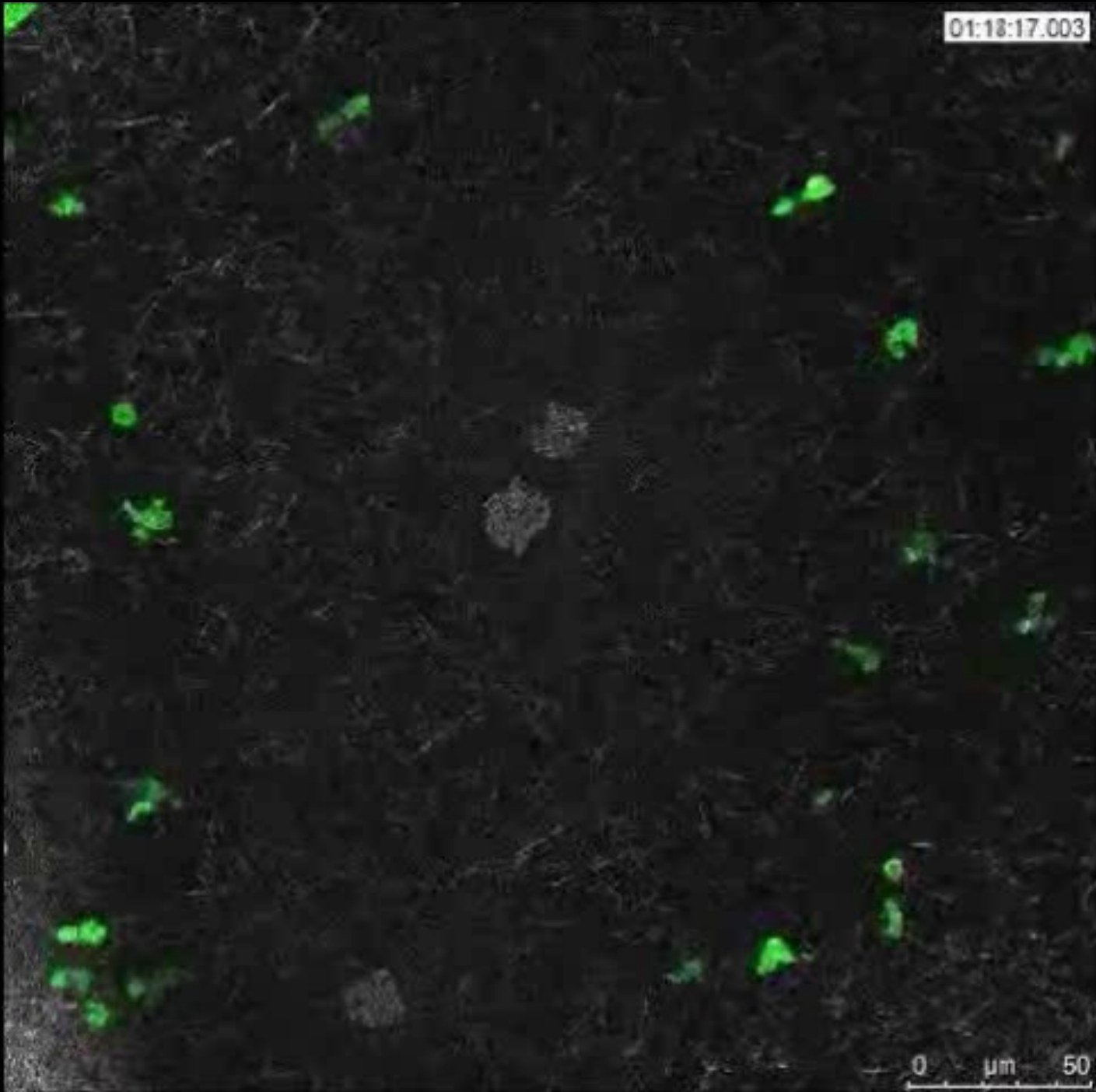
Abscess

Quorum

Staph Aureus Has Evolved



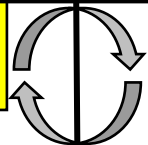
01:18:17.003



0 μm 50

Survival-APR

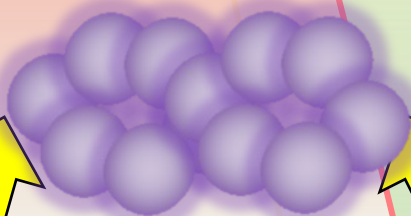
Repair-APR



Hemostasis

**FIBRIN
CONTAINMENT**

**Survival
Inflammatory**



**Reparative
Inflammatory**

**Matrix
Remodeling**

Angiogenesis

Osteogenesis

FIBRINOLYSIS

Trauma

1

2

3

4

5

6

7

8

9

10

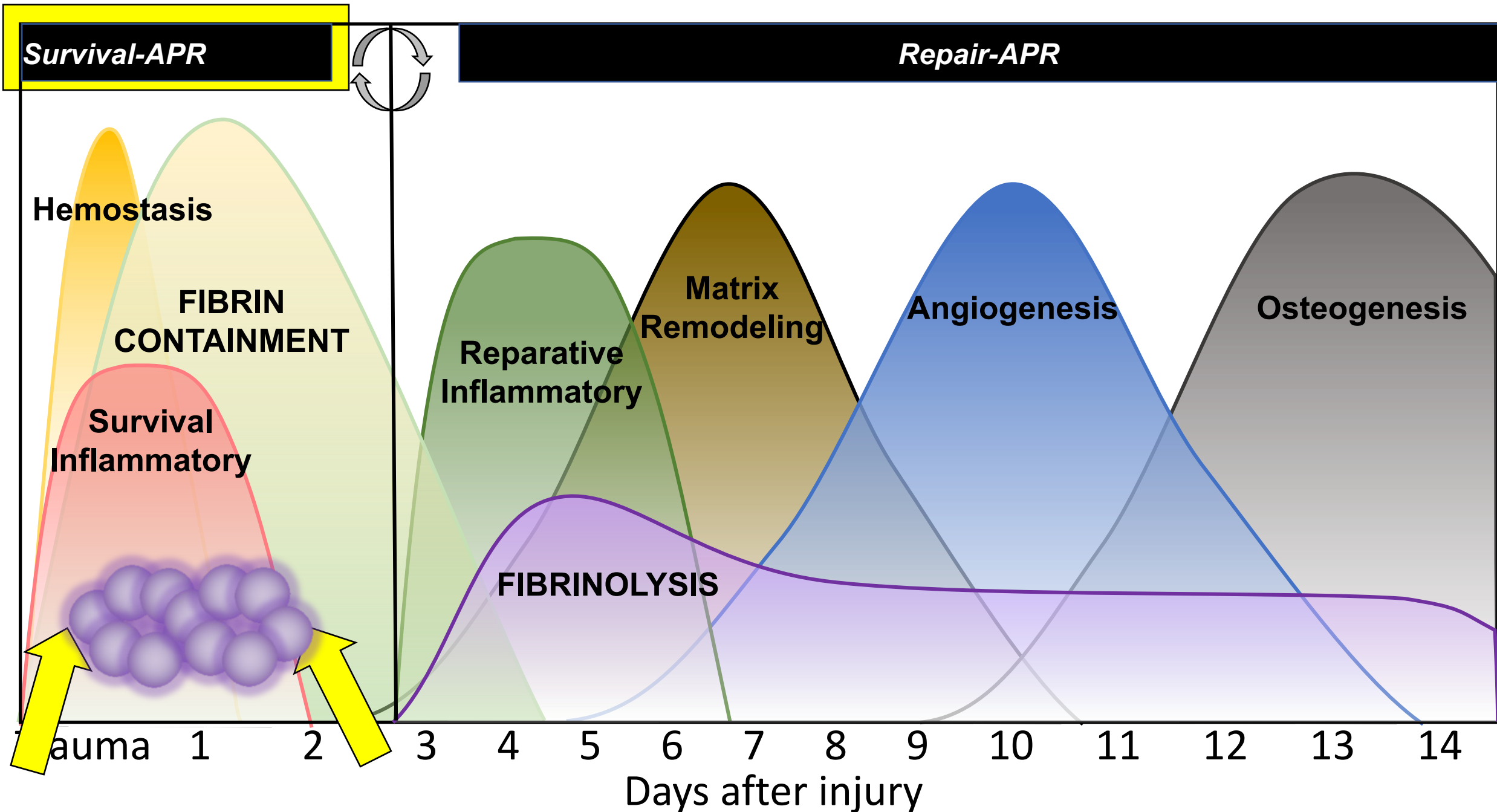
11

12

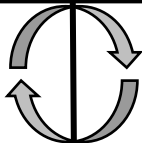
13

14

Days after injury



Survival-APR



Repair-APR

Hemostasis

**FIBRIN
CONTAINMENT**

**Survival
Inflammatory**

**Reparative
Inflammatory**

**Matrix
Remodeling**

Angiogenesis

Os

FIBRINOLYSIS



trauma

1

2

3

4

5

6

7

8

9

10

11

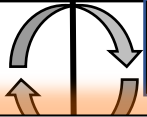
12

13

14

Days after injury

Survival-APR



Repair-APR

**Thrombosis
MODS**

Hemostasis

**FIBRIN
CONTAINMENT**

**Survival
Inflammatory**


**Reparative
Inflammatory**

**Matrix
Remodeling**

Angiogenesis

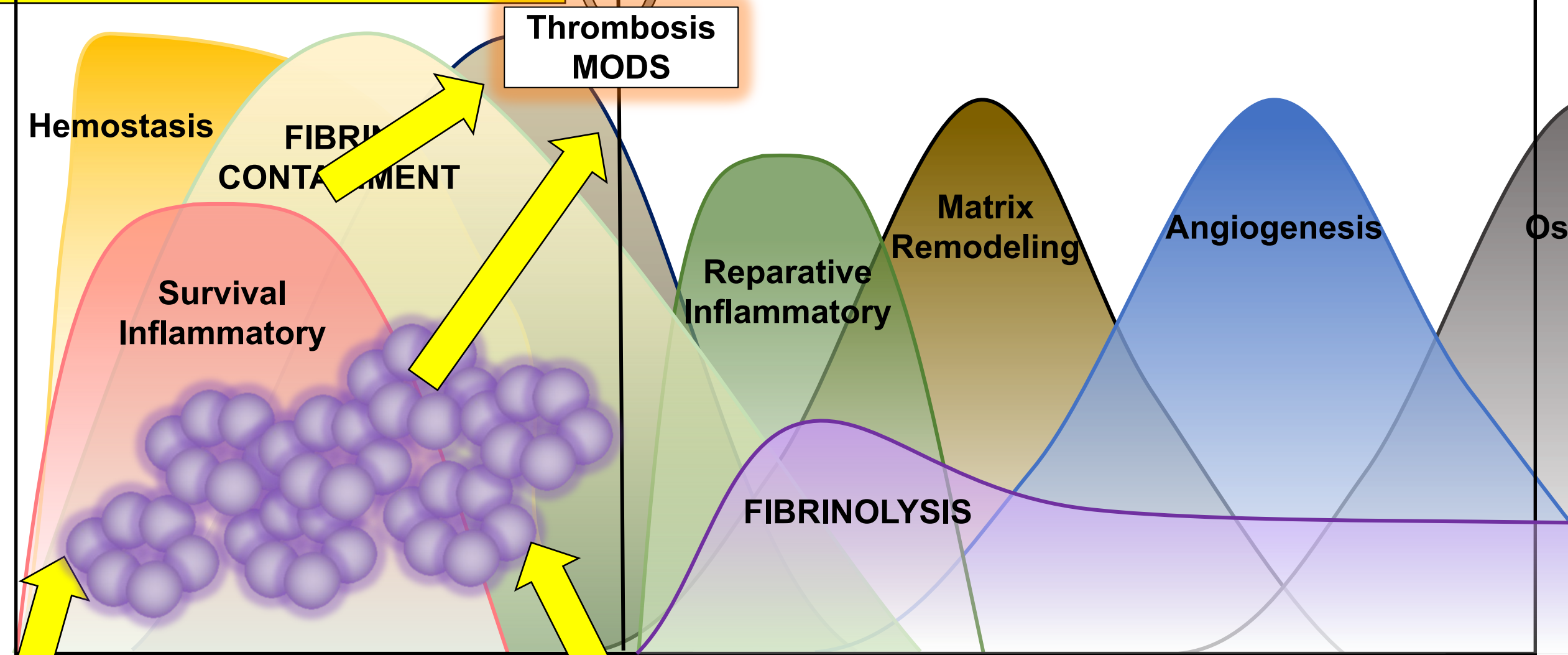
Os

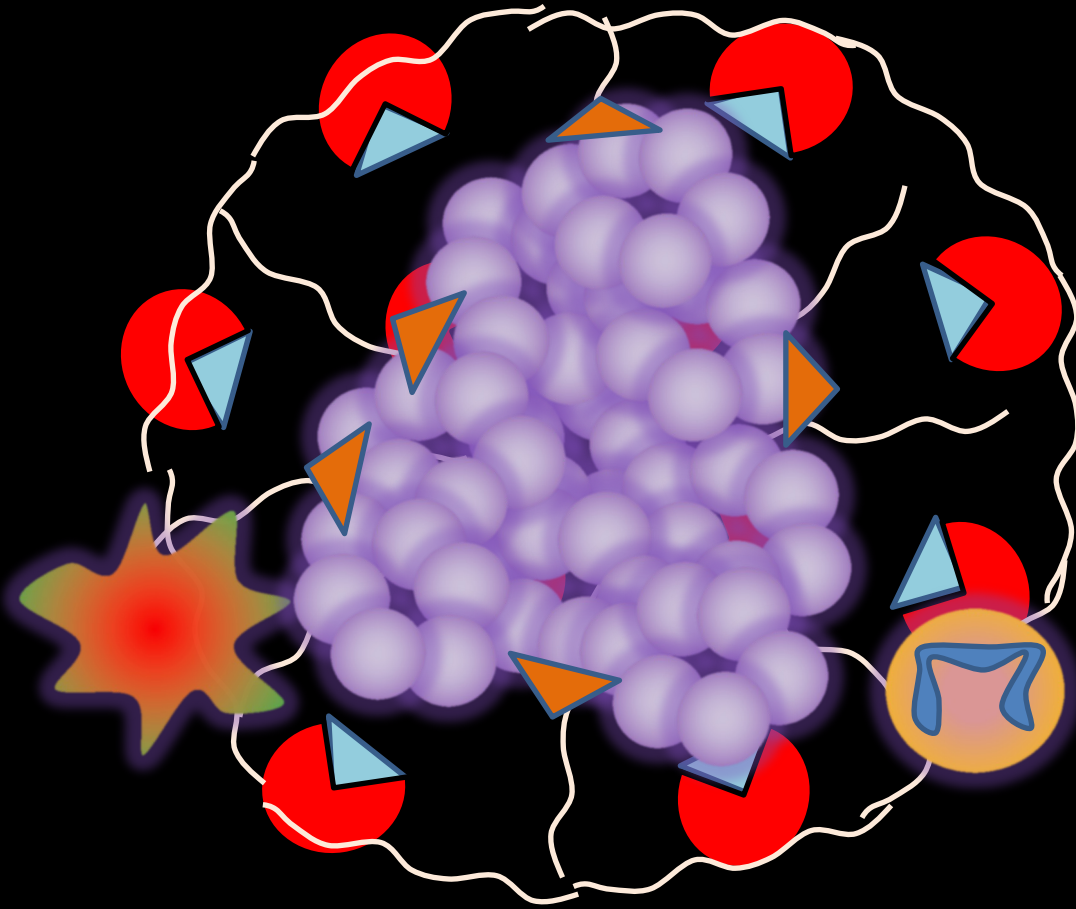
FIBRINOLYSIS



Trauma 1 2 3 4 5 6 7 8 9 10 11 12 13 14

Days after injury

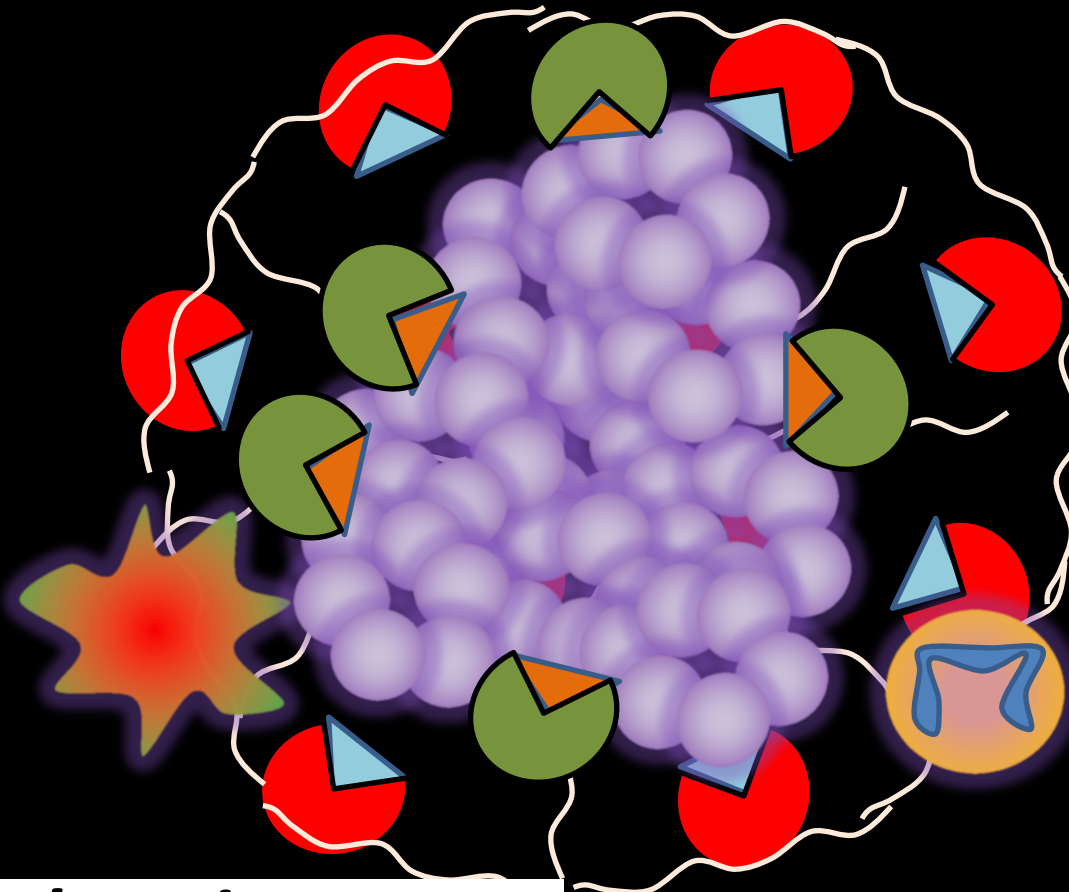




SAK

Quorum

Staph Aureus Has Evolved

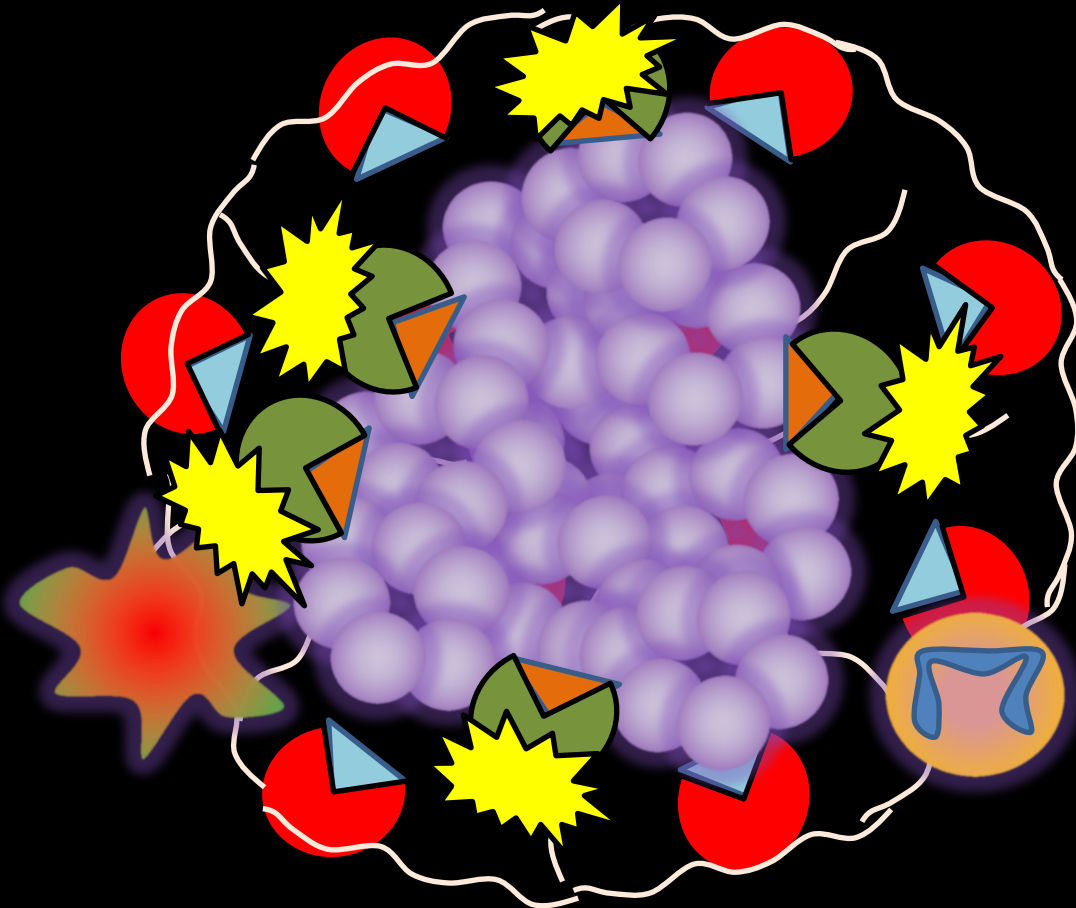


 *Plasmin*

 *SAK*

Quorum

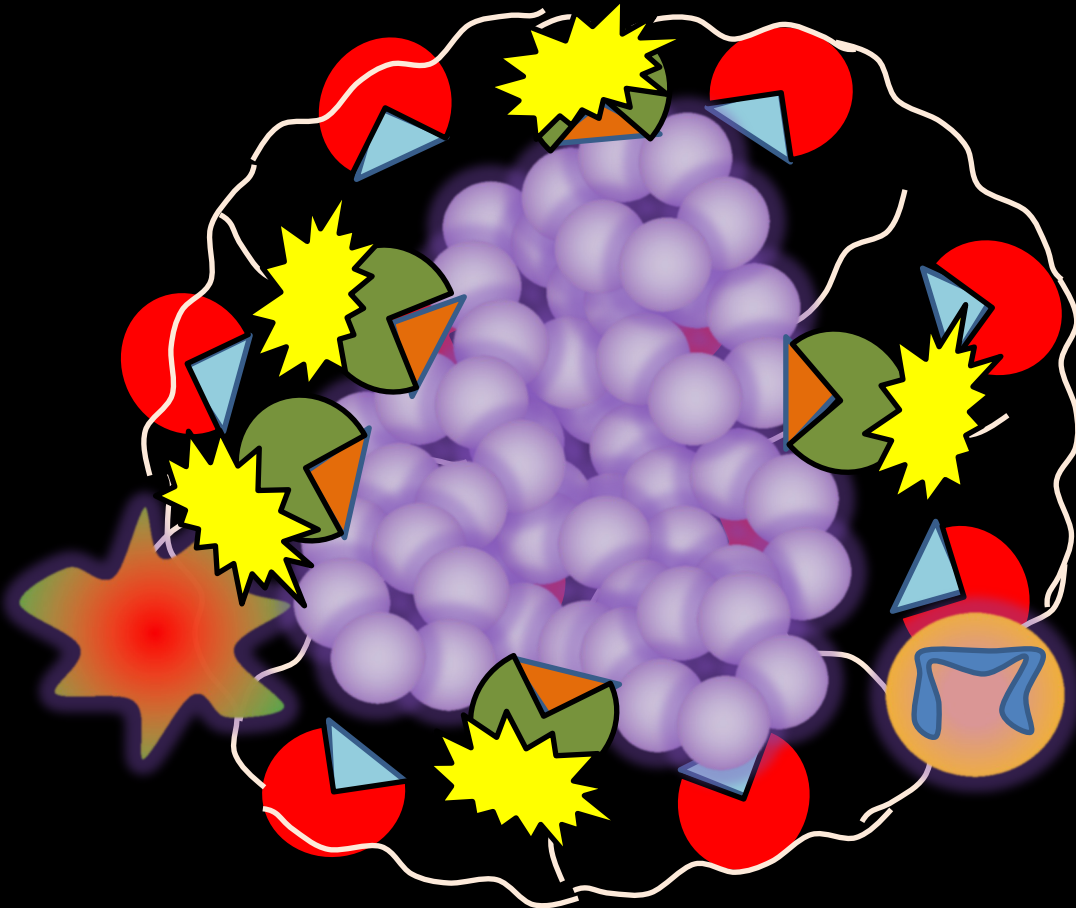
Staph Aureus Has Evolved



SAK

Quorum

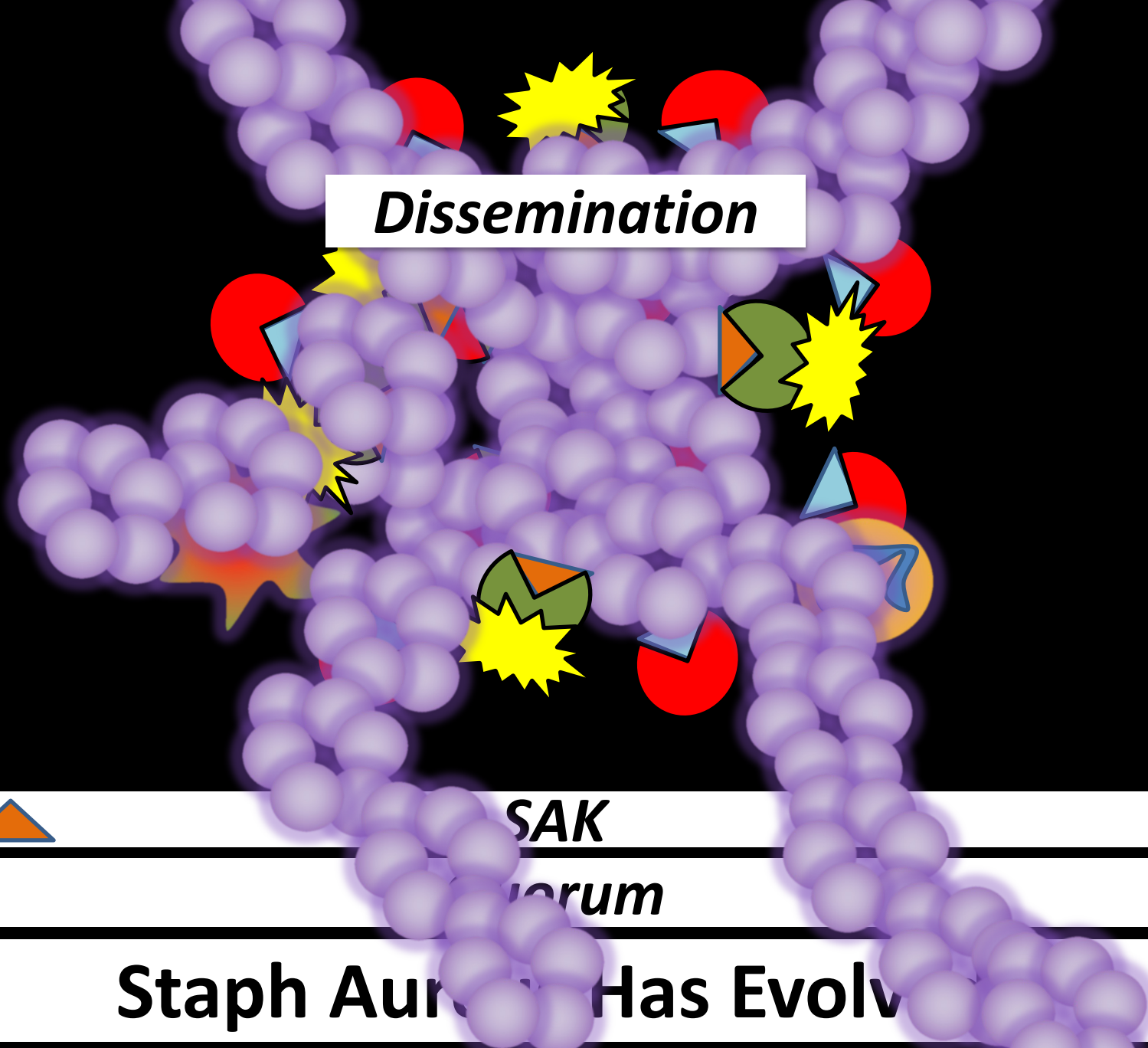
Staph Aureus Has Evolved



SAK

Quorum

Staph Aureus Has Evolved

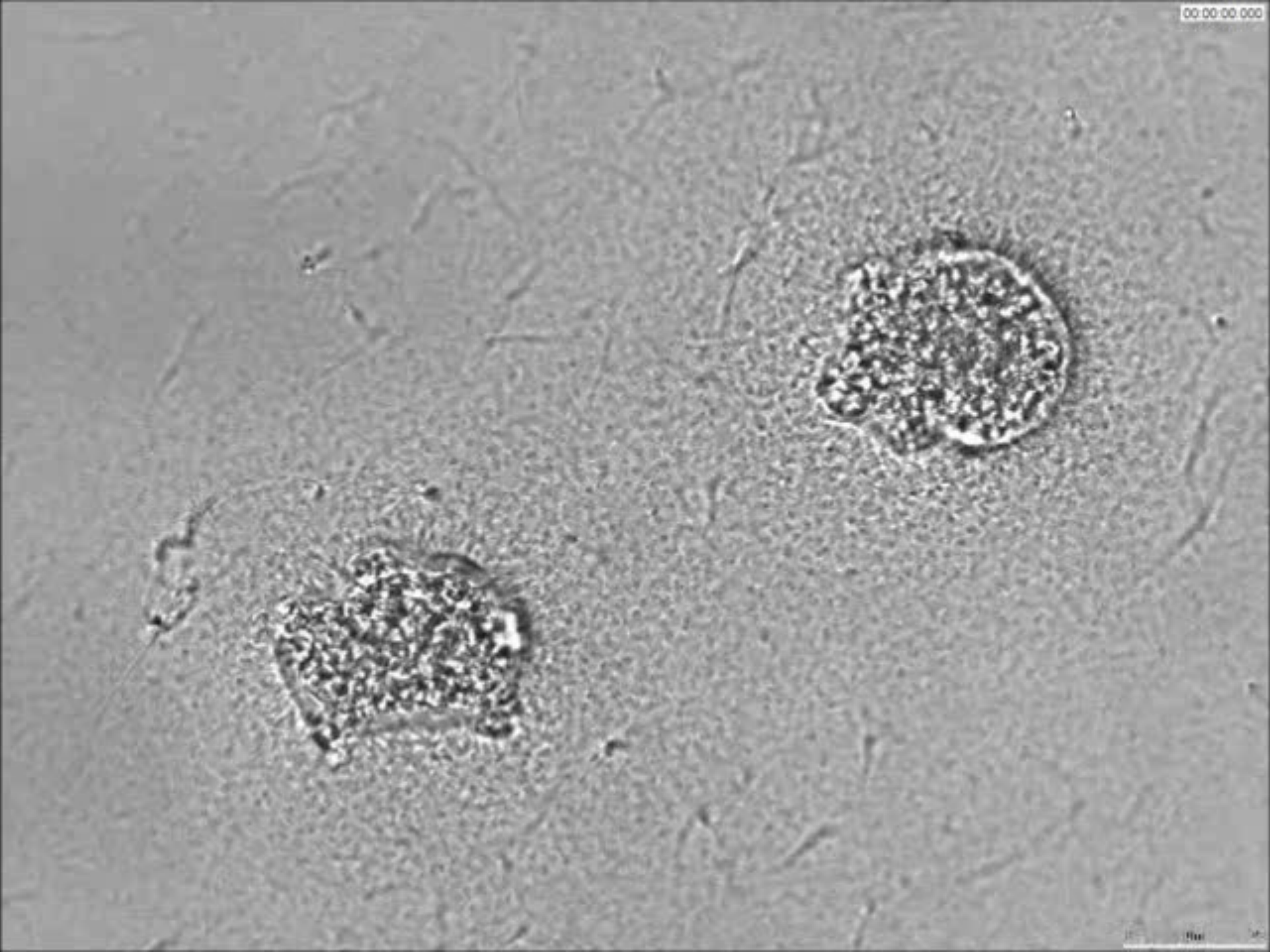

Dissemination

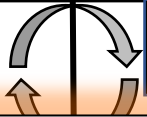
 **SAK**

erum

Staph Aureus Has Evolv



Survival-APR



Repair-APR

**Thrombosis
MODS**

Hemostasis

**FIBRIN
CONTAINMENT**

**Survival
Inflammatory**

**Reparative
Inflammatory**

**Matrix
Remodeling**

Angiogenesis

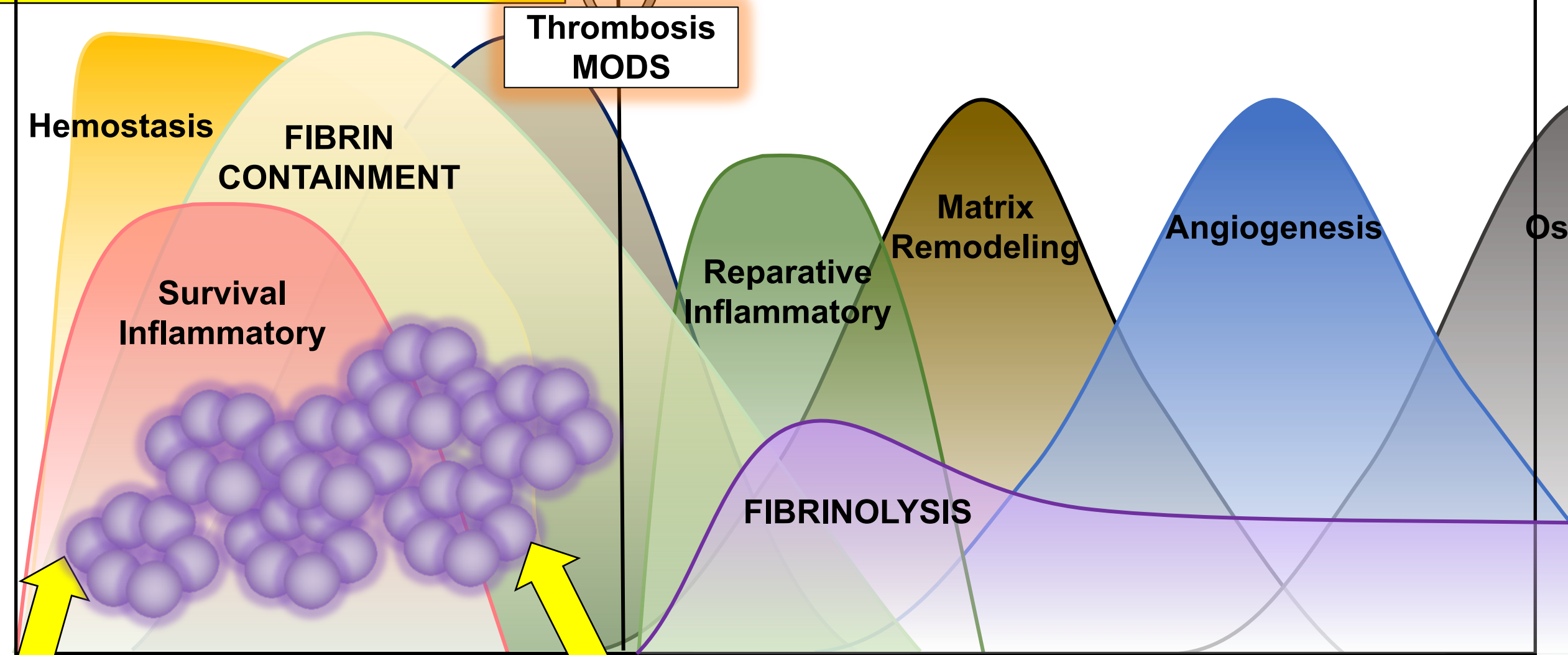
Os

FIBRINOLYSIS



trauma 1 2 3 4 5 6 7 8 9 10 11 12 13 14

Days after injury



Survival-APR




**Thrombosis
MODS**

Hemostasis

**FIBRIN
CONTAINMENT**

**Survival
Inflammatory**

FIBRINOLYSIS



Trauma

1

2

3

4

5

6

7

8

9

10

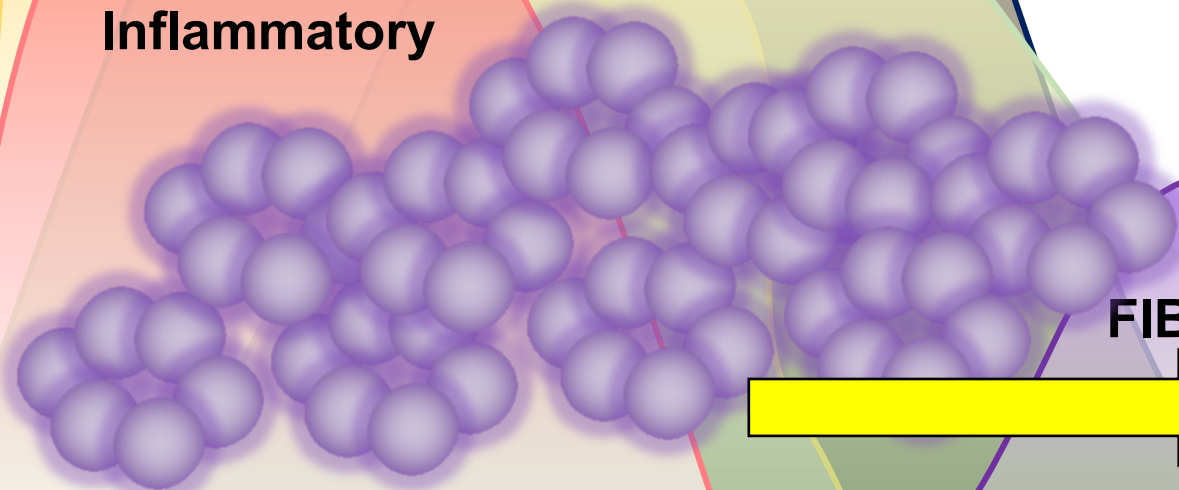
11

12

13

14

Days after injury



Survival-APR




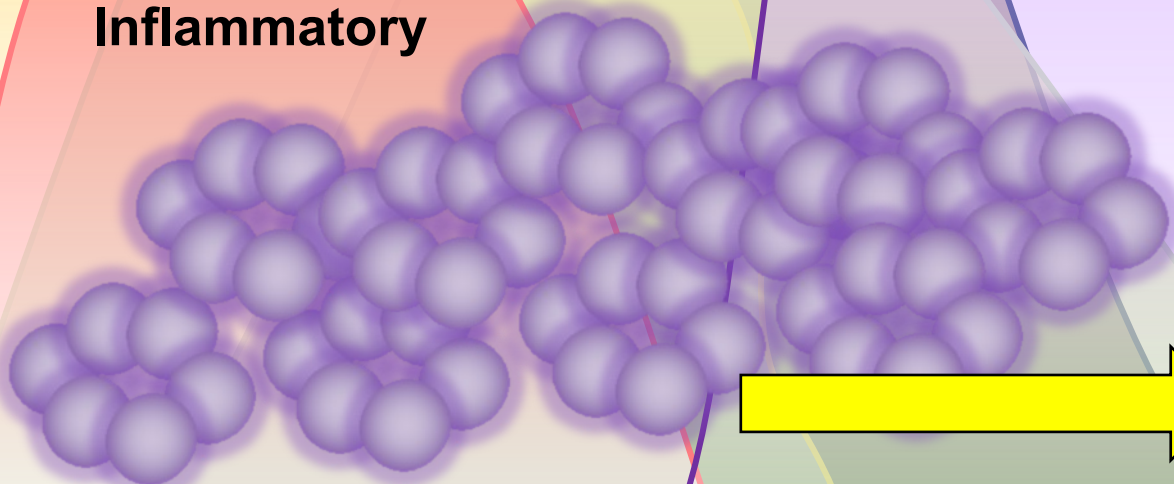
Hemostasis

**FIBRIN
CONTAINMENT**

**Survival
Inflammatory**

**Thrombosis
MODS**

FIBRINOLYSIS



Trauma

1

2

3

4

5

6

7

8

9

10

11

12

13

14

Days after injury

Survival-APR



Hemostasis

**Survival
Inflammatory**

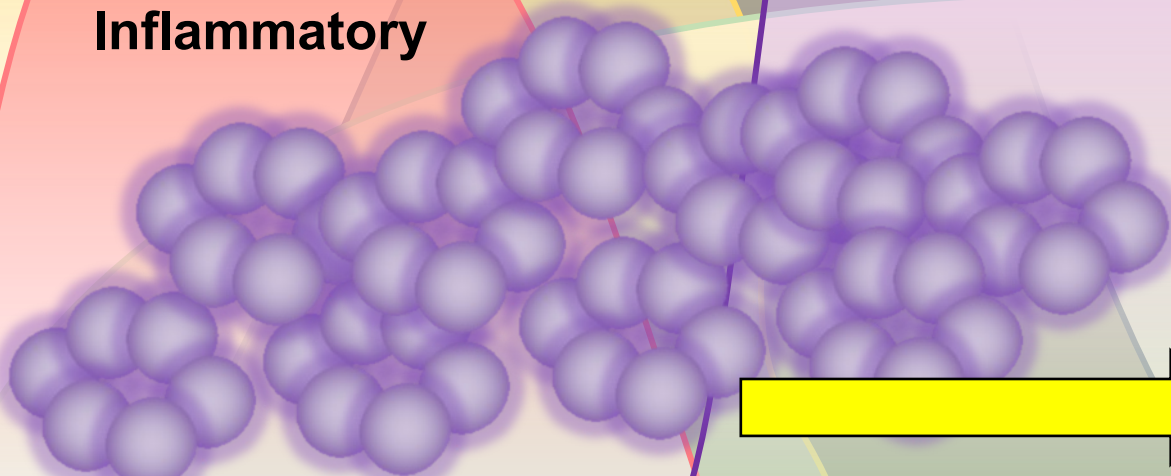
**Thrombosis
MODS**

FIBRINOLYSIS

**FIBRIN
CONTAINMENT**

Trauma 1 2 3 4 5 6 7 8 9 10 11 12 13 14

Days after injury



Survival-APR



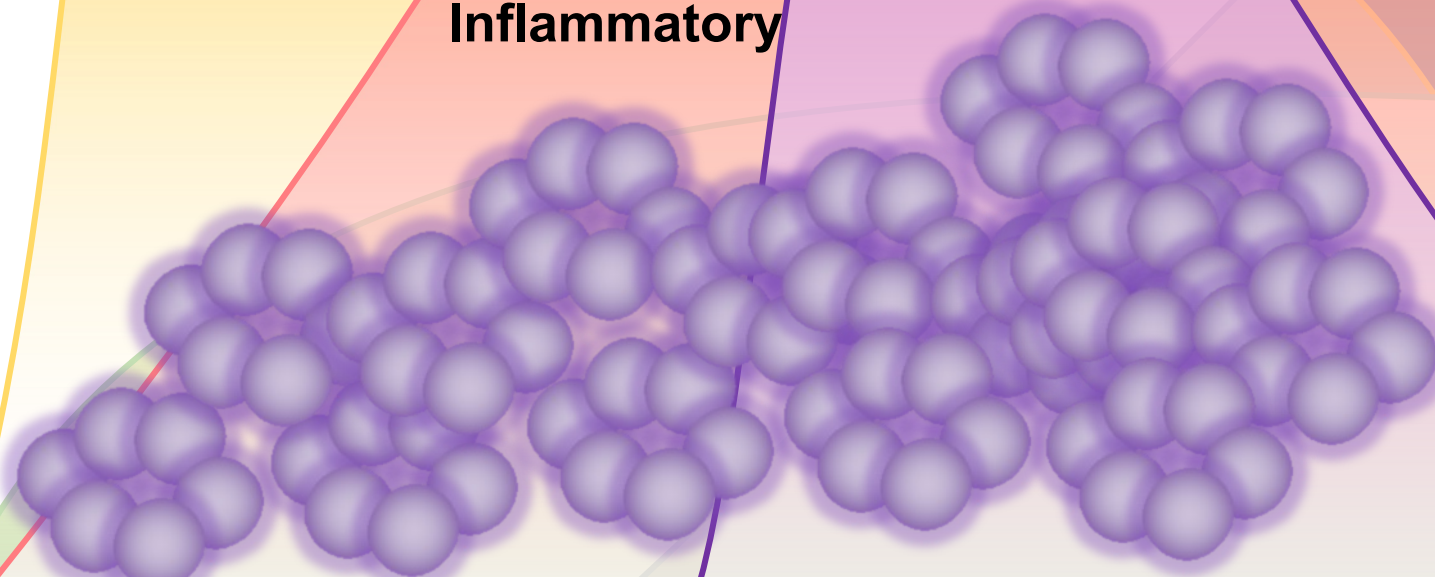
Hemostasis

**Survival
Inflammatory**

FIBRINOLYSIS

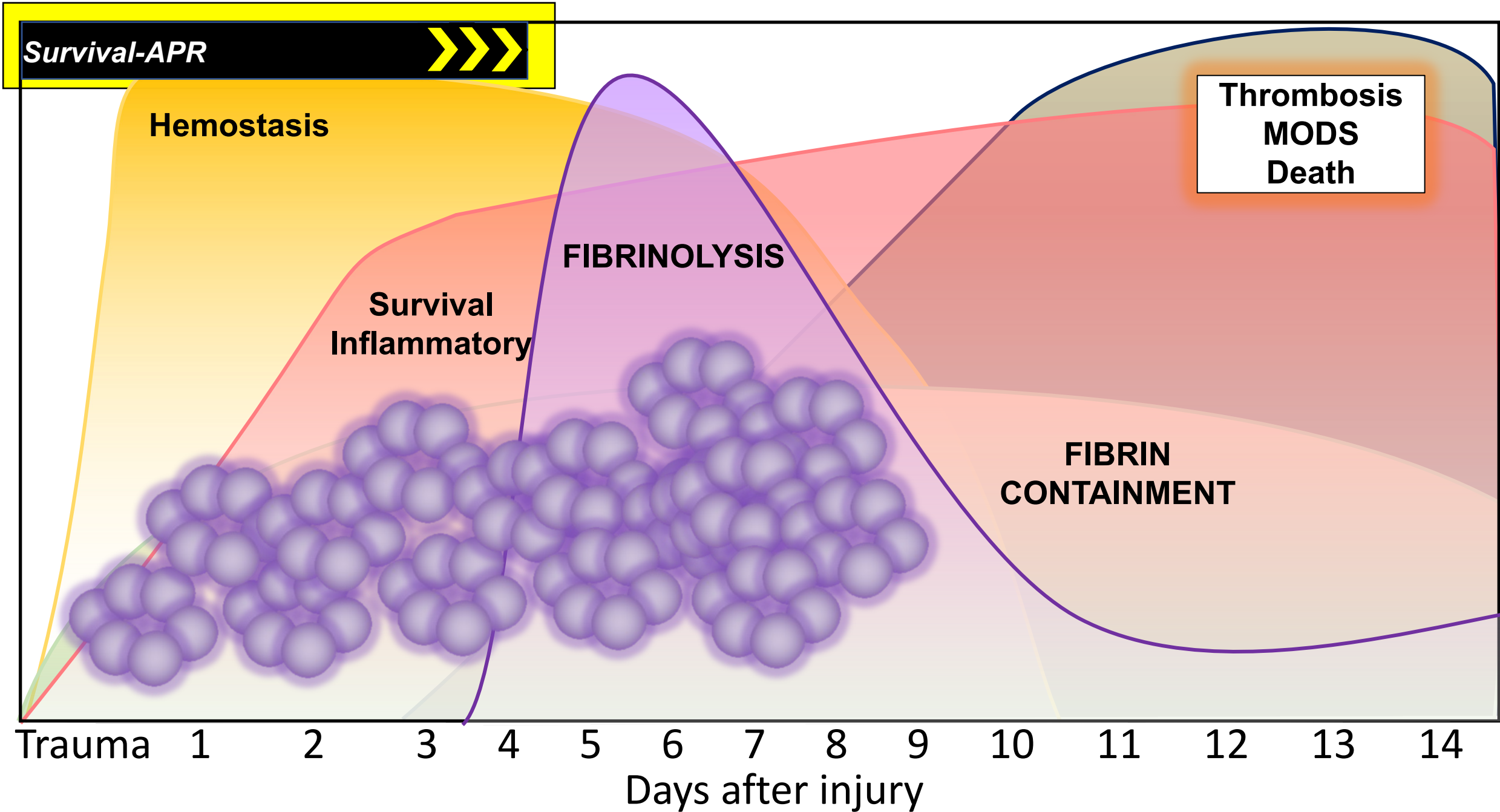
**Thrombosis
MODS
Death**

**FIBRIN
CONTAINMENT**



Trauma 1 2 3 4 5 6 7 8 9 10 11 12 13 14

Days after injury



Musculoskeletal

Infection

Hijacks The

Acute Phase Response

OSTEO

Team-Effort

Where Is It?

Is It A Bug?

How Severe Is It?

Treat It!

4 QUESTIONS

OSTEO

Team-Effort


Where Is It?

Is It A Bug?

How Severe Is It?

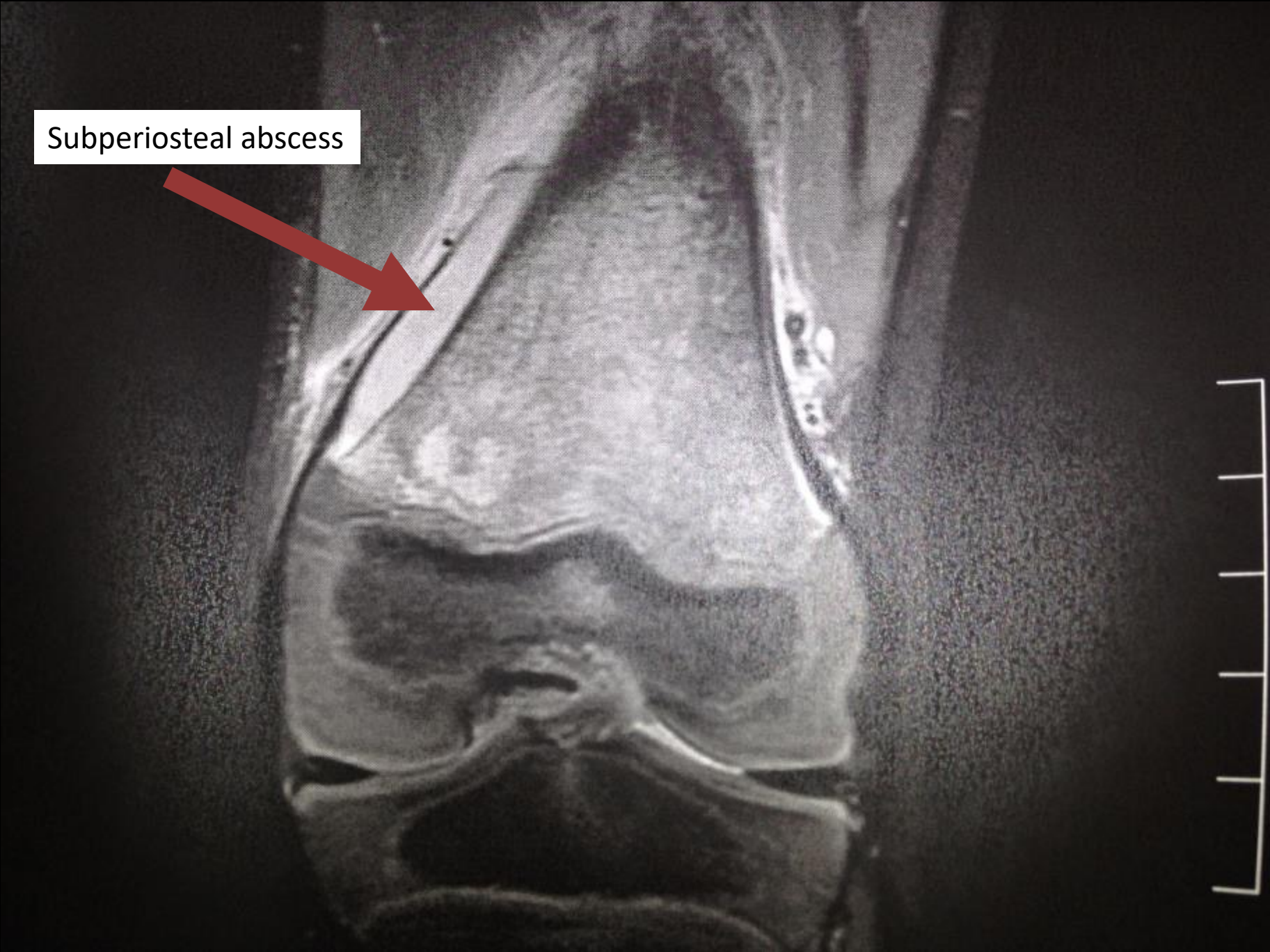
Treat It!

4 QUESTIONS

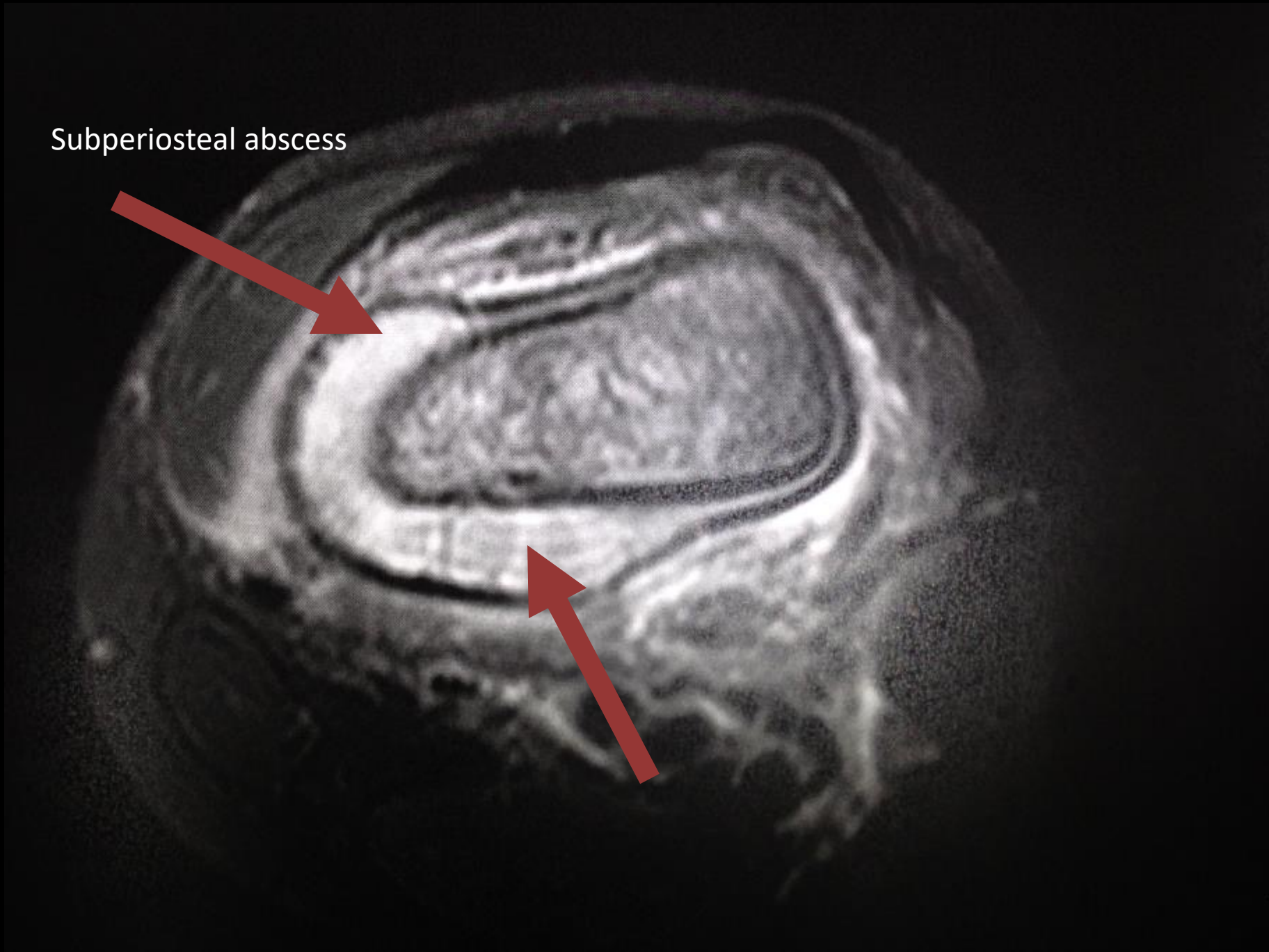

Knife

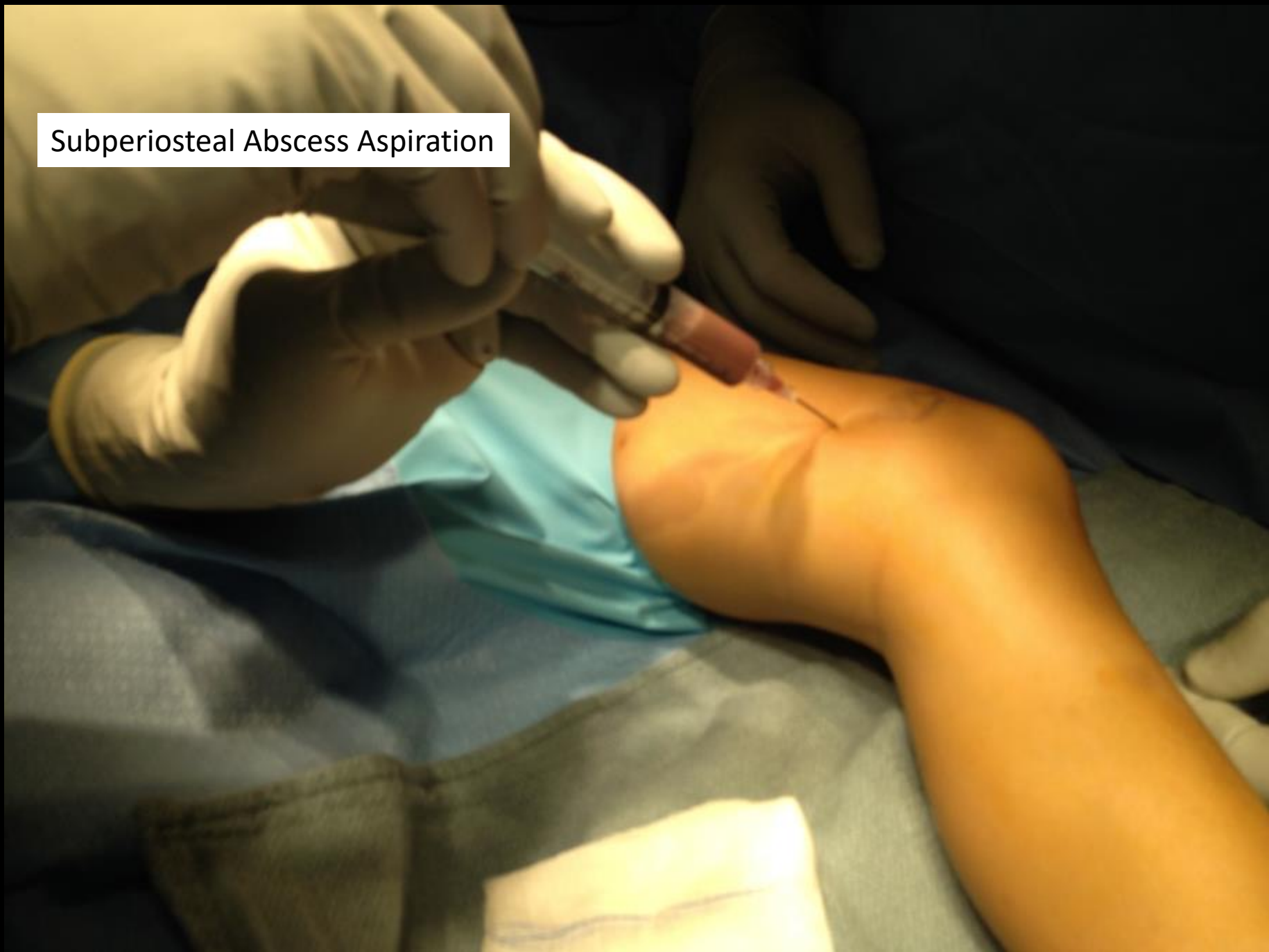Subperiosteal abscess



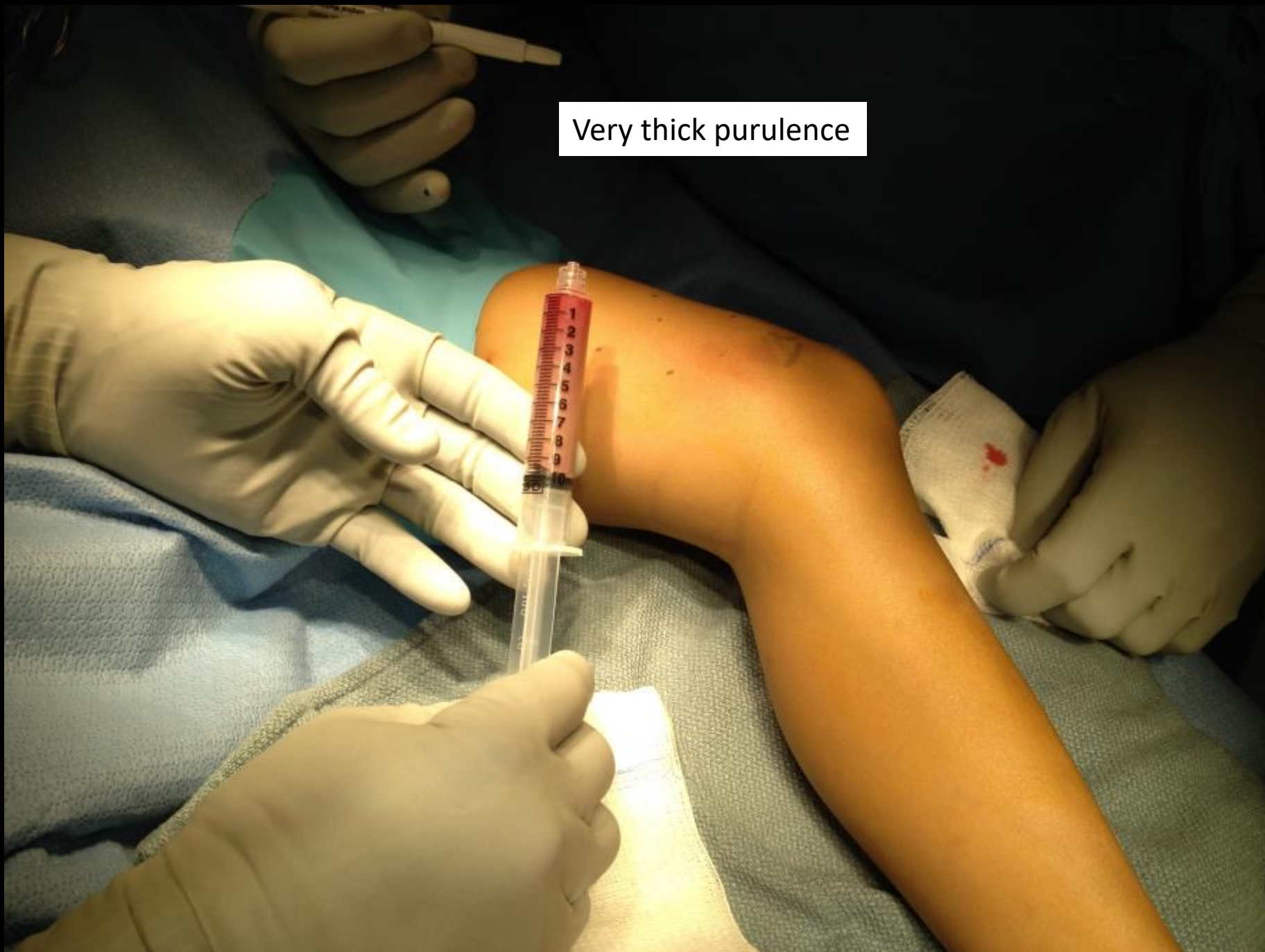Subperiosteal abscess



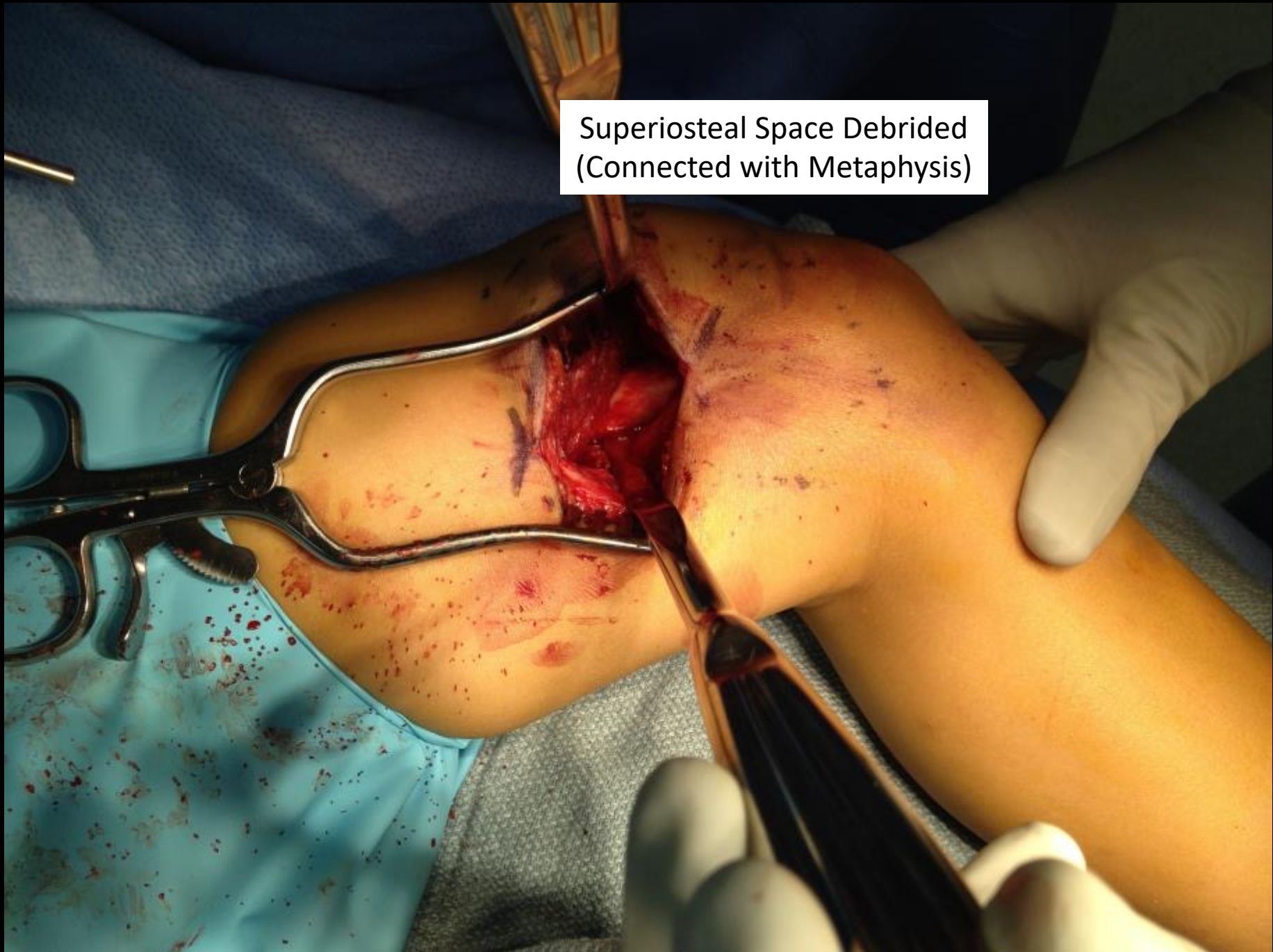
Subperiosteal Abscess Aspiration



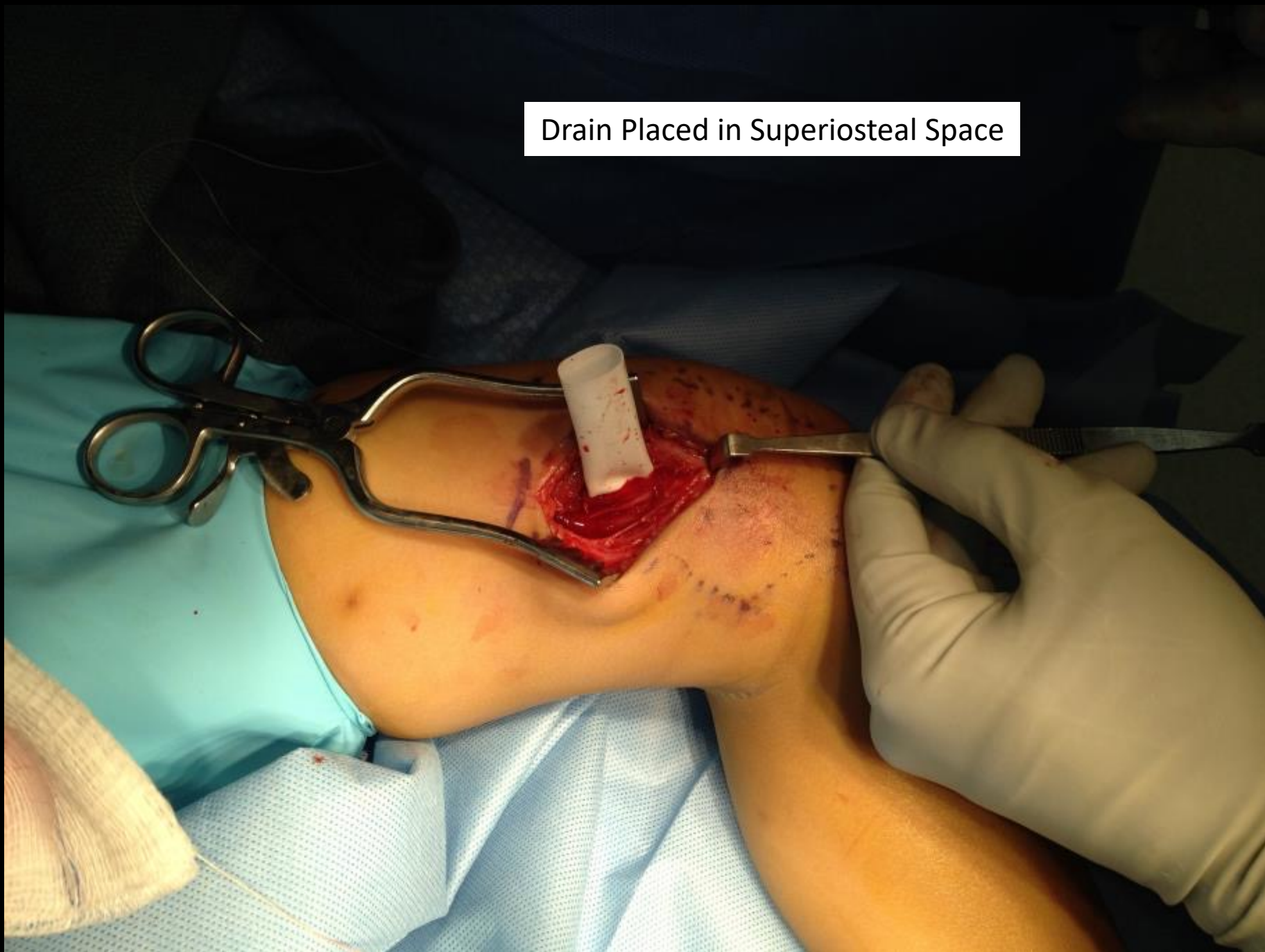Very thick purulence



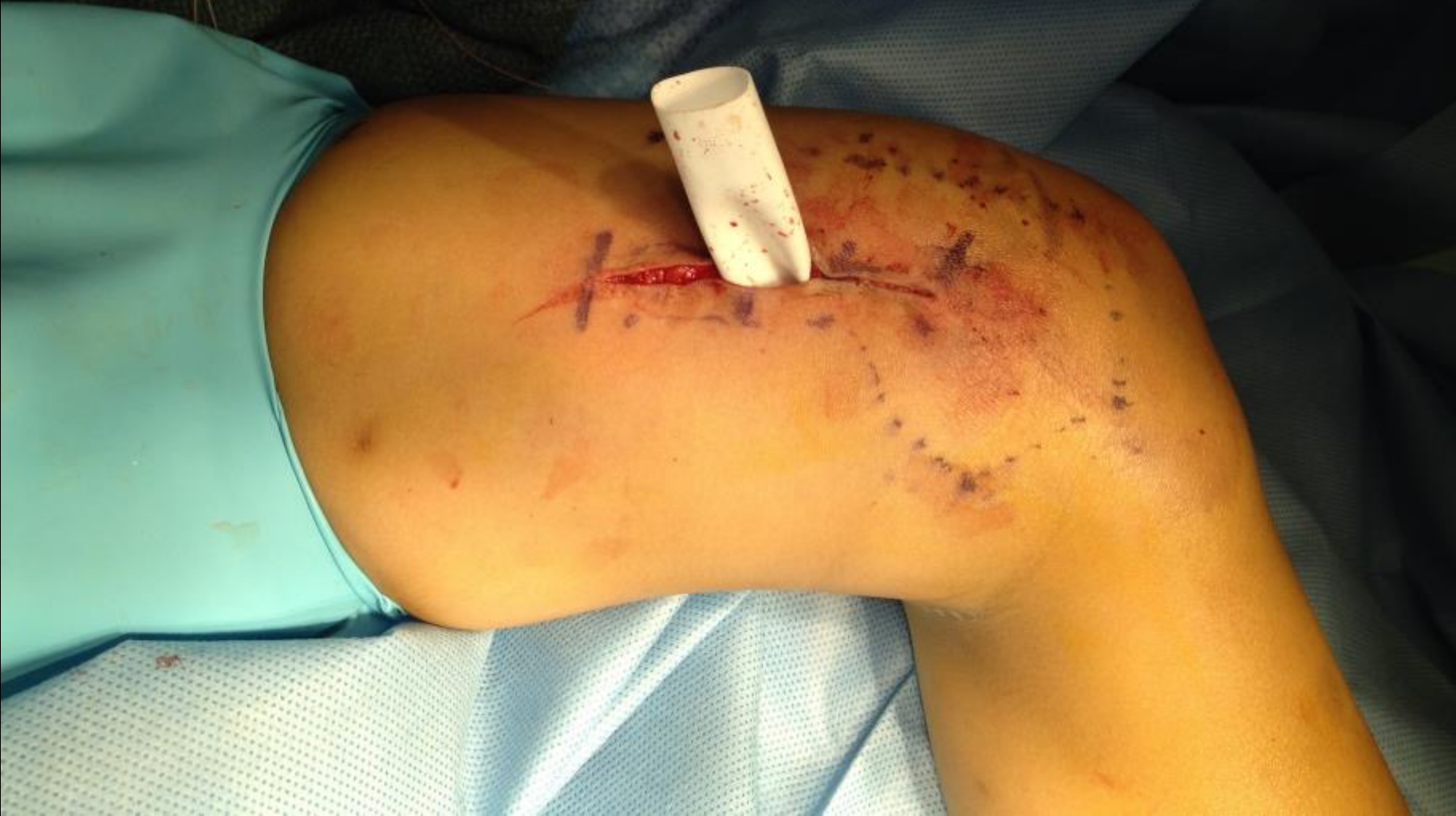Superoiosteal Space Debrided
(Connected with Metaphysis)



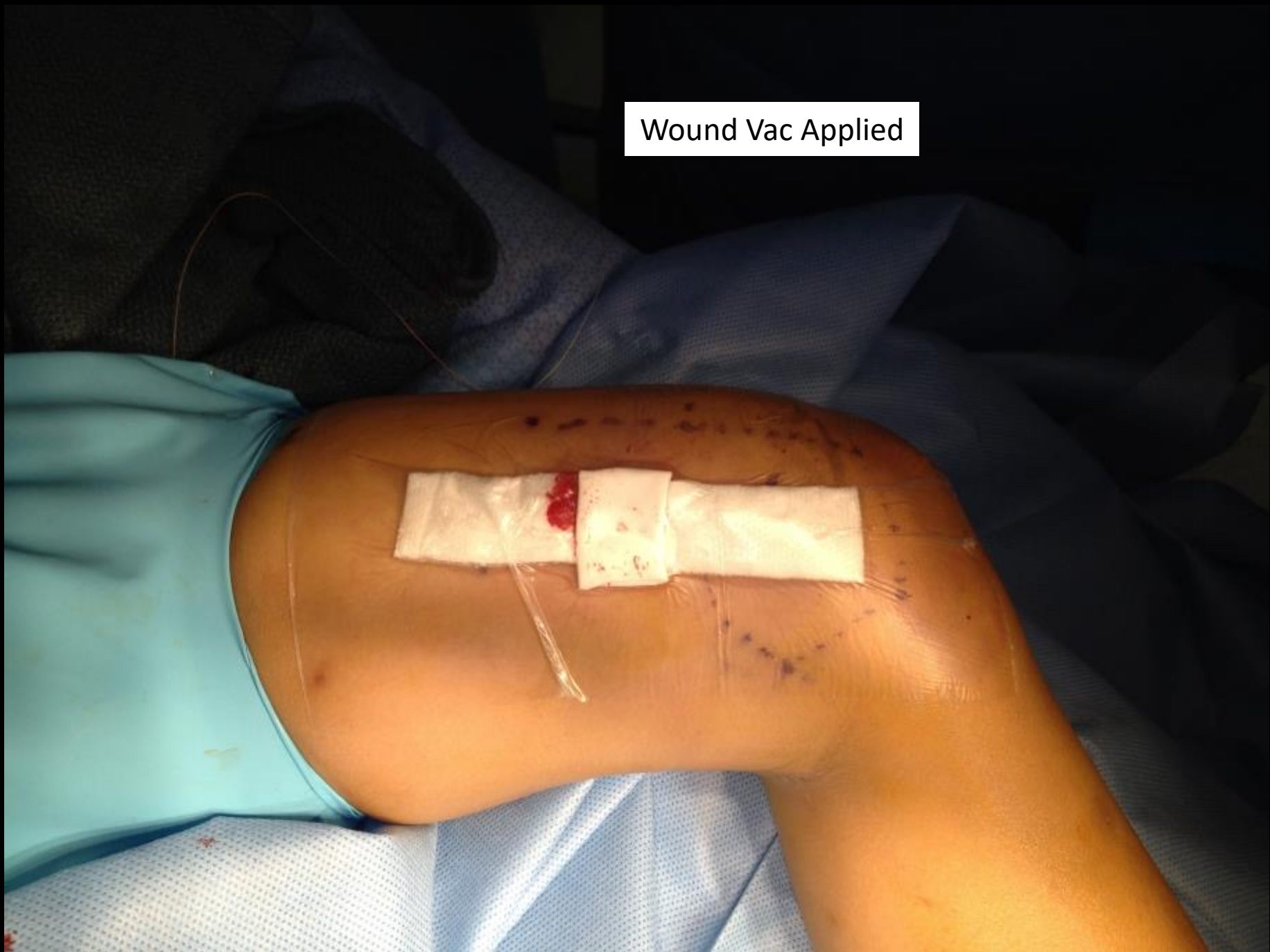Drain Placed in Superiosteal Space



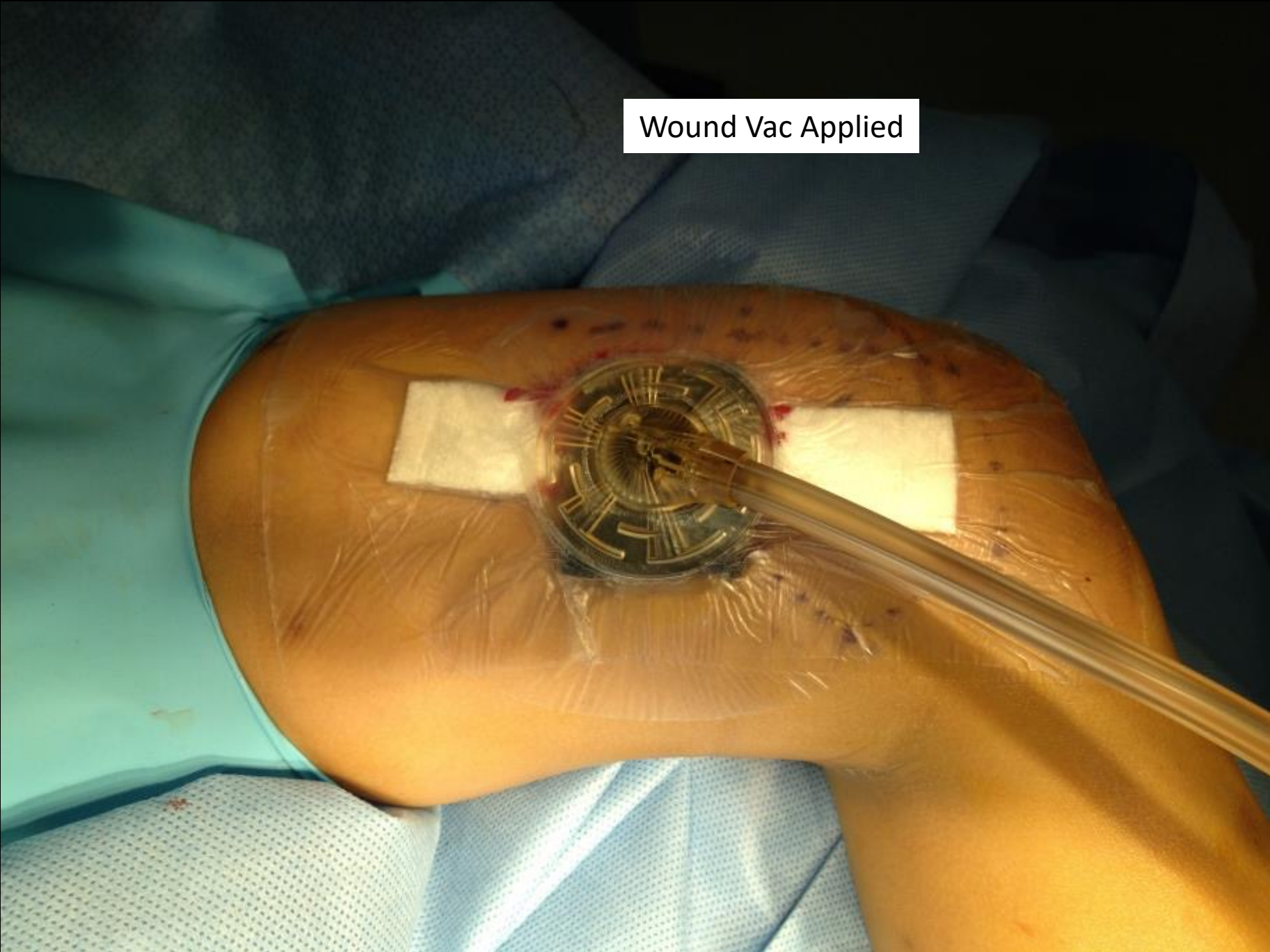Wound closed around drain



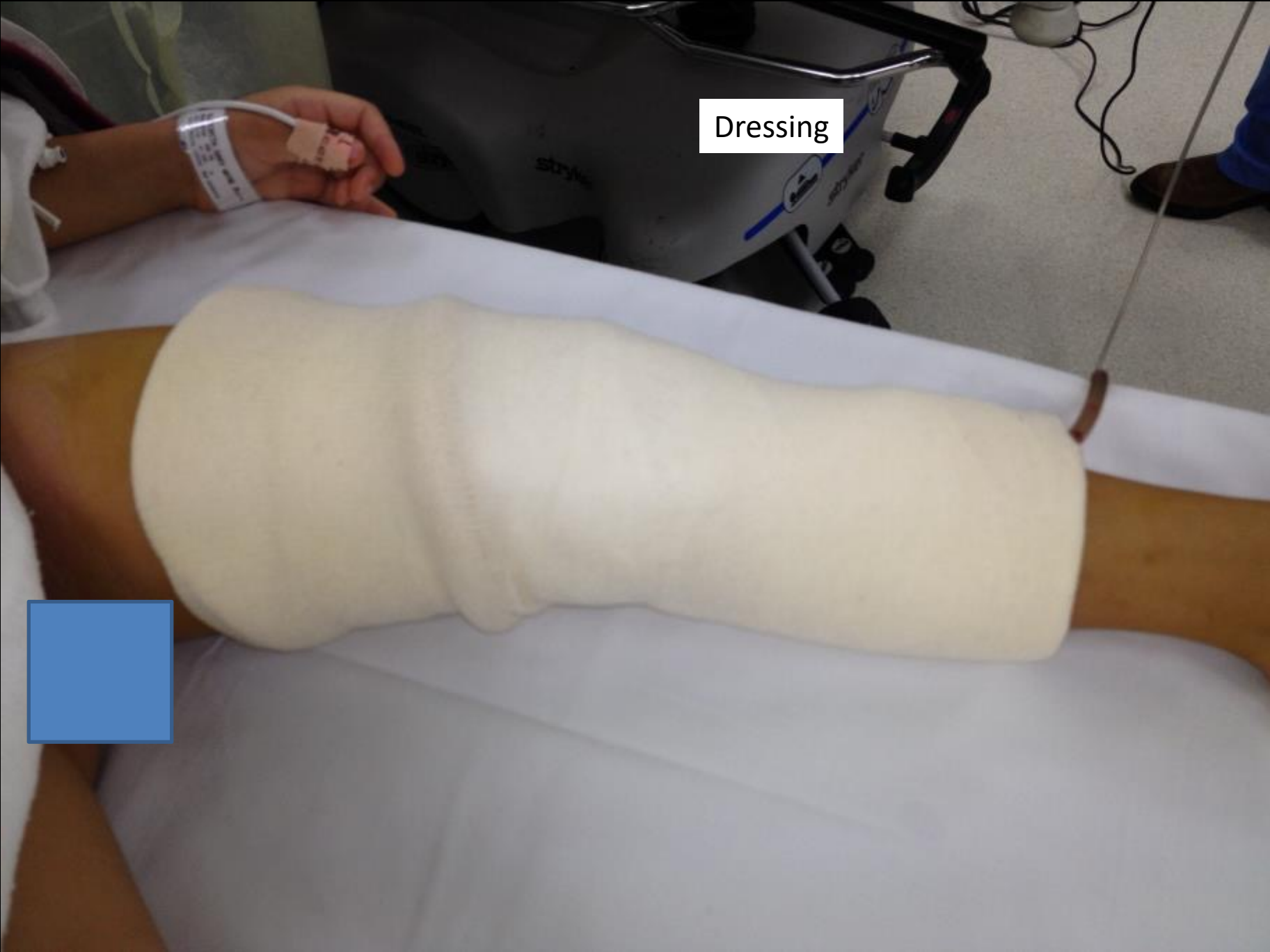Wound Vac Applied



Wound Vac Applied



Dressing





Antibiotics

Antibiotics



Table 4. Snapshot – Antibiotics for Treating MSKI Every Orthopaedic Surgeon Should Know

Class	Beta-Lactams	Glycopeptides	Lincosamides & Aminoglycosides	Rifampin	Lipopeptides
MOA & Key Clinical Features	<ul style="list-style-type: none"> Rapid bactericidal activity by lysing cell wall Overall, well-tolerated with few side effects Allergy is commonly reported; many patients have outgrown these allergies Bacterial resistance is common Administered IV and PO 	<ul style="list-style-type: none"> Bacteriostatic effects by inhibiting bacterial cell wall formation Limited bacterial resistance Administered IV or topically 	<ul style="list-style-type: none"> Elicit bacteriostatic effects by binding to bacterial ribosomal subunits → inhibiting protein synthesis Lincosamides inhibit 50s subunit Aminoglycosides inhibit the 30s subunit 	<ul style="list-style-type: none"> Elicit bactericidal effect by inhibiting bacterial RNA polymerase during replication Administered IV or PO Potential hepatotoxic effects if administered at high concentrations 	<ul style="list-style-type: none"> Rapid, concentration-dependent bactericidal activity Distinct mechanism of action by disrupting multiple aspects of the bacterial cell membrane Limited bacterial resistance Administered IV
Therapeutic Options	<p>Anti-staphylococcal penicillin: (e.g., oxacillin, nafcillin, methicillin, dicloxacillin)</p> <ul style="list-style-type: none"> Resistant to beta-lactamase enzyme commonly produced by <i>S. aureus</i> Used for MSSA infection <p>Cephalosporins: (e.g., cefazolin (ancef), cephalexin (Keflex), cefadroxil) are commonly utilize to treat gram positive MSKI</p> <ul style="list-style-type: none"> 3rd generation: (e.g., cefotaxime, ceftriaxone, cefixime, and cefdinir) have increased stability against gram negative pathogens 5th generation: (e.g., ceftaroline and ceftolizole) include activity against MRSA 	<p>Vancomycin:</p> <ul style="list-style-type: none"> Commonly used as empiric therapy in cases where MRSA, enterococcal, or other serious gram-positive infections are suspected Once culture results are available, narrowing to alternative agents is essential Vancomycin is inferior to beta-lactams in susceptible strains <p>New Therapeutics: (e.g., dalbavancin and oritavancin)</p> <ul style="list-style-type: none"> Very long half-lives and simplified dosing regimens Potential for intermittent (e.g. weekly) dosing Studies presently ongoing examining optimal dosing 	<p>Clindamycin:</p> <ul style="list-style-type: none"> Effective against gram positive and anaerobic pathogens effective at limiting toxin-mediated illness (e.g. Group A streptococcus and <i>S. aureus</i>) given their effect on protein synthesis Excellent activity against MRSA Growing bacterial resistance, up to 20% in some regions Administered PO <p>Aminoglycosides: (e.g., gentamicin, tobramycin, amikacin)</p> <ul style="list-style-type: none"> Broad spectrum activity Effective against gram negative organisms Narrow therapeutic window Significant ototoxicity and nephrotoxicity 	<p>Rifampin:</p> <ul style="list-style-type: none"> Effective against a wide variety of gram-positive and gram-negative organisms, particularly staphylococcus Administered in combination with other agents to increase potency 	<p>Daptomycin:</p> <ul style="list-style-type: none"> Effective against gram positive pathogens, including MRSA Effective alternative in cases where vancomycin is ineffective Studies presently ongoing examining optimal dosing Randomized clinical trials still required for MSKI
Highlights for MSKI	<ul style="list-style-type: none"> Cephalexin is well absorbed orally and has good bone penetration 5th generation cephalosporins can be useful in patients where disseminated disease is suspected 	<ul style="list-style-type: none"> Useful in patients where disseminated disease is suspected Vancomycin troughs can impede resolution of MSKI; therefore, monitoring may be required 	<ul style="list-style-type: none"> Clindamycin has great oral bioavailability and penetration into tissues Given aminoglycosides risk profile, agents form other classes are often a more appropriate first-line therapy 	<ul style="list-style-type: none"> Extreme tissue penetration Useful adjunct therapy to treat MSKI where indwelling hardware or prostheses are present 	<ul style="list-style-type: none"> Excellent soft tissue and bone penetrance Has bactericidal activity within biofilms



OSTEO

Team-Effort

Where Is It?

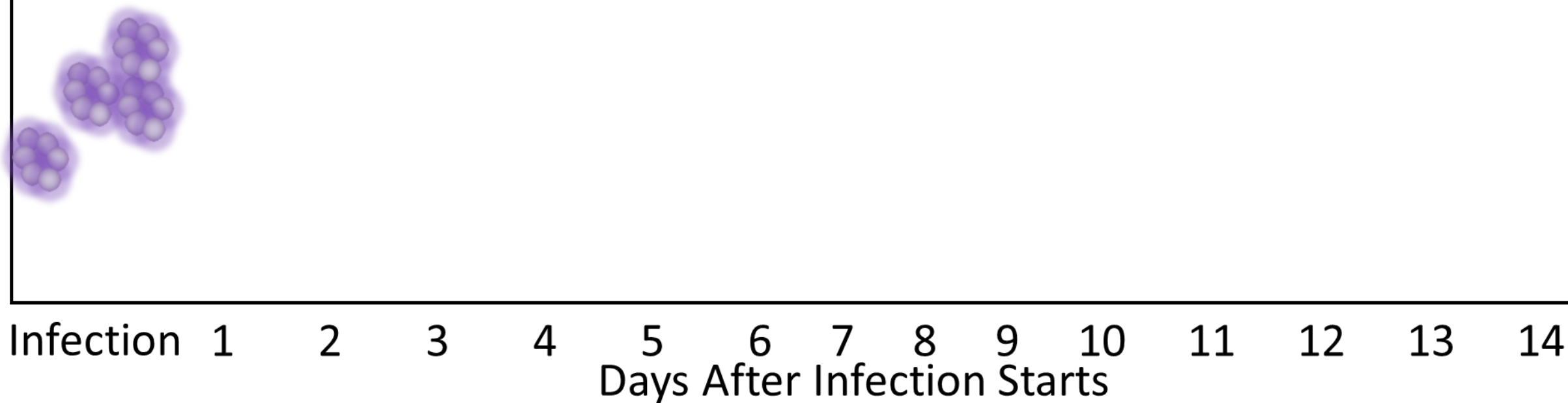
Is It A Bug?

How Severe Is It?

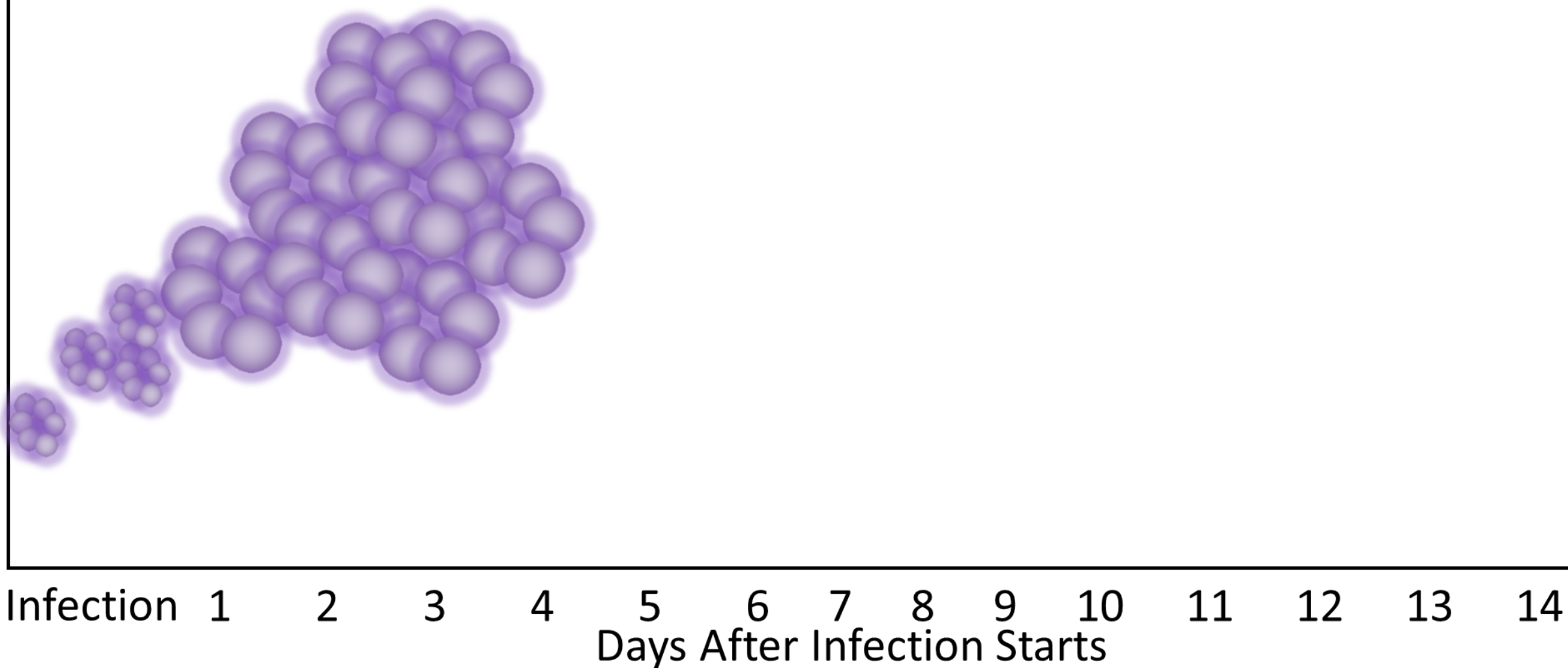
Treat It!

4 QUESTIONS

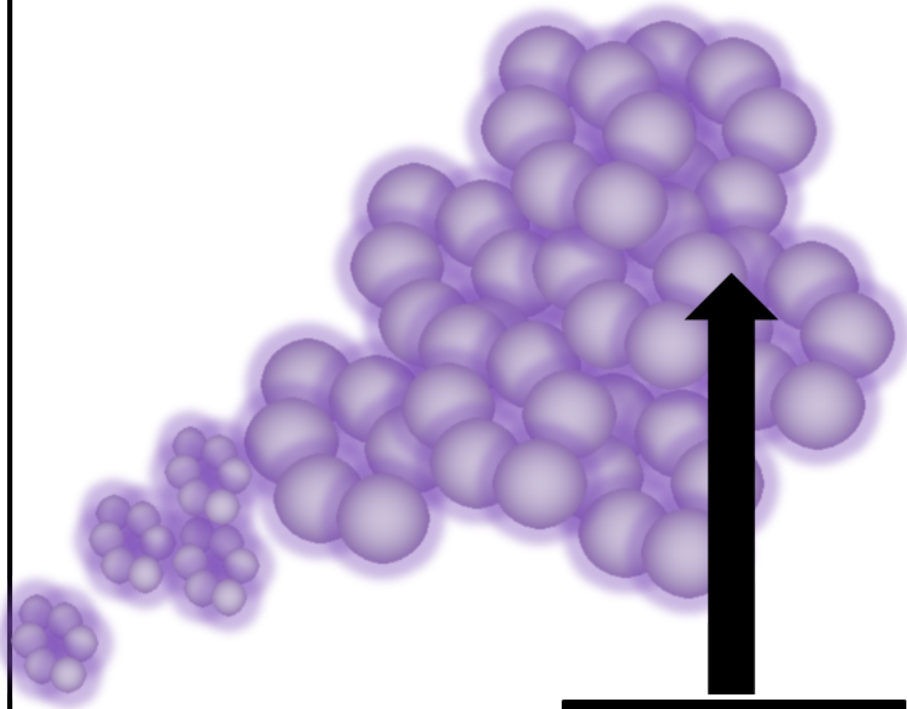
ACTIVE INFECTION
(Survival-APR)



ACTIVE INFECTION – “CONTINUOUS INJURY”
(Survival-APR)



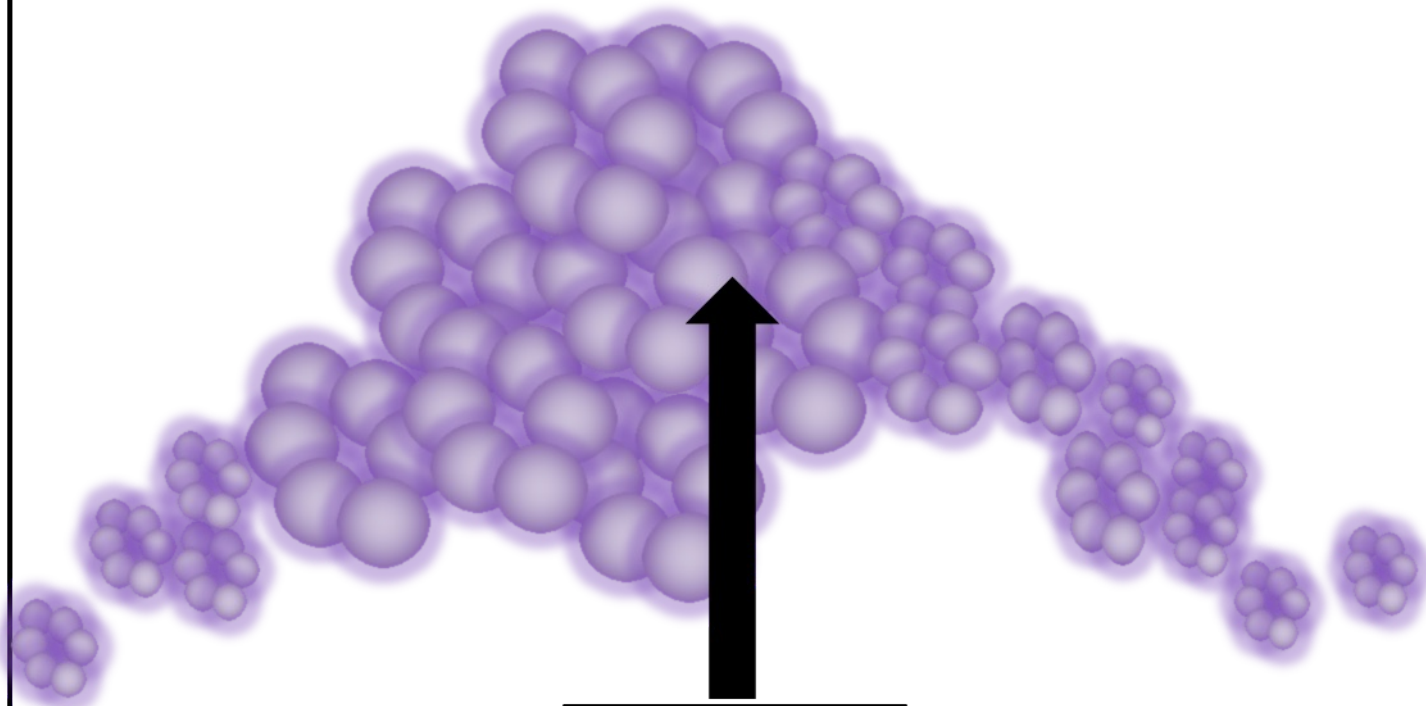
ACTIVE INFECTION – “CONTINUOUS INJURY”
(Survival-APR)



**Antibiotics
Surgery**

Infection 1 2 3 4 5 6 7 8 9 10 11 12 13 14
Days After Infection Starts

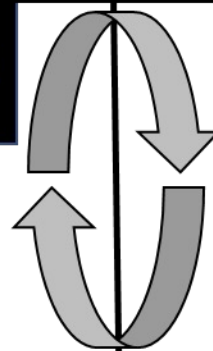
ACTIVE INFECTION – “CONTINUOUS INJURY”
(Survival-APR)



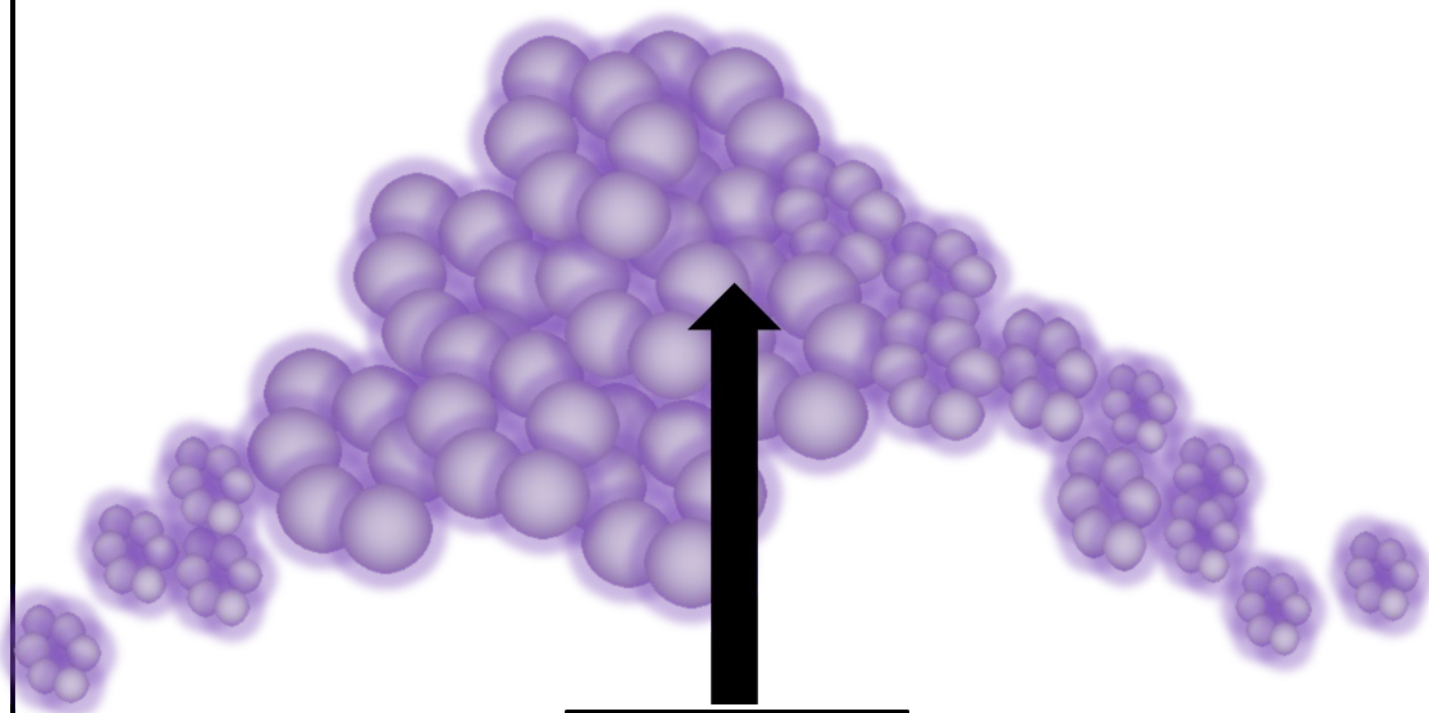
**Antibiotics
Surgery**

Infection 1 2 3 4 5 6 7 8 9 10 11 12 13 14
Days After Infection Starts

ACTIVE INFECTION – “CONTINUOUS INJURY”
(Survival-APR)



INFECTION CONVALESCENCE
(Repair-APR)



**Antibiotics
Surgery**

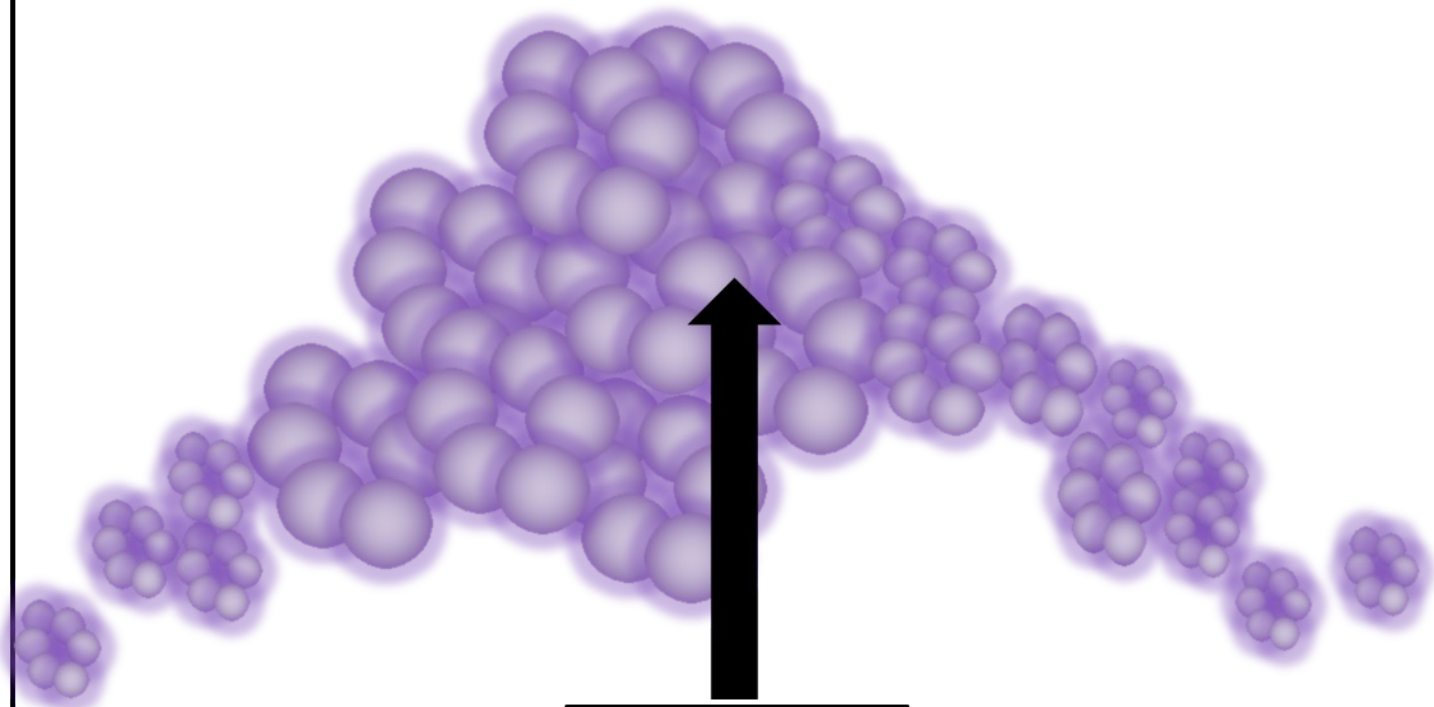
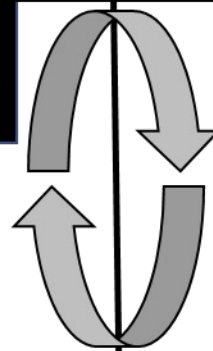
Infection 1 2 3 4 5 6 7 8 9 10 11 12 13 14
Days After Infection Starts

ACTIVE INFECTION – “CONTINUOUS INJURY”
(Survival-APR)



INFECTION CONVALESCENCE
(Repair-APR)

FEBRILE



**Antibiotics
Surgery**

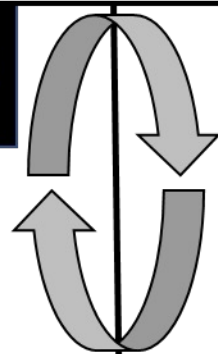
Infection 1 2 3 4 5 6 7 8 9 10 11 12 13 14
Days After Infection Starts

ACTIVE INFECTION – “CONTINUOUS INJURY”
(Survival-APR)

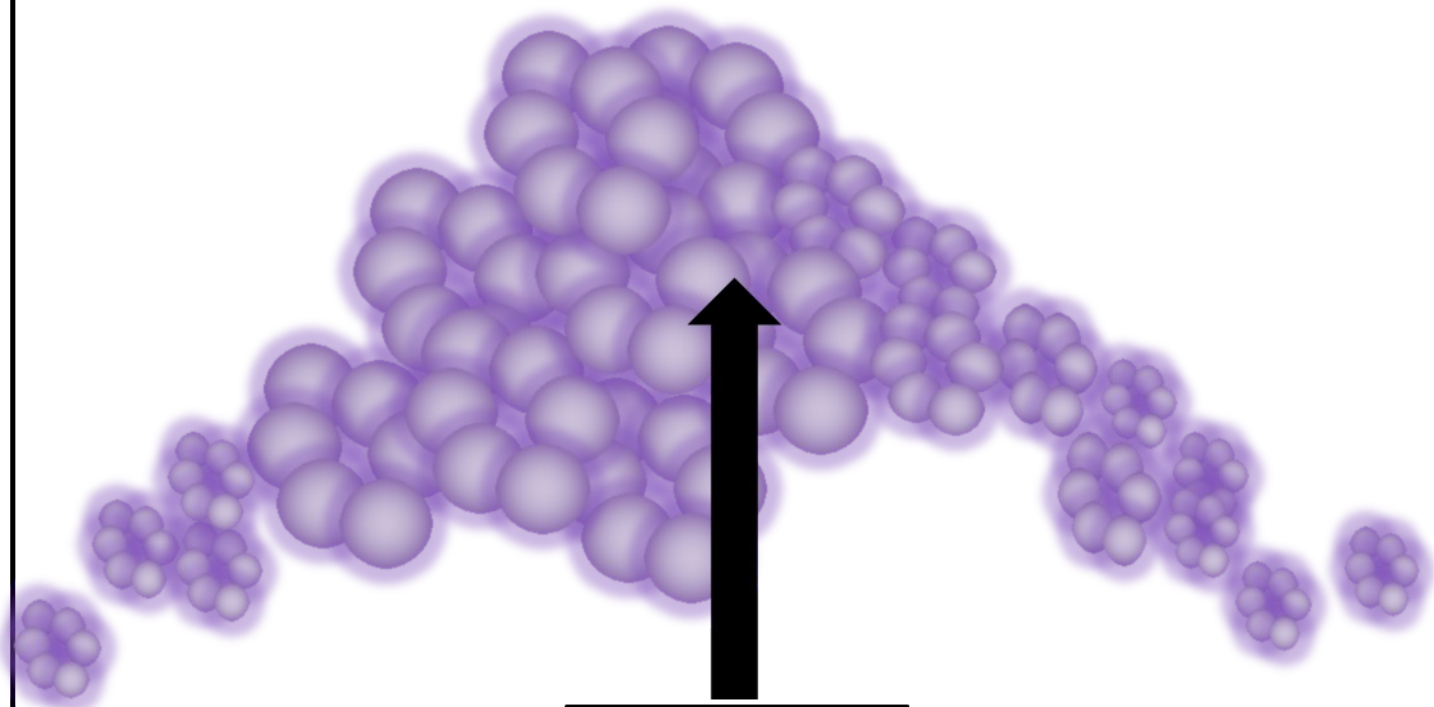


INFECTION CONVALESCENCE
(Repair-APR)

FEBRILE



AFEBRILE



**Antibiotics
Surgery**

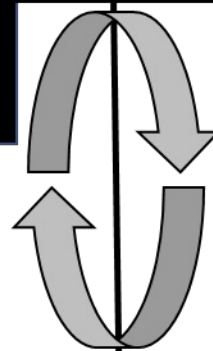
Infection 1 2 3 4 5 6 7 8 9 10 11 12 13 14
Days After Infection Starts

ACTIVE INFECTION – “CONTINUOUS INJURY”
(Survival-APR)



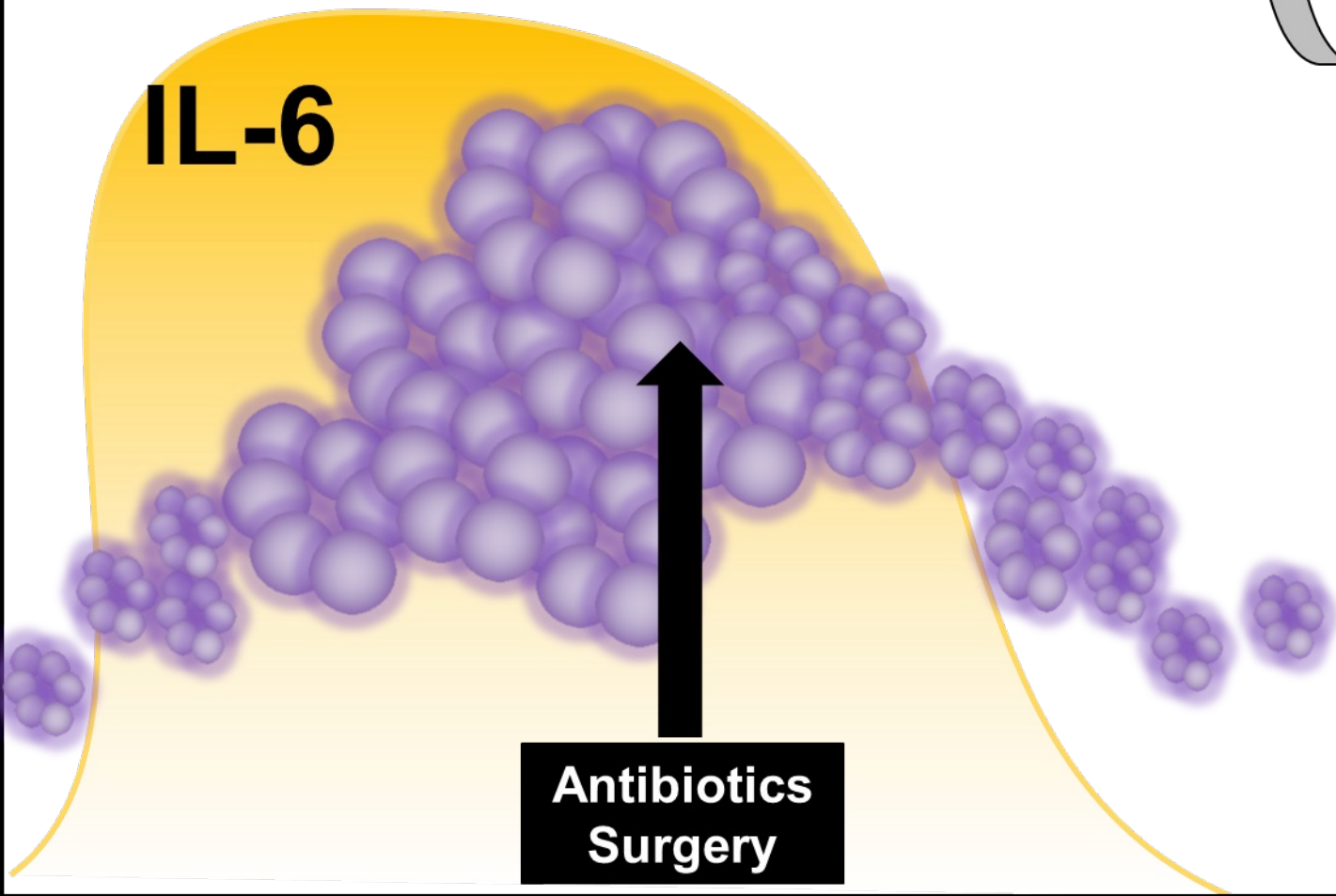
INFECTION CONVALESCENCE
(Repair-APR)

FEBRILE



AFEBRILE

IL-6



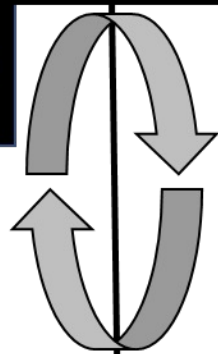
**Antibiotics
Surgery**

Infection 1 2 3 4 5 6 7 8 9 10 11 12 13 14
Days After Infection Starts

ACTIVE INFECTION – “CONTINUOUS INJURY”
(Survival-APR)



INFECTION CONVALESCENCE
(Repair-APR)



FEBRILE

AFEBRILE

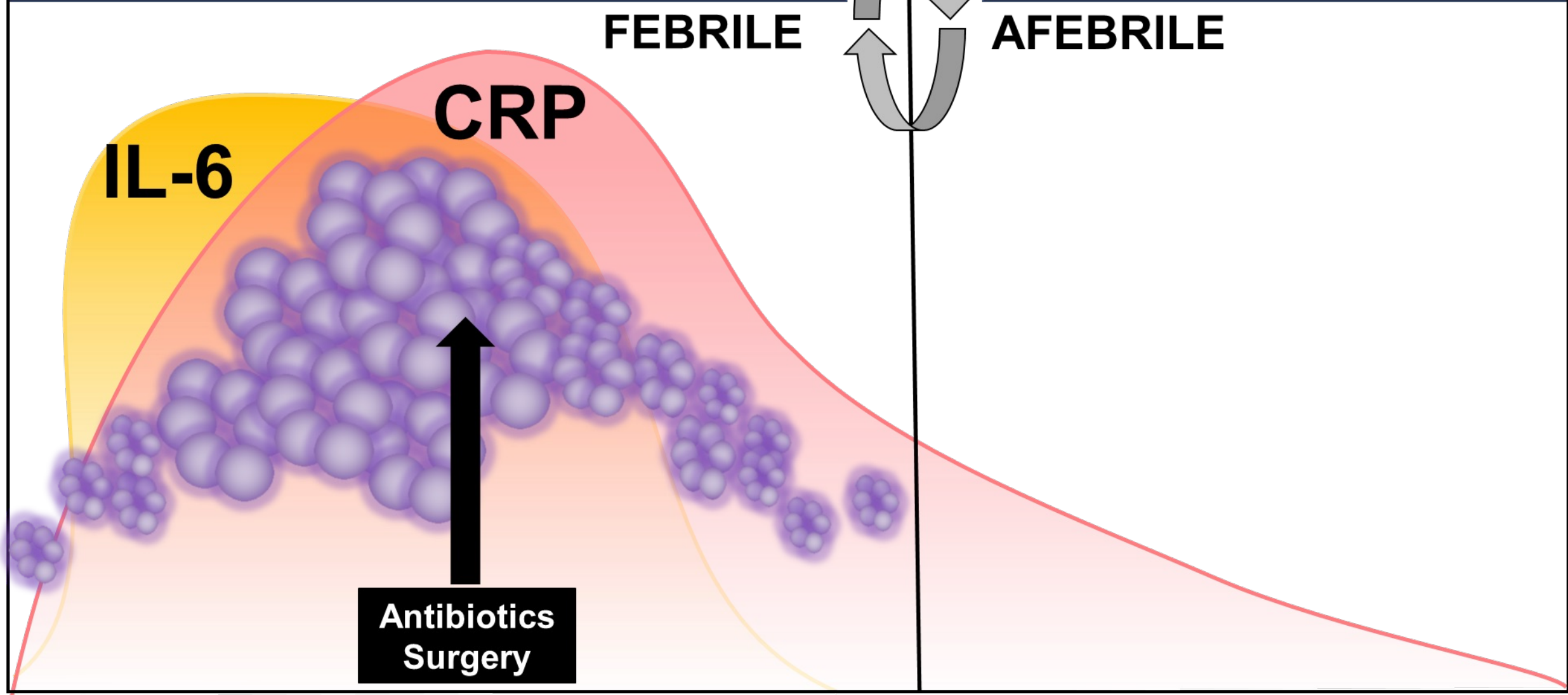
CRP

IL-6



**Antibiotics
Surgery**

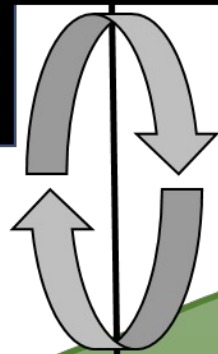
Infection 1 2 3 4 5 6 7 8 9 10 11 12 13 14
Days After Infection Starts



ACTIVE INFECTION – “CONTINUOUS INJURY”
(Survival-APR)



INFECTION CONVALESCENCE
(Repair-APR)



FEBRILE

AFEBRILE

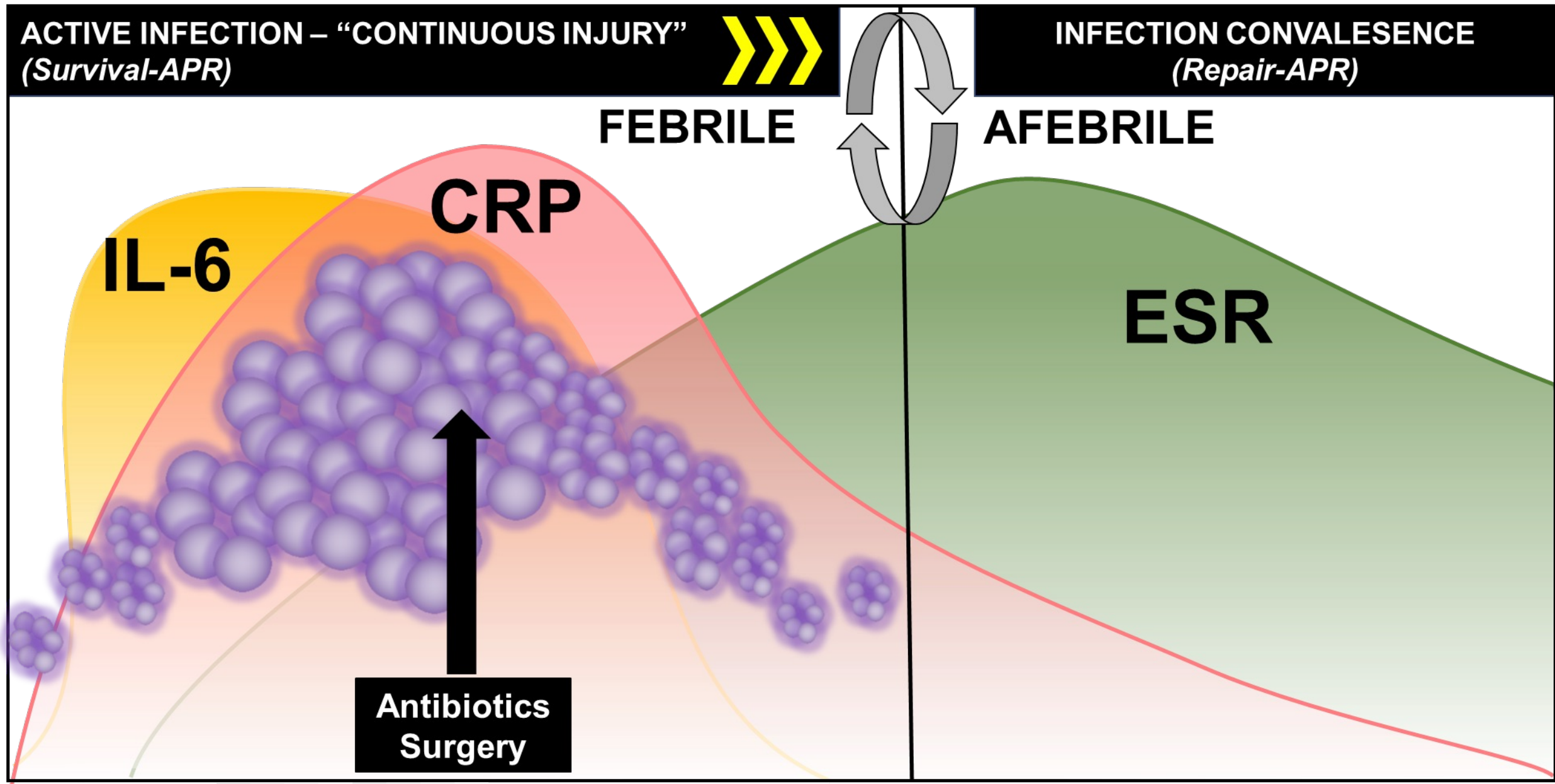
IL-6

CRP

ESR

**Antibiotics
Surgery**

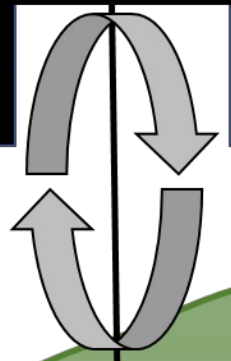
Infection 1 2 3 4 5 6 7 8 9 10 11 12 13 14
Days After Infection Starts



ACTIVE INFECTION – “CONTINUOUS INJURY”
(Survival-APR)



INFECTION CONVALESCENCE
(Repair-APR)



FEBRILE

AFEBRILE

CRP

IL-6

ESR

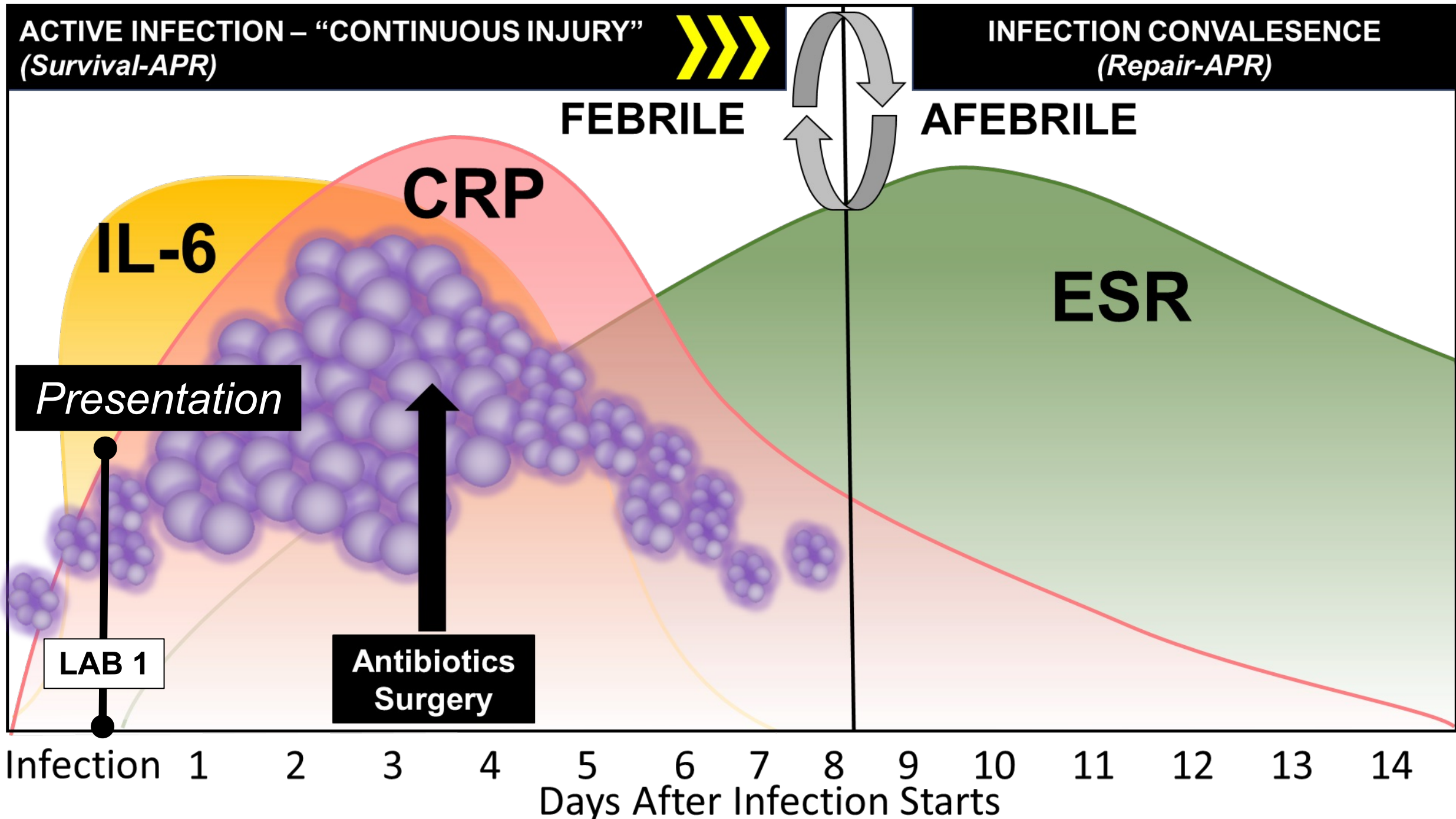
Presentation

LAB 1

**Antibiotics
Surgery**

Infection 1 2 3 4 5 6 7 8 9 10 11 12 13 14

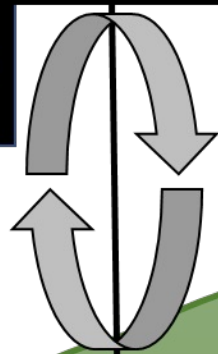
Days After Infection Starts



ACTIVE INFECTION – “CONTINUOUS INJURY”
(Survival-APR)



INFECTION CONVALESCENCE
(Repair-APR)



FEBRILE

AFEBRILE

CRP

ESR

IL-6

Presentation

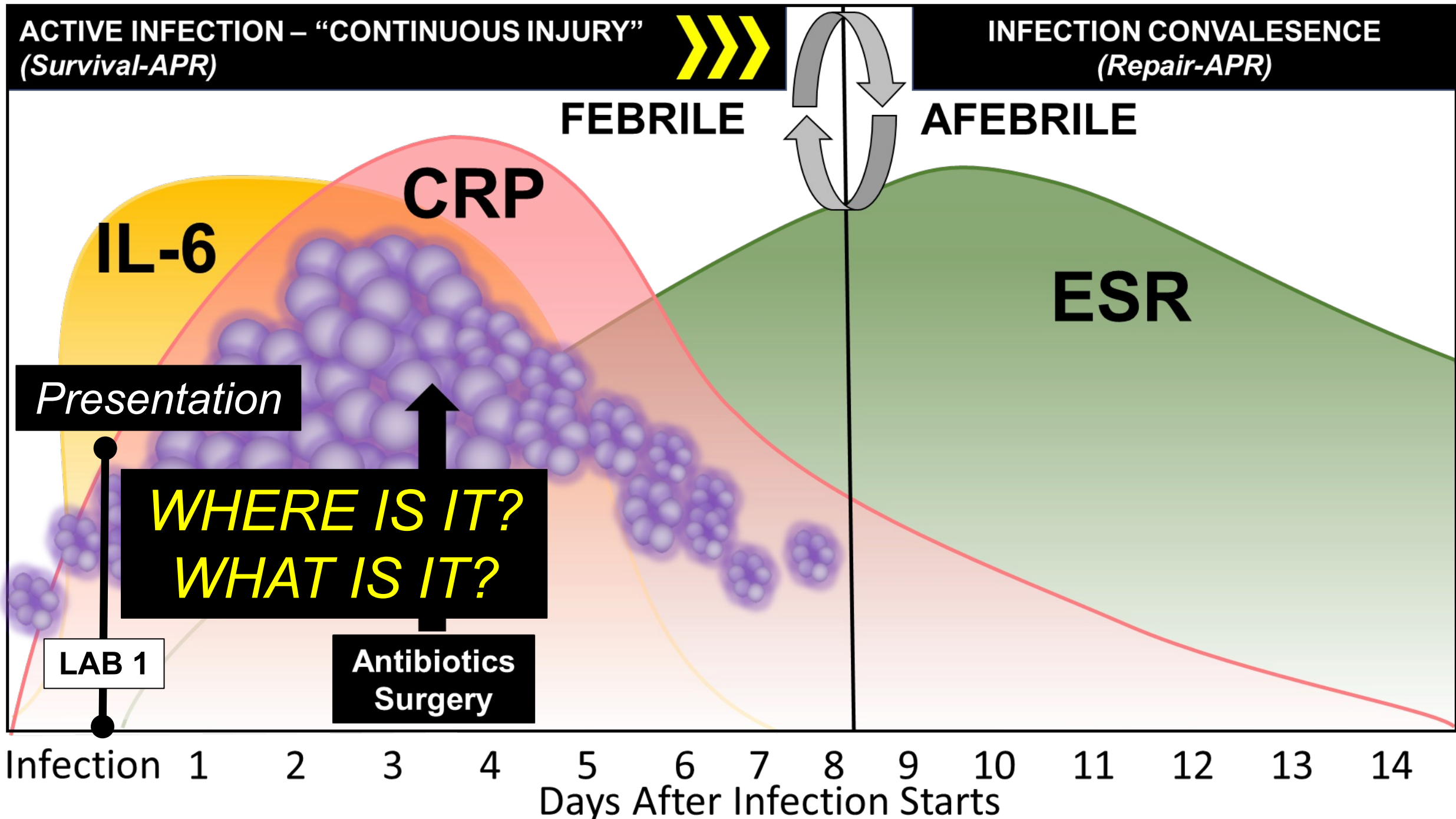
**WHERE IS IT?
WHAT IS IT?**

LAB 1

**Antibiotics
Surgery**

Infection 1 2 3 4 5 6 7 8 9 10 11 12 13 14

Days After Infection Starts

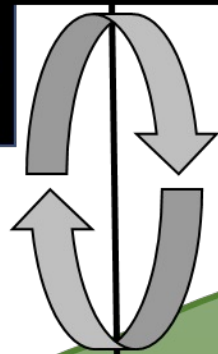


ACTIVE INFECTION – “CONTINUOUS INJURY”
(Survival-APR)



INFECTION CONVALESCENCE
(Repair-APR)

FEBRILE



AFEBRILE

CRP

IL-6

ESR

**WHERE IS IT?
WHAT IS IT?**

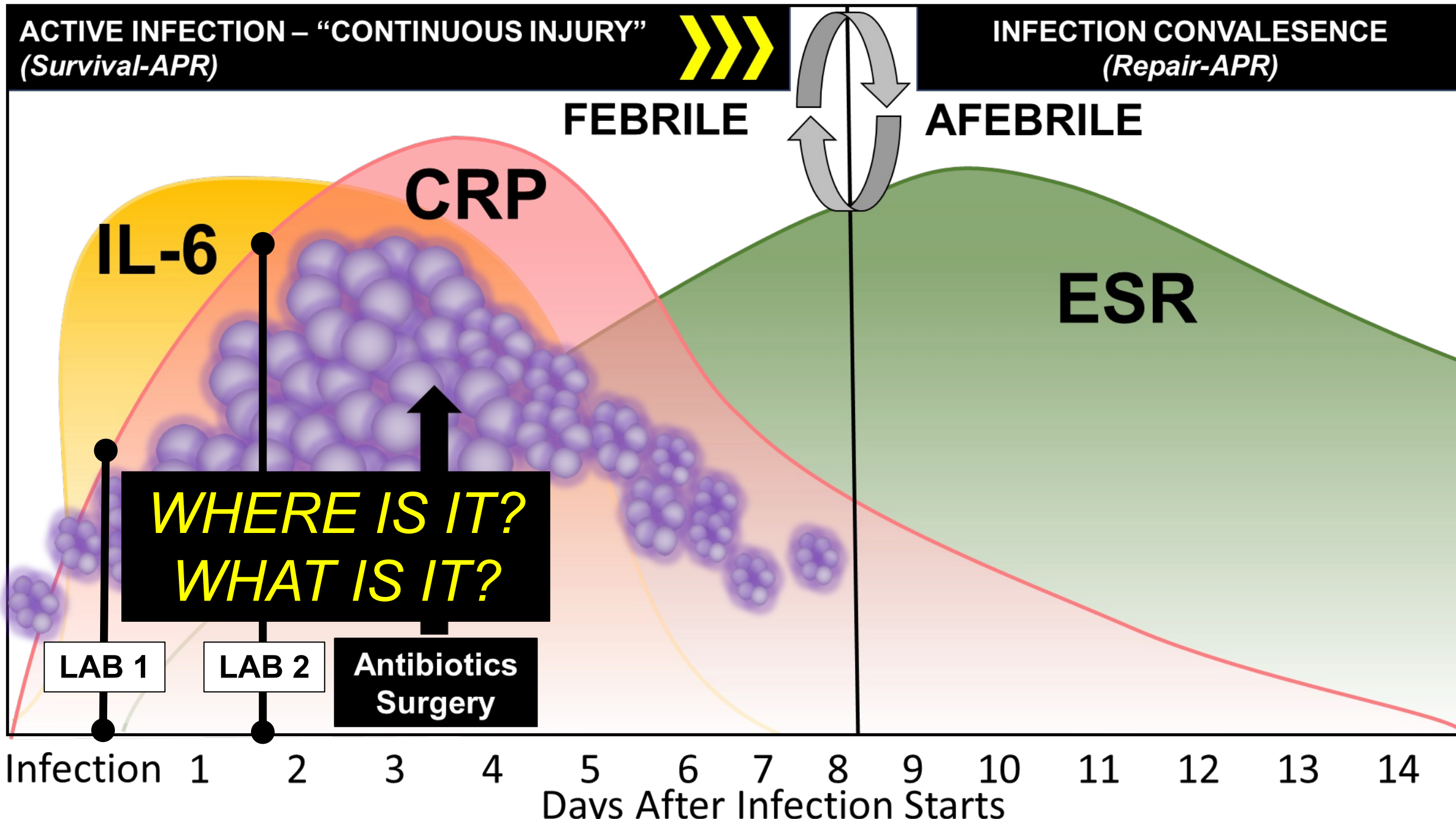
LAB 1

LAB 2

**Antibiotics
Surgery**

Infection 1 2 3 4 5 6 7 8 9 10 11 12 13 14

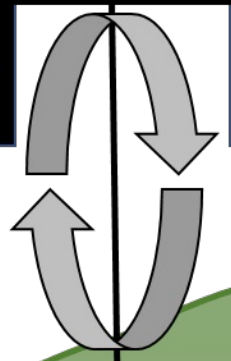
Days After Infection Starts



ACTIVE INFECTION – “CONTINUOUS INJURY”
(Survival-APR)



INFECTION CONVALESCENCE
(Repair-APR)



FEBRILE

AFEBRILE

Progression?

CRP

ESR

IL-6

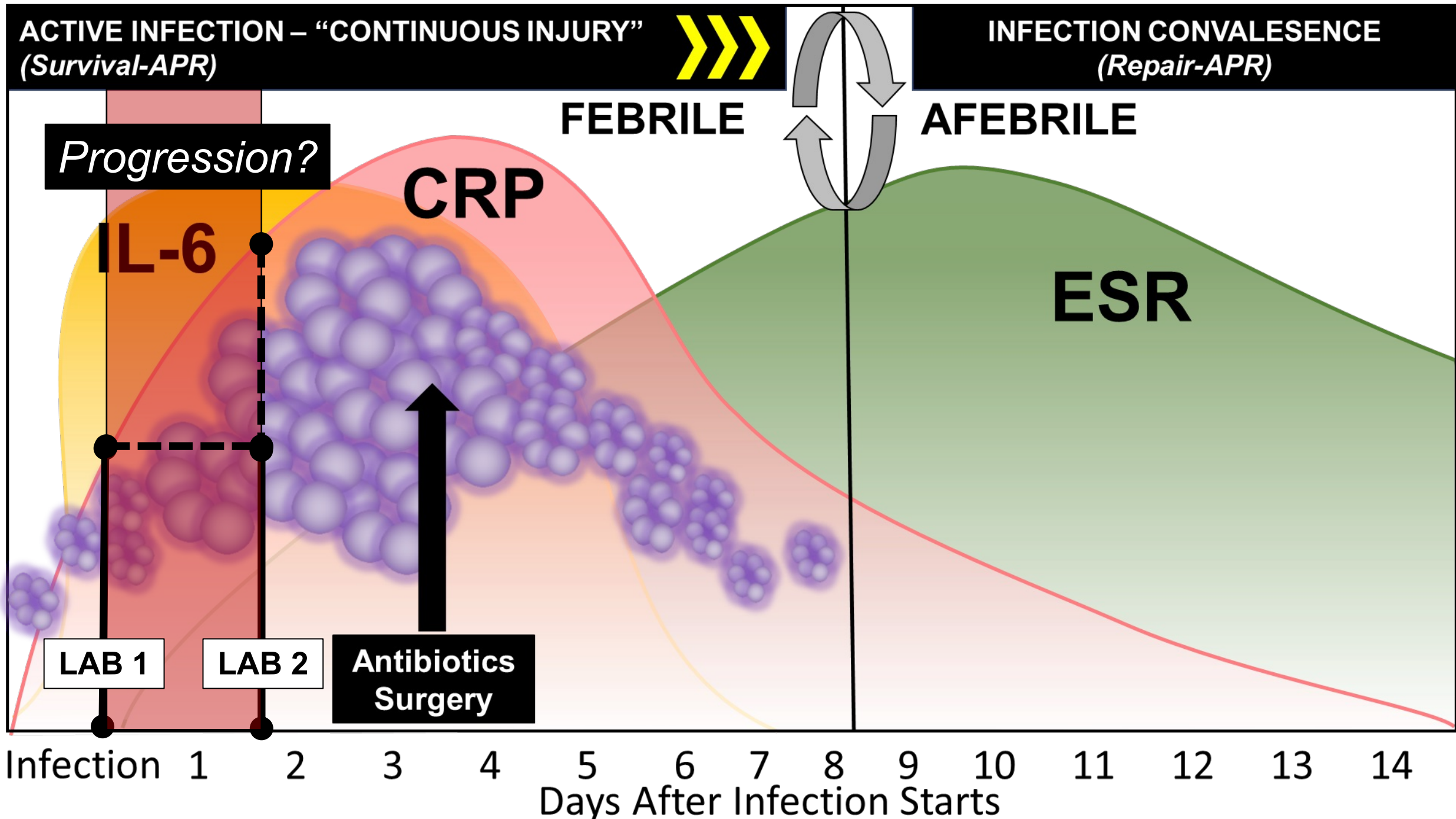
LAB 1

LAB 2

**Antibiotics
Surgery**

Infection 1 2 3 4 5 6 7 8 9 10 11 12 13 14

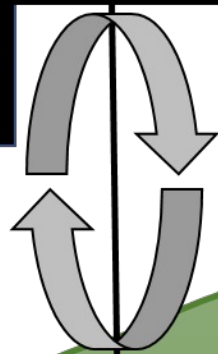
Days After Infection Starts



ACTIVE INFECTION – “CONTINUOUS INJURY”
(Survival-APR)



INFECTION CONVALESCENCE
(Repair-APR)



Peak Values

FEBRILE

AFEBRILE

CRP

IL-6

How Severe is It?

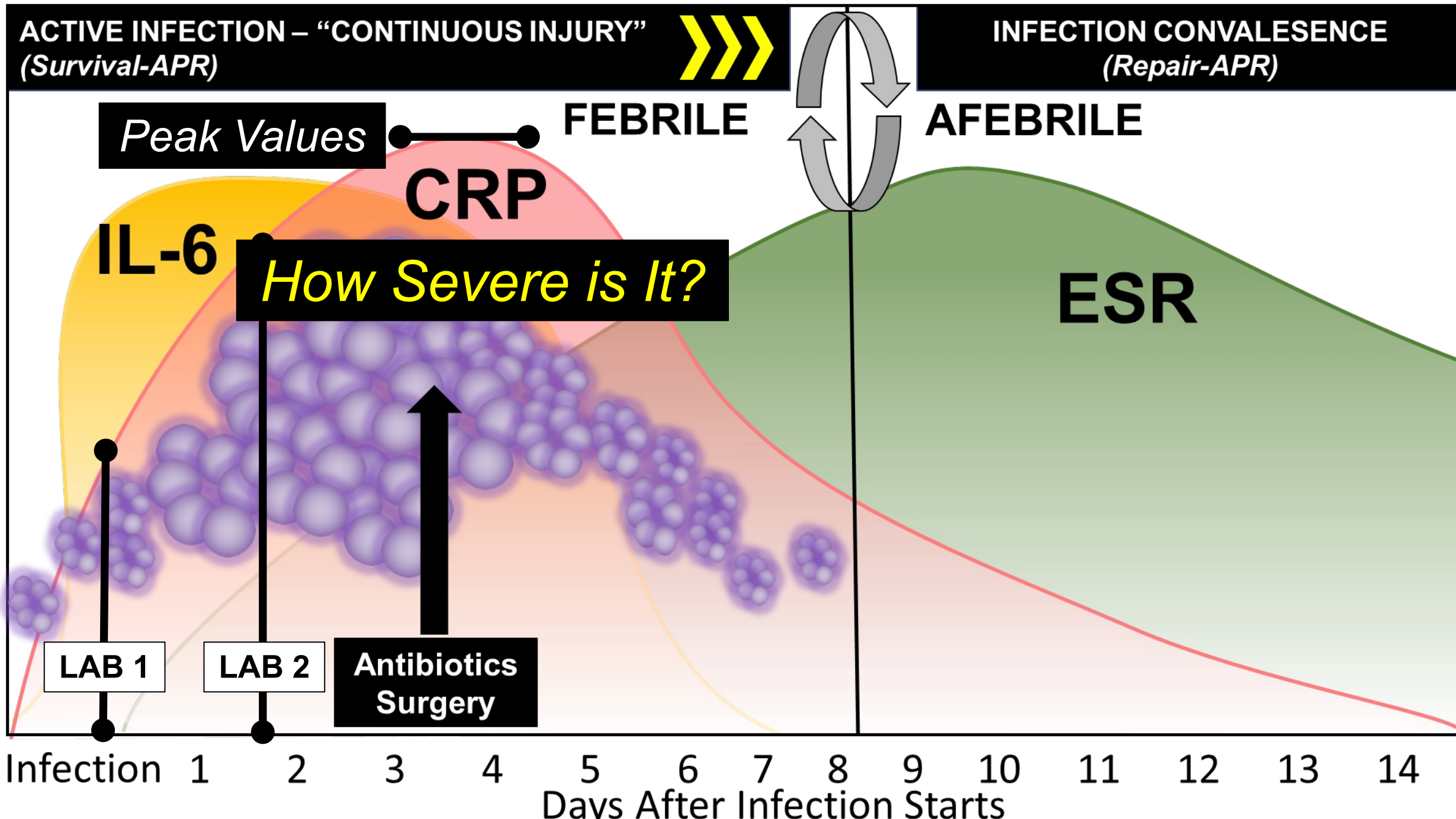
ESR

LAB 1

LAB 2

**Antibiotics
Surgery**

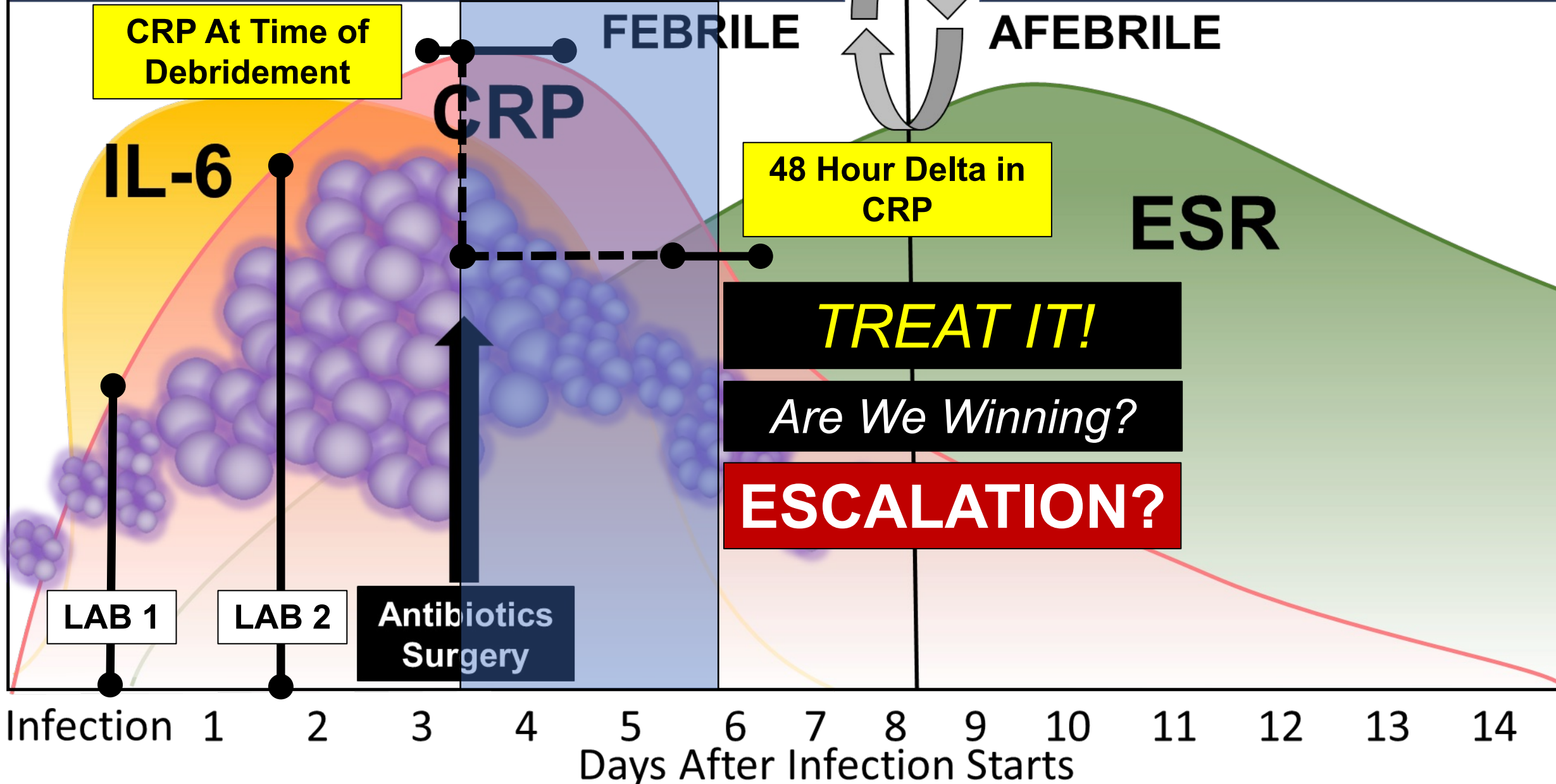
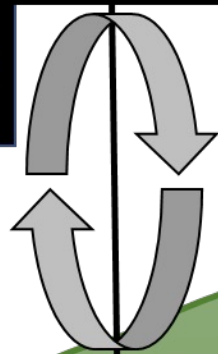
Infection 1 2 3 4 5 6 7 8 9 10 11 12 13 14
Days After Infection Starts



ACTIVE INFECTION – “CONTINUOUS INJURY”
(Survival-APR)



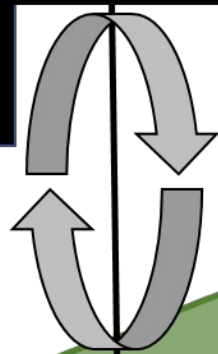
INFECTION CONVALESCENCE
(Repair-APR)



ACTIVE INFECTION – “CONTINUOUS INJURY”
(Survival-APR)



INFECTION CONVALESCENCE
(Repair-APR)



FEBRILE

AFEBRILE

CRP

ESR

IL-6

TREAT IT!

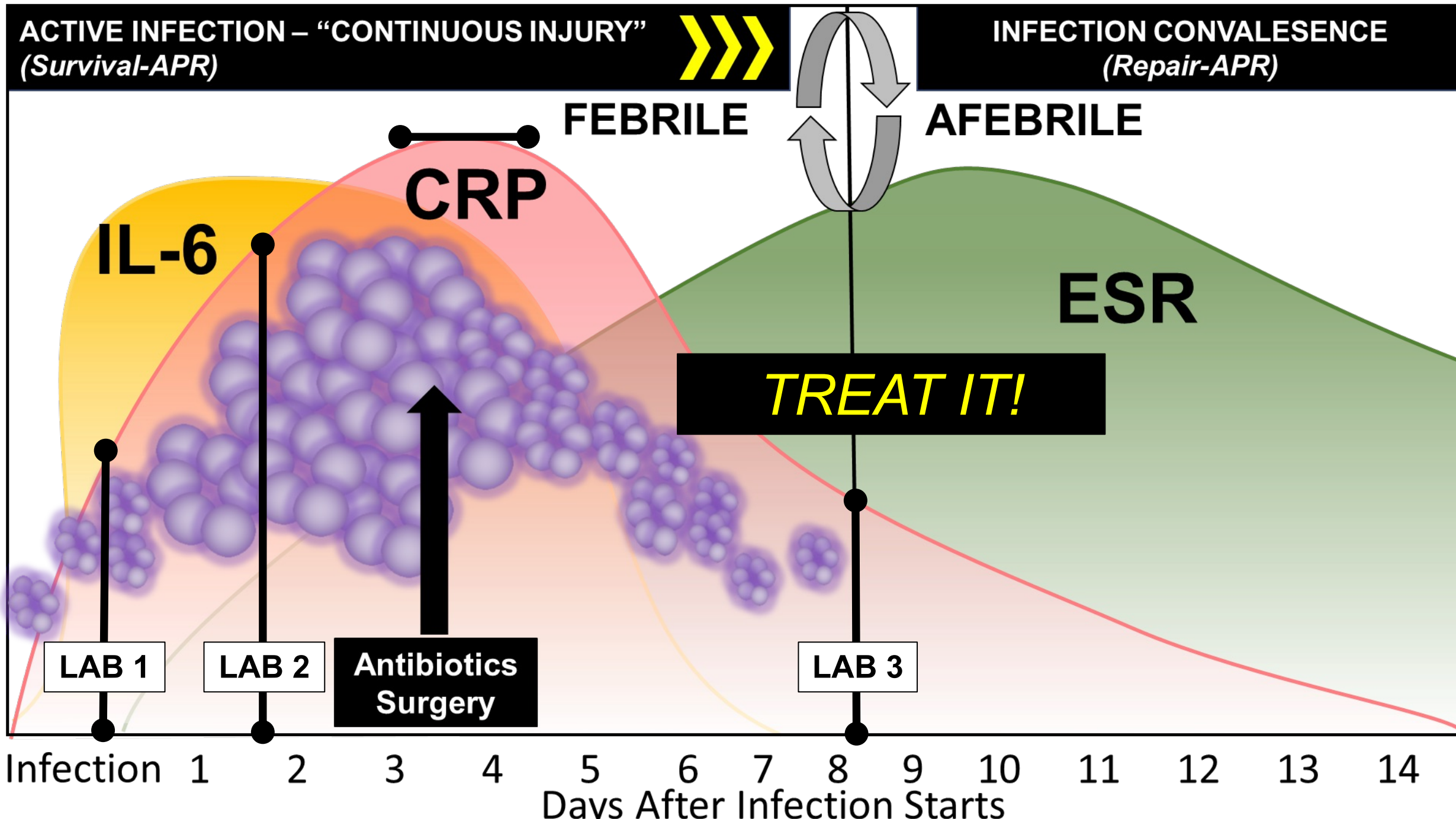
LAB 1

LAB 2

**Antibiotics
Surgery**

LAB 3

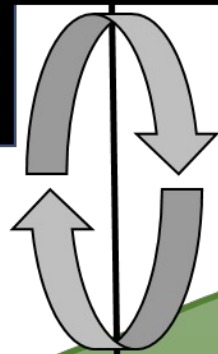
Infection 1 2 3 4 5 6 7 8 9 10 11 12 13 14
Days After Infection Starts



ACTIVE INFECTION – “CONTINUOUS INJURY”
(Survival-APR)



INFECTION CONVALESCENCE
(Repair-APR)



FEBRILE

AFEBRILE

CRP

ESR

IL-6

TREAT IT!

*Off
Antibiotics?*

LAB 1

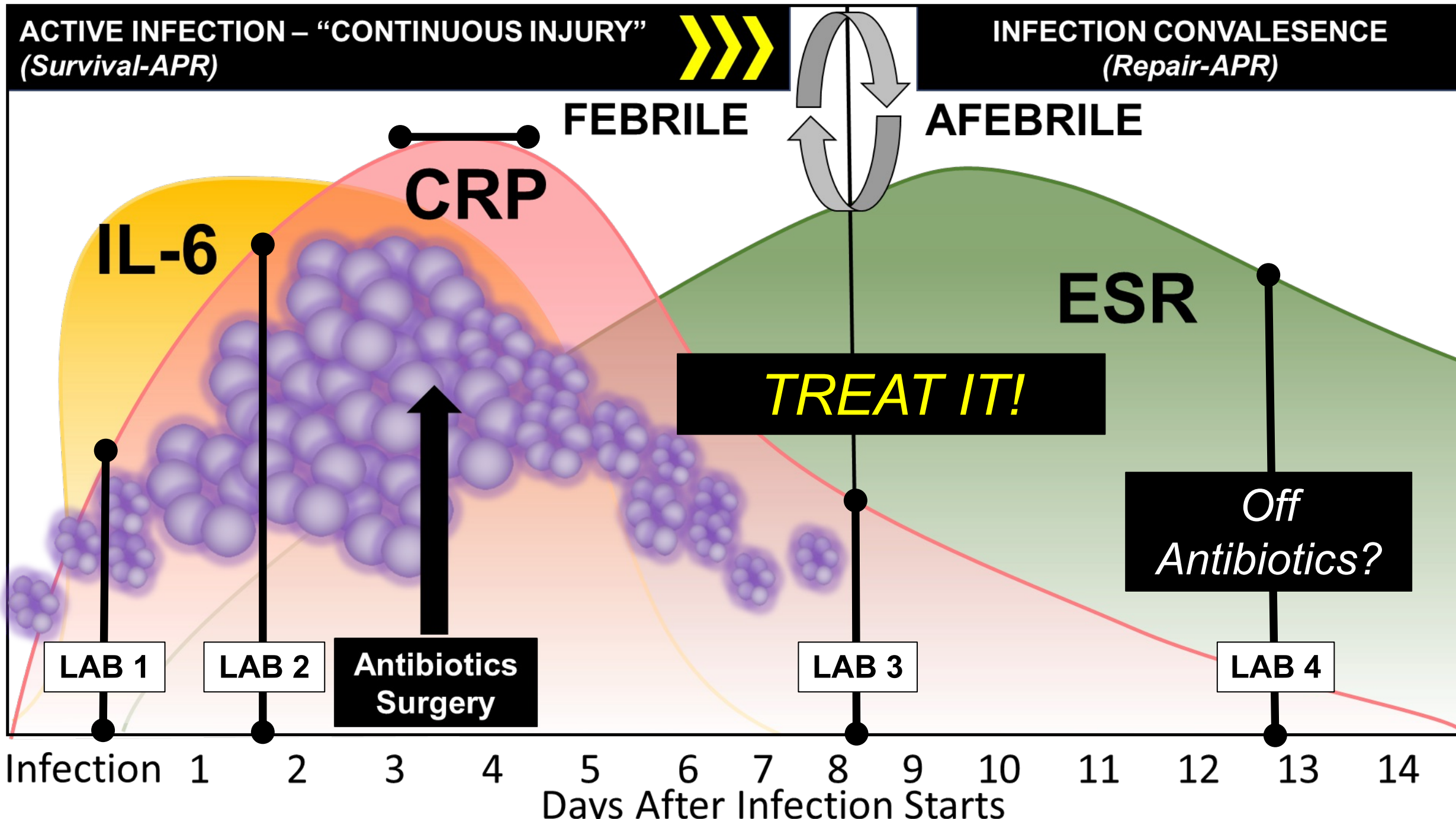
LAB 2

**Antibiotics
Surgery**

LAB 3

LAB 4

Infection 1 2 3 4 5 6 7 8 9 10 11 12 13 14
Days After Infection Starts



OSTEO

Team-Effort

Where Is It?

Is It A Bug?

How Severe Is It?

Treat It!



4 QUESTIONS

<https://www.jposna.org/ojs/index.php/jposna/article/view/124>
Or just search JPOSNA Schoenecker

THANK YOU

