

Management of Degenerative Adult Spine and the Osteoporotic Spine

Casey T. Davidson, M.D.

Welcome to Nashville, TN



A little bit about myself

Grew up in Gatesville, Texas

Medical School University of Texas Medical Branch Galveston, TX

Orthopedic Surgery Residency University of Mississippi

Visiting Fellowship in Bern, Switzerland

Spine Surgery Fellowship training in Charlotte, NC at OrthoCarolina

Currently with Bone and Joint Institute in Franklin, TN

Maturing

~~Aging~~ population statistics

- By 2050, the population aged 65 years is projected to be 83.7 million, nearly double the 43.1 million estimated for 2012.
- In 2012, the total US expenditure for Medicare was \$572 billion growth by 2023 is estimated to be \$1.1 trillion.

Pertinent Spine Terminology

- Spondylosis (spondy=spine, osis=problem)– natural degenerative process of the lumbar and cervical discs and facet joints
- Spondylolysis - condition in which there is a defect in the pars interarticularis of the vertebra
- Stenosis - narrowing of the spinal canal or foramen
- Spondylolisthesis – condition in which one vertebral body is slipped forward over another
- Spondyloptosis - a vertebra is completely disconnected from the following vertebra

Pertinent Spine Terminology

- Radiculopathy – compression or irritation of a nerve as it exits the spinal column
- Myelopathy – compression on the cervical or thoracic spinal cord

Conditions Affecting the Degenerative Spine

- Disc Degeneration/Facet arthropathy
- Disc Herniation
- Stenosis
- Osteoporosis
- Fractures

Good sources of information on spine disorders/pathology

Instructional Course Lecture

Treating the Aging Spine

Theodore J. Choma, MD
Glenn R. Rechtine, MD
Robert A. McGuire, Jr, MD
Darrel S. Brodke, MD

Abstract

Demographic trends make it incumbent on orthopaedic spine surgeons to recognize the special challenges involved in caring for older patients with spine pathology. Unique pathologies, such as osteoporosis and degenerative deformities, must be recognized and dealt with. Recent treatment options and recommendations for the medical optimization of bone health include vitamin D and calcium supplementation, diphosphonates, and teriparatide. Optimizing spinal fixation in elderly patients with osteoporosis is critical; cement augmentation of pedicle screws is promising. In the management of geriatric odontoid fractures, nonsurgical support with a collar may be considered for the low-demand patient, whereas surgical fixation is favored for high-demand patients. Management of degenerative deformity must address sagittal plane balance, including consideration of pelvic incidence. Various osteotomies may prove helpful in this setting.

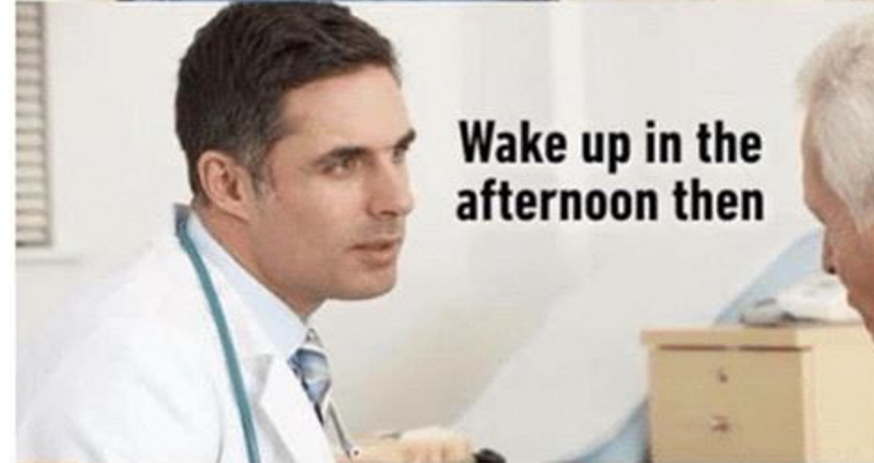Review Article

Management of Symptomatic Lumbar Degenerative Disk Disease

Luke Madigan, MD
Alexander R. Vaccaro, MD, PhD
Leo R. Spector, MD
R. Alden Milam, MD

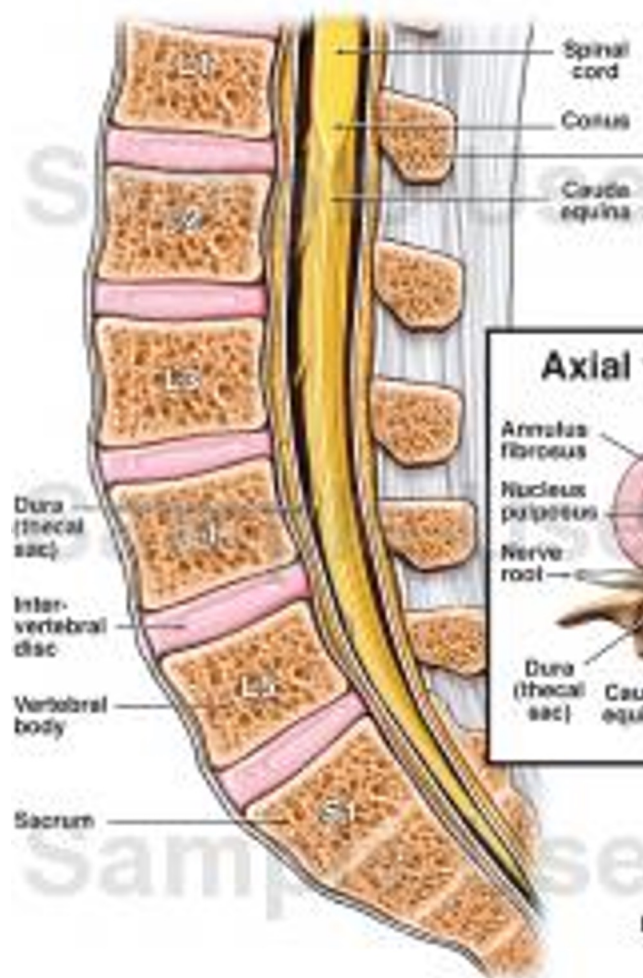
Abstract

Symptomatic lumbar degenerative disk disease, or discogenic back pain, is difficult to treat. Patients often report transverse low back pain that radiates into the sacroiliac joints. Radicular or claudicatory symptoms are generally absent unless there is concomitant nerve compression. Physical examination findings are often unremarkable. Radiographic examination may reveal disk space narrowing, end-plate sclerosis, or vacuum phenomenon in the disk; magnetic resonance imaging is useful for revealing hydration of the disk, annular bulging, or lumbar spine end-plate (Modic) changes in the adjacent vertebral bodies. The use of diskography as a confirmatory study remains controversial. Recent prospective, randomized trials and meta-analyses of the literature have helped expand what is known about degenerative disk disease. In most patients with low back pain, symptoms resolve without surgical intervention; physical therapy and nonsteroidal anti-inflammatory drugs are the cornerstones of nonsurgical treatment. Intradiskal electrothermal treatment has not been shown to be effective, and arthrodesis remains controversial for the treatment of discogenic back pain. Nucleus replacement and motion-sparing technology are too new to have demonstrated long-term data regarding their efficacy.

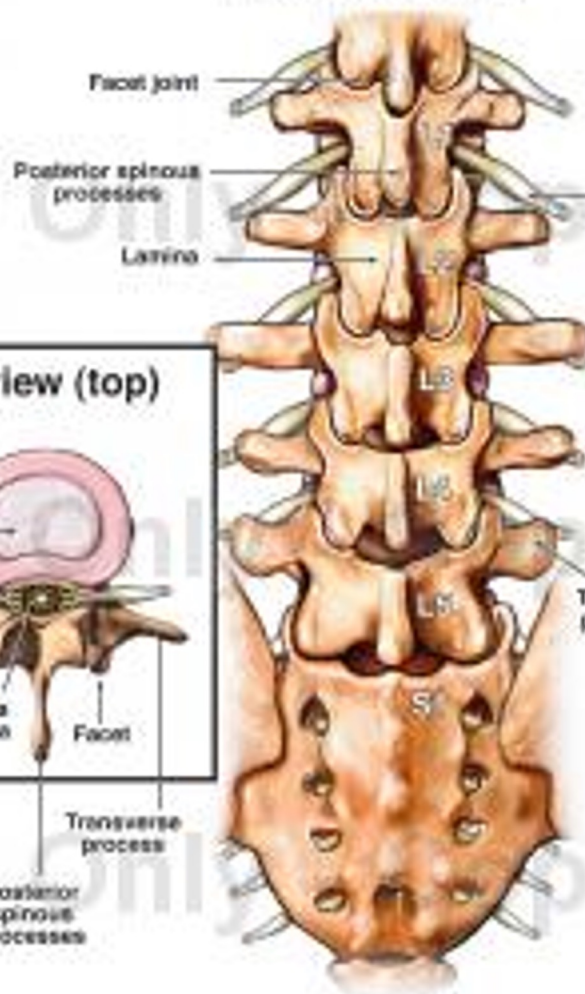


Lumbar Spine Anatomy

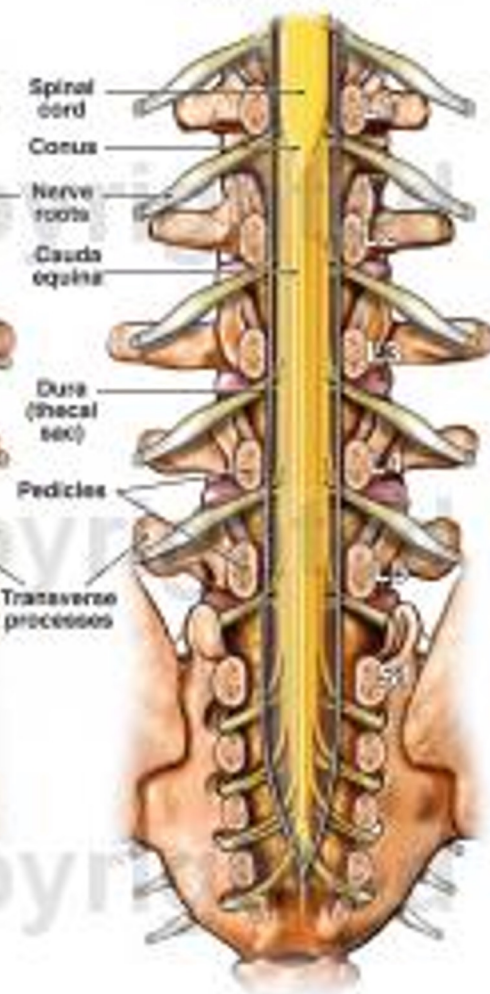
Sagittal view
(cut-away from the side)



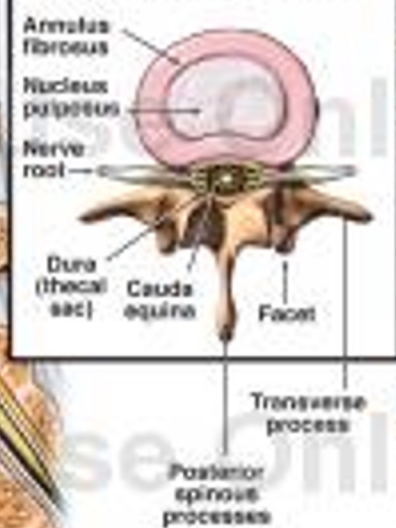
Posterior view
(from the back)



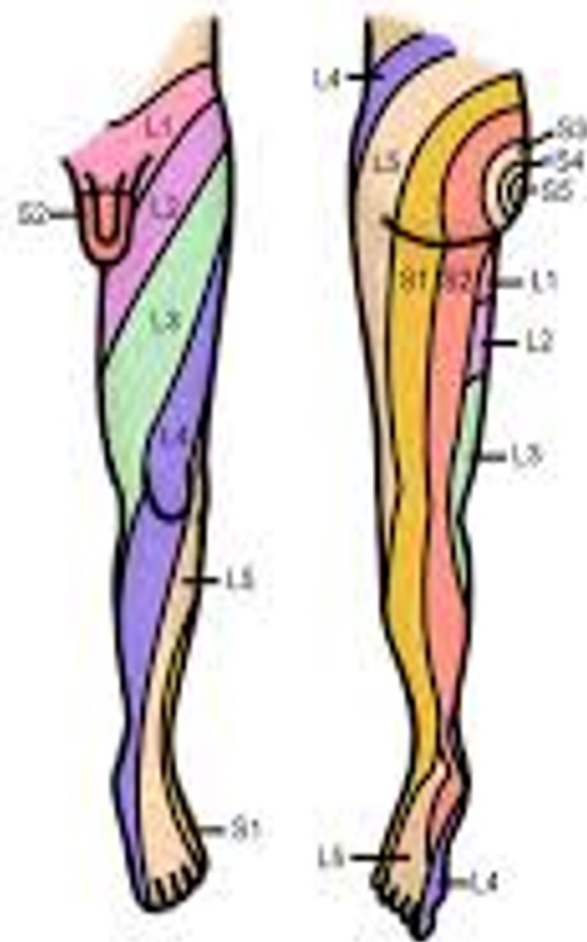
Posterior view
(cut-away)



Axial view (top)



Lower Extremity Dermatome



© Lineage

Moises Dominguez
Moises Dominguez

Disc Degeneration

- Who does disc degeneration affect?
- When does it occur?
- What are the signs and symptoms of disc degeneration?
- What can we do to treat disc degeneration-related pain?

Table 2: Age-specific prevalence estimates of degenerative spine imaging findings in asymptomatic patients^a

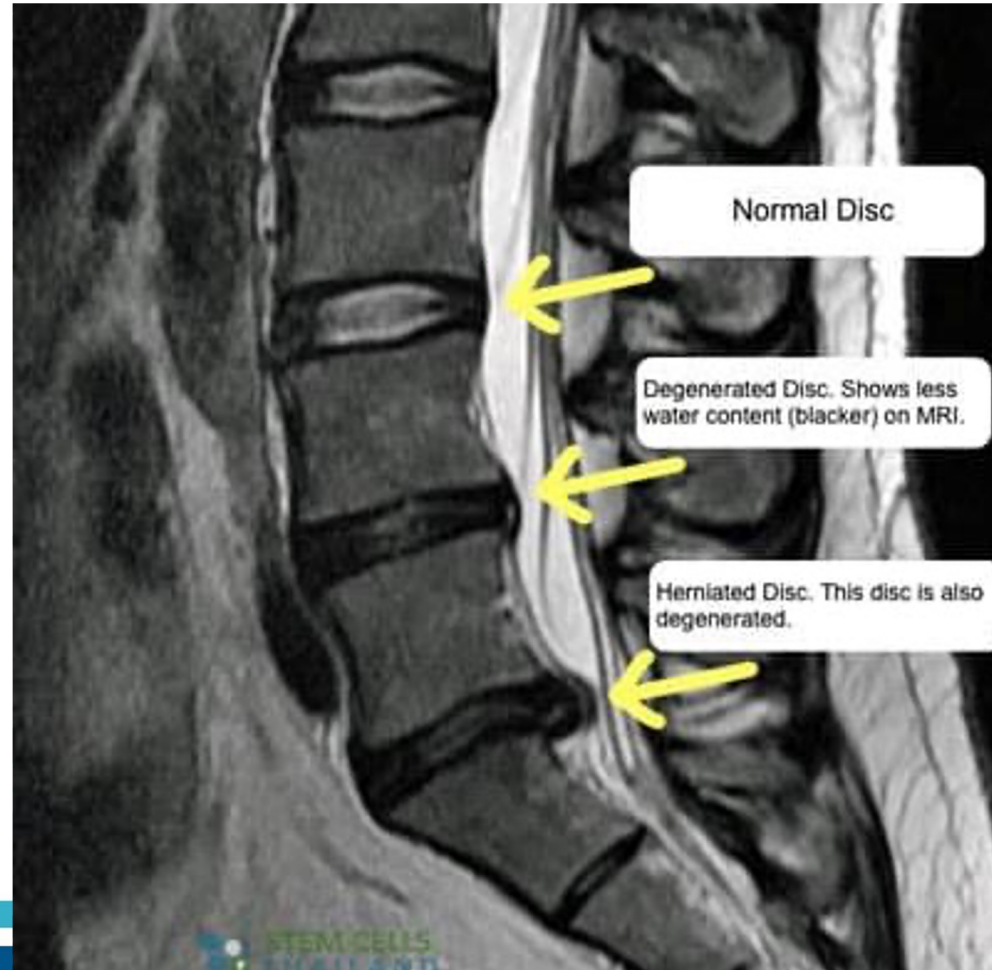
Imaging Finding	Age (yr)						
	20	30	40	50	60	70	80
Disk degeneration	37%	52%	68%	80%	88%	93%	96%
Disk signal loss	17%	33%	54%	73%	86%	94%	97%
Disk height loss	24%	34%	45%	56%	67%	76%	84%
Disk bulge	30%	40%	50%	60%	69%	77%	84%
Disk protrusion	29%	31%	33%	36%	38%	40%	43%
Annular fissure	19%	20%	22%	23%	25%	27%	29%
Facet degeneration	4%	9%	18%	32%	50%	69%	83%
Spondylolisthesis	3%	5%	8%	14%	23%	35%	50%

^a Prevalence rates estimated with a generalized linear mixed-effects model for the age-specific prevalence estimate (binomial outcome) clustering on study and adjusting for the midpoint of each reported age interval of the study.

Disc Degeneration

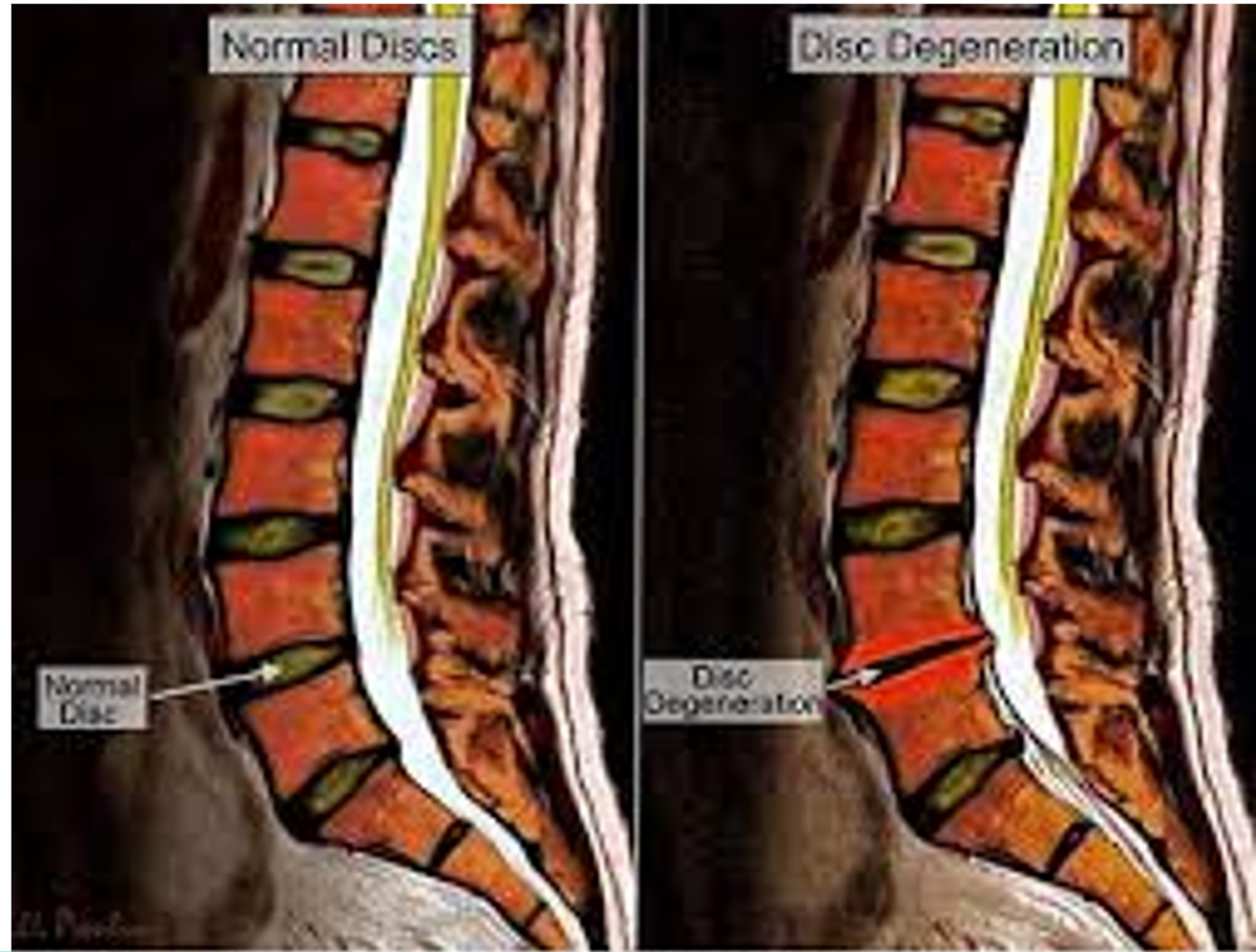- Can be completely asymptomatic
- Can cause mild back pain that is worse when getting up in the morning or after sitting for long periods of time
- Can have acute “flare ups” where there is intense localized back pain that can run across the low back and into the back of the hips

Disc Degeneration Process

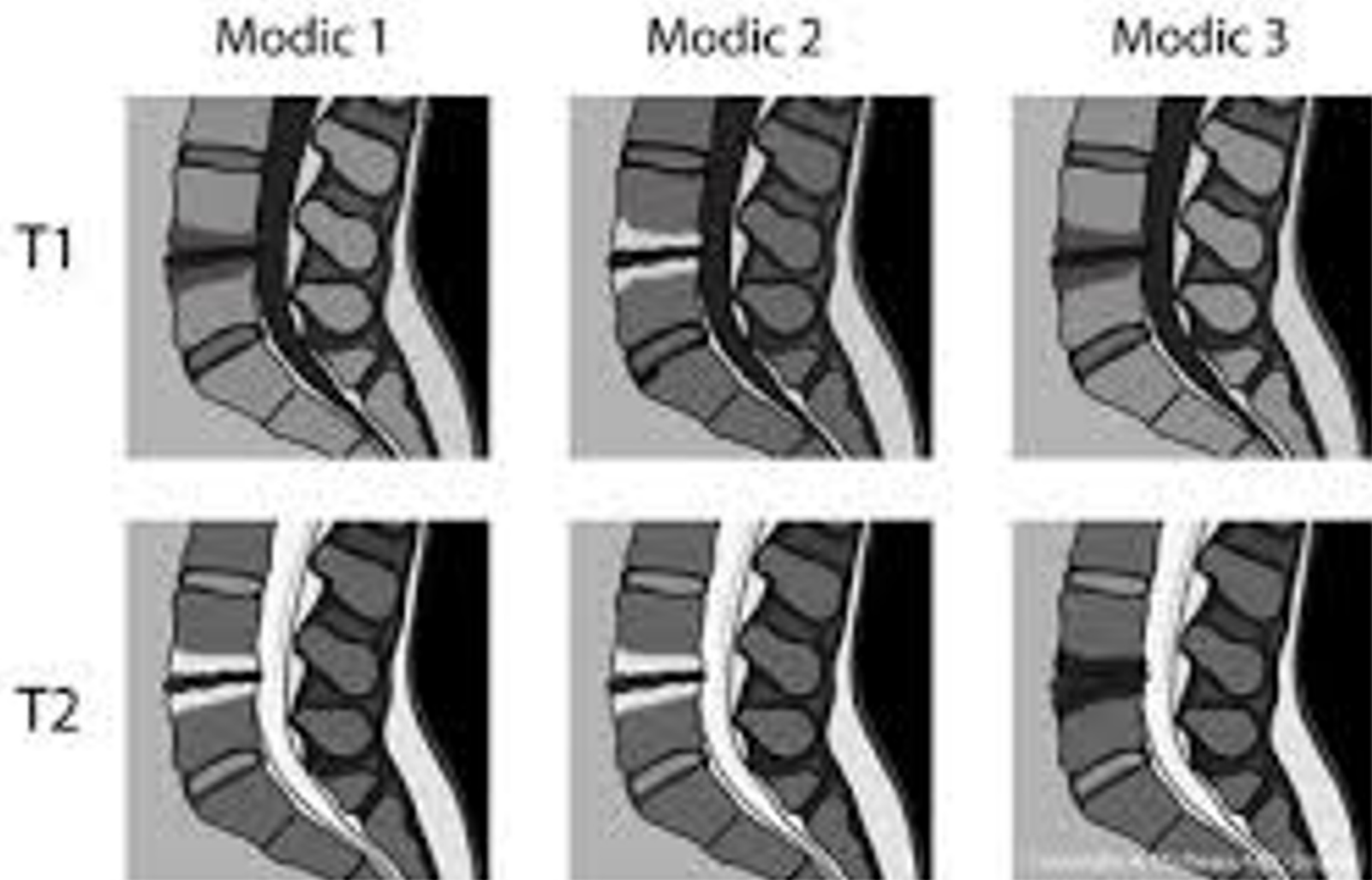


Disc Degeneration

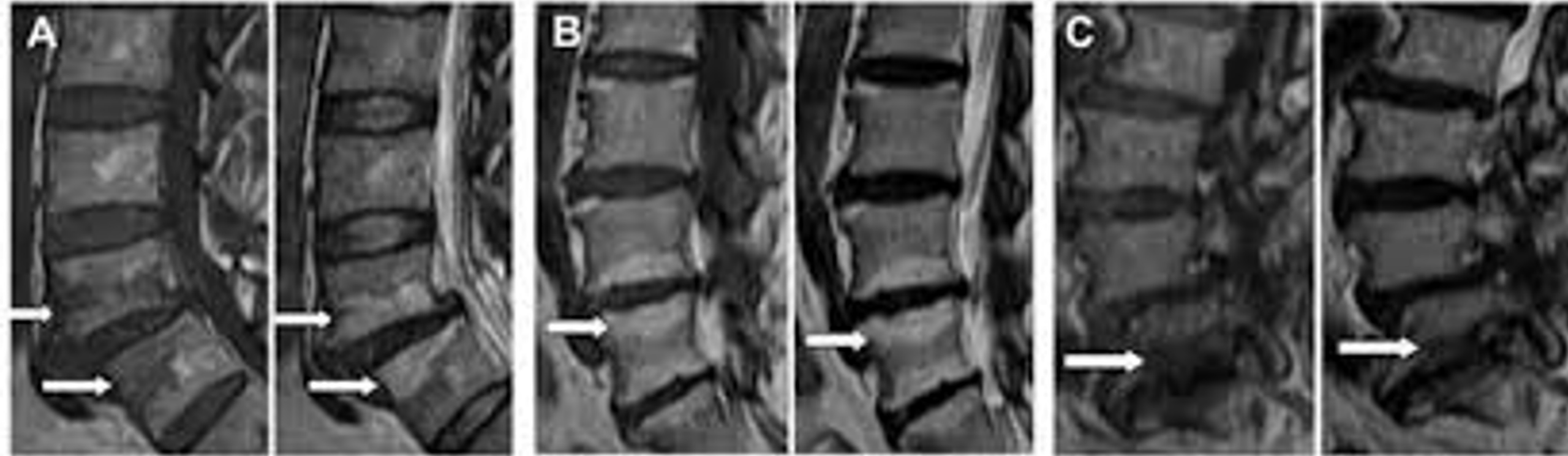- As the discs age they become less pliable and lose some of their effect as a bumper pad

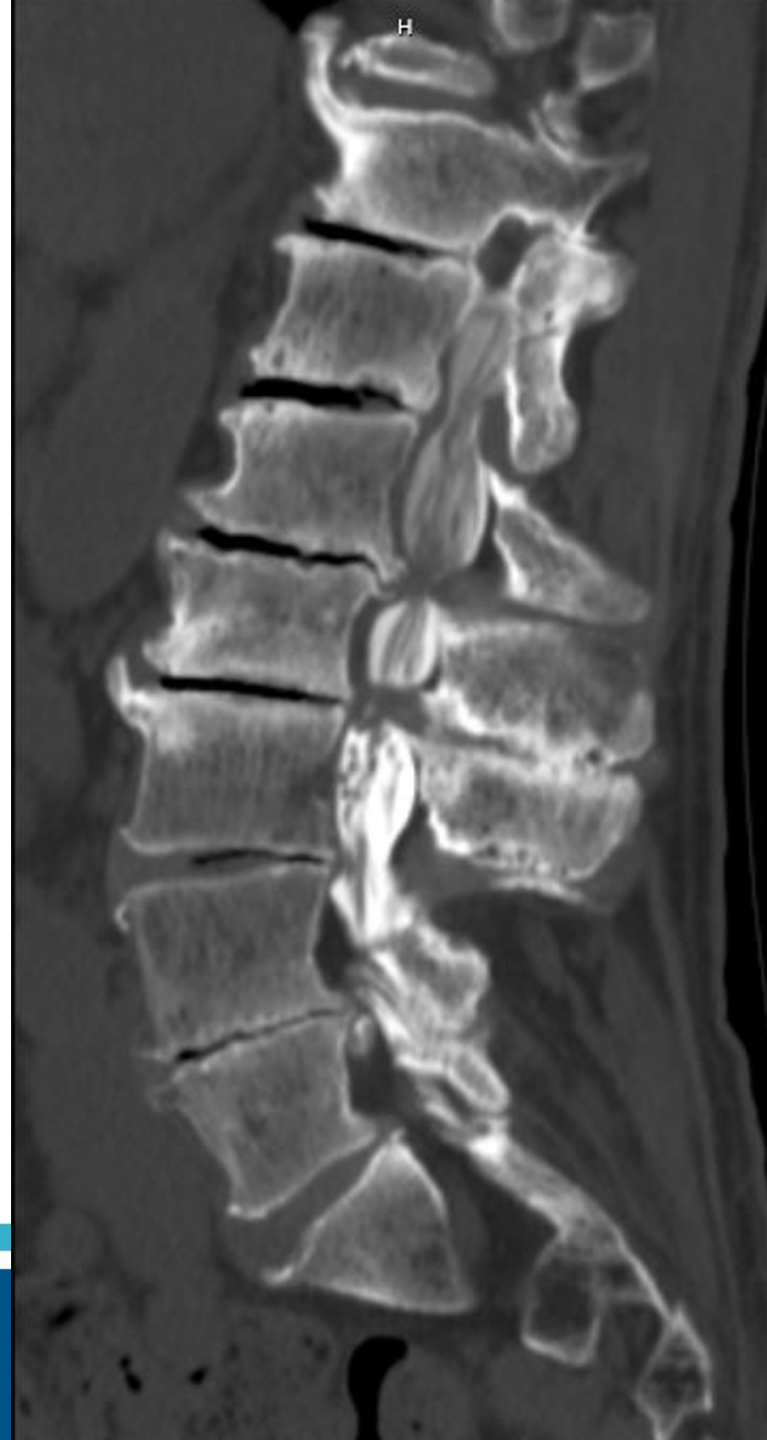


Modic changes



Disc Degeneration with Modic Changes



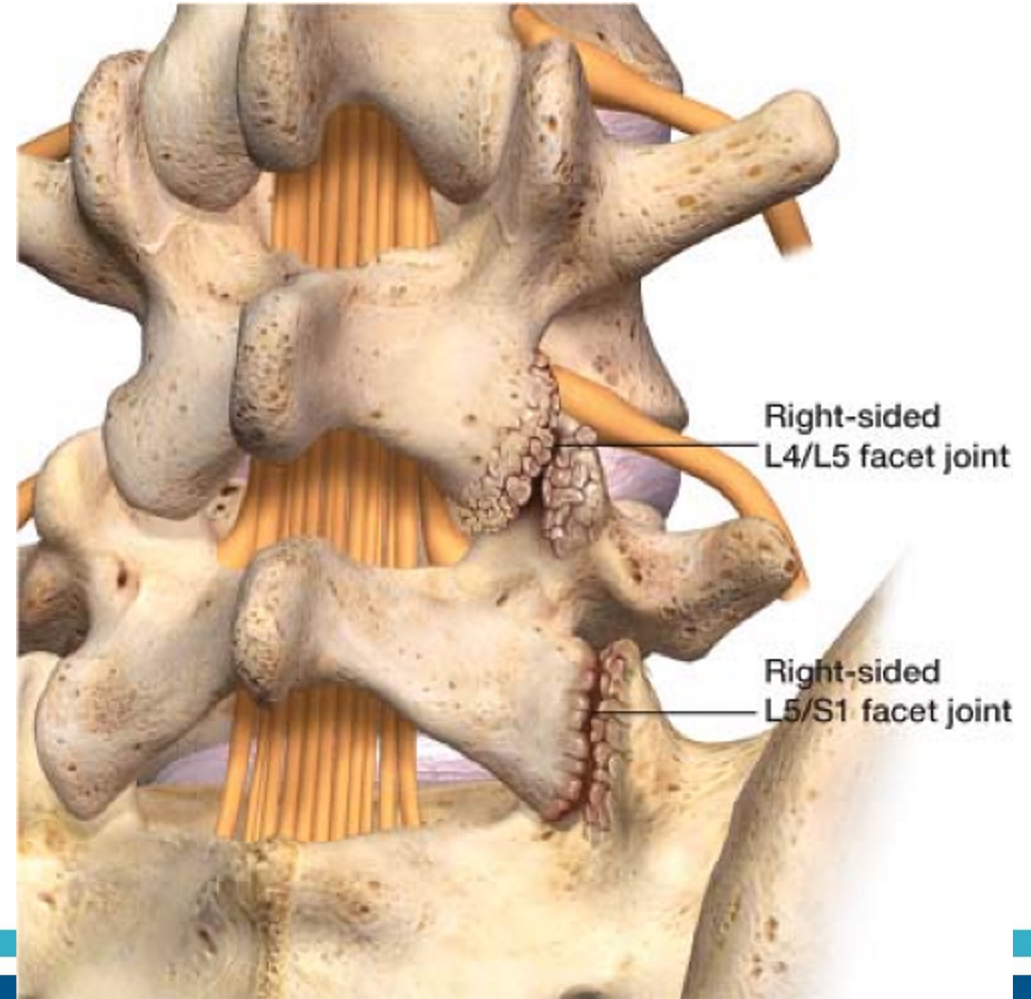


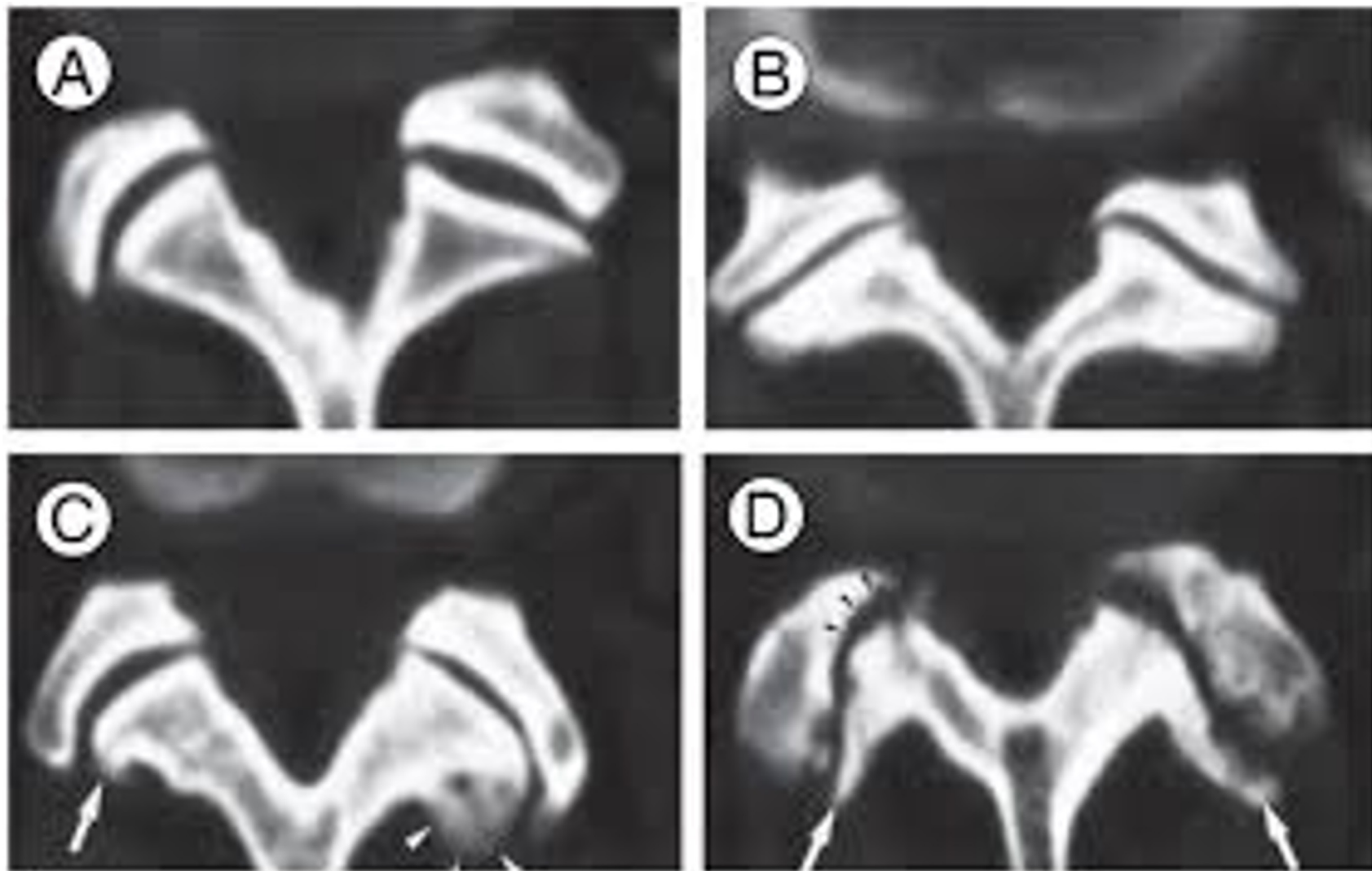
Facet Arthropathy

Arthritis of Cervical or lumbar facet joints

Axial pain can refer out to shoulders (cervical) or buttock (lumbar)

Pain with extension





Treatment of lumbar disc degeneration/facet arthropathy

Physical therapy - Williams and McKenzie methods

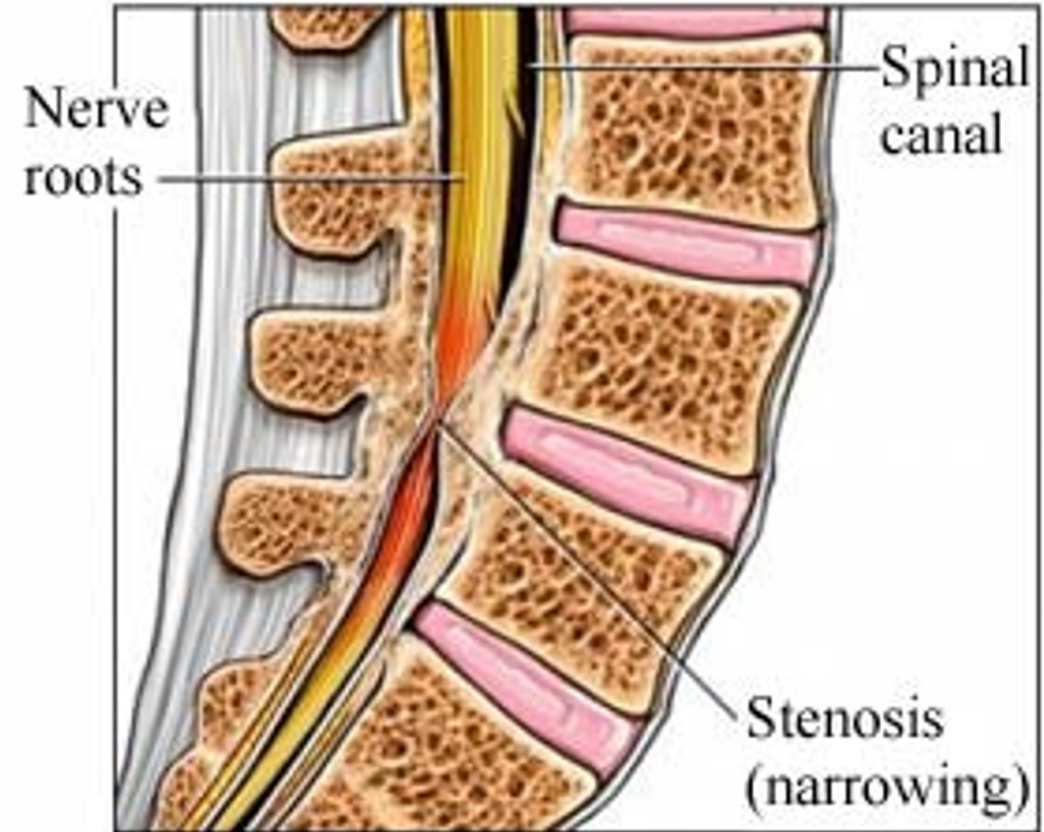
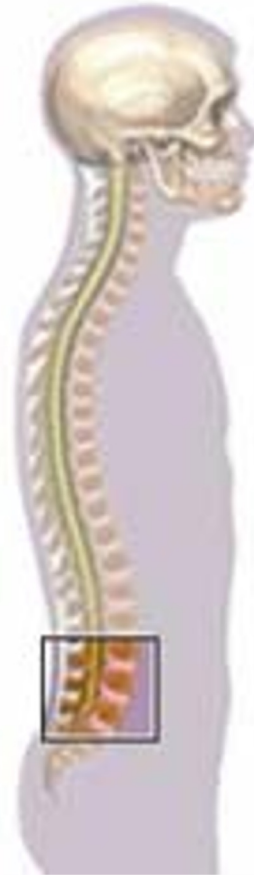Medications: NSAIDs, Tylenol, muscle relaxants, oral or IM steroids

Injections: often have concurrent facet arthropathy so can achieve good improvement in symptoms with facet joint injections/Radiofrequency ablation.

Newer techniques including basivertebral nerve ablation are showing promising outcomes

Stenosis

A term meaning tightness or narrowing around the spinal cord or nerve roots



Symptoms of Stenosis

- Shooting pain into the arms or legs
- Burning pain in relatively linear patterns
- Occasionally weakness
- Throbbing pain
- Back or neck pain

Where is the Stenosis?

Cervical or Lumbar?

Central or Foraminal?

Cervical Stenosis

Central stenosis → cervical myelopathy

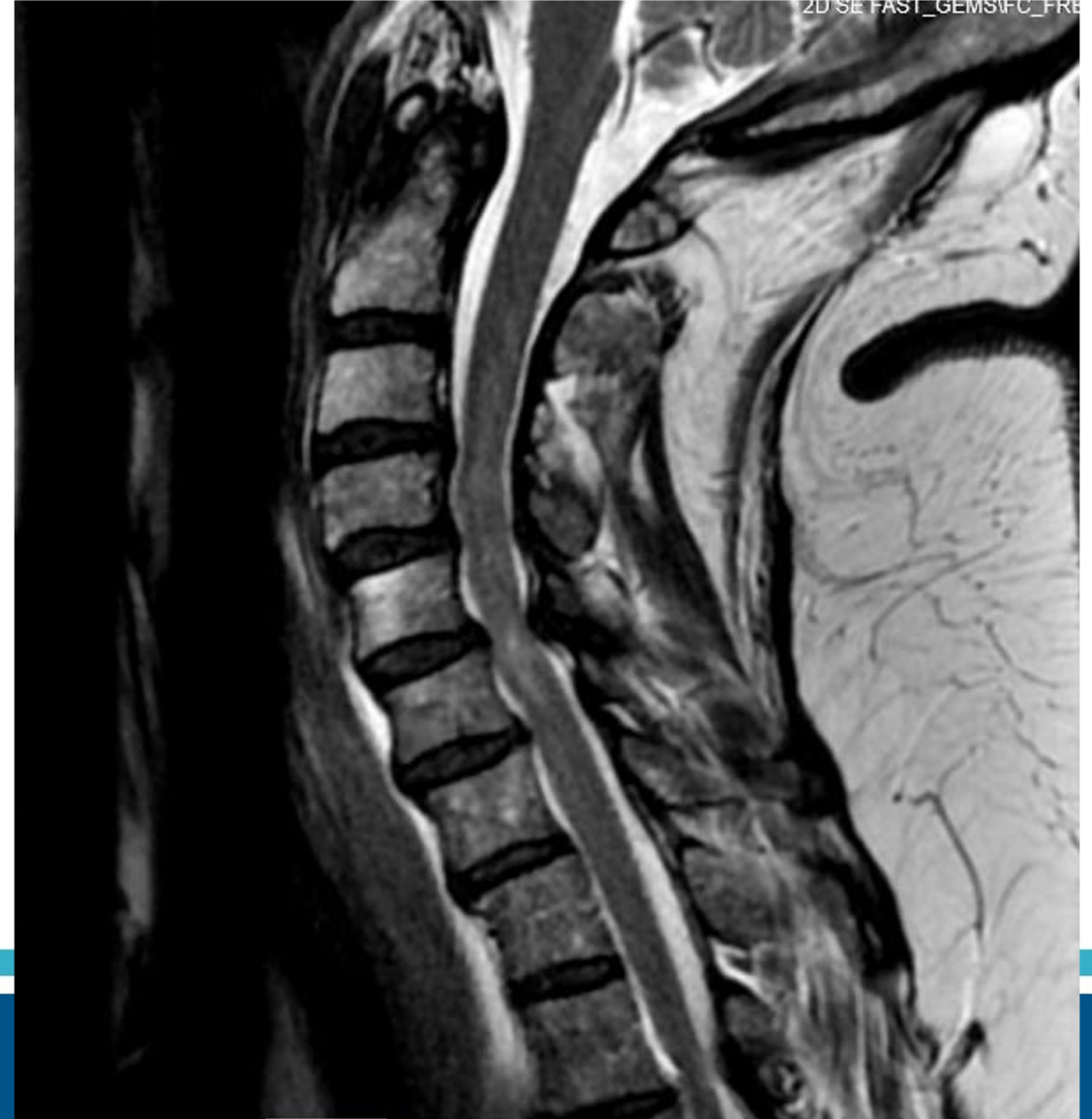Foraminal stenosis → cervical radiculopathy

Cervical Myelopathy

Compression of cervical spinal cord

Symptoms: gait instability, loss of dexterity, numbness/tingling

Exam: + Hoffman, hyperreflexia, numbness, clonus, inability to perform tandem walk, +Babinski



Cervical Myelopathy

Get patients up and watch them walk!

Cervical Myelopathy

Treatment: Almost always requires surgical decompression unless it is very mild.

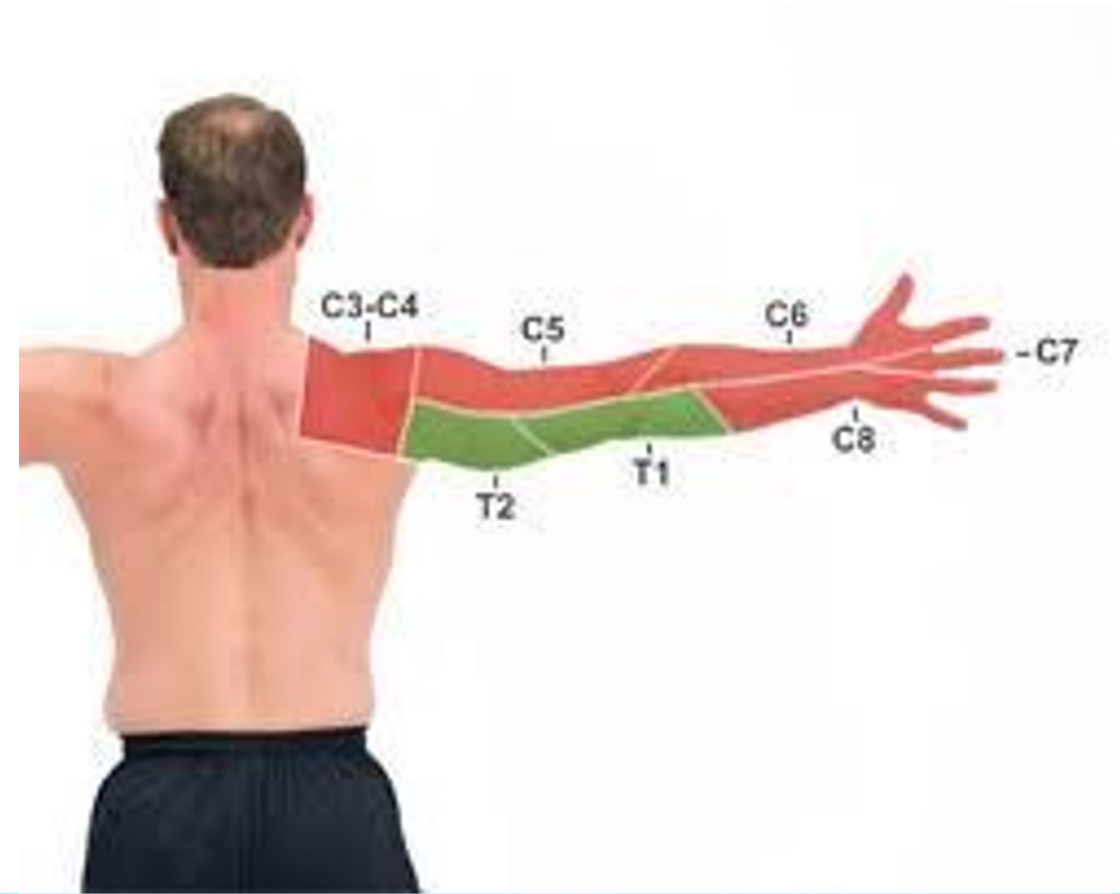Cervical myelopathy usually progresses in a stepwise manner and a patient may have a period of time where they suffer significant decline in function

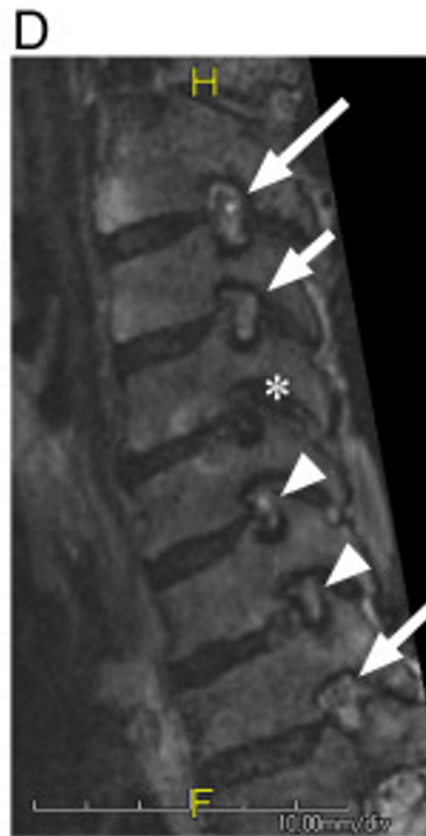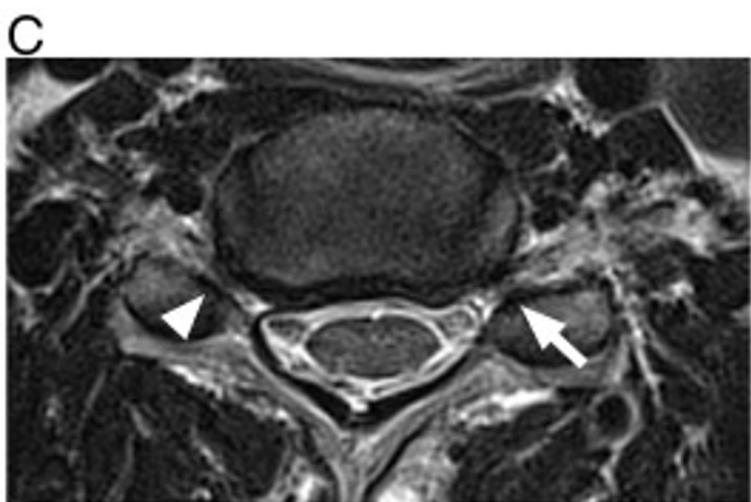
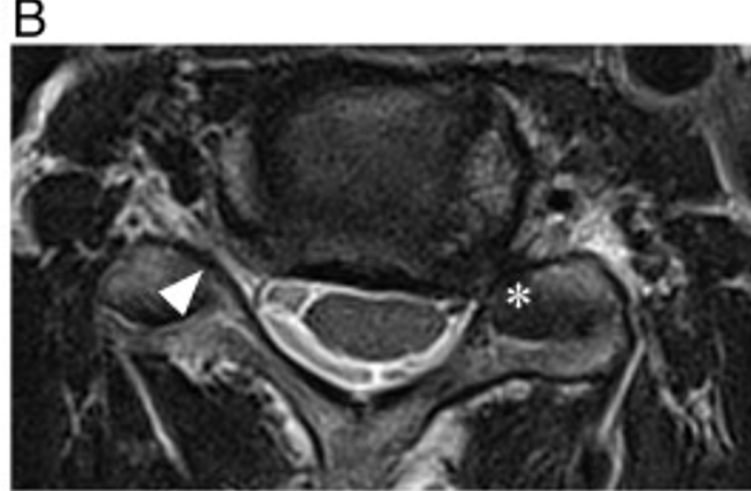
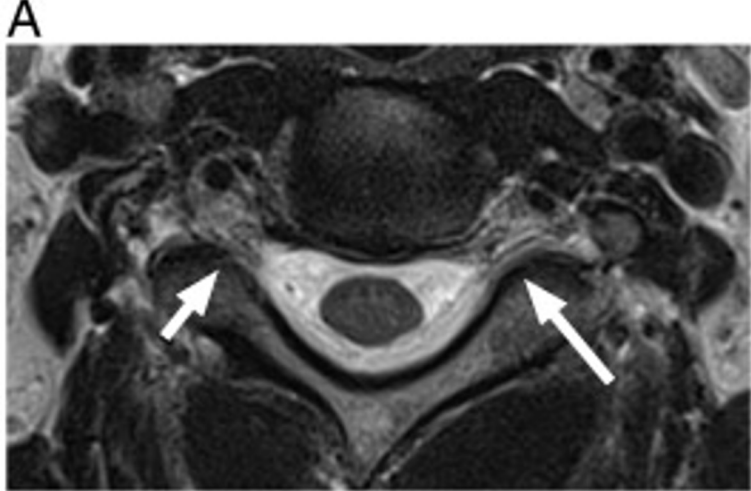
Once there is a decline in function it's difficult to regain even after surgery

Cervical Radiculopathy

Caused by foraminal stenosis rather than central

Symptoms: Radiating pain shooting down arm in relatively linear distribution. Usually doesn't cause weakness but if so most common in C5 weakness of deltoid.





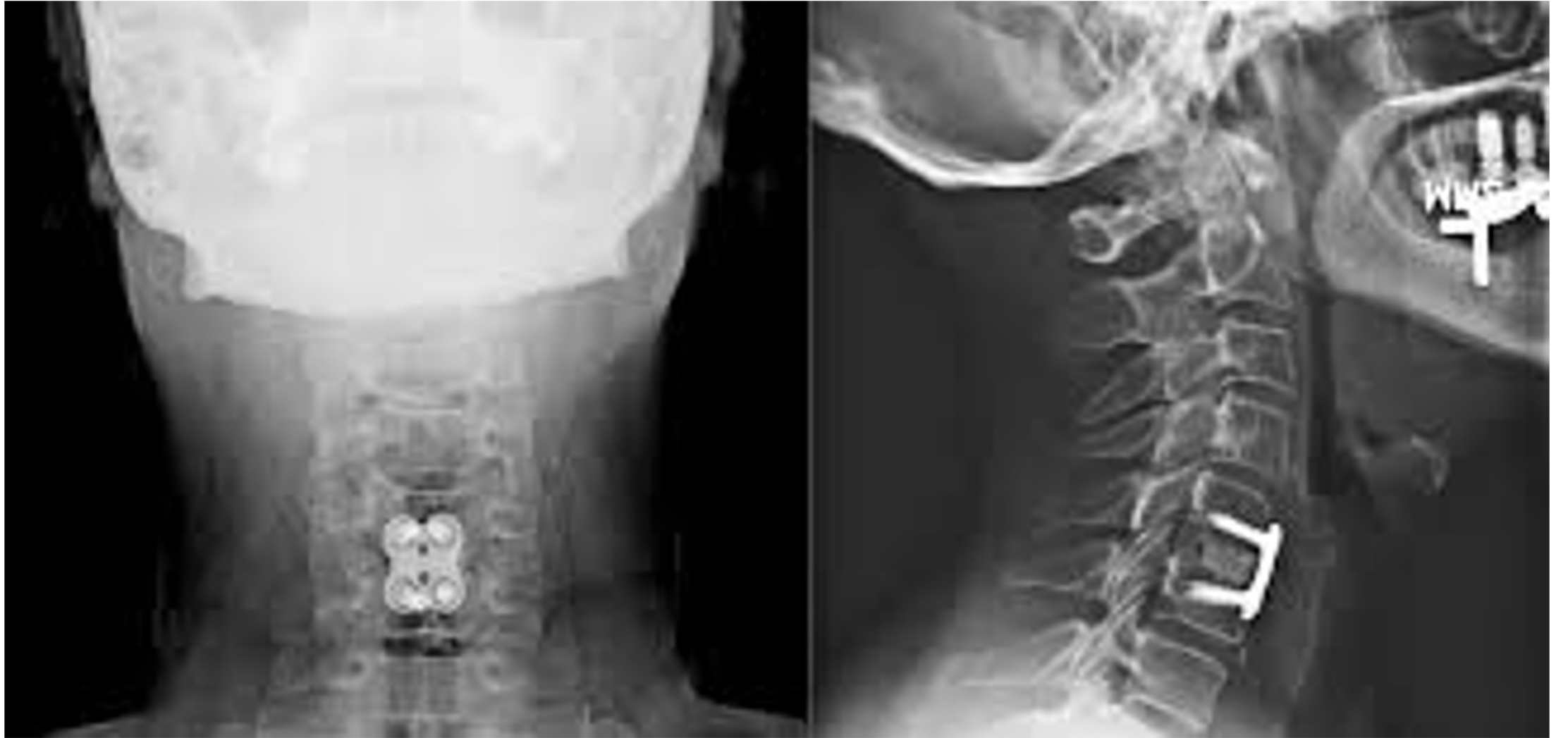Cervical Radiculopathy

Treatment: medications, Physical Therapy, Epidural Steroids

If significant neurologic deficit may require more aggressive treatment

Medications: NSAIDs, IM Steroids, Oral Steroids, Gabapentin/Lyrica, narcotics

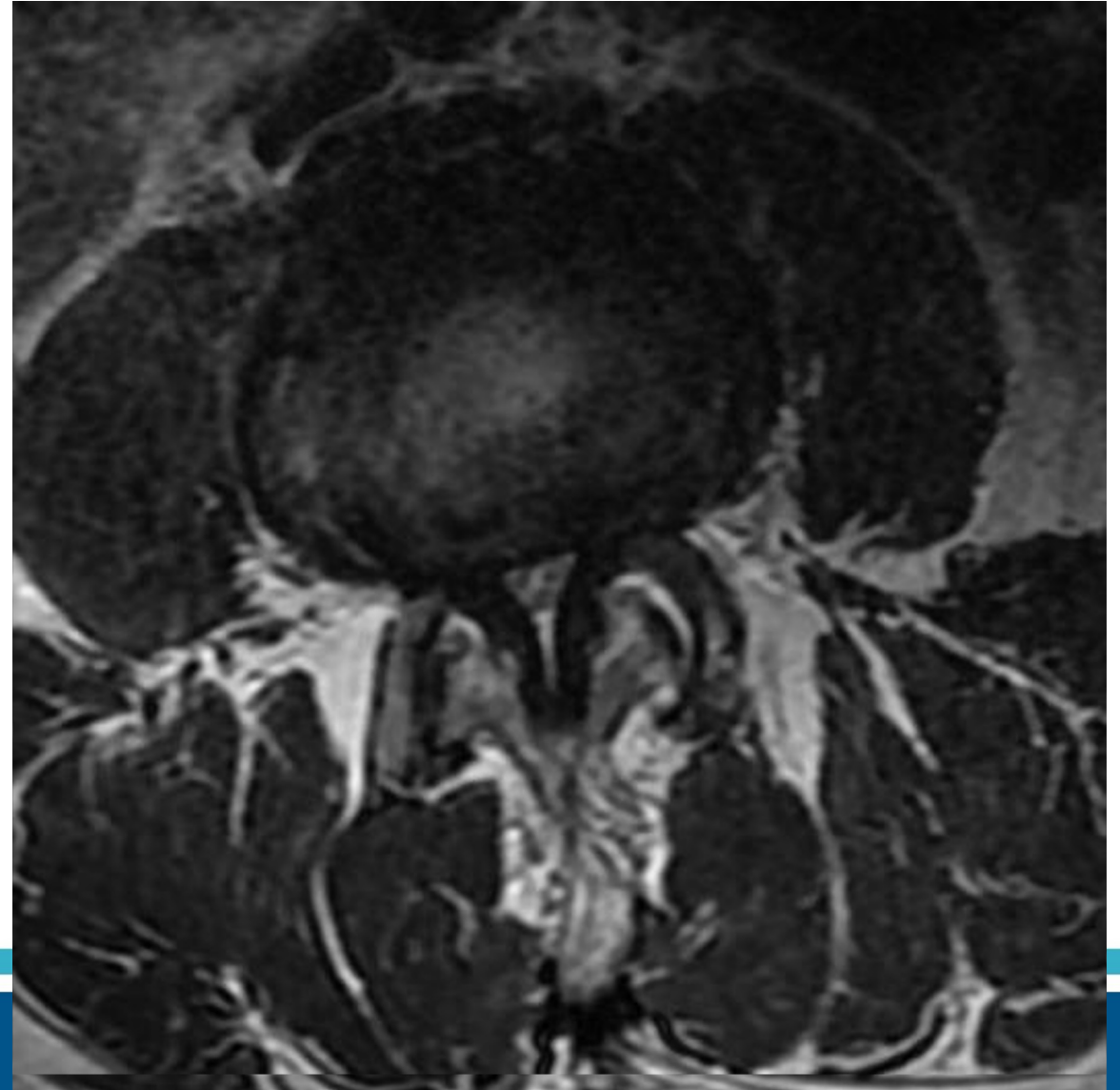
Surgical management: if no improvement of symptoms. Most commonly ACDF



Lumbar stenosis

Central Stenosis: Usually more numbness, tingling, “heavy sensation” called neurogenic claudication

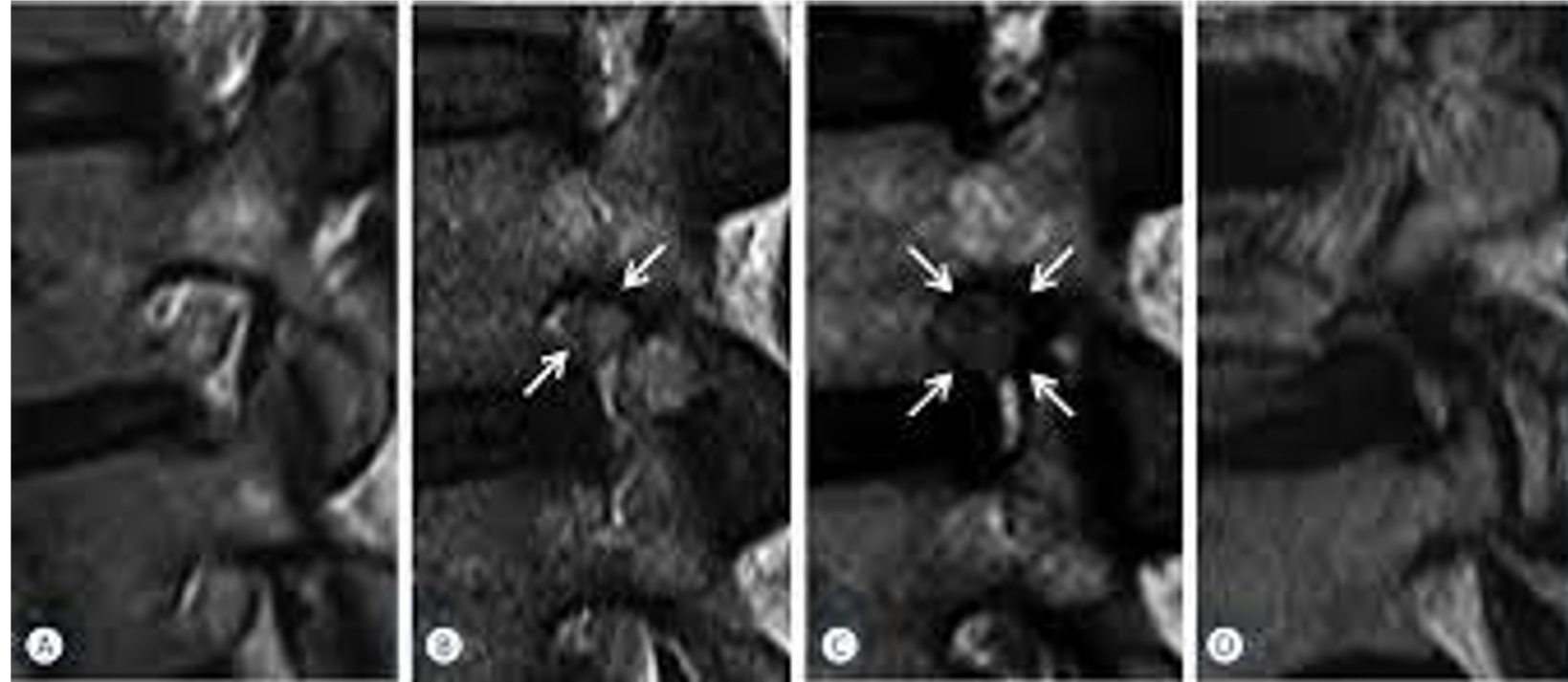
Severe central stenosis can occasionally lead to cauda equina syndrome



Lumbar Stenosis

Paracentral/foraminal: Produces more traditional radicular nerve pain down legs

No risk for cauda equina unless concurrent central stenosis



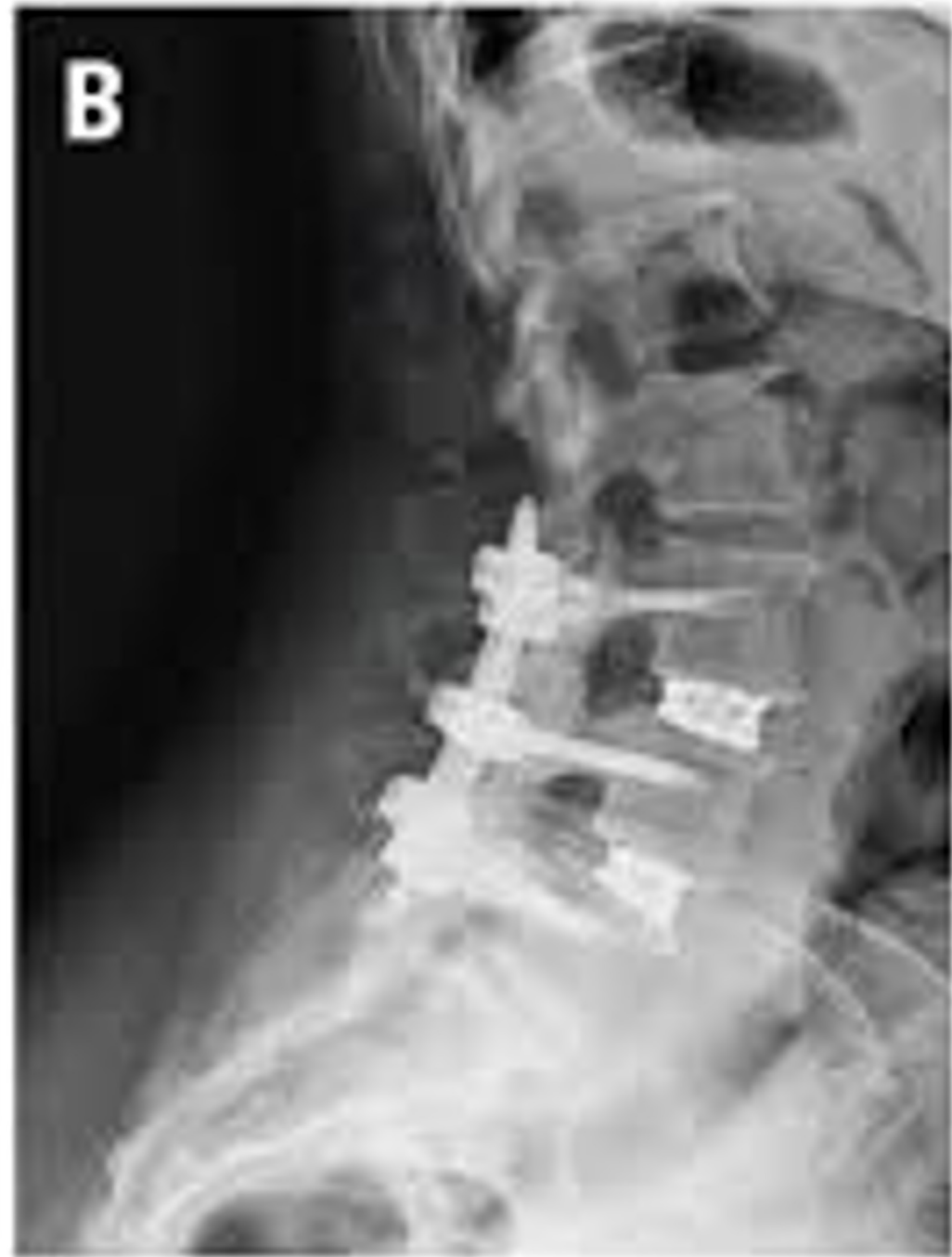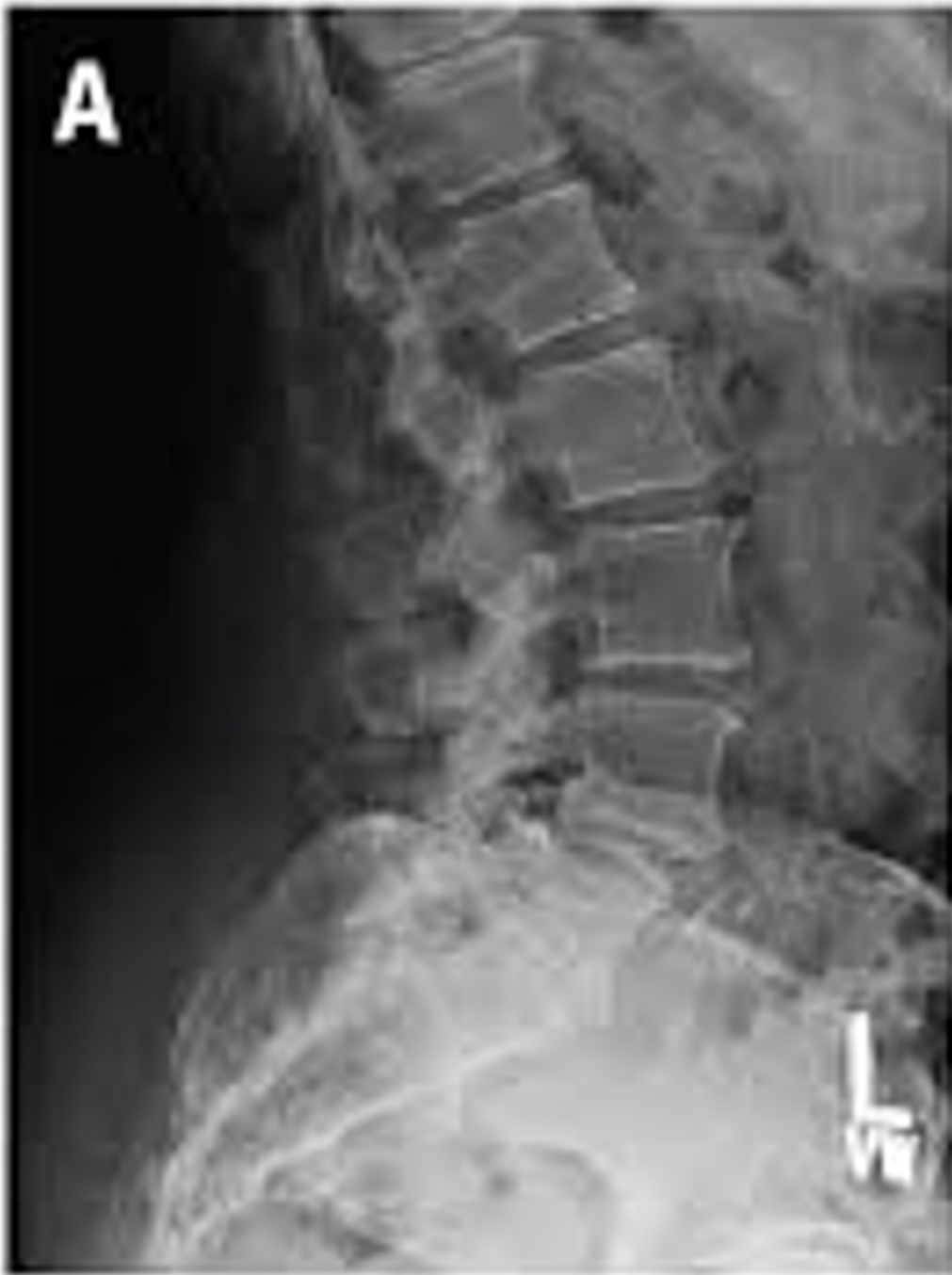Lumbar Stenosis Treatment

Treatment: medications, Physical Therapy, Epidural Steroids

If significant neurologic deficit may require more aggressive treatment

Medications: NSAIDs, IM Steroids, Oral Steroids, Gabapentin/Lyrica, narcotics

Surgical management: if no improvement of symptoms. Decompression of the affected nerves with or without fusion

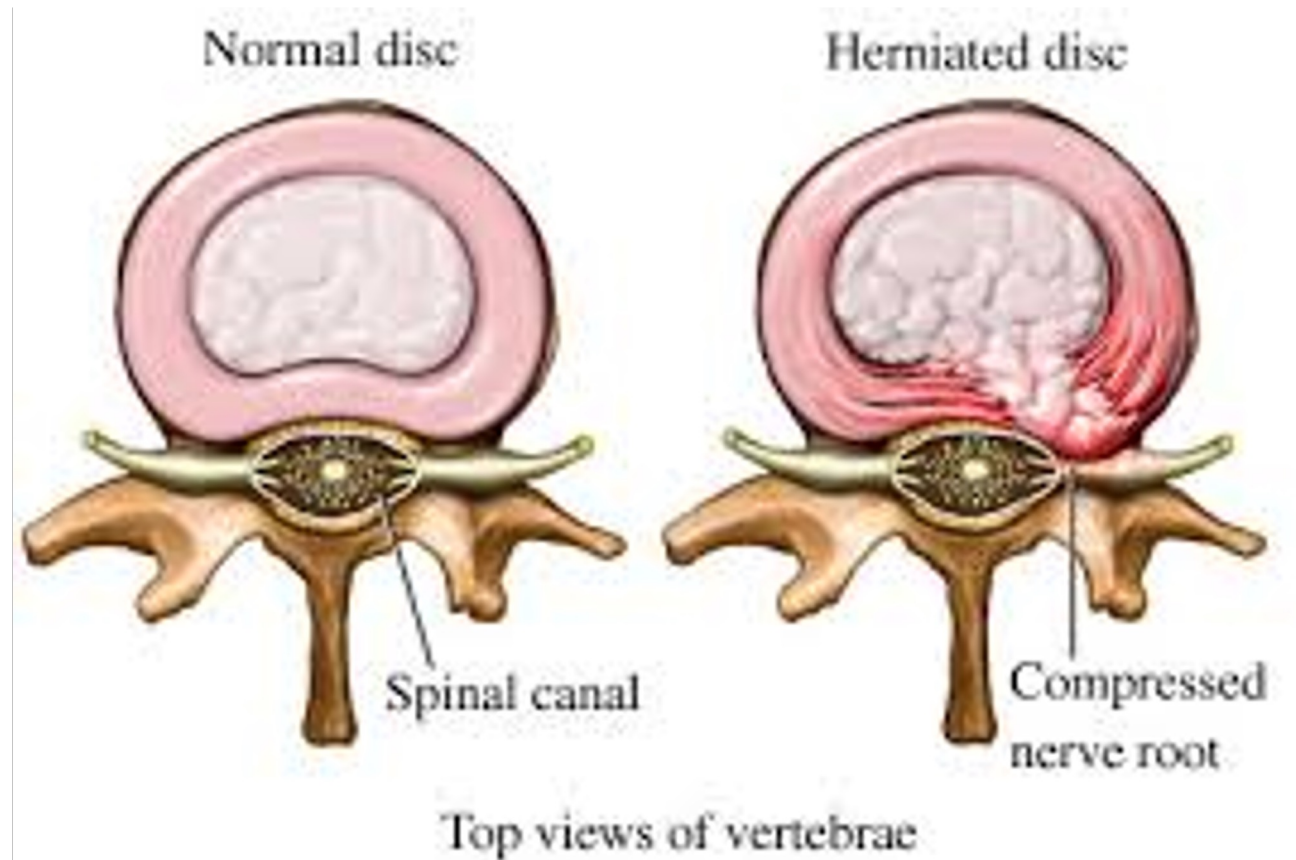


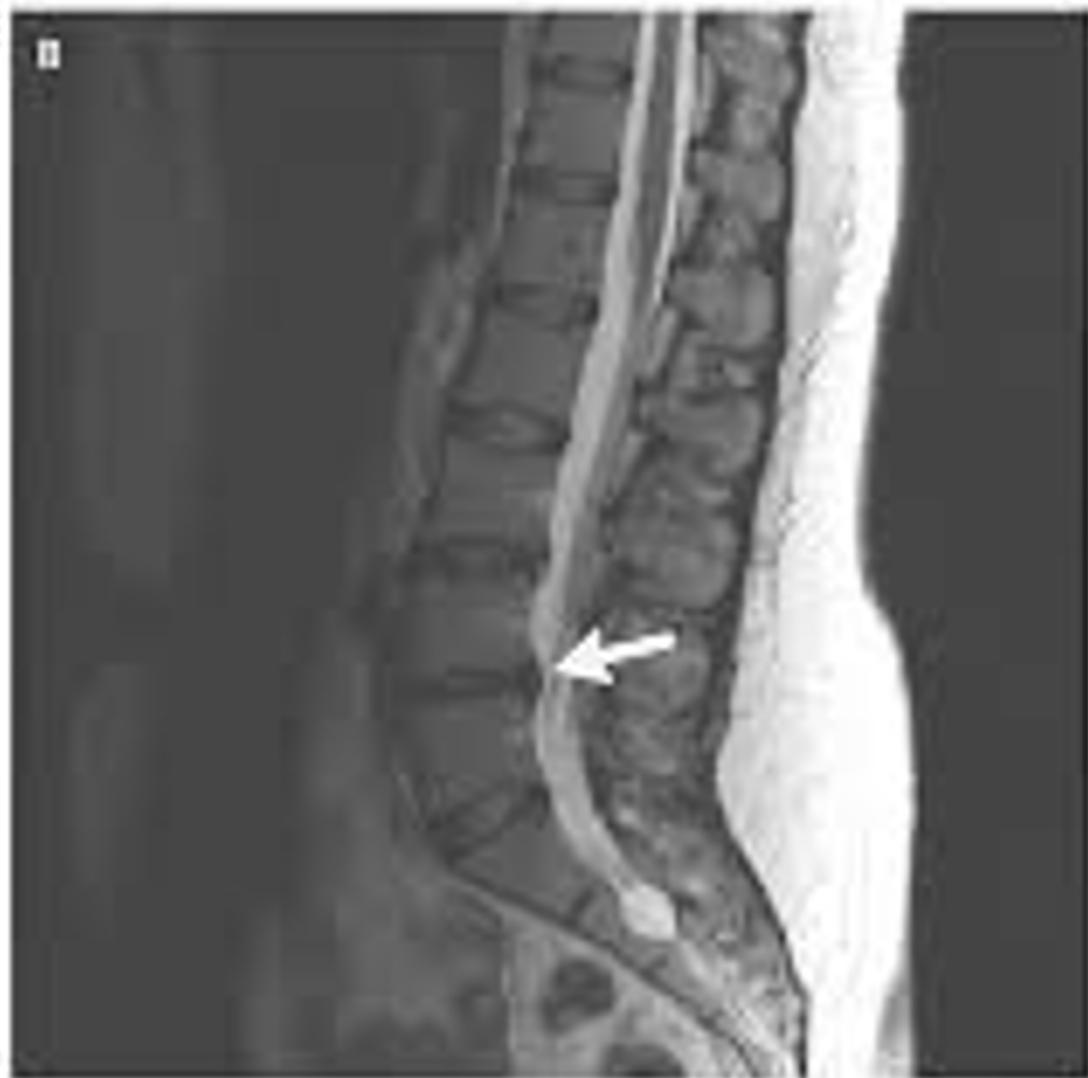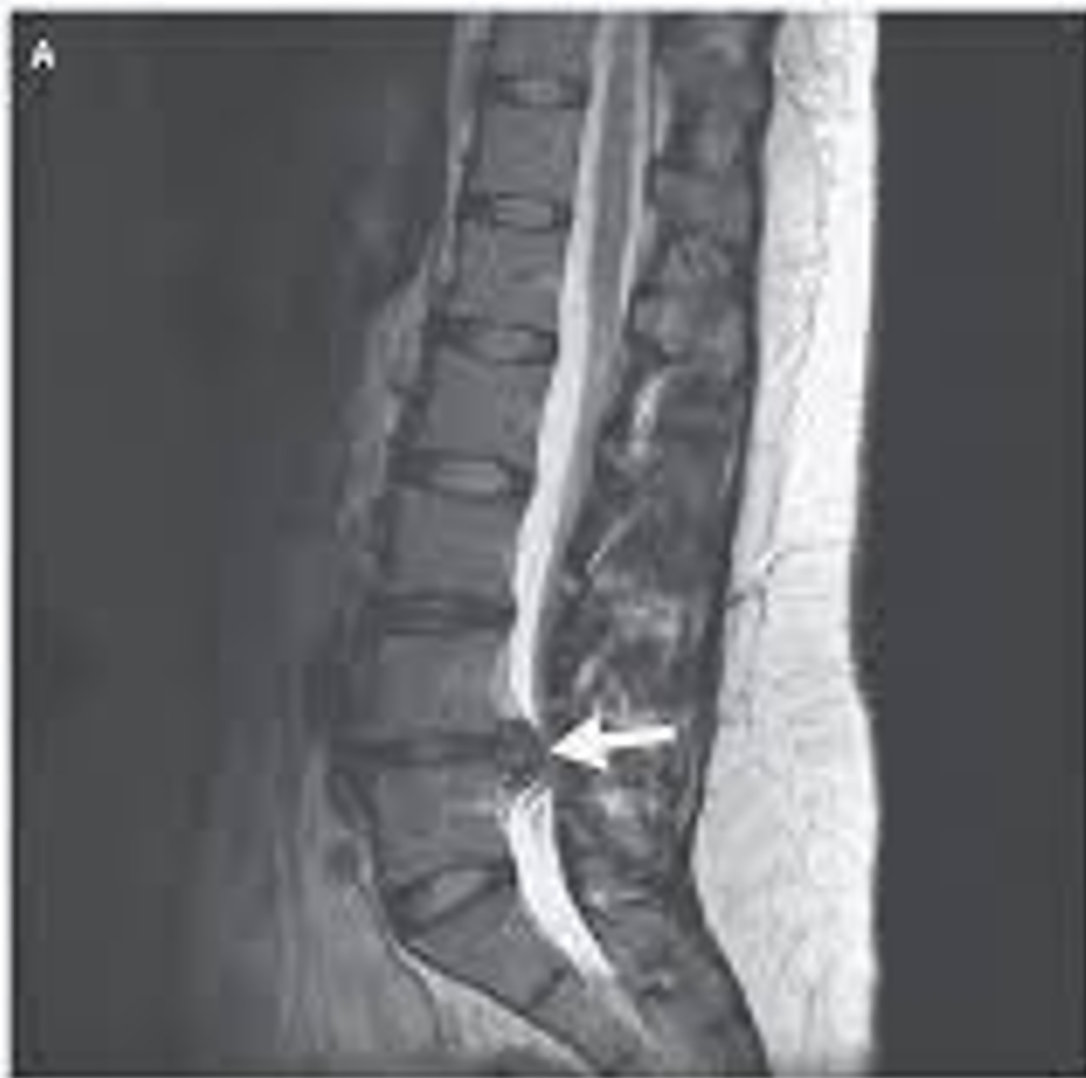Disc Herniation

- Symptomatic herniations has 2% lifetime prevalence usually 4-6th decades
- Most are asymptomatic - 36% of people without symptoms over 60 had disk herniation compared to 43% of asymptomatic patients younger than 60
- Acute pain thought to be related to injury to annulus fibrosis which is innervated by nociceptive sinuvertebral nerve fibers
- ~80-90% improve or completely resolve with non-operative management

Disc Herniation

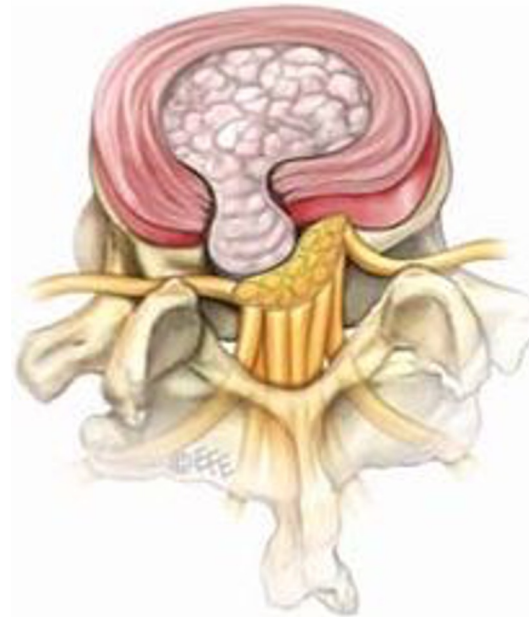
- Back or neck pain
- radicular pain (arm/leg pain) -often worse with sitting, improves with standing and bending at waist
- bilateral leg pain or weakness
- saddle anesthesia
bowel/bladder symptoms



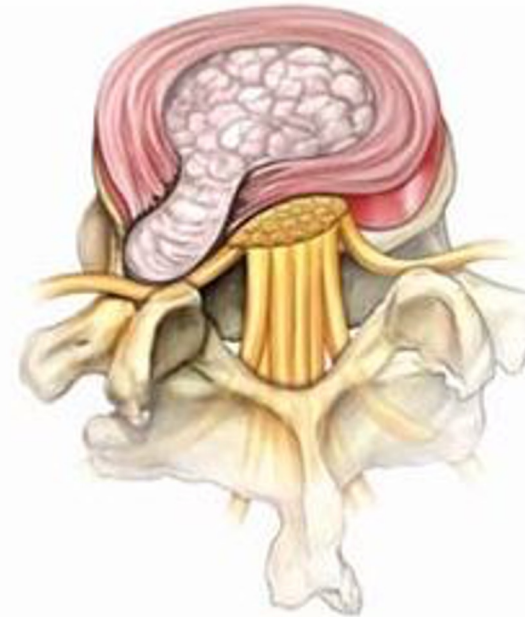


Location of disc herniation

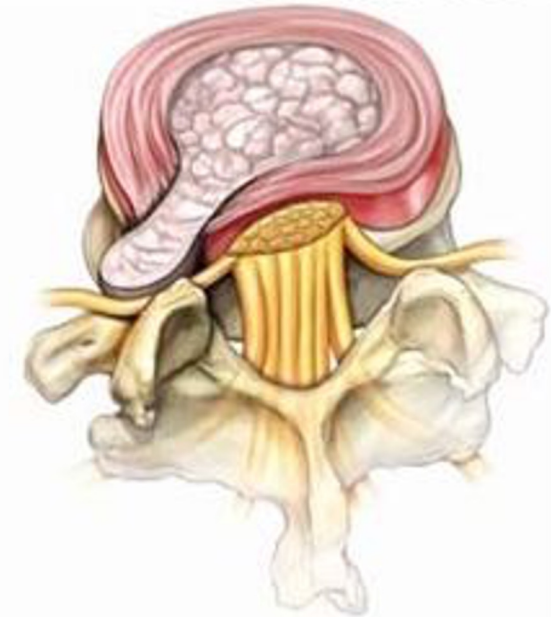
Central or paracentral



(I) Median or paramedian



(II) Foraminal



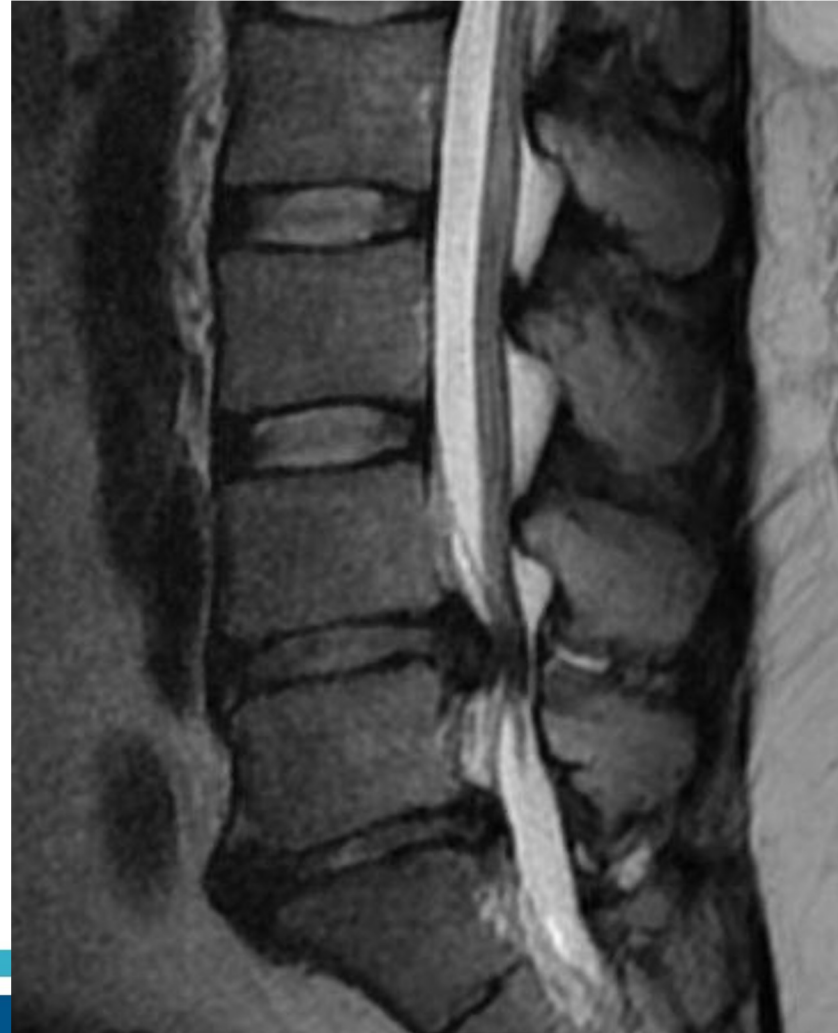(III) Extraforaminal

Foraminal/Extraforaminal

Central Disc Herniation

Potential cauda equina syndrome - peri-anal numbness/tingling, loss of bowel or bladder control

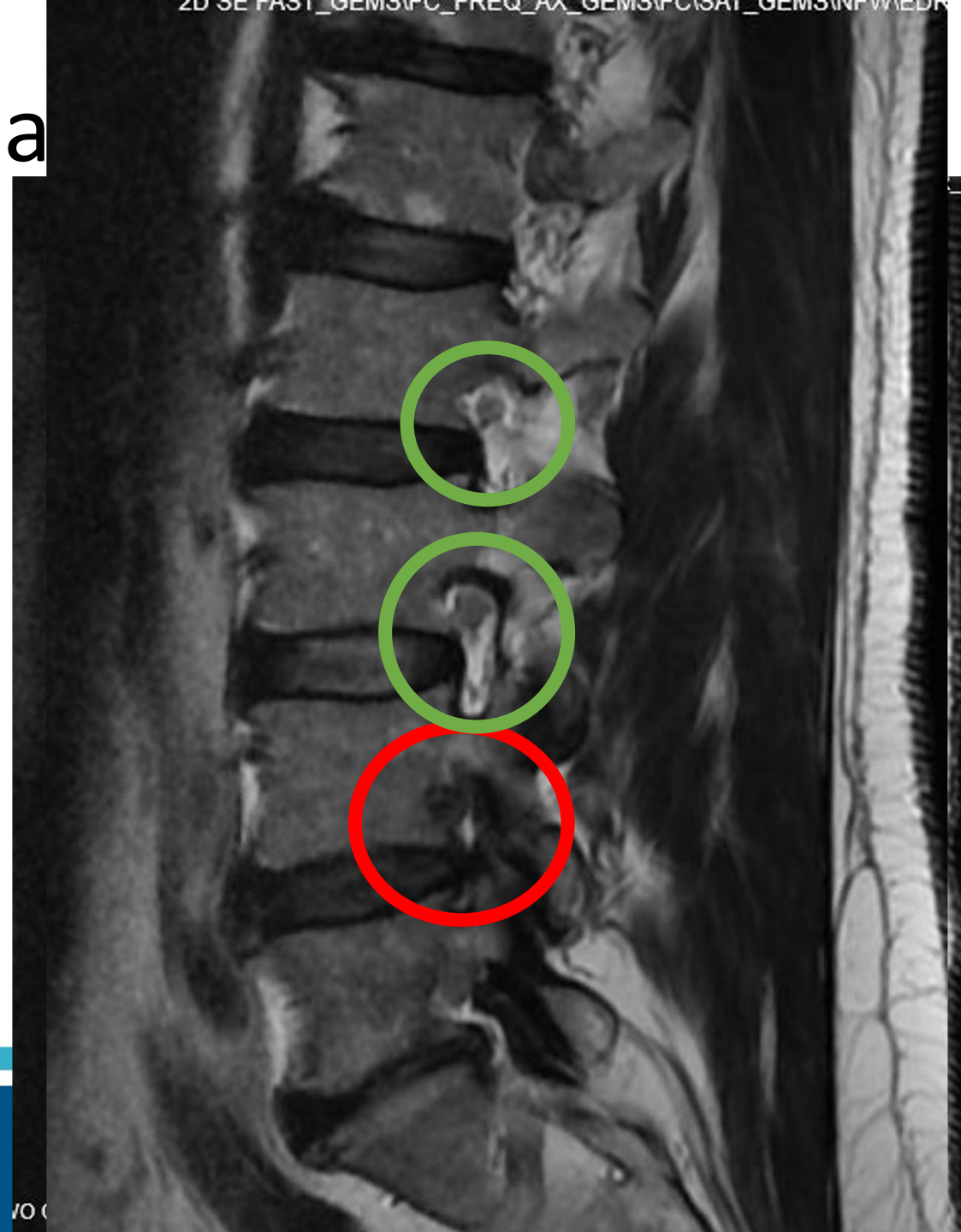
Must perform rectal exam and document rectal tone and sensation



Foramina

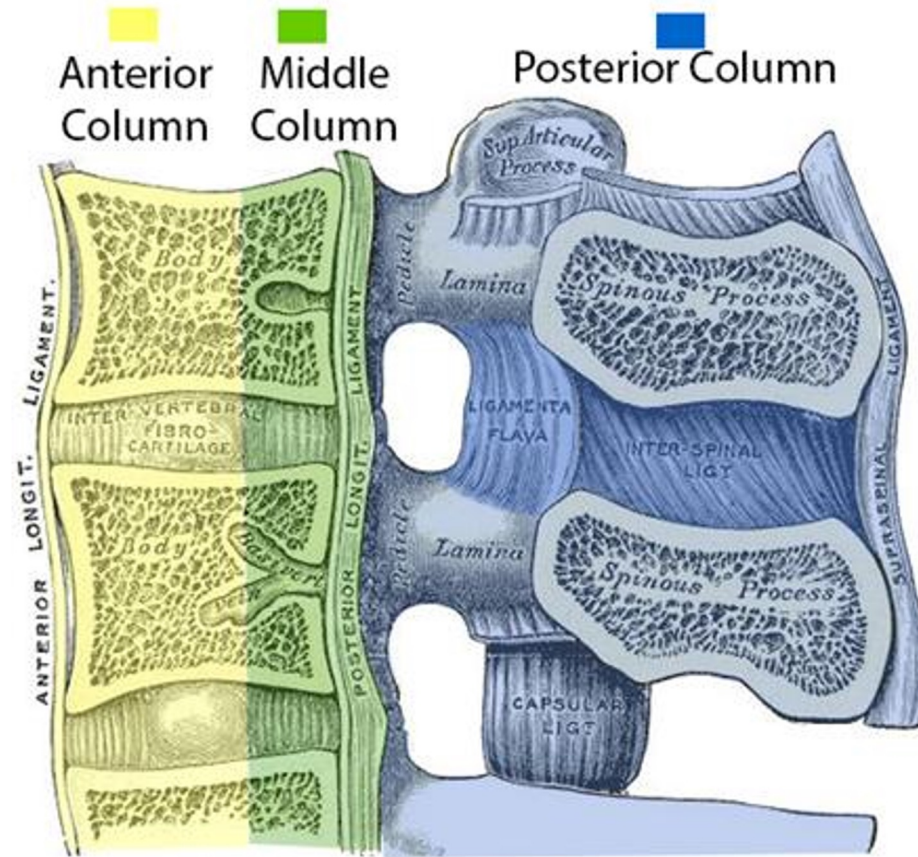
Extremely painful

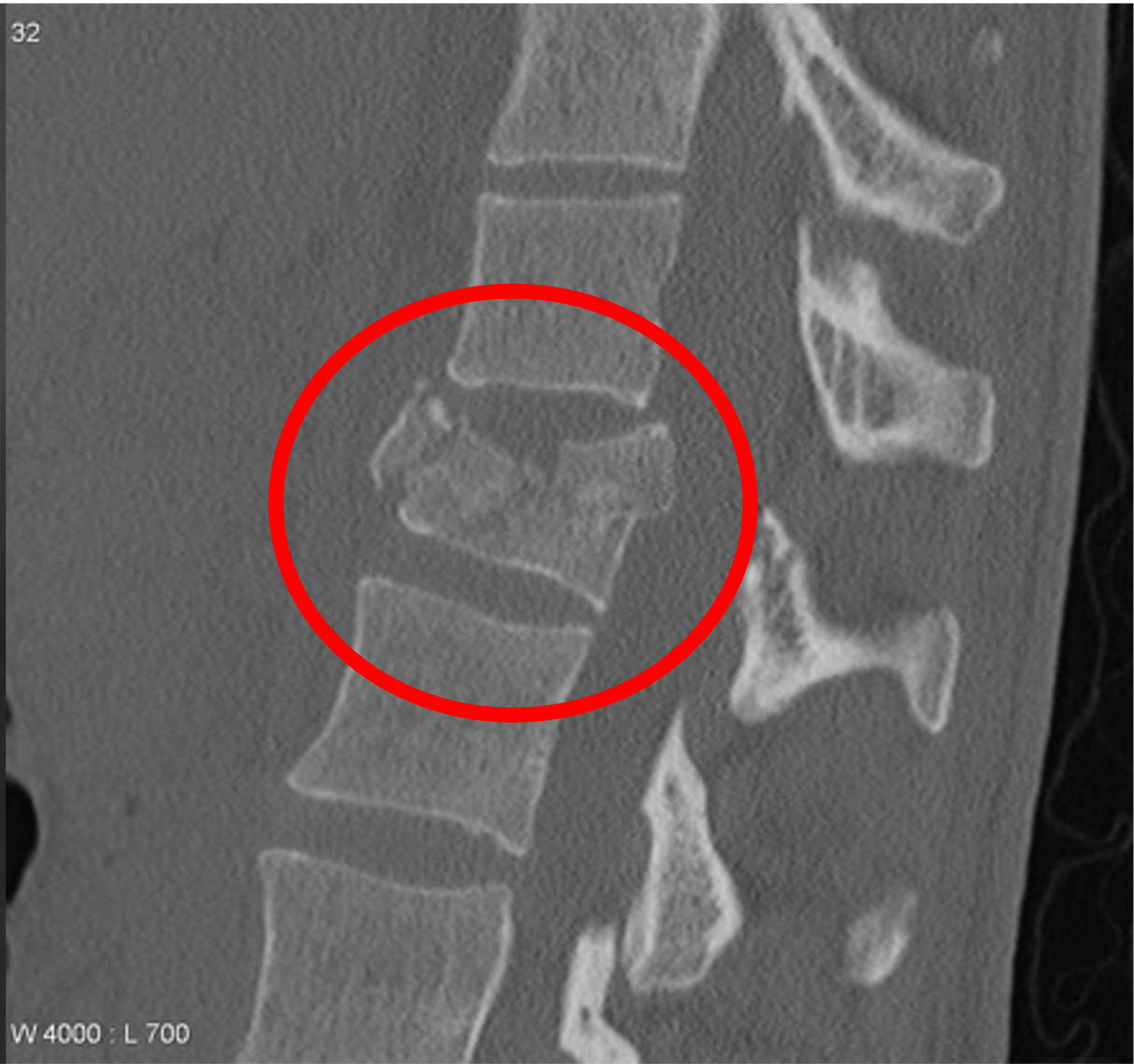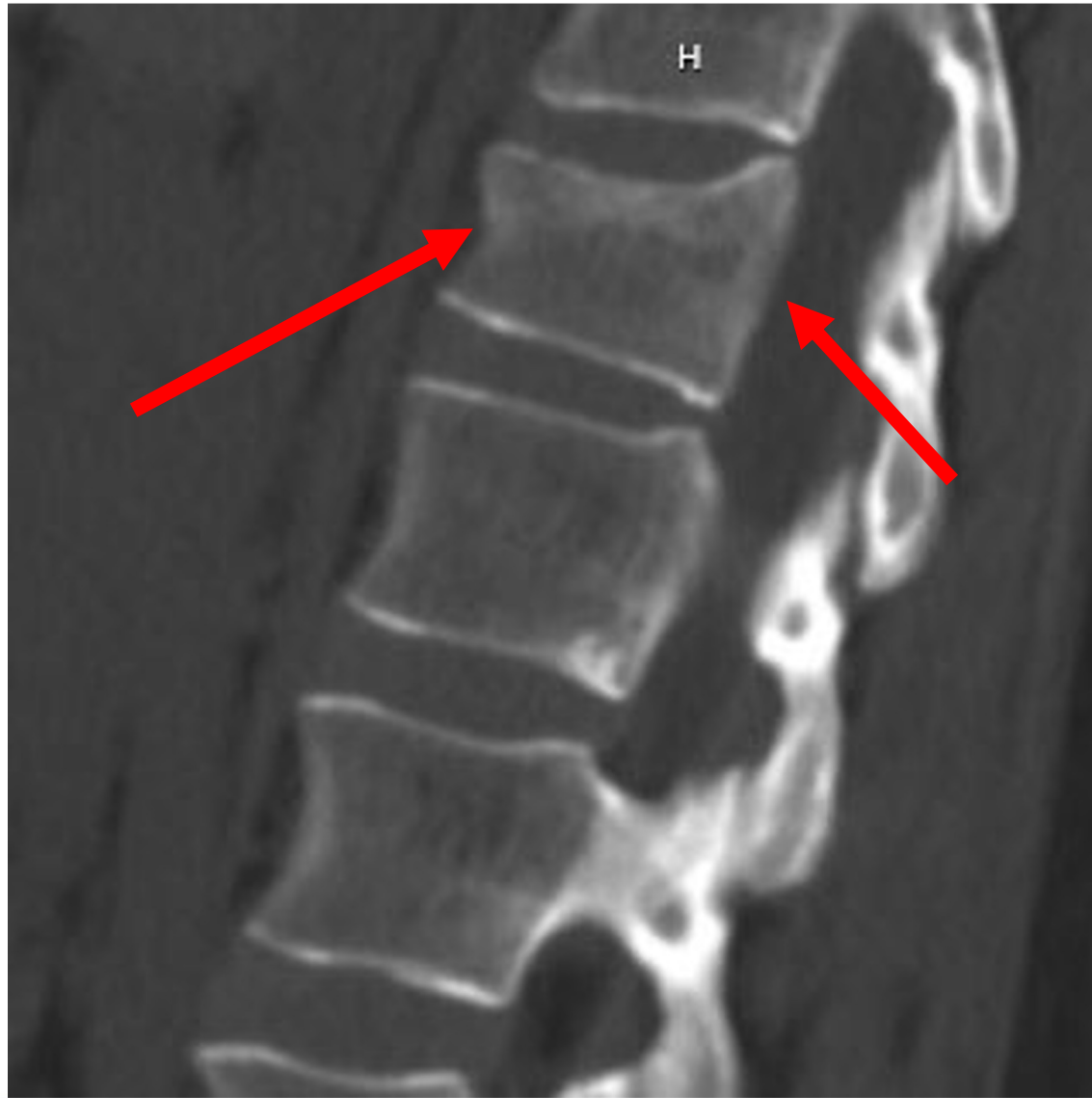Compresses Dorsal Root Ganglion



Fractures

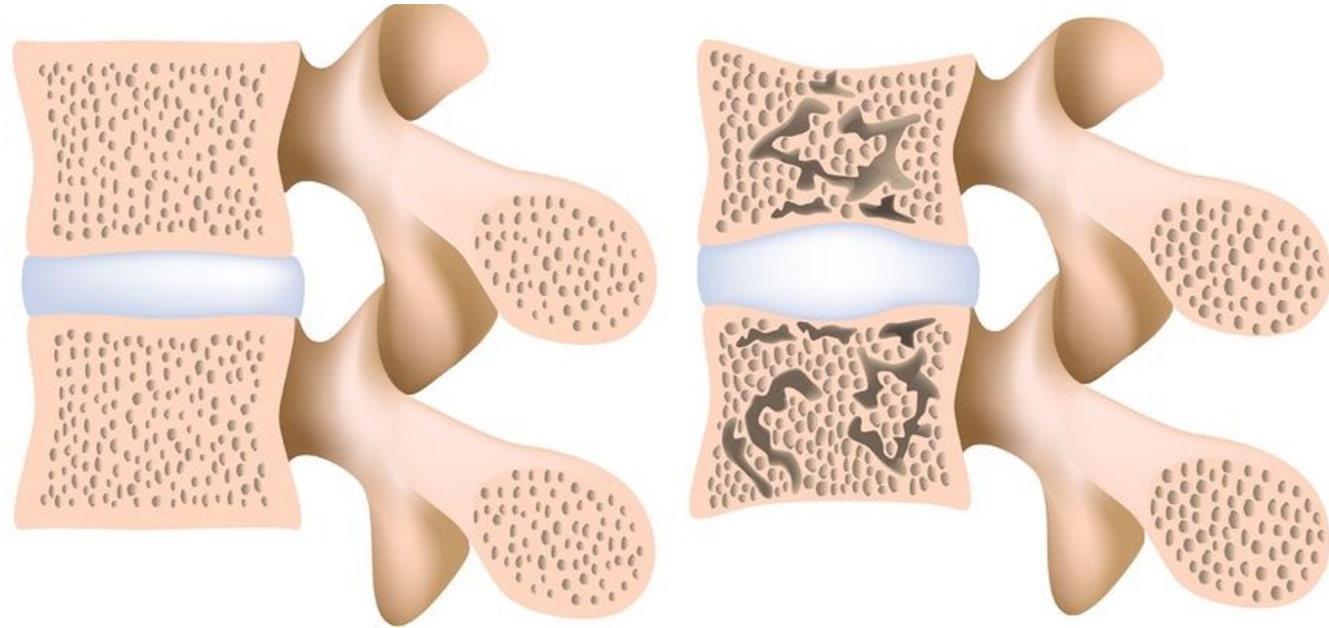
Compression vs Burst

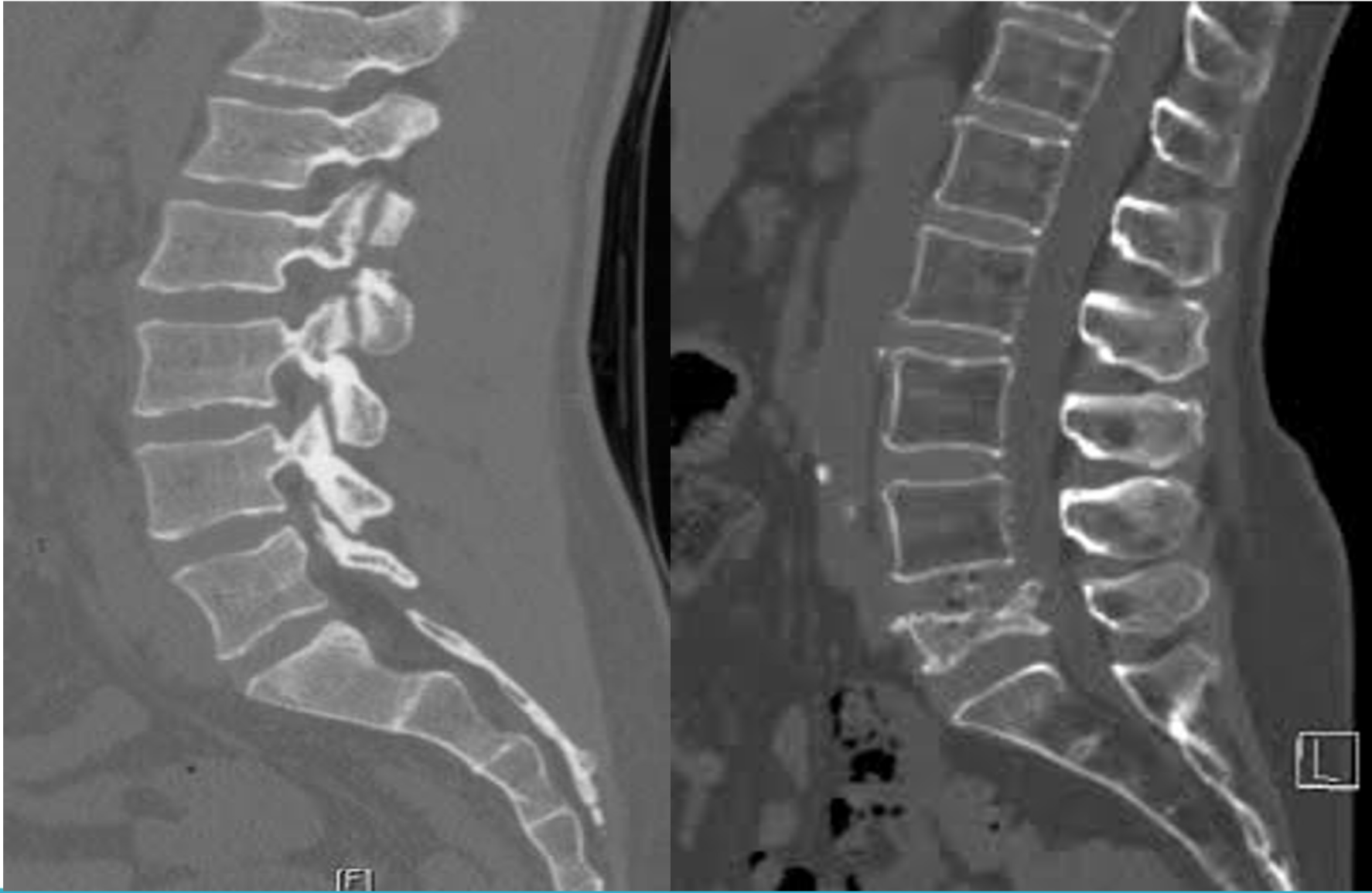



Osteoporosis

- Decrease in bone quantity and density that causes structural weakening of the bones in the body





Osteoporotic Fractures

- 10 million Americans and 200 million people worldwide have osteoporosis
- 34 million Americans have osteopenia
- 1.5 million osteoporotic fractures occur each year
- 700,000 are vertebral fractures

Osteoporotic Compression Fractures

- Vertebral compression fractures (VCF) are the most common fragility fracture
- 70,000 hospitalizations annually
- 15 billion in annual costs

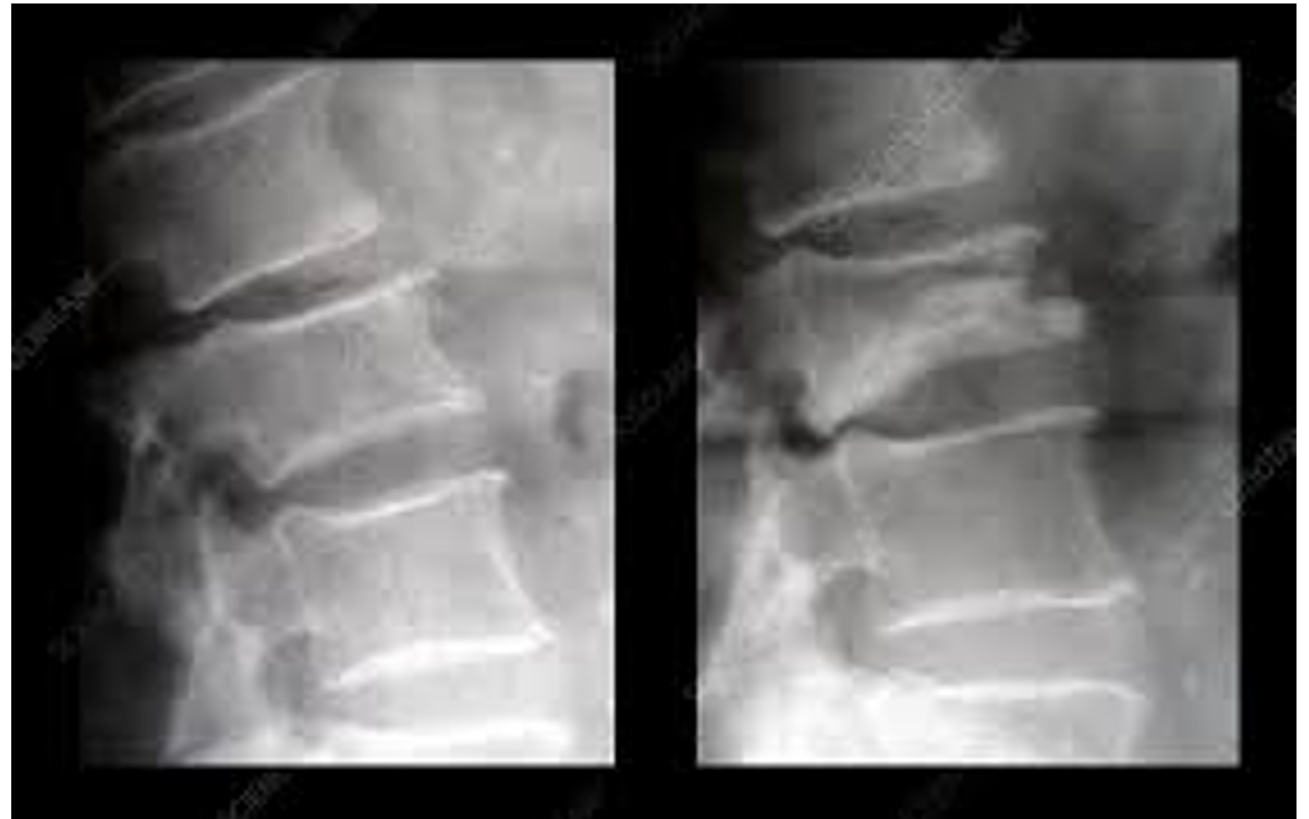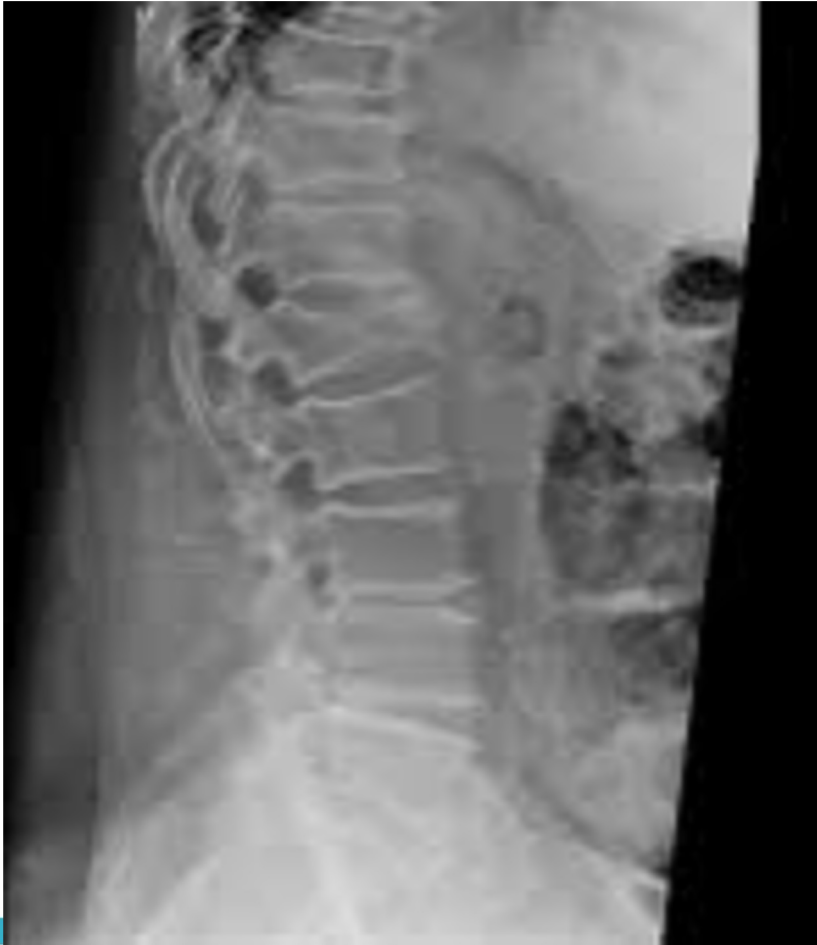Osteoporosis evaluation

- Studies have shown that, when the orthopaedic surgeon/clinic initiates diagnosis and risk stratification, the likelihood that the patient will receive proper treatment increases dramatically.

Osteoporotic Compression Fractures

- Once patient has one compression fracture their risk of having another increases dramatically
- 1-year mortality ~ 15% (less than hip fx)
- 2-year mortality ~20% (equivalent to hip fx)

Compression Fractures



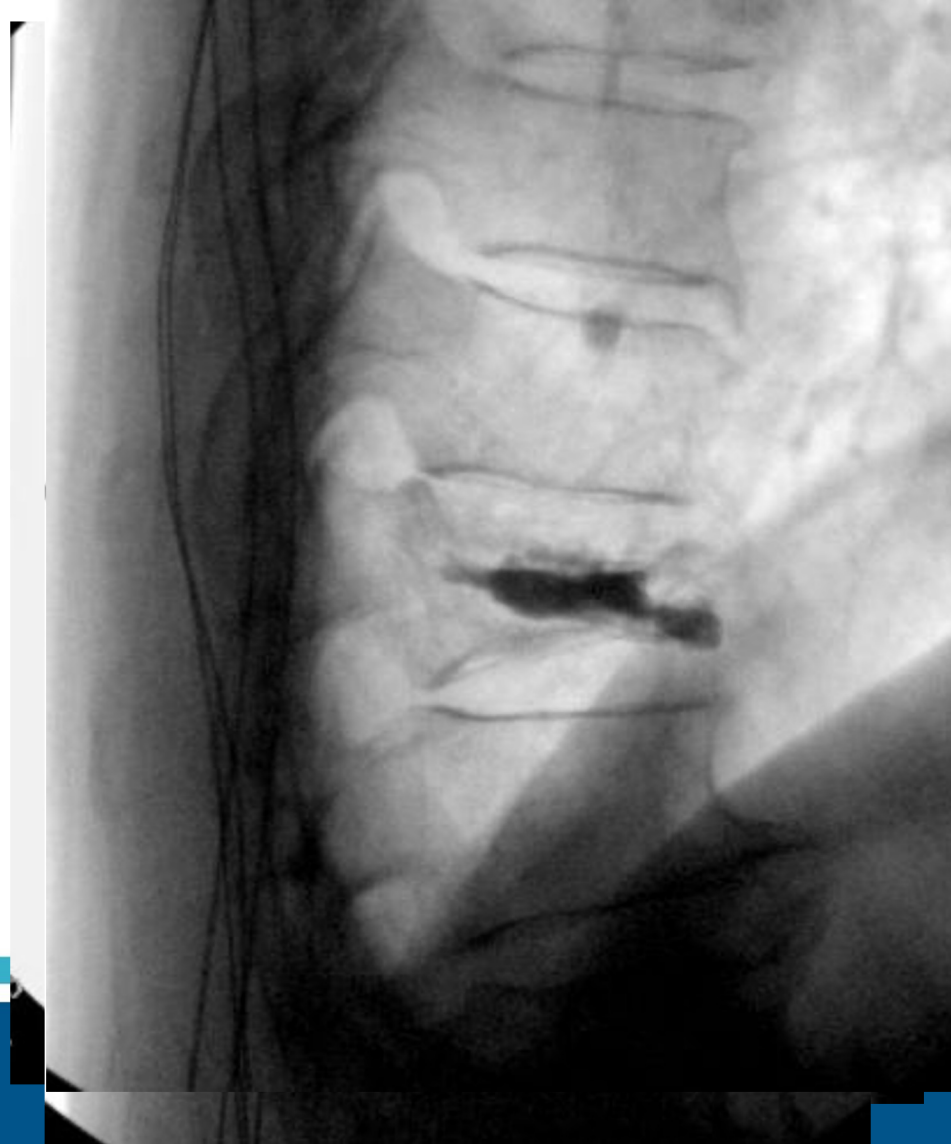
Treatment

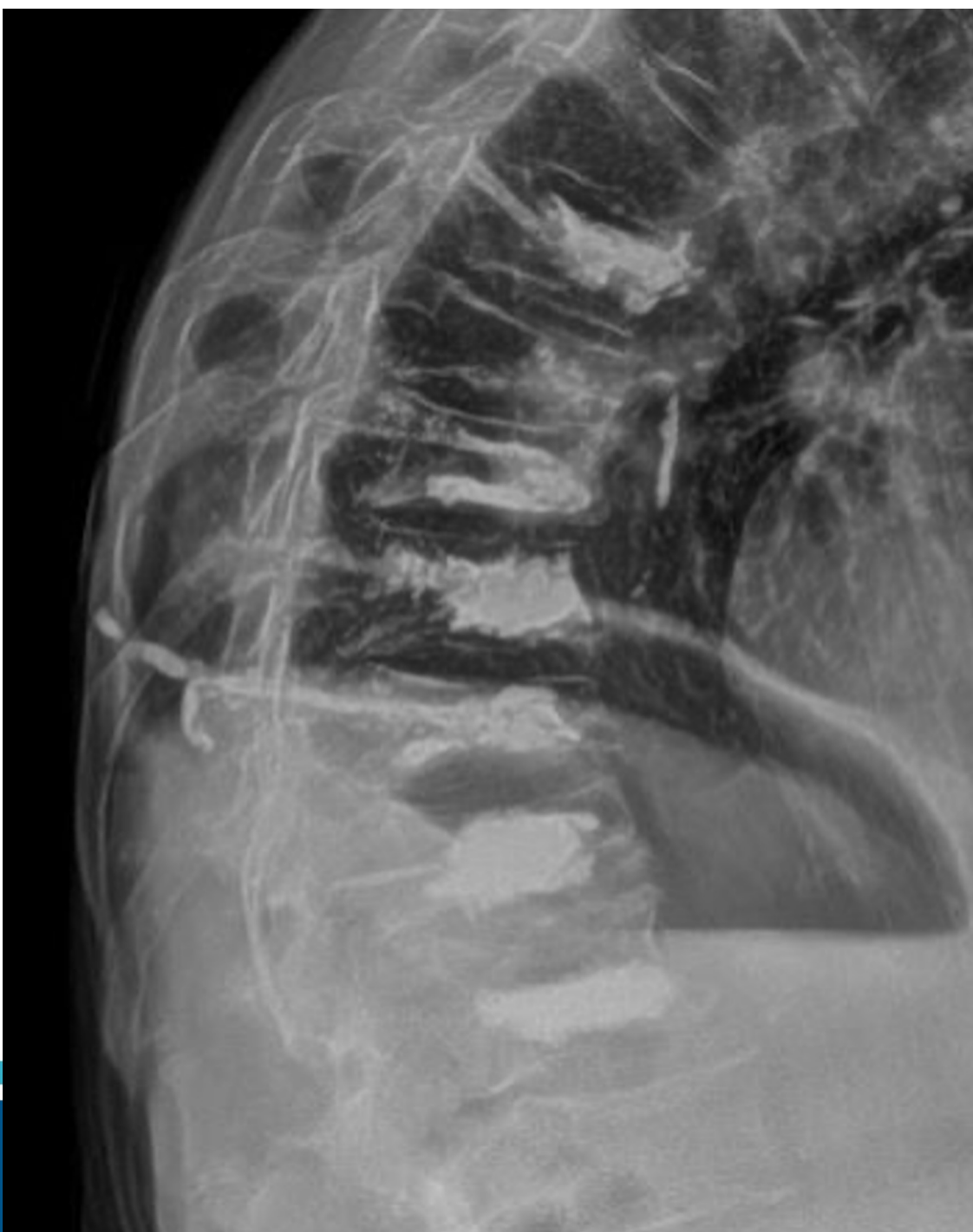
Compression or Burst fracture without neurologic impairment almost always start with conservative management

Brace? - studies show there is some benefit in pain control with brace but not necessarily healing rates or overall outcome

Medications: Intranasal calcitonin shown to improve pain if used in first 6 weeks of fracture (also usual NSAIDs, muscle relaxers etc...)

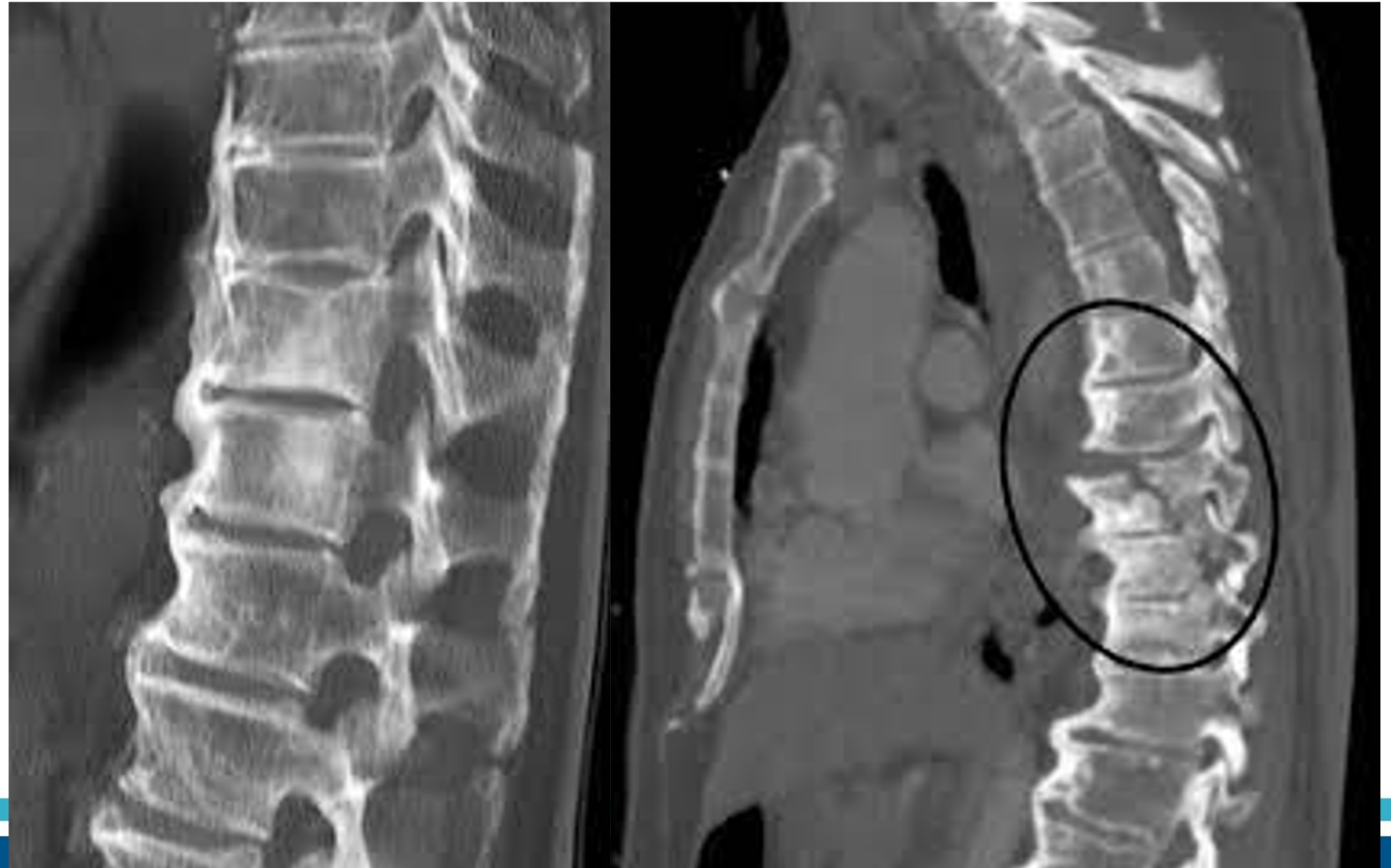Kyphoplasty





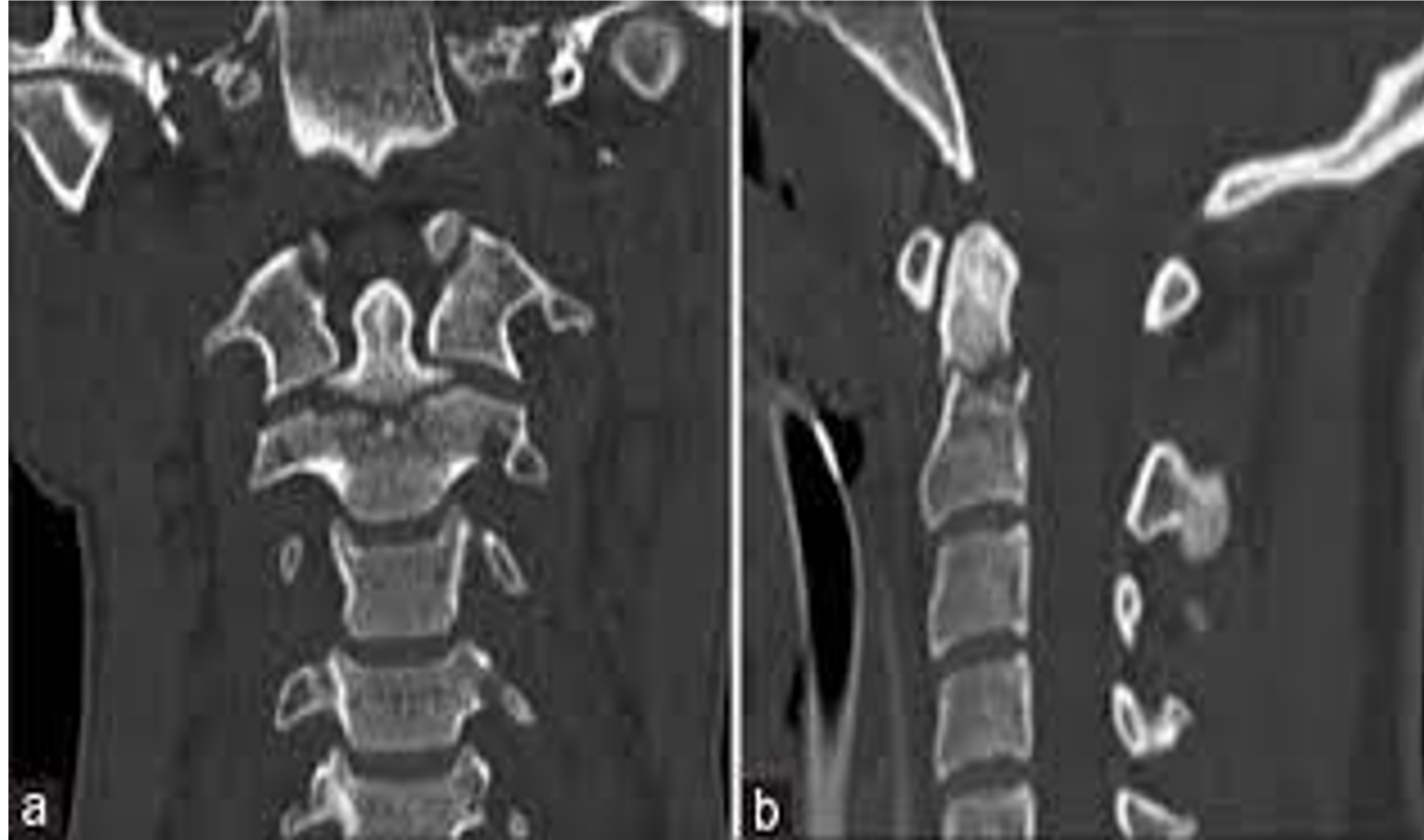
Beware!

DISH or Ankylosis
Spondylitis patients
can have unstable
fractures from low
energy accidents



Odontoid Fractures

- Fracture of C2 vertebrae commonly caused by low energy falls in elderly
- Poor blood supply and healing potential
- Treat in collar as long as no neuro deficits



Red Flags

- Loss of bowel or bladder control
- Acute drastic loss of strength
- Worsening balance or hand or feet dexterity or control
- Worsening back pain with concurrent fever, chills, weight loss, severe fatigue

Thank you. Questions?

