

Managing a patient with acute colonic diverticulitis

Elizabeth Donovan, MPAS, PA-C; Denise Rizzolo, PhD, MPH, PA-C

ABSTRACT

Acute diverticulitis is a common condition in Western society with the potential for substantial patient morbidity. Depending on the severity, the patient's clinical presentation and treatment options vary considerably, leaving uncertainty about optimal management. Traditionally, surgery was recommended to prevent complications, persistent symptoms, and recurrent episodes. Improvements in the understanding of the disease's natural history, diagnostic imaging, and long-term outcomes have prompted changes to diagnosis and treatment guidelines.

Keywords: acute diverticulitis, colonic, colon, treatment, nonsurgical management, surgical management

Learning objectives

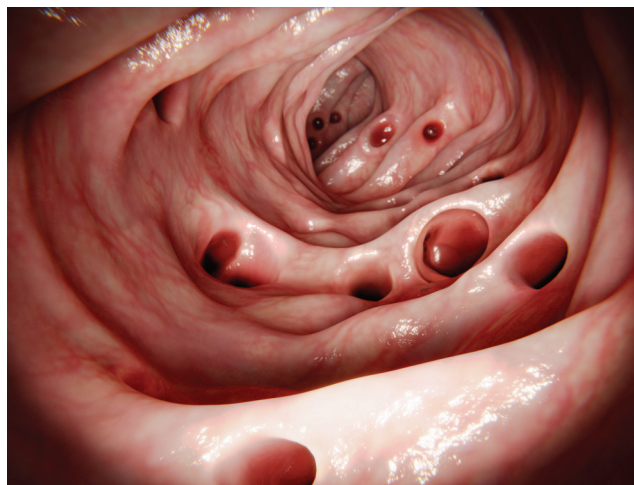
- Review the epidemiology, diagnosis, and treatment of acute diverticulitis.
- Discuss the nuances of acute uncomplicated diverticulitis and acute complicated diverticulitis.
- Describe the surgical and medical treatment considerations.
- Identify risks for recurrence, long-term morbidity, and when to refer patients for surgical consultation.

Acute diverticulitis is a common gastrointestinal disease with rising incidence and burden on the healthcare system.¹ Because of acute diverticulitis' unpredictable presentation, ranging from mild abdominal pain to perforation and sepsis, clinicians in primary care and surgery need evidence-based guidance on the best nonsurgical and surgical treatment approaches.²

Elizabeth Donovan practices in general surgery at Chevy Chase Surgical Associates in Chevy Chase, Md. **Denise Rizzolo** is an assistant clinical professor in the Pace Completion Program in the Department of Physician Assistant Studies in New York City and an assessment specialist at the Physician Assistant Education Association. The authors have disclosed no potential conflicts of interest, financial or otherwise.

DOI:10.1097/01.JAA.0000832644.97318.f3

Copyright © 2022 American Academy of PAs



© JUAN GAERTNER/SHUTTERSTOCK.COM

Acute diverticulitis can be uncomplicated or complicated (characterized by presence of an abscess, fistula, stricture, or free perforation).³ Changes to the treatment paradigm over the past 10 years focus on the selective use of antibiotics for uncomplicated diverticulitis and a decline in the number of elective colon resections performed.^{4,5} However, no medical treatments exist to reduce the risk of recurrence and there are no clear guidelines for when elective colon resection is appropriate.^{4,6} Treatment goals for patients with acute diverticulitis should be to alleviate symptoms, prevent complications associated with recurrence, and perform elective surgery when appropriate to minimize morbidity and mortality associated with emergency surgery.⁷ A comprehensive review of diverticular disease pathogenesis and risk factors was published in the October 2018 issue of *JAAPA*.⁸ This article reviews current literature on operative and nonoperative treatment of acute diverticulitis.

EPIDEMIOLOGY

Diverticular disease encompasses a wide range of conditions defined by clinically significant and symptomatic diverticula. An estimated 60% of patients over age 60 years have diverticular disease, and population data show the incidence and number of diverticula increases with age.^{9,10} A 2019 report found that 208,015 hospital admissions each year were for acute diverticular disease of the colon,

Key points

- The clinical presentation of acute diverticulitis varies widely.
- Medical and surgical treatment paradigms for acute diverticulitis have changed over the past 10 years based on quality research.
- Treatment goals should address alleviating symptoms, minimizing adverse reactions, and preventing recurrence and surgical morbidity.
- Elective surgical management should be decided on a case-by-case basis.

and the aggregate cost associated with this care was estimated at more than \$2 billion.¹¹

Much of the research on acute diverticulitis focuses on acute left-sided colonic disease, the most common presentation in Western countries.^{2,12} Acute right colonic diverticulitis is much less common and is more often seen in patients of Asian descent.

Eighty-five percent of acute diverticulitis cases are uncomplicated, and the prevalence is increasing in patients under age 50 years.^{10,13,14} Ten to 25 percent of patients with diverticulosis will experience a first episode of acute diverticulitis, known as the incident or index episode. However, the true prevalence may be lower, based on a recent population-based study showing that the long-term risk of acute diverticulitis in patients with incidental diverticular disease on screening colonoscopy was closer to 4.3%.^{2,10,14} Sex and age studies show the incidence is higher in men until age 60 years; thereafter it becomes more common in women.⁴

RISK FACTORS

Factors linked to the development of diverticular disease include weakness of the bowel wall, increased intraluminal pressure, dysmotility, genetic predisposition, lack of dietary

fiber, constipation, and age.² These changes can lead to colonic stasis and obstruction of diverticula (Figure 1). In patients with known diverticular disease, modifiable risk factors for acute diverticulitis include smoking, obesity, poor diet, and alcohol consumption.⁴ The regular use of nonsteroidal anti-inflammatory drugs (NSAIDs) increases the risk of complicated diverticulitis and free perforation.^{3,4} NSAID enteropathy and perforation are due to increased mucosal permeability, inflammation, erosion, and ulceration.¹⁵ Regular use (two or more times per week) is associated with a 70% increased risk of diverticulitis, and non-aspirin NSAIDs are associated with a greater risk than aspirin.³ For this reason, the American Gastroenterology Association does not recommend discontinuing aspirin therapy in patients with a history of acute diverticulitis and coronary artery disease who may value the secondary prevention benefits of aspirin use.¹⁶

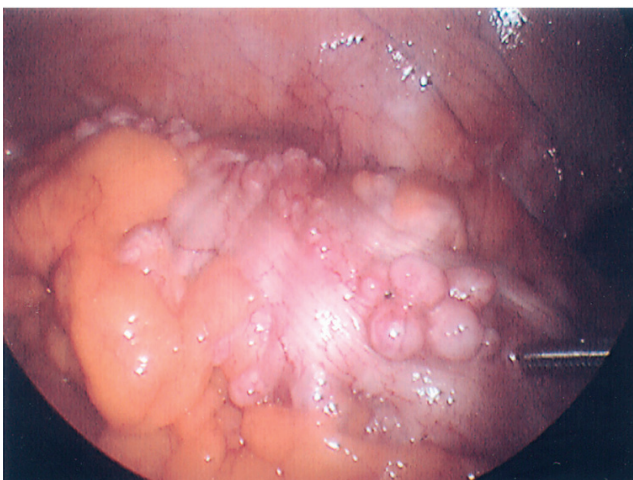
PATHOGENESIS

The pathophysiology of acute diverticulitis as a mechanical alteration in the wall of the colon, trapping stool and bacteria with localized inflammation and microperforation, has been challenged.^{9,13,16,17} A more recent theory of inflammation as the basis for pathogenesis is derived from several areas of research. Multiple studies show associations between mucosal inflammation and diverticulitis with states of chronic inflammation (Western diet, physical inactivity, and obesity), variations in the gut microbiome, and increased inflammatory biomarkers.^{2,4,18-21} Similarities are seen in mucosal biopsies of patients with inflammatory bowel disease (IBD) and chronic diverticular disease.⁴ The prevalence of obesity in the United States is a significant health determinant; not only is obesity associated with the chronic inflammatory state implicated in the pathophysiology of acute diverticulitis, but the concomitant increased visceral-to-subcutaneous fat ratio and loss of skeletal muscle also increase the rate of severe postoperative complications.²

PATIENT EVALUATION

The important findings in a patient with acute diverticulitis are left lower quadrant abdominal pain (70%), fever, leukocytosis, sometimes diarrhea, and the absence of vomiting.^{2,5} Left lower quadrant tenderness, localized rebound or guarding, and sometimes a palpable mass or fullness are noted on physical examination. Although rarer, right-sided abdominal pain associated with right colonic diverticulitis should be considered (especially in patients of Asian descent) and needs to be distinguished from appendicitis on imaging. Order routine laboratory tests, including complete blood count, metabolic panel, and urinalysis, to evaluate for pyuria, which could be a sign of colovesical fistula. Consider stool studies to rule out an infectious cause of diarrhea. Biomarkers such as C-reactive protein (CRP), procalcitonin, and fecal calprotectin are

FIGURE 1. Colonic diverticula seen on laparoscopy. Image reprinted with permission from Mohammed Kalan, MD, FACS, FRCS.



not routinely used in uncomplicated cases but can be used to monitor more complicated disease.⁵

Although acute left lower quadrant abdominal pain has a broad differential, this is addressed by the ubiquitous use of contrast-enhanced CT. As the gold standard, CT evaluates for alternative diagnoses and disease severity, thereby aiding in identifying potential risks of failed nonoperative management and the need for future surgical intervention.^{5,12} The selective use of CT to reduce the cost of care and radiation exposure in patients with suspected mild diverticulitis has been proposed but remains under debate. This approach has consensus support in some but not all surgical societies.^{1,5} Point-of-care ultrasound (POCUS) in the ED is under study as an alternative to CT. Diverticulitis on ultrasonography is characterized by edema of the bowel wall greater than 5 mm and surrounding a diverticulum, enhancement of pericolic fat (indicating inflammatory changes), and tenderness with probe palpation.²² The potential benefits of POCUS include lower costs, less patient time in the ED, and avoiding exposure to ionizing radiation. POCUS can have comparable sensitivity and specificity to CT in the hands of a well-trained and experienced operator; however, its use is not standard of care because it is operator-dependent.²² The importance of this skill set continues to gain traction with the implementation of more formal POCUS training in some PA programs.

UNCOMPLICATED OR COMPLICATED?

Distinguishing uncomplicated from complicated diverticulitis helps to determine whether the patient needs antibiotics, avoids unnecessary hospital admission, lowers overall healthcare costs, and can predict whether conservative treatment will be successful.²³ Eighty-five percent of acute diverticulitis is uncomplicated with evidence of diverticula, thickening of the bowel wall, and increased density of the pericolic fat or stranding on CT.^{12,24} The inflammation and possible microperforation localizes to the bowel wall and mesenteric fat.

Complicated diverticulitis is defined as the presence of an abscess, fistula, stricture, or free perforation on CT. Although the incidence of complicated diverticulitis ranges from 12% to 40%, about 80% of patients can be successfully managed without surgery.^{4,12,25,26} Abscess is the most common complication seen on CT, accounting for 15% to 20% of complicated cases.^{2,12,27,28} Multiple grading systems can be used for complicated diverticulitis, but none are superior in predicting outcomes.¹² The CT-based modified Hinchey classification (Table 1) is the most often used, with the primary goal of determining the extent of intra-abdominal contamination.

CRP is the only biomarker with data to show an association with uncomplicated and complicated acute diverticulitis. Studies have shown that CRP greater than 50 mg/L at the time of symptom onset strongly supports the diagnosis of acute diverticulitis, and CRP greater than 100 mg/L

TABLE 1. Modified Hinchey Classification^{11,25}

- Stage 0—mild clinical diverticulitis
- Stage Ia—confined pericolic inflammation
- Stage Ib—confined pericolic abscess
- Stage II—pelvic or distant intra-abdominal abscess
- Stage III—generalized purulent peritonitis
- Stage IV—fecal peritonitis at presentation

in association with abdominal guarding and leukocytosis is a strong predictor of more severe or complicated diverticulitis.^{20,21} CRP greater than 150 mg/L accurately discriminated acute complicated diverticulitis from uncomplicated diverticulitis and was an independent risk factor for postoperative mortality.²⁹ However, because of limited evidence, the American Society of Colon and Rectal Surgeons (ASCRS) does not support the routine use of CRP levels to distinguish uncomplicated from complicated acute diverticulitis.⁵ Considering the patient's entire clinical picture is essential when determining severity, because objective findings alone do not always predict a decline in the patient's condition.

NONOPERATIVE MANAGEMENT: UNCOMPLICATED CASES

Treatment decisions for acute diverticulitis depend primarily on CT findings that delineate uncomplicated from complicated acute diverticulitis. Nonoperative management is appropriate for most patients with uncomplicated diverticulitis (modified Hinchey stages 0 to Ia). The treatment of CT-proven uncomplicated acute diverticulitis can be provided safely on an outpatient basis, which reduces the cost of care.^{23,30} A meta-analysis looking at the safety of outpatient management concluded that this approach was safe in selected patients (40%), and failure was more common in patients with previous diverticulitis and comorbidities.^{23,30}

The mainstays of outpatient therapy are dietary modification, pain control, and antibiotics. A clear liquid diet for 2 to 3 days, advancing to a low-fiber diet, achieves the needed bowel rest. Acetaminophen and antispasmodics can be used to treat pain. Oral antibiotics for 7 to 14 days covering Gram-negative and anaerobic organisms are routine.² Common regimens used are amoxicillin/clavulanate, ciprofloxacin/metronidazole, or monotherapy with moxifloxacin.³ Follow-up is recommended in 3 to 5 days to evaluate for an appropriate treatment response, to provide further counseling, and to recommend specialty referral if needed. Observation without antibiotics in selected patients with mild acute diverticulitis accounts for the most recent change in the treatment paradigm, focusing on antibiotic stewardship. There is robust evidence that most patients with mild CT-proven uncomplicated acute diverticulitis treated without antibiotics show no

significant difference in rates of complications or time to recovery compared with those treated with antibiotics. This evidence comes from multiple studies, including two European randomized controlled trials.^{19,31} The long-term follow-up studies for both trials showed no significant differences between the treatment groups in recurrence rates, complications, or surgery for diverticulitis.^{32,33}

The definition of failed conservative treatment without antibiotics varies widely and may constitute requiring antibiotic treatment, hospital admission, recurrent symptoms after 1 month, or the need for intervention such as percutaneous abscess drainage or surgery.³⁴ Rates of failed treatment without antibiotics across studies range from 3% to 24%, depending on its definition.²¹ Risk factors for failed conservative treatment are female sex, older age, immunosuppression, free fluid around the colon, comorbidities, American Society of Anesthesiologists (ASA) classification greater than 2, and CRP level greater than 170 mg/L.^{4,12,21} A 2019 meta-analysis comparing successful and failed nonantibiotic treatment of uncomplicated acute diverticulitis found no statistical difference using the “need for additional intervention to settle the initial episode” as the defined endpoint.³⁴ Examination of the current evidence has led to society guidelines recommending careful consideration of conservative treatment without antibiotics, with the caveat that disease severity is variable.^{1,5,12} Despite this strong evidence, the nonantibiotic approach is not widely accepted in the United States, possibly due to less concern for antibiotic stewardship, well-established practice patterns, and medicolegal concerns.³⁵

NONOPERATIVE MANAGEMENT: COMPLICATED CASES

Acute complicated diverticulitis with abscess occurs in about 15% to 20% of all patients with acute diverticulitis.¹² The intermediate grades of CT-confirmed Hinchey Ib and II define this subgroup of patients who typically require inpatient treatment with IV antibiotics with or without abscess drainage.³⁶ Inpatient treatment also includes bowel rest and IV fluids.^{6,36,37} Monitoring for clinical deterioration is required, as classification does not always predict severity or the need for surgery.⁶ This approach is successful in up to 80% of patients; however, some will not respond to nonoperative management and ultimately require surgery.^{24,26,36}

In complicated cases, the mainstay of nonoperative inpatient treatment is empiric therapy with broad-spectrum IV antibiotics covering Gram-negative and anaerobic organisms, once source control is achieved.^{37,38} Source control is “the mechanical process that contains, restricts and eradicates from the peritoneal cavity microbial pathogens, inflammatory exudates and necrotic tissue that drive the systemic septic response.”³⁷ The source can be any degree of intra-abdominal contamination, from a localized abscess adjacent to the colon to feculent peritonitis.²

Perforation of a diverticulum can present with a small amount of pericolic free air, which is not considered complicated, to large amounts of free air or fluid consistent with gross perforation and feculent contamination requiring urgent surgery.²⁷ In the absence of peritonitis with sepsis, the approach to nonoperative source control is determined by abscess size and location. All abscesses, regardless of size, require antibiotic therapy. Localized pericolic abscesses 3 to 4 cm or smaller may not be amenable to percutaneous drainage. Larger abscesses (greater than 4 cm or distant from the site of inflammation) require percutaneous drainage for source control, because antibiotics alone may not achieve adequate tissue concentration.

Once source control is achieved, the length of antibiotic treatment need not be prolonged; the length of therapy varies with disease severity and practice patterns.³⁹ Following the initiation of treatment with broad-spectrum antibiotics, clinicians should consider narrowing the therapy based on culture data (if available) and assess the appropriate length of therapy.⁴⁰ A randomized controlled trial by Sawyer and colleagues comparing 4 days of antibiotic therapy with 8 days demonstrated similar outcomes for both groups after source control was achieved.³⁹ The Agency for Healthcare Research and Quality recommends 5 to 10 days of therapy (based on clinical response and reimaging) in cases without percutaneous abscess drainage or 4 days following surgical management or drainage.⁴⁰ Percutaneous drain management involves monitoring output and flushing daily with 0.9% sodium chloride solution to keep the catheter patent. Once the output is less than 10 mL/24 hours, the drain can be safely removed if fluoroscopic sinogram confirms resolution of the abscess.

Although colonoscopy has no role in the acute setting because of the risk of perforation, consider it 6 to 8 weeks following resolution of an acute episode of complicated diverticulitis to rule out malignancy. Routine colonoscopy following an acute episode of uncomplicated diverticulitis is controversial, based on study evidence showing the diagnostic yield is similar to the background rate in an age-matched reference population.⁴¹ However, more recent literature describes a significantly higher incidence of occult malignancy in patients with complicated diverticulitis, and highly recommends colonoscopy.⁵

Extensive surgical literature looking at the failed nonoperative treatment of diverticular abscess stems from limited quality evidence to guide clinicians in treating this intermediate group.⁴² The definition of failure, although not always widely agreed upon, includes development of sepsis, need for surgery, or recurrent abscess within 30 days.⁵ Multiple studies looking at patients with modified Hinchey Ib and II disease found an overall recurrence rate of 28%.⁴² Rates of failed nonoperative management leading to additional treatment range from 15% to 40% across studies.²⁵ How to predict failure

remains unclear because some abscesses resolve without percutaneous drainage and heterogeneity across studies is a limiting factor.⁴² Multiple studies have identified associations between failure of nonoperative management and the following factors: elevated CRP, age 60 years or older, previous episodes of acute diverticulitis, high-risk abscesses (pelvic, 5 cm or greater, needing percutaneous drainage), and extraluminal air.^{7,21,28,36,43} A retrospective multicenter study by Lambrechts and colleagues found higher failure rates of nonsurgical management in cases with abscesses greater than 5 cm, leading to surgery in the short term.³⁶

OPERATIVE MANAGEMENT: COMPLICATED CASES

The indication for urgent surgery and the approach are dictated by the patient's clinical condition and surgeon preference.² Between 15% and 32% of all patients admitted for acute diverticulitis will require emergency surgery.³⁶ Indications include cases of purulent or fecal peritonitis (modified Hinchey III and IV), sepsis, hemodynamic instability, extraluminal air, inability to rule out malignancy, and nonoperative treatment failure.^{1,2,5} A subgroup of patients with symptomatic fistulae (colovesical or colovaginal) or acute colonic obstruction due to stricture will require urgent or semielective resection.⁵

The historical gold standard approach to complicated acute diverticulitis with perforation and generalized peritonitis is exploratory laparotomy, sigmoid colon resection, and the creation of a colostomy or Hartmann procedure.^{2,3} Although this approach is safest for the most acutely ill patients, it carries higher 30-day operative mortality and permanent stoma rates, which has led to research on alternative approaches.⁵ Three small randomized controlled trials comparing Hartmann procedure to primary colonic anastomosis, with or without the creation of a diverting loop ileostomy, have shown no significant difference in overall complication rates, morbidity, or mortality.⁴⁴⁻⁴⁶ The benefit of the latter approach was higher ileostomy reversal rates compared with the Hartmann colostomy.⁴⁴⁻⁴⁶ The decision to create the diverting ileostomy is based on the degree of intra-abdominal contamination and tissue friability from acute inflammation, both of which contribute to the risk of a leak from the colonic anastomosis.⁵ Postoperative primary anastomotic leak may lead to abscess formation, requiring percutaneous drainage or reoperation with diverting colostomy. A recent multivariable analysis of the National Surgical Quality Improvement Program (NSQIP) database found no difference in morbidity or mortality between the two approaches, concluding that primary anastomosis with diverting ileostomy for Hinchey III and IV diverticulitis is a safe alternative to Hartmann procedure in stable patients.^{47,48} In turn, the 2020 ASCRS guidelines have given a strong recommendation for primary anastomosis, with or without diverting loop ileostomy, instead of Hartmann procedure based on moderate-

quality evidence.⁵ However, other research shows that adoption of this approach remains low.^{5,49}

Laparoscopic lavage for the treatment of Hinchey III diverticulitis has been studied as an alternative to urgent sigmoid resection with stoma formation. After three randomized controlled trials comparing laparoscopic lavage with colectomy, controversy remains because of significant variation in methods and endpoints, contradictory results, and increased rates of short-term adverse events with laparoscopic lavage (such as surgical site infection and unplanned reoperation).⁵⁰⁻⁵² Advantages of laparoscopic lavage include shorter operative times, fewer surgical site infections, decreased need for stoma formation, and shorter length of hospital stay.⁵ Disadvantages include increased risks of intra-abdominal abscesses, peritonitis, future emergency operations, missed malignancy, and unresolved or recurrent diverticulitis.^{1,5,12,53} Some investigators consider this less invasive approach safe for emergent source control and a bridge to safer elective resection in selected cases of Hinchey III diverticulitis.⁵³ Laparoscopic lavage is currently not recommended as first-line therapy for Hinchey IV diverticulitis.^{1,5,12}

ROLE OF ELECTIVE SURGERY

Deciding when to recommend elective surgery is a subject of great debate. Historically, elective surgery was intended to prevent recurrence, complications, and the need for emergency surgery with stoma formation.⁵ The criteria for elective colectomy formerly considered the number of previous episodes (two or more), chronic symptoms following treatment of acute diverticulitis, abscesses greater than 5 cm in size or pelvic in location, age under 40 years, and immunosuppression.^{5,54} The decline in the number of elective sigmoid resections over the past 10 years stems from extensive research looking at recurrent uncomplicated and complicated acute diverticulitis separately.^{1,5,12,43}

Recurrent uncomplicated acute diverticulitis. Recurrence rates following an episode of uncomplicated acute diverticulitis range widely in different studies, from 15% to 40%.^{5,10,49,55} Long-term retrospective data on patients following an episode of uncomplicated acute diverticulitis show a significant increase in recurrence risk with each subsequent attack.⁵⁶ Despite the risk of recurrence, complicated presentation and need for emergency surgery were no more likely with each episode; three or more previous episodes was the only independent risk factor.^{26,57-59} Other risk factors with variable predictive value include age over 55 years, previous complicated diverticulitis, smoking, obesity, and significant comorbidities.⁵⁶ Although data show elective colon resection has not decreased the number of emergency surgeries for acute diverticulitis, 25% to 36% of patients will have chronic symptoms of smoldering diverticulitis without inflammation on CT and may obtain relief from elective resection.^{4,54,60,61} The DIRECT trial and other studies compared elective surgery versus

observation in patients with multiple previous episodes of acute diverticulitis, and surgically treated patients reported less chronic abdominal pain and better quality of life (QOL) scores.^{54,61} Improved outcomes in patients with recurrent uncomplicated acute diverticulitis without surgery are likely related to the effect of widespread use of high-resolution CT, percutaneous abscess drainage, and better antibiotics.⁶² Treatments directed at altering the gut microbiome and minimizing chronic inflammation (such as probiotics, rifamixin, and mesalamine) have not proven effective in preventing recurrent episodes, resolving chronic symptoms, or eliminating the need for surgery.^{4,5,16} In the absence of proven medical therapy to prevent recurrence or chronic symptoms, patients should discuss preferences and operative risk with a surgeon.^{5,13,43,56,62}

Recurrent complicated acute diverticulitis. Patients with CT-proven modified Hinchey Ib–II abscesses are the most controversial group regarding whether to recommend elective surgery after nonoperative management. Recommendations for elective colon resection in this group have been based on data showing higher recurrence rates (up to 40%) and more complications such as stricture and fistulae.^{4,24,27,59} Over the past 10 years, multiple investigators have studied this treatment question with mixed results. A meta-analysis of small retrospective studies found no direct evidence that elective surgery prevented recurrence, although the rate of elective surgery was higher in this subgroup of patients and choosing conservative management may result in chronic diverticular symptoms.⁴² On the other hand, a retrospective review of a large population database found significant harm with increased morbidity and mortality without resective surgery.²⁴ Predicting risk for future complicated recurrence is challenging. Associated risk factors include elevated CRP, history of diverticulitis, family history of diverticulitis, corticosteroid use, length of colon segment involved, and retroperitoneal or pelvic abscesses.^{4,57} Although younger patients may have a higher recurrence rate, they do not have a statistically significant increased risk of requiring emergency surgery or worse outcomes.⁶³ A 2020 retrospective review of a US National Readmissions Database, including 201,384 patients managed nonoperatively, found a twofold higher risk of failure within 90 days of discharge in patients with a complicated index episode.⁷

Despite the high recurrence rates, data show that recurrent episodes of complicated acute diverticulitis are not associated with increased severity, risk of mortality, or poor outcomes, and usually resolve with conservative treatment.^{26,43,58,59,62} Most complicated cases with abscess occur with the incident episode, and the risk of free perforation does not increase with repeated episodes.^{4,10,27,62} Based on evidence from these datasets and others showing that recurrence of complicated acute diverticulitis can be successfully managed conservatively, the ASCRS changed its guidelines in 2020. ASCRS previously recom-

mended elective resection based on the presence of abscesses greater than 5 cm or pelvic in location, but has downgraded to “should typically be considered” after successful nonoperative management of a diverticular abscess.⁵

In summary, recommendations for elective sigmoid resection should be based on individual patient-related factors and not the number of episodes, abscess size, or to prevent recurrence. These guidelines are based on long-term follow-up data showing lower recurrence rates and more successful nonoperative treatments.⁵

CONCLUSION

Over the past 10 years, there have been changes to the treatment paradigm for acute diverticulitis. These have been based on extensive research challenging the routine use of antibiotics in uncomplicated cases, determining the best surgical approach for complicated disease, and evaluating the indications for elective colon resection following successful nonoperative management. A lack of clarity remains regarding prevention of recurrence, benefits of elective colon resection, and long-term management of intermediate cases of complicated diverticulitis with abscess. Treatment goals should address alleviating symptoms while minimizing adverse reactions, improving quality of life, and preventing recurrence and surgical morbidity. Practice patterns regarding elective colon resection are now focused on individualized treatment. **JAAPA**

Earn Category I CME Credit by reading both CME articles in this issue, reviewing the post-test, then taking the online test at <http://cme.aapa.org>. Successful completion is defined as a cumulative score of at least 70% correct. This material has been reviewed and is approved for 1 hour of clinical Category I (Preapproved) CME credit by the AAPA. The term of approval is for 1 year from the publication date of July 2022.

REFERENCES

- Francis NK, Sylla P, Abou-Khalil M, et al. EAES and SAGES 2018 consensus conference on acute diverticulitis management: evidence-based recommendations for clinical practice. *Surg Endosc*. 2019;33(9):2726-2741.
- Meara MP, Alexander CM. Emergency presentations of diverticulitis. *Surg Clin North Am*. 2018;98(5):1025-1046.
- Swanson SM, Strate LL. Acute colonic diverticulitis. *Ann Intern Med*. 2018;168(9):ITC65-ITC80.
- Strate LL, Morris AM. Epidemiology, pathophysiology, and treatment of diverticulitis. *Gastroenterology*. 2019;156(5):1282-1298.e1.
- Hall J, Hardiman K, Lee S, et al. The American Society of Colon and Rectal Surgeons clinical practice guidelines for the treatment of left-sided colonic diverticulitis. *Dis Colon Rectum*. 2020;63(6):728-747.
- Young-Fadok TM. Diverticulitis. *N Engl J Med*. 2019;380(5):500-501.
- Al-Masroui S, Garfinkle R, Al-Rashid F, et al. Readmission for treatment failure after nonoperative management of acute diverticulitis: a nationwide readmissions database analysis. *Dis Colon Rectum*. 2020;63(2):217-225.

8. Liner K, Sandor P. Changing theories on the pathogenesis and risk factors for diverticulitis. *JAAPA*. 2018;31(10):36-41.
9. Feuerstein JD, Falchuk KR. Diverticulosis and diverticulitis. *Mayo Clin Proc*. 2016;91(8):1094-1104.
10. Shah SD, Cifu AS. Management of acute diverticulitis. *JAMA*. 2017;318(3):291-292.
11. Peery AF, Crockett SD, Murphy CC, et al. Burden and cost of gastrointestinal, liver, and pancreatic diseases in the United States: update 2018. *Gastroenterology*. 2019;156(1):254-272.e11.
12. Sartelli M, Weber DG, Kluger Y, et al. 2020 update of the WSES guidelines for the management of acute colonic diverticulitis in the emergency setting. *World J Emerg Surg*. 2020;15(1):32.
13. Morris AM, Regenbogen SE, Hardiman KM, Hendren S. Sigmoid diverticulitis: a systematic review. *JAMA*. 2014;311(3):287-297.
14. Shahedi K, Fuller G, Bolus R, et al. Long-term risk of acute diverticulitis among patients with incidental diverticulosis found during colonoscopy. *Clin Gastroenterol Hepatol*. 2013;11(12):1609-1613.
15. Lanas A. Nonsteroidal antiinflammatory drugs and cyclooxygenase inhibition in the gastrointestinal tract: a trip from peptic ulcer to colon cancer. *Am J Med Sci*. 2009;338(2):96-106.
16. Stollman N, Smalley W, Hirano I; AGA Institute Clinical Guidelines Committee. American Gastroenterological Association Institute Guideline on the management of acute diverticulitis. *Gastroenterology*. 2015;149(7):1944-1949.
17. Peery AF, Keku TO, Martin CF, et al. Distribution and characteristics of colonic diverticula in a United States screening population. *Clin Gastroenterol Hepatol*. 2016;14(7):980-985.e1.
18. Mali JP, Mentula PJ, Leppäniemi AK, Sallinen VJ. Symptomatic treatment for uncomplicated acute diverticulitis: a prospective cohort study. *Dis Colon Rectum*. 2016;59(6):529-534.
19. Chabok A, Pählman L, Hjern F, et al.; AVOD Study Group. Randomized clinical trial of antibiotics in acute uncomplicated diverticulitis. *Br J Surg*. 2012;99(4):532-539.
20. Ma W, Jovani M, Nguyen LH, et al. Association between inflammatory diets, circulating markers of inflammation, and risk of diverticulitis. *Clin Gastroenterol Hepatol*. 2020;18(10):2279-2286.e3.
21. Bolkenstein HE, Draaisma WA, van de Wall BJM, et al. Treatment of acute uncomplicated diverticulitis without antibiotics: risk factors for treatment failure. *Int J Colorectal Dis*. 2018;33(7):863-869.
22. Cohen A, Li T, Stankard B, Nelson M. A prospective evaluation of point-of-care ultrasonographic diagnosis of diverticulitis in the emergency department. *Ann Emerg Med*. 2020;76(6):757-766.
23. Cirocchi R, Randolph JJ, Binda GA, et al. Is the outpatient management of acute diverticulitis safe and effective? A systematic review and meta-analysis. *Tech Coloproctol*. 2019;23(2):87-100.
24. Rose J, Parina RP, Faiz O, et al. Long-term outcomes after initial presentation of diverticulitis. *Ann Surg*. 2015;262(6):1046-1053.
25. Gregersen R, Andresen K, Burcharth J, et al. Long-term mortality and recurrence in patients treated for colonic diverticulitis with abscess formation: a nationwide register-based cohort study. *Int J Colorectal Dis*. 2018;33(4):431-440.
26. Aquina CT, Becerra AZ, Xu Z, et al. Population-based study of outcomes following an initial acute diverticular abscess. *Br J Surg*. 2019;106(4):467-476.
27. Kaiser AM, Jiang J-K, Lake JP, et al. The management of complicated diverticulitis and the role of computed tomography. *Am J Gastroenterol*. 2005;100(4):910-917.
28. Devaraj B, Liu W, Tatum J, et al. Medically treated diverticular abscess associated with high risk of recurrence and disease complications. *Dis Colon Rectum*. 2016;59(3):208-215.
29. Mäkelä JT, Klintrup K, Takala H, Rautio T. The role of C-reactive protein in prediction of the severity of acute diverticulitis in an emergency unit. *Scand J Gastroenterol*. 2015;50(5):536-541.
30. Biondo S, Golda T, Kreisler E, et al. Outpatient versus hospitalization management for uncomplicated diverticulitis: a prospective, multicenter randomized clinical trial (DIVER Trial). *Ann Surg*. 2014;259(1):38-44.
31. Daniels L, Ünlü Ç, de Korte N, et al. Randomized clinical trial of observational versus antibiotic treatment for a first episode of CT-proven uncomplicated acute diverticulitis. *Br J Surg*. 2017;104(1):52-61.
32. Isacson D, Smedh K, Nikberg M, Chabok A. Long-term follow-up of the AVOD randomized trial of antibiotic avoidance in uncomplicated diverticulitis. *Br J Surg*. 2019;106(11):1542-1548.
33. van Dijk ST, Daniels L, Ünlü Ç, et al.; Dutch Diverticular Disease (3D) Collaborative Study Group. Long-term effects of omitting antibiotics in uncomplicated acute diverticulitis. *Am J Gastroenterol*. 2018;113(7):1045-1052.
34. Au S, Aly EH. Treatment of uncomplicated acute diverticulitis without antibiotics: a systematic review and meta-analysis. *Dis Colon Rectum*. 2019;62(12):1533-1547.
35. Wexner SD, Talamini MA. EAES/SAGES consensus conference on acute diverticulitis: a paradigm shift in the management of acute diverticulitis. *Surg Endosc*. 2019;33(9):2724-2725.
36. Lambrechts DPV, Bolkenstein HE, van der Does DCHE, et al. Multicentre study of non-surgical management of diverticulitis with abscess formation. *Br J Surg*. 2019;106(4):458-466.
37. Bohnen JM, Marshall JC, Fry DE, et al. Clinical and scientific importance of source control in abdominal infections: summary of a symposium. *Can J Surg*. 1999;42(2):122-126.
38. Marcus G, Levy S, Salhab G, et al. Intra-abdominal infections: the role of anaerobes, enterococci, fungi, and multidrug-resistant organisms. *Open Forum Infect Dis*. 2016;3(4):ofw232.
39. Sawyer RG, Claridge JA, Nathens AB, et al. Trial of short-course antimicrobial therapy for intraabdominal infection. *N Engl J Med*. 2015;372(21):1996-2005.
40. Agency for Healthcare Research and Quality. Best practices in the diagnosis and treatment of diverticulitis and biliary tract infections. www.ahrq.gov/antibiotic-use/acute-care/diagnosis/gastro.html. Accessed April 27, 2022.
41. Daniels L, Ünlü Ç, de Wijkerslooth TR, et al. Yield of colonoscopy after recent CT-proven uncomplicated acute diverticulitis: a comparative cohort study. *Surg Endosc*. 2015;29(9):2605-2613.
42. Lamb MN, Kaiser AM. Elective resection versus observation after nonoperative management of complicated diverticulitis with abscess: a systematic review and meta-analysis. *Dis Colon Rectum*. 2014;57(12):1430-1440.
43. Regenbogen SE, Hardiman KM, Hendren S, Morris AM. Surgery for diverticulitis in the 21st century: a systematic review. *JAMA Surg*. 2014;149(3):292-303.
44. Binda GA, Karas JR, Serventi A, et al.; Study Group on Diverticulitis. Primary anastomosis vs nonrestorative resection for perforated diverticulitis with peritonitis: a prematurely terminated randomized controlled trial. *Colorectal Dis*. 2012;14(11):1403-1410.
45. Bridoux V, Regimbeau JM, Ouaisi M, et al. Hartmann's procedure or primary anastomosis for generalized peritonitis due to perforated diverticulitis: a prospective multicenter randomized trial (DIVERTI). *J Am Coll Surg*. 2017;225(6):798-805.
46. Oberkofler CE, Rickenbacher A, Raptis DA, et al. A multicenter randomized clinical trial of primary anastomosis or Hartmann's procedure for perforated left colonic diverticulitis with purulent or fecal peritonitis. *Ann Surg*. 2012;256(5):819-827.
47. Lee JM, Bai P, Chang J, El Hechi M, et al. Hartmann's procedure vs primary anastomosis with diverting loop ileostomy for acute diverticulitis: nationwide analysis of 2,729 emergency surgery patients. *J Am Coll Surg*. 2019;229(1):48-55.

48. Lambrichts DPV, Vennix S, Musters GD, et al. Hartmann's procedure versus sigmoidectomy with primary anastomosis for perforated diverticulitis with purulent or faecal peritonitis (LADIES): a multicentre, parallel-group, randomised, open-label, superiority trial. *Lancet Gastroenterol Hepatol.* 2019;4(8):599-610.
49. Li D, Baxter NN, McLeod RS, et al. Evolving practice patterns in the management of acute colonic diverticulitis: a population-based analysis. *Dis Colon Rectum.* 2014;57(12):1397-1405.
50. Vennix S, Musters GD, Mulder IM, et al. Laparoscopic peritoneal lavage or sigmoidectomy for perforated diverticulitis with purulent peritonitis: a multicentre, parallel-group, randomised, open-label trial. *Lancet.* 2015;386(10000):1269-1277.
51. Angenete E, Thornell A, Burcharth J, et al. Laparoscopic lavage is feasible and safe for the treatment of perforated diverticulitis with purulent peritonitis: the first results from the randomized controlled trial DILALA. *Ann Surg.* 2016;263(1):117-122.
52. Schultz JK, Yaqub S, Wallon C, et al. Laparoscopic lavage vs primary resection for acute perforated diverticulitis: the SCANDIV randomized clinical trial. *JAMA.* 2015;314(13):1364-1375.
53. Biffi WL, Moore FA, Moore EE. The evolving role of laparoscopic lavage and drainage. *J Trauma Acute Care Surg.* 2019;86(2):376.
54. van de Wall BJM, Stam MAW, Draaisma WA, et al. Surgery versus conservative management for recurrent and ongoing left-sided diverticulitis (DIRECT trial): an open-label, multicentre, randomised controlled trial. *Lancet Gastroenterol Hepatol.* 2017;2(1):13-22.
55. El-Sayed C, Radley S, Mytton J, et al. Risk of recurrent disease and surgery following an admission for acute diverticulitis. *Dis Colon Rectum.* 2018;61(3):382-389.
56. Ho VP, Nash GM, Milsom JW, Lee SW. Identification of diverticulitis patients at high risk for recurrence and poor outcomes. *J Trauma Acute Care Surg.* 2015;78(1):112-119.
57. Sallinen V, Mali J, Leppäniemi A, Mentula P. Assessment of risk for recurrent diverticulitis: a proposal of risk score for complicated recurrence. *Medicine (Baltimore).* 2015;94(8):e557.
58. You K, Bendl R, Taut C, et al.; Study Group on Diverticulitis. Randomized clinical trial of elective resection versus observation in diverticulitis with extraluminal air or abscess initially managed conservatively. *Br J Surg.* 2018;105(8):971-979.
59. Gaertner WB, Willis DJ, Madoff RD, et al. Percutaneous drainage of colonic diverticular abscess: is colon resection necessary? *Dis Colon Rectum.* 2013;56(5):622-626.
60. Simianu VV, Strate LL, Billingham RP, et al. The impact of elective colon resection on rates of emergency surgery for diverticulitis. *Ann Surg.* 2016;263(1):123-129.
61. Andeweg CS, Berg R, Staal JB, et al. Patient-reported outcomes after conservative or surgical management of recurrent and chronic complaints of diverticulitis: systematic review and meta-analysis. *Clin Gastroenterol Hepatol.* 2016;14(2):183-190.
62. Chapman JR, Dozois EJ, Wolff BG, et al. Diverticulitis: a progressive disease? Do multiple recurrences predict less favorable outcomes? *Ann Surg.* 2006;243(6):876-883.
63. Li D, de Mestral C, Baxter NN, et al. Risk of readmission and emergency surgery following nonoperative management of colonic diverticulitis: a population-based analysis. *Ann Surg.* 2014;260(3):423-431.

Visit

www.JAAPA.com

for online-only articles, past issues, article collections, podcasts, and more!